First description of a herpesvirus infection in genus Lepus

Abade dos Santos, F.A.[1,2*], *Monteiro, M.[1], Pinto, A.[3], Carvalho, C.L. [1], Peleteiro M.C.*[2], Carvalho, P.[1], Mendonça, P.[1], Carvalho, T.[3], Duarte, M.D.[1,2]

Running title : First Herpesvirus in Iberian hare.

Corresponding author:

Abade dos Santos, F.A.

Faculdade de Medicina Veterinária, Avenida da Universidade Técnica 1300-477 Lisbon

Faas@fmv.ulisboa.pt

+351 21 365 2800

Key words

Herpesviruses, Gammaherpesvirinae, European hare, *Lepus granatensis*, Leporids

Abstract

During the necropsies of Iberian hares obtained in 2018/2019, along with signs of the nodular myxomatosis form, other unexpected external lesions were also observed. Histopathology revealed nuclear inclusion bodies in stromal cells suggesting the additional presence of a nuclear replicating virus.

Electron microscopy further demonstrated the presence of herpesvirus particles in the tissues of affected hares.

We confirmed the presence of herpesvirus in 13 MYXV-positive hares by PCR and sequencing analysis. Herpesvirus-DNA was also detected in six healthy hares, suggesting its asymptomatic circulation.

Phylogenetic analysis based on DNA polymerase gene, grouped this virus within the gammaherpesvirus cluster, close to herpesviruses from bats and rodents.

We propose to name this new virus Leporid gammaherpesvirus 5 (LeHV-5), according to the International Committee on Taxonomy of Viruses standards.

The impact of herpesvirus infection on the reproduction and mortality of Iberian hare is yet unknown but may aggravate the population loss caused by the recently emerged myxomatosis.

1. Introduction

The Iberian hare (*Lepus granatensis*), also known as Granada hare, is an endemic specie of the Iberian Peninsula whose populations are considered stable by the IUCN holding a '*least concern'* conservation status[1].

Lepus granatensis is the only hare species found in Portugal and the most widespread in the Iberia[2], therefore, highly relevant for the hunting activity in both countries and particularly for greyhound racing. Over the years, the Iberian hare has been unaffected by viral diseases that, alongside environmental and anthropogenic factors, led to the drastic decline of the wild rabbit. *Lepus granatensis* was considered naturally resistant to myxomatosis, which is endemic in Iberian Peninsula since 1956[3], despit very sporadic reports of the disease in the European brown hare (*Lepus europaeus*), namely in France and Ireland[4–6]. However, during the summer and autumn of 2018 outbreaks of myxomatosis in the Iberian hare were reported in Spain[7] and Portugal[11], respectively.

No other diseases of viral origin have been described in the Iberian hare, including any caused by Herpesviruses that may have a fatal outcome in rabbits.

Until now, four herpesviruses have been identified in leporids: Leporid herpesvirus 1 (LHV-1), Leporid herpesvirus 2 (LHV-2), Leporid herpesvirus 3 (LHV-3) and Leporid herpesvirus 4 (LHV-4) (Table 1). Of these, the most common naturally occurring herpesvirus infections identified in rabbits are LHV-2 and LHV-3 (revised on Jin et al., 2008), which alongside LHV-1 belong to the Gammaherpesvirinae subfamily. Conversely, LHV-4 is a member of the alfaherpesvirinae subfamily. These distinct herpesviruses have a broadly variable impact on the European rabbit, with LHV-2 and LHV-3 infections usually passing unnoticed, while LHV-4 is far more aggressive, causing fatal infections.

Herpesviruses are enveloped, linear dsDNA viruses, with 200-250nm in diameter, organised in four concentric layers[9], 1) a core with the DNA, 2) T=16 icosahedral capsid with about 125nm of diameter surrounded by a 3) proteinaceous tegument that contains many virus-coded proteins and enclosed in a 4) lipid envelope containing several viral glycoproteins. Morphologically, herpesviruses are distinct from all other viruses[10].

Herpesviruses belong to order *Herpesvirales* that comprises three families, namely the *Herpesviridae* family, which includes more than 100 viruses of mammals, birds and reptiles and whose members have large genomes ranging from 125 to 290kb[11], the *Alloherpesviridae* family, which includes the fish and frog viruses, and the *Malacoherpesviridae* family, which contains the bivalve virus[10].

The *Herpesviridae* family includes the subfamilies *Alphaherpesvirinae*, *Betaherpesvirinae* and *Gammaherpesvirinae* that have different biologic properties and distinct classification, supported by phylogeny. The Gammaherpesvirinae subfamily is divided into four genera, namely *Macavirus*, *Percavirus*, *Lymphocryptovirus*, and *Rhadinovirus*[10].

While the subfamily *Alfaherpesvirinae* causes rapid lysis in cell culture, members of *Betaherpesvirinae* grow slowly inducing the formation of giant cells in culture, and *Gammaherpesvirinae* typically infect lymphoid tissue, meaning a primary tropism for lymphoid lineage cells[12], which can lead to lymphoproliferative diseases[8] and oncogenesis[11]. The lack of a suitable animal model for the gammaherpesvirinae subfamily, hampers the study of the reactivation mechanisms and pathogenesis of these oncogenic viruses [13].

In this study, we investigated the presence of herpesvirus in MYXV-positive hares because during necropsies, along with the typical myxoma virus-induced skin lesions, other lesions were registered in the genitalia, palpebrae, lips and nose of the animals. Moreover, in histopathological examination, nuclear inclusion bodies compatible with Herpesvirus were also observed. To investigate the prevalence of herpesvirus in the hare populations, healthy hares were also tested.

2. Materials and Methods

2.1. Sample

A total of 38 Iberian hares, were investigated within the scope of a National surveillance program (Dispatch 4757/17, 31th may)[14] in action since August 2017. Of these, 16 were males, 20 females and two failed sex-determination. Eighteen were hunted during the 2018/2019 legal season (October to December), while 20 were found dead in the field between October 2018 and June 2019. The hares originated from south Portugal namely from the districts of Santarém, Beja and Évora.

2.2. Necropsy and Histopathology

Cadavers were necropsied and spleen, liver, lung, duodenum and skin samples (namely scrotum, lips and nose) were collected for virology, bacteriology and histopathology. The entire gastrointestinal tract was taken for parasitological analysis. From hunted hares, only spleen, liver and lung samples were received at the laboratory.

For histopathology, skin and genitalia fragments were fixated in 10% neutral buffered formalin, routinely paraffin embedded, sectioned at 4 µm, and stained with H&E.

2.3. Transmission electron microscopy

The fragments selected for transmission electron microscopy (TEM) were formalin fixated for 48h or on a solution 0.1M sodium cacodylate (sigma©) containing 2.5% gluteraldehyde (sigma©) for 72h. For samples previously included in paraffin, the regions of interest were extracted from the block, sliced smaller than ~1mm^3 with a scalpel blade into two separate viles, and washed thoroughly in xylene. After rehydration using decreasing concentrations of ethanol, fragments were washed in 0.1M cacodylate buffer[15]. Samples were then post-fixed with 2% osmium tetroxide (EMS) for 30min, and stained in block with 1% Millipore-filtered uranyl acetate (Agar Scientifics), after which they were dehydrated in increasing concentrations of ethanol, infiltrated and embedded in EMBed-812 hard (EMS). Polymerization was performed at 60°C for 2days. Ultrathin sections were cut either in a UC7 ultramicrotome or in a Reichert ultracut E ultramicrotome (Leica), collected to 1% formvar coated copper slot grids (Agar scientific), stained with uranyl acetate and lead citrate (Sigma) and examined in a H-7000 transmission electron microscope (Hitachi) at an accelerating voltage of 100 kV or Jeol 1400plus transmission electron microscope at an accelerating voltage of 120 kV. Digital images were obtained using a Megaview mid mount digital camera (Olympus) or using a AMT XR16 bottom mid mount digital camera (AMT©). The sections were systematically analysed using AMT© software and several high and low magnifications were acquired.

2.4. Bacteriological and Parasitological examination

Liver, spleen and lung samples were analysed using standard bacteriological methods. Parasitological examination of the intestine was carried out resourcing to direct wet mount, sedimentation and filtration techniques.

2.5. Virological examination

All the animals were tested for rabbit haemorrhagic disease virus 2 (RHDV2) and Myxoma virus (MYXV) by real time PCR systems described before[12,22]. LHV-4 was investigated specifically by using the PCR described by Jin et al, 2008[8]. A generalist nested PCR directed to the herpesviral *DNA polymerase* that allows the detection of several species herpesviruses (Devanter et al. 1996) was also used (Table 2).

For nucleic acid extraction, fresh samples of liver and spleen were homogenised at 10% with phosphate buffered saline (PBS) and clarified at 3000g for 5 min. Total DNA and RNA were extracted from 200µl of the clarified supernatants, using the MagAttract 96 cador Pathogen Kit in a BioSprint 96 nucleic acid extractor (Qiagen, Hilden, Germany), according to the manufacturer's protocol.

Amplifications were carried out in a Bio-Rad CFX96™ Thermal Cycler (Bio-Rad Laboratories Srl, Redmond, USA), using the One Step RT-PCR kit (Qiagen, Hilden, Germany) for RHDV2, and the HighFidelity PCR Master Mix (Roche Diagnostics GmbH, Mannheim, Germany), for MYXV and herpesvirus detection, respectively.

All amplifications were performed as described in Table 2.

2.6. Sequencing analysis

The PCR product was visualised in 2% horizontal electrophoresis agarose gel, purified using the NZYGelpure kit (NZYTECH), and directly sequenced using the ABI Prism BigDye Terminator v3.1 Cycle sequencing kit on a 3130 Genetic Analyser (Applied Biosystems, Foster City, CA, U.S.A). Nucleotide forward and reverse sequences were analysed, assembled into consensus sequences, and submitted to GenBank. The nucleotide sequences were translated using Mega X 10.1 software.

2.7. Phylogenetic analysis

Partial nucleotide and amino acid sequences of the viral *DNA polymerase* were aligned using the Clustal W with gap opening penalty and a gap extend penalty of 30 and 15, respectively.

For both sets of data, evolutionary analyses were conducted in MEGA X[19].

The model for both phylogenies was selected by *Model function* (MEGA X). LG+G model according to BIC (4355.57) and AICC (3943.54) criteria was selected for the protein- based tree.

The phylogeny partial nucleotide sequences of gammaherpesviruses was inferred by using the Maximum Likelihood method and Tamura 3-parameter model[20]. The bootstrap consensus trees were inferred from 1000 replicates[21].

2.8. Herpesvirus isolation

Isolation of herpesvirus was attempted from organs of MYXV and Herpesvirus co-infected hares, namely from liver and spleen, penile and vulva samples. In addition, liver and spleen samples from two hares infected with Herpesvirus alone, were also used.

Samples were homogenized at 20% in phosphate-buffered saline containing penicillin, streptomycin and amphotericin B (antibiotic-antimycotic), used according to the manufacturer (Gibco, Life Technologies Corporation). Following centrifugation, the supernatant was filtered through a 0.45-µm-pore-size filter (Millipore Express) and used to inoculate sub 70% confluent Candrel R Feline Kidney (CRFK) epithelial cells, Vero cells and Rabbit Kidney (RK13). RK13 grown in Eagle medium and the others in Dulbecco's modified Eagle's Media was supplemented with 10% foetal calf serum (Gibco) and 50µg/ml gentamicin (Gibco). Cells were maintained at 37°C under a humidified atmosphere with 5% CO2 and observed daily for cytopathic effect (CPE) by microscopy. Three passages were carried out and the supernatant and cell pellet of each passage tested for the presence of Herpesvirus by PCR.

3. Results

3.1. Necropsy showed lesions compatible with herpesvirus infection in Iberian hares with Myxomatosis

Overall, MYXV-positive hares revealed poor body condition and, alongside typical myxomatosis lesions, necrosis of the genitalia (most evident in males affecting the penile glans but also observed in females, affecting the vulva) was noted in over 70% of the hares studied. Other lesions observed in these hare specimens, uncommon in rabbits affected by myxomatosis, included the presence of herpetic-like skin vesicles.
Further investigation of the macroscopic lesions and histopathological patterns was carried out in hares co-infected with LeHV-5 and MYXV. At this time, we disclose the macroscopic and histopathological findings from two male hares found dead in November 2018 (#38455/18) and August 2019 (#25456/19).

Hare #38455/18 presented with eyelids thickened by the accumulation of mucopurulent exudate and marked enlargement of the penis with irregular surface measuring 1.3x1cm in diameter (normal diameter is less than 0.5cm) (Figure 1 and Figure 1A) lined with light-yellow dry exudate.

At the necropsy of hare #25456/19, ulcerated multinodular thickening of the eyelids and lips was observed. Accumulation of mucopurulent exudate in both eyes was also noted and a small vesicle was present in the lower lip (Figure 2).

3.2. Histopathology

The dermis of hare #38455/18 showed fusiform or stellate mesenchymal cell proliferation, surrounded by abundant extracellular matrix, scattered infiltration by lymphocytes and macrophages, and small aggregates of heterophiles, consistent with myxomatosis.

The penile epithelium of this hare was mostly necrotic and replaced by a thick band of necrotic cells, heterophils and red blood cells (Figure 1).

Severe heterophile infiltrations of the stroma, in either a diffuse pattern or multifocal aggregates, were also seen. In the stroma, there was proliferation of pleomorphic spindle cells, with some nuclei almost completely filled with slightly eosinophilic inclusion bodies (Cowdry type A inclusions) (Figure 3), suggesting a nuclear replicating virus. These lesions unexpected from myxomatosis are compatible with herpesvirus.

In the skin of hare #25456/19, a ballooning degeneration of keratinocytes was registered. Coalescent intra-epidermal and subepidermal vesicopustules (Figure 4) filled with fibrin and necrotic cells debris and multifocal detachment of the eyelids, lips and foreskin epidermis were seen. In the underlying dermis, multifocal haemorrhages, intense infiltration by heterophils and necrotic cells with accumulation of chromatin debris were present (Figure 4).

Below the dermis, accumulation of myxoid tissue with pleomorphic spindle cells, some of which showing rounded or oval and slightly eosinophilic intranuclear inclusion bodies, was observed (Figure 5). An infiltrate of mononucleated inflammatory cells and heterophils was present in skeletal muscle tissue.

3.3. Electron microscopy

Samples from hares #38455/18 and #25456/19, were further processed and analysed for TEM allowing the confirmation of the presence of herpesvirus in different tissues.

In the penile soft tissue of hare #38455/18 (Figure 6), spherical virions, with structure and dimensions compatible with herpesviruses, comprising an inner core packed into an icosahedral capsid, were observed in the nucleus of stromal cells, indicating nuclear replication which is an attribute of herpesviruses (Figure 2). The viral capsid contained a relatively small, asymmetrical, electron-dense region, which probably represents the condensed DNA core. In this animal, also positive to myxomatosis, no MYXV particles were found in the samples processed.

In the case of hare #25456/19, herpesviruses were visualised in epithelial and stroma cells of the eyelid (*results not shown*).

3.4. Virological, bacteriological and parasitological results

None of the 38 hares investigated in this study tested positive to RHDV, RHDV2 or LHV-4. Fifty percent of the hares were positive to LeHV-5, of which 68.4% (13/19) were also positive to MYXV.

Herpesvirus-DNA was also detected by PCR in the liver, spleen and lung samples of apparently healthy hares that tested negative for MYXV (n=7). From these hunted specimens, no genitalia/skin samples were available for histopathology. Six hares showed doubtful results.

Parasitological and bacteriological examinations did not reveal any infections that could justify the death of these animals.

3.5. Molecular characterisation of Iberian hare herpesvirus

For 19 of the 38 animals, an amplicon ~225 bp-long, compatible with herpesvirus, was obtained in the pan-herpesvirus PCR, while for six samples only a weak band was generated. The presence of herpesvirus was confirmed by sequencing analysis in 16 hares. For 11 of these amplicons, the readings obtained independently were assembled and edited, showing 100% similarity to each other. Blast analysis of the sequences confirmed that the obtained fragment is part of the Herpesvirus *DNA polymerase gene*. Comparison with other Herpesvirus sequences available in the GenBank database (03.07.2019), showed similarity, with 46% of query cover and 81.73% of identity, with an unidentified herpesvirus (KT591396.1) obtained from *Rattus norvegicus*.

Five of the obtained sequences were submitted to the Genbank and attributed the accession numbers MN557129, MN557130, MN557131, MN557132 and MN557133.

3.6. Phylogenetic analysis

The region amplified by the nested PCR has discriminatory power to allow phylogenetic inferences[18]. To investigate the phylogenetic relationship of the Iberian hare herpesviruses found by this study (represented by sequence MN557129), with other members of the Herpesviridae family, a set of 37 DNA polymerase protein sequences from alpha, beta and gammaherpesviruses, obtained in the Genbank, were edited to contain a 68 aa-residue region.

Unrooted Maximum Likelihood tree showed that the herpesvirus sequence from *Lepus granatensis* clearly groups within the gammaherpesvirinae cluster (Figure 7). MN557129 appears to share a common ancestor with gammaherpesviruses from *Scotophilus kuhlii* (Genbank access numbers ALH21079.1, KR261869.1 and ALH21071.1), a small insectivore bat native of Asia and India, as well as with some rodents (Genbank access numbers KT591396.1, KT591394.1 and others) despite supported by a low bootstrap value (<25) (Figure 7).

To refine the phylogenetic analysis with regards to gammahespesviruses (Figure 8), we explored the nucleotide variability among this group, using a second set of 25 herpesviruses sequences from orders Artiodactyla, Carnivora, Chiroptera, Lagomorpha, Perissodactyla, Primates and Rodentia. The access numbers of the original sequences from which the *DNA Polymerase* 225nt long sequences were edited, are indicated in Figure 8.

This phylogenetic analysis confirmed that the leporid herpesvirus under study is a gammaherpesvirus, more closely related to herpesviruses from *Scotophilus kuilii*, of unclassified genera.

According with the most recent International Committee on Taxonomy of Viruses (ICTV) guidelines for classification of viruses, we propose to name this virus species leporid gammaherpesvirus 5 (LeHV-5), following the rabbit alphaherpesvirus 4 (LHV-4), although we cannot suggest a genus for LeHV-5.

3.7. Isolation of the viruses in cell cultures

The fact that LeHV-5 is a gammaherpesvirus may explain the difficulties found in viral isolation, which was not achieved with either of the two strategies adopted.

Despite LeHV-5 not appearing to multiply in human (Hela) and primate (Vero) cells, because gammaherpesviruses may be zoonotic, as is the case of cercopithecine herpesvirus-1 and murine gamma herpesvirus[13], isolation attempts was performed under BSL-2 conditions.

4. Discussion and Conclusion

This study describes the detection of a new gammaherpesvirus in the genus Lepus that, according to the present databases, is more similar to bats' and rodents' herpesviruses.

Viral isolation was not accomplished in RK13, CRFK or Vero cells. The difficulty in growing the virus *in vitro*, an important step towards its characterisation, may be related

to the co-infection with MYXV. The greater ease in multiplication of MYXV, which grows in many cell cultures[22,23], may hamper herpesvirus isolation. Moreover, wild animal samples are frequently somewhat autolysed and usually frozen before reaching the laboratory, which may lead to herpesvirus inactivation. The complexity in isolating genital gammaherpesvirus in cell culture was also referred by Saliki et al. (2006). The lack of cell cultures from Lepus species may pose further challenges.

Our investigation revealed the presence of necrosis of the genitals and herpetic-like vesicles in the lips of hares co-infected with LeHV-5 and MYXV, which were attributed to herpesvirus.

Notwithstanding the sampling limitation, the fact that macroscopic lesions were only seen in animals with myxomatosis, suggests that MYXV may play a role on herpesvirus replication and/or reactivation by compromising the immune response of the host, leading to the development of clinical disease with exuberant lesions. Immunosuppression facilitates herpesviruses' infections and virus reactivation and it was demonstrated that certain MYXV proteins, such as Serp-1, have strong immune suppressing effects[23]. MYXV infection may hence represent a stress and/or immunosuppressive triggering factor for herpesvirus. It is known that stress, disease and other factors such as extreme temperatures can lead to the resurgence of herpesviruses in other species[25]. It was observed that depressed T-cell immune function reduces the quality of immune surveillance resulting in the increase of viral activity [13].

Herpesviruses generally follow one of three distinct strategies[13] within the host, namely i) latency with occasional re-emergence, ii) hit-and-run' approach and iii) slow-and-low' tactic [13].In the case of LeHV-5, because it affects wildlife, specimens are mainly animals found dead or moribund, limiting the conclusions on the strategy of the virus.

In addition, herpesviruses are frequently found either in the absence of clinical signs or in association with very diverse clinical signs[26].This fact complicates the understanding of the true role and contribution of many herpesviruses in the courses of certain diseases, especially with regards to wild species that are often exposed to, and infected by, many pathogens. On the other hand, animal experimentation is complicated by the absence of available specific pathogen free (SPF) specimens, and by the difficulties in keeping hares in captivity, limiting cause-effect experiments. Moreover, during latency, herpesviruses may not be detected by current methods, as it is the case of γ-HV in horses, resulting in an underestimated prevalence in the populations[26,27].Reports indicate that Equine herpesvirus 2 (EHV-2) can be detected in immuncompetent animals in the absence of signs of disease (revised on Marenzoni et

al., 2015), meaning that healthy animals can be a potentially source of viral transmission.

According with our study, based on viral DNA amplification, around half of animals tested (63% symptomatic and 37% asymptomatic) were positive to herpesvirus. However, this value may be an underestimation given that the tropism of LeHV-5 is still unknown, and consequently the tissue samples used for diagnosis may have been inadequate. This means that we cannot assure that PCR negative animals were not infected by LeHV-5.

The fact that herpetic lesions were not observed in young, could mean that if the acquisition of LeHV-5 occurs at an early age, primary infection takes place with mild or no symptoms. In the absence of an unbalancing triggering factor such as MYXV infection, LeHV-5 may successfully establish a long-term relationship with the hare host, with subclinical disease and transient viremia. This would explain the detection of Herpesvirus DNA in apparently healthy hares.

Interestingly, the gammaherpesvirus identified in external genitalia of the investigated hares was not associated with the development of papillary lesions as in other genital gammaherpesviruses' infections[24]. However, given hunters, hunting managers and landowners are of the opinion that the reproduction of the Iberian hare has been declining in recent years, it is important to clarify if this reduction is also associated with the emergence or circulation of LeHV-5. Other important concern is the potential production of oncogenic proteins by this herpesvirus.

According to our findings, genital herpesvirus may have a critical effect on hares' fertility and reproduction as well as in their survival. Hence, it is crucial to evaluate and understand the extent to which MYXV plays a role in the infection/reactivation of herpesvirus, as well as the putative role of herpesvirus in favouring infection of hares by MYXV or aggravating the severity of myxomatosis clinical forms.

The virological results obtained in this study also disclosed the infection of apparently healthy hares by LeHV-5, suggesting the possible circulation of this virus in the wild populations in a systemic subclinical form.

Although Iberian hare populations are still considered stable, no census is available for the hare populations in Portugal.

Presently, we continue monitoring apparently healthy and MYXV-positive hares in mainland Portugal to determine the extent of the geographic distribution of LeHV-5 among the wild hare populations, and the putative association of herpesviruses with the virulence of the recent emerged hare myxoma virus.

It is important to evaluate the geographical distribution of the virus, the epidemiology of the disease, the real extent and severity of the lesions induced in hares by LeHV-5,

the persistence and latency of herpesvirus in the wild populations and the LeHV-5-MYXV associated pathology in order to predict the consequences of the LeHV-5 infection at population level and to evaluate its importance in the future of this iconic species.

References

1. Soriguer, A. Lepus granatensis , Granada Hare. **8235**, (2019).
2. Palacios, F. On the taxonomic status of the genus Lepus in Spain. *Acta Zool. Fennica* **17**, 27–30 (1983).
3. Fenner, F. & Fantini, B. History of Myxomatosis - an Experiment in Evolution. in *Biological Control of Vertebrate Pests* (1999).
4. Barlow, A. *et al.* Confirmation of myxomatosis in a European brown hare in Great Britain. *Vet. Rec.* **175**, 75–76 (2014).
5. Collins, J. J. Myxomatosis in the common hare. *Ir. Vet. J.* **9**, **268**, (1955).
6. Wibbelt, G. Infectious Diseases in European Brown Hare (Lepus europaeus). (2014). doi:10.2461/wbp.2005.1.11
7. Bocanegra, I. G., Dalton, K. P. & Gómez, J. C. First outbreak of myxomatosis in Iberian hares (Lepus granatensis). 1–5 (2019). doi:10.1111/tbed.13289
8. Jin, L. *et al.* Characterization of a novel alphaherpesvirus associated with fatal infections of domestic rabbits. *Virology* **378**, 13–20 (2008).
9. C. Brown, J. & W. Newcomb, W. Herpesvirus Capsid Assembly□: Insights from Structural Analysis. *Curr. Opin. Virol.* **1**, 142–149 (2011).
10. Davison, A. J. *et al.* The order of Herpesvirales. *Arch. Virol.* **154**, 171–177 (2009).
11. Sunohara-Neilson, J. R., Brash, M., Carman, S., Nagy, É. & Turner, P. V. Experimental infection of New Zealand white rabbits (Oryctolagus cuniculi) with leporid herpesvirus 4. *Comp. Med.* **63**, 422–431 (2013).
12. David M. Knipe, P. M. . Fields Virology. in *Fields Virology* (eds. Williams, L. & Wilkins) (2013).
13. Grinde, B. Herpesviruses: latency and reactivation□? viral strategies and host response. *J. Oral Microbiol.* **5**, 125–136 (2013).
14. OIE. Myxomatosis, Portugal. (2018). Available at:

https://www.oie.int/wahis_2/public/wahid.php/Reviewreport/Review?page_refer=MapFullEventReport&reportid=28628.

15. Graham, L. & Orenstein, J. M. Processing tissue and cells for transmission electron microscopy in diagnostic pathology and research. *Nat. Protoc.* **2**, 2439–2450 (2007).
16. Duarte, M. D. *et al.* A real time Taqman RT-PCR for the detection of rabbit hemorrhagic disease virus 2 (RHDV2). *J. Virol. Methods* **219**, 90–95 (2015).
17. Duarte, M. D. *et al.* Development and validation of a real time PCR for the detection of myxoma virus based on the diploid gene M000 . 5L / R. *J. Virol. Methods* **196**, 219–224 (2014).
18. Devanter, D. R. V. A. N. *et al.* Detection and Analysis of Diverse Herpesviral Species by Consensus Primer PCR. **34**, 1666–1671 (1996).
19. Kumar, S., Stecher, G., Li, M., Knyaz, C. & Tamura, K. MEGA X: Molecular Evolutionary Genetics Analysis across computing platforms. Molecular Biology and Evolution. (2018).
20. Tamura, K. Estimation of the number of nucleotide substitutions when there are strong transition-transversion and G + C-content biases. *Mol. Biol. Evol.* **9**, 678–687 (1992).
21. J., F. Confidence limits on phylogenies: An approach using the bootstrap. *Evolution (N. Y).* **39**, 783–791 (1985).
22. Fenner, F. & Ratcliffe, F. N. Myxomatosis. *Cambridge Univ. Press. London, UK.* (1965).
23. Spiesschaert, B., Mcfadden, G., Hermans, K., Nauwynck, H. & Walle, G. R. Van De. The current status and future directions of myxoma virus , a master in immune evasion. *Vet. Res.* **42**, 76 (2011).
24. Saliki, J. T. *et al.* A Novel Gammaherpesvirus Associated with Genital Lesions in a Blainville's Beaked Whale (Mesoplodon densirostris). *J. Wildl. Dis.* **42**, 142–148 (2006).
25. Izumi, Y. *et al.* Characterization of bovine herpesvirus type 4 isolated from cattle with mastitis and subclinical infection by the virus among cattle. *J. Vet. Med. Sci.* **68**, 189–193 (2006).
26. Marenzoni, M., Stefanetti, V., Danzetta, M. L. & Timoney, P. J. Gammaherpesvirus infections in equids: a review. *Vet. Med. Res. Reports* 91 (2015). doi:10.2147/vmrr.s39473
27. Williams, K. J. *et al.* Experimental Induction of Pulmonary Fibrosis in Horses with the Gammaherpesvirus Equine Herpesvirus 5. *PLoS One* **8**, 1–15 (2013).

Table 1 – Summary of the characteristics of the four herpesviruses identified in leporids.

Type	Subfamily	Genus/Specie	Name	Host	Physiopathology	Others
LeHV-1	γ	Viruses which may be members of the genus Rhadinovirus [35] but have not been approved as species [36].	Cottontail herpesvirus	*Sylvilagus floridanus* *Oryctolagus cuniculus* not infected		Isolated from primary kidney cells cultures [17]. No report of disease in domestic rabbits [37,38].
LeHV-2	γ		Herpesvirus cuniculi	*Oryctolagus cuniculus*	. Some evidences of a subclinical encephalitis after infection of New Zealand white rabbits [39].	LHV-2 was isolated in 1968 from kidneys of apparently healthy Sylvilagus floridanus [37]. Oryctolagus cuniculus is the natural host but infection is asymptomatic [40]
LeHV-3	γ		Herpesvirus sylvilagus	*Sylvilagus floridanus* *Oryctolagus cuniculus* not infected	Lymphoproliferative disease and tumor-like lesions in lymph nodes, kidney, spleen, and liver [37,41] .	Isolated from primary kidney cells cultures [17]. Hinze (1971) isolated in DRK-3 cells. CPE appear after 10-15 days of inoculation. Infected cells show focal areas of round and distorted cells, and in 1-2 days, emerged syncytial masses containing 50 or more nuclei. H&E coloration show typical type A intranuclear inclusions in the infected cells. Complete cell destruction occurred after a 5-7 days period. Not isolated in WI-38, HeLa, Chang's conjunctiva, human amnion (FL), green monkey kidney (Vero), primary rhesus monkey kidney, primary hamster kidney, BHK-21, primary mouse embryo, and primary chick embryo [41].
LeHV-4	α	Leporid alphaherpesvirus 4		*Oryctolagus cuniculus*	Lethargy, anorexia, conjunctivitis, fever, and abortion. Hemorrhagic dermatitis, splenic necrosis, hepatic necrosis, and multifocal pulmonary hemorrhage and edema. Distinctive glassy eosinophilic herpetic intranuclear inclusion bodies were observed in the skin and mesenchymal cells of the spleen and lung [19,42].	Isolated in rabbit skin (RS), RK13 and Vero cells. [19]. CPE characterized by syncytium formation, cell enlargement, and cell lysis, similar to human herpesvirus type 1 (HHV-1). Jin et al. (2008) verified that in rabbits inoculated with LHV-4, the appendix, sciatic nerve, kidney, adrenal gland, and many other organs were positive for the virus at the 5 days post infection(dpi), while at the 14 dpi only trigeminal ganglia eye and tonsil were positive.

Table 1 – Reaction conditions used in the molecular diagnosis for search of different virus.

Primer	Sequence (5'-3')	Amplicon size (bp)	Amplification conditions	Reference
RHDV2-F	TGGAACTTGGCTTGAGTGTTGA	127	50◦C -45min 95◦C-15min 50x (95◦C-15s 60◦C-30s 72◦C-30s)	21
RHDV2-R	ACAAGCGTGCTTGTGGACGG			
RHDV2-Probe	[FAM]-TGTCAGAACTTGTTGACATCCGCCC-[TAMRA]			
M000.5R/L-F	CGACGTAGATTTATCGTATACC	125	95◦C- 10min 45X (95◦C-30s 50ºC-30s 60◦C-30s)	22
M000.5R/L-R	GTCTGTCTATGTATTCTATCTCC4			
MYXV-probe	[FAM]-TCTATGTCTGCCCGAGGATAGA-[TAMRA]			
LHV-4 F1F	ATGACGCCCACCAACGTCTC	1617 1162 945	95ºC-10min 35x (95º-15s 54ºC-20s 72ºC-3min) 72ºC-10min	42
LHV-4 F2F	GCACAGTGTGTGTTAGACG			
LHV-4 F3F	TGTGGCCAAGAACAACGATA			
LHV-4 F1R	CATAGACCGTAGGCGGTTC			
LHV-4 F2R	ACGTGAACAGGAACCGGTAG			
LHV-4 F3R	CTAGAGGTCGTTCACCACCG			
LHV DFA (F 1st round)	GAYT TYGCNAGYYTNTAYCC	215 to _315	94ºC- 10min 35x (94ºC-60s 46ºC-60s 72ºC-3min)	23
LHV ILT (F1st round)	TCCTGGACAAGCAGCARNYS GCNMTNAA			
LHV TGV (F1st round)	TGTAACTCGGTGTAYGGNTTYACNGGNGT			
LHV KG1 (R 2ndround)	GTCTTGCTCACC AGNTCNACNCCYTT			
LHV IYG (R 2nd round)	CACAGAGTCCGTRTCNCCRTADAT			

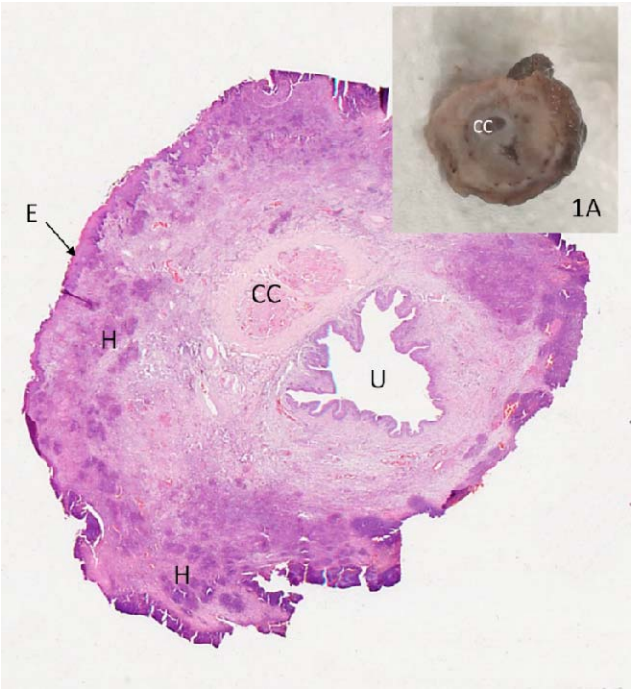

Figure 1 - Cross section of the penis of hare #38455/18 after fixation and H&E staining. E- penis epithelium CC- corpus cavernosum, U- penile urethra, H- stromal heterophils aggregates. H&E, 4x. 1A – Cross section of penis. 53x57mm (300 x 300 DPI)

Figure 2 - Lower lip vesicle of hare #25456/19 (arrow). Nodular thickening of lips and eyelids.

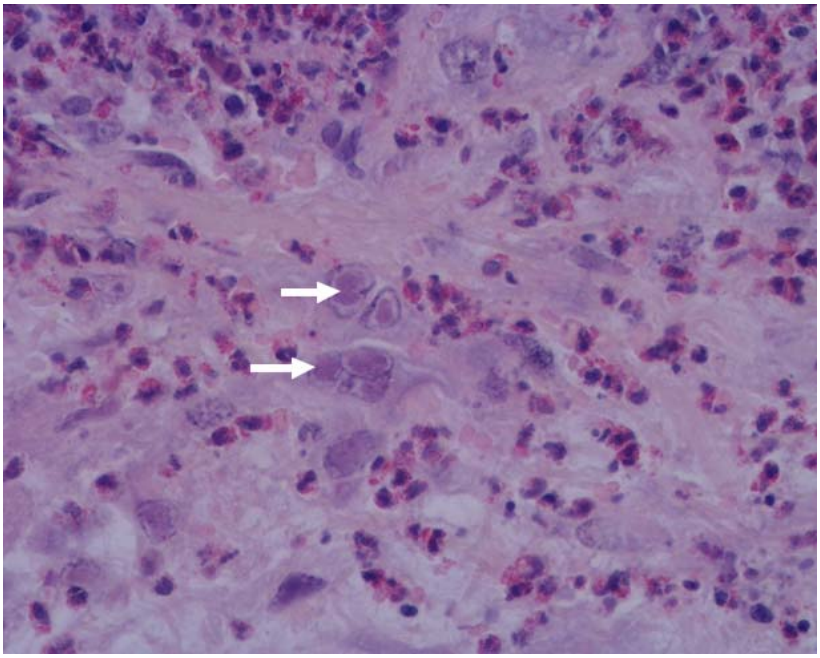

Figure 3 - Penis of hare #38455/18. Intranuclear inclusion bodies in mesenchymal cells (arrow) and moderate to severe infiltration by heterophils. H&E, 400x.

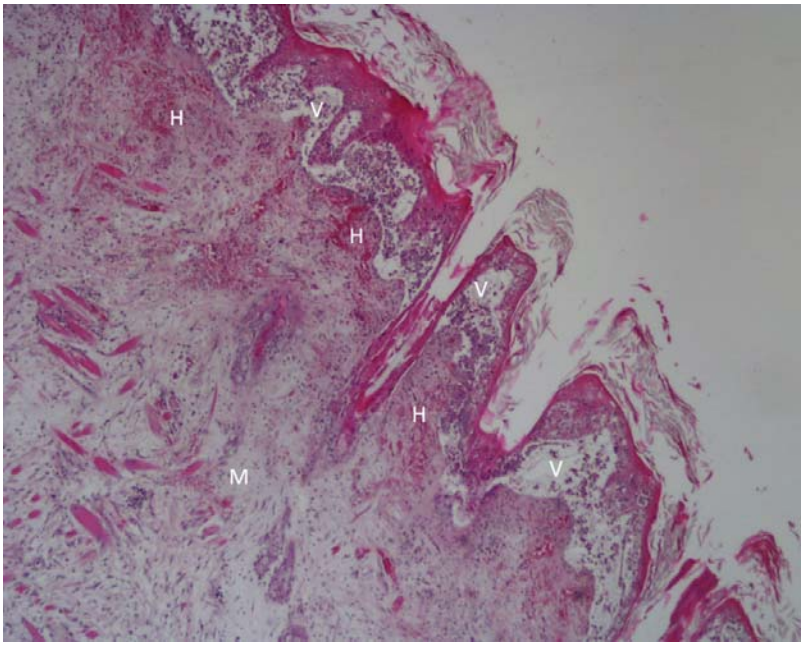

Figure 4 - Histopathological examination of the lip of hare #25456/19. M-mixomatous tissue in the dermis, Hmicrohemorrhages, V-Intraepidermal vesicopustules between the dermis and the epidermis. H&E, 40x

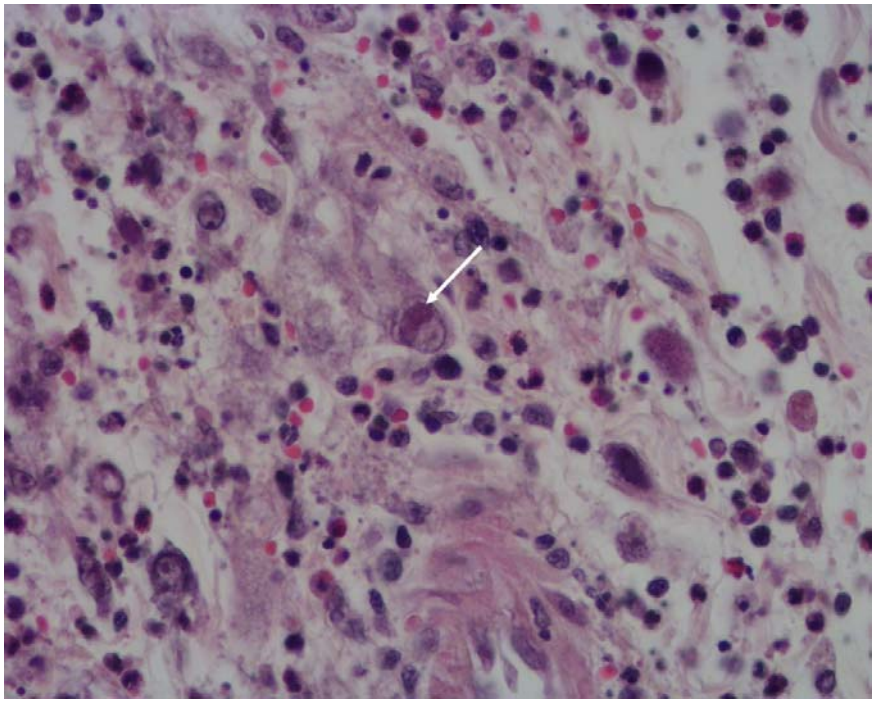

Figure 5- Histopathological examination of the lip of hare #25456/19. Intranuclear inclusion body in a mesenchymal cell (arrow). H&E, 400x

- **Acknowledgements**

We thank Sebastião Miguel (Hunting manager), João Carvalho (ANPC), Jacinto Amaro (FENCAÇA), Fernando Castanheira Pinto (CNCP) and Duarte Nuno (ICNF) for sample collection and organization of the sampling events. We are also greateful to Teresa Fagulha (INIAV, Virology Laboratory) for help with molecular characterization and to Maria João (INIAV, Virology Laboratory) for technical assistance. Finally we also thank to all the hunters who participated in field work and sample collection.

Declarations

This article didn't use live animals and was carried out within the scope of a National Plan for the Control of Rabbit Haemorrhagic Disease Virus 2 in rabbits (Dispatch no. 4757/2017 of 31 May), with the legal authorizations from the National Authority, the Instituto da Conservação da Natureza e Florestas (ICNF).

- **Funding**

Most of the field and laboratory work referred to in this manuscript was supported by the Fundação para a Ciência e Tecnologia (FCT) (Grant SFRH/BD/137067/2018), Fundo Florestal Permanente (Government of Portugal) in the scope of the Action Plan for the Control of Rabbit Viral Haemorrhagic Disease (+COELHO, Dispatch no. 4757/2017 of 31 May) and by the Interdisciplinary Research Centre on Animal Health, Faculty of Veterinary Medicine, University of Lisbon (CIISA, FMV-UL) (Portugal) (Project UID/CVT/00276/2013).

Funding bodies played no direct role in the design or conclusion of the study.