Hippocampal volume in Provisional Tic Disorder predicts tic severity at 12-month follow-up

Soyoung Kim[1], Deanna J. Greene[1], Carolina Badke D'Andrea[1], Emily C. Bihun[1], Jonathan M. Koller[1], Bridget O'Reilly[1], Bradley L. Schlaggar[2,3], and Kevin J. Black[1]

[1]Washington University in St. Louis
[2]Kennedy Krieger Institute
[3]The Johns Hopkins University School of Medicine

February 5, 2020

Abstract

Background: Previous studies have investigated the relationships between the volumes of subcortical structures (e.g. caudate, putamen, thalamus, amygdala, hippocampus) and present tic symptom severity or future tic outcome in individuals with Tourette syndrome (TS). The largest such study found increased hippocampal volume in children with TS, but studies in adolescents and adults found the opposite. Subcortical volumes have not been studied in children in their first year after tic onset.

Objective: This study aimed to examine whether the volumes of subcortical structures measured shortly after tic onset can predict tic symptom severity at the one-year anniversary of tic onset, when TS can first be diagnosed.

Methods: We obtained T1-weighted structural MRI scans from 40 children (24 with prospective motion correction [vNavs]) whose tics had begun less than 9 months (median 3.7 months) prior to the first study visit (baseline). We re-examined them at the 12-month anniversary of their first tic (follow-up), assessing tic severity using the YGTSS. We quantified the volumes of subcortical structures using volBrain software.

Results: Hippocampal volume measured at the baseline visit correlated with tic outcome at the 12-month follow-up, with a larger hippocampus at baseline predicting worse tic outcome at follow-up. The volumes of other subcortical structures did not predict tic outcome at follow-up.

Conclusion: These findings suggest that hippocampal volume may be an important marker in predicting prognosis in Provisional Tic Disorder.

Introduction

Tic disorders are neurodevelopmental disorders defined by the presence of tics - sudden, rapid, recurrent, nonrhythmic motor movements or vocalizations [1]. Tics are very common, appearing in at least 20% of children in elementary school [2]. Provisional Tic Disorder (PTD) is diagnosed when tics have been present for less than a year. Tic symptoms may persist over one year but with variability in severity across individuals; while most children experience improvement in tic symptoms within the first few months, some children may show worsening of tic symptoms which can impair quality of life [3]. Better prognostic ability in PTD may lead to patient-specific treatment, with a focus on those who are at risk of tic symptom worsening. Biomarkers identified in this population with only a short duration of tics are more likely to be related to the primary cause of tics, while findings from patients with Tourette syndrome or Chronic Tic Disorder (hereafter "TS"), who have had tics for a year or more, may be confounded by secondary, compensatory changes. The goal of the current study was to identify volumetric MRI biomarkers that can predict a one-year tic outcome in children with recent-onset tics (*i.e.*, tic duration < 9 months).

Quite a few cross-sectional studies examined the group differences in subcortical structure volumes between individuals with diagnosed TS and controls. However, the results are inconsistent. Reduced caudate volume has been reported in TS children [4]; [5] and adults [5]; [6]; [7], but a large multi-site study found no significant differences in caudate volumes between children with TS and age-matched controls [8]. Discrepant results have been found for other subcortical structure volumes as well. Some studies reported smaller volumes in the putamen ([5] [possibly due to OCD symptoms]; [9]), thalamus [4]; [10], and hippocampus [11], while other studies reported larger volumes in TS individuals forthe putamen [11]; [12]; [13], thalamus [14]; [15]; [8], hippocampus [16], and amygdala ([16]; [17] in TS with co-morbid ADHD). Some studies reported significant volume differences only in TS with comorbidities such as smaller globus pallidus in children with TS and ADHD [18] or smaller hippocampal volume in adults with TS and OCD [19].

The only longitudinal MRI study of children with TS showed that a smaller caudate nucleus in childhood predicted more severe tics and other symptoms an average of 7.5 years later [9]. However, this hypothesis has not been studied in children in their first year after tic onset. We hypothesized *a priori* (https://osf.io/y5vxj/) that a smaller caudate volume in children with recent-onset tics (hereafter "NewTics") would predict worse tic outcome at the one-year anniversary of tic onset; *i.e.*, that tics would worsen or show less improvement.

We extended our hypothesis beyond a priori hypothesis, and examined whether the volume of other subcortical structures could predict tic outcome within the NewTics group. We also recruited age-matched participants with diagnosed TS and tic-free controls (hereafter "Tic-free"). We hypothesized that the volumes of subcortical structures will differ between children with tics (i.e. NewTics and TS) and age-matched tic-free controls . We used a fully automatic segmentation tool, volBrain (http://volbrain.upv.es) to estimate the volume of the caudate, putamen, pallidum, thalamus, hippocampus, amygdala, and nucleus accumbens [20]. volBrain showed superior accuracy in segmenting all 7 subcortical structures [20] compared to other publicly available software packages, FreeSurfer [21] and FSL-FIRST [22]. Although the hippocampus is known to be difficult to segment [23], another study showed that volBrain showed high dice similarity indices in comparison to manual segmentation in segmenting hippocampus [24]. Since we found significant results with the volume of the hippocampus, we conducted an additional analysis using volBrain HIPS pipeline [25] for hippocampus subfield segmentation.

Although null results are not strong evidence for no differences, we should note that Greene and colleagues carefully controlled the scan quality, and studied a large sample. The quality control of head motion artifact is important in the studies comparing morphometry in clinical and control groups, as motion can be increased in clinical groups [26]. Previous studies showed that scan images with motion artifact produced smaller estimated subcortical volumes [27]; [28]. In order to reduce the motion artifact, we adopted prospective motion correction (vNav, [29]) in our recent data collection. All scans with and without vNav sequences were carefully quality controlled and scans contaminated by visible artifact were excluded.

Methods

Participants

NewTics is a longitudinal study of recent-onset tic disorder conducted at Washington University School of Medicine, St. Louis, Missouri (www.newtics.org). Here we report the results of structural MRI data collected between Sep 2010 and Dec 2019. We enrolled children aged 5-10 years in three different groups: 1) NewTics group who started to show tics within 9 months from the baseline session, 2) TS control group who had tics for more than one year (i.e., children with Tourette's Disorder or Persistent Tic Disorder), 3) Tic-free control group (no tics by history, examination, or audiovisual observation). This study consists of baseline and 12-month follow-up sessions. The baseline visit included neuropsychological tests and clinical examination on one day and an MRI scan visit (functional and structural MRI) within one week of the baseline visit. Clinical examination was repeated at a follow-up session 12 months after the best estimate

date of the first definite tic. All participants who completed the study by Dec 2019 were included in the current study. For additional MRI data, we turned to other studies at our center for 11 children with TS and 22 children without tics. Initially, we had 54 participants in the NewTics group, 38 participants in the TS group, and 41 participants in the Tic-free group. After scan quality control (see Scan QC below), 41 NewTics, 34 TS, and 40 Tic-free participants remain for analyses. Table 1 shows the characteristics of these participants. Table 2 shows symptom status in the NewTics group at the baseline and 12-month follow-up visits.

Variable	NewTics	TS	Tic-free
N	41	34	40
Sex	30 M/11F	25 M/9F	29 M/11F
Age	7.87±1.61 (5.41-10.81)	8.33±1.55 (5.11-10.99)	8.09±1.59 (4.05-10.92)
Tic duration (year)	0.34±0.16 (0.07-0.73)	3.08±1.67 (1.07-6.63)(N=22)	n/a
YGTSS total tic (TTS)	17.59±6.1 (7-32)	18.59±6.54 (7-30)	n/a
YGTSS impairment	8.29±8.56 (0-30)	11.3±13.07 (0-40)(N=23)	n/a
ADHD diagnosis*	14	17 out of 30	10 out of 26
OCD diagnosis*	3	5 out of 30	0 out of 26
N with brain active medications*	9	8 out of 23	8 out of 26

Table 1: Characteristics of the participants in the NewTics, TS, and Tic-free Groups. *Full clinical data were not available for some participants whose data came from other studies.

Variable	Baseline visit	12-mo Follow-up
N	41	41
Tic duration (days)	123.07±58.52 (25-268)	371.71±11.13 (355-409)
YGTSS total tic (TTS)	17.59±6.1 (7-32)	13.78±7.6 (0-37)
YGTSS impairment	8.29±8.56 (0-30)	4.63±6.84 (0-20)
DCI	33.24±14.36 (12-80)	43.41±15.85 (13-79)
PUTS	13.66±5.39 (9-31)(N=38)	15.32±5.65 (9-30)
ADHD Rating Scale (ARS)	13.41±11.81 (0-40)	15.05±11.92 (0-41)
ADHD diagnosis	14	17
CY-BOCS	3.95±6.45 (0-26)	6.93±8.62 (0-26)
OCD diagnosis	3	9
SRS	48.83±10.01 (35-78)	N/A

Table 2: Characteristics of the NewTics group participants at the baseline and 12-month follow-up session

MRI Acquisition

To improve scan quality, participants entered a mock scanner on the day of clinical examination and played a statue game at home to practice holding still. On the MRI day, scans lasted about one hour to collect T1-weighted scans, T2-weighted scans, resting-state fMRI, and pCASL images. Scan quality was checked immediately after the acquisition, and sequences were repeated if necessary. In the current study, high-resolution T1-weighted MPRAGE images covering the whole brain were analyzed. Different scanners and sequences were used depending on the period (Cohort 1: Siemens TRIO 3T MRI scanner, 176 slices, FOV=224 $\times$ 256, 1 mm isotropic resolution, TR=2200 ms, TE=2.34 ms, TI=1000 ms, flip angle=7 degrees; Cohort 2: Siemens Prisma 3T MRI scanner, 196 slices, FOV= 240 $\times$ 256, 0.8 mm isotropic resolution, TR=2400 ms,

TE=2.22 ms, TI=1000 ms, flip angle=8 degrees; Cohort 3: Siemens Prisma 3T scanner, 196 slices, FOV=256 × 256, 1 mm isotropic resolution, TR=2500 ms, TE=2.9 ms, TI=1070, flip angle=8 degrees). Children with recent onset of tic disorder often do not come to medical attention, so even with active community recruitment, we enrolled subjects over a period of years. Importantly, 25 NewTics, 27 TS, and 19 Tic-free control participants were scanned with a prospective motion correction sequence (vNav, [30]). We also included T1-weighted MPRAGE images from 11 children with TS and 22 children without tics (including 11 participants scanned with a vNav sequence) from other studies. Detailed scan parameters are shown in Supplemental material S1 . If the participant had more than one T1 scan, the scan with a better QC rating was used for the analysis.

Scan QC

In order to control the scan quality, we extracted MRIQC from each T1 scan [31]. Among 64 image quality metrics of MRIQC, we found that the average of signal-to-noise ratio of gray matter, white matter, and CSF (hereafter @was highly correlated with subjective rating rated by visual inspection following standardized criteria (Backhausen et al., 2016). We excluded T1 scans with scan rating C3 (fail) or SNR total below 7.5 from the further analysis (see Supplemental material S2). Thus 13 NewTics, 4TS, and 2 Tic-free participants were excluded.

Analysis

We used the volBrain pipeline [20], which segments and quantifies the volumes of subcortical structures including the putamen, caudate, pallidum, thalamus, hippocampus, amygdala, and accumbens. It also estimates total intracranial volume (ICV). We adopted the residual approach [32] to control for inter-individual head size differences (see Supplemental material S3). As we did not hypothesize asymmetry to be of interest, we summed left and right hemisphere volumes for each structure. Total (left + right) regional volumes adjusted for ICV were the dependent variables. We conducted multiple regression analyses within the NewTics participants to test whether subcortical structure volume at the baseline visit could predict tic severity at the follow-up visit. Baseline total tic score from the YGTSS, age, sex, ADHD diagnosis, OCD diagnosis, and scanner were included as covariates, but insignificant terms were eliminated via backward stepwise regression. Group comparisons were conducted using one-way ANOVA. Also, we conducted independent t-tests specifically comparing NewTics vs. Tic-free and TS vs. Tic-free. As we did not correct for multiple comparisons, we added Bayesian hypothesis testing with BIC method. BF_{10} over 3 was considered as positive [33] /substantial [34] evidence (strong evidence if $BF_{10} > 10$) [35]. We used JASP (JASP Team. JASP Version 0.9, https://jasp-stats.org/) for Bayesian hypothesis testing, and SPSS for all othter statistical analyses.

Results

Mean clinical change

Consistent with our previous report ([3]; 20 participants overlapping), NewTics participants' tic symptoms improved on average between the baseline and follow-up sessions. The mean total tic score was 17.59 (SD = 6.10) at the baseline session and 13.78 (SD = 7.60) at the 12-month follow-up session.

Predictors of change in the NewTics group

Total tic score at 12-month follow-up visit was significantly predicted by the volume of hippocampus at the baseline visit after controlling for the baseline tic symptoms $R^2 = .492$, $F(2,38) = 18.38$, $p < .001$; Adjusted $R^2 = .465$ (Figure 1). The estimated Bayes factor BF_{10} was 16.88, indicating strong evidence in favor of

adding hippocampal volume to the null model with baseline tic symptoms alone. Stepwise regression analysis was conducted to test whether age, sex, handedness, comorbid ADHD diagnosis, OCD diagnosis or scanner significantly improved the model, but none of the factors were selected. The final model is shown in Table 3.

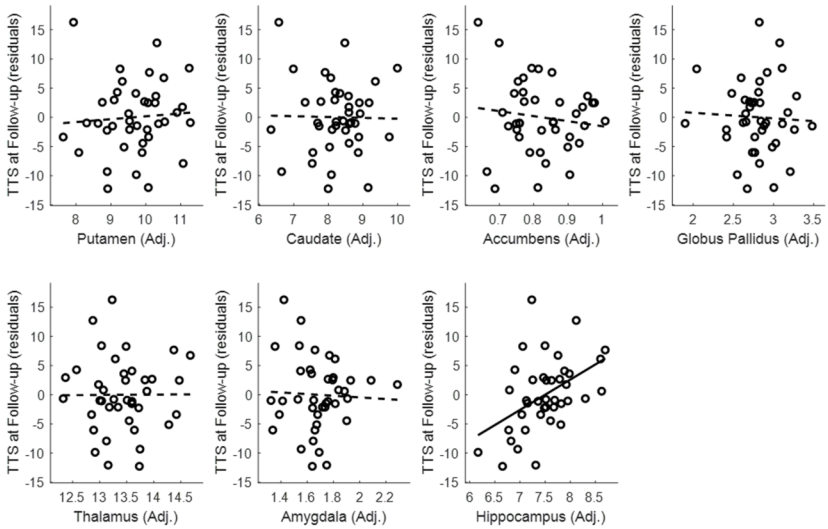

Figure 1: Tic severity prognosis by volumes of subcortical structures.

Variable		B	SE_B	β	p
Y = Total Tic Score at 12-month Follow-up					
	Hippocampus volume (Adjusted)	5.31	1.63	0.38	0.0
	Total Tic Score at baseline session	0.68	0.15	0.54	¡.001
	Intercept	-38.02	12.2		0.0

Table 3: Stepwise regression analysis for prediction of tic severity at 12-month visit based on hippocampal volume at baseline visit and other baseline clinical variables

As the volume of the hippocampus significantly predicted one-year tic outcome, we conducted a further, exploratory analysis to test whether a specific hippocampal subfield predicted tic outcome. The baseline CA1 volume , $R^2 = .622$, $F(2,57) = 46.85$, $p < .001$; adjusted $R^2 = .608$, and CA2 and CA3 volume , $R^2 = 617$, $F(2,57) = 45.84$, $p < .001$; adjusted $R^2 = 0.603$, predicted 12-month total tic score controlling for total tic score at the baseline visit such that participants with larger CA1 volume or CA2 and CA3 volume at the baseline visit showed less improvement (or worsening) of tic severity (see Supplemental material S4).

This result was not due to an association already present at baseline. Cross-sectional analyses to examine the relationship between the volumes of subcortical structures and the total tic score within the baseline session revealed no significant association in any subcortical structure volumes (p *[?]* .25; Figure 2).

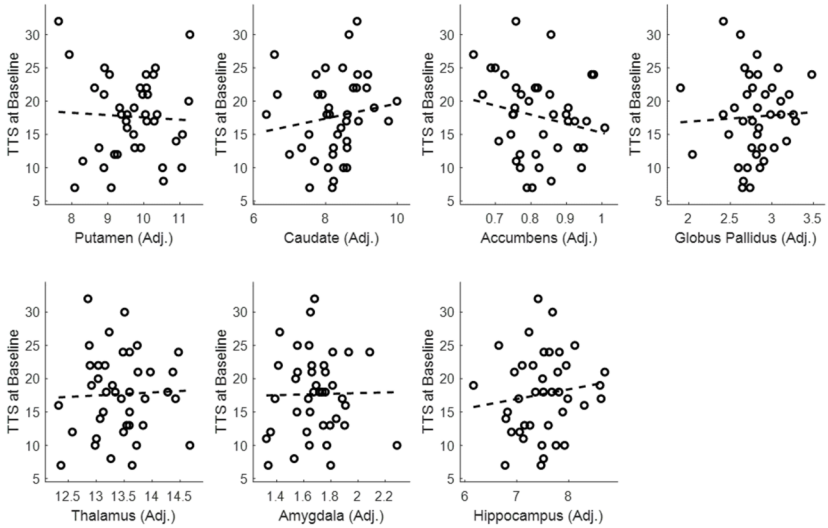

Figure 2: Relationship between the Volumes of Subcortical Structures and Total Tic Score (TTS) at the Baseline Visit

Group comparisons

Putamen, caudate, nucleus accumbens, globus pallidus, amygdala, thalamus, and hippocampus volumes for each group are shown in Figure 3. One-way ANOVAs revealed no significant main effects of the group in any subcortical structure (p [?] .113). As we specifically hypothesized that children with tics (NewTics group and TS group) would differ from Tic-free children (H1), we compared NewTics and TS group to Tic-free group separately using independent t-tests. Hippocampal volume differed between NewTics and Tic-free control groups, t(79)=2.022, p=.047. The estimated Bayes factor BF_{10} was 1.40, indicating weak evidence in favor of the alternative hypothesis (H1). There was no significant difference between NewTics and Tic-free in other subcortical structures (minimum p=.122) or between TS and Tic-free participants in any subcortical structures (minimum p=.116). We conducted a sub-group analysis with the selected sample whose T1 scans were collected with prospective motion correction (vNav). One-way ANOVA revealed a significant main effect of group for hippocampal volume (see Supplemental material S5); post-hoc tests showed greater hippocampal volume in each patient group compared to controls.

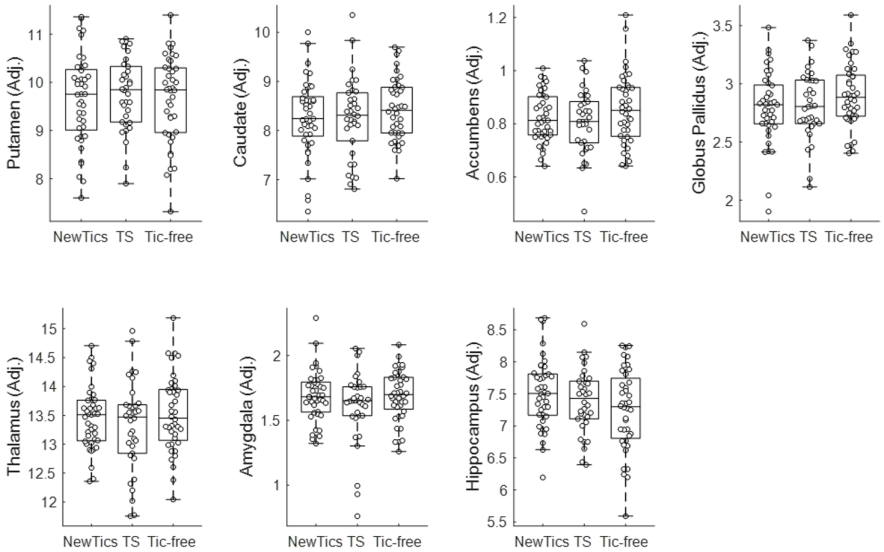

Figure 3: Group comparison of subcortical structure volumes

Discussion

The goal of the current study was to examine whether the volume of subcortical structures in children with recent-onset tics predicted tic outcome at the one-year anniversary of tic onset (when Tourette's Disorder or Persistent Motor or Vocal Tic Disorder can first be diagnosed). We found that the hippocampal volume estimated within months of tic onset predicted one-year tic outcome, such that children with a larger volume of hippocampus showed less improvement or worse tic outcome. The volume of other subcortical structures did not predict tic outcome. We also examined whether the volumes of any subcortical structures differed between NewTics, TS, and Tic-free groups. Hippocampal volume differed between NewTics and controls, but it was only weak evidence. No significant difference was found in any other subcortical structures.

Our *a priori* hypothesis regarding caudate volume was not supported. Smaller caudate volumes in children and adults with TS have been repeatedly reported (reviewed in [36]), and one longitudinal study in TS showed that smaller caudate volume in childhood predicted worse tic outcome in young adulthood [9]. The different patterns of prognosis results might be due to the different phase of illness or different periods of follow-up. While we studied the prognosis of children presenting within a few months of tic onset, measured at one year, Bloch et al. examined subjects at least a year after tic onset, with follow-up a mean of 7.5 years later. However, neither could we replicate lower mean caudate volumes reported by others in children with diagnosed TS.

MR images with motion artifact can lead to artifactually smaller volumes [27]; [28], raising concerns about studies that did not specify how carefully they controlled the scan quality. We adopted a prospective motion correction sequence (vNav, [29]) to reduce the impact of head motion, and also excluded the scan images with low SNR from the analysis. Within this carefully controlled dataset we have not found any significant group difference in caudate volume or its association with tic symptoms. Previous findings of smaller caudate volume might be partially due to the individuals with tics moving more inside the MRI scanner. Alternatively, the lack of significance in the current study may reflect type II error. However, one of the largest studies similarly found no significant reduction in caudate volume in children with TS [8].[8]

In the current study, the significant association between the volumes and tic symptom severity at follow-up was specific to the hippocampus. None of the other subcortical structures revealed significant results even when comorbidities were statistically controlled. Although hippocampal enlargement in children with TS has

been reported previously [16], it is somewhat surprising that the biomarker predicting tic symptom severity is hippocampal volume. The finding that the hippocampal volume quantified at the baseline visit was not associated with the tic symptom severity at the baseline visit but correlated with the tic symptom severity at 12-month visit suggests that the volume of hippocampus may not be related to the initial acquisition of tics but related to the persistence of tic symptoms. This finding is consistent with the idea that tics are thought to result from aberrant habit learning [37]. Both tics and habits are inflexible and repetitive behaviors that are acquired over a period of time. Given these similarities, a behavioral study using a motor learning and memory task reported a negative correlation between the rate of forgetting (unlearning) and motor tic severity [38]. Children/adolescents with severe tics showed evidence of enhanced motor memory, in that they took longer to unlearn previously learned motor patterns of behavior. The hippocampus plays a role in memory consolidation not just in the cognitive domain but also in the motor domain [39]. Together with the previous behavioral finding, our results suggest that tics, once they develop, are more likely to persist in children with a larger hippocampus.

The apparent lack of a significant group difference is complicated. If the hippocampus is related to the main cause of tic symptom persistence, then one would expect greater hippocampus volume in TS group compared to Tic-free controls. The lack of significant group differences may indicate that the hippocampus plays a critical role in initial tic symptom persistence up to about a year after tic onset, but after that the relationship between the hippocampal volumes and tic symptoms may be more complicated. For example, ADHD, OCD [40]; [41]; [42], and anxiety disorder [43], all of which frequently co-occur with tic disorders, have been associated with reduced hippocampal volume. However, in the current study, these clinical subgroups (among subjects whose comorbid symptom records were available) did not differ in terms of hippocampal volume. Alternatively, the nonsignificant group difference may be due to variance with age: although Peterson et al. found greater hippocampal volume in children, some subregions became smaller than in controls by adulthood [16], and reduced hippocampal volumes have been reported in adolescents [44]and in TS adults with co-morbid OCD [19]. On the other hand, the data collected using the prospective motion correction MR sequence, and with tics carefully screened by face-to-face interview, video recording of the child sitting alone, and a semi-standardized diagnostic interview (K-SADS), revealed increased hippocampal volumes in the NewTics and TS groups compared to the Tic-free group. Further studies need to be conducted to determine whether additional data collected with this improved methodology can confirm this potential group difference. Prospective motion correction is advantageous because it can acquire the scan data with adequate quality even in those participants with some head motion, while scan quality control after acquisition may bias the sample by excluding the participants with more severe tic symptoms.

In summary, our results suggest that hippocampus volume may be a critical biomarker predicting tic symptom persistence in children with Provisional Tic Disorder. Further studies with longer follow-up are required to understand more fully the relationship between hippocampal volume and tic symptoms.

Ethical Approval

The study was approved by the Washington University Human Research Protection Office (IRB), protocol numbers 201109157 and 201707059. Each child assented and a parent (guardian) gave informed consent. Also, for those individuals who gave informed consent for the data sharing, MRI scan data and their clinical information were shared by the CTS study (IRB 201412136), TRACK study (IRB 201301004, 201808060), or NEWT study (IRB 201601135).

Funding

Research reported in this publication was supported by National Institutes of Health, awards K24 MH087913 to KJB; R21 NS091635 to BLS and KJB; K01 MH104592 to DJG; R01 MH104030 to KJB and BLS; the Washington University Institute of Clinical and Translational Sciences grants UL1 RR024992 and UL1 TR000448; and the Eunice Kennedy Shriver National Institute of Child Health & Human Development of the National Institutes of Health under Award Number U54 HD087011 to the Intellectual and Developmental Disabilities Research Center at Washington University.

Data Availability

The supplementary data file provides individual participant data.

Supplemental Material

S1. Structural MRI collection specifications

vNav_category	Study	Scanner	Sequence parameters	NewTics_N	TS_N	Tic-free_N	Note
non-vNav	NewTics (Cohort 1)	SIEMENS Trio 3T	MPRAGE; tfl3d1_ns; Frames 176; FOV 224×256 Voxels; Vox. Res. 1.0 1.0 1.0; TR 2200; TE 2.34; TI 1000; flip angle 7	23 (12 QC fail)	-	-	Data collected between 2010-Oct and 2015-Jul
non-vNav	NewTics (Cohort 2)	SIEMENS Prisma 3T	MPRAGE; *tfl3d1_16ns; Frames 196; FOV 240×256 Voxels; Vox. Res. 0.8 0.8 0.8; TR 2400; TE 2.22; TI 1000; flip angle 8	6 (1 QC fail)	-	-	Data collected between 2015-Dec and 2016-Sep
vNav	NewTics (Cohort 3)	SIEMENS Prisma 3T	MPRAGE; tfl3d1_16ns; Frames 196; FOV 256×256 Voxels; Vox. Res. 1.0 1.0 1.0; TR 2500; TE 2.9; TI 1070; flip angle 8	25	27 (4 QC fail)	19	Data collected between 2016-Oct and 2019-Dec
non-vNav	CTS	SIEMENS Trio 3T	MPRAGE; *tfl3d1_ns; Frames 256; FOV 256×256 Voxels; Vox. Res. 1.0 1.0 1.0; TR 2400; TE 3.08; TI 1000; flip angle 8	-	7	4	
non-vNav	JCA	SIEMENS Trio 3T	MPRAGE; *tfl3d1_ns; Frames 176; FOV 256×256 Voxels; Vox. Res. 1.0 1.0 1.0; TR 2400; TE 3.08; TI 1000; flip angle 8	-	4	-	
non-vNav	TRACK	SIEMENS Trio 3T	MPRAGE; *tfl3d1_ns; Frames 192; FOV 256×256 Voxels; Vox. Res. 1.0 1.0 1.0; TR 2400; TE 3.16; TI 1000; flip angle 8	-	-	4	
vNav	NEWT	SIEMENS Prisma 3T	MPRAGE; tfl3d1_16ns; Frames 192; FOV 256×256 Voxels; Vox. Res. 1.0 1.0 1.0; TR 2500; TE 2.9; TI 1070; flip angle 8	-	-	8	
vNav	MSCPI	SIEMENS Prisma 3T	MPRAGE; tfl3d1_16ns; Frames 192; FOV 256×256 Voxels; Vox. Res. 1.0 1.0 1.0; TR 2500; TE 2.9; TI 1070; flip angle 8	-	-	3	
non-vNav	TR	SIEMENS Trio 3T	MPRAGE; *tfl3d1_ns; Frames 176; FOV 180×180 Voxels; Vox. Res. 1.0 1.0 1.0; TR 2400; TE 3.28; TI 1000; flip angle 8	-	-	1 (1 QC fail)	
non-vNav	TR	SIEMENS Trio 3T	MPRAGE; *tfl3d1_ns; Frames 176; FOV 256×256 Voxels; Vox. Res. 1.0 1.0 1.0; TR 2400; TE 3.12; TI 1000; flip angle 8			1	
non-vNav	TR	SIEMENS Trio 3T	MPRAGE; *tfl3d1_ns; Frames 174; FOV 256×256 Voxels; Vox. Res. 1.0 1.0 1.0; TR 2400; TE 3.08; TI 1000; flip angle 8			1	

Table 4: Structural MRI collection specifications

S2. Scan Quality Control

All scans were rated from 1 to 3 with 1 being good and 3 being bad (decimals were allowed) using the four criteria suggested by [45]: 1) image sharpness, 2) ringing, 3) subcortical structure contrast-to-noise ratio (CNR), and 4) GM and WM CNR, and averaged these four ratings. The rater was blinded to the participants' characteristics. We excluded 2 NewTics and 4 TS participants whose scan rating was 3 (fail). Correlation analysis revealed that SNR (total) was highly correlated with the averaged scan rating (Figure below). We found that SNR (total) was higher for the scans with vNav sequence compared to the scans without prospective motion correction, even when the scans were rated similarly by visual inspection. The minimum SNR of the vNav scans which got an average rating of 1 (pass) or 2 (check) was about 7.5, so we used this criterion to quality control all scans, acquired with or without the vNav sequence. This allowed us to include the non-vNav scans when they were objectively of equal quality as the vNav scans. 11 NewTics and 1 Tic-free participants were excluded due to low SNR.

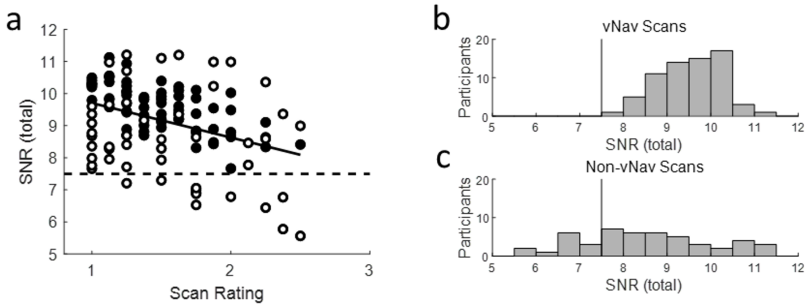

Figure 4: SNR Total of MRIQC. (a) The relationship between scan rating with visual inspection and SNR (total) of T1 scans. Black circles indicate T1 scans with vNav sequence, and white circles indicate T1 scans with non-vNav sequences. The histogram of SNR total of T1 scans with vNav sequence (b) and T1 scans with non-vNav sequences (c). The vertical lines in (b) and (c) indicate the cutoff criterion for scan quality control. See text in S2. Scan Quality Control.

S3. Intracranial volume adjustment

The residual approach [32] was adopted to control for inter-individual head size differences. As we did not hypothesize asymmetry to be of interest, we summed left and right hemisphere volumes for each structure. A linear regression model was fitted between the total (left + right) volume of subcortical structure and intracranial volume (ICV) to predict ICV-adjusted volumes. Adjusted volumes were obtained as the sum of the residuals from the regression model and the mean volume. Total (left + right) regional volumes adjusted for ICV were the dependent variables.

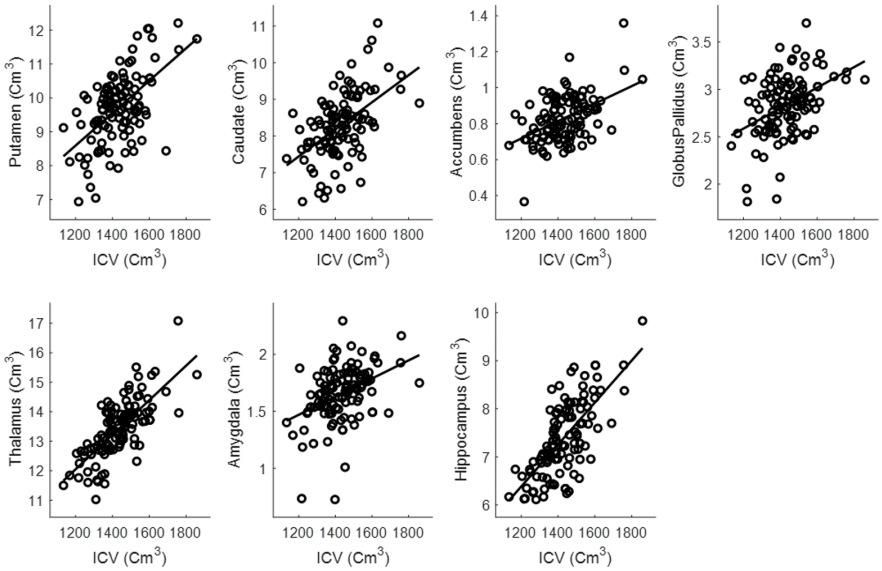

Figure 5: Relationship between the total (left + right) subcortical structure volumes and ICV. See text in S3. Intracranial volume adjustment

S4. Tic severity prognosis by volumes of hippocampal subfields.

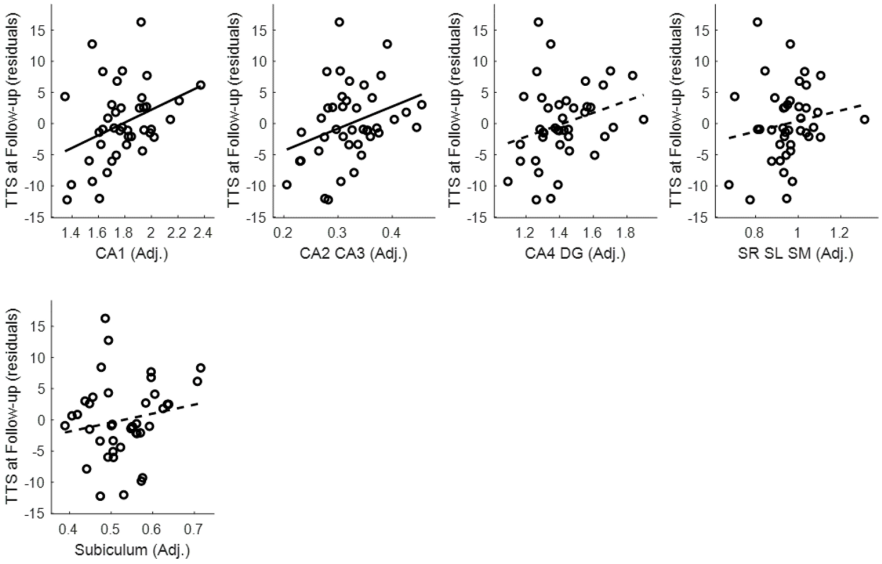

Figure 6: Figure for S4. Tic severity prognosis by volumes of hippocampal subfields.

S5. Group comparison within the selected subsample

We conducted a sub-group analysis with the selected sample whose T1 scans were collected with prospective motion correction (vNav sequence). One-way ANOVA revealed a significant main effect of group for hippocampal volume (p=.018). Post-hoc analysis revealed that both the NewTics group (mean=7.54, SD=0.56, t(42)=2.66, p= .011) and TS group (mean=7.47, SD=0.53, t(40)=2.30, p=.027) had larger hippocampal volume than did the Tic-free group (mean=7.05, SD=0.64). Volumes did not differ significantly in any other subcortical region (p [?] .099).

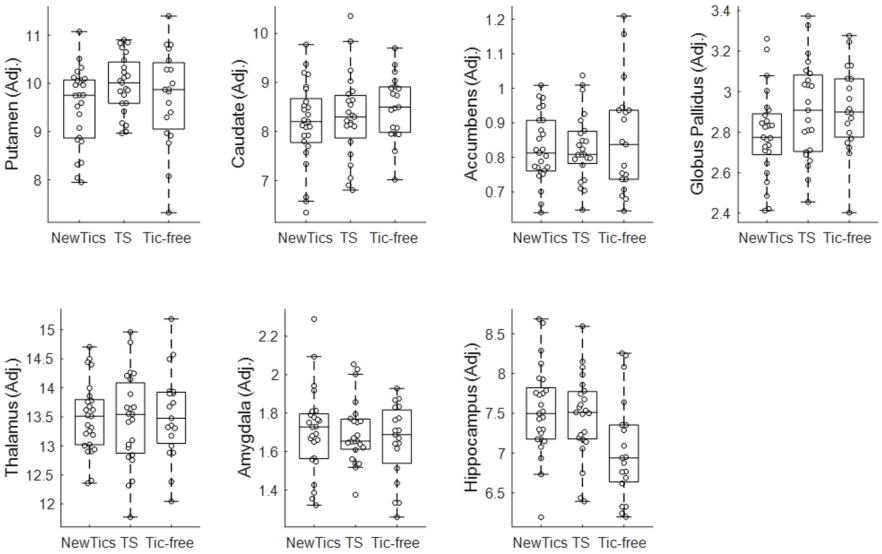

Figure 7: See text in S5. Group comparison within the selected subsample

References

1. Association AP. Diagnostic and Statistical Manual of Mental Disorders. American Psychiatric Association; 2013.

2. Black KJ, Black ER, Greene DJ, Schlaggar BL. Provisional Tic Disorder: What to tell parents when their child first starts ticcing. F1000Research. 2016;5:696.

3. Kim S, Greene DJ, Bihun EC, Koller JM, Hampton JM, Acevedo H, et al. Provisional Tic Disorder is not so transient. Scientific Reports. 2019;9.

4. Makki MI, Behen M, Bhatt A, Wilson B, Chugani HT. Microstructural abnormalities of striatum and thalamus in children with Tourette syndrome. Movement Disorders. 2008;23:2349–2356.

5. Peterson BS, Thomas P, Kane MJ, Scahill L, Zhang H, Bronen R, et al. Basal Ganglia Volumes in Patients With Gilles de la Tourette Syndrome. Archives of General Psychiatry. 2003;60:415.

6. Moriarty J, Varma AR, Stevens J, Fish M, Trimble MR, Robertson MM. A volumetric MRI study of Gilles de la Tourette's syndrome. Neurology. 1997;49:410–415.

7. Müller-Vahl KR, Kaufmann J, Grosskreutz J, Dengler R, Emrich HM, Peschel T. Prefrontal and anterior cingulate cortex abnormalities in Tourette Syndrome: evidence from voxel-based morphometry and magnetization transfer imaging. BMC Neuroscience. 2009;10.

8. Greene DJ, Williams III A C, Koller JM, Schlaggar BL, Black KJ, America Neuroimaging Consortium TTA of. Brain structure in pediatric Tourette syndrome. Molecular Psychiatry. 2017;22:972–980.

9. Bloch MH, Leckman JF, Zhu H, Peterson BS. Caudate volumes in childhood predict symptom severity in adults with Tourette syndrome. Neurology. 2005;65:1253–1258.

10. Makki MI, Govindan RM, Wilson BJ, Behen ME, Chugani HT. Altered Fronto-Striato-Thalamic Connectivity in Children with Tourette Syndrome Assessed with Diffusion Tensor MRI and Probabilistic Fiber Tracking. Journal of Child Neurology. 2009;24:669–678.

11. Ludolph AG, Juengling FD, Libal G, Ludolph AC, Fegert JM, Kassubek J. Grey-matter abnormalities in boys with Tourette syndrome: magnetic resonance imaging study using optimised voxel-based morphometry. British Journal of Psychiatry. 2006;188:484–485.

12. Roessner V, Overlack S, Schmidt-Samoa C, Baudewig J, Dechent P, Rothenberger A, et al. Increased putamen and callosal motor subregion in treatment-naïve boys with Tourette syndrome indicates changes in the bihemispheric motor network. Journal of Child Psychology and Psychiatry. 2010;52:306–314.

13. Worbe Y, Marrakchi-Kacem L, Lecomte S, Valabregue R, Poupon F, Guevara P, et al. Altered structural connectivity of cortico-striato-pallido-thalamic networks in Gilles de la Tourette syndrome. Brain. 2015;138:472–482.

14. Lee J-S, Yoo S-S, Cho S-Y, Ock S-M, Lim M-K, Panych LP. Abnormal thalamic volume in treatment-naive boys with Tourette syndrome. Acta Psychiatrica Scandinavica. 2006;113:64–67.

15. Miller AM, Bansal R, Hao X, Sanchez-Pena JP, Sobel LJ, Liu J, et al. Enlargement of Thalamic Nuclei in Tourette Syndrome. Archives of General Psychiatry. 2010;67:955.

16. Peterson BS, Choi HMA, Hao X, Amat JA, Zhu H, Whiteman R, et al. Morphologic Features of the Amygdala and Hippocampus in Children and Adults With Tourette Syndrome. Archives of General Psychiatry. 2007;64:1281.

17. Wittfoth M, Bornmann S, Peschel T, Grosskreutz J, Glahn A, Buddensiek N, et al. Lateral frontal cortex volume reduction in Tourette syndrome revealed by VBM. BMC Neuroscience. 2012;13.

18. Singer HS, Reiss AL, Brown JE, Aylward EH, Shih B, Chee E, et al. Volumetric MRI changes in basal ganglia of children with Tourette's syndrome. Neurology. 1993;43:950–950.

19. Worbe Y, Gerardin E, Hartmann A, Valabrégue R, Chupin M, Tremblay L, et al. Distinct structural changes underpin clinical phenotypes in patients with Gilles de la Tourette syndrome. Brain. 2010;133:3649–3660.

20. Manjón JV, Coupé P. volBrain: An Online MRI Brain Volumetry System. Frontiers in Neuroinformatics. 2016;10.

21. Fischl B, Salat DH, Busa E, Albert M, Dieterich M, Haselgrove C, et al. Whole Brain Segmentation. Neuron. 2002;33:341–355.

22. Patenaude B, Smith SM, Kennedy DN, Jenkinson M. A Bayesian model of shape and appearance for subcortical brain segmentation. NeuroImage. 2011;56:907–922.

23. Akudjedu TN, Nabulsi L, Makelyte M, Scanlon C, Hehir S, Casey H, et al. A comparative study of segmentation techniques for the quantification of brain subcortical volume. Brain Imaging Behav. 2018;12:1678–1695.

24. Næss-Schmidt E, Tietze A, Blicher JU, Petersen M, Mikkelsen IK, Coupé P, et al. Automatic thalamus and hippocampus segmentation from MP2RAGE: comparison of publicly available methods and implications for DTI quantification. International Journal of Computer Assisted Radiology and Surgery. 2016;11:1979–1991.

25. Romero JE, Coupé P, Manjón JV. HIPS: A new hippocampus subfield segmentation method. NeuroImage. 2017;163:286–295.

26. Pardoe HR, Hiess RK, Kuzniecky R. Motion and morphometry in clinical and nonclinical populations. NeuroImage. 2016;135:177–185.

27. Alexander-Bloch A, Clasen L, Stockman M, Ronan L, Lalonde F, Giedd J, et al. Subtle in-scanner motion biases automated measurement of brain anatomy from in vivo MRI. Human Brain Mapping. 2016;37:2385–2397.

28. Reuter M, Tisdall MD, Qureshi A, Buckner RL, Kouwe AJW van der, Fischl B. Head motion during MRI acquisition reduces gray matter volume and thickness estimates. NeuroImage. 2015;107:107–115.

29. Tisdall MD, Reuter M, Qureshi A, Buckner RL, Fischl B, Kouwe AJW van der. Prospective motion correction with volumetric navigators (vNavs) reduces the bias and variance in brain morphometry induced by subject motion. NeuroImage. 2016;127:11–22.

30. Tisdall MD, Hess AT, Reuter M, Meintjes EM, Fischl B, Kouwe AJW van der. Volumetric navigators for prospective motion correction and selective reacquisition in neuroanatomical MRI. Magnetic Resonance in Medicine. 2012;68:389–399.

31. Esteban O, Birman D, Schaer M, Koyejo OO, Poldrack RA, Gorgolewski KJ. MRIQC: Advancing the automatic prediction of image quality in MRI from unseen sites. PLoS One. 2017;12:e0184661.

32. Voevodskaya O, Simmons A, Nordenskjöld R, Kullberg J, Ahlström H, Lind L, et al. The effects of intracranial volume adjustment approaches on multiple regional MRI volumes in healthy aging and Alzheimer's disease. Frontiers in Aging Neuroscience. 2014;6.

33. Raftery AE. Bayesian Model Selection in Social Research. Sociological Methodology. 1995;25:111.

34. Jeffreys H. The theory of probability. OUP Oxford; 1998.

35. Jarosz AF, Wiley J. What Are the Odds? A Practical Guide to Computing and Reporting Bayes Factors. The Journal of Problem Solving. 2014;7.

36. Greene DJ, Black KJ, Schlaggar BL. Neurobiology and functional anatomy of tic disorders. Oxford: Oxford University Press; 2013.

37. Leckman JF, Riddle MA. Tourette's Syndrome. Neuron. 2000;28:349–354.

38. Kim S, Jackson SR, Groom M, Jackson GM. Visuomotor learning and unlearning in children and adolescents with tourette syndrome. Cortex. 2018;109:50–59.

39. Schapiro AC, Reid AG, Morgan A, Manoach DS, Verfaellie M, Stickgold R. The hippocampus is necessary for the consolidation of a task that does not require the hippocampus for initial learning. Hippocampus. 2019;29:1091–1100.

40. Hong SB, Shin Y-W, Kim SH, Yoo SY, Lee J-M, Kim IY, et al. Hippocampal shape deformity analysis in obsessive–compulsive disorder. European Archives of Psychiatry and Clinical Neuroscience. 2007;257:185–190.

41. Atmaca M, Yildirim H, Ozdemir H, Ozler S, Kara B, Ozler Z, et al. Hippocampus and amygdalar volumes in patients with refractory obsessive–compulsive disorder. Progress in Neuro-Psychopharmacology and Biological Psychiatry. 2008;32:1283–1286.

42. Reess TJ, Rus OG, Gürsel DA, Schmitz-Koep B, Wagner G, Berberich G, et al. Association between hippocampus volume and symptom profiles in obsessive–compulsive disorder. NeuroImage: Clinical. 2018;17:474–480.

43. Gold AL, Steuber ER, White LK, Pacheco J, Sachs JF, Pagliaccio D, et al. Cortical Thickness and Subcortical Gray Matter Volume in Pediatric Anxiety Disorders. Neuropsychopharmacology. 2017;42:2423–2433.

44. Jackson SR, Sigurdsson HP, Dyke K, Condon M, Jackson GM. The role of the cingulate cortex in the generation of motor tics and the experience of the premonitory urge-to-tic in Tourette syndrome. BioRxiv. 2020. January 2020. https://doi.org/10.1101/2020.01.29.924399.

45. Backhausen LL, Herting MM, Buse J, Roessner V, Smolka MN, Vetter NC. Quality Control of Structural MRI Images Applied Using FreeSurfer-A Hands-On Workflow to Rate Motion Artifacts. Front Neurosci. 2016;10:558.