COMBINED ABDOMINAL HETEROTOPIC HEART AND AORTA TRANSPLANT MODEL IN MICE

Hao Dun[1], Li Ye[1], Yuehui Zhu[1], Brian W. Wong[1]

[1]Laboratory of Lymphatic Metabolism + Epigenetics, Department of Surgery, Washington University School of Medicine, St. Louis, MO, USA 63110

Editorial correspondence: B. Wong, PhD
Laboratory of Lymphatic Metabolism + Epigenetics
Department of Surgery
Washington University School of Medicine
660 South Euclid Avenue, Campus Box 8234
St. Louis, MO, USA 63110
phone: (314) 747-7316; fax: (314) 361-8706
email: brian.wong@wustl.edu

Keywords: mouse model, transplantation, heart transplantation, aorta transplantation, cardiac allograft vasculopathy (CAV)

ABBREVIATIONS

AV – allograft vasculopathy
CAV – cardiac allograft vasculopathy
IVC – inferior vena cava
SVC – superior vena cava

ABSTRACT

Background: Allograft vasculopathy (AV) remains a major obstacle to the long-term allograft survival. While the mouse aortic transplantation model has been proven as a useful tool for study of the pathogenesis of AV, simultaneous transplantation of the aorta alongside the transplantation of another organ, may reveal more clinically relevant mechanisms regarding well-defined characteristics of chronic allograft rejection. Therefore, we developed a combined heterotopic abdominal heart and aorta transplantation model in mice, which is aimed at improving our understanding of the progressive nature of AV, reducing animal and drug utilization and further optimizing the immunosuppressive strategies for its prevention.

Methods: The middle of the infrarenal aorta of the recipient mouse was ligatured between the renal artery and its bifurcation. Proximal and distal aortotomy was performed at this site above and below the ligature, respectively, for the subsequent anastomoses of the donor's aortic and heart grafts to the recipient infrarenal aorta in an end-to-side fashion. The distal anastomotic site of the recipient infrarenal aorta was connected with the outlet of the donor aorta. Uniquely, the proximal anastomotic site on the recipient infrarenal aorta was shared to connect with both the inlet of the donor aorta and the inflow tract to the donor heart. The outflow tract from the donor heart was connected to the recipient inferior vena cava (IVC).

Results: Harvest of the heart and aorta grafts required 20-25 minutes, 10 minutes for the recipient's preparation, 40-50 minutes for anastomoses, and overall ischemic time was within 70 minutes. The surgery survival rate was more than 96% (29/30). Both the syngeneic *C57Bl/6* aorta and heart grafts survived more than 90 days in 29 *C57Bl/6* recipients. Further, *Balb/c* to *C57Bl/6* allografts treated with anti-CD40L and CTLA4.Ig survived more than 90 days with a 100% survival rate (3/3).

Conclusions: This new model is presented as a new tool for investigators to explore transplant immunology and assess immunosuppressive strategies. It is possible to share a common anastomotic stoma on the recipient's abdominal aorta to reconstruct both the aorta graft entrance and heart graft inflow tract. This allows for investigation of allogeneic effects on both the aorta and heart from the same animal, in a single survival surgery.

INTRODUCTION

Solid organ transplantation is one of the most effective interventions for patients with end-stage organ failure. However, persistent transplant rejection remains unsolved. Chronic allograft rejection remains the leading cause of graft loss one-year post-transplantation. It is well known that T cell-mediated immune responses play a central role in acute allograft rejection (1).

Current strategies of immunosuppression targeting T cell activation and effector function have dramatically reduced the acute graft loss. However, the development of chronic allograft injury remains the major obstacle to the long-term allograft survival (2). Although the exact mechanism is unclear, the multifactorial mechanisms including both immunological and nonimmunological components are likely involved in the development of chronic allograft rejection (3). A common feature in most of solid organ transplants undergoing chronic rejection is the allograft vasculopathy (AV) (transplant-associated arteriosclerosis), despite their demonstrating the specific histopathological characteristics depending on the type of the solid organ transplanted. In heart allograft, it is referred to as cardiac allograft vasculopathy (CAV), which is characterized by the accelerated form of arteriosclerosis in the arteries of the allograft as a result of the proliferation of the intimal smooth muscle cells, leading to ischemic injury and fibrosis and eventually the graft loss (4). Unfortunately, it is not effectively prevented by current immunosuppressive drugs in most cases. Hence, there is a growing need for the development of the reliable animal models to decipher underlying mechanism of CAV and further optimize and develop immunosuppressive strategies for its prevention.

Heterotopic heart transplantation in mice has been considered as the best model in study of transplant immunology, since introduced by Corry and Russell in 1973 (5). Without immunosuppressive cover, transplantation of fully mismatched MHC cardiac allograft induces strong alloreactive T cell responses that mediate rapid graft destruction (6). In this situation, the model recapitulates a pathologic process of acute allograft rejection. Therefore, to closely simulate the clinical definition of a chronic allograft injury, immunosuppressive drugs have to be introduced to suppress the acute immune response. However, almost all of current used immunosuppressive drugs target on T cell activation in preventing acute transplant rejection. With such a specific pharmacologic

intervention, the developed AV is probably a reflection of amount of sub-acute rejection by suppression of certain acute rejection. This strict dependence on acute rejection reveals the limitation of this model for drawing conclusions regarding the human condition (7). Moreover, because many of the current used immunosuppressive drugs are also responsible for the development of AV (8), the introduction of these agents may increase complexities in interpreting results from this model to clinically relevant AV.

Alternatively, in contrast with fully mismatched MHC, cardiac grafts transplanted across multiple minor histocompatibility mismatch (6) or single class I or class II MHC mismatches (9) are commonly long-term accepted and ultimately develop CAV. For example, mice of B6C.H-2^{bm12} are a mutant strain of C57BL/6 at I-A locus of MHC II but are identical at MHC I and minor MHC loci (9). B6C.H-2^{bm12} heart allografts are not acutely rejected in C57BL/6 recipients and eventually can develop CAV (9). Mechanisms accounting for long-term B6C.H-2^{bm12} heart allograft survival with the development of significant vasculopathy in C57BL/6 recipients are the emergence of $CD25^{+}$ regulatory cells that inhibits alloreactive T-cell activation (10). Since the pathogenesis of CAV is considered to be multifactorial, an appropriate model should not exclusively confine it under a specific condition, such as the limited alloreactive T-cells activation, which limited the clinical relevance of this model as well.

The aorta transplantation model in mice has been used as a chronic rejection model for the study of immunological and/or molecular mechanisms of AV. With this model, the aorta allografts transplanted, even across fully mismatched MHC, show long-term allograft survival along with the developments of a degree of transplant arteriosclerosis in absence of immunosuppressants (11), appearing to circumvent the strict influence of acute rejection. Acute rejection episodes have been considered as a risk factor for the future development of AV (12). However, in this model the aorta allograft is spared from acute rejection, which normally is seen in parenchymal organs such as heart allografts. Therefore, it remains controversial whether the vascular changes in aortic allograft represent those that develop in solid-organ transplants (13).

To address those issues, investigators have developed the combined heart and aorta/carotid artery transplantation models in mice to investigate the potential impact of acute rejection on CAV (13, 14). As expected, compared with isolated carotid allografts,

a significantly more intimal hyperplasia of carotid allografts was noted when transplanted in combination with a heart graft, indicating that CAV is promoted by acute parenchymal rejection of the heart (14). The result has further heightened the need for a parenchymal organ in combination with aorta transplantation in exploring clinic relevance of CAV. Despite impressive results made by their models, the transplantation of heart and aorta/carotid graft into two different operative sites, abdominal and cervical respectively, will inevitably increase operative traumas and prolong operative times, which may limit its widespread use. In order to simplify the surgical procedures and reduce unnecessary operative traumas and shorten graft ischemia and whole operative times, we developed a new technique to transplant both the heart and aorta graft in a single site of the abdomen. Furthermore, transplantation of the aorta and heart in a single surgery reduces donor animal utilization. The aim of our study was therefore to evaluate a new microsurgical technique of simultaneous heterotopic abdominal heart and aorta transplantation in mice as well as to assess the feasibility of sharing a common anastomotic stoma on the recipient's infrarenal aorta to reconstruct both the aorta-graft entrance and heart-graft inflow tract.

Our results demonstrate that this new model is characterized by the reliable reproducibility. Further studies using this model should provide insight into the clinical process of chronic allograft rejection and tool for assessing the novel immunosuppressive strategies for its prevention. In addition, to our knowledge, this is the first demonstration of a novel microsurgical technique in which an anastomotic stoma on the recipient's infrarenal aorta can be connected with two individual vessels, providing a new pathway of revascularization for multi-organ transplantation.

MATERIALS AND METHODS

ANIMALS

Adult female Balb/c mice 6-10 weeks of age (20-25g body weight) and male C57BL/6 mice, 6-10 weeks of age (20-25g body weight) were purchased from Jackson Laboratory (Bar Harbor, MD, USA). Animals were housed under standard conditions subjected to regular 12-hour light-dark cycles. Water and chow were supplied *ad libitum*. Animal experiments were conducted in accordance with an approved Washington University Animal Care and Use Committee protocol (#20190173). Anesthesia was induced by a mixture of ketamine (80-100 mg/kg)/xylazine HCl (8-12 mg/kg), intraperitoneally (i.p.) and maintained with 1-2% isoflurane gas, as required.

DONOR OPERATION

A longitudinal laparotomy was made and abdominal contents were reflected to the left side to expose the inferior vena cava (IVC). About 1.0 mL of cold saline containing heparin (100 U/mL) was injected into the IVC. After 1 minute for the systemic heparinization, an aortotomy of abdominal aorta is made to decompress the blood circulatory system, following which, a bilateral thoracotomy was performed through the ribs along both sides of the thoracic spine, and then the anterior chest wall was levered up cranially. The IVC around diaphragmatic hiatus was clamped with a hemostat, above that, the IVC was cannulated and then 0.5 mL of cold heparin (100 U/mL) is again infused into the right atrium. The thymus was resected to expose the aortic arch and pulmonary artery. The ascending aorta was transected proximal to the innominate artery. The pulmonary artery was transected proximal to its bifurcation. The IVC and the right superior vena cava (SVC) were proximally ligated with 7-0 sutures, respectively. A 5-0 ligature was placed underneath the IVC and the right SVC and around the heart to ligate all other vessels *en bloc* including the pulmonary veins and the left SVC as distally as possible. The IVC, the right SVC and the remaining connective tissues were all dissected distally in order. The donor's heart was then gently detached from the thorax and stored in ice-cold saline. In the following steps, the donor thoracic descending aorta would be harvested as described by Cho *et al* (15). Lungs were resected, then the diaphragm was divided as close to the aorta as possible to expose descending aorta. The descending aorta was further flushed

by cold heparin (100 U/mL) solution from the aorta bellow the diaphragm. The parietal pleura in front of the descending aorta were divided. Intercostal arteries were carefully divided from the segment of the descending aorta between the left subclavian artery proximally and the diaphragmatic hiatus distally. The thoracic descending aorta was harvested and stored in ice-cold saline. Although the thoracic aorta can be divided into three segments for individual transplantation, it is preferable to use the proximal section, as it is most compatible in diameter with ascending aorta of the donor heart, and therefore facilitates the subsequent anastomosis.

RECIPIENT OPERATION

A midline laparotomy was made from the pubis to the xiphoid, and then a micro-retractor was placed to expose the abdominal cavity. The intestines were gently retracted right outside the abdomen and covered with moistened gauze and kept moist throughout the procedure with saline. Using two cotton swabs, the abdominal aorta and the IVC below the renal vessels and above its bifurcation were exposed and dissected gently from the surrounding tissues. However, a complete isolation of infrarenal aorta from IVC was unnecessary for performing subsequent end-to-side anastomosis. One or two groups of the lumber arteries and veins underneath the abdominal aorta and IVC were ligated with 9-0 silk sutures. To interrupt the blood flow in both the aorta and the IVC, a 5-0 silk was single-tied at the proximal side of its bifurcation to allow it to be untied easily after anastomosis, and then a micro clamp was placed just at below the renal vessels. Next, the middle of the sequestered aorta was sutured with a 9-0 nylon suture (**Fig. 1A,B**). Thus, the aorta was partitioned into proximal and distal anastomotic areas without transection. The proximal and distal aortotomies were performed above and below the ligature respectively, for the subsequent anastomoses of the aorta- graft into the recipient in an end-to-side fashion (**Fig. 2A**). We preferred to make the aortotomy by a simple and reliable technique described by Mao *et al.* (16). Briefly, the tip of a 4 mm (3/8) needle was longitudinally passed in and slightly out of the anterior wall of the recipient's aorta and kept in position by a needle holder. By gently lifting the needle upwardly, the piece of the anterior wall of the aorta above the needle could be easily excised by cutting underneath the needle with fine scissors, so that an approximate 1 mm elliptical opening with the trim-

edge was made. In the same way, a venotomy in parallel with proximal aortotomy was made for the subsequent construction of heart-graft outflow tract. The openings of the aorta and the IVC were flushed with saline to remove the blood.

The aorta graft was placed on the left side of the recipient abdomen, and then covered with gauzes moistened with icy cold saline. First, using 11-0 nylon surgical suture, the aorta-graft exit was constructed in the distal anastomotic site of the recipient's infrarenal aorta in an end-to-side fashion. The posterior and the anterior walls of the anastomosis were completed inside and outside vessels with 4-5 continuous running sutures respectively. And then, the aorta-graft entrance and heart-graft inflow tract were constructed by sharing to connect the proximal anastomotic site of the recipient's infrarenal aorta. Briefly, the left side of the anastomotic site of the recipient's infrarenal aorta was anastomosed to the posterior wall of the donor's aorta-graft inside vessel (**Fig. 2B**). In the following step, the donor's heart graft was placed on the left side of the recipient's abdomen with the remnant of the ascending aorta underneath the pulmonary artery and perpendicular to the clamped vessels, and then covered with gauzes moistened with icy cold saline. The anterior wall of the aorta-graft was anastomosed to the posterior wall of the ascending aorta of the heart-graft inside vessel (**Fig. 3A,B**). The anterior wall of the ascending aorta of the donor heart was then anastomosed to the right side of the anastomotic site of the recipient's infrarenal aorta outside vessel (**Fig. 4A,B**). The last step in the procedure was to construct the heart-graft outflow tract, similarly, by an end-to-side anastomosis between the donor's pulmonary artery and the recipient's IVC with continuous running sutures of the posterior wall inside vessel and the anterior wall outside vessel (**Fig. 5A**).

After completion of anastomoses, the distal ligature was untied first, followed by the proximal clamp. The anastomotic sites should be gently pressed by two cotton swabs for several seconds, so that the small bleeding could be minimized and readily stopped. Optionally, small pieces of hemostatic agent spongostan could be placed around the anastomotic sites to prevent the anastomotic bleeding. Normally the aorta- and heart-graft immediately filled with blood and consequently becomes bright red in color. Prominent pulsations of the aorta-graft were visible and after a short episode of fibrillation, the sinus rhythm began to appear in the heart-graft (**Fig. 5B**). Making sure there is no

further bleeding, the abdominal incision was closed with 4-0 suture by continuous running stitches.

Immunosuppression

For a subset of additional transplants, the long-term viability of this combined aorta and heart transplant model were tested in syngraft (C57Bl/6 to C57Bl/6) and allograft (Balb/c to C57Bl/6) models, with the administration of 200 µg of *InVivoMab* anti-mouse CD40L (CD154; clone MR-1; Bio X Cell, West Lebanon, NH) and 200 µg of *InVivoMab* recombinant CTLA-4-Ig (hum/hum; Bio X Cell) on the day of transplantation, and on days 2, 4 and 6 post-transplantation (17, 18).

Histology and imaging

Four representative sections from each aortic and heart graft were stained with hematoxylin and eosin (H&E; Leica Biosystems, Buffalo Grove, IL) or Movat's pentachrome (Newcomer Supply, Middleton, WI) and digital images were captured using an Olympus BX61 microscope (Center Valley, PA).

Results

A total of 30 combined heterotopic abdominal heart and aorta syngrafts were performed using this technique in *C57Bl/6* mice. It took approximately 20–25 minutes for harvesting of the heart and aorta grafts, 10 minutes for the preparation of the transplant recipient and 40-50 minutes for anastomoses of the donor organs. Total ischemic time was within 70 minutes. The surgery survival rate of syngrafts was greater than 96% (29/30). One mouse died due to anastomotic hemorrhage on the same day as transplantation. Survival of both the syngeneic aorta and heart graft was more than 100 days.

To validate this surgical method, we subsequently performed allografts using *Balb/c* donor aorta and hearts transplanted into *C57Bl/6* recipients in the presence of double co-stimulatory blockade (17, 18), or syngrafts using *C57Bl/6* donor aorta and hearts transplanted into *C57Bl/6* recipients. Histological examination of aorta (Fig. 6A) or cardiac (Fig. 6B) grafts revealed long-term survival consistent with single transplant models.

Discussion

AV, which is resistant to current immunosuppressive therapies, has become the major obstacle to long-term survival in clinical organ transplants. Although, there are controversies concerning the relative contribution of acute transplant rejection to the subsequent development of AV, current evidences increasingly suggest that acute rejection is a strong risk factor for the late development of AV (19). Indeed, clinical reduction in acute rejections has significantly decreased the incidence of chronic rejection graft failure (20).

The aortic transplant model in mice has been reported as a useful tool for investigating chronic allograft rejection, based on its advantage of formation of consistent lesions, which can be easily quantified (21). However, unlike solid parenchymal allografts, the isolated aortic allografts can achieve long-term acceptance in the absence of immunosuppressive interventions to suppress the acute allograft rejection, meaning that it is spared from the strict influence of acute rejection. Therefore, acute transplantation rejection may not affect the type of changes in the aortic allograft that would be expected if the acute transplantation rejection is a significant factor for the development of CAV. Hence, the question was raised whether this model represents a clinical process of AV. This feature may make the model less clinic relevant. In contrast, the strategy of combining the aorta with the solid organ graft transplantation can include the possibility of the influence of the acute allograft rejection on the development of CAV, and therefore produce more clinically relevant conditions for study of chronic allograft rejection. As a result, this alteration of model has caused the marked changes of lesions contained in transplanted carotid segments (14). This observation confirmed that the acute parenchymal rejection is an important contributor to CAV, and further emphasized that a combined model may provide more clinic relevant understanding of mechanisms that are involved in the development of AV.

Researchers have developed the combined aorta/carotid and heart transplantation models in mice, in which, however, two individual grafts are transplanted into two different surgical sites, abdominal and cervical respectively. A likely rationale for the use of an additional surgical site is that the recipient's abdominal aorta between the renal artery and its bifurcation is not sufficient to make three aortotomies for connecting aorta-graft entrance and exit as well as heart-graft inflow tract. Thus, a cervical operation has to be

performed to accommodate another graft. However, two surgical sites of operations are associated with additional surgical procedures and prolonged anaesthesia, frequently resulting in increased surgical complications and poor outcomes, even though Ensminger *et al*. (13) carried out the procedure on separate days to minimize the surgical insult to the recipient. To avoid the unnecessary surgical traumas and shorten the ischemia and whole operative times, we developed a simplified model, in which two individual grafts can be accommodated in a single surgical site of abdomen with a high success rate.

Several arterial transplantation models have been well-established in mice. Both aortic and carotid grafts are most commonly used for study of CAV. Compared to the carotid segments with similar length, the aortic graft is larger in size, and therefore has more tissue available for histology and biomolecular analysis. On other hand, longer segments of aorta are available for transplantation. In our experience, a whole-length of thoracic ascending aorta from a single donor is long enough to be divided and transplanted into three to four individual recipients. Therefore, adoption of aortic, instead of carotid, graft is more efficient in such models.

In mice, the aortic graft can be transplanted into the recipient's infrarenal aorta by using either an end-to-end (21) or an end-to-side (11) anastomoses pattern. Due to the obvious disparity in size between the thoracic and abdominal segments of the aorta, the end-to-end pattern is technically more difficult and with higher incidence of anastomotic complications, up to approximately 20% of thrombotic complications being reported (21). In contrast, the end-to-side pattern is technically relatively easy and with a more than 98% of high success rate being reported (11). Therefore, end-to-side pattern has recently gained increasing popularity. In addition, a mild dissection of the infrarenal aorta from IVC is sufficient for performing end-to-side anastomosis. Thus, the donor operation is simplified by obviating the dissection of abdominal vessels, which are very easily injured. However, a potential limitation of this pattern is that a curved loop of aortic graft may alter the blood flow patterns and produce the unexpected and unreliable experimental results. To address this issue, after completion of the procedure of end-to-side anastomosis, Sun *et al*. (11) tried to convert an end-to-side to a quasi end-to-end anastomosis by transection of the native infrarenal aorta between the anastomotic sites of aortic allograft entrance and exit. However, this technique appeared to increase the likelihood of kinking at the

anastomotic sites (22). Importantly, data showed a loop and an interposition of aortic allograft made by end-to-side and end-to-end pattern respectively, demonstrated similar experimental results (22). Therefore, on the basis of merit, we combined the end-to-side anastomosis pattern of aortic transplantation without transection of native infrarenal aorta described by Cho et al. (15) in our study.

We adopted the abdominal, instead of cervical, approach to implant both heart and aortic allografts, because the abdominal infrarenal aorta is much larger in size and longer than the carotid artery, which makes anastomosis easier in abdomen than in cervix. Although the infrarenal aorta is divided from the inferior vena cava (IVC), however, a complete separation of these vessels from each other is unnecessary. Instead, a mild dissection of the abdominal vessels is easily performed and adequate for doing end-to-side anastomosis. In order to transplant both heart and aorta grafts abdominally, three anastomotic stomas in recipient infrarenal aorta are needed for reconstruction of aorta-graft entrance and exit as well as heart-graft inflow tract. However, we discovered that two adequate aortotomies, at a maximum, can be made in recipient infrarenal aorta for anastomosis, although we replaced the distal clamp by a ligature of 5-0 silk to utilize infrarenal aorta as long as possible. To address this issue, we adopted the proximal anastomotic stoma on recipient infrarenal aorta to connect both aorta-graft entrance and heart-graft inflow tract, and therefore successfully increased the availability of the recipient's infrarenal aorta. Results obtained from our preliminary study demonstrated this novel microsurgical technique can be easily performed with a high success rate, without thrombotic occlusion or stenosis observed in heart and aortic allografts. This novel technique also provides a new pathway in revascularization for multi-organ transplantation within a limited space.

Su *et al*. (23) argued that an entire everting suture technique was able to decrease the anastomotic complications. However, in our laboratory, we favoured the parachute technique to suture the vessel posterior walls inside the vessels (inverting suture) and anterior walls outsider the vessels (everting suture). In this way, grafts did not need to be repositioned into opposite side, and therefore the possibility of increased surgical complexities and warm ischemia times was limited. In our previous experience with this method, a more than 90% success rate of heterotopic heart transplantation in mice could

be stably achieved by a skilled microsurgeon. Consistently, in our current model, we adopted the same suture technique and achieved a high success rate. In addition, using a technique described by Mao *et al*. (16) to create the aortotomy and the venotomy, an elliptical anastomotic stoma is easily made with trim-edge, which may facilitate the vascular anastomosis. Nevertheless, the proficiency in microsurgical technique is required to enable researchers to achieve reliable and stable results with this model.

Conclusions

In conclusion, our preliminary study demonstrated a simple and reliable technique for combined heterotopic abdominal heart and aorta transplantation in mice, which can be achieved by sharing a common anastomotic stoma on the recipient's infrarenal aorta with two individual graft vessels. Further studies using this model should provide more insight into the mechanism of CAV and reveal correlation between the acute rejection and the subsequent development of CAV. In addition, the novel technique applied in this model provides a new pathway for revascularization and increases availability of methodological options for the development of experimental animal models.

Acknowledgements

We acknowledge the support of funding from the Joel D. Cooper Career Development Award from the International Society of Heart and Lung Transplantation.

Conflict of interest declaration: The authors have no conflicts to disclose.

Figure Legends

Figure 1: Diagrammatic (A) and photographic (B) representation of the middle of the recipient's infrarenal aorta between renal artery and its bifurcation, which was ligatured with a 9-0 nylon suture.

Figure 2: (A) Diagrammatic representation of the proximal and the distal aortotomies on the recipient's infrarenal aorta were performed above and below the ligature, respectively, for the subsequent anastomoses of the donor's aorta graft into the recipient in an end-to-side fashion. (B) Diagrammatic representation of the left side of the anastomotic site of the recipient's infrarenal aorta, which was anastomosed to the posterior wall of the donor's aorta graft within the vessel.

Figure 3: Diagrammatic (A) and photographic (B) representation of the anterior wall of the aorta graft, which was anastomosed to the posterior wall of the ascending aorta of the heart graft within the vessel.

Figure 4: Diagrammatic (A) and photographic (B) representation of the anterior wall of the ascending aorta of the heart graft, which was anastomosed to the right side of the anastomotic site of the recipient's infrarenal aorta.

Figure 5: Diagrammatic (A) and photographic (B) representation of the outflow tract (pulmonary artery) of the donor's heart graft, which was connected to the recipient's inferior vena cava (IVC).

Figure 6: Representative micrographs of the aortic (A) and cardiac (B) grafts 90+ days post-transplantation treated with anti-CD40L and CTLA4.Ig stained with hematoxylin & eosin. Scale bars = 100 μm for (A); 500 μm for (B).

References

1. Perico N, Remuzzi G. Prevention of transplant rejection: current treatment guidelines and future developments. Drugs. 1997;54(4):533-70.

2. Solini S, Aiello S, Cassis P, Scudeletti P, Azzollini N, Mister M, et al. Prolonged cold ischemia accelerates cellular and humoral chronic rejection in a rat model of kidney allotransplantation. Transpl Int. 2012;25(3):347-56.

3. Mazer SP, Pinsky DJ. Alive and kicking: endothelium at the geographic nexus of vascular rejection. Circ Res. 2002;91(12):1085-8.

4. Lee MS, Finch W, Weisz G, Kirtane AJ. Cardiac allograft vasculopathy. Rev Cardiovasc Med. 2011;12(3):143-52.

5. Corry RJ, Winn HJ, Russell PS. Primarily vascularized allografts of hearts in mice. The role of H-2D, H-2K, and non-H-2 antigens in rejection. Transplantation. 1973;16(4):343-50.

6. Sho M, Yamada A, Najafian N, Salama AD, Harada H, Sandner SE, et al. Physiological mechanisms of regulating alloimmunity: cytokines, CTLA-4, CD25+ cells, and the alloreactive T cell clone size. J Immunol. 2002;169(7):3744-51.

7. Poston RS, Billingham M, Hoyt EG, Pollard J, Shorthouse R, Morris RE, et al. Rapamycin reverses chronic graft vascular disease in a novel cardiac allograft model. Circulation. 1999;100(1):67-74.

8. Tepperman E, Ramzy D, Prodger J, Sheshgiri R, Badiwala M, Ross H, et al. Surgical biology for the clinician: vascular effects of immunosuppression. Can J Surg. 2010;53(1):57-63.

9. Yun JJ, Fischbein MP, Whiting D, Irie Y, Fishbein MC, Burdick MD, et al. The role of MIG/CXCL9 in cardiac allograft vasculopathy. Am J Pathol. 2002;161(4):1307-13.

10. Schenk S, Kish DD, He C, El-Sawy T, Chiffoleau E, Chen C, et al. Alloreactive T cell responses and acute rejection of single class II MHC-disparate heart allografts are under strict regulation by CD4+ CD25+ T cells. J Immunol. 2005;174(6):3741-8.

11. Sun H, Valdivia LA, Subbotin V, Aitouche A, Fung JJ, Starzl TE, et al. Improved surgical technique for the establishment of a murine model of aortic transplantation. Microsurgery. 1998;18(6):368-71.

12. Azuma H, Tilney NL. Chronic graft rejection. Curr Opin Immunol. 1994;6(5):770-6.

13. Ensminger SM, Billing JS, Morris PJ, Wood KJ. Development of a combined cardiac and aortic transplant model to investigate the development of transplant arteriosclerosis in the mouse. J Heart Lung Transplant. 2000;19(11):1039-46.

14. Soleimani B, Fu F, Lake P, Shi VC. Development of a combined heart and carotid artery transplant model to investigate the impact of acute rejection on cardiac allograft vasculopathy. J Heart Lung Transplant. 2008;27(4):450-6.

15. Cho HR, Suh JH, Lee EA, Kim JE, Lee SC, Kwon B. Improved surgical technique for heterotopic aortic transplantation in mice. J Korean Med Sci. 2007;22(1):12-5.

16. Mao M, Liu X, Tian J, Yan S, Lu X, Gueler F, et al. A novel and knotless technique for heterotopic cardiac transplantation in mice. J Heart Lung Transplant. 2009;28(10):1102-6.

17. Zheng XX, Markees TG, Hancock WW, Li Y, Greiner DL, Li XC, et al. CTLA4 signals are required to optimally induce allograft tolerance with combined donor-specific transfusion and anti-CD154 monoclonal antibody treatment. J Immunol. 1999;162(8):4983-90.

18. Gilson CR, Milas Z, Gangappa S, Hollenbaugh D, Pearson TC, Ford ML, et al. Anti-CD40 monoclonal antibody synergizes with CTLA4-Ig in promoting long-term graft survival in murine models of transplantation. J Immunol. 2009;183(3):1625-35.

19. Khalifah AP, Hachem RR, Chakinala MM, Yusen RD, Aloush A, Patterson GA, et al. Minimal acute rejection after lung transplantation: a risk for bronchiolitis obliterans syndrome. Am J Transplant. 2005;5(8):2022-30.

20. Tejani A, Ho PL, Emmett L, Stablein DM, North American Pediatric Renal Transplant Cooperative S. Reduction in acute rejections decreases chronic rejection graft failure in children: a report of the North American Pediatric Renal Transplant Cooperative Study (NAPRTCS). Am J Transplant. 2002;2(2):142-7.

21. Koulack J, McAlister VC, Giacomantonio CA, Bitter-Suermann H, MacDonald AS, Lee TD. Development of a mouse aortic transplant model of chronic rejection. Microsurgery. 1995;16(2):110-3.

22. Chereshnev I, Trogan E, Omerhodzic S, Itskovich V, Aguinaldo JG, Fayad ZA, et al. Mouse model of heterotopic aortic arch transplantation. J Surg Res. 2003;111(2):171-6.

23. Su S, Turk TR, Wu S, Fan H, Fu J, Wu K, et al. Modified suture technique in a mouse heart transplant model. Asian J Surg. 2011;34(2):86-91.

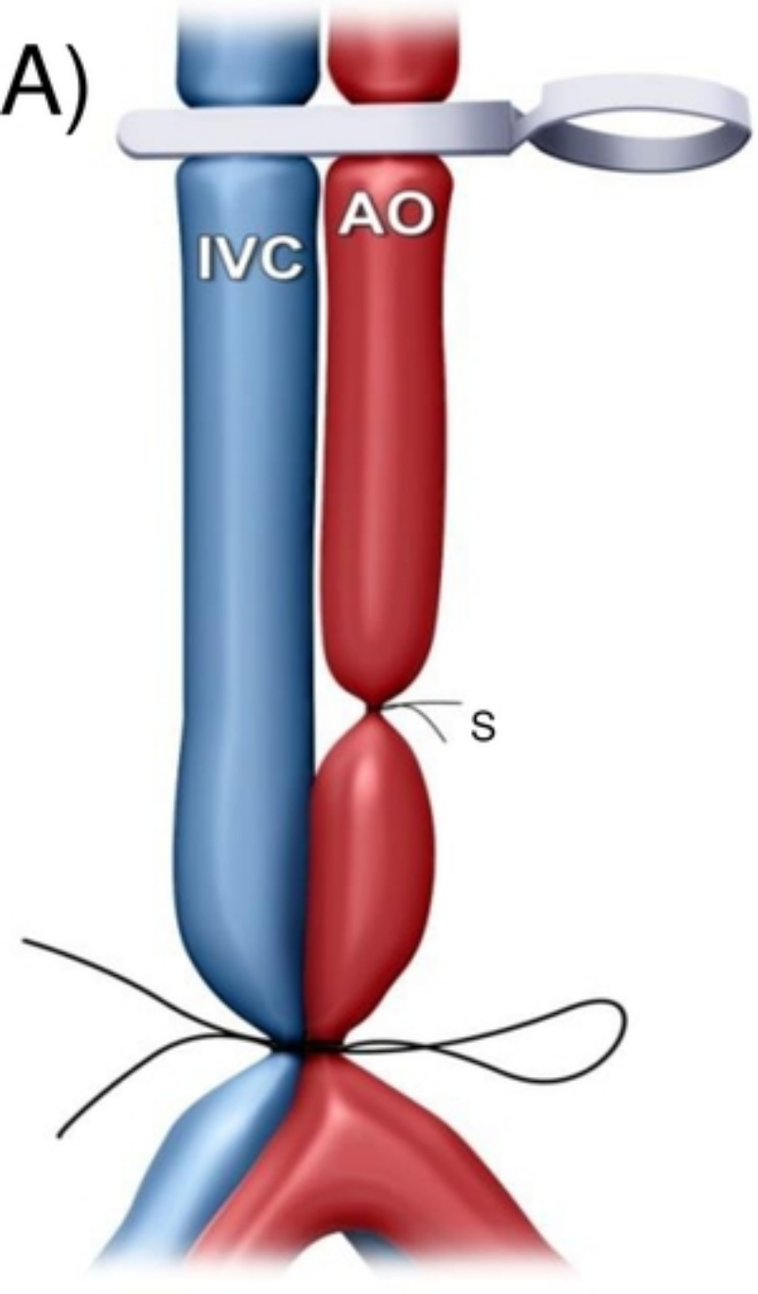

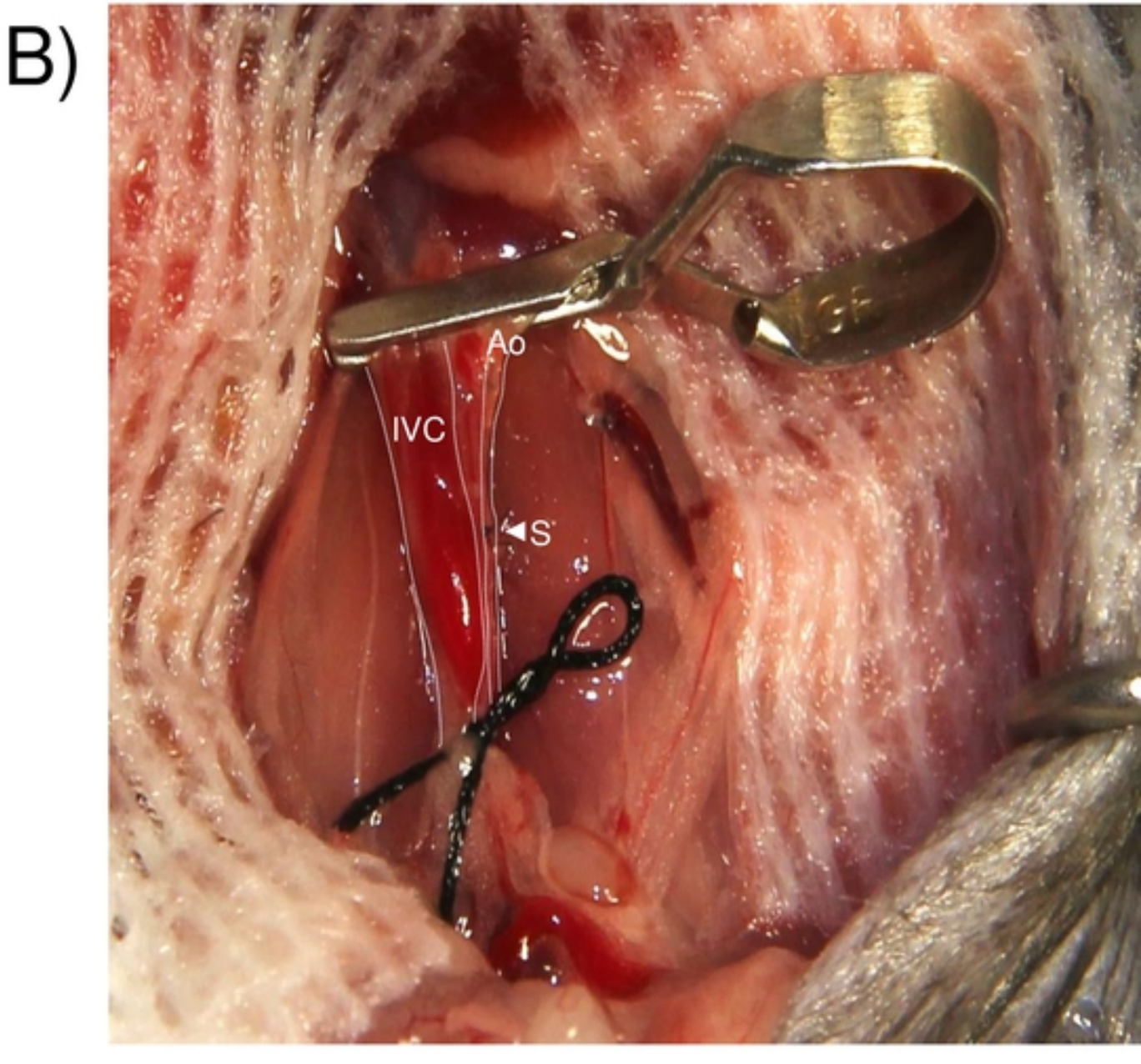

Figure 1.

Figure 1

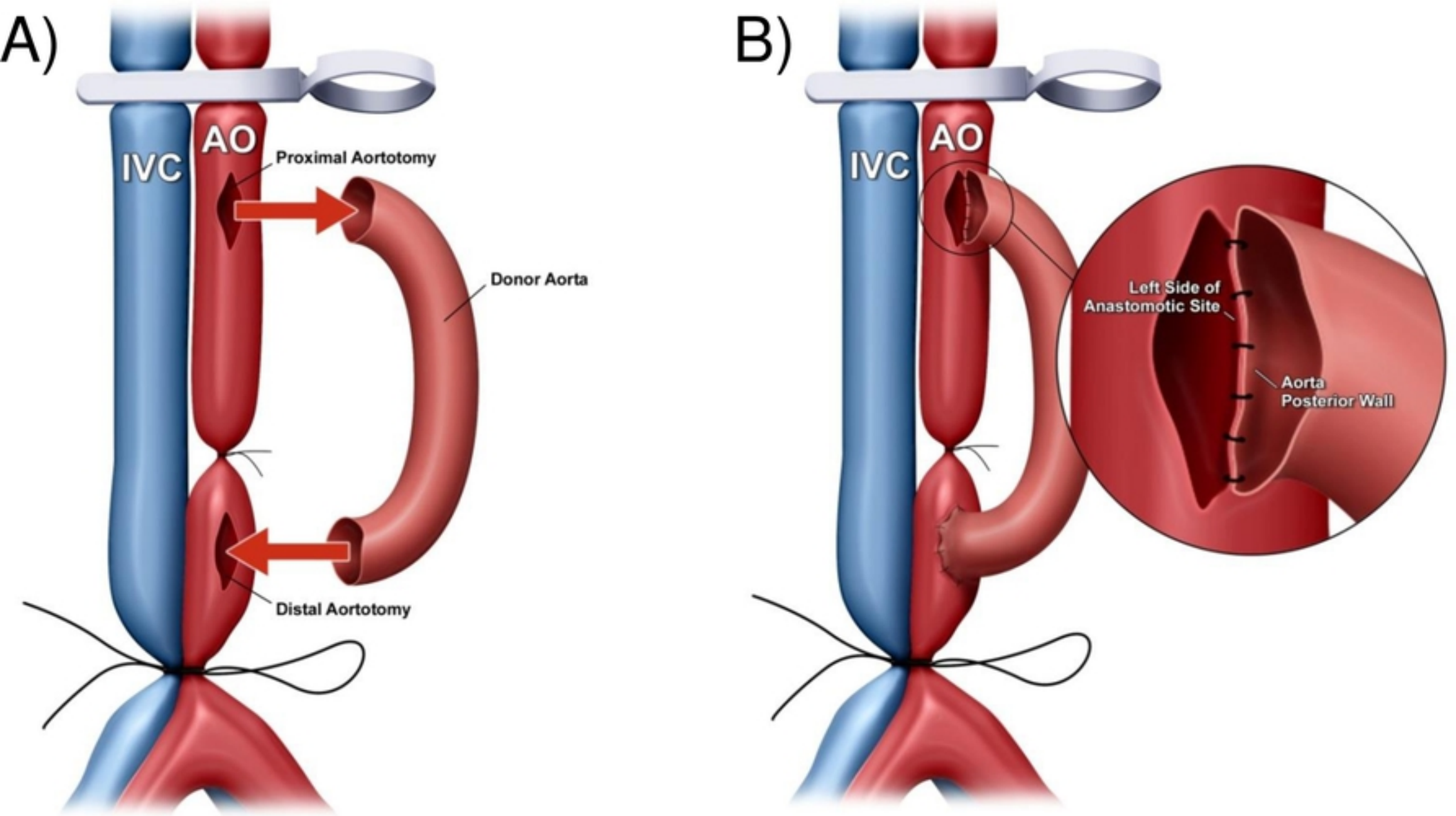

Figure 2.

Figure 2

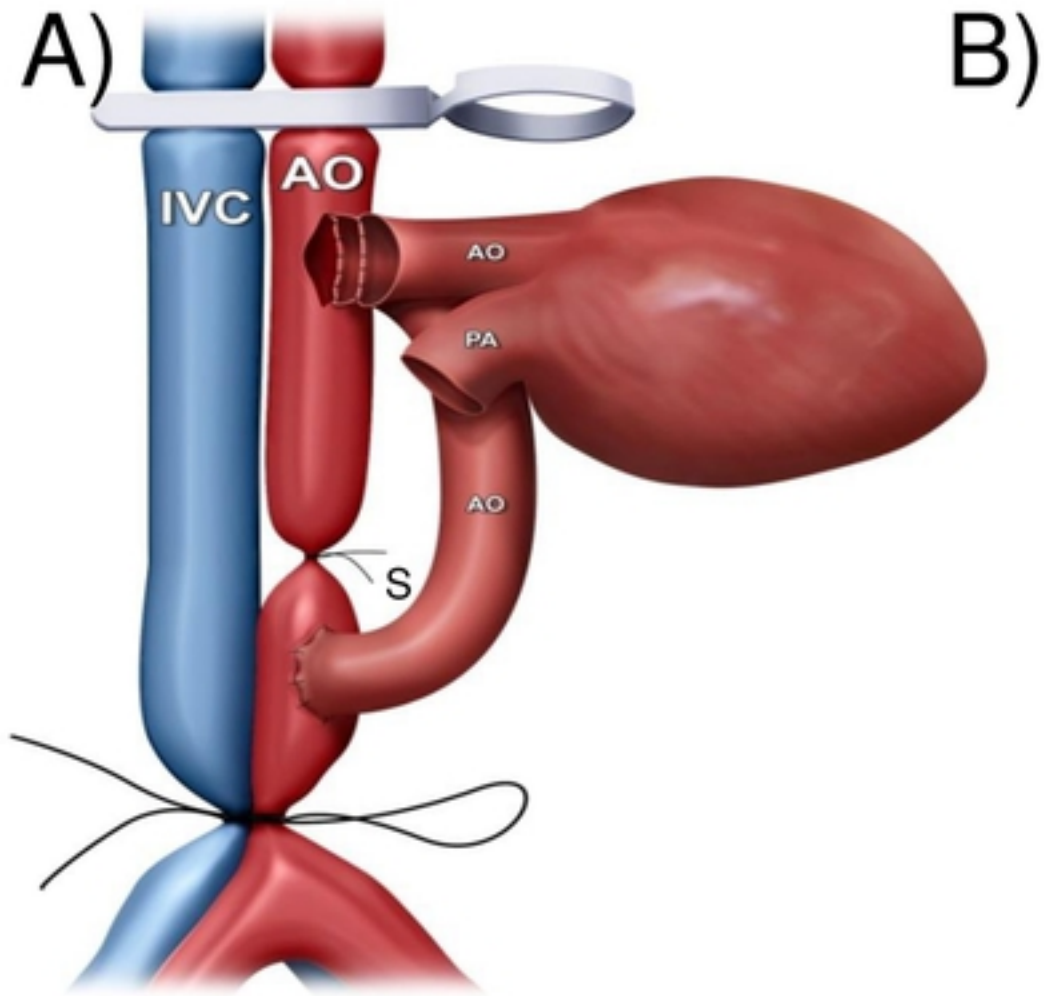

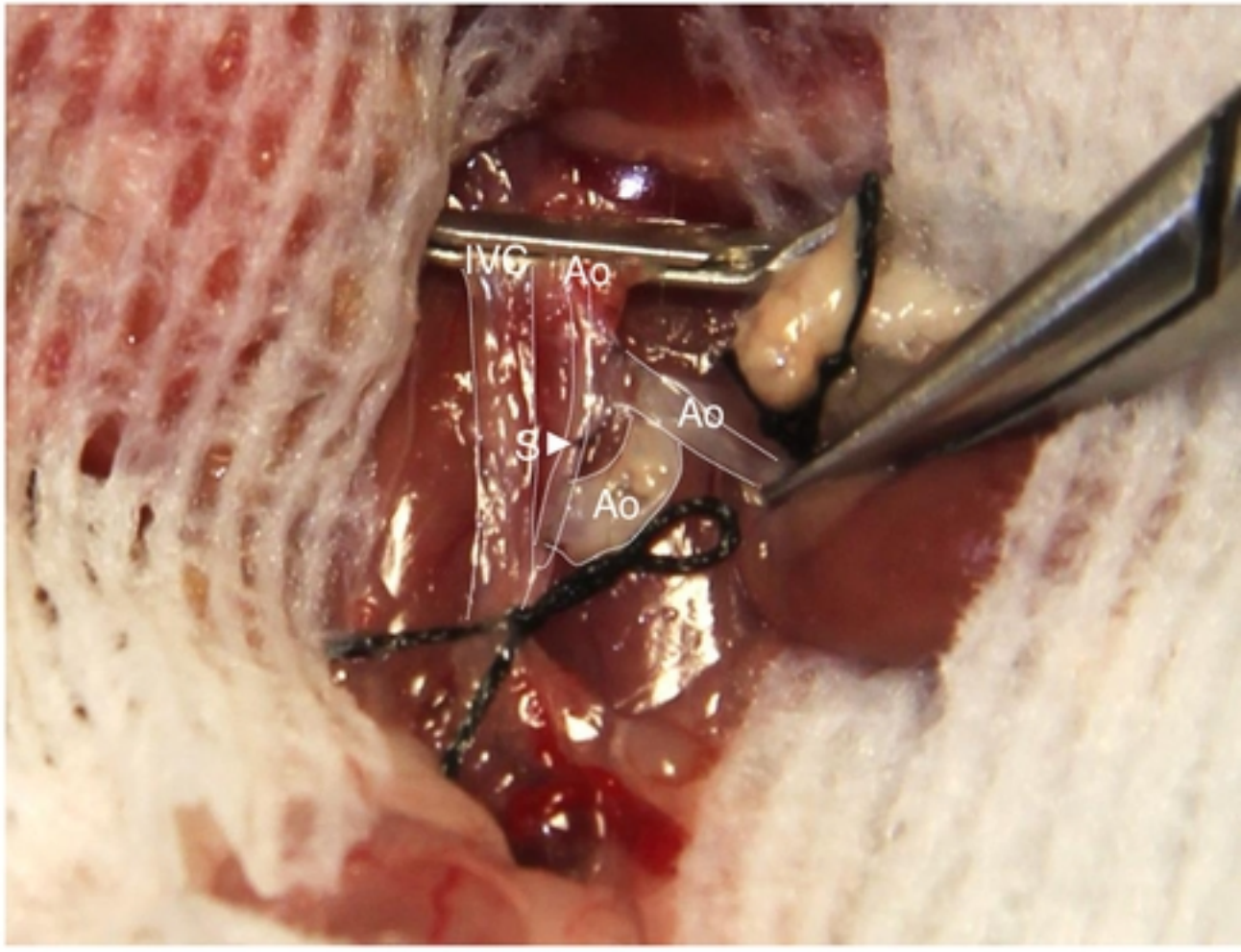

Figure 3.

Figure 3

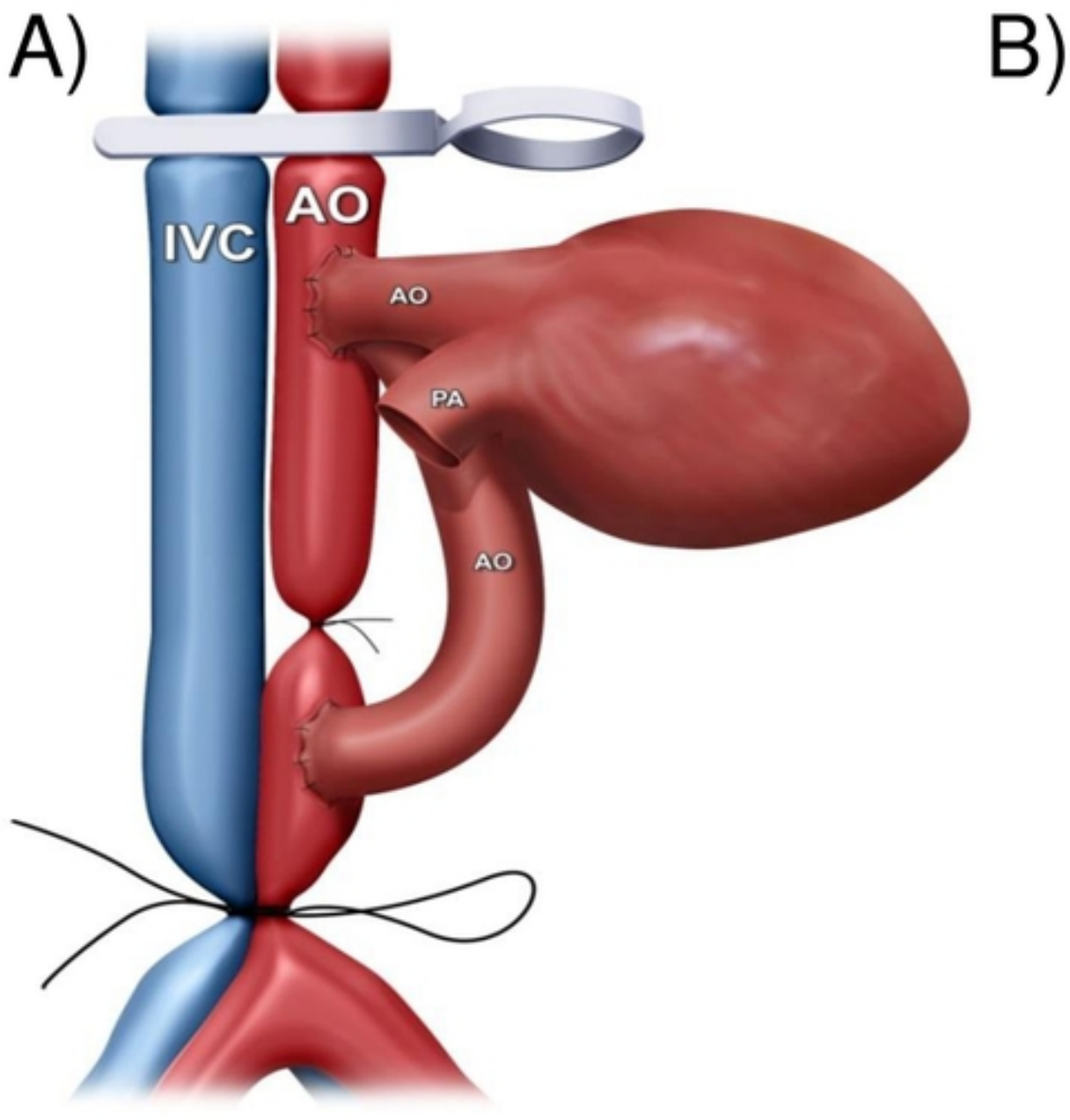

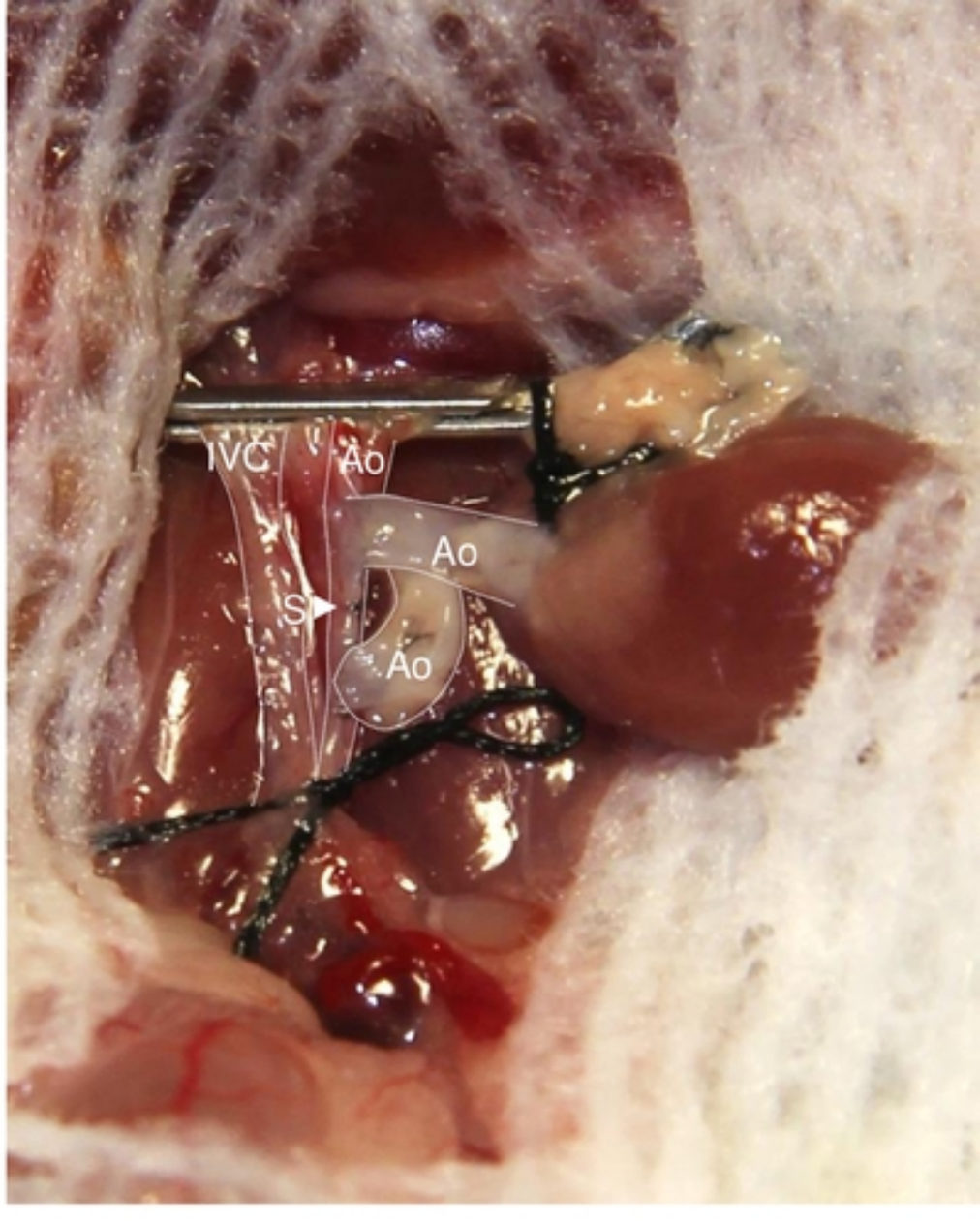

Figure 4.

Figure 4

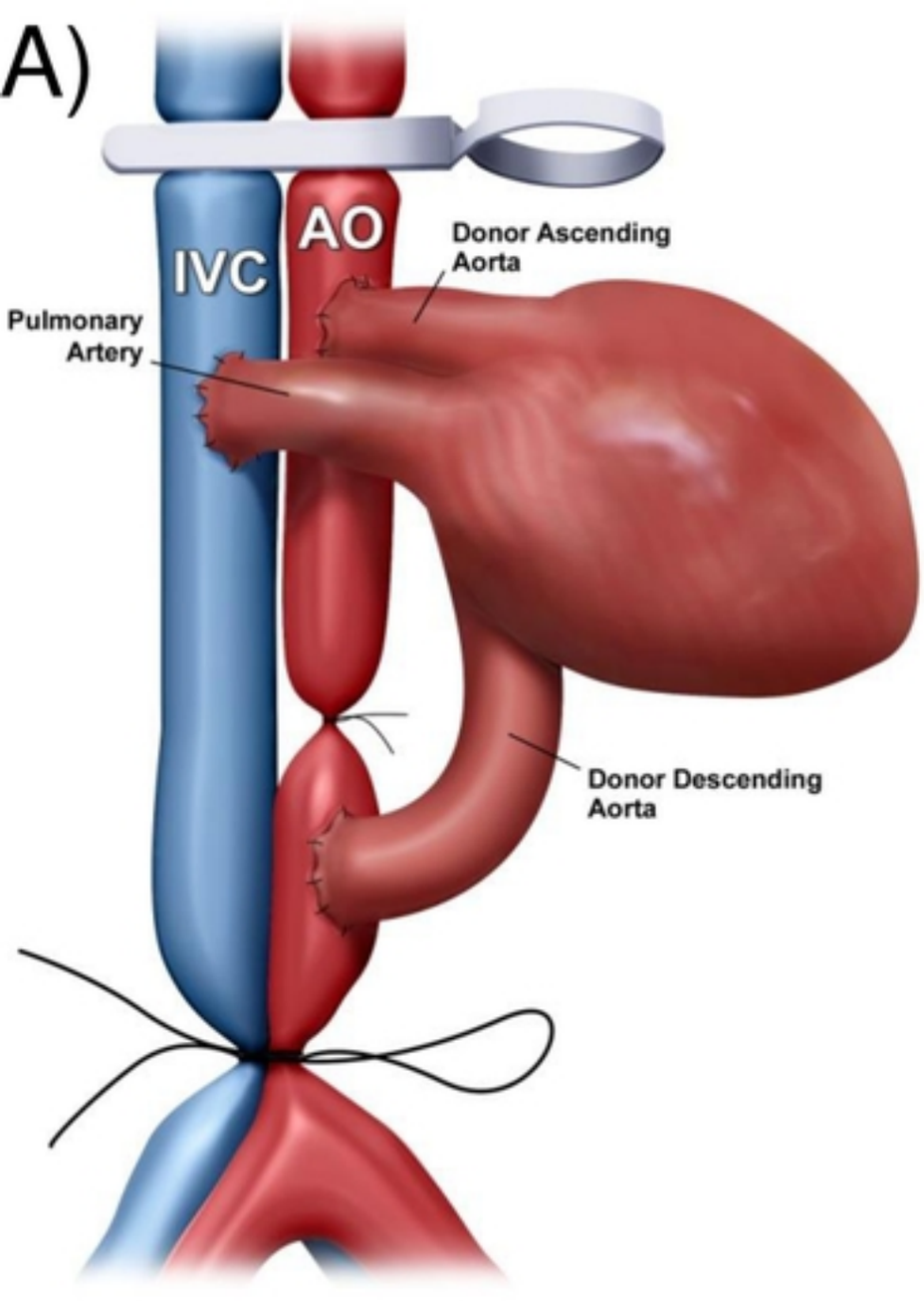

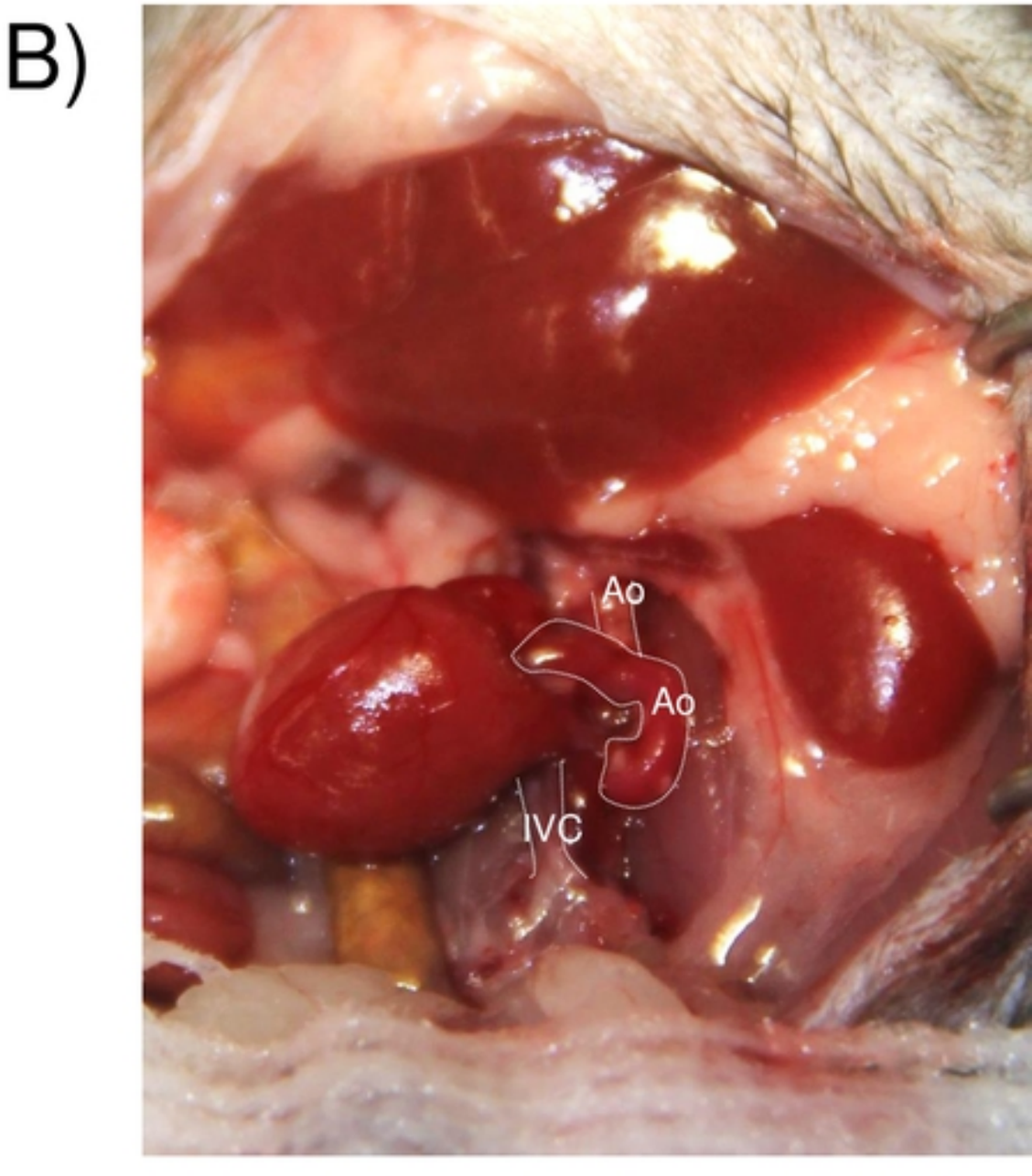

Figure 5.

Figure 5

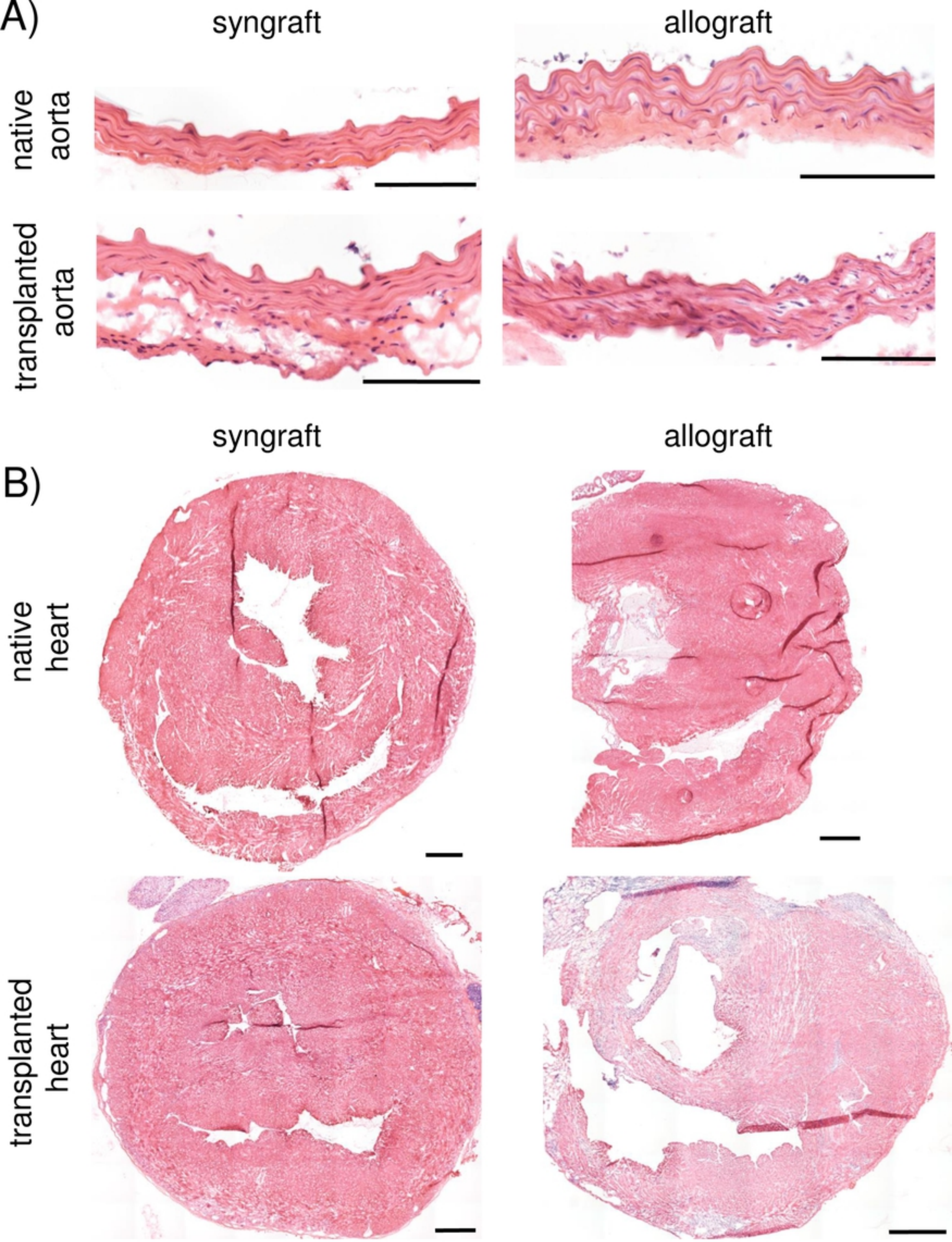

Figure 6.

Figure 6