Mapping the human praxis network: an investigation of white matter disconnection in limb apraxia

Hannah Rosenzopf[1]; Daniel Wiesen[1]; Alexandra Basilakos[2]; Grigori Yourganov[3]; Leonardo Bonilha[4]; Christopher Rorden[3]; Julius Fridriksson[2]; Hans-Otto Karnath[1,2]; Christoph Sperber[1]

Centre of Neurology, Division of Neuropsychology, Hertie-Institute for Clinical Brain Research, University of Tübingen, Tübingen, Germany

[2]Department of Communication Sciences and Disorders, University of South Carolina, Columbia, SC, USA

[3]Department of Psychology, University of South Carolina, Columbia, SC

[4] Department of Neurology, Medical University of South Carolina, Charleston, SC, USA

Correspondence should be addressed to:

Christoph Sperber

Centre of Neurology

University of Tübingen

72076 Tübingen

Germany

Phone: 49 - 7071 - 29 80463

e-mail: christoph.sperber@klinikum.uni-tuebingen.de

Abstract

Stroke to the left hemisphere of the brain can cause limb apraxia, a disorder characterised by deficits of higher order motor skills such as the failure to accurately produce meaningful gestures. This disorder provides unique insights into the anatomy of the human praxis system. The present study aimed to identify the structural brain network, that when damaged by stroke, causes limb apraxia. We assessed the ability to perform meaningful gestures with the hand in 101 patients with chronic left hemisphere stroke. Structural damage to white matter fibres was assessed by diffusion tensor imaging. A support vector regression model predicting apraxia based on individual topographies of tract-based fractional anisotropy was utilised to obtain multivariate topographical inference. We found pathological white matter alterations in a densely connected fronto-temporo-parietal network of short and long association fibres to predict limb apraxia deficits. Major disconnection affected temporo-parietal and temporo-temporal connections. Grey matter areas with a high number of disconnections included inferior parietal lobe, middle and superior temporal gyrus, inferior and middle frontal lobe, precentral gyrus, putamen, and caudate nucleus. These results demonstrate the relevance of frontal and inferior parietal regions in praxis, but they also highlight the temporal lobe and its connections to be an important contributor to the human praxis network.

Keywords: stroke; gesture; connectome; fractional anisotropy; multivariate; support vector regression

Running title: White matter connections in limb apraxia

Introduction

Common consequences of stroke to the left hemisphere include disorders of higher-order motor control. These disorders are summarised under the term 'apraxia' and include symptoms such as the inability to perform, imitate, or recognize different kinds of gestures. Among those are meaningful gestures such as the pantomime of tool use (De Renzi *et al.*, 1982; Goldenberg & Hagmann, 1998) and communicative gestures like 'waving goodbye' (Haaland & Flaherty, 1984; Dressing *et al.*, 2018). The present study investigated apraxia in the production of the two previously mentioned forms of meaningful gestures, hereafter simply called 'apraxia'. Many previous studies aimed to identify the neural correlates of deficits in gesture production by lesion-behaviour mapping (e.g. Goldenberg *et al.*, 1996; Haaland *et al.*, 2000; Goldenberg *et al.*, 2007; Buxbaum *et al.*, 2014; Hoeren *et al.*, 2014; Goldenberg & Randerath, 2015; Weiss *et al.*, 2016; Sperber *et al.*, 2019a; Wong *et al.*, 2019). Damage to several parietal, temporal, and frontal cortical regions mainly in the left hemisphere have been found to be associated with apraxia, including the angular and supramarginal gyri (Varney & Damasio, 1987; Sperber *et al* 2019a), middle temporal (Johnson-Frey *et al.*, 2005; Manuel *et al.*, 2013; Buxbaum *et al.*, 2014; Hoeren *et al.*, 2014;) and superior temporal gyri (Varney & Damasio, 1987), inferior frontal gyrus (Goldenberg, *et al.*, 2007; Manuel *et al.*, 2013; Weiss *et al.*, 2016), insula (Goldenberg *et al.*, 2007; Hermsdörfer, *et al.*, 2011 Hoeren *et al.*, 2014; Sperber *et al.*, 2019a), and premotor areas (Bohlhalter *et al.*, 2009; Weiss *et al.*, 2016). In the light of these findings, several theories postulated a brain network to underlie apraxia, and further findings, e.g. based on electroencephalography (Wheaton *et al.*, 2005) and fibre tracking in healthy subjects (Vry *et al.*, 2015), support this notion.

The idea that apraxia results from disruptions of a complex brain network is as old as its first case descriptions by Liepmann (1905). Although theories about the architecture of this network have undergone adaptations throughout the past century, the notion of a fronto-

(temporo-)parietal praxis network still dominates the field (Geschwind, 1975; Heilman & Rothi, 1993; Niessen, *et al.*, 2014; Goldenberg, 2003; Sperber *et al.*, 2019a). A popular network theory highlights distinct dorso-dorsal, dorso-ventral and ventral visual processing streams in the human brain. Originally proposed for action-related (dorsal) and non-action-related (ventral) visual processing (Ungerlieder & Mishkin, 1982; Milner & Goodale, 1995; Rizzolatti & Martelli, 2003), these streams were later discussed in context with apraxia (Buxbaum & Kalenine, 2010). The pathways' contributions to different forms of apraxia were disentangled (Hoeren *et al.*, 2014), who suggested that imitation appeared strongly associated with the dorso-dorsal stream, whereas impairment of pantomime was associated with injury to the ventral stream and regions in the dorsal-ventral junction (Hoeren *et al.*, 2014).

One component of an anatomical brain network underlying praxis are fibre tracks connecting relevant cortical areas. However, most network theories of apraxia focus on cortical nodes of hypothesized networks. Accordingly, white matter contributions were only a minor topic in previous lesion-behaviour mapping studies. Some studies using structural lesion imaging found topographical statistical results in white matter (Goldenberg *et al.*, 2007; Manuel *et al.*, 2013; Sperber *et al.*, 2019a). White matter tracts associated with apraxia of pantomime were found in parietal regions (in tumour patients, Manuel *et al.*, 2013), below the precentral gyrus (in stroke patients, Goldenberg *et al.*, 2007) as well as in ventral fibres of the extreme capsule (Hoeren *et al.*, 2014; Vry *et al.*, 2015). A multivariate lesion-behaviour mapping study found focal lesion damage to several major fibre bundles, including fronto-parietal connections, to be associated with apraxia (Sperber *et al.*, 2019a).

Importantly, the identification of white matter damage contributions to apraxia based on lesion-behaviour mapping bears some limitations. First, univariate statistical approaches might sometimes lack statistical power to identify a full brain network (Sperber *et al.*, 2019a, 2019b), and thus might fail to identify some relevant fibre tracks. Second, topographical lesion-brain inference only indirectly assesses white matter contributions to symptoms via

reference to brain atlases, and conclusions largely depend on what brain atlas is chosen to interpret results (de Haan & Karnath, 2017).

The present study aimed to directly assess white matter damage contributions to stroke patients' apractic deficits in gesture production. This was carried out by using tract-based multivariate spatial statistics on fractional anisotropy maps in chronic patients with left hemisphere stroke. We aimed to identify both i) direct effects of lesion damage to white matter tracts, and ii) remote lesion effects on white matter integrity, as, for example, induced by Wallerian degeneration.

Materials and methods

Patients and behavioural assessment

Data from 101 individuals who had suffered a single-event left hemispheric stroke were extracted from an archival database at the University of South Carolina. This database is comprised of testing from several research studies investigating aphasia and its clinical management. Patients were included in these research studies based on the following criteria: i) between the ages of 21-80, and ii) at least six months post-single-event left hemisphere ischemic stroke. Exclusion criteria included: i) stroke involving the right hemisphere, brainstem, and/or cerebellum, ii) other neurologic illness/injury affecting the brain, iii) history of developmental speech and/or language disorder. Of note, participants were included in the present study regardless of aphasia diagnosis. All participants signed an informed consent form that was approved by the Institutional Review Board at the University of South Carolina or Medical University of South Carolina. All study procedures adhered to the principles set forth by the revised Declaration of Helsinki. Descriptive statistics concerning demographic, behavioural and lesion data can be found in table 1.

Participants were included in the chronic stage of stroke and were on average 43 months post-stroke (SD = 47 months). Aphasia was tested with the Western Aphasia Battery

(WAB; Kertesz, 1982) or the Western Aphasia Battery-Revised (WAB-R; Kertesz, 2007). For patients with a diagnosis of aphasia (i.e., a WAB or WAB-R Aphasia Quotient <93.8), it was ensured that their understanding was sufficient for further tasks, and patients with severe comprehension difficulties were excluded.

Table 1

Demographic and clinical data of all 101 patients. WAB = Western Aphasia Battery (cut-off for diagnosis of aphasic impairment < 93.8), ABA-2 = Aphasia Battery for Adults-2nd Edition.

	Mean	SD	Range
Age	59.9 years	11.0	30-81
Sex: f/m	34/67		
Lesion size	128756 mm^3	92821	2094 – 472377
ABA-2	44.3	8.01	0 – 50
WAB	60.0	23.4	16.5 – 96.4
Time post-stroke at screening	43.2 months	46.7	5 - 224

Apraxia was assessed using the limb apraxia subscale from the Apraxia Battery for Adults-2 (Dabul, 2000). The test contains ten gestures that are to be executed upon oral instruction ("make a fist", "wave good-bye", "snap your fingers", "throw a ball", "hide your eyes", "make a hitchhiking sign", "make a pointing sign", "salute", "play the piano" "scratch". [For those gestures involving objects, those objects weren't actually present, and participants had to pantomime their use]). The gesture was executed using the dominant hand post stroke and rated between 0 (inability to complete the gesture even after demonstration of

the gesture by the examiner) and 5 for best performance (i.e., the participant provides an accurate and prompt gestural response). Four points were given if the examinee produced an incorrect gesture, but self-corrected it; three points were given if the gesture was basically correct but "crude and defective"; two points were given if the examinee produced the correct gesture after additional demonstration by the examiner; one point was given if the gesture was basically correct, but crude and defective after demonstration (Dabul, 2000). Tests were either rated online by the clinician who administered the test, or, in some cases, videos were recorded and reviewed later for scoring purposes.

Imaging and image processing

Brain imaging was acquired close to the behavioural assessment using a 3-T Siemens Trio scanner with a 12-channel head coil. T1-weighted scans were obtained with an MP-RAGE (TFE) sequence with voxel size = 1 mm^3, FOV = 256 × 256 mm, 192 sagittal slices, 9-degree flip angle, TR = 2250 ms, TI = 925 ms, and TE = 4.15 ms, GRAPPA = 2, 80 reference lines. T2-weighted scans were obtained with 3D SPACE protocol with voxel size = 1 mm^3, FOV = 256 × 256 mm, 160 sagittal slices, variable flip angle, TR = 3200 ms, TE = 352 ms, no slice acceleration, and the same slice centre and angulation as in the T1 imaging. Fractional anisotropy (FA) was computed using diffusion tensor imaging (DTI). Diffusion imaging which was acquired by a mono-polar sequence with 82 isotropic (2.3mm) volumes (×10 B = 0,×72 B = 1000), TR = 4987 msec, TE = 79.2 msec, 90 × 90 matrix, with parallel imaging GRAPPA = 2, and 50 contiguous slices. The sequence was carried out in two series (41 volumes in each series) with opposite phase encoding. Images were denoised using MRTrix (https://www.mrtrix.org/), and undistorted using FSL's TOPUP and Eddy tools (Andersson & Sotiropoulos, 2016; Andersson *et al.*, 2003). Conversion of 4D DTI images, bvecs, and bvals to fractional anisotropy maps was carried out by FSL's DTIFIT tool. Fractional anisotropy data were processed according to the standard procedures for tract-based spatial statistics

(TBSS, Smith *et al.*, 2006), with the exception that during nonlinear registration each patient's individual lesion was masked to avoid distortions. TBSS projects all subjects' FA data onto a mean FA tract skeleton. An average skeletonised fractional anisotropy map of all patients is depicted in figure 1.

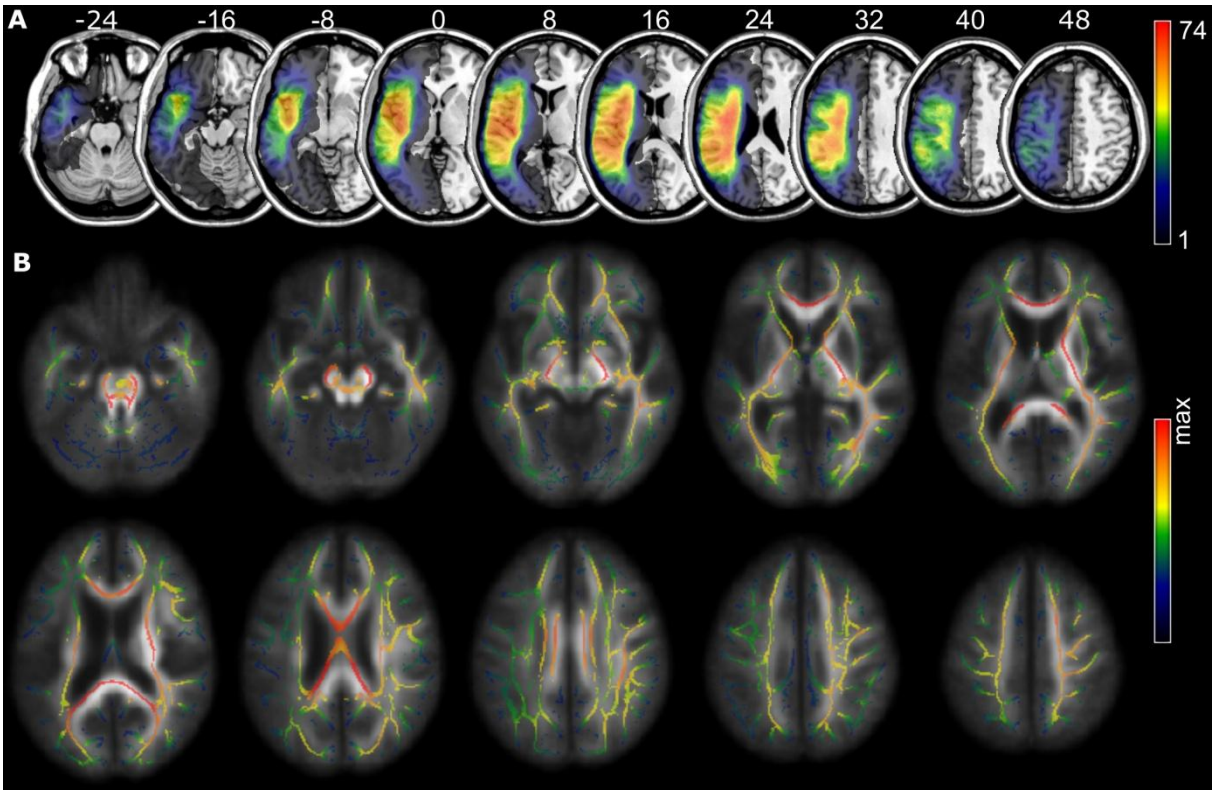

Figure 1
Lesion topography and mean fractional anisotropy. For all 101 patients, the (A) lesion topography after enantiomorphic normalisation in SPM and (B) average skeletonised FA topography after normalisation and skeletonization with TBSS is shown on the average non-skeletonised, normalised FA maps. Numbers above slices indicate the Z-coordinate in MNI space.

Brain lesions were mapped using T2-weighted imaging, which better depicts the position of a structural lesion than T1-weighted imaging. Trained experts manually delineated lesions on T2-weighted images using MRIcron (http://www.mricron.com/). T2-weighted scans and lesion masks were co-registered to T1-weighted imaging. Lesion masks were normalised by warping T1-weighted images to age-specific normalisation templates of elderly healthy controls using SPM 12 (http://www.fil.ion.ucl.ac.uk/spm/software/spm12/) and

Clinical Toolbox (Rorden *et al.*, 2012) with enantiomorphic-segmentation normalisation (Nachev *et al.*, 2008). A lesion topography of all patients is depicted in figure 1.

Support-vector regression-based fractional anisotropy mapping

The relation between voxel-wise fractional anisotropy and apraxia scores was investigated with a multivariate, machine-learning-based topographical analysis using support-vector regression. The general approach was adopted from state-of-the-art multivariate topographical inference methods used in the field of lesion behaviour mapping, where support vector regression-based lesion-symptom mapping (SVR-LSM, Zhang *et al.*, 2014) was recently used to identify the neural correlates of apraxia of pantomime (Sperber *et al.*, 2019a). This method involved two major steps: first, a support vector regression (Vapnik, 1995) was trained to predict behavioural scores based on voxel-wise, skeletonised fractional anisotropy values. Second, the contribution of individual voxels to the model was statistically evaluated with a permutation approach. The analysis was based on the FA-skeleton topographies. A support vector regression (SVR) with a linear kernel was used to predict apraxia scores by modelling voxel-wise, skeletonised fractional anisotropy values. Hyper-parameter C was optimised to maximise model fit and reproducibility of feature weights (Rasmussen *et al.*, 2012; Zhang *et al.*, 2014) with a five times five-fold cross-validation procedure in the range of $C = [2^{-20}, 2^{-19}, \ldots 2^{0}, \ldots 2^{19}, 2^{20}]$. Model fit was computed by SVR modelling of four fifths of the data and assessing the correlation between the real and predicted scores in the last fifth of the data. Reproducibility was assessed by computing the average correlation coefficient r of feature weights between cross-validation subsets, and then computing the average r of all possible combinations of subsets. With the optimised C, an SVR was computed including data from all 101 patients, and the feature weights, i.e. the contribution of each voxel-wise FA value to the model, were determined. A second step aimed to identify the features that provide a statistically significant contribution to this model by using a permutation procedure. Using the

same procedures as described above, voxel-wise feature weights were also computed 25000 times for data sets consisting of the original FA data, and a random permutation of the original behavioural data. Next, for each voxel, a statistical p-value was assigned to each feature weight in the original feature weight map by reference to the permutation-based feature weights. The required correction for multiple comparisons (Sperber *et al.*, 2019b) was carried out by false discovery rate (FDR; Benjamini & Yekuteli, 2001) correction at $q = 0.05$. Further analyses were conducted with the FDR-corrected topography, and with small clusters <20 voxels removed.

Region-based evaluation of structural disconnectivity

To get a more detailed description which of the connections between grey matter areas are affected, we evaluated the disconnectome of our TBSS-based SVR-LSM analysis. The exact procedure can be found in the supplementary material. In short, we first created a whole brain tractogram with MRtrix (https://www.mrtrix.org/; Tournier *et al.*, 2012) by using input files from the IIT Human Brain Atlas v.5.0 (https://www.nitrc.org/projects/iit/; Zhang & Arfanakis, 2018). Next the connectome based on 84 ROIs of the Desikan-Kilkenny atlas and the whole-brain tractogram (Desikan *et al.*, 2006) was derived. By extracting all tracts running though our significant SVR-FA-map, we then quantified the disconnectome of our analysis (i.e. the number of affected tracts between any two atlas ROIs related to limb apraxia).

In a second analysis, the clusters of significant voxels in the SVR-FA-mapping were referenced to a probabilistic white matter atlas based on diffusion tensor imaging (Zhang *et al.*, 2010) to identify a possible affection of major fibre tracks. Probabilistic maps of long association, projection, and commissural fibres were binarised at $p \geq 0.4$. Binary maps were overlaid with the SVR-FA-map and the overlapping volume was identified.

Data availability

All analysis scripts and resulting topographies are publicly available at http://dx.doi.org/10.17632/dcpst33wc7.1. The clinical datasets analysed in the current study are not publicly available due to the data protection agreement approved by the local ethics committees and signed by the participants. They are available from Julius Fridriksson (fridriks@mailbox.sc.edu) on reasonable request.

Results

The hyper-parameter optimisation found $C=2^{-18}$ to provide both a high reproducibility of $r = 0.84$ and a relatively high model fit of $r^2 = 0.25$. The permutation-based and FDR-controlled SVR-FA-map identified larger clusters of significant FA-behaviour relations in several left hemisphere regions, where lowered FA was predictive of apraxia scores (Figure 2). These included the largest clusters in parieto-temporal and temporal white matter, and further cluster in inferior frontal, parietal, and subcortical white matter.

Since the present study analyzed DTI data from neurological patients and examined them for inter-regional discontinuities using DTI data from healthy subjects, we decided to also use a DTI based atlas for referencing clusters of significant voxels to white matter anatomy (cf. Table 2). It implicated the involvement of several major fibre tracts in limb apraxia, including all segments of the superior longitudinal fascicle, the uncinate fascicle, the inferior fronto-occipital fascicle, and the inferior longitudinal fascicle. Further, some significant clusters were assigned to projection fibres, including the cortico-spinal tract. However, since such anatomical interpretation largely depends on what white matter brain atlas is chosen to interpret results (de Haan & Karnath, 2017), we additionally referenced clusters of significant voxels to the Juelich probabilistic cytoarchitectonic atlas (Bürgel *et al.*, 2006). Results are documented in the supplementary materials. Moreover, we make topographies publicly available at [http://dx.doi.org/10.17632/dcpst33wc7.1] for own purposes. In regions outside of the direct lesion areas, no significant FDR-corrected FA

alterations could be detected. This means that the analysis did not identify any supra-threshold remote effects of fractional anisotropy related to apractic deficits. However, several sub-FDR-threshold clusters in the uncorrected SVR-FA-map (see supplementary Figure and online materials) hinted at possible remote white matter alterations. Small clusters were scattered across frontal and posterior parts of the corpus callosum, and in the right hemisphere.

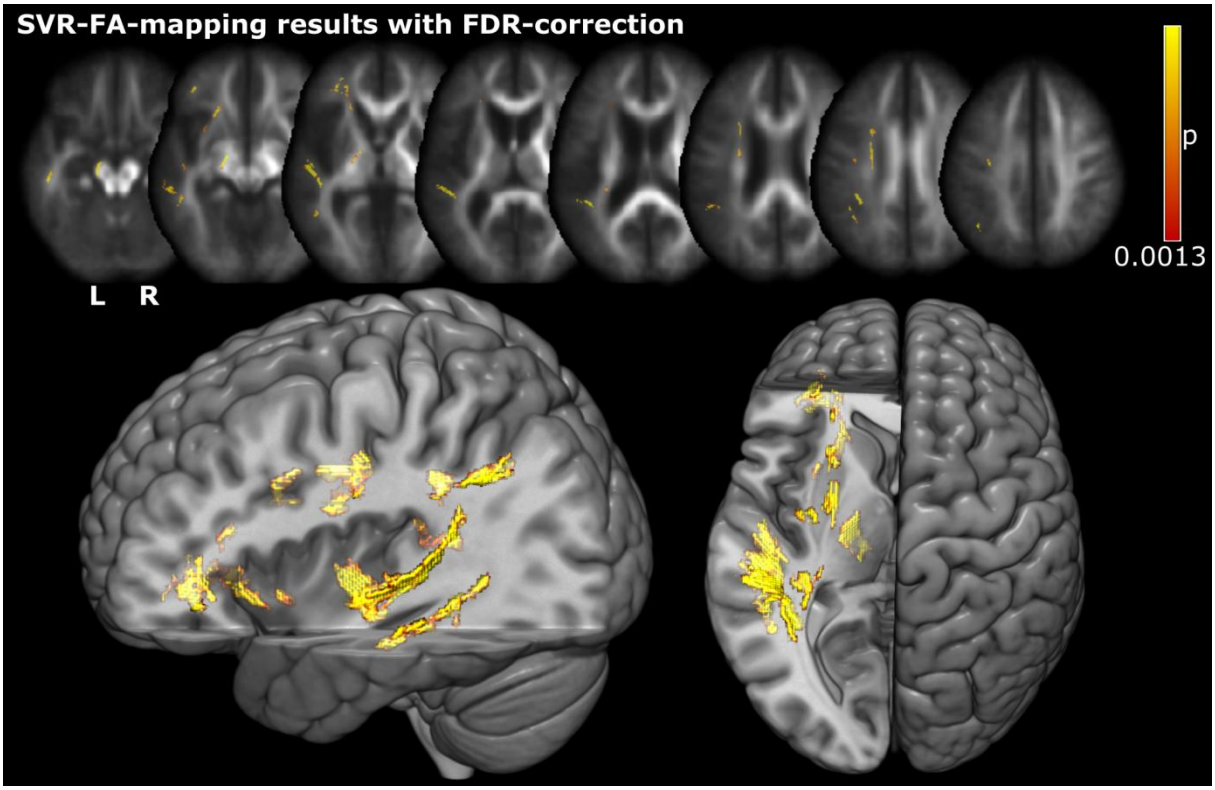

Figure 2
Results of the SVR-fractional anisotropy-mapping analysis. Permutation-based statistical topographies of voxels where FA values significantly contribute to apraxia are depicted after false discovery rate correction with $q = 0.05$ (equal to $p < 0.0013$) and removal of small clusters <20 voxels. The 2D topography is depicted on the un-skeletonized average FA maps; the 3D topography is depicted on the MNI152 template in MRIcroGL.

Table 2

Overlap between fibre tracts as defined by Zhang *et al.* (2010) and the significant voxels found in our analysis. Abbreviations: f = fasciculus, FP = fronto-parietal, FT = fronto-temporal, PT = parieto-temporal. There was no overlap with commissural fibre tracts. Fibre tracts with less than 20mm³ overlap are not depicted.

Fibre tract category		Number of affected voxels/ mm^3
Long association	Inferior fronto-occipital f.	307
	Inferior longitudinal f.	103
	Superior longitudinal f. (FP)	98
	Superior longitudinal f. (FT)	268
	Superior longitudinal f. (PT)	474
	Uncinate fasciculus	279
Projection	Corticospinal tract	326
	Thalamus – precentral gyrus	38
	Thalamus – superior frontal gyrus	127
	Thalamus – superior occipital gyrus	36

The region-based evaluation of structural disconnectivity identified a large number of inter-regional disconnections of varying strength. The most severe disconnections in terms of absolute numbers of disconnected streamlines are depicted in figures 3 and 4. A complete overview on disconnection metrics of all affected fibres can be found in the data provided in the online repository.

Left hemisphere grey matter areas displaying the highest number of disconnections (in descending order) included the putamen, superior temporal gyrus, caudate nucleus,

supramarginal gyrus, inferior parietal cortex (according to the Desikan parcellation consisting of inferior parietal gyrus and angular gyrus [Desikan *et al.*, 2006]), precentral gyrus, middle temporal gyrus, and the lateral orbitofrontal cortex. Noteworthy disconnections (in descending order) between two ROIs include the pathways between the superior temporal gyrus and transverse temporal cortex, putamen and caudate nucleus, the supramarginal gyrus and superior temporal gyrus, the middle temporal gyrus and the bank of the superior temporal sulcus, the supramarginal gyrus and inferior parietal lobe, lateral orbitofrontal cortex and the pars orbitalis, the middle temporal gyrus and the inferior parietal lobe, the superior temporal lobe and the bank of the superior temporal sulcus, the inferior and superior parietal cortex, rostral middle frontal cortex and the caudate nucleus, the lateral orbitofrontal cortex and putamen, as well as the putamen and insula.

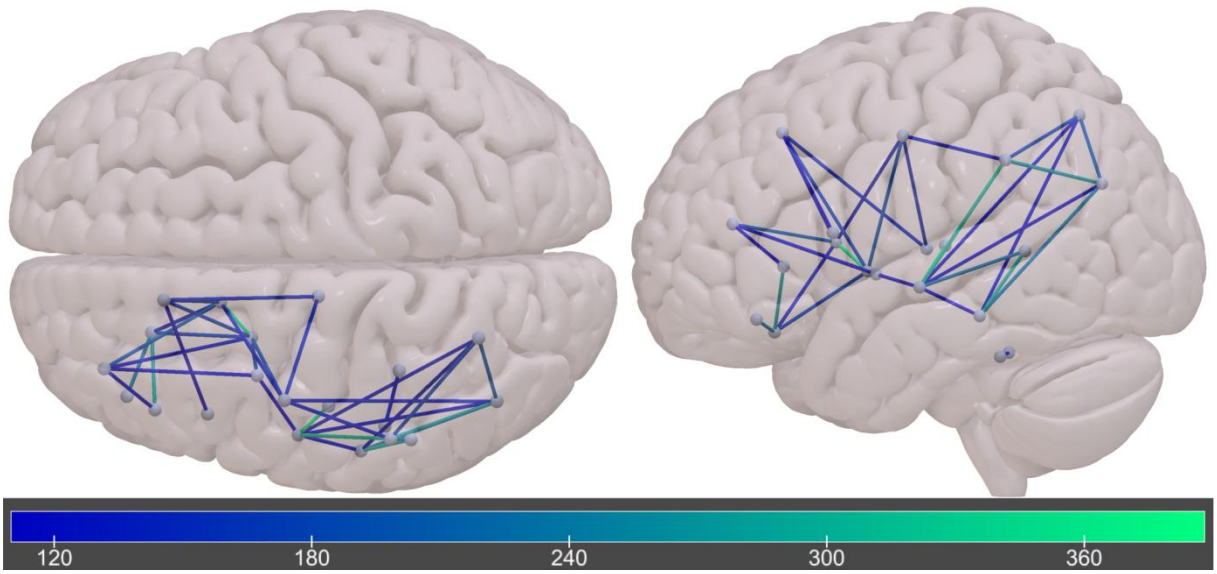

Figure 3
Region-based evaluation of structural disconnectivity (1). Line colour indicates the number of disconnected fibre bundles between grey matter areas in the Desikan atlas in the fibre tracking analysis in MRtrix. The threshold was set to 130 fibres to depict the strongest inter-regional disconnections. Data were visualised using Surf Ice (https://www.nitrc.org/projects/surfice/).

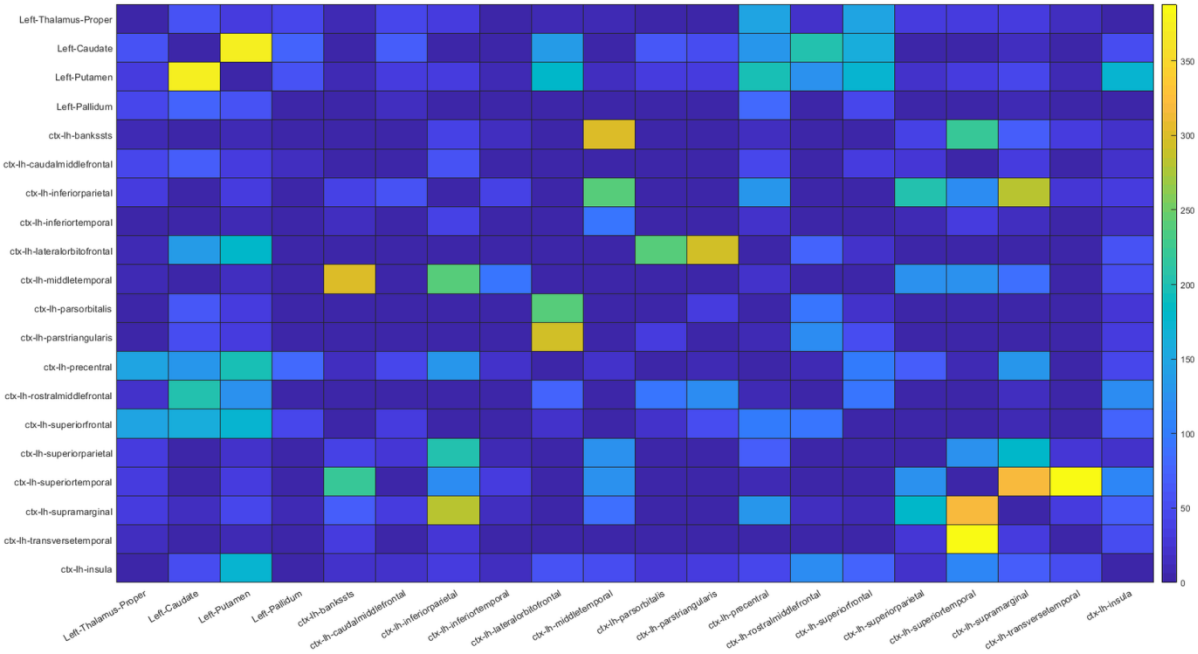

Figure 4
Region-based evaluation of structural disconnectivity (2). Heatmap of the 20 areas found to be most severely disconnected according to our analysis. Cell colour refers to the number of disconnected fibre bundles between the brain areas represented by the corresponding row and column. Full disconnectivity data are available in the online materials.

Discussion

The present analysis used MR diffusion imaging and tract-based, multivariate topographical analysis to uncover white matter damage related to limb apraxia. We identified a fronto-parieto-temporal praxis network with a particular parieto-temporal focus. Among others, severe apraxia-related disconnection was found for the superior temporal gyrus and transverse temporal cortex, supramarginal gyrus and superior temporal gyrus, as well as middle temporal gyrus and the inferior parietal lobe. Grey matter areas that were most severely disconnected included the inferior parietal cortex, respectively angular and supramarginal gyri, and to a lesser extent also the superior parietal cortex, the lateral orbitofrontal cortex, the superior, middle, and transversal temporal gyri, the banks of the superior temporal sulcus, putamen, as well as the precentral gyrus, the pars triangularis, the pars orbitalis, and the insula.

A structural praxis network

Clusters of white matter voxels where reduced fractional anisotropy was associated with apractic deficits in the present study show correspondence to some existing network models. Niessen and colleagues (2014) drew from their meta-analysis that pantomime – i.e. gestures with an imaginary tool – involves a network containing inferior parts of the parietal lobe, frontal gyrus and temporal regions, as well as middle frontal regions. All areas proposed by Niessen and colleagues were indeed found here to display high numbers of disconnections in the apraxic sample. Our results implicate a prominent role of the temporo-parietal connections between lateral portions of the temporal lobe and posterior parietal areas. In addition, our parcellation allowed for more detailed conclusions concerning region-wise disconnection in frontal areas. In the middle frontal gyrus, both rostral and caudal portions were found have high numbers of disconnected fibres. In the inferior frontal gyrus, particularly the pars orbitalis and pars triangularis were disconnected.

Disconnections were further found to affect the inferior and superior parietal cortex, key components in the dual stream model as proposed by Rizolatti and Martelli (2003). This model postulates that visual information is projected from occipital to frontal areas via two alternative routes, processing different properties of information. They hypothesized a dorso-dorsal stream responsible for online action control and a dorso-ventral stream concerned with action organization. While the present study indeed found parietal and frontal areas to be connected both dorsally and ventrally, we also found numerous affected streamlines interconnecting both pathways. That is, on top of the dorsal and ventral connections from posterior to anterior regions, a considerable amount of relevant disconnections between dorsal and ventral areas. However, the exact interpretation of our results in reference to the dual stream model is restricted as an exact region-wise definition of the pathways' precise anatomy in humans is to our knowledge not yet established. Existing descriptions concerning components of dorso-ventral, and dorso-dorsal streams (e.g. Rizzolatti & Martelli, 2003;

Binkofski & Buxbaum, 2013) are not sufficient to define corresponding brain regions in available atlases of the human brain. There are several possible explanations for our findings. First, it is already known that the different streams do not process information in pure isolation, but in relative dependence (van Polanen & Davare, 2015; Milner, 2017). Thus, the present study might have identified relevant disconnection in fiber tracts that connect different processing streams. Another explanation is that different praxis skills, of which many can be affected by highly specific, dissociating deficits (Gonzalez-Rothi *et al.*, 1991; Manuel *et al.*, 2013; Goldenberg, 2014; Finkel *et al.*, 2018), cannot be only attributed to the functioning of a single major processing stream in the human brain. Instead, different praxis skills might depend on networks that only in part relate to the major processing streams, and in other parts on specific, connected sub-components of a fronto-temporo-parietal network.

One aim of the present paper was to identify components of a praxis network that go beyond regions where direct structural lesions induce apractic deficits, i.e. remote lesion effects on white matter integrity. However, the FDR-corrected main analysis failed to find such remote lesion effects. The uncorrected statistical topography, on the other hand, hints at possible effects. Sub-FDR-threshold clusters were apparent both in the splenium and the genu of the corpus callosum. This is in line with the rare case of callosal apraxia, where damage usually to the splenial corpus callosum induces unilateral apraxia (Watson & Heilman, 1983; Acosta *et al.*, 2014). While our results do not directly contribute to disentangle those areas' involvement, they do contribute to the notion that there might be involvement of said commissural connections in the interhemispheric communication related to higher order motor skills.

Grey matter nodes in the praxis network

The region-wise, connectome-based interpretation of the tract-based topographical analysis validated the importance of frontal, temporal, and parietal nodes in a praxis network. The

most severely disconnected areas in terms of absolute numbers of disconnected fibers in the present study were found for grey matter regions that were already assumed to be critically involved in the emergence of apraxia by previous lesion-behaviour mapping studies. Importantly, by using a multivariate topographical analysis, the present study succeeded in identifying disconnection in most, if not all, brain regions that were hypothesized to be relevant in apraxia which contrasts a large number of previous studies that, due to possible methodological limitations of univariate statistical approaches, might have only found parts of this praxis network (cf. Sperber *et al.*, 2019a).

The inferior parietal cortex, i.e. both angular and supramarginal gyrus, was often seen as a main region involved in praxis skills (Buxbaum & Randerath, 2018, Varney & Damasio, 1987; Sperber *et al.*, 2019a). Our results support this notion. The supramarginal gyrus was among those areas with the highest number of disconnected streamlines passing areas of apraxia-associated white matter affection. This was closely followed by the inferior parietal cortex including the angular gyrus. The parietal regions of the praxis network were most commonly assigned to the processing of spatio-temporal aspects of acquired movements (e.g., Goldenberg, 2014; Heilman *et al.*, 1982). The parietal lobe seems to store motor programs that are involved in both tool use and the equivalent pantomimes (Buxbaum & Randerath, 2018; Niessen *et al.*, 2014). It is further believed to code object positions in relation to oneself (Buxbaum, 2001; Buxbaum & Randerath, 2018; Goldenberg, 2009). Other functions that have been assigned to the parietal lobe include planning, predicting, and choosing an appropriate action (Buxbaum & Randerath, 2018).

We further found disconnections of pars triangularis and pars orbitalis in the inferior frontal gyrus to be relevant, in accordance with previous accounts that highlighted a major role of the inferior frontal gyrus in apraxia of pantomime (Goldenberg *et al.*, 2007). An attempt to explain involvement of inferior frontal regions in apraxia of pantomime is provided by Goldenberg and colleagues (2007). They argued that activations in the inferior frontal

gyrus might account for the selection of pantomime specific action features from semantic memory. While Goldenberg focused on apraxia of pantomime exclusively, the apraxia test of the present study consisted not only of pantomimes of object use (such as “play the piano”), but also of emblems (such as “wave good-bye”). A more suitable explanation for our results, accounting for both pantomimes and emblems, is that those frontal activations are concerned with the gestures’ inherent symbolism. The inferior frontal gyrus is popular for its role in language, a skill similarly depending on symbolism, since the relationship between a word and the concept it denotes is merely arbitrary (de Saussure, 1959). Its involvement is not restricted to spoken language, but also applies to other forms of communication (Emmorey *et al.*, 2010; Andric *et al.*, 2013; Goldenberg, 2017). Deaf signers of American Sign Language displayed inferior frontal activations when attending to signs, more than when watching pantomimes (Emmorey *et al.*, 2010). Hearing non-signers, on the other hand, showed higher activations for familiar pantomimes than for the ASL signs unfamiliar to them (Emmorey *et al.*, 2010). Andric and colleagues (2013) found that participants displayed similar activations in the inferior frontal gyrus while watching emblems being executed and processing spoken language. These results seem in accordance with more recent work by Goldenberg (2017), which concludes that tool use pantomimes are indeed communicative gestures, rather than replications of real tool use gestures.

Inferior frontal activations and their connections might further indicate involvement of the mirror neuron system (MNS; Buccino *et al.*, 2004; Iacoboni & Dapretto, 2006; Emmorey *et al.*, 2010; Andric *et al.*, 2013), which engages the same neurons both when watching an action and executing it (Di Pellegrino *et al.*, 1992; Gallese *et al.*, 1996; Rizzolatti *et al.*, 1996). The activations found by watching communicative gestures in afore mentioned studies might therefore be involved in the execution of engrams as well, and lesions in said areas might induce difficulties in processing a gesture’s inherent symbolism. The inferior parietal cortex which is, according to current knowledge, another crucial MNS region (Iacoboni & Dapretto,

2006) also displayed a high number of disconnections in the current study. The present study also found damage to fronto-parietal fibre tracks to be related to apraxia, including the fronto-parietal segments of the superior longitudinal fascicle. The region-based evaluation of structural disconnectivity, however, only found indirect connections between frontal and parietal regions to be associated with apraxia.

Disconnections involving precentral areas also became apparent. Precentral areas held an important role already in classical models of apraxia and are believed to process motor programmes forwarded from parietal areas (e.g. Heilman *et al.*, 1982). The course of brain activity spreading as part of pantomime production supports this idea. EEG activity in this context was found to begin in parietal areas and spread to left premotor areas as part of movement preparation (Wheaton *et al.*, 2005). That role of premotor areas was argued to be generally applicable for complex motor tasks (Niessen *et al.*, 2014). It has been reported further to be involved in the planning of movement trajectories (Wong, *et al.*, 2019). Those results were found for imitation but might also extend to gesture production more generally.

Finally, the insula, which was proposed to be critically involved in apraxia of pantomime (Goldenberg *et al.*, 2007; Hermsdörfer, *et al.*, 2013; Hoeren *et al.*, 2014; Sperber *et al.*, 2019a), displayed a reduced connectivity. Like inferior parietal and frontal cortices, the insula is associated with the MNS. The insula is argued to connect the frontoparietal MNS to the limbic system (Iacoboni & Dapretto, 2006). Although our results do not demonstrate large alterations in insular-limbic connections, the insula was found to be severely disconnected to the putamen, a region closely associated both to the limbic system and motor processing (Alexander *et al.*, 1986; Wymbs *et al.*, 2012).

Temporal contributions to a praxis network

While the relevance of inferior parietal and frontal areas in a praxis network is a long-existing common view, the role of temporal areas in praxis skills seems to be far less pronounced.

Only a few lesion-behaviour mapping studies have implicated temporal regions (e.g. Manuel *et al.*, 2013; Buxbaum *et al.*, 2014; Hoeren *et al.*, 2014). Interestingly, the present study found that temporo-parietal and temporo-temporal connections were most severely affected in apraxia. Thus, not only cortical lesions to the middle temporal gyrus seem to be associated to apraxia, as already shown by previous studies (Manuel *et al.*, 2013; Buxbaum *et al.*, 2014; Hoeren *et al.*, 2014; Johnson-Frey *et al.*, 2005), but also decreased connectivity to that very region.

In network theories of praxis, temporal areas are most commonly assigned to action recognition (Kalénine *et al.*, 2010). Since action recognition was not assessed in the present study, this does not explain our findings. However, it seems that recognition capabilities related to this area are not limited to actions, but it also includes objects (Tranel *et al.*, 1997). In accordance, middle temporal activity was found for naming objects (Martin *et al.*, 1996). White matter specific lesions affecting the posterior part of the middle temporal gyrus were further associated with deficits concerning conceptual aspects of action knowledge (Tranel *et al.*, 2003). Similarly, the middle temporal lesions found in the present study might reflect conceptual issues that might have impaired action knowledge and thus contributed to apraxia.

Results concerning the superior temporal sulcus are again prompting towards action recognition, more precisely, the perception of biological motion (Giese & Poggio, 2003; Urgesi et al., 2014; Dayan *et al.*, 2016), an important foundation for recognizing actions (Thompson & Parasuraman, 2012). Again, this remains a speculation, and future studies are required to investigate the relation between biological motion perception and apraxia. The superior temporal gyrus is further believed to play a role in understanding the intention of actions, or rather their plausibility in a certain context (Pelphrey *et al.*, 2004; Vander Wyk *et al.*, 2009). Although one could argue that understanding an action's intention is crucial for successful gesture production, action understanding was not explicitly tested, so that it remains an enigma if and how understanding an action and performing it relate.

No praxis network to rule them all

'Apraxia' is an umbrella term that can refer to a multitude of deficits of higher-order motor skills (Goldenberg, 2011; Wheaton & Hallet, 2007). This includes deficits affecting pantomime, tool use, imitation of either meaningful or meaningless gestures, mechanical reasoning, or gesture recognition (Goldenberg, 2011). Further, it has been shown that even these categories of higher-order motor skills can both behaviourally and anatomically dissociate into sub-deficits (Manuel *et al.*, 2013; Finkel *et al.*, 2018; Wong *et al.*, 2019). The present study focussed on the execution of meaningful gestures after verbal instruction. We utilised behavioural items that can be assigned to two different classes of meaningful gestures. Those gesture classes are known to dissociate in their cognitive load and neural correlates, namely transitive and intransitive meaningful gestures (Bartolo *et al.*, 2019).

A question that is yet to be answered is how different apraxia subtypes are related. While several forms of apraxia often occur together, they are also known to dissociate occasionally (Goldenberg, 2009). In addition to the differentiation based on action form (imitation versus execution on verbal command versus actual tool use), apparently, even this classification can be further subdivided, for example according to error type (Hanna-Pladdy *et al.*, 2001). Configuration errors, specifically, can be classified as internal or external configuration errors (Hanna-Pladdy *et al.*, 2001). While internal configuration refers to the spatial relation of individual body parts to one another, external configuration represents the appropriate synergy of body parts and a (real or imagined) external object. Naturally, the necessary degree of required external and internal configuration varies from action to action. Unlike transitive gestures which require both forms of configuration, intransitive gestures do not require external configuration, since there is no external object that needs to be taken into account. The extent to which internal configuration needs to be applied depends on how many body parts are involved in an action and need to be aligned for a successful execution. Using a

spoon to stir cup of coffee requires mainly the fingers of the dominant hand as well as the relevant wrist. In contrast, when brushing your hair, you also need to position your arm in the appropriate angle to reach your head. To conclude, given the complexity of praxis skills and the many facets of apraxia, the delineation of the entire praxis network is not feasible within a single study. Whatever behavioural measure is chosen to access certain praxis skills, other aspects of praxis skills will not be assessed. Likewise, the present study cannot claim to have identified the entire praxis network, but the praxis sub-network related to production of meaningful gestures – a major symptom in the clinical assessment of limb apraxia. It remains an open question what further brain areas can be involved in other praxis skills. To solve this question, further clarification of what basic cognitive functions are disrupted in apraxia is required.

Limitations

It should be noted that disconnection severity in the region-wise interpretation refers to the absolute number of disconnected streamlines, rather than to the ratio of destroyed to intact connections. On the one hand, this approach avoids the overestimation of complete disconnections of originally faintly connected areas. On the other hand, this data presentation strategy does not provide information concerning the fraction of fibres still intact. Therefore, it fails to supply information considering the amount of fibre tracts that are still intact. The amount of surviving fibres is equally important as the amount of disrupted fibres, since it makes a difference to what extent two regions are disconnected.

Conclusion

The present study provides new insights into pathological white matter alterations associated with apraxia of meaningful gesture execution. The results complement and unify previous studies that found different frontal, temporal and parietal cortical areas to be involved in

apraxia. This supports the notion that limb apraxia is caused by damage to a complex network, with high relevance of both short and long association fibres constituting a fronto-temporo-parietal network. A striking finding was the particular importance of temporal lobe, and temporo-parietal connections.

Future investigations should aim to pin down the essential cognitive functions damaged in apraxia and identify the parts of the fronto-temporo-parietal network that constitute their neural correlates. Further, it might be highly interesting to re-evaluate the role of the major visual streams in the emergence of apractic deficits, and to find out in what way they might interact in implementing praxis skills.

The demonstrated relevance of white matter damage for praxis deficits could further impact clinical practice in the context of long-term stroke outcome prediction. When predicting outcome based on imaging data, algorithms might profit from including topographical variables that represent white matter damage.

Author contributions

Concept & idea: C.S.; Planned & designed the study: C.S., H.O.K., H.R.; collected and processed data: A.B., G.Y., L.B., C.R., J.F.; analysed the data: H.R., G.Y., C.S., D.W.; wrote the manuscript: H.R., C.S.; critically revised the manuscript: H.O.K., D.W., A.B., G.Y., L.B., C.R., J.F.

Funding

This work was funded by the Deutsche Forschungsgemeinschaft (KA1258/15-1, KA 1258/23-1) and grants from the National Institutes of Health National Institute on Deafness and Other Communication Disorders (NIH NIDCD) to J.F. (P50 DC014664, U01 DC011739) and A.B. (trainee: T32 DC014435)

Competing interests

The authors report no competing interests.

References

Acosta LM, Bennett JA, Heilman KM. Callosal disconnection and limb-kinetic apraxia. Neurocase 2014; 20: 599–605.

Alexander G. Parallel Organization of Functionally Segregated Circuits Linking Basal Ganglia and Cortex. Annu Rev Neurosci 1986; 9: 357–381.

Andersson JLR, Skare S, Ashburner J. How to correct susceptibility distortions in spin-echo echo-planar images: Application to diffusion tensor imaging. Neuroimage 2003; 20: 870–888.

Andersson JLR, Sotiropoulos SN. An integrated approach to correction for off-resonance effects and subject movement in diffusion MR imaging. Neuroimage 2016; 125: 1063–1078.

Andric M, Solodkin A, Buccino G, Goldin-Meadow S, Rizzolatti G, Small, Steven L. Brain Function Overlaps When People Observe Emblems, Speech, and Grasping. Neuropsychologia 2013; 51

Bartolo A, Claisse C, Gallo F, Ott L, Sampaio A, Nandrino JL. Gestures convey different physiological responses when performed toward and away from the body. Sci Rep 2019; 9: 1–10.

Benjamini Y, Yekutieli D. The control of the false discovery rate in multiple testing under dependency. Ann Stat 2001; 29: 1165–1188.

Binkofski F, Buxbaum LJ. Two action systems in the human brain. Brain Lang 2013

Bohlhalter S, Hattori N, Wheaton L, Fridman E, Shamim EA, Garraux G, et al. Gesture subtype-dependent left lateralization of praxis planning: An event-related fMRI study.

Cereb Cortex 2009; 19: 1256–1262.

Buccino G, Lui F, Canessa N, Patteri I, Lagravinese G, Benuzzi F, et al. Neural Circuits Involved in the Recognition of Actions Performed by Nonconspecifics: An fMRI Study. J Cogn Neurosci 2004; 16: 114–126.

Bürgel U, Amunts K, Hoemke L, Mohlberg H, Gilsbach JM, Zilles K. White matter fiber tracts of the human brain: Three-dimensional mapping at microscopic resolution, topography and intersubject variability. Neuroimage 2006; 29: 1092–1105.

Buxbaum LJ. Ideomotor Apraxia: a Call to Action. Neurocase 2001; 7: 445–458.

Buxbaum LJ, Randerath J. Limb apraxia and the left parietal lobe. 1st ed. Elsevier B.V.; 2018Available from: http://dx.doi.org/10.1016/B978-0-444-63622-5.00017-6

Buxbaum LJ, Shapiro AD, Coslett HB. Critical brain regions for tool-related and imitative actions: A componential analysis. Brain 2014; 137: 1971–1985.

Buxbaum, Laurel J; Kalénine S. Action knowledge, visuomotor activation, and embodiment in the two action systems. Ann N Y Acad Sci 2010; 1191: 201–218.

Dabul B. Apraxia Battery for Adults. 2nd Edition. Austin: PRO-ED; 2000.

Dayan E, Sella I, Mukovskiy A, Douek Y, Giese MA, Malach R, et al. The Default Mode Network Differentiates Biological from Non-Biological Motion. Cereb Cortex 2016; 26: 234–245.

de Haan B, Karnath HO. ‘Whose atlas I use, his song I sing?’ – The impact of anatomical atlases on fiber tract contributions to cognitive deficits after stroke. Neuroimage 2017; 163: 301–309.

De Renzi E, Faglioni P, Sorgato P. Modality-specific and supramodal mechanisms of apraxia.

Brain 1982; 105: 301–312.

De Renzi E, Motti F, Nichelli P. Imitating Gestures: A Quantitative Approach to Ideomotor Apraxia. Arch Neurol 1980; 37: 6–10.

De Saussure, F. The Nature of the Linguistic Sign. In: Bally C, Sechehaye A, editors. Course in General Linguistics New York: The Philosophical Society, 1959. pp 65-70

Desikan RS, Ségonne F, Fischl B, Quinn BT, Dickerson BC, Blacker D, et al. An automated labeling system for subdividing the human cerebral cortex on MRI scans into gyral based regions of interest. Neuroimage 2006; 31: 968–980.

di Pellegrino G, Fadiga L, Fogassi L, Gallese V, Rizzolatti G. Understanding motor events: a neurophysiological study. Exp Brain Res 1992; 91: 176–180.

Dressing A, Nitschke K, Kümmerer D, Bormann T, Beume L, Schmidt CSM, et al. Distinct Contributions of Dorsal and Ventral Streams to Imitation of Tool-Use and Communicative Gestures. Cereb Cortex 2018; 28: 474–492.

Emmorey K, Xu J, Gannon P, Golding_Meadow S, Braun A. CNS activation and regional connectivity during pantomime observation: No engagement of the mirror neuron system for deaf signers. Neuroimage 2010; 49: 994–1005.

Finkel L, Hogrefe K, Frey SH, Goldenberg G, Randerath J. It takes two to pantomime: Communication meets motor cognition. NeuroImage Clin 2018; 19: 1008–1017.

Gallese V, Fadiga L, Fogassi L, Rizzolatti G. Action recognition in the premotor cortex. Brain 1996; 119: 593–609.

Geschwind, N. The apraxias: neural mechanisms of disorders of learned move- ment. Am Sci 1975; 63: 188–195.

Giese MA, Poggio T. Cognitive neuroscience: Neural mechanisms for the recognition of biological movements. Nat Rev Neurosci 2003; 4: 179–192.

Goldenberg, G. Apraxien. Göttingen: Hogrefe; 2011.

Goldenberg G. Defective imitation of gestures in patients with Damage in the Left or Right Hemispheres. Science 1996: 176–180.

Goldenberg G. Pantomime of object use: A challenge to cerebral localization of cognitive function. Neuroimage 2003; 20: 101–106.

Goldenberg G. Apraxia and the parietal lobes. Neuropsychologia 2009; 47: 1449–1459.

Goldenberg G. Challenging traditions in apraxia. Brain 2014; 137: 1858–1859.

Goldenberg G. Facets of Pantomime. J Int Neuropsychol Soc 2017; 23: 121–127.

Goldenberg G, Hagmann S. Tool use and mechanical problem solving in apraxia. Neuropsychologia 1998; 36: 581–589.

Goldenberg G, Hermsdörfer J, Glindemann R, Rorden C, Karnath HO. Pantomime of tool use depends on integrity of left inferior frontal cortex. Cereb Cortex 2007; 17: 2769–2776.

Goldenberg G, Randerath J. Shared neural substrates of apraxia and aphasia. Neuropsychologia 2015; 75: 40–49.

Gonzalez Rothi LJ, Ochipa C, Heilmann KM. A cognitive neuropsychological model of limb praxis. Cogn Neuropsychol 1991; 8: 443–458.

Haaland KY, Flaherty D. The different types of limb apraxia errors made by patients with left vs. right hemisphere damage. Brain Cogn 1984; 3: 370–384.

Haaland KY, Harrington DL, Knight RT. Neural representations of skilled movement. Brain

2000; 123: 2306–2313.Hanna-Pladdy B. Cortical and subcortical contributions to ideomotor apraxia: Analysis of task demands and error types. Brain 2001; 124: 2513–2527.

Heilman, KM, Rothi, LJ. Apraxia. In: Heilman KM, Valenstein E, editors. Clinical Neuropsychology. Third ed. New York: Oxford University Press; 1993. p. 141–163.

Heilman KM, Rothi LJ, Valenstein E. Two forms of ideomotor apraxia. Neurology 1982; 32: 342–446.

Hermsdörfer J, Li Y, Randerath J, Roby-Brami A, Goldenberg G. Tool use kinematics across different modes of execution. Implications for action representation and apraxia. Cortex 2011; 49: 184–199.

Hoeren M, Kümmerer D, Bormann T, Beume L, Ludwig VM, Vry MS, et al. Neural bases of imitation and pantomime in acute stroke patients: Distinct streams for praxis. Brain 2014; 137: 2796–2810.

Iacoboni M, Dapretto M. The mirror neuron system and the consequences of its dysfunction. Nat Rev Neurosci 2006; 7: 942–951.

Johnson-Frey SH., Newman-Norlund R, Grafton ST. A Distributed Left Hemisphere Network Active During Planning of Everyday Tool Use Skills. Cereb Cortex 2005; 15: 681–695.

Kalénine S, Buxbaum LJ, Coslett HB. Critical brain regions for action recognition: Lesion symptom mapping in left hemisphere stroke. Brain 2010; 133: 3269–3280.

Kertesz A. Western Aphasia Battery. San Antonio: The Psychological Corporation; 1982.

Kertesz A. Western Aphasia Battery-Revised. San Antonio: Pearson; 2007.

Liepmann H. The left hemisphere and action. London: University of Western Ontario Press; 1905.

Manuel AL, Radman N, Mesot D, Chouiter L, Clarke S, Annoni JM, et al. Inter- and intrahemispheric dissociations in ideomotor apraxia: a large-scale lesion-symptom mapping study in subacute brain-damaged patients. Cereb Cortex 2013; 23: 2781–2789.

Martin A, Wiggs CL, Ungerleider LG, Haxby J V. Neural correlates of category-specific knowledge. Nature 1996; 379: 649–652.

Milner AD. How do the two visual streams interact with each other? Exp Brain Res 2017; 235: 1297–1308.

Milner AD, Goodale MA. The Visual Brain in Action (book excerpt). Psyche (Stuttg) 1998; 4

Nachev P, Coulthard E, Jäger HR, Kennard C, Husain M. Enantiomorphic normalization of focally lesioned brains. Neuroimage 2008; 39: 1215–1226.

Niessen E, Fink GR, Weiss PH. Apraxia, pantomime and the parietal cortex. NeuroImage Clin 2014; 5: 42–52.

Pelphrey K, Morris J, McCarthy G. Grasping the Intentions of Others: The Perceived Intentionality of an Action Influences Activity in the Superior Temporal Sulcus during Social Perception. J Cogn Neurosci 2004: 1706–1716.

Rasmussen PM, Hansen LK, Madsen KH, Churchill NW, Strother SC. Model sparsity and brain pattern interpretation of classification models in neuroimaging. Pattern Recognit 2012; 45: 2085–2100.

Rizzolatti G, Fadiga L, Gallese V, Fogassi L. Premotor cortex and the recognition of motor

actions. Cogn Brain Res 1996; 3: 131–141.

Rizzolatti G, Matelli M. Two different streams form the dorsal visual system: Anatomy and functions. Exp Brain Res 2003; 153: 146–157.

Rorden C, Bonilha L, Fridriksson J, Bender B, Karnath H-O. Age-specific CT and MRI templates for spatial normalization. Neuroimage 2012; 61: 957–965.

Smith SM, Jenkinson M, Johansen-Berg H, Rueckert D, Nichols TE, Mackay CE, et al. Tract-based spatial statistics: voxelwise analysis of multi-subject diffusion data. Neuroimage 2006; 31: 1487–505.

Sperber C, Wiesen D, Goldenberg G, Karnath HO. A network underlying human higher-order motor control: Insights from machine learning-based lesion-behaviour mapping in apraxia of pantomime. Cortex 2019; 121: 308–321.

Sperber C, Wiesen D, Karnath HO. An empirical evaluation of multivariate lesion behaviour mapping using support vector regression. Hum Brain Mapp 2019; 40: 1381–1390.

Thompson J, Parasuraman R. Attention, biological motion, and action recognition. Neuroimage 2012; 59: 4–13.

Tournier JD, Calamante F, Connelly A. MRtrix: Diffusion tractography in crossing fiber regions. Int J Imaging Syst Technol 2012; 22: 53–66.

Tranel D, Damasio H, Damasio AR. A neural basis for the retrieval of conceptual knowledge. Neuropsychologia 1997; 35: 1319–1327.

Tranel D, Kemmerer D, Adolphs R, Damasio H, Damasio AR. Neural correlates of conceptual knowledge for actions. Cogn Neuropsychol 2003; 20: 409–432.

Urgesi C, Candidi M, Avenanti A. Neuroanatomical substrates of action perception and

understanding: An anatomic likelihood estimation meta-analysis of lesion-symptom mapping studies in brain injured patients. Front Hum Neurosci 2014; 8: 1–17.

Ungerleider LG, Mishkin M. Two cortical visual systems. In: Ingle DJ, Goodale MA, Mansfield RJW, editors. Analysis of Visual Behavior.Cabbridge: MIT press;1982. p. 549–586.

van Polanen V, Davare M. Interactions between dorsal and ventral streams for controlling skilled grasp. Neuropsychologia 2015; 79: 186–191.

Vander Wyk BC, Hudac CM, Carter EJ, Sobel DM, Pelphrey KA. Action understanding in the superior temporal sulcus region. Psychol Sci 2009; 20: 771–777.

Vapnik, VN. The nature of statistical learning theory. New York: Springer; 1995.

Varney NR, Damasio H. Locus of Lesion in Impaired Pantomime Recognition. Cortex 1987; 23: 699–703.

Vry MS, Tritschler LC, Hamzei F, Rijntjes M, Kaller CP, Hoeren M, et al. The ventral fiber pathway for pantomime of object use. Neuroimage 2015; 106: 252–263.

Watson R, Heilman KM. Callosal apraxia. Neurology 1983; 106: 391–403.

Weiss PH, Ubben SD, Kaesberg S, Kalbe E, Kessler J, Liebig T, et al. Where language meets meaningful action: a combined behavior and lesion analysis of aphasia and apraxia. Brain Struct Funct 2016; 221: 563–576.

Wheaton LA, Hallett M. Ideomotor apraxia: A review. J Neurol Sci 2007; 260: 1–10.

Wheaton LA, Shibasaki H, Hallett M. Temporal activation pattern of parietal and premotor areas related to praxis movements. Clin Neurophysiol 2005; 116: 1201–1212.

Wong AL, Jax SA, Smith LL, Buxbaum LJ, Krakauer JW. Movement imitation via an abstract trajectory representation in dorsal premotor cortex. J Neurosci 2019; 39: 3320–3331.

Wymbs NF, Bassett DS, Mucha PJ, Porter MA, Grafton ST. Differential Recruitment of the Sensorimotor Putamen and Frontoparietal Cortex during Motor Chunking in Humans. Neuron 2012; 74: 936–946.

Zhang S, Arfanakis K. Evaluation of standardized and study-specific diffusion tensor imaging templates of the adult human brain: Template characteristics, spatial normalization accuracy, and detection of small inter-group FA differences. Neuroimage 2018; 172: 40–50.

Zhang Y, Zhang J, Oishi K, Faria, Andreia V, Jiang H, Li X, et al. Atlas-Guided Tract Reconstruction for Automated and Comprehensive Examination of the White Matter Anatomy. Neuroima 2010; 52: 1289–1301.

Zhang Y, Kimberg DY, Coslett HB, Schwartz MF, Wang Z. Multivariate lesion-symptom mapping using support vector regression. Hum Brain Mapp 2014; 35: 5861–5876.

Figure Legends

Figure 1

Lesion topography and mean fractional anisotropy. For all 101 patients, the (A) lesion topography after enantiomorphic normalisation in SPM and (B) average skeletonised FA topography after normalisation and skeletonization with TBSS is shown on the average non-skeletonised, normalised FA maps. Numbers above slices indicate the Z-coordinate in MNI space.

Figure 2

Results of the SVR-fractional anisotropy-mapping analysis. Permutation-based statistical topographies of voxels where FA values significantly contribute to apraxia are depicted after false discovery rate correction with $q = 0.05$ (equal to $p < 0.0013$) and removal of small clusters <20 voxels. The 2D topography is depicted on the un-skeletonized average FA maps; the 3D topography is depicted on the MNI152 template in MRIcroGL.

Figure 3

Region-based evaluation of structural disconnectivity (1). Line colour indicates the number of disconnected fibre bundles between grey matter areas in the Desikan atlas in the fibre tracking analysis in MRtrix. The threshold was set to 130 fibres to depict the strongest inter-regional disconnections. Data were visualised using Surf Ice (https://www.nitrc.org/projects/surfice/).

Figure 4

Region-based evaluation of structural disconnectivity (2). Heatmap of the 20 areas found to be most severely disconnected according to our analysis. Cell colour refers to the number of

disconnected fibre bundles between the brain areas represented by the corresponding row and column. Full disconnectivity data are available in the online materials.