Significant expression of FURIN and ACE2 on oral epithelial cells may facilitate the efficiency of 2019-nCov entry

Bing-peng Lin[1,2ϕ], Mei Zhong[2ϕ], Hong-bin Gao[3], Kai-bin Wu[1,2], Ming-xiao Liu[1,2], Chang Liu[4], Xin-hong Wang[1,2], Jian-ming Chen[1,2], Learn-han Lee[5], Cui-ling Qi[6], Lin-hu Ge[2*] , Li-jing Wang[2,6*]

[1] Stomatology Hospital of Guangzhou Medical University, Guangzhou 510140, China
[2]Key Laboratory of Oral Medicine, Guangzhou Institute of Oral Disease, Stomatology Hospital of Guangzhou Medical University, Guangzhou 510140, China
[3]Guangdong Laboratory Animals Monitoring Institute, Key Laboratory of Guangdong Laboratory Animals, Guangzhou 510663, China
[4] Stomatology school of Ji'nan University, Guangzhou 510000, China
nstitute of Biomedical and Pharmaceutical Sciences, Guangdong University of Technology, Guangzhou 510006, PR China
[5]Novel Bacteria and Drug Discovery Research Group, School of Pharmacy, Monash University Malaysia, Bandar Sunway, Malaysia
[6]Vascular Biology Research Institute, School of Life Sciences and Biopharmaceutics, Guangdong Pharmaceutical University, Guangzhou 510006, Guangdong, China

*Correspondence: gelinhu@yeah.net, (L.-H. G); wanglijing@gdpu.edu.cn (L.W.);

ϕThese authors contributed equally to this work.

Abstract

Background:
Leading to a sustained epidemic spread with >40,000 confirmed human infections, including >10,000 deaths, COVID-19 was caused by 2019-nCov and resulted in acute respiratory distress syndrome (ARDS) and sepsis, which brought more challenges to the patient's treatment. The S-glycoprotein, which recognized as the key factor for the entry of 2019-nCov into the cell, contains two functional domains: an ACE2 receptor binding domain and a second domain necessary for fusion of the coronavirus and cell membranes. FURIN activity, exposes the binding and fusion domains, is essential for the zoonotic transmission of 2019-nCov. Moreover, it has been reported that ACE2 is likely to be the receptor for 2019-nCoV. In addition, FURIN enzyme and ACE2 receptor were expressed in airway epithelia, cardiac tissue, and enteric canals, which considered as the potential target organ of the virus. However, report about the expression of FURIN and ACE2 in oral tissues was limited.
Methods: In order to investigate the potential infective channel of new coronavirus in oral cavity, we analyze the expression of ACE2 and FURIN that mediate the new coronavirus entry into host cells in oral mucosa using the public single-cell sequence datasets. Furthermore, immunohistochemical staining experiment was performed to confirm the expression of ACE2 and FURIN in the protein level.
Results: The bioinformatics results indicated the differential expression of ACE2 and FURIN on epithelial cells of different oral mucosal tissues and the proportion of FURIN-positive cells was obviously higher than that of ACE2-positive cells. IHC experiments revealed that both the ACE2-positive and FURIN-positive cells in the target tissues were mainly positioned in the epithelial layers, partly expressed in fibroblasts, which further confirm the bioinformatics results.
Conclusions: Based on these findings, we speculated that 2019-nCov could effectively invade oral mucosal cells though two possible routes: binding to the ACE2 receptor and fusion with cell membrane activated by FURIN protease. Our results

indicated that oral mucosa tissues are susceptible to 2019-nCov, which provides valuable information for virus-prevention strategy in clinical care as well as daily life.

Key words: Covid-19, oral mucosa, scRNA-Seq, ACE2, FURIN

Introduction

In December 2019, an increasing number of patients with pneumonia caused by unknown pathogen emerged in Wuhan, Hubei, China, with clinical presentations greatly resembling viral pneumonia [1, 2, 3]. A novel coronavirus, which was named as Corona Virus Disease 19 (COVID-19) by The World Health Organization (WHO), was detected from lower respiratory tract samples via deep sequencing analysis [1]. As of 15th April 2020, the number of coronavirus infections approaches more than two million people and kill more than a hundred thousand [4]. The present outbreak of the 2019 coronavirus strain has been labeled as a global pandemic by WHO [5]. The Covid-19 outbreak has posed critical challenges for the public health, research, and medical communities.

Similar to those of patients with SARS and MERS, the clinical manifestations of COVID-19 at illness onset are fever, dry cough, and myalgia. The patients may suffer from dyspnea, shortness of breath, and then respiratory failure and even death in later stages [2, 6, 7]. Previous findings indicated that the ACE2 plays an important role in cellular entry, thus ACE2-expressing cells may act as target cells and are susceptible to COVID-19 infection [2, 8, 9, 10,]. Besides, ACE2 receptor was proven to be expressed in 72 human tissues, and is abundantly present in the epithelia of the lung and small intestines [11]. Studies also found ACE2 expression in the epithelial layer of nasal and oral mucosa. However, this conclusion was based on the bulk RNA datasets. The cell type and number of cells expressing ACE2 in each tissue could not be estimated.

As a co-expressed membrane endopeptidase of ACE2 receptor, FURIN play a central role in the human immunodeficiency virus type-1 (HIV-1) entering into the host cells through cleaving its envelope glycoprotein [12]. Genomic characterization of the 2019-nCov have revealed that FURIN enzyme could activate the specific site of its spike protein [13]. Meanwhile, Li H. et. al revealed that a putative FURIN-cleavage site reported recently in the spike protein of 2019-nCov may facilitate the virus-cell fusion, which can explain the virus transmission features[14]. In addition, Ma Y and co-authors found that presence of FURIN cleavage site, which is absent in other coronavirus, during the course of 2019-nCov infection may cause some distinct clinical symptoms from SARS-CoV infection[15]. Similar results were also reported in Li X.'s study from China[16]. Hence, the expression and distribution of ACE2 and FURIN in human body were the key factors for the coronavirus to invade host cells. Furthermore, online single-cell sequence datasets analysis unveiled that FURIN was expressed in coronavirus's potential target organs, such as lung, heart, nose, rectum, colon, intestine and ileum [14]. However, information on the expression and distribution of ACE2 and FURIN in oral cavity were limited.

Single-cell RNA sequencing (scRNA-Seq) technique, which provides an avenue to understand gene regulation networks, metastasis and the complexity of intratumoral cell-to-cell heterogeneity at the single-cell level, has diverse applications on bioinformatics, stem cell differentiation, organ development, whole-tissue subtyping and tumor biology [17,18,19]. It captures cellular differences underlying tumor biology at a higher resolution than regular bulk RNA-seq and has revolutionized studies of cancer mechanisms and personalized medicine [20]. For better understanding the

potential infection risk in oral cavity, we explored whether the ACE2 and FURIN were expressed and their expressing cells composition and proportion in different oral tissues based on the public scRNA-seq profiles from GEO public databases. Then IHC analysis was used to further confirm the results in the protein level.

Materials and methods

Public scRNA-seq dataset acquisition

Single-cell RNA-seq dataset(GSE103322) including the gene expression and cell type annotation from human oral squamous cell carcinoma tissue were downloaded from the GEO database (https://www.ncbi.nlm.nih.gov/geo/).

Single-cell sequencing analysis

Single-cell RNA-seq datasets (GSE103322) were downloaded from the GEO database. Datasets of five patients, which have the closest histological features with normal tissue, were selected for futher analysis. The scRNA-seq data sets of GSE103322_HN_UMI_table.txt was used to subsequently analyze based on R package Seurat (Version 3.6.2). To control quality, we removed cells with < 50 genes, and as well as the cells with mitochondrial content higher than 5%. Besides, the genes detected in < 3 cells were filtered out in the function CreateSeuratObject. Subsequently, the data was log-normalized using the function NormalizeData with the default parameters. The FindVariableGenes function was used to determine the highly expressed variable genes, followed by PCA dimensionality reduction by RunPCA function. PCA components, which P value was less than 0.05, were selected to further analyze using Two-dimensional t-distributed stochastic neighbor embedding (tSNE). The setting of k.param was 20 in the function FindNeighbors, and the setting of the resolution was 0.5 in the function FindClusters. Finally, the cell types were assigned based on their canonical markers. Gene expression of different cell types was displayed by the functions of DotPlot and VlnPlot. The significant level was set as 0.05.

Human oral tissue specimens

Ten tissues of oral mucosa (three buccal tissues, two palatal tissues, two tongue tissues and three gingival tissues) were obtained from patients after informed consent and ethical approval from Stomatology Hospital of Guangzhou Medical University, then sent for IHC. Oral tissue was taken from 10 different patients with an average age of 53. Tissue morphology was evaluated in haematoxylin and eosin-stained sections by a qualified pathologist. Tissues meeting the diagnostic criteria of non-diseased were included in our research. [11,21]

Immunohistochemical staining

4-μm sections of selected tissues were de-waxed, rehydrated, and subjected to heat-induced antigen retrieval by overnight incubation in 0.1 M Tris–HCl buffer at 80 ◦C. Subsequently, they were dried and incubated anti-ACE2 (cat. no. ab15348 , Abcam, Cambridge, CB, UK) antibody overnight at 4 ℃. The next day, the HRP-conjugated secondary antibody was added to the sections. Peroxidase activity was developed by using DAB for 8 min and counterstained with hematoxylin. The expression levels of ACE2 were evaluated by two experimenters. A qualified pathologist analyzed the staining for structures positive for ACE2. The stain intensity of ACE2 and FURIN was semiquantitatively graded according to the previous methods[22].

Statistical analysis

Statistical significance was determined with a one-way ANOVA followed by Bonferroni's post-hoc test for multiple group comparisons or Student's t-test for two group comparisons. For all tests, $p < 0.05$ or < 0.01 was considered statistically significant or very significant.

Results

Identification of cell types in the oral mucosal tissues

We analyzed 1843 individual cells from the oral mucosa of five patients. Using the unsupervised graph-based clustering, we found that at least thirteen distinct cell clusters existed in the oral tissues (Fig. 2A), including epithelial cells (clusters 1, 4, 5), fibroblasts (clusters 0, 2, 7), T-cells (clusters 8, 9), and B cells (cluster 12). The heatmap of main corresponding cell marker gene expression profiles across the cell types can be found in Fig. 2B. The marker gene of epithelial cells included KRT6B, GJB2, SFN, and KRT14, fibroblasts included THY1, COL1A1, DCN, ACTA2, B cells included SLAMF7, CD19, CD20 and CD79A and T-cells included CD2, CD3, CD45.

Identification of ACE2-expressing cells in the oral mucosa

As ACE2 had been proven to be one of the major receptors of COVID-2019 in human body, we explored the online datasets to find out the expression level of ACE2 in oral mucosa. As expected, data from GEO indicated that ACE2 receptor expression level was relatively higher in epithelial cells (cluster 1, 5, 6)(Fig. 3A, 3B), while very little cellular expression of ACE2 was found in fibroblasts (cluster 2). Then we calculated the percent of ACE2-expressing cells in the dataset (Fig. 3C). We find that, in oral tissue, the percentage of ACE2-positive cells was 2.2%. Among them, 92% were epithelial cells.

Identification of FURIN-expressing cells in the oral mucosa

To determine the cell types of expressing FURIN, we analyzed the FURIN mRNA expression using tSNE method. Violin and scatter plot showed that FURIN was highly expressed in epithelial cells, follow by fibroblasts, T-cells, and endothelial cells of the oral mucosal tissues, but hardly expressed in B cells (Fig. 4A, 4B). Meanwhile, the proportion of FURIN-expression cells was approximately 10%. Among them, epithelial cells make up more than 55% (Fig. 4C).

ACE2 protein was highly expressed in epithelial layer of the buccal mucosa, lip, palate, tongue and gingiva

To further determine the protein expression level of ACE2 in the oral mucosa, IHC experiments were performed. The first remarkable finding was that ACE2 was present in epithelial cells in all the tissues studied (Fig. 5). Results indicated that the expression level of ACE2 protein was significantly higher in the lip, tongue, and buccal mucosa, especially the epithelial cells in the basal layer, although the mRNA expression level is not as high (Fig. 3). The ACE2-postive cells in the gingival and palate tissue were limited. The corresponding gingiva and palate epithelial cells showed weak positive ACE2 staining. Also, we found that ACE2 expressed in fibroblasts and endothelial cells. These results indicate that oral epithelial cells were the potential targets of 2019-nCov.

FURIN protein was highly expressed in the normal oral mucosa

FURIN mRNA expression has been described mainly in oral epithelial cells through scRNA-seq technique. To determine whether this differential expression of FURIN was maintained at the protein level, oral tissues from different sites were screened. As shown in Fig. 6, moderate to mild immunostaining in the cytoplasm of epithelial cells can be seen in five normal oral tissues. Surprisingly, except for the positive cells in the basal layer of oral epithelium, the spinous layer in all examined tissues also turned out with large numbers of FURIN-positive cells. In addition, the percentage of FURIN-positive cells in lip, tongue and gingiva was higher than that of buccal and palate mucosa. These results indicated that 2019-nCov might be able to infect oral tissues through the route of FURIN-mediated fusion with oral mucosal cell.

Discussion

The amazing spreading speed of 2019-nCov and the large number of infected people have quickly overwhelmed the public health services in the world, and have become a global public health problem [23]. As mentioned before, ACE2 receptor in cell membrane and FURIN clearage site of 2019-nCov were the key factors that allowed the virus to invade the host [14, 15]. Many studies have shown that ACE2 receptor was highly expressed in respiratory epithelium, kidney, cardiovascular system and testis [24]. Some scholars also found that ACE2 was expressed in oral tissues with bulk RNA sequencing data, which could not accurately reflect the expression of ACE2 on the single cell level [21, 25]. Chen et al. benefited from the single-cell sequencing data to further proved the expression of ACE2 receptor in tongue, buccal mucosa and gingiva [11]. However, these studies were based on public databases and were not analyzed together, and further validation of protein levels was lacking.

In addition, virologist Gary Whittaker of Cornell University, whose team published another structural analysis of the coronavirus S protein on bioRxiv on February 18th, argues that the FURIN cutting site allows the virus to enter cells in a very different way than SARS, and this may affect the stability and spread of the virus [26]. Other research teams have also identified this activation site, suggesting that it may enable the virus to spread effectively between humans [13]. It has been demonstrated that 2019-nCov could fuse with cell membrane and then entry into the target cells[27,28]. Researchers have found FURIN proteases in many tissues, including the lungs, liver, and small intestine [29]. However, limited reports were seen regarding the expression of FURIN in oral cavity and whether the new coronavirus could spread by oral cavity are not fully understood. Thus, 2019-nCov host cell receptor ACE2 and FURIN enzyme were investigated in five different oral sites and the results would be valuable for the prevention of the COVID-19 spreading.

The present study detected the expression of ACE2 and FURIN in different oral mucosal tissues via scRNA-Seq technique. As expected, ACE2 and FURIN were mainly expressed in the epithelial cells of oral mucosa, which were similar to the previous reports [30, 31, 32]. In addition, we also found that FURIN were expressed on the fibroblasts, endothelial cells and T-cells, and the percentage of positive cells was dramatically higher than that of ACE2. These results were further validated by the IHC tests. Interestingly, although no ACE2 receptors were found using scRNA-Seq methods, IHC result revealed that the ACE2 also expressed in lymphocytes within oral mucosa, and similar results were found in oral cavity and other various organs [21]. But, the proportion of ACE2-positive lymphocytes is quite small, whether coronaviruses invade the lymphocytes needs further validation. The underlying reason

may be the individual differences of sampling tissues and different dimensionality reduction methods in data processing. Stringkly, the live 2019-nCov was consistently detected in the self-collected saliva of 91.7% of patients till 11 days after hospitalization, and it could be transmitted via saliva, directly or indirectly, even among asymptomatic infected patients [33]. These results indicated that ACE2 and FURIN were abundantly expressed in oral mucosa, which implied the potential attack and spread of 2019-nCov in the oral tissues through two possible target protein. Therefore, we should pay close attention to protecting the oral tissues of all people, preventing the virus from spreading through the mouth.

In the current study, we investigated the expression of other endopeptidases in various oral mucosa cells using the public single-cell sequence datasets. As shown by voilin plot in supplemental files, the high expression of ACE2 sheddase, ADAM17, ADAM10 indicated the higher membrane fusion activity, virus uptake and virus replication in the oral mucosa. Besides, the endopeptidases (such as CAPN1 and CAPNS1) were abundantly enriched in the oral mucosal cells. Large proportion of endopeptidases positive cells in the different oral sites provided opportunities for 2019-nCov infection and rapid replication in the oral cavity [15]. These results were in accordance with the previous study, which indicated the residence of 2019-nCov in nasal and throats swab samples, suggesting the strong spread ability in oral cavity [34].

Based on our results, we would like to make a few suggestions about the prevention of this new virus. First, all the healthcare workers should focus on taking effective measures to prevent the virus from spreading via the oral cavity. It is necessary to wear facemask and face shields during this pandemic. Due to the droplets and aerosols generated during dental clinical procedures and high risk of cross infection, strict and effective infection control protocols are urgently needed for patients and dental practitioners [35]. In addition, antimicrobial mouth rinse, which was proven to reduce the number of microbes in the oral cavity, was suggested before any dental operation [36]. Second, for groups with higher virus prevalence, it is worth advocating and encouraging this population to drink from their own glass, have separate meals, and reduced conversation while eating. Also, washing hands before meals and after going to the toilet is needed. Third, oral symptoms, such as dry mouth and taste blindness may also be considered as initial symptoms of COVID-19 infection [25]. Moreover, potential impairment of oral tissues should be evaluated after infected with 2019-nCov, giving more evidence to the prevention and treatment of COVID-19.

In conclusion, our results further confirm the potential role of ACE2 receptor of 2019-nCov invading targeted oral mucosal cells in the protein level. Additionally, we discovered that FURIN enzyme and ACE2 recepor were mainly expressed in epithelial cells, implying the possible two transmission routes of the coronavirus through oral mucosa, which provides a new insight to the future prevention strategy in clinical cares as well as daily life. More evidence is still needed to reinforce these findings.

Declarations

Ethics approval and consent to participate

All human participants signed the informed consent before collecting the samples. Each of the human studies was reviewed and approved by the Institution Ethics Committee of Stomatology Hospital of Guangzhou Medical University.

Consent for publication

Not applicable.

Availability of data and material

The datasets supporting the results of this article are included within the article (and its additional files).

Competing interests

The authors declare that they have no competing interests.

Funding

We acknowledge funding from Medical Research Foundation of Guangdong province (No. A2017583 to LBP and No. A2017589 to ZM), and High-level university construction funding of Guangzhou Medical University (02-412-B205002-1003018 to WLJ).

Authors' contributions

LBP, ZM and GHB helped in the sample collection, gathering of participant data, writing original draft. WXR and Andrew J. Young helped in the manuscript writing, data analysis, and interpretation. WXH, LC, WKB and LMX helped in the IHC assays, and final approval of manuscript. LLH, QCL and CJM helped in the research design, analysis and interpretation of results. WLJ and GLH conceived of the study, and participated in its design and coordination. All authors read and approved the final manuscript.

Acknowledgements

We thank all of the volunteers who agreed to participate in this study, as well as Wang Xinran for his contributions to this work.

Authors' information

Not applicable

Reference

1. Huang C, Wang Y, Li X, et al. Clinical features of patients infected with 2019 novel coronavirus in Wuhan, China [published correction appears in Lancet. 2020 Jan 30]. *Lancet*. 2020; 395 (10223):497–506. doi:10.1016/S0140-6736(20)30183-5.
2. Zhou P, Yang XL, Wang XG, et al. A pneumonia outbreak associated with a new coronavirus of probable bat origin. Nature. 2020;579(7798):270–273. doi:10.1038/s41586-020-2012-7.
3. WHO. Novel coronavirus – China. Jan 12, 2020. http://www.who.int/csr/don/12-january-2020-novel-coronavirus-china/en/ (accessed Jan 19, 2020).
4. Coronavirus latest: global infections pass two million
5. 11 March 16:35 GMT — Coronavirus outbreak is a pandemic, says WHO
6. Wang D, Hu B, Hu C, et al. Clinical Characteristics of 138 Hospitalized Patients With 2019 Novel Coronavirus-Infected Pneumonia in Wuhan, China [published online ahead of print, 2020 Feb 7]. JAMA. 2020; e201585. https://jamanetwork.com/journals/jama/fullarticle/2761044 (2020).
7. Yang Y, Lu Q, Liu M, Wang Y, Zhang A, Jalali N, Dean N, Longini I, Halloran ME, Xu B, Zhang X, Wang L, Liu W, Fang L. Epidemiological and clinical features of the 2019 novel coronavirus outbreak in China. medRxiv preprint 2020.
8. Xu X, Chen P, Wang J, et al. Evolution of the novel coronavirus from the ongoing Wuhan outbreak and modeling of its spike protein for risk of human transmission. Sci China Life Sci. 2020;63(3):457–460.
9. Zou, X. et al. The single-cell RNA-seq data analysis on the receptor ACE2 expression reveals the potential risk of different human organs vulnerable to Wuhan 2019-nCoV infection. Front. Med. http://journal.hep.com.cn/fmd/EN/10.1007/s11684-020-0754-0 (2020).
10. Zhao Y. et al. Single-cell RNA expression profiling of ACE2, the putative receptor of Wuhan 2019-nCoV, in the nasal tissue. Preprint at bioRxiv. Doi: https://doi.org/10.1101/2020.01.26.919985
11. Hamming I, Timens W, Bulthuis ML, Lely AT, Navis G, van Goor H. Tissue distribution of ACE2 protein, the functional receptor for SARS coronavirus. A first step in understanding SARS pathogenesis. J Pathol. 2004;203(2):631–637.
12. Kong L, He L, de Val N, et al. Uncleaved prefusion-optimized gp140 trimers derived from analysis of HIV-1 envelope metastability. Nat Commun. 2016;7:12040. Published 2016 Jun 28.
13. Mallapaty S. Why does the coronavirus spread so easily between people?. Nature. 2020; 579 (7798):183. doi:10.1038/d41586-020-00660-x
14. Li, H. et al. Preprint at ChinaXiv http://chinaxiv.org/abs/202002.00062 (2020).
15. Ma, Y. et al. ACE2 shedding and FURIN abundance in target organs may influence the efficiency of 2019-nCov entry. Preprint at ChinaXiv http://chinaxiv.org/abs/ chinaXiv:202002.00082.
16. Li X, Duan G, Zhang W, Shi J, Chen J, Chen X, Gao S, Ruan J. A FURIN cleavage site was discovered in the S protein of the 2019 novel coronavirus. chinaXiv:202002.00004v2.
17. Navin, N.E. (2015). The first five years of single-cell cancer genomics and beyond. Genome Res. 25, 1499–1507.
18. Tanay A, Regev A. Scaling single-cell genomics from phenomenology to mechanism. Nature. 2017;541(7637):331–338. doi:10.1038/nature21350
19. Zhu S, Qing T, Zheng Y, Jin L, Shi L. Advances in single-cell RNA sequencing and its applications in cancer research. Oncotarget. 2017;8(32):53763–53779. Published 2017 May 16.
20. Qi Z, Barrett T, Parikh AS, Tirosh I, Puram SV. Single-cell sequencing and its applications in head and neck cancer. Oral Oncol. 2019;99:104441. doi:10.1016/j.oraloncology.2019.104441
21. Xu H, Zhong L, Deng J, et al. High expression of ACE2 receptor of 2019-nCoV on the epithelial cells of oral mucosa. Int J Oral Sci. 2020;12(1):8. Published 2020 Feb 24.
22. R López de Cicco, Bassi D E , Page R , et al. Furin expression in squamous cell carcinomas of the oral cavity and other sites evaluated by tissue microarray technology[J]. Acta odontológica latinoamericana: AOL, 2002, 15(1-2):29-37.
23. Wu Z, McGoogan JM. Characteristics of and Important Lessons From the Coronavirus Disease 2019 (COVID-19) Outbreak in China: Summary of a Report of 72 314 Cases From the Chinese Center for Disease Control and Prevention [published online ahead of print, 2020 Feb 24]. JAMA. 2020;10.1001/jama.2020.2648.
24. Cabin Fan, et al. ACE2 Expression in Kidney and Testis May Cause Kidney and Testis Damage After 2019-nCoV Infection. MedRxiv. 13 Feb, 2020
25. Chen, Lili and Zhao, Jiajia and Peng, Jinfeng and Li, Xiaoshuang and Deng, Xuliang and Geng, Zhi and Shen, Zhenyu and Guo, Fengyuan and Zhang, Qianwen and Jin, Yang and Wang, Lin and Wang, Songlin, Detection of 2019-nCoV in Saliva and Characterization of Oral Symptoms in COVID-19 Patients (March 14, 2020). Available at SSRN: http://dx.doi.org/10.2139/ssrn.3557140

26. Structural modeling of 2019-novel coronavirus (nCoV) spike protein reveals a proteolytically-sensitive activation loop as a distinguishing feature compared to SARS-CoV and related SARS-like coronaviruses
27. Abassi ZA, Skorecki K, Heyman SN, Kinaneh S, Armaly Z. Covid-19 infection and mortality - A physiologist's perspective enlightening clinical features and plausible interventional strategies [published online ahead of print, 2020 Mar 24]. Am J Physiol Lung Cell Mol Physiol. 2020;10.1152/ajplung.00097.2020.
28. Walls AC, Park YJ, Tortorici MA, Wall A, McGuire AT, Veesler D. Structure, Function, and Antigenicity of the SARS-CoV-2 Spike Glycoprotein [published online ahead of print, 2020 Mar 6]. Cell. 2020;. doi:10.1016/j.cell.2020.02.058
29. Yuanchen Ma,Yinong Huang,Tao Wang,Andy Peng Xiang,Weijun Huang.(2020).ACE2 shedding and furin abundance in target organs may influence the efficiency of SARS-CoV-2 entry.[ChinaXiv:202002.00082]
30. Zou X, Chen K, Zou J, Han P, Hao J, Han Z. Single-cell RNA-seq data analysis on the receptor ACE2 expression reveals the potential risk of different human organs vulnerable to 2019-nCoV infection [published online ahead of print, 2020 Mar 12]. Front Med. 2020;10.1007/s11684-020-0754-0.
31. Zhao, Y. et al. Single-cell RNA expression profiling of ACE2, the putative receptor of Wuhan 2019-nCov. Preprint at https://www.biorxiv.org/content/10.1101/ 2020.01.26.919985v1 (2020).
32. Zhang, H. et al. The digestive system is a potential route of 2019-nCov infection: a bioinformatics analysis based on single-cell transcriptomes. Preprint at https://www.biorxiv.org/content/10.1101/2020.01.30.927806v1.
33. To KK, Tsang OT, Chik-Yan Yip C, et al. Consistent detection of 2019 novel coronavirus in saliva [published online ahead of print, 2020 Feb 12]. Clin Infect Dis. 2020;ciaa149.
34. Zou L, Ruan F, Huang M, et al. SARS-CoV-2 Viral Load in Upper Respiratory Specimens of Infected Patients. N Engl J Med. 2020;382(12):1177–1179. doi:10.1056/NEJMc2001737
35. Meng L, Hua F, Bian Z. Coronavirus Disease 2019 (COVID-19): Emerging and Future Challenges for Dental and Oral Medicine [published online ahead of print, 2020 Mar 12]. J Dent Res. 2020;22034520914246.
36. Marui VC, Souto MLS, Rovai ES, Romito GA, Chambrone L, Pannuti CM. Efficacy of preprocedural mouthrinses in the reduction of microorganisms in aerosol: A systematic review. J Am Dent Assoc. 2019;150(12):1015–1026.e1.

Figure legend

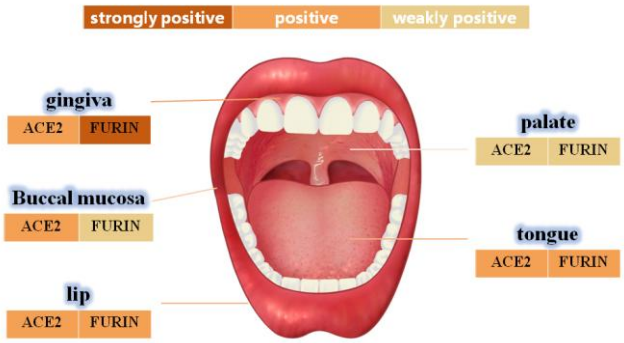

Fig. 1 The schematic diagram of FURIN and ACE2 expression levels in different oral sites.

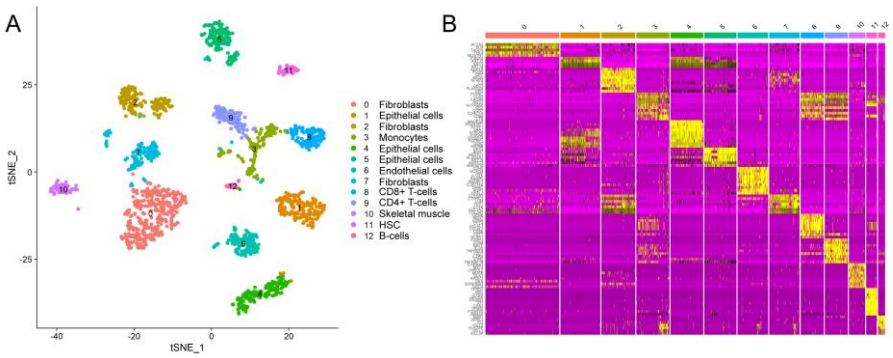

Fig. 2 Single-cell atlas of the human oral mucosa. (A and B) Analysis of single-cell sequencing data identified thirteen cell sub-clusters in the oral mucosal cells.

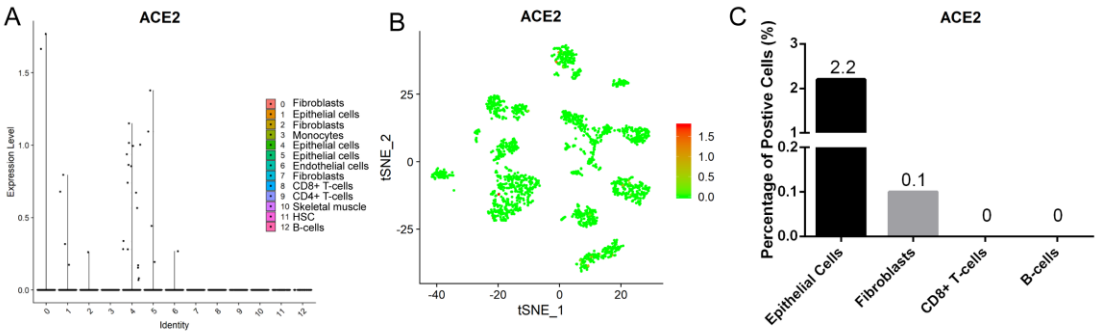

Fig. 3 The expression profiles of ACE2 in the oral mucosal cells. (A) Violin and (B) scatter plot showed the expression profile of ACE2 receptor in oral mucosal cells. ACE2 was expressed in epithelial cells. (C) The percentage of ACE2-postive cells in oral mucosa.

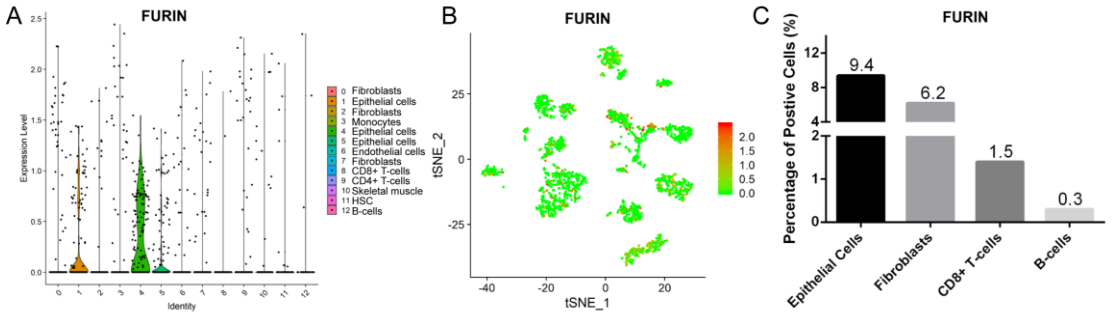

Fig. 4 The expression profiles of FURIN in the oral mucosal cells. (A) Violin and (B) scatter plot showed the expression profile of FURIN enzyme in oral mucosal cells. FURIN was highly expressed in epithelial cells. (C) The percentage of FURIN-expressed cells in oral mucosal cells.

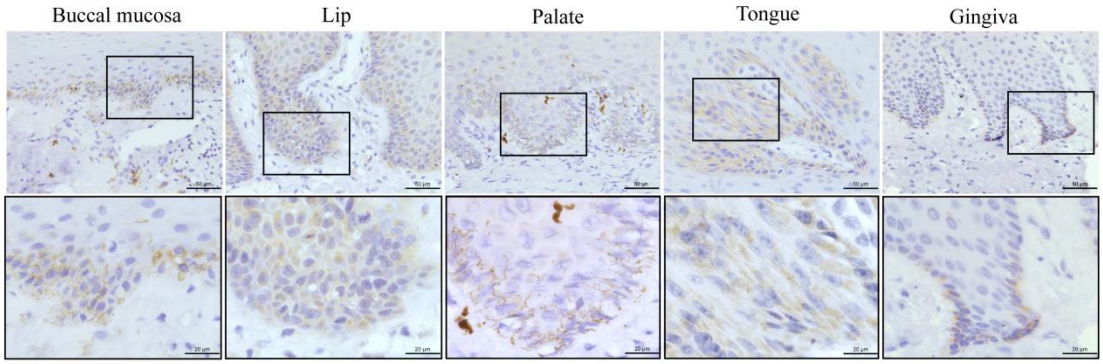

Fig. 5 ACE2 protein was highly expressed in the various oral tissues. Immunohistological staining against ACE2 was used to determine whether ACE2 express in the normal buccal, lip, palate, tongue, and gingival tissues from the human. The lower panels demonstrate the appearance of basal layer and epithelial cells at higher magnification as indicated by black squares in upper panels. ACE2 was highly expressed in basal layer epithelial cells of these five oral tissues. Scale bars = 50 μm.

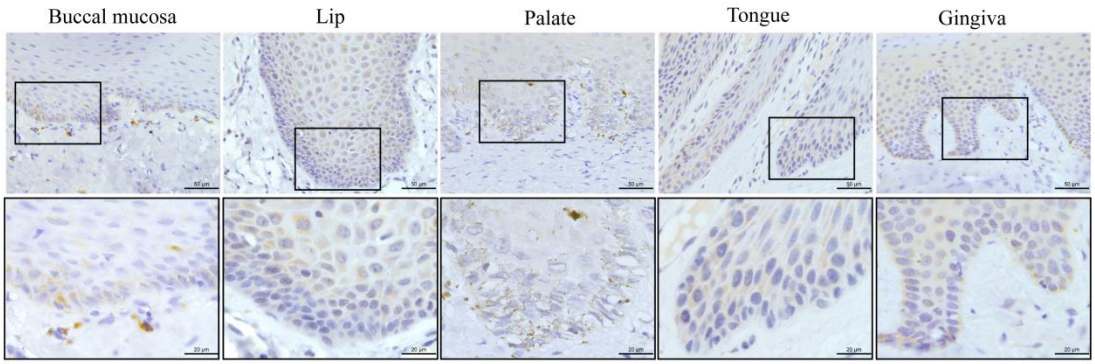

Fig. 6 FURIN was highly expressed in the various oral tissues. Immunohistological staining against FURIN was used to determine whether FURIN expressed in the normal buccal mucosa, lip, palate, tongue, and gingival tissues from the patients. The lower panels demonstrate the appearance of basal layer and epithelial cells at higher magnification as indicated by black squares in upper panels. FURIN was highly expressed in spinous and basal layer cells, while FURIN-positive

fibroblasts and endothelial cells in tongue, buccal and palate tissues were limited. Scale bars = 50 μm.

Supplemental Files

Designation	Age/Sex	Primary site	Pathologic stage	Grade	LVI
MEP 6	88/F	right floor of mouth	T4aN2c	1	Absent
MEP 8	82/F	right hard palate	T4aN0	1	Absent
MEP 16	63/F	left lateral tongue	T2N0	1	Absent
MEP 22	77/M	left buccal mucosa	T1N0	2	Absent
MEP 28	58/M	right lateral tongue	T2N2c	1	Present

Table S1. Patients and samples included in dataset

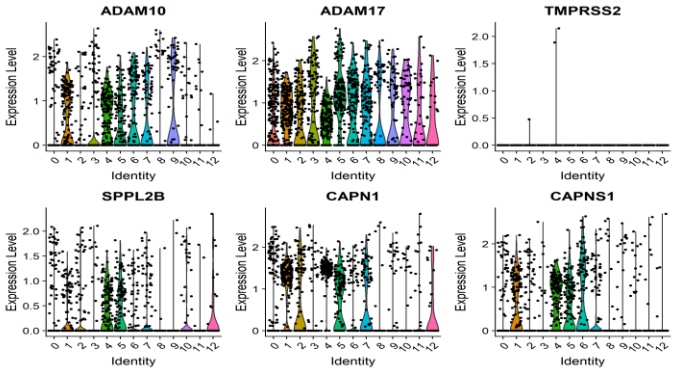

Fig. S2 The expression profiles of FURIN in the oral mucosal cells. (A) Violin and (B) scatter plot showed the expression profile of FURIN receptor in the oral mucosal cells. FURIN was highly expressed in epthelial cells. (C) The percentage of FURIN-expression cells in the adult oral mucosal cells.

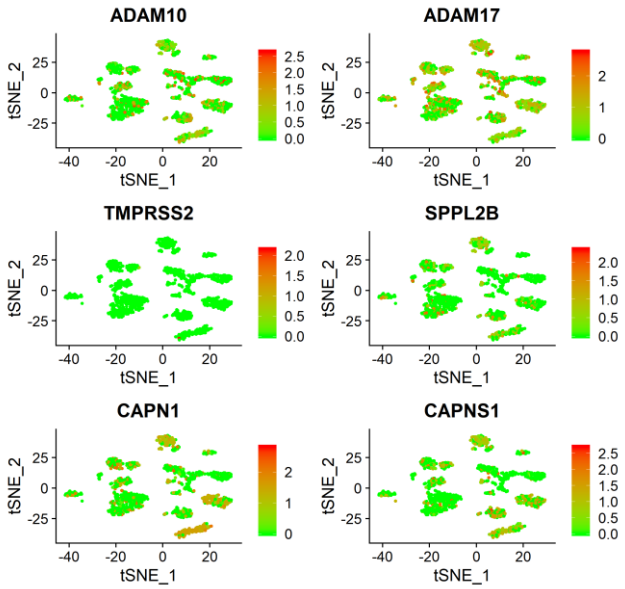

Fig. S3 The expression profiles of other endopeptidase in the oral mucosal cells. Scatter plot showed the distribution profile of ADAM10, ADAM17, TMPRSS2, SPPL2B, CAPN1 and CAPNS1 in the oral mucosal cells.