Background mechanisms of olfactory dysfunction in COVID-19: expression of ACE2, TMPRSS2, and Furin in the nose and olfactory bulb in human and mice

Rumi Ueha[1]*, M.D., Ph.D.; Kenji Kondo[1] M.D., Ph.D.; Ryoji Kagoya[1] M.D., Ph.D.; Shigeyuki Shichino[2], Ph.D.; Satoshi Ueha[2], Ph.D.; and Tatsuya Yamasoba M.D., Ph.D.

1. Department of Otolaryngology and Head and Neck Surgery, Faculty of Medicine, the University of Tokyo, Tokyo, Japan
2. Division of Molecular Regulation of Inflammatory and Immune Diseases, Research Institute for Biomedical Sciences, Tokyo University of Science, Chiba, Japan

Correspondence to: Rumi Ueha
Department of Otolaryngology and Head and Neck Surgery, Faculty of Medicine, the University of Tokyo, Tokyo, Japan, 113-8655
E-mail: ruu1025@yahoo.co.jp
Tel: +81-3-3815-5411, Fax: +81-3-3814-9486

Short Summary: Protein expression patterns of ACE2, TMPRSS, and Furin suggest that COVID-19 related anosmia can occur due to mainly sensorineural dysfunction without olfactory neuronal damage.

Funding: This work was supported by JSPS KAKENHI Grant-in-Aid for Scientific Research (C) [grant number 24791749, 16K20231] and by the Smoking Research Foundation (Tokyo, Japan).

Abstract

Background: Anosmia is a frequent symptom in patients with the coronavirus disease 2019 (COVID-19) driven by severe acute respiratory syndrome coronavirus 2 (SARS-CoV-2) and mostly recovers within weeks. This clinical figure is significantly different from that of anosmia after upper respiratory infection, which occurs in only a small proportion of patients and does not recover or requires months to recover. The background mechanisms of COVID-19 induced olfactory dysfunction have not been elucidated.

Methods: To address the unique pathophysiology of olfactory dysfunction associated with COVID-19, we examined the existence and distribution of ACE2 (virus binding receptor), TMPRSS2 and Furin (proteases to facilitate virus entry) in the nasal mucosa, composed of the respiratory mucosa (RM) and olfactory mucosa (OM), and the olfactory bulb (OB) in mouse and human tissues by immunohistochemistry and gene analyses.

Results:

Ace2, Tmprss2, and *Furin* gene expressions were confirmed in the nasal mucosa and OB. ACE2 was widely expressed all in the RM, OM and OB. Co-expression of ACE2, TMPRSS2, and Furin was observed in the RM including the RE and subepithelial glands and in the OM, especially in the supporting cells on the olfactory epithelium and the Bowman's glands. Notably, the olfactory receptor neurons (ORNs) in the OM were positive for ACE2 but almost negative for TMPRSS2 and Furin. The cells in the OB expressed ACE2 strongly and Furin weakly and did not express TMPRSS2.

Conclusions: ACE2 was widely expressed in the RM, OM and OB, but TMPRSS2 and Furin were expressed in certain types of cells and were absent in the ORNs. These findings, together with clinically reported ones, suggest that COVID-19 related anosmia can occur due to mainly sensorineural and central dysfunction and, to some extent, conductive olfactory dysfunction. That the ORNs express ACE2 but not TMPRSS2 or Furin may explain the early recovery of anosmia.

Introduction

The recent international spread of the coronavirus disease 2019 (COVID-19) driven by severe acute respiratory syndrome coronavirus 2 (SARS-CoV-2) poses a serious health emergency. COVID-19 usually begins with simple respiratory symptoms such as fever, shore throat, and cough for 2−3 days (*1, 2*). Notably, chemosensitive disorders, such as loss or decline of smell (anosmia or hyposmia), and loss of taste (ageusia or dysgeusia), have been repeatedly reported as a unique clinical feature of COVID-19 (*3, 4*), and now is considered as typical symptoms of the early stage of the SARS-CoV-2 infection (*4, 5*). Recently published meta-analysis demonstrated a 52.73% prevalence of olfactory dysfunction among 1,627 COVID-19 patients (*6*). Of particular, a high rate of anosmia (a complete loss of smell) has been well documented (*3, 5, 7, 8*). In contrast, only a smaller proportion (up to 20%) of patients with upper respiratory infection (URI) exhibits olfactory dysfunction (*9*). The prognosis of olfactory dysfunction due to URI is generally poor, with a majority of patients showing no or slight recovery within a few months (*10*), whereas olfactory dysfunction in patients with COVID-19 recovers relatively early, with reported duration being from 1 to 4 weeks (*3, 8, 11-13*). In a cohort of COVID-19 patients with olfactory dysfunction, loss of smell was reported to be the first symptom of COVID-19 in 27% of patients (*12*). These three clinical features in COVID-19 are significantly different from those found in patients with common URI, which occurs due to various virus including rhinovirus, picornavirus, and parainfluenza virus (*9, 14-16*).

Cell entry of SARS-CoV-2 depends on binding of the viral spike proteins to a cellular receptor, angiotensin-converting enzyme 2 (ACE2) (*17-19*) and depends on spike protein cleavage by Furin (*19-21*) and spike protein priming by host cell proteases including transmembrane protease serine 2 (TMPRSS2) (*19, 22*). Thus, high expressions of ACE2, TMPRSS2, and Furin are considered to enhance SARS-CoV-2 entry and the resulting clinical symptoms. To date, the expression of ACE2 (*23, 24*) and TMPRSS2 (*24*), but not Furin, has been reported in the nasal epithelium by using gene analyses. However, histological evaluation of their expression has been limited; only one study reported expression of ACE2 and TMPRSS2 proteins in the nasal mucosa and respiratory sinus, but it did not demonstrate immunostaining images of the nasal mucosa (*25*).

The nasal mucosa is divided into the respiratory mucosa (RM) and olfactory mucosa (OM) based on its histological components and functions. The RM consists of various types of epithelial cells including the ciliated columnar and goblet cells. The OM serves olfaction and consists of the olfactory epithelium (OE) and subepithelial tissues (*26*). The degree of olfaction is closely related to the number of mature olfactory receptor neurons (ORNs) in the OE. The olfactory system consists of peripheral compartments such as the

OM and central structures, such as the olfactory bulb (OB) and piriform/entorhinal cortex (*27*).

In the present study, in order to elucidate the background mechanisms of olfactory dysfunction and the pathogenesis of high viral load in the upper airway in COVID-19 patients, we investigated the expression of ACE2, TMPRSS2, and Furin in the RM, OM, and OB in human and mouse tissues.

Methods

Experimental samples

Animal tissue samples were all obtained from the mice examined in the previous published studies (*26, 28*), because purchasing new animals had been prohibited in our facility due to the epidemic spread. The samples from 6 eight-week-old male C57BL/6 mice (*26*) and an eight-week-old- male Sprague Dawley rat (*28*) were used, and the following paraffin-embedded tissues were collected; the RM area and OM area of the nose, the OB area, and the kidney and prostate for positive controls of immunostaining (Figure 1A). Human tissues were obtained from patients undergoing surgery for the treatment of chronic sinusitis or olfactory neuroblastoma. These included the OM (n = 3), the middle turbinate (n = 5), and inferior turbinate (n = 6); the latter two were used for the evaluation of the RM. Routine morphology was evaluated in haematoxylin and eosin-stained sections by a qualified pathologist and otolaryngologists. Tissue evaluation was performed only in the parts characterized as non-diseased. All experiments were conducted in accordance with institutional guidelines and with the approval of the Animal Care and Use Committee of the University of Tokyo (No. P14-051, P15-115) and of the Research Ethics Committee of the Graduate School of Medicine and Faculty of Medicine, the University of Tokyo, Japan (12009, 2019073NI). Since archived specimens were used, written informed consent was waived.

Histological analyses

To detect the expressions of ACE2 and TMPRSS2 in the RM, OM, and OB, histological analyses were performed by immunostaining. Four-µm-thick serial paraffin sections were deparaffinized in xylene and dehydrated in ethanol before immunostaining. Prior to immunostaining, deparaffinized sections were treated with 3% hydrogen peroxide to block endogenous peroxidase activity and were incubated in Blocking One (Nacalai Tesque, Kyoto, Japan) to block non-specific immunoglobulin binding. After antigen activation, primary antibodies against ACE2 (1:300 dilution; rabbit monoclonal, Abcam, ab108252; Cambridge, UK), TMPRSS2 (1:1000 dilution; rabbit monoclonal, Abcam, ab92323;

Cambridge, UK), Furin (1:100 dilution; rabbit monoclonal, Abcam, ab183495; Cambridge, UK) , and PGP9.5 for a neuronal marker (1:500 dilution; guinea pig polyclonal, Abcam, ab10410; Cambridge, UK) were detected with peroxidase conjugated appropriate secondary antibodies and a diaminobenzidine substrate. The mouse kidney and rat prostate were stained for positive controls for ACE2 and for TMPRSS2 and Furin, respectively (Figure 1B). All samples were stained under the same condition and protocol as the positive control staining. Images of all sections were captured using a digital microscope camera (Keyence BZ-X700) with 4×, 10x, 20×, and 40x objective lenses.

Gene expression analyses

Our previous DNA microarray data from the nasal mucosa and OB (NCBI Gene Expression Omnibus database under the series number GSE 103191) was used to examine the expressions of *ACE2, TMPRSS2,* and *Furin*. The expression levels of each gene were normalized against the expression level of *Rps3* (encoding ribosomal protein S3) in each sample.

Results

The immunohistological data is summarized in Table 1. ACE2, TMPRSS2, and Furin were present in the human and mouse nasal mucosa and in the mouse OB, though the expression pattern of ACE2, TMPRSS2, and Furin varied among tissues. Remarkably, co-expression of ACE2, TMPRSS, and Furin was detected in the supporting cells and the Bowman's glands in the OM and diffusely in the RM, but not in the ORNs of the OM or the OB.

In the mouse RM, ACE, TMPRSS2, and Furin were all strongly expressed in the cytoplasm of the RE cells and the subepithelial glands (Fig.2a, b). ACE2 and TMPRSS2 were highly co-expressed in the RE. The villous brush border of the respiratory columnar epithelium was strongly positive for TMPRSS2 expression. Moderate cytoplasmic staining for TMPRSS2 and Furin was observed in the subepithelial tissue (Fig. 2a, b). In the OM, only the supporting cells and the Bowman's glands expressed all of ACE2, TMPRSS2, and Furin. The olfactory nerve bundles were moderately positive for ACE2 and TMPRSS2. Notably, all cells in the OE including the supporting cells, ORNs, and basal cells, were definitely positive for ACE2, while the ORNs was negative for TMPRESS2 and Furin (Fig. 2c, d). In the OB, no cells expressed ACE2, TMPRSS2, or Furin simultaneously (Fig. 3a-c). ACE2 positive cells were recognized in the glomerular layer, mitral cell layer, and granule cell layer, whereas those cells were all negative for TMPRSS2. On the contrary, some cells in the glomerular layer and mitral cells were positive for Furin. TMPRSS2 was strongly

expressed in the cells in the core of the OB (Fig. 3b).

To reinforce the above histological result, we investigated the presence or absence of gene expressions of *Ace2*, *Tmprss2,* and *Furin* in the mouse nasal mucosa and OB. From the database of the previous study, expression of the three genes in the nasal mucosa and OB were confirmed (Fig. 3d).

In human nasal mucosa, PGP9.5 antibody clearly visualized the OE containing olfactory neurons. ACE2 was localized in PGP9.5-positive ORNs. While Furin were not present in the OE, TMPRSS2 was weakly expressed in the apical layer of the OE. (Fig. 4a, b). In the RM, ACE2, TMPRSS2, and Furin were widely co-expressed in the epithelium (Fig. 4c, d). These findings were basically identical to those found in mouse tissues.

Discussion

COVID-19 has been observed to present with numerous clinical symptoms, including a deteriorated sense of taste and smell, respiratory and digestive disorders (*3, 4, 29*). The results of the present study explain why olfaction is frequently impaired in COVID-19 patients. We observed the immunolocalization of ACE2, TMPRSS2, and Furin in the nasal tissue and the OB, which were considered to play a pivotal role in the manifestation of olfactory dysfunction induced by SARS-CoV-2 infection. Histologically, ACE2, TMPRSS, and Furin were co-expressed in the supporting cells and the Bowman's glands on the OM, and the RM, but not in the ORNs of the OM or the OB. Confirmation of *Ace2*, *Tmprss2*, and *Furin* gene expressions in the nasal mucosa and the OB supported these immunohistochemical findings.

Olfactory dysfunction is defined into three types according to anatomical location; conductive, sensorineural, and central dysfunction (*30*). Conductive dysfunction results from blockage of odorant airflow to the OE. Sensorineural dysfunction is caused by damage of the ORNs and olfactory nerve, impaired olfactory adaptation, and/or odorant transport. The supporting cells and the Bowman's glands are involved in olfactory adaptation and neurotrophic and physical support for the OE (*31-33*). Thus, if the function of the supporting cells and Bowman's glands is deteriorated, odor adaptation is impaired and subsequent sensorineural dysfunction occurs. Central dysfunction occurs by the damage of the olfactory processing pathways in the central nervous system (*30*). Based on the present histological results, olfactory dysfunction induced by SARS-CoV-2 can be either conductive, sensorineural, or central dysfunction, but be mainly sensorineural dysfunction without olfactory neuronal damage.

In the olfactory mucosa, co-expression of ACE2, TMPRSS2, and Furin in the supporting cells and the Bowman's glands suggest that COVIT19 may induce deterioration

of mucus production and OE support, resulting in impairment of odor adaptation and transduction. Moreover, co-expression of ACE2 and TMPRSS2 in the olfactory nerve bundle implies odor transduction can be impaired by neuronal dysfunction. It is unlikely that SARS-CoV-2 directly damages the ORNs in the OM, because the ORNs expressed ACE2, but not TMPRSS2 or Furin. Also, the severe damage of the ORNs cannot explain the early recovery of olfaction in COVID-19 patients with anosmia, since the turnover rate of ORNs is approximately 30 days (*34*). Centrally, in the OB, co-expression of ACE2 and Furin in the mitral cells, which have large cell body and secondary dendrites, suggests that central olfactory dysfunction may occur due to synaptic inhibition from the ORNs through to processing at the olfactory bulb. Although most patients with COVID-19 are likely to improve olfactory dysfunction, some patients did not recover their olfaction in a few months (*8*). COVID-19 patients with prolonged olfactory dysfunction may suffer from continuing sensorineural and central olfactory dysfunction.

Considering that high expression of all ACE2, TMPRSS2, and Furin in the RE and the subepithelial glands, SARS-CoV-2 possibly induces conductive olfactory dysfunction due to hypersecretion and goblet cell hyperplasia (*14, 35*). In fact, not a few patients with COVID-19 are reported to suffer from nasal obstruction and rhinorrhea (*3*). However, olfactory symptoms due to conductive olfactory dysfunction may fluctuate and rarely become completely lost. Also, certain proportion of COVID-19 patients with hyposmia and anosmia did not exhibit nasal obstruction or rhinitis symptoms (*3, 36*). Thus, the contribution of conductive olfactory loss may be limited.

The present study demonstrated high expression of ACE2 with TMPRSS2 and Furin in the nasal mucosa and OB. Their expression patterns suggest that olfactory dysfunction in COVID-19 patients may be mainly of sensorineural and central and, to some extent, conductive.

References

1. C. Huang *et al.*, Clinical features of patients infected with 2019 novel coronavirus in Wuhan, China. *Lancet* **395**, 497 (Feb 15, 2020).
2. X. Huang, F. Wei, L. Hu, L. Wen, K. Chen, Epidemiology and Clinical Characteristics of COVID-19. *Archives of Iranian medicine* **23**, 268 (Apr 1, 2020).
3. J. R. Lechien *et al.*, Olfactory and gustatory dysfunctions as a clinical presentation of mild-to-moderate forms of the coronavirus disease (COVID-19): a multicenter European study. *European archives of oto-rhino-laryngology : official journal of the European Federation of Oto-Rhino-Laryngological Societies*, (Apr 6, 2020).
4. L. A. Vaira *et al.*, Objective evaluation of anosmia and ageusia in COVID-19 patients: Single-center experience on 72 cases. *Head & neck*, (Apr 27, 2020).
5. J. Krajewska, W. Krajewski, K. Zub, T. Zatonski, COVID-19 in otolaryngologist practice: a review of current knowledge. *European archives of oto-rhino-laryngology : official journal of the European Federation of Oto-Rhino-Laryngological Societies*, (Apr 18, 2020).
6. J. Y. Tong, A. Wong, D. Zhu, J. H. Fastenberg, T. Tham, The Prevalence of Olfactory and Gustatory Dysfunction in COVID-19 Patients: A Systematic Review and Meta-analysis. *Otolaryngology--head and neck surgery : official journal of American Academy of Otolaryngology-Head and Neck Surgery*, 194599820926473 (May 5, 2020).
7. B. Russell *et al.*, Anosmia and ageusia are emerging as symptoms in patients with COVID-19: What does the current evidence say? *Ecancermedicalscience* **14**, ed98 (2020).
8. C. Hopkins, P. Surda, E. Whitehead, B. N. Kumar, Early recovery following new onset anosmia during the COVID-19 pandemic - an observational cohort study. *Journal of otolaryngology - head & neck surgery = Le Journal d'oto-rhino-laryngologie et de chirurgie cervico-faciale* **49**, 26 (May 4, 2020).
9. A. M. Seiden, Postviral olfactory loss. *Otolaryngologic clinics of North America* **37**, 1159 (Dec, 2004).
10. M. Yamagishi, M. Fujiwara, H. Nakamura, Olfactory mucosal findings and clinical course in patients with olfactory disorders following upper respiratory viral infection. *Rhinology* **32**, 113 (Sep, 1994).
11. C. H. Yan, F. Faraji, D. P. Prajapati, C. E. Boone, A. S. DeConde, Association of chemosensory dysfunction and Covid-19 in patients presenting with influenza-like symptoms. *International forum of allergy & rhinology*, (Apr 12, 2020).
12. R. Kaye, C. W. D. Chang, K. Kazahaya, J. Brereton, J. C. Denneny, 3rd, COVID-19

Anosmia Reporting Tool: Initial Findings. *Otolaryngology--head and neck surgery : official journal of American Academy of Otolaryngology-Head and Neck Surgery*, 194599820922992 (Apr 28, 2020).

13. A. R. Sedaghat, I. Gengler, M. M. Speth, Olfactory Dysfunction: A Highly Prevalent Symptom of COVID-19 With Public Health Significance. *Otolaryngology--head and neck surgery : official journal of American Academy of Otolaryngology-Head and Neck Surgery*, 194599820926464 (May 5, 2020).
14. M. Suzuki *et al.*, Identification of viruses in patients with postviral olfactory dysfunction. *The Laryngoscope* **117**, 272 (Feb, 2007).
15. D. A. Deems *et al.*, Smell and taste disorders, a study of 750 patients from the University of Pennsylvania Smell and Taste Center. *Archives of otolaryngology--head & neck surgery* **117**, 519 (May, 1991).
16. W. S. Cain, J. F. Gent, R. B. Goodspeed, G. Leonard, Evaluation of olfactory dysfunction in the Connecticut Chemosensory Clinical Research Center. *The Laryngoscope* **98**, 83 (Jan, 1988).
17. W. Li *et al.*, Angiotensin-converting enzyme 2 is a functional receptor for the SARS coronavirus. *Nature* **426**, 450 (Nov 27, 2003).
18. F. Wu *et al.*, A new coronavirus associated with human respiratory disease in China. *Nature* **579**, 265 (Mar, 2020).
19. S. Lukassen *et al.*, SARS-CoV-2 receptor ACE2 and TMPRSS2 are primarily expressed in bronchial transient secretory cells. *The EMBO journal*, e105114 (Apr 4, 2020).
20. A. C. Walls *et al.*, Structure, Function, and Antigenicity of the SARS-CoV-2 Spike Glycoprotein. *Cell* **181**, 281 (Apr 16, 2020).
21. B. Coutard *et al.*, The spike glycoprotein of the new coronavirus 2019-nCoV contains a furin-like cleavage site absent in CoV of the same clade. *Antiviral research* **176**, 104742 (Apr, 2020).
22. S. Matsuyama *et al.*, Enhanced isolation of SARS-CoV-2 by TMPRSS2-expressing cells. *Proceedings of the National Academy of Sciences of the United States of America* **117**, 7001 (Mar 31, 2020).
23. X. Zou *et al.*, Single-cell RNA-seq data analysis on the receptor ACE2 expression reveals the potential risk of different human organs vulnerable to 2019-nCoV infection. *Frontiers of medicine*, (Mar 12, 2020).
24. W. Sungnak *et al.*, SARS-CoV-2 entry factors are highly expressed in nasal epithelial cells together with innate immune genes. *Nature medicine*, (Apr 23, 2020).

25. S. Bertram *et al.*, Influenza and SARS-coronavirus activating proteases TMPRSS2 and HAT are expressed at multiple sites in human respiratory and gastrointestinal tracts. *PloS one* **7**, e35876 (2012).
26. R. Ueha, S. Ueha, K. Kondo, H. Nishijima, T. Yamasoba, Effects of Cigarette Smoke on the Nasal Respiratory and Olfactory Mucosa in Allergic Rhinitis Mice. *Frontiers in neuroscience* **14**, 126 (2020).
27. R. Ueha *et al.*, Reduction of Proliferating Olfactory Cells and Low Expression of Extracellular Matrix Genes Are Hallmarks of the Aged Olfactory Mucosa. *Frontiers in aging neuroscience* **10**, 86 (2018).
28. R. Ueha *et al.*, Laryngeal mucus hypersecretion is exacerbated after smoking cessation and ameliorated by glucocorticoid administration. *Toxicology letters* **265**, 140 (Jan 4, 2017).
29. L. Pan *et al.*, Clinical Characteristics of COVID-19 Patients With Digestive Symptoms in Hubei, China: A Descriptive, Cross-Sectional, Multicenter Study. *The American journal of gastroenterology* **115**, 766 (May, 2020).
30. T. Hummel *et al.*, Position paper on olfactory dysfunction. *Rhinology* **56**, 1 (Jan 31, 2016).
31. M. Okano, S. F. Takagi, Secretion and electrogenesis of the supporting cell in the olfactory epithelium. *The Journal of physiology* **242**, 353 (Oct, 1974).
32. B. Branigan, P. Tadi, in *StatPearls*. (Treasure Island (FL), 2020).
33. C. Acevedo, K. Blanchard, J. Bacigalupo, C. Vergara, Possible ATP trafficking by ATP-shuttles in the olfactory cilia and glucose transfer across the olfactory mucosa. *FEBS letters* **593**, 601 (Mar, 2019).
34. D. G. Moulton, Dynamics of cell populations in the olfactory epithelium. *Annals of the New York Academy of Sciences* **237**, 52 (Sep 27, 1974).
35. T. Hummel, Perspectives in Olfactory Loss Following Viral Infections of the Upper Respiratory Tract. *Archives of otolaryngology--head & neck surgery* **126**, 802 (Jun, 2000).
36. L. A. Vaira, G. Salzano, G. Deiana, G. De Riu, Anosmia and Ageusia: Common Findings in COVID-19 Patients. *The Laryngoscope*, (Apr 1, 2020).

Table 1. Protein expression levels of ACE2, TMPRSS2, and Furin in the respiratory mucosa, olfactory mucosa, and olfactory bulb.

RM: Respiratory mucosa, RE: Respiratory epithelium, LP: Lamina propria, OM: Olfactory mucosa, OE: Olfactory epithelium, OB: Olfactory bulb, LP: Lamina propria.

+: mild expression, ++: moderate to strong expression, -: negative.

			ACE2	TMPRSS2	Furin
RM	RE	Nucleus	++	+	-
		Cytoplasm	+	+	+
	LP	Subepithelial Gland	+	++	++
OM	OE	Supporting cell	++	+	+
		Olfactory receptor neuron	++	-	-
		Basal cell	++	±	-
		Cytoplasm	-	+	+
	LP	Bowman's Gland	+	++	++
		Olfactory nerve bundle	+	+	-
OB	Glomerular layer		++	-	+
	Mitral cell layer		++	-	+
	Granule cell layer		++	-	-

Figure 1. Nose sagittal section and representative images of ACE2 staining in the mouse kidney, TMPRSS2 and Furin staining in the rat prostate.

a: Sagittal section of the rodent nose. The burs indicate the respiratory mucosal section (RM), olfactory mucosal section (OM), and the olfactory bulb section (OB). **b**: Positive stainings for ACE2 in the kidney, TMPRSS2 and Furin in the prostate were shown. ACE2 positive cells were observed in the brush boarder and the cytoplasm and nucleus of the tubular cells. TMPRSS2 positive cells were observed in the cytoplasm and nucleus of acinar cells. Furin positive cells were observed in the supernuclear cytoplasm (mainly Golgi apparatus) of acinar cells in the prostate glands.

Figure 2: Representative images of mouse respiratory and olfactory mucosa stained with antibodies against ACE2, TNPRSS2, and Furin.

a and **b**: The boxes in (a) indicate parts of the respiratory mucosa (RM), which were shown at higher magnification in (b) (a, 40× magnification; b, 400× magnification). In the RM area, the respiratory epithelium (RE) was stained by ACE2. On the other hand, TMPRSS2 and Furin were stained strong in the cilia of the ciliated columnar RE and were moderately positive in the supernuclear cytoplasm of RE cells and subepithelial glands. **c** and **d**: In the olfactory mucosal (OM) area, the supporting cells (SPs, arrows), olfactory receptor neurons (ORNs), and basal cells (BCs, arrow heads) were strongly stained by ACE2. TMPRSS2 expression was negative in the ORNs, while moderately positive in the SPs and strongly positive in the Bowman's glands (thick black arrows) and the lamina propria. The olfactory nerve bundles weakly co-expressed ACE2 and TMPRSS2 (star marks). Furin was also expressed in the SPs and the Bowman's glands (thick black arrows) The boxes in (c) indicate parts of the OM, which were shown at higher magnification in (d) (c, 40× magnification; d, 400× magnification).

Figure 3: Representative images of mouse olfactory bulb stained with antibodies against ACE2, TNPRSS2, and Furin.

a, b, c: The olfactory bulb (OB) area. The boxes in (a) and (b) were shown at higher magnification in (b) and (c), respectively (a, 40× magnification; b, 100× magnification; c, 400x magnification). The OB parenchyma was weakly positive for ACE2 and definitely positive for TMPRSS2, and negative for Furin. While ACE2 positive cells were recognized in the glomerular layer (GL), mitral cell layer (MCL, arrow heads), and granule cell layer (GCL), those cells were negative for TMPRSS2. Some mitral cells were positive for Furin (thick black arrows). TMPRSS2 was strongly expressed in the cells in the core of the OB (star marks). **d**: Gene expression levels of *Ace2*, *Tmprss2,* and *Furin* in the nasal mucosa and

olfactory bulb.

Gene expression levels of *Ace2*, *Tmprss2,* and *Furin* in the nasal mucosa and olfactory bulb are expressed relative to the expression of the endogenous control gene Rps3 (encoding ribosomal protein S3). The graph is shown in $\log_{10}$ scale.

Figure 4: Representative images of human tissues stained with antibodies against ACE2, TMPRSS2, and Furin.

a and **b**: In the olfactory mucosal area, the area of the olfactory epithelium was recognized by PGP9.5 staining. PGP9.5^{+} ORNs mostly expressed ACE2 but not TMPRSS2 and Furin. Expression of TMPRSS2 was strong in the cytoplasm of the subepithelial glands. Furin was rarely detected in the human olfactory epithelium, but weak expression of Furin was noted in the subepithelial glands. The boxes in (a) were shown at higher magnification in (b) (a, 40× magnification; b, 400x magnification). **c** - **f**: Representative images of the middle turbinate and inferior turbinate. The boxes in (c) and (e) indicate parts of the respiratory mucosa, which were shown at higher magnification in (d) and (f) (c, e, 40× magnification; d, f, 400x magnification). Protein expression of ACE2, TMPRSS2 and Furin was detected in the respiratory epithelium and subepithelial glands. Especially, TMPRSS2 expression was well-defined.

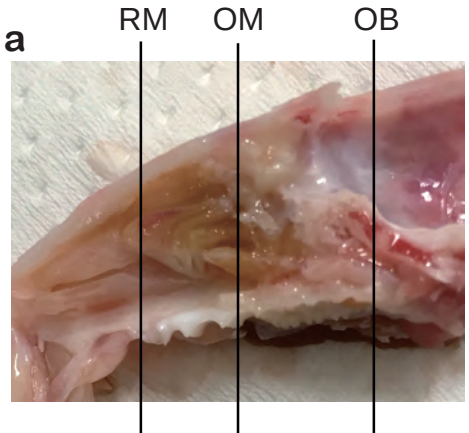
a
RM
OM
OB

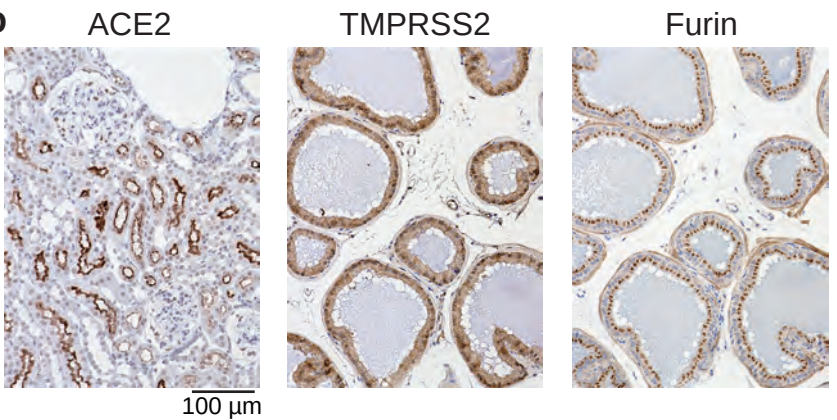
b
ACE2
TMPRSS2
Furin
100 µm

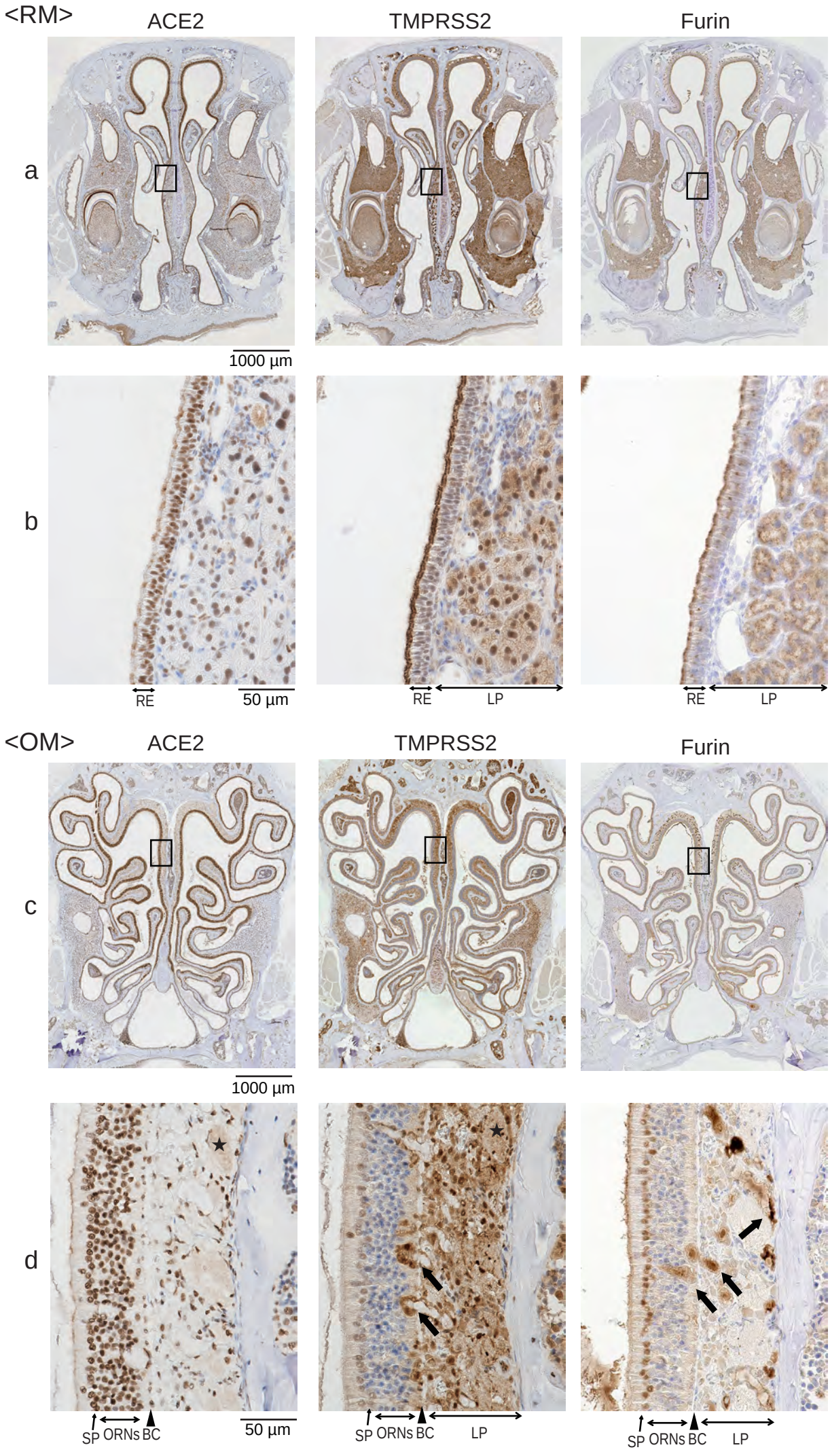
<RM>
ACE2
TMPRSS2
Furin
a
1000 µm
b
RE
50 µm
RE
LP
RE
LP
<OM>
ACE2
TMPRSS2
Furin
c
1000 µm
d
SP ORNs BC
50 µm
SP ORNs BC
LP
SP ORNs BC
LP

<Olfactory bulb>

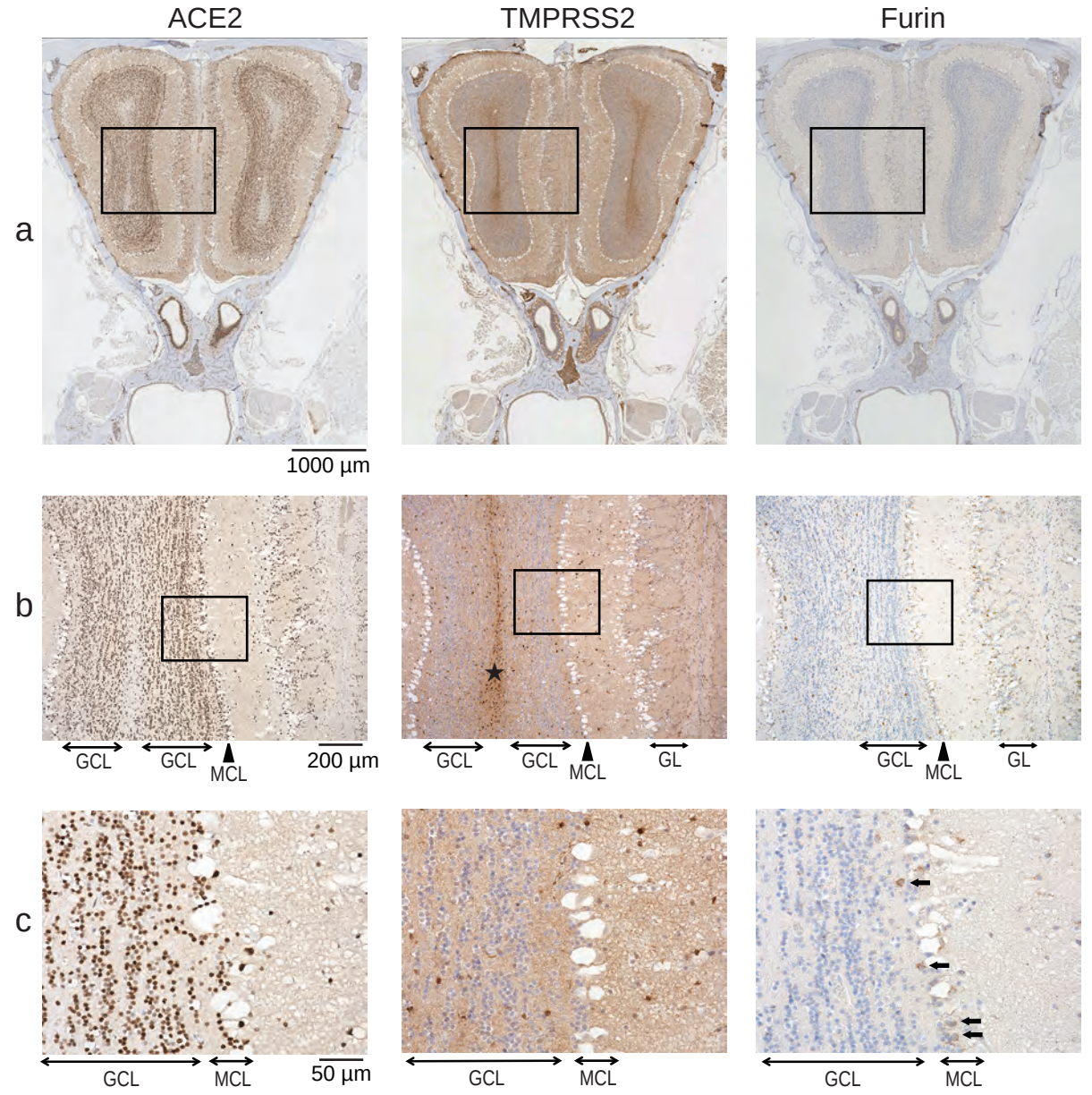

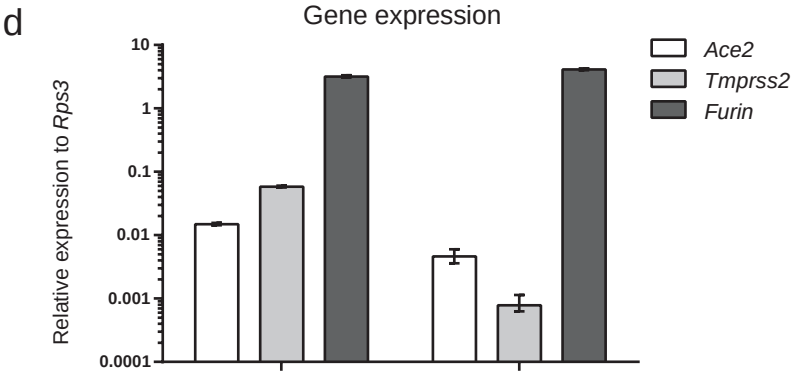

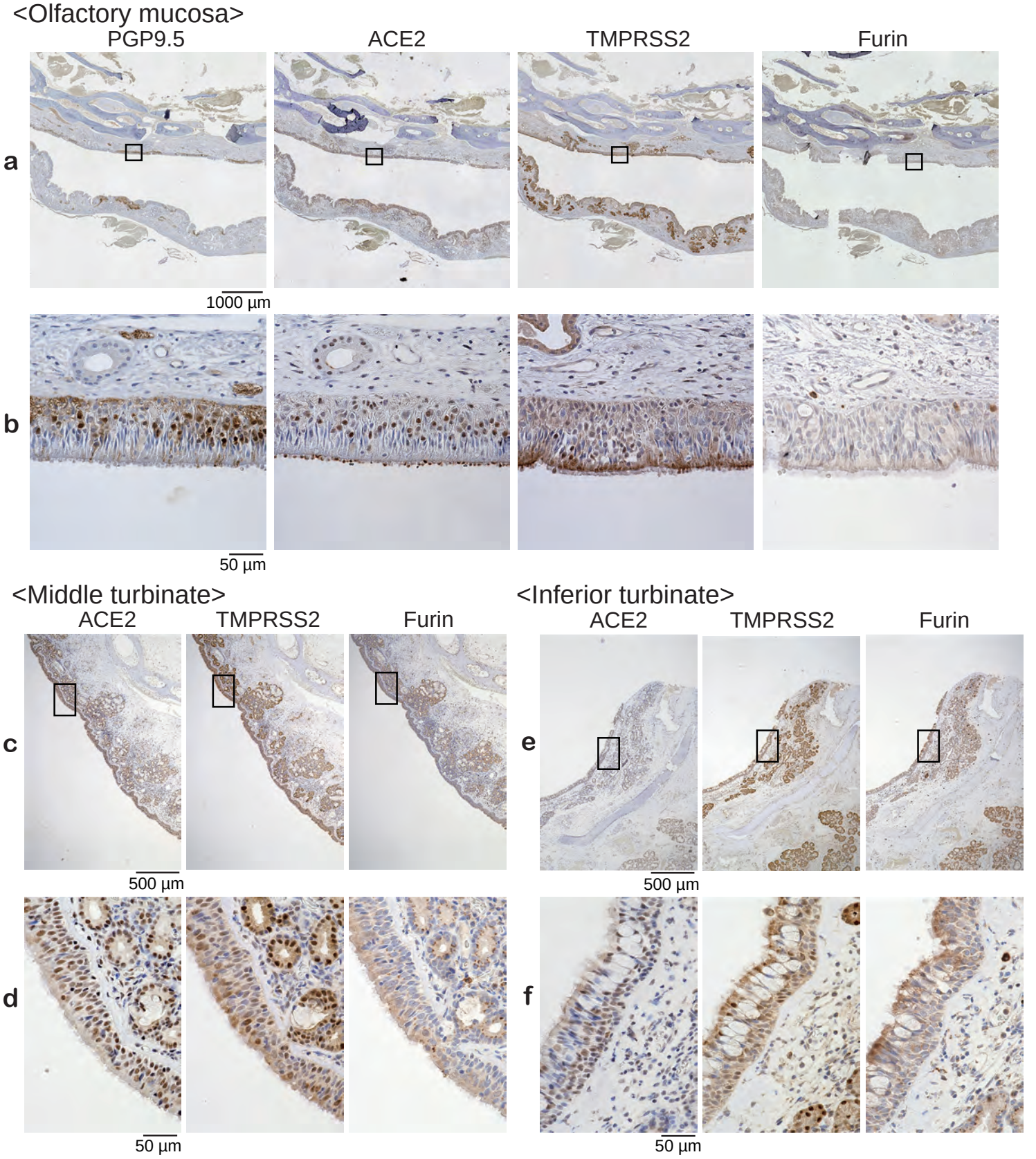
<Olfactory mucosa>
PGP9.5
ACE2
TMPRSS2
Furin
a
1000 µm
b
50 µm
<Middle turbinate>
ACE2
TMPRSS2
Furin
c
500 µm
d
50 µm
<Inferior turbinate>
ACE2
TMPRSS2
Furin
e
500 µm
f
50 µm