Intraperitoneal oil application causes local inflammation with depletion of resident peritoneal macrophages

Elisenda Alsina-Sanchis[1], Ronja Mülfarth[1], Iris Moll[1], Carolin Mogler[2], Juan Rodriguez-Vita[1,*], Andreas Fischer[1,3,4,*]

[1] Division Vascular Signaling and Cancer (A270), German Cancer Research Center (DKFZ), 69120 Heidelberg, Germany.

[2] Institute of Pathology, Technical University of Munich, 81675 Munich, Germany.

[3] Department of Medicine I and Clinical Chemistry, University Hospital of Heidelberg, 69120 Heidelberg, Germany.

[4] European Center for Angioscience, Medical Faculty Mannheim, Heidelberg University, 68167 Mannheim, Germany.

*, These authors contributed equally to this work

Running title: Oil depletes resident peritoneal macrophages

Key words: oil; resolution of inflammation; peritoneum; thioglycolate; xanthogranuloma;

*** Correspondence:** Division of Vascular Signaling and Cancer, German Cancer Resersach Institute, Im Neuenheimer Feld 280, 69120 Heidelberg, Germany. Phone: +40 6221 4150. FAX: 06221 42 4159. Email: j.rodriguezvita@dkfz.de (J. Rodriguez-Vita) and a.fischer@dkfz.de (A. Fischer).

Funding sources: This work was funded by the Deutsche Forschungsgemeinschaft (DFG) project number 394046768 - SFB1366 projects C4 and Z2 (to A.F., C.M.), DFG project number 419966437 (to J.R.V.) and the Helmholtz Association (to A.F.).

Conflict of interest: The authors declare that they have no conflict of interest.

Abstract

Oil is frequently used as a solvent to inject lipophilic substances into the peritoneum of laboratory animals. Although mineral oil causes chronic peritoneal inflammation, little is known whether other oils are better suited. Here we show that olive, peanut, corn or mineral oil causes xanthogranulomatous inflammation with depletion of resident peritoneal macrophages. However, there were striking differences in the severity of the inflammatory response. Peanut and mineral oil caused severe chronic inflammation with persistent neutrophil and monocyte recruitment, expansion of the vasculature and fibrosis. Corn and olive oil provoked no or only mild signs of chronic inflammation. Mechanistically, the vegetal oils were taken up by macrophages leading to foam cell formation and induction of cell death. Olive oil triggered caspase-3 cleavage and apoptosis, which facilitates the resolution of inflammation. Peanut oil and, to a lesser degree, corn oil triggered caspase-1 activation and macrophage pyroptosis, which impairs the resolution of inflammation. As such, intraperitoneal oil administration can interfere with the outcome of subsequent experiments. As a proof-of-principle, intraperitoneal peanut oil injection was compared to its oral delivery in a thioglycolate-induced peritonitis model. The chronic peritoneal inflammation due to peanut oil injection impeded the proper recruitment of macrophages and the resolution of inflammation in this peritonitis model. In summary, the data indicate that it is advisable to deliver lipophilic substances like tamoxifen by oral gavage instead of intraperitoneal injection.

Introduction

Oil is frequently used as solvent in animal research. For instance, inducible gene recombination using the Cre-ERT2 -loxP system requires administration of tamoxifen which is usually dissolved in olive, peanut, corn or mineral oil. The oil solution is administered orally or by intraperitoneal injection (*i.p.*) (1, 2). Also, in a liver fibrosis model carbon tetrachloride (CCl_4) is delivered by *i.p.* injection in oil, inhalation or oral gavage (3). Interestingly, *i.p.* injection generates stronger liver fibrosis when compared with the other two administration methods (4),

raising the question whether CCl_4 or its solvent act locally within the peritoneum. Indeed, *i.p.* injection of mineral oil causes chronic inflammation (5-9). Also, subcutaneous injection of olive oil can cause lipogranuloma, a granulomatous inflammatory soft tissue reaction (10).

Therefore, it can be assumed that any experimental immune cell analysis within the peritoneal cavity would be strongly affected by oil. It is surprising how little is known about the peritoneal immune cell reaction towards oil and comparative studies of different oils are missing to our knowledge.

Peritoneal inflammation can be divided into the initiation and resolution phase. Pathogens trigger infiltration of neutrophils, which phagocytose pathogens, clear apoptotic cells and recruit monocytes from the blood stream into the peritoneal fluid. Recruited monocytes eliminate dying neutrophils and differentiate into monocyte-derived macrophages (11). This is important, as the number of resident peritoneal macrophages, which are derived from embryonic progenitors and have self-renewal capacity (12), get strongly decreased as a result of the so-called “macrophage disappearance reaction” (13). As such, resident peritoneal $CD11b^+$ macrophages, expressing high F4/80 levels ($F4/80^{hi}$) get replaced by monocyte-derived $CD11b^+$ macrophages, expressing low F4/80 levels ($F4/80^{low}$) on the membrane (12, 14, 15). Subsequently, monocyte-derived macrophages increase surface expression of F4/80 from a low to an intermediate level ($F4/80^{int}$) to initiate the resolution phase (16).

The switch from inflammatory to resolving macrophages is triggered by phagocytosis of apoptotic cells. Deficiency in this phagocytic process leads to chronic inflammation (17). For instance in atherosclerotic plaques, macrophages take up excessive amounts of lipids and become foam cells, which cannot initiate the resolution phase, perpetuating further neutrophil and monocytes infiltration (18).

The aim of this study was to analyze how the most commonly used oils in animal research affect the myeloid cells within the peritoneum and whether this would diminish their capability to resolve the peritoneal inflammation.

Materials and methods

Animal models

The study was approved by institutional and regional animal research committees. All animal procedures were in accordance with institutional guidelines and performed according to the guidelines of the local institution and the local government. Female C57BL/6 mice were group-housed under specific pathogen-free barrier conditions.

Administration of peanut (P2144, Sigma-Aldrich, St. Louis, USA), corn (C8267, Sigma- Aldrich, St. Louis, USA), olive (88631, Carl Roth, Germany), mineral oil (HP50.2, Carl Roth, Germany) or 0,9% sterile NaCl (Braun, Germany) in 8 to 12-week-old randomized mice was performed by daily *i.p.* injection of 100 µl for 5 consecutive days or by oral gavage of peanut oil once with 100 µl. After three weeks mice were euthanized. For peritoneal lavage, 5 ml of cold PBS (Gibco/Thermo Fisher Scientific, NY, USA) was injected *i.p.* after a careful massage to mobilize cells, peritoneal fluid was collected. Cells were isolated by centrifugation (5 min, 200 g) and suspended in 1 ml of PBS.

8 to 12-week-old randomized mice were euthanized and administrated with peanut, olive, corn and mineral oil. After 5 minutes the peritoneal lavage was collected.

Three weeks after oil treatment, mice were *i.p.* injected with thioglycolate (2 mg in 1 ml H_2O; B2551, Sigma Aldrich, St. Louis, USA). After 24 or 72 hours mice were sacrificed and peritoneal lavage collected. All groups were randomized.

Immunofluorescence and tissue histology

Histological analysis was performed on formalin-fixed paraffin-embedded sections (3 µm). Sections were deparaffinized and rehydrated. For hematoxylin-eosin (H&E) and Sirius Red (Dianova, Germany) staining, sections were processed according to standard protocols. For myeloid cell staining, antigen retrieval at pH 6 with citrate buffer and the primary antibody rabbit anti-mouse CD11b (1:200) (ab133357, Abcam, Cambridge, MA, USA) and antigen retrieval

105 with 1:20 proteinase K/TE buffer and rat anti-mouse F4/80 (1:100) (T-2006, Dianova,
106 Germany) incubated at 4°C overnight. After washing, sections were incubated with secondary
107 antibodies coupled with HRP (1:200) (DAKO, Agilent Technologies, Santa Clara, CA, USA) for
108 one hour at room temperature. For immunofluorescence staining, antigen retrieval at pH 9 was
109 performed using citrate buffer and sections were incubated with the primary antibody rabbit
110 anti-mouse CD31 (1:50) (ab28364, Abcam, Cambridge, MA, USA) at 4°C overnight. After
111 washing, sections were incubated with secondary antibody (1:200) goat anti-rabbit Alexa
112 Fluor-647 (A21245, Life Technologies/Thermo Fisher Scientific, NY, USA) for 1 hour at room
113 temperature. H&E images were obtained with slide scanner (Zeiss Axio Sacn.Z1, Carl Zeiss,
114 Germany). CD11b images were obtained with widefield microscope (Zeiss Axioplan, Carl
115 Zeiss, Germany). All images were processed with ZENblue software (Carl Zeiss, Germany).
116 Immunofluorescence was imaged at the confocal (LSM 700, Carl Zeiss, Germany) microscope
117 with ZENblack software (Carl Zeiss, Germany). Sections of seven Z-stacks per omentum and
118 mesentery and three random fluorescence images per slide were taken. Numbers of CD31
119 positive vessels per view field and lipid droplet size from H&E images were counted with
120 ImageJ software (NIH, Bethesda, MD, USA).

121

122 **Oil Red O staining**

123 Peritoneal lavage was plated into one well of a 6-well plate on top of coverslips and incubated
124 for 30 min with Dulbecco's modified Eagle's medium (DMEM) (Gibco/ Thermo Fisher Scientific,
125 NY, USA). Afterwards non-adherent cells were removed by careful washing three times with
126 PBS. J774A.1 cells cultured in DMEM with 10% fetal calf serum (Biochrom, UK) were seeded
127 into 12-well plates on coverslips and treated with 100 µl oil in 1 ml medium for four hours. Cells
128 on coverslips were stained with Oil Red O (O0625, Sigma-Aldrich) following the protocol
129 published elsewhere (19) and counterstained with hematoxylin. Images were obtained with
130 widefield microscope (Zeiss Axioplan Carl Zeiss, Germany).

131

132 **Flow cytometry**

133 Cells obtained from peritoneal lavage were washed and erythrocytes lysed with ACK lysis
134 buffer (Gibco/Thermo Fisher Scientific, NY, USA). Cells were suspended at approximately 10^6
135 cells/ml in PBS with 2% FCS. Cell suspensions were incubated with the different fluorophore-
136 coupled primary antibodies for 20 minutes on ice. These antibodies were used: CD45
137 (552848), CD11b (552850), CD19 (560375), Ly6G (560600), Ly6C (560594) and F4/80-like
138 (564227) all from BD Biosciences (Bedford, MA, USA), CD3 (100203) and F4/80 (123128)
139 from BioLegend (St. Diego, CA, USA) and Tim4 (12-5866-82, Life Technologies/Thermo
140 Fisher Scientific, NY, USA). Concentration of the different antibodies was determined by
141 titration. Flow cytometer results in percentage were extrapolated to the total amount of cells
142 obtained from the previous cell counting.

143

144 **Western Blot analysis**

145 Cell lysates were separated by SDS-PAGE and proteins blotted on nitrocellulose membranes.
146 Membranes were blocked with 5% skim milk in TBS with 1% Tween-20. The following primary
147 antibodies were used: CD36 (ab124515), VCP (ab11433) from Abcam (Cambridge, MA, USA),
148 ABCG1 (NB400-132SS, Novus Biologicals, CO, USA), Cleaved-Caspase 3 (Asp175; 9664S),
149 Arginase-1 (D4E3M™; 93668S) from Cell Signaling (Danvers, MA, USA) and Caspase 1
150 (14F468; sc-56036, Santa Cruz Technologies, Dallas, TX, USA). Primary antibodies were
151 incubated overnight at 4°C and appropriate HRP-conjugated secondary antibodies (DAKO,
152 Agilent Technologies, Santa Clara, CA, USA) for 1 hour at room temperature.
153 Chemiluminescence was detected by Pierce ECL Western Blotting Substrate (Thermo Fisher
154 Scientific, NY, USA) and ChemiDoc imaging system (Biorad, Hercules, CA, USA) and
155 quantified with Image Lab 3.0 software (Biorad, Hercules, CA, USA).

156

157 **Quantitative PCR**

158 RNA was isolated using the innuPREP RNA Mini kit (Analytik Jena, Germany). cDNA was
159 synthesized with the High-Capacity cDNA Reverse Transcription Kit (Applied Biosystems). The
160 cDNA was applied to qPCR using the POWER SYBR Green Master Mix (Applied Biosystems).
161 Fold changes were assessed by $2^{-\Delta\Delta Ct}$ method and normalized with the *CPH* gene. The
162 following primers were used for qPCR: CD36 forward GCAAAACGACTGCAGGTCAA and
163 reverse GGCCATCTCTACCATGCCAA, ABCG1 forward CTTTCCTACTCTGTACCCGAGG
164 and reverse CGGGGCATTCCATTGATAAGG, IL10 forward GCATGGCCCAGAAATCAAGG
165 and reverse GAGAAATCGATGACAGCGCC and CPH forward ATGGTCAACCCCACCGTG
166 and reverse TTCTTGCTGTCTTTGGAACTTTGTC.

167

168 **Cell death detection**

169 J774A.1 cells were plated at $5x10^5$ cells per well into a 12 well-plate with 100 µl of the different
170 oils in 1 ml medium and incubated for four hours. Afterwards, supernatant and attached cells
171 were collected and stained with Annexin V-FITC (640905, BioLegend, St. Diego, CA, USA)
172 and PI (Cayman Chemical, USA) and incubated for 15 minutes on ice. After washing, cells
173 were immediately analyzed by flow cytometry.

174 An apoptosis/necrosis immunofluorescence assay kit (ab176749, Abcam, Cambridge, MA,
175 USA,) was used for detection of necrosis or apoptosis cell death. J774A.1 cells were plated at
176 $5x10^5$ cells/well into a 24 well-plate on top of a coverslip. To each well, 50 µl of oil was added
177 in a final volume of 1 ml medium and incubated for two hours. Afterwards, the staining was
178 performed following the manufacturer's protocol. Three fluorescence images of each channel
179 at fixed positions of each triplicate were collected at the wide-field Cell Observer microscope
180 (Carl Zeiss, Germany) with ZENblue software (Carl Zeiss, Germany). FIJI software was
181 employed for the quantification of positive cells of each channel per field.

182 For determination of lactate dehydrogenase activity in the cell supernatant, J774A.1 cells were
183 plated at $5x10^4$ cells/well into a 96 well-plate with 100 µl of medium containing 10 µl oil in
184 triplicates and incubated for 2 hours. Oleic acid (O1008, Sigma- Aldrich, St. Louis, USA),

185 diluted in absolute ETOH was added to the medium or mixed with 5 µl peanut oil when
186 indicated. Then, levels of LDH were detected using the LDH-Cytotoxicity Assay Kit (Ab65393,
187 Abcam, Cambridge, MA, USA) following the manufacturer's protocol.

188

189 **Statistical analysis**

190 GraphPad Prism 8 (GraphPad Software, San Diego, CA, USA) was used to generate graphs
191 and for statistical analysis. Statistical significance was calculated using one-way or two-way
192 ANOVA as indicated in the figure legends. Data sets are presented as mean ± SD. $P < 0.05$
193 was considered as significant.

194

195

196 **Results**

197 **Macroscopic changes upon intraperitoneal oil injection**

198 Peanut, olive, corn and mineral oil were injected into the peritoneum (*i.p.*) of adult mice
199 for five consecutive days. This mimics a typical protocol for delivering tamoxifen to induce gene
200 recombination in transgenic mice expressing Cre^{ERT2} recombinase (2). Analysis was done
201 three weeks later. As controls, untreated mice and mice treated with peanut oil by oral gavage
202 were used (**Figure 1A**).

203 In contrast to untreated mice or those receiving oil by oral gavage, the *i.p.* injected mice
204 showed macroscopically visible alterations in the peritoneal cavity. Peanut oil was still visible
205 as oil droplets (**Figure 1B**), whereas this was not the case for the other oils. White nodules, in
206 the size of <3 mm, were visible on the surface of liver, diaphragm or colon in mice receiving
207 peanut, olive and mineral oil *i.p.* but not corn oil. The nodules formed due to olive oil treatment
208 were only loosely attached to the organ surfaces, whereas the nodules in mice that were *i.p.*
209 injected with peanut or mineral oil were firmly attached to the liver surface (**Figure 1B**).

210

211 **Xanthogranulomatous inflammation in the peritoneum upon oil injection**

212 Histological analysis revealed no pathological changes in liver (**Figure 1C**) and spleen
213 (**Supplementary Figure 1A**) of mice that received *i.p.* injection of oil. The nodules that were
214 firmly attached to the liver surface in mice treated with peanut or mineral oil could be classified
215 as xanthogranulomas with foamy macrophages and mixed inflammatory background (**Figure**
216 **1C**).

217 Next, we examined the greater omentum. The greater omentum is an organ that filters
218 excessive fluid from the abdominal cavity, senses microorganisms or damaged cells, initiates
219 immune responses and supports repair of damaged organs (20). Omenta of mice treated with
220 oral gavage were indistinguishable from those of untreated mice. However, omenta of mice
221 that received *i.p.* oil injections showed a remarkable change in morphology. The omenta were
222 swollen, darker and had enlarged blood vessels, particularly in mice treated with peanut and
223 mineral oil (**Figure 2A**). Histological analysis revealed that lipid droplet size in adipocytes was
224 reduced in mice treated *i.p.* with any of the different oils. Again, the changes were most
225 pronounced in mice injected with peanut and mineral oil (**Figures 2B and 2F**).

226 Immunohistochemical analysis of CD31-positive endothelial cells revealed an increase
227 in vessel density in the omenta after oil injection. It was strongly increased in the case of peanut
228 and mineral oil but mild in olive and corn oil-treated mice (**Figure 2C and 2G**). In addition,
229 higher numbers of $CD11b^+$ myeloid cells were present in all four oil-treated mice, but again,
230 peanut and mineral oil-treated mice had highest infiltration rates (**Figure 2D**).

231 So far, the described changes are indicative of peritoneal inflammation upon local oil
232 injection. Prolonged inflammation may impede tissue healing resulting in organ fibrosis.
233 Indeed, Sirius Red staining revealed an increase in collagen deposition, a typical sign of
234 fibrosis, in the greater omentum of *i.p.* oil-injected mice. Such fibrotic changes were in
235 particular observed in mice treated with peanut and mineral oil (**Figures 2E**).

236 Histopathological scoring of the inflammation grade in the greater omentum by H&E
237 staining was based on the granularity of the tissue, the presence of foamy macrophages or

238 other inflammatory cells, multinucleated giant cells, fibrosis or necrosis with a score from 0 (no
239 inflammation) to 3 (severe chronic inflammation). This showed that *i.p.* injection of all four oils
240 causes xanthogranulomatous inflammation of the omentum with highest scores for mineral
241 and peanut oil. (**Figure 2H**).

242 Similar data were obtained during the analysis of mesentery. The almost transparent
243 membrane became opaque in mice treated *i.p.* with oil. The strongest changes were observed
244 in mice treated with peanut and mineral oil (**Figure 3A**). Lipid droplets in adipocytes of
245 mesentery from mineral oil-treated mice were much smaller compared to controls. Such
246 changes were also observed but to a lesser extent in mice injected *i.p.* with peanut oil, whereas
247 the effects of olive and corn oil were mild (**Figures 3B and 3F**). The number of blood vessels
248 were increased in peanut and mineral oil-treated mice. We detected increased numbers of
249 $CD11b^+$ myeloid cells in the mesentery of olive, corn, peanut and to the maximum extent in
250 mineral oil-treated mice (**Figure 3D**). There was mild fibrosis in the mesentery of mice treated
251 with peanut oil and severe fibrosis in mice that had received mineral oil (**Figure 3E**).
252 Histopathological scoring of the inflammation grade revealed that peanut and mineral oil, but
253 not olive and corn oil, generated xanthogranulomatous inflammation (**Figure 3H**).

254 In summary, the histopathological analysis revealed that mineral oil and peanut oil
255 induce a strong xanthogranulomatous inflammatory response in the peritoneum. Olive and
256 corn oils also induce inflammation, but to a much lesser degree.

257

258 **Intraperitoneal oil injection causes myeloid cell infiltration into the peritoneum**

259 To further analyze the immune response, peritoneal lavage was obtained three weeks
260 after the *i.p.* injection. Flow cytometry revealed that the total cell number in the peritoneal
261 lavage was significantly increased in mice treated with either peanut or mineral oil compared
262 to untreated animals (**Figure 4A**). The vast majority of the cell population were myeloid cells
263 ($CD45^+CD19^-CD11b^+$). Peanut and mineral oil increased the total number of myeloid cells,

whereas olive and corn oil had no significant effect (**Figure 4B and Supplementary Figure 2A**).

We also observed that oil injection led to a decrease in the number of B ($CD45^+CD19^+CD3^-$) and T lymphocytes ($CD45^+CD19^-CD3^+$) (**Supplementary Figure 2B**). This was expected as during peritoneal inflammation lymphocytes migrate from the peritoneal fluid into the greater omentum (21, 22).

Peanut and mineral oil increases neutrophil and monocyte recruitment

A more detailed evaluation of the myeloid population revealed that peanut and mineral oil injection strongly increased the presence of neutrophils ($CD45^+CD11b^+Ly6G^+Ly6C^{int}$) and recruited monocytes ($CD45^+CD11b^+Ly6G^-Ly6C^+$) in the peritoneal fluid. Neutrophils and infiltrated monocytes were almost absent in peritoneal lavage derived from untreated mice or mice treated with olive oil, corn oil or oral gavage (**Figures 4C, D and E**).

Importantly, the injection itself did not cause such alterations. Injection of 0.9% NaCl did not lead to macroscopic or histological changes, nor to significant changes in total number of cells in peritoneal fluid or changes within the myeloid cell compartment (**Supplementary Figure 3A-G**).

Oil injection leads to a severe reduction of resident peritoneal macrophages

During inflammation, neutrophils are the first cells being recruited to clear apoptotic cells or eliminate pathogens. Afterwards, monocytes reach the inflamed zone to eliminate dying neutrophils and to differentiate into macrophages. The latter is in particular essential when resident macrophages are eradicated. Therefore, we next examined the macrophage population within the peritoneum. The total macrophage ($CD45^+CD11b^+F4/80^+$) cell number was not significantly changed in peritoneal lavage of mice treated *i.p.* with oil compared to the untreated mice or to those which received oil by oral gavage (**Figure 4F**).

290 We further characterized the F4/80 population by analyzing the amount of Tim4 on the
291 cell surface as Tim4 can be employed as a marker to differentiate long-term ($F4/80^{+}Tim4^{+}$)
292 from newly recruited ($F4/80^{+}Tim4^{-}$) resident macrophages (23). This revealed that all four oils
293 led to a dramatic decrease in long-term resident ($F4/80^{+}Tim4^{+}$) macrophages and a
294 replacement by recently recruited ($F4/80^{+}Tim4^{-}$) macrophages (**Figure 4G**).

295 The level of F4/80 on the macrophage cell membrane varies depending on the
296 differentiation stage (15). In this regard, resident macrophages express high levels of F4/80,
297 while newly recruited monocyte-derived macrophages express low to intermediate levels
298 ($F4/80^{int}$). Peanut oil injection led to a strong decrease in resident $F4/80^{hi}$ macrophage numbers
299 (**Figure 4H**). Mineral oil showed a similar but not significant trend, whereas olive oil and corn
300 oil did not alter the proportion of $F4/80^{hi}$ macrophages.

301 The full resolution of inflammation is carried out by $F4/80^{int}$ macrophages (16). Analysis
302 of this cell population revealed that only the *i.p.* injection of olive oil led to a significant increase
303 in $F4/80^{int}$ macrophages at this time point (**Figure 4I**).

304 Collectively, the data imply that injection of any oil into the peritoneum triggers an
305 inflammatory response in which resident macrophages get replaced by monocyte-derived
306 ones. However, the resolution of inflammation depends on the type of oil, with olive oil and
307 corn oil (to a lesser extent) showing signs of resolution.

308

309 **Oil injection induces foam cell formation**

310 Monocytes and macrophages can take up excessive amounts of lipids (24). Therefore,
311 we examined lipid uptake in macrophages upon oil injection. Peritoneal lavage was performed
312 three weeks after *i.p.* oil injection. Adherent peritoneal macrophages were stained with Oil Red
313 O, which marks lipids and neutral triglycerides. Macrophages derived from the control mice
314 were not stained by Oil Red O while peritoneal macrophages derived from mice injected *i.p.*
315 with peanut oil contained multiple large lipid droplets. Fewer amounts were detected in the

316 macrophages from the olive oil and corn oil group, whereas the macrophages of the mineral
317 oil group contained almost no detectable lipid droplets (**Figure 5A**).

318 To further evaluate this, we tested lipid uptake in the J774A.1 macrophage cell line.
319 J774A.1 macrophages took up lipids when in contact with olive, corn and peanut oil, but not
320 mineral oil, suggesting that the effect of this oil is independent of the cellular lipid uptake.

321 In atherosclerotic plaques, monocyte-derived macrophages endocytose lipids such as
322 oxidized LDL and become foam cells. During this transition, an upregulation of the fatty acid
323 translocase (CD36) expression and downregulation of the cholesterol transporter ABCG1 is
324 evident (25). J774A.1 macrophages showed the same changes in gene expression when
325 cultured for four hours in the presence of vegetal oils (**Figure 5C-F**).

326 In summary, these results indicate that peanut, olive and corn, but not mineral oil *i.p.*
327 injection leads to foam cell formation.

328

329 **Peritoneal macrophage cell death after exposure to different oils**

330 Lipoprotein uptake can cause macrophage cell death (26). Therefore, we evaluated
331 whether peritoneal macrophage cell death is induced by the four different oils. Mice were
332 injected once *i.p.* with 100 µl oil and five minutes later peritoneal cells were harvested and
333 subjected to flow cytometry (**Figure 6A**). This revealed that compared to untreated mice there
334 was approximately a 50% decrease in $CD11b^{+}F4/80^{+}$ macrophages in the peritoneum of mice
335 that received any of the oils (**Figure 6B**). There was a 5-10% decrease in the fraction of live
336 cells (Annexin V^{-}, PI^{-}) and an equivalent increase of necrotic (PI^{+}), apoptotic (Annexin V^{+}) and
337 Annexin $V^{+}PI^{+}$ cells in the peritoneal lavage of mice that received peanut or olive oil (**Figure**
338 **6C**). The Annexin $V^{+}PI^{+}$ double-positive population can be the result of both, apoptosis and
339 necrosis (27). The increase in cell death was milder in the presence of corn oil, whereas in
340 mineral oil injected mice cell death was not different as compared to untreated mice,
341 suggesting that the mechanism for mineral oil-induced injury is different (**Figure 6C**).

342 To further analyze cell death in macrophages, J774A.1 cells were treated with different
343 oils. All three vegetal oils increased cell death. In this case, the increase in Annexin V^+, PI^+
344 double positive cells was present for olive, corn and peanut oil. Moreover, necrotic cell death
345 (Annexin V^-, PI^+) was also increased in the presence of peanut and corn oil (**Figure 6D**).

346 In order to further clarify whether macrophages die by apoptosis or necrosis we
347 incubated J774A.1 cells with different oils to determine apoptotic and necrotic cell death. There
348 was an increase in apoptotic cells in the case of incubation with olive oil and a mild increase
349 in the presence of corn oil. 7-AAD incorporation (necrosis) was increased upon treatment with
350 peanut and to a lesser extent upon treatment with corn and mineral oil (**Figure 6E-G**).

351 Another way to detect necrotic cell death is measuring lactate dehydrogenase (LDH)
352 activity in the cell culture supernatant. Membrane disruption of necrotic cells allows release of
353 cytosolic LDH. Peanut oil caused pronounced release of LDH. There was also LDH release
354 from macrophages treated with olive and corn oil, however to a lesser degree (**Figure 6H**).
355 Interestingly, the LDH release upon treatment with peanut oil could be strongly decreased by
356 supplementing peanut oil with the polyunsaturated oleic acid (**Supplemental Figure 4A**).

357 We corroborated the different mechanisms of cell death further and observed that only
358 treatment with olive oil induces cleavage of caspase-3 in macrophages, a major effector of
359 apoptosis (**Figure 6J**). On the other hand, peanut oil-treated macrophages showed an
360 increase in active p20 caspase-1, which is a marker for pyroptosis (**Figure 6J-K**), which has
361 similar features as necrosis but is driven by caspase-1 activation (28). In contrast, olive oil-
362 treated macrophages showed increased levels of IL10 and Arginase-1 indicating an anti-
363 inflammatory switch towards resolution of inflammation (**Figure 6I-K**).

364 These results suggest that macrophages in contact with olive oil die by apoptosis,
365 which facilitates the subsequent resolution of the inflammation, whereas peanut oil induces
366 macrophage pyroptosis, which impairs the resolution of inflammation.

367

368 ***I.p.* injection of peanut oil impairs the resolution of inflammation in a peritonitis model**

369 The results presented indicate that *i.p.* oil injection leads to a dramatic change in the
370 peritoneal immune cell composition. Chronic inflammation is induced by peanut oil and this
371 would potentially alter the outcome of experiments executed subsequently. One such example
372 could be a peritonitis experiment in transgenic mice that had been injected *i.p.* before with
373 tamoxifen in peanut oil to induce gene recombination. We decided to test this in experimental
374 peritonitis model, in which mice received peanut oil by *i.p.* injection or by oral gavage as control.
375 Three weeks later, thioglycolate was applied to mimic bacterial peritonitis (**Figure 7A**).

376 It is known that thioglycolate initially induces a massive neutrophil and monocyte
377 infiltration, followed by differentiation into macrophages that resolve inflammation by clearance
378 of apoptotic cells (16). Consistently, mice that had received peanut oil by oral gavage had
379 approximately 50% increase in myeloid cell numbers 24 and 72 hours after thioglycolate
380 injection. However, mice pretreated *i.p.* with oil, already had high numbers of $CD45^{+}CD11b^{+}$
381 myeloid cells in peritoneal fluid at baseline and this was not further increased upon
382 thioglycolate administration (**Figure 7C**). In mice treated by oral gavage, the number of
383 monocytes and neutrophils in peritoneal fluid increased strongly upon thioglycolate injection
384 and subsequently returned below baseline. This suggests that the first inflammatory response
385 by these cells had already been cleared. However, in mice that had been *i.p.* injected with
386 peanut oil there was a higher proportion of monocytes and neutrophils already under basal
387 conditions, which was maintained after thioglycolate administration (**Figure 7B and D-E**).

388 Mice treated orally showed the expected increase in $CD45^{+}CD11b^{+}F4/80^{+}$
389 macrophages 72 hours after thioglycolate injection. However, mice that had been injected *i.p.*
390 with peanut oil had only few macrophages present in the peritoneum (approximately 12% of
391 all myeloid cells) and these increased only marginally (**Figure 7F**). Orally treated mice showed
392 disappearance of $F4/80^{hi}$ macrophages 24 hours after thioglycolate administration and
393 subsequent recovery, which was accompanied by an increase of $F4/80^{int}$ macrophages
394 (**Figure 7G-H**). This suggests that resident macrophages disappear after thioglycolate
395 administration and get replaced by monocyte-derived macrophages as the inflammation
396 resolves. Yet, in mice that received peanut oil *i.p.* there were only few $F4/80^{hi}$ macrophages at

397 baseline and there was only a minor increase in F4/80^{int} macrophages (**Figure 7G-H**). The
398 lower presence of F4/80^{int} macrophages, together with the continuous influx of monocytes and
399 neutrophils, suggests that resolution of inflammation cannot take place. As such, *i.p.* peanut
400 oil injection leads to a dramatic change in the myeloid cell composition of the peritoneum that
401 affects the outcome of subsequent experiments.

402

403 **Discussion**

404 Animal experimentation requires careful planning and analysis to allow reproducibility
405 and the possibility to translate basic research into successful clinical trials. Oil injection is
406 frequently performed in animal research, in particular to deliver tamoxifen for inducible gene
407 recombination (1, 2, 4). Oil is considered to be safe and non-toxic. However, few studies
408 reported peritoneal inflammation after subcutaneous or intraperitoneal oil injection (6, 10, 29).
409 To our knowledge, little is still known about changes in the immune cell composition and related
410 reactions within the peritoneum upon intraperitoneal oil delivery. This work demonstrates that
411 intraperitoneal injection of four different oils causes inflammation, foam cell formation and
412 depletion of resident macrophages. However, the severity of inflammation strongly depends
413 on the type of oil.

414 Within the peritoneum, the omentum plays a major role in recognition and
415 encapsulation of pathogens (30). During this process, it expands, a feature which we observed
416 after injection of the different oils. Interestingly, the applied oils were not completely resorbed
417 even three weeks after injection into the peritoneal cavity. In particular larger amounts of
418 peanut oil were still visible in the peritoneal fluid. The failed clearance can be assumed to
419 prolong the phase of acute inflammation (17). Consistently, chronic xanthogranulomatous
420 inflammation and fibrosis were observed, particularly upon peanut and mineral oil treatment.
421 Myeloid cell infiltration and fibrosis were more severe in the omentum compared to the
422 mesentery. This is consistent with the fact that the omentum is an immunological niche and

423 the first organ to react against pathogens, but only when this inflammation becomes chronic it
424 starts to affect the mesentery (20).

425 Mechanistically, the type of oil-induced macrophage cell death appears to determine
426 whether inflammation gets resolved. For successful resolution of the inflammation, there is the
427 need of efferocytosis, where macrophages engulf apoptotic cells (31). Non-resolving
428 inflammation contributes substantially to the progression of atherosclerotic plaques and other
429 chronic inflammatory diseases (18, 32, 33). Our data indicate that macrophages in contact with
430 olive oil die by apoptosis, which facilitates efferocytosis-mediated resolution of inflammation.
431 Conversely, peanut oil induces pyroptosis of macrophages. Excessive pyroptosis impairs the
432 resolution of inflammation (34, 35). As such, peanut oil injection results in chronic peritoneal
433 inflammation, whereas olive oil induces macrophage apoptosis, followed by efferocytosis and
434 initiation of the resolution phase.

435 At the cellular level, all three vegetal oils were taken up by macrophages and caused
436 foam cell formation. This change in the expression pattern has been observed in peritoneal
437 macrophages isolated from obese mice, and blood monocytes from patients suffering from
438 severe atherosclerosis (36-38). In principle, one could even use intraperitoneal peanut oil
439 injection as a fast model to obtain viable foam cells for *in vitro* experiments. Future research
440 will determine the potential of this model.

441 In conclusion, our study shows that intraperitoneal injection of different oils causes
442 peritoneal inflammation and depletion of resident peritoneal macrophages. Whereas olive oil
443 triggers macrophage apoptosis and resolution of inflammation, peanut oil induces pyroptosis
444 and chronic non-resolved inflammation. This has important consequences for animal
445 experiments. In a proof-of-principle approach, we demonstrated this in a thioglycolate-induced
446 peritonitis model after peanut oil injection. To overcome such limitations, it is advisable to
447 deliver lipophilic substances like tamoxifen by oral gavage instead of intraperitoneal injection.

448

449

Acknowledgements

This work was funded by the Deutsche Forschungsgemeinschaft (DFG) project number 394046768 - SFB1366 projects C4 and Z2 (to A.F., C.M.), DFG project number 419966437 (to J.R.V.) and the Helmholtz Association (to A.F.).

Conflict of interest

The authors declare that they have no conflict of interest.

References

1. Sauer B. Inducible gene targeting in mice using the Cre/lox system. Methods. 1998;14(4):381-92.
2. Feil S, Valtcheva N, Feil R. Inducible Cre mice. Methods Mol Biol. 2009;530:343-63.
3. Scholten D, Trebicka J, Liedtke C, Weiskirchen R. The carbon tetrachloride model in mice. Lab Anim. 2015;49(1 Suppl):4-11.
4. Yanguas SC, Cogliati B, Willebrords J, Maes M, Colle I, van den Bossche B, et al. Experimental models of liver fibrosis. Arch Toxicol. 2016;90(5):1025-48.
5. Anderson PN, Potter M. Induction of plasma cell tumours in BALB-c mice with 2,6,10,14-tetramethylpentadecane (pristane). Nature. 1969;222(5197):994-5.
6. Kuroda Y, Akaogi J, Nacionales DC, Wasdo SC, Szabo NJ, Reeves WH, et al. Distinctive patterns of autoimmune response induced by different types of mineral oil. Toxicol Sci. 2004;78(2):222-8.
7. Chen H, Liao D, Cain D, McLeod I, Ueda Y, Guan Z, et al. Distinct granuloma responses in C57BL/6J and BALB/cByJ mice in response to pristane. Int J Exp Pathol. 2010;91(5):460-71.
8. Nacionales DC, Kelly KM, Lee PY, Zhuang H, Li Y, Weinstein JS, et al. Type I interferon production by tertiary lymphoid tissue developing in response to 2,6,10,14-tetramethyl-pentadecane (pristane). Am J Pathol. 2006;168(4):1227-40.
9. Brand C, da Costa TP, Bernardes ES, Machado CM, Andrade LR, Chammas R, et al. Differential development of oil granulomas induced by pristane injection in galectin-3 deficient mice. BMC Immunol. 2015;16:68.

476 10. Ramot Y, Ben-Eliahu S, Kagan L, Ezov N, Nyska A. Subcutaneous and intraperitoneal
477 lipogranulomas following subcutaneous injection of olive oil in Sprague-Dawley rats. Toxicol
478 Pathol. 2009;37(7):882-6.
479 11. Prame Kumar K, Nicholls AJ, Wong CHY. Partners in crime: neutrophils and
480 monocytes/macrophages in inflammation and disease. Cell Tissue Res. 2018;371(3):551-65.
481 12. Schulz C, Gomez Perdiguero E, Chorro L, Szabo-Rogers H, Cagnard N, Kierdorf K, et al. A lineage of
482 myeloid cells independent of Myb and hematopoietic stem cells. Science. 2012;336(6077):86-90.
483 13. Barth MW, Hendrzak JA, Melnicoff MJ, Morahan PS. Review of the macrophage disappearance
484 reaction. J Leukoc Biol. 1995;57(3):361-7.
485 14. Sieweke MH, Allen JE. Beyond stem cells: self-renewal of differentiated macrophages. Science.
486 2013;342(6161):1242974.
487 15. Cassado Ados A, D'Imperio Lima MR, Bortoluci KR. Revisiting mouse peritoneal macrophages:
488 heterogeneity, development, and function. Front Immunol. 2015;6:225.
489 16. Gautier EL, Ivanov S, Lesnik P, Randolph GJ. Local apoptosis mediates clearance of macrophages
490 from resolving inflammation in mice. Blood. 2013;122(15):2714-22.
491 17. Lawrence T, Gilroy DW. Chronic inflammation: a failure of resolution? Int J Exp Pathol.
492 2007;88(2):85-94.
493 18. Kasikara C, Doran AC, Cai B, Tabas I. The role of non-resolving inflammation in atherosclerosis. J
494 Clin Invest. 2018;128(7):2713-23.
495 19. Xu S, Huang Y, Xie Y, Lan T, Le K, Chen J, et al. Evaluation of foam cell formation in cultured
496 macrophages: an improved method with Oil Red O staining and DiI-oxLDL uptake. Cytotechnology.
497 2010;62(5):473-81.
498 20. Meza-Perez S, Randall TD. Immunological Functions of the Omentum. Trends Immunol.
499 2017;38(7):526-36.
500 21. Carlow DA, Gold MR, Ziltener HJ. Lymphocytes in the peritoneum home to the omentum and are
501 activated by resident dendritic cells. J Immunol. 2009;183(2):1155-65.

502 22. Laurin LP, Brissette MJ, Lepage S, Cailhier JF. Regulation of experimental peritonitis: a complex
503 orchestration. Nephron Exp Nephrol. 2012;120(1):e41-6.
504 23. Bain CC, Hawley CA, Garner H, Scott CL, Schridde A, Steers NJ, et al. Long-lived self-renewing bone
505 marrow-derived macrophages displace embryo-derived cells to inhabit adult serous cavities. Nat
506 Commun. 2016;7:ncomms11852.
507 24. Remmerie A, Scott CL. Macrophages and lipid metabolism. Cell Immunol. 2018;330:27-42.
508 25. Rahaman SO, Lennon DJ, Febbraio M, Podrez EA, Hazen SL, Silverstein RL. A CD36-dependent
509 signaling cascade is necessary for macrophage foam cell formation. Cell Metab. 2006;4(3):211-21.
510 26. Seimon TA, Nadolski MJ, Liao X, Magallon J, Nguyen M, Feric NT, et al. Atherogenic lipids and
511 lipoproteins trigger CD36-TLR2-dependent apoptosis in macrophages undergoing endoplasmic
512 reticulum stress. Cell Metab. 2010;12(5):467-82.
513 27. Ormerod MG. The study of apoptotic cells by flow cytometry. Leukemia. 1998;12(7):1013-25.
514 28. Yuan J, Najafov A, Py BF. Roles of Caspases in Necrotic Cell Death. Cell. 2016;167(7):1693-704.
515 29. Hubbard JS, Chen PH, Boyd KL. Effects of Repeated Intraperitoneal Injection of Pharmaceutical-
516 grade and Nonpharmaceutical-grade Corn Oil in Female C57BL/6J Mice. J Am Assoc Lab Anim Sci.
517 2017;56(6):779-85.
518 30. Litbarg NO, Gudehithlu KP, Sethupathi P, Arruda JA, Dunea G, Singh AK. Activated omentum
519 becomes rich in factors that promote healing and tissue regeneration. Cell Tissue Res.
520 2007;328(3):487-97.
521 31. Boada-Romero E, Martinez J, Heckmann BL, Green DR. The clearance of dead cells by
522 efferocytosis. Nat Rev Mol Cell Biol. 2020.
523 32. Schrijvers DM, De Meyer GR, Kockx MM, Herman AG, Martinet W. Phagocytosis of apoptotic cells
524 by macrophages is impaired in atherosclerosis. Arterioscler Thromb Vasc Biol. 2005;25(6):1256-
525 61.
526 33. Schett G, Neurath MF. Resolution of chronic inflammatory disease: universal and tissue-specific
527 concepts. Nat Commun. 2018;9(1):3261.

528 34. Bergsbaken T, Fink SL, Cookson BT. Pyroptosis: host cell death and inflammation. Nat Rev
529 Microbiol. 2009;7(2):99-109.
530 35. Wu J, Lin S, Wan B, Velani B, Zhu Y. Pyroptosis in Liver Disease: New Insights into Disease
531 Mechanisms. Aging Dis. 2019;10(5):1094-108.
532 36. Mauldin JP, Srinivasan S, Mulya A, Gebre A, Parks JS, Daugherty A, et al. Reduction in ABCG1 in
533 Type 2 diabetic mice increases macrophage foam cell formation. J Biol Chem.
534 2006;281(30):21216-24.
535 37. Piechota M, Banaszewska A, Dudziak J, Slomczynski M, Plewa R. Highly upregulated expression of
536 CD36 and MSR1 in circulating monocytes of patients with acute coronary syndromes. Protein J.
537 2012;31(6):511-8.
538 38. Chistiakov DA, Melnichenko AA, Myasoedova VA, Grechko AV, Orekhov AN. Mechanisms of foam
539 cell formation in atherosclerosis. J Mol Med (Berl). 2017;95(11):1153-65.

Figure legends

Figure 1. Macroscopic changes in mice three weeks after *i.p.* oil injection. A. Schematic illustration of the *i.p.* or oral oil administration protocol. **B.** Representative images of the peritoneum. Black arrows indicate visible lipid droplets. White arrowheads mark nodules on the surface of organs. Scale bar, 3 mm. **C**. Representative microscopic images of liver sections stained with H&E. Xanthogranuloma on the liver surface in mice treated with peanut and mineral oil. Scale bar, 50µm.

Figure 2. Xanthogranulomatous inflammation in the omentum upon oil injection. **A**. Representative images of omenta from untreated mice and such that were treated with oil by *i.p.* injection or oral gavage. Analysis was performed three weeks after treatment. **B.** Representative confocal images of mesentery sections stained with H&E. Scale bar, 50 µm. **C**. Immunofluorescence microscopy to detect $CD31^+$ endothelial cells (white). Scale bar 20 µm. **D**. $CD11b^+$ myeloid cells. Scale bar, 100 µm. **E** Sirius Red staining to detect fibrosis. Scale bar, 100 µm. **F**. Lipid droplet size quantification from H&E images. Untreated micen=3, peanut oil n=4, olive oil n=3, corn oil n=5, mineral oil n=5 and oral gavage n=3. Bar graphs show mean ± SD, *, $p<0.05$ (one way ANOVA). **G**. Quantification of microvessel density. Olive oil n=4 and all other groups n=5. Bar graphs show mean ± SD, *, $p<0.05$ (one way ANOVA). **H**. Xanthogranulomatous inflammation score. 0: no inflammation to 3: very strong inflammation. All data represent n=5 mice, bar graphs show mean ± SD, *, $p<0.05$ (one way ANOVA).

Figure 3. Xanthogranulomatous inflammation in the mesentery upon peanut and mineral oil injection. A. Representative images of mesentery from untreated mice and such that were treated with oil by *i.p.* injection or oral gavage. Analysis was performed three weeks after treatment. **B.** Representative confocal images of mesentery sections stained with H&E. Scale bar, 50 µm. **C**. Immunofluorescence microscopy to detect $CD31^+$ endothelial cells (white). Scale bar, 20 µm **D**. $CD11b^+$ myeloid cells. Scale bar, 100 µm **E** Sirius Red staining to

28 detect fibrosis. Scale bar, 100 µm **F**. Lipid droplet size quantification from H&E images. n=3
29 mice. Bar graph shows mean ± SD, *, p<0.05 (one way ANOVA). **G**. Quantification of
30 microvessel density. n=5 mice. Bar graph shows mean ± SD, *, p<0.05 (one way ANOVA). **H**.
31 Xanthogranulomatous inflammation score. 0: no inflammation to 3: very strong inflammation.
32 Olive oil n=4 and all other groups n=5. Bar graph shows mean ± SD, *, p<0.05 (one way
33 ANOVA).

34

35 **Figure 4. Resident peritoneal macrophage depletion and persistent monocyte and**
36 **neutrophil infiltration upon peanut and mineral oil injection.** Peritoneal lavage (PL) was
37 obtained three weeks after treatment with oil. **A**. Total cell number in peritoneal lavage **B**.
38 Myeloid cells ($CD45^+CD11b^+$) in peritoneal lavage. **C**. Neutrophils
39 ($CD45^+CD11b^+Ly6G^+Ly6C^{int}$) in peritoneal lavage. **D**. Monocytes ($CD45^+CD11b^+Ly6G^-Ly6C^+$)
40 in peritoneal lavage. **F**. Macrophages ($CD45^+CD11b^+F4/80^+$) in peritoneal lavage. **E**.
41 Representative blots of flow cytometry analysis of monocytes, neutrophils and macrophages.
42 **G.** Percentage of $CD45^+CD11b^+F4/80^+Tim4^+$ and $CD45^+CD11b^+F4/80^+Tim4^-$ macrophages. **H.**
43 Percentage of $CD45^+CD11b^+F4/80^{hi}$ macrophages. **I.** Percentage of $CD45^+CD11b^+F4/80^{int}$
44 macrophages. All data represent n=4 mice for untreated, peanut, corn and mineral groups and
45 n=5 for olive and oral gavage groups. Bar graphs show mean ± SD, *, p<0.05 (one way
46 ANOVA).

47

48 **Figure 5. Macrophage foam cell formation upon contact with vegetal oil. A**. Isolation of
49 peritoneal macrophages from untreated mice and three weeks after peanut, olive, corn,
50 mineral oil intraperitoneal injection. Cells from peritoneal lavage were plated for 30 minutes
51 and stained with Oil Red O. Scale bar, 5 µm. **B.** J774A.1 macrophages after four hours in
52 contact with the different oils. Representative images of Oil Red O staining. Scale bar, 50 µm.
53 **C**. Representative Western blot of CD36 expression in J774A.1 macrophages after four hours
54 in contact with the different oils. **D.** Representative Western blot of ABCG1 expression in

55 J774A.1 macrophages after four hours in contact with the different oils. **E.** Quantification of
56 CD36 and ABCG1 mRNA expression levels expression in J774A.1 macrophages after four
57 hours in contact with the different oils. Fold change in comparison to untreated cells. All data
58 from n=3 biological replicates, bar graphs represent mean ± SD, *, $p<0.05$ (one way ANOVA).

59

60 **Figure 6. Macrophage cell death upon exposure to vegetal oil. A**. Schematic illustration of
61 *i.p.* oil administration. Peritoneal lavage was obtained five minutes later. **B**. Percentage of
62 macrophages ($CD45^+CD11b^+F4/80^+$). Untreated mice n=3, peanut oil n=6 mice and all other
63 groups n=5 mice, mean ± SD, *, $p<0.05$ (one way ANOVA). **C**. Percentage of live (Annexin V^-
64 PI^-), apoptotic (Annexin V^+PI^-), necrotic (Annexin V^-PI^+) or double positive (Annexin V^+PI^+) cells
65 from total number of cells in peritoneal lavage. Untreated mice n=6, peanut and olive oil n=9
66 mice, corn and mineral oil n=10 mice, bar graphs represent mean ± SD, *, $p<0.05$ (2-way
67 ANOVA). **D.** J774A.1 macrophage cell line untreated or incubated with different oils for four
68 hours and analysis of the percentage of live (Annexin V^-PI^-), apoptotic (Annexin V^+PI^-), necrotic
69 (Annexin V^-PI^+) or double positive (Annexin V^+PI^+) cells. n=3 biological replicates, bar graphs
70 represent mean ± SD, *, $p<0.05$ (2-way ANOVA). **E.** J774A.1 macrophages untreated or
71 incubated with different oils for two hours. Quantification positive cells per field in comparison
72 to untreated, blue (alive cells), green (apoptotic) and red (necrotic). n=3 biological replicates,
73 mean ± SD, *, $p<0.05$ (one-way ANOVA). **H.** LDH activity in the supernatant upon treatment
74 of J774A.1 macrophages for two hours. n=3 biological replicates, mean ± SD, *, $p<0.05$ (one-
75 way ANOVA). **I.** Normalized mRNA expression levels of IL10. n=4 biological replicates,
76 mean ± SD, *, $p<0.05$ (one-way ANOVA). **J.** Representative Western blot cleaved caspase-3,
77 arginase-1 and active p20 caspase-1 of J774A.1 macrophages untreated or incubated for four
78 hours with different oils. **K.** Quantification of Western blots. n=3 biological replicates,
79 mean ± SD, *, $p<0.05$ (one-way ANOVA).

80

81 **Figure 7. Intraperitoneal injection of peanut oil impairs the resolution of inflammation in**
82 **a thioglycolate-induced peritonitis model. A**. Schematic illustration of *i.p.* or oral oil
83 administration followed by thioglicolate *i.p*. injection three weeks after treatment with oil. **B.**
84 Representative blots of flow cytometry analysis of monocytes, neutrophils. **C**. Percentage of
85 myeloid cells ($CD45^{+}CD11b^{+}$) in peritoneal lavage. **D**. Percentage of neutrophils
86 ($CD45^{+}CD11b^{+}Ly6G^{+}Ly6C^{int}$) in peritoneal lavage. **E**. Percentage of monocytes in peritoneal
87 lavage. **F**. Percentage of macrophages ($CD45^{+}CD11b^{+}F4/80^{+}$) in peritoneal lavage. **G.**
88 Percentage of macrophages $CD45^{+}CD11b^{+}F4/80^{hi}$ in peritoneal lavage. **I.** Percentage of
89 macrophages $CD45^{+}CD11b^{+}F4/80^{in}$ in peritoneal lavage. n=3 mice for oral gavage followed
90 by thioglycolate and analysis at 24 hours. All other groups n=4 mice.

91

A

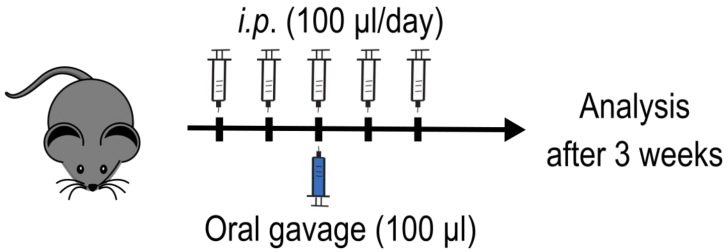
i.p. (100 µl/day)
Analysis
after 3 weeks
Oral gavage (100 µl)

B

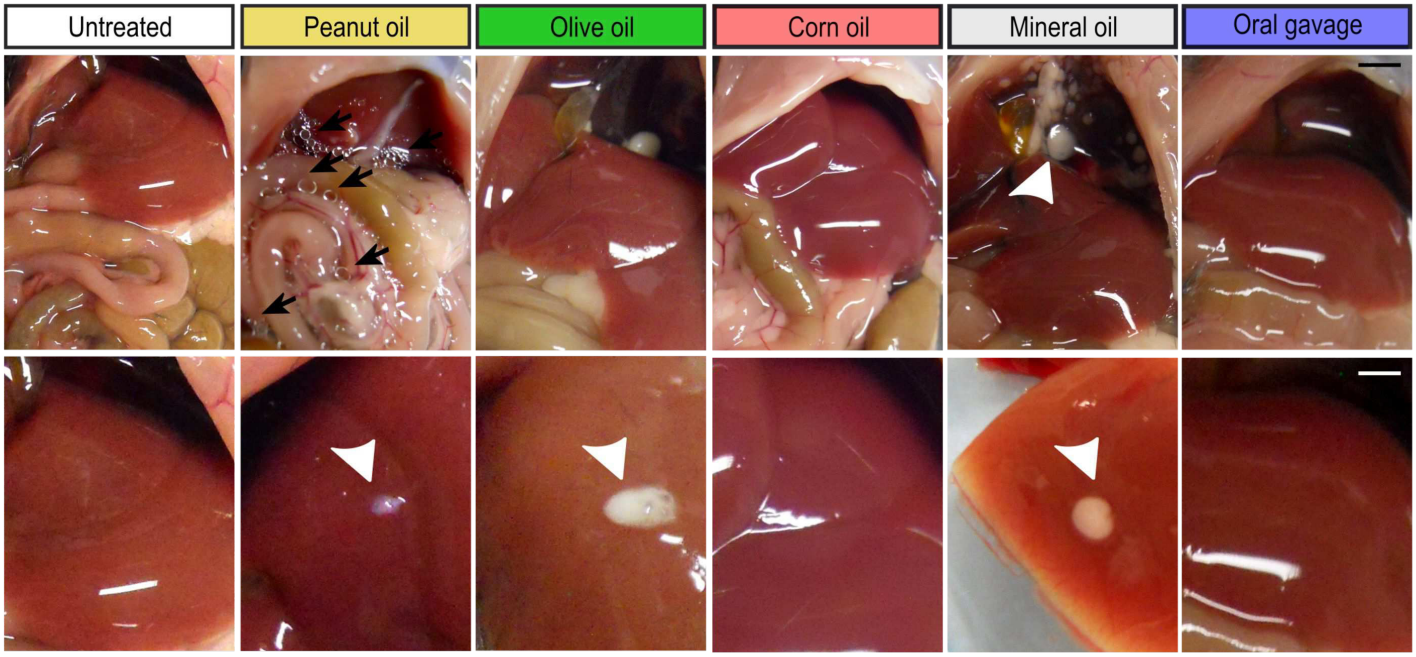
Untreated
Peanut oil
Olive oil
Corn oil
Mineral oil
Oral gavage

C

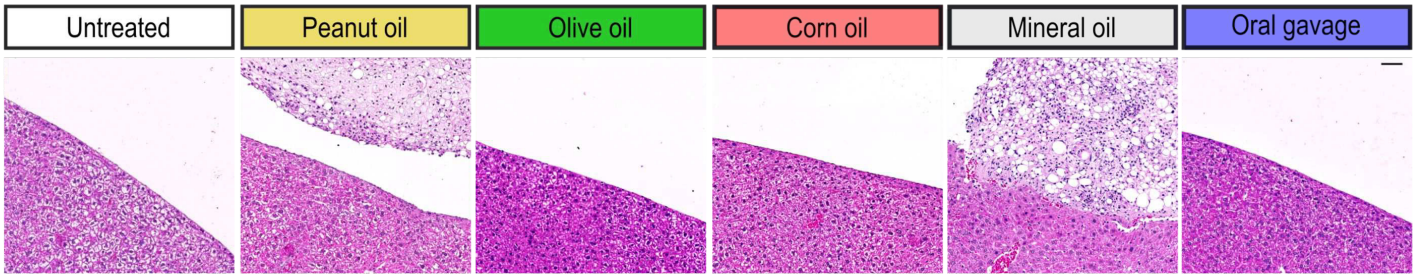
Untreated
Peanut oil
Olive oil
Corn oil
Mineral oil
Oral gavage

Figure 1

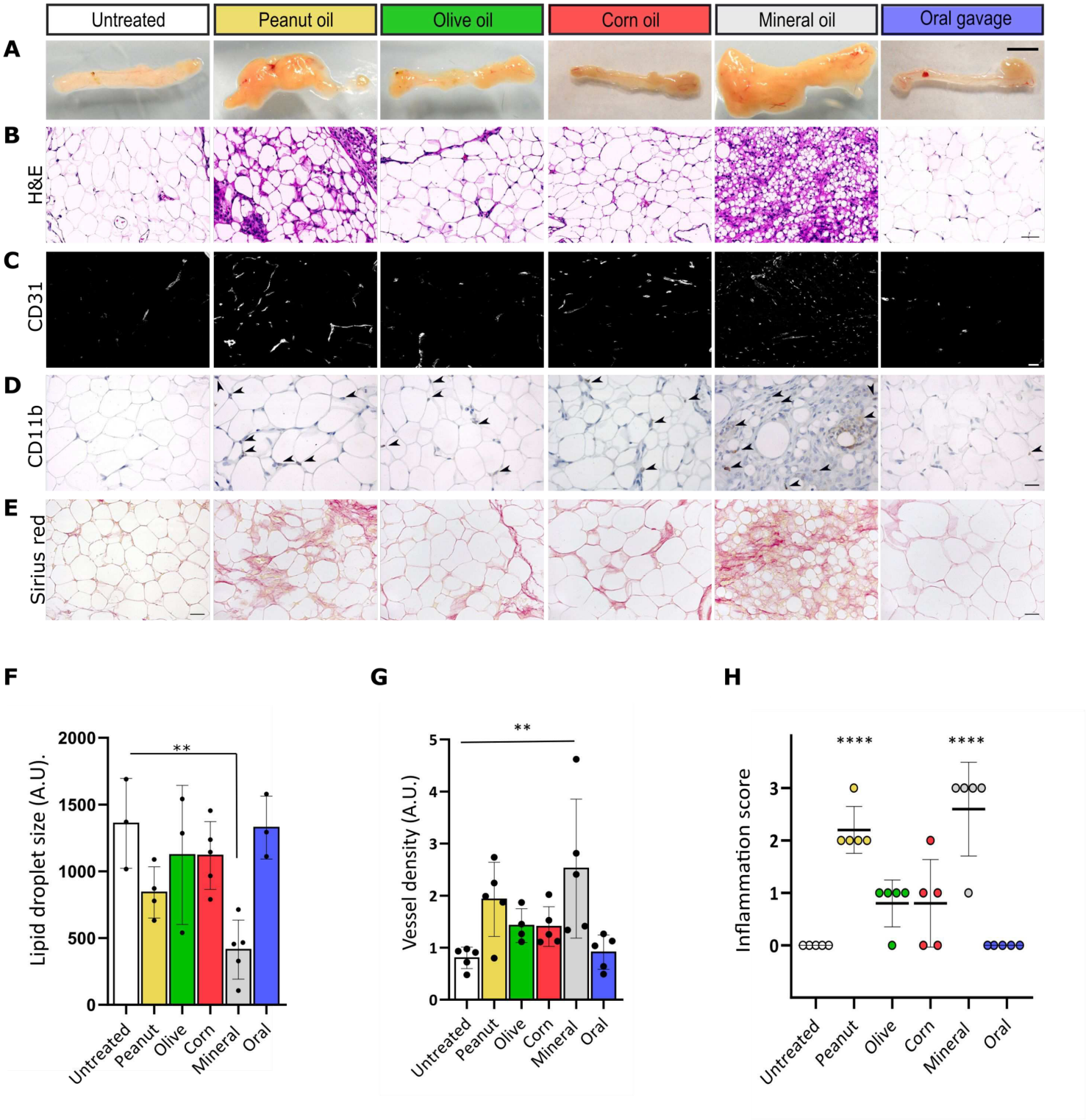
Untreated
Peanut oil
Olive oil
Corn oil
Mineral oil
Oral gavage
A
B
H&E
C
CD31
D
CD11b
E
Sirius red
F
Lipid droplet size (A.U).
2000
1500
1000
500
0
**
Untreated
Peanut
Olive
Corn
Mineral
Oral
G
Vessel density (A.U.)
5
4
3
2
1
0
**
Untreated
Peanut
Olive
Corn
Mineral
Oral
H
Inflammation score
3
2
1
0
****
****
Untreated
Peanut
Olive
Corn
Mineral
Oral

Figure 2

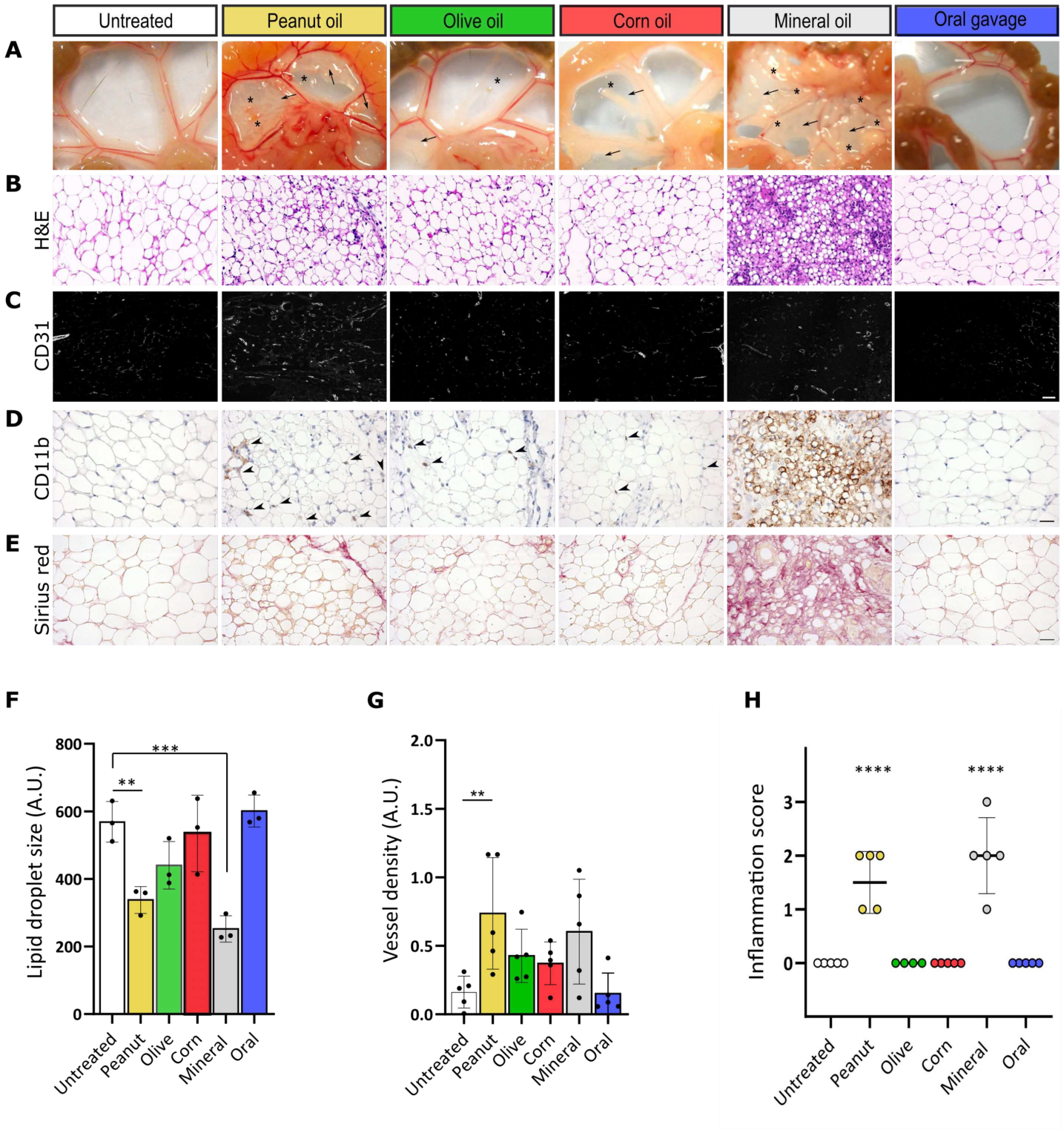
Untreated
Peanut oil
Olive oil
Corn oil
Mineral oil
Oral gavage
A
B
H&E
C
CD31
D
CD11b
E
Sirius red
F
Lipid droplet size (A.U.)
800
600
400
200
0
***
**
Untreated
Peanut
Olive
Corn
Mineral
Oral
G
Vessel density (A.U.)
2.0
1.5
1.0
0.5
0.0
**
Untreated
Peanut
Olive
Corn
Mineral
Oral
H
Inflammation score
3
2
1
0
****
****
Untreated
Peanut
Olive
Corn
Mineral
Oral

Figure 3

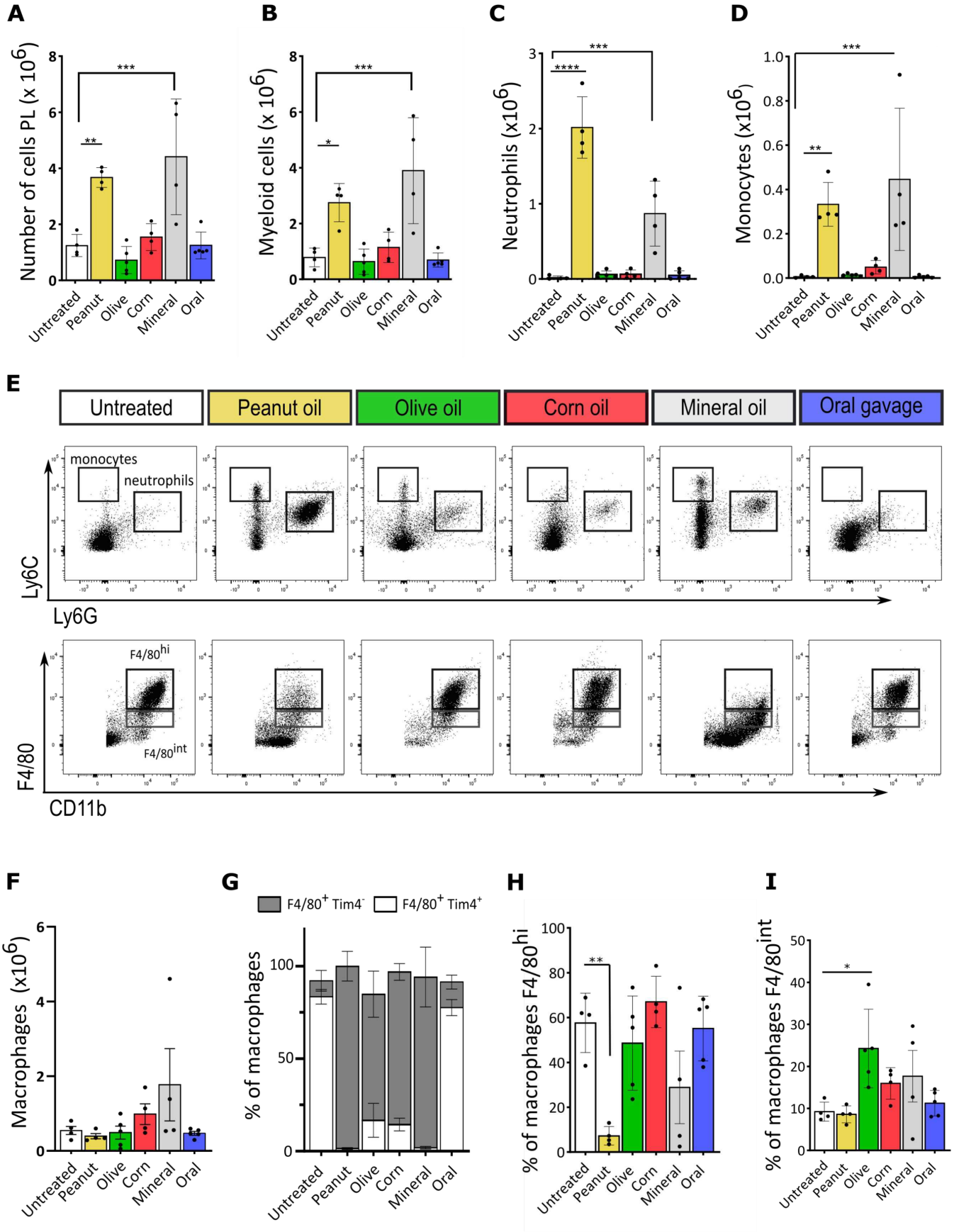
A
Number of cells PL (x 10^6)
B
Myeloid cells (x 10^6)
C
Neutrophils (x10^6)
D
Monocytes (x10^6)
Untreated
Peanut
Olive
Corn
Mineral
Oral
E
Untreated
Peanut oil
Olive oil
Corn oil
Mineral oil
Oral gavage
monocytes
neutrophils
Ly6C
Ly6G
F4/80^hi
F4/80^int
F4/80
CD11b
F
Macrophages (x10^6)
G
F4/80+ Tim4-
F4/80+ Tim4+
% of macrophages
H
% of macrophages F4/80^hi
I
% of macrophages F4/80^int

Figure 4.

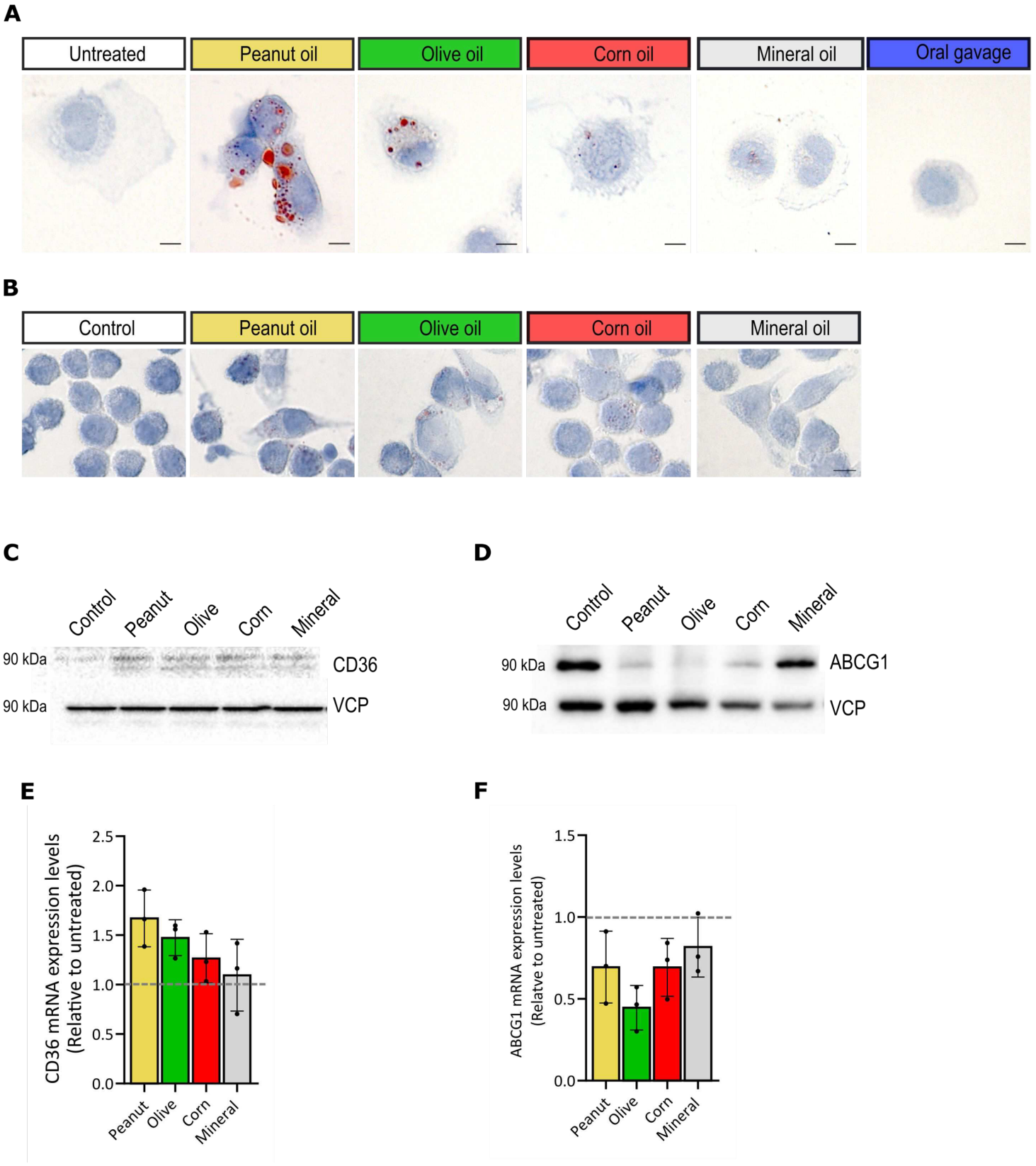
A
Untreated
Peanut oil
Olive oil
Corn oil
Mineral oil
Oral gavage
B
Control
Peanut oil
Olive oil
Corn oil
Mineral oil
C
Control
Peanut
Olive
Corn
Mineral
90 kDa
CD36
90 kDa
VCP
D
Control
Peanut
Olive
Corn
Mineral
90 kDa
ABCG1
90 kDa
VCP
E
CD36 mRNA expression levels
(Relative to untreated)
2.5
2.0
1.5
1.0
0.5
0.0
Peanut
Olive
Corn
Mineral
F
ABCG1 mRNA expression levels
(Relatve to untreated)
1.5
1.0
0.5
0.0
Peanut
Olive
Corn
Mineral

Figure 5.

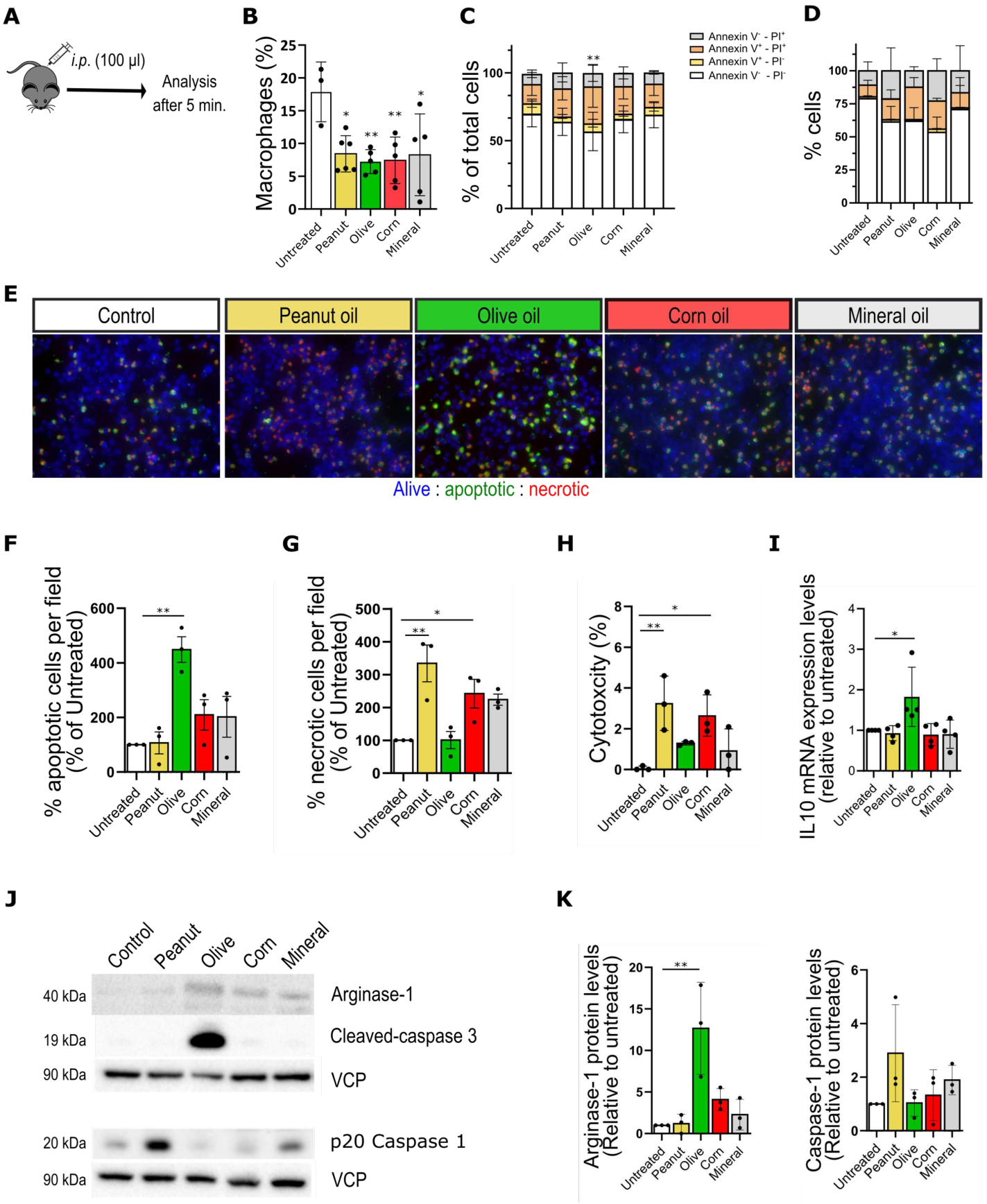
A
i.p. (100 µl)
Analysis after 5 min.
B
Macrophages (%)
Untreated
Peanut
Olive
Corn
Mineral
C
% of total cells
Annexin V⁻ - PI⁺
Annexin V⁺ - PI⁺
Annexin V⁺ - PI⁻
Annexin V⁻ - PI⁻
D
% cells
E
Control
Peanut oil
Olive oil
Corn oil
Mineral oil
Alive : apoptotic : necrotic
F
% apoptotic cells per field (% of Untreated)
G
% necrotic cells per field (% of Untreated)
H
Cytotoxcity (%)
I
IL10 mRNA expression levels (relative to untreated)
J
Control
Peanut
Olive
Corn
Mineral
40 kDa
Arginase-1
19 kDa
Cleaved-caspase 3
90 kDa
VCP
20 kDa
p20 Caspase 1
90 kDa
VCP
K
Arginase-1 protein levels (Relative to untreated)
Caspase-1 protein levels (Relative to untreated)

Figure 6.

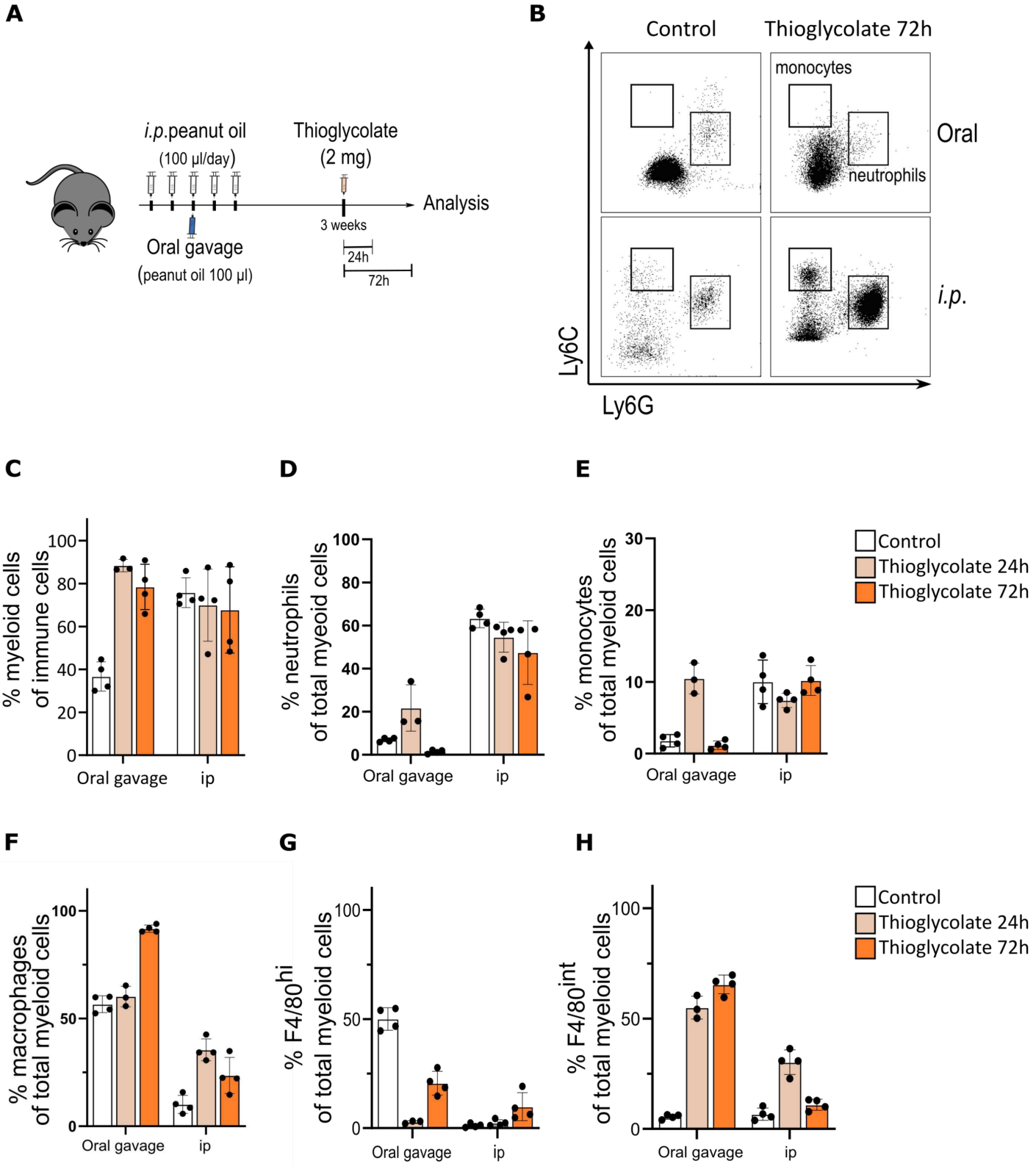
A
i.p.peanut oil
(100 µl/day)
Thioglycolate
(2 mg)
Analysis
3 weeks
Oral gavage
(peanut oil 100 µl)
24h
72h
B
Control
Thioglycolate 72h
monocytes
neutrophils
Oral
i.p.
Ly6C
Ly6G
C
% myeloid cells of immune cells
Oral gavage
ip
D
% neutrophils of total myeoid cells
E
% monocytes of total myeloid cells
Control
Thioglycolate 24h
Thioglycolate 72h
F
% macrophages of total myeloid cells
G
% F4/80hi of total myeloid cells
H
% F4/80int of total myeloid cells

Figure 7.