Acute unilateral emphysema induced by *Pseudomonas aeruginosa* in mice

Yajie Zhu[1], and Shuming Pan[1]*

[1]Department of Emergency Medicine, Xinhua Hospital, Shanghai Jiao Tong University School of Medicine, Shanghai, 200092, China

*Correspondence：Shu-ming Pan, Tel: +8602125078999, Fax: +8602165030840, E-mail: panshuming@xinhuamed.com.cn

Abstract

Background: Pulmonary emphysema, a major form of chronic obstructive pulmonary disease (COPD), has long been regarded as a chronic airway response result from cigarette smoking. Airway infection on the other hand, is not considered to play a major role in emphysema pathogenesis. Acute emphysema caused by airway infection has never been reported. Until recently, we accidentally found that the secretion from *Pseudomonas aeruginosa* could cause significant lung emphysema in mice rapidly. Using a unilateral lung injury model, we further studied the unique pathological change and tested if it can be induced by direct *P. aeruginosa* airway infection. **Method:** *P. aeruginosa* secretion was extracted and instilled intratracheally into the left lung of C57BL/6 and C3HHeJ mice, while the right lung used as self-control. Alveolar diameter and lung compliance were measured and compared. The dynamic change of emphysema in different mice were closely watched. C57BL/6, immunosuppressed C57BL/6 and C3HHeJ mice were used to examine if the emphysema can be caused by *P. aeruginosa* infection. **Results:** *P. aeruginosa* secretion extract containing metal-dependent hydrolase and other enzymes caused acute panacinar emphysema and a decrease of dynamic lung compliance in mice. However, the *P. aeruginosa* infection could only elicit emphysema in immunocompromised mice but not in immunocompetent mice. Panacinar emphysema interwoven with inflammation developed into various types of emphysema and bullae. **Conclusion:** *P. aeruginosa* lung infection in mice recapitulates main features of human pulmonary emphysema and COPD.

Key point: We are the first to report *P. aeruginosa* airway infection could lead to emphysema in immunocompromised mice.

Key words: Emphysema, COPD, pathology, unilateral lung injury, *Pseudomonas aeruginosa*

Introduction

Chronic obstructive pulmonary disease (COPD) is the third leading cause of death globally, characterized by poorly reversible obstruction of the small airways (chronic obstructive bronchiolitis) and emphysema, which lead to air trapping, dyspnea and even respiratory failure[1]. Cigarette smoking is regarded the most important cause of emphysema while bacterial airway infection is not considered as an initiator [2, 3]. However, emphysema was found in many patients who do not smoke [4]. And even for heavy smokers, only 40% developed emphysema[5]. Accumulating evidence suggests a better understanding of emphysema pathogenesis is needed [1, 6].

Pseudomonas aeruginosa is a gram-negative, aerobic, nonfastidious, opportunistic bacterium widely distributed in the environment[7]. In the lung, *P. aeruginosa* is known to prevalent among immunocompromised hosts, causing cystic fibrosis, bronchiectasis and nosocomial pneumonia [8, 9]. *P. aeruginosa* colonize after COPD formation and contribute to the acute exacerbation [10]. It can be isolated from 4-15% of adults with COPD, a number probably underestimated due to this organism's unique ability to form biofilms, making it difficult to detect[11]. *P. aeruginosa* secret a variety of virulence factors including endotoxin, exotoxin, elastase A, elastase B, alkaline proteases and hemolysins [12]. The proteases can disrupt epithelial cell tight junctions, cleave collagen, IgG, IgA, complement, and degrade surfactant proteins, causing harm to the lung[13]. However, the manifestations of *P. aeruginosa* pneumonia reported are nonspecific compared with other bacteria[14].

Recently, we accidently discovered that distinguished from Klebsiella pneumoniae, Staphylococcus aureus, Escherichia coli and Proteus mirabilis, the secretion of *P. aeruginosa* could induce severe pulmonary emphysema in murine rapidly. We hypothesized that this phenomenon is caused by the proteases secreted by *P. aeruginosa*. Thus, theoretically, *P. aeruginosa* infection could lead to acute emphysema too. To address this issue, unilateral lung instillation model of normal C57BL/6,

immunosuppressed C57BL/6 and C3HHeJ mice were used and the dynamic pathological changes were observed. Lm Ratio was used to measure air space enlargement after *P. aeruginosa* inoculation.

Method

Ethical statement

All experiments referring to the use of animals in this study were approved by the Institutional Animal Care and Use Committee of Shanghai Xinhua Hospital affiliated to Shanghai Jiao Tong University School of Medicine (XHEC-F-2018-047).

Mice

C57BL/6 mice (10 weeks old) were purchased from Shanghai Sippr-BK laboratory animal Co. Ltd; C3HHeJ mice (10weeks old) were purchased from Shanghai SLAC laboratory animal Co. Ltd. All mice were accommodated in specific pathogen-free animal facility under constant temperature and humidity, with sufficient qualified food and water for 1 to 2 weeks before use at Model Animal Research Center, Xinhua Hospital, SJTUSM.

Isolation and identification of *P. aeruginosa*

Typical *P. aeruginosa* strain were originally separated from sputum, confirmed through mass spectrometry and the strain kept at bacteriology lab of Xinhua Hospital. To observe the morphology and culture characteristics, the purified strain was streaked on Sheep blood agar plates (Yi Hua, Shanghai) and nutrient agar plates (Comagal, Shanghai) and incubated at 37°C for 24-36 hours.

Bacterial secretion extraction and identification

1×10^6 CFU *P. aeruginosa* were streaked on sheep blood agar plate and incubated at 37°C for 24–48 hours. To harvest the *P. aeruginosa* bacteria secretion, all colonies on the blood agar plate were scratched down, collected and dissolved in 5ml PBS then

centrifuged at 3000 rcm for 10 minutes. Supernatant was collected, filtered through 0.22μm PES membrane filter unit (Millex, Merck) and stored at -20℃ for later use. The quantification of the supernatant protein concentration was carried through BCA protein assay (Beyotime, China). Protein types in the secretion were identified by protein mass spectrometry. Briefly, the secretion extract went through enzymatic hydrolysis and was analyzed by a Q-Exactive mass spectrometer (Thermo, USA) equipped with a Nanospray Flex source (Thermo, USA). Proteome Discoverer (v.2.4) was used to search all of the raw data thoroughly against the protein database (UniProt_ *Pseudomonas aeruginosa*). Names and abundances of proteins were acquired as the result.

Live bacteria preparation

P. aeruginosa were streaked on sheep blood agar plate and incubated at 37°C for 8 hours. Proper number of colonies were inoculated in sterile PBS and the turbidity was adjusted to 2 McFarland standards (MCF), which equals to 6×10^8 CFU/ml, by standard procedure for later use.

Immunosuppression model

Immunosuppressed model of C57BL/6 mice was established by intraperitoneally administration of dexamethasone sodium phosphate 25mg/kg per day for a consecutive 5 days referring to the method described by Rasmussen KR and colleges[15]. Control mice received a same dosage normal saline intraperitoneally. The immunosuppression status was confirmed at the sixth day by evaluate the organ-to-body weight ratios of spleen (relative spleen weight)[16]. C3HHeJ mice were used directly as immunodeficient mice for their lack of Toll-like receptor 4.

Unilateral lung instillation

In the unilateral lung injury mice model, left lung was set as the instillation side and right lung was set as the control side. Mice were anesthetized through injecting 1%

pentobarbital sodium (50mg/Kg) intraperitoneally and put to a proper supine position. The anterior cervical hair was removed and skin disinfected with 75% ethanol. To expose the trachea, a small longitudinal incision was made and endotracheal intubation performed between second to fourth cricoid cartilage using a 24G intravenous indwelling catheter (Introcan, BRAUN). The 19mm long 24G cannula then was inserted gently into the left main bronchus. A volume of 30ul *P. aeruginosa* secretion extract was delivered into the left lung of each mouse using microliter syringes (Gaoge, Shanghai). Different dosage of live bacteria was inoculated through the same method. After the intratracheal instillation, mice were put back to the mouse cage with a thermo pad underneath, resting in left recumbent position until full recovery from anesthesia.

Measurement of lung compliance

Dynamic lung compliances were measured 7 days after unilateral lung instillation of bacteria secretion. Main surgery procedures were same as above. A 22G intravenous indwelling catheter (Introcan, BRAUN) was used for endotracheal intubation. After exposure of the main trachea, 5mm of the catheter tip was inserted into the main trachea and a ventilator for rodents (Vent Jr, Kent) was connected to the catheter. Target tidal volume range between 0.2-0.5ml was set and the corresponding peak pressure recorded each (RR=100bpm). Lung dynamic compliance (C_{dyn}) was calculated through linear regression by GraphPad Prism 8 software.

Lung Histopathology and analysis

Mice were sacrificed at different time points set. Lung was inflated with 4% paraformaldehyde fixative under a constant pressure of 15 to 25 cm H_2O via the trachea and the trachea then tied off. Lung and heart were harvested en bloc and submerged in fixative for approximately 24 hours before the heart was removed and lung was embedded in paraffin blocks for tissue sections (5μm). Hematoxylin and eosin staining were performed subsequently. Slides were scanned (PANNORAMIC, 3DHISTECH),

reviewed and evaluated.

Alveolar mean linear intercept (Lm)

Air space enlargement was measured using the Short & Hennig method, 1967. Briefly, HE stained sections were scanned and reviewed in Caseviewer software. 10 random fields of each right lung and left lung were randomly selected. Equally crossed two lines (both 1000um) were drawn on the scope. The number of intercepts was counted on both the horizontal and the vertical line for each field and the sum for all the sections obtained. The mean linear intercept Lm was then calculated from m, the sum of all the intercepts, L, the length of the traverses, and N, the number of times the traverses were placed on the lung. $Lm=N*L/m$ [17]. In this case, $Lm=2*10^4/m$ (μm). To better measure how much the left lung air space has enlarged compare to the right lung, Lm Ratio were further calculated, Lm Ratio=Lm (left lung)/ Lm (right lung).

Statistics

The data were expressed as the mean ± standard error of mean. Statistical analysis was performed in the GraphPad Prism 8 software, by using t-test or one-way analysis of variance (ANOVA) test, respectively, as indicated. Confidence interval was set at 95% for all tests. Groups of three or four animals were used in each experiment.

Result

Identification of *P. aeruginosa*

P. aeruginosa was originally isolated and purified from a clinical sputum sample and confirmed through mass spectrometry. The strain exhibited typical *P. aeruginosa* characteristics including strong ginger odor, green metallic sheen and beta-hemolytic on blood agar with blue-green pigment producing on nutrient agar (**Figure 1**).

Bacteria secretion extract

The *P. aeruginosa* secretion extract was translucid, light green colored with a strong ginger odor. The total protein concentration was 0.35mg/ml.

Unilateral pulmonary instillation of bacteria secretion

Two days after *P. aeruginosa* secretion instillation, prominent panacinar emphysema with acute inflammation were developed in the left lung of both C57BL/6 mice and C3HHeJ mice while the right lung remained mostly unharmed (**Figure 2**). The inflammation is characterized with neutrophil infiltration and erythrocyte diapedesis. Lm Ratio indicates the alveolar of left lung had enlarged more than three times in C57BL/6 mice, and two times in C3HHeJ mice.

Seven days after the instillation, inflammation faded and panacinar emphysema were well developed and remained in C3HHeJ without fibrosis. While interestingly in C57BL/6 mice, the panacinar emphysema had changed to distal emphysema with most of the left lung consolidated. Fibrosis is obvious, inflammation cells can be seen excreting from alveolars and bronchus. To decide if the panacinar emphysema would recur after inflammation resolution, we observed C57BL/6 mice models to three weeks after instillation. Surprisingly, Large apical and subpleural bullae appeared. Histopathology shows all four types of emphysema (centriacinar, panacinar, distal acinar and irregular) coexisting in the left lung and compensatory emphysema has developed in the right lung (**Figure 2**).

During the above modeling process, C57BL/6 mice underwent dyspnea, huddle, weight loss and scaphoid abdomen while C3HHeJ mice showed no obvious symptoms or weight loss (**Figure 3**).

Bacterial secretion identification

After heated for 80°C, 30mins, the bacteria secretion was still able to cause neutrophil infiltration but not emphysema (data not shown), indicating the emphysema was most likely to be caused by heat labile proteases. Protein mass spectrometry confirmed the

protein types in the secretion includes high abundance metal-dependent hydrolase, urocanate hydratase and other enzymes (supplementary material).

Dynamic lung compliance

7 days after unilateral lung instillation of bacteria secretion, C_{dyn} of C57BL/6 mice decreased from 0.041 to 0.031 ml/cmH_2O while C_{dyn} of C3HHeJ mice decreased from 0.045 to 0.036 ml/cmH_2O. Peak pressure and targeted tidal volume were not well linearly correlated as they used to.

Unilateral lung instillation of live bacteria

Different bacteria dosages, infection time and other conditions in normal C57BL/6 mice were tested, but none of the mice showed noteworthy emphysema (n≥10). A representative case is the mouse was attacked with 15μl of 5 MCF *P. aeruginosa*, which formed a prominent abscess full of *P. aeruginosa* bacteria at the apex of the left lung after 24 hours, but it only caused bronchiectasis-like pathology change in a few areas (**Figure 4)**. Whereas, all C3HHeJ mice developed homogenous emphysema after live bacteria instillation (n=7). 15μl of 0.5 MCF *P. aeruginosa*—one tenth of the dosage used in C57BL/6 mice—was able to cause obvious centriacinar emphysema in C3HHeJ.

In order to decide if the emphysema induced is more related to species or immunity differences, immune suppressed C57BL/6 mice, C3HHeJ mice and normal C57BL/6 mice were infected with 30μl of 2 MCF *P. aeruginosa* for 9 hours (**Figure 5**). Centriacinar pulmonary emphysema occurred in both immunosuppressed C57BL/6 mice and C3HHeJ mice. A comparison of the Lm Ratios between different groups reveals that *P. aeruginosa* infection had caused airspace enlargement in two immunocompromised mice group but alveolar collapse and lung compression in normal C57BL/6 mice group.

Discussion

We were researching on acute lung injury (ALI) using a unilateral lung instillation

model for the past two years. All of our ALI models showed a morphology of lung consolidation and deflation after injury, until this unusual inflated lung appeared and caught our eyes. We thus found the secretion of *P. aeruginosa* containing metal-dependent hydrolase could cause acute emphysema, a role that has never been reported before. While the homogenize emphysema caused by *P. aeruginosa* secretion exhibited a stable pattern in immunodeficient mice, it went through dynamic change interweaved with inflammation and developed to all four subtypes of emphysema in normal C57BL/6 mice.

Given this result, we inferred that theoretically, animals would develop emphysema after *P. aeruginosa* lung infection too, which however, proved otherwise. None of the normal C57BL/6 mice showed noteworthy emphysema. Whereas, all C3HHeJ mice developed diffused centriacinar emphysema after *P. aeruginosa* inoculation, which also applied to immunosuppressed C57BL/6 mice. Our findings show that the pathogenesis of COPD can be naturally acute and cigarette smoking irrelevant. Chronic inhalation of noxious particles is more likely to have led to immunity impairment, created a circumstance favors *P. aeruginosa* to survive and thrive, and caused COPD in the end[18, 19].

The bacteria secretion is a mixture of metal-dependent hydrolase, different enzymes and bacterial toxins which elicited strong inflammation in normal mice. Interestingly, it seems the neutrophils had played a positive role in preventing emphysema development. Immunosuppressed C57BL/6 as well as TLR4 deficient C3HHeJ mice whom had lighter inflammatory response and neutrophils infiltration than C57BL/6 mice, exhibited more severe airspace enlargement.

Degradation of the elastin framework is a leading potential mechanism of COPD[5]. Protease–antiprotease imbalance as a result of noxious particles induced chronic inflammation is proposed based on the observation that smokers with a genetic deficiency of α-anti-trypsin have a predisposition to develop emphysema. Emphysema caused by lung instillation of porcine pancreatic elastase has been a disease model

widely used in support of the protease-antiprotease imbalance[20]. Many studies found elevated MMPs concentration and increased elastin degradation in chronic obstructive pulmonary diseases[21-23]. Neutrophil elastase or matrix metalloproteinases (MMPs) were held culprit[24]. But it appears that the protease secreted by various bacteria had never been taken into account. Proteases secretion is a common feature in *P. aeruginosa* and other bacteria[25], however, it seems never occurred to us that the excessive elastase may come from a pathogen rather than our own neutrophils. This is probably due to the fact that in immunocompetent animal models, bacterial infection can hardly cause COPD like pathological change. α1-anti-trypsin, the major inhibitor of proteases during inflammation could be an explanation[2]. It is secreted by local macrophages as well as liver, and normally presented in serum, tissue fluids. If the immunity is normal, proper inflammation response can increase α1-anti-trypsin level to eliminate the destruction effects caused by bacteria proteases[2].

There are plenty of researches studied the correlation of *P. aeruginosa* and COPD. Nevertheless, it is mostly accepted that *P. aeruginosa* colonized in the lung after COPD formed and only contribute partially to the exacerbation of COPD[26, 27]. Pulmonary *P. aeruginosa* infection is not considered of any differences than other bacterial infection[28]. This may due to the fact that *P. aeruginosa* could only cause limited bronchiectasis like pathology change in normal mice. And more importantly, minor differences of air space volume can be extremely hard to detect since lung tissue has a nature of instability. In our study, even if the lungs were inflated with fixative under a constant pressure carefully, the many steps in histopathology preparation process still impacted the final pressure, a result can be seen from the variation of alveolar diameters in control lung of different mouse.

Unilateral lung injury animal models were readily used in a few studies[29, 30]. A mouse model of unilateral injury can provide valuable self-control, eliminate systemic influence, and reduce the use of lab animals. By ensuring the pressure is equal in both side of the lung, we detected the minor changes. The Lm Ratio of left lung to right lung further revealed clearly how much the airspace has enlarged due to the tested factor.

However, a unilateral lung injury model is not perfect. Sometimes contamination of the control lung caused by the sneeze or cough of mice is not totally avoidable, especially in bacterial infection models. Thus, the histology change in the main bronchus of control lung should been interpreted carefully.

On the contrary to the current paradigm, we discovered for the first time that emphysema can be caused by pulmonary infection. *P. aeruginosa* infection could lead to emphysema in immunodeficient animals, which is in comply with its predilection to infect immunocompromised patients. We believe this may apply to human too and *P. aeruginosa* could be an important pathogen of COPD.

Acknowledgements

We would like to thank Dr. Feng Chen and Dr. Jingxian Liu (Bacteriology Lab, Xinhua Hospital) as well as Professor Yong Zhang (Department of Immunology, SJTUSM) and Professor Min Wang (Department of Histology and Embryology, SJTUSM) for their skilled advice and assistance;

Authors' Contributions

Yajie Zhu contributed to the original findings and majority of the study conception, data analysis and manuscript preparation. Shuming Pan contributed partly to the study conception, data analysis and manuscript preparation. Shuming Pan was responsible for the study supervision. Both authors critically reviewed the manuscript for important intellectual content and read and approved the final manuscript.

Declaration of interests

The authors declare no conflicts of interest in this work.

References

1. Rabe KF, Watz H. Chronic obstructive pulmonary disease. *Lancet (London, England)* 2017; 389: 1931-1940.
2. Aster VKAAJ. Robbins Basic Pathology. 2017.
3. Liang GB, He ZH. Animal models of emphysema. *Chinese medical journal* 2019;

132: 2465-2475.
4. Hogg JC. Pathophysiology of airflow limitation in chronic obstructive pulmonary disease. *Lancet (London, England)* 2004; 364: 709-721.
5. MacNee W. Pathogenesis of chronic obstructive pulmonary disease. *Proceedings of the American Thoracic Society* 2005; 2: 258-266; discussion 290-251.
6. Yoshida T, Tuder RM. Pathobiology of cigarette smoke-induced chronic obstructive pulmonary disease. *Physiol Rev* 2007; 87: 1047-1082.
7. Hu F, Guo Y, Yang Y, Zheng Y, Wu S, Jiang X, Zhu D, Wang F. Resistance reported from China antimicrobial surveillance network (CHINET) in 2018. *European journal of clinical microbiology & infectious diseases : official publication of the European Society of Clinical Microbiology* 2019; 38: 2275-2281.
8. Restrepo MI, Babu BL, Reyes LF, Chalmers JD, Soni NJ, Sibila O, Faverio P, Cilloniz C, Rodriguez-Cintron W, Aliberti S. Burden and risk factors for Pseudomonas aeruginosa community-acquired pneumonia: a multinational point prevalence study of hospitalised patients. *Eur Respir J* 2018; 52.
9. Cillóniz C, Dominedò C, Torres A. Multidrug Resistant Gram-Negative Bacteria in Community-Acquired Pneumonia. *Critical care (London, England)* 2019; 23: 79.
10. Sethi S, Murphy TF. Infection in the pathogenesis and course of chronic obstructive pulmonary disease. *N Engl J Med* 2008; 359: 2355-2365.
11. Murphy TF, Brauer AL, Eschberger K, Lobbins P, Grove L, Cai X, Sethi S. Pseudomonas aeruginosa in chronic obstructive pulmonary disease. *Am J Respir Crit Care Med* 2008; 177: 853-860.
12. Li J, Ramezanpour M, Fong SA, Cooksley C, Murphy J, Suzuki M, Psaltis AJ, Wormald PJ, Vreugde S. Pseudomonas aeruginosa Exoprotein-Induced Barrier Disruption Correlates With Elastase Activity and Marks Chronic Rhinosinusitis Severity. *Frontiers in cellular and infection microbiology* 2019; 9: 38.
13. Sadikot RT, Blackwell TS, Christman JW, Prince AS. Pathogen-host interactions in Pseudomonas aeruginosa pneumonia. *Am J Respir Crit Care Med* 2005; 171: 1209-1223.
14. Fujitani S, Sun HY, Yu VL, Weingarten JA. Pneumonia due to Pseudomonas aeruginosa: part I: epidemiology, clinical diagnosis, and source. *Chest* 2011; 139: 909-919.
15. Rasmussen KR, Healey MC. Experimental Cryptosporidium parvum infections in immunosuppressed adult mice. *Infect Immun* 1992; 60: 1648-1652.
16. Manente FA, Quinello C, Ferreira LS, de Andrade CR, Jellmayer JA, Portuondo DL, Batista-Duharte A, Carlos IZ. Experimental sporotrichosis in a cyclophosphamide-induced immunosuppressed mice model. *Medical mycology* 2018; 56: 711-722.
17. Dunnill MS. Quantitative methods in the study of pulmonary pathology. *Thorax* 1962; 17: 320-328.
18. Faure K, Sawa T, Ajayi T, Fujimoto J, Moriyama K, Shime N, Wiener-Kronish JP. TLR4 signaling is essential for survival in acute lung injury induced by virulent Pseudomonas aeruginosa secreting type III secretory toxins. *Respiratory research* 2004; 5: 1.
19. Drannik AG, Pouladi MA, Robbins CS, Goncharova SI, Kianpour S, Stämpfli MR.

Impact of cigarette smoke on clearance and inflammation after Pseudomonas aeruginosa infection. *Am J Respir Crit Care Med* 2004; 170: 1164-1171.
20. Antunes MA, Rocco PR. Elastase-induced pulmonary emphysema: insights from experimental models. *Anais da Academia Brasileira de Ciencias* 2011; 83: 1385-1396.
21. Chaudhuri R, McSharry C, Brady J, Donnelly I, Grierson C, McGuinness S, Jolly L, Weir CJ, Messow CM, Spears M, Miele G, Nocka K, Crowther D, Thompson J, Brannigan M, Lafferty J, Sproule M, Macnee W, Connell M, Murchison JT, Shepherd MC, Feuerstein G, Miller DK, Thomson NC. Sputum matrix metalloproteinase-12 in patients with chronic obstructive pulmonary disease and asthma: relationship to disease severity. *J Allergy Clin Immunol* 2012; 129: 655-663.e658.
22. Maclay JD, McAllister DA, Rabinovich R, Haq I, Maxwell S, Hartland S, Connell M, Murchison JT, van Beek EJ, Gray RD, Mills NL, Macnee W. Systemic elastin degradation in chronic obstructive pulmonary disease. *Thorax* 2012; 67: 606-612.
23. Wells JM, Parker MM, Oster RA, Bowler RP, Dransfield MT, Bhatt SP, Cho MH, Kim V, Curtis JL, Martinez FJ, Paine R, 3rd, O'Neal W, Labaki WW, Kaner RJ, Barjaktarevic I, Han MK, Silverman EK, Crapo JD, Barr RG, Woodruff P, Castaldi PJ, Gaggar A. Elevated circulating MMP-9 is linked to increased COPD exacerbation risk in SPIROMICS and COPDGene. *JCI Insight* 2018; 3.
24. Tanner L, Single AB. Animal Models Reflecting Chronic Obstructive Pulmonary Disease and Related Respiratory Disorders: Translating Pre-Clinical Data into Clinical Relevance. *Journal of innate immunity* 2020; 12: 203-225.
25. Galloway DR. Pseudomonas aeruginosa elastase and elastolysis revisited: recent developments. *Molecular microbiology* 1991; 5: 2315-2321.
26. Martínez-Solano L, Macia MD, Fajardo A, Oliver A, Martinez JL. Chronic Pseudomonas aeruginosa infection in chronic obstructive pulmonary disease. *Clin Infect Dis* 2008; 47: 1526-1533.
27. Boutou AK, Raste Y, Reid J, Alshafi K, Polkey MI, Hopkinson NS. Does a single Pseudomonas aeruginosa isolation predict COPD mortality? *Eur Respir J* 2014; 44: 794-797.
28. Curran CS, Bolig T, Torabi-Parizi P. Mechanisms and Targeted Therapies for Pseudomonas aeruginosa Lung Infection. *Am J Respir Crit Care Med* 2018; 197: 708-727.
29. Dames C, Akyüz L, Reppe K, Tabeling C, Dietert K, Kershaw O, Gruber AD, Meisel C, Meisel A, Witzenrath M, Engel O. Miniaturized bronchoscopy enables unilateral investigation, application, and sampling in mice. *Am J Respir Cell Mol Biol* 2014; 51: 730-737.
30. Singer T, Brand V, Moehrlen U, Fehrenbach H, Purkabiri K, Ott SR, Stammberger U, Ochs M, Hamacher J. Left-sided mouse intubation: description and evaluation. *Experimental lung research* 2010; 36: 25-30.

Figures

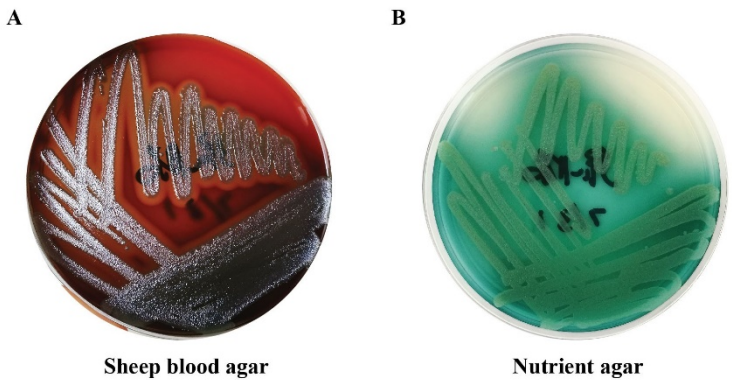

Figure 1 Culture characteristics of the *P. aeruginosa* strain. Typical green metallic sheen and beta-hemolysis seen on blood agar. Blue-green pigment produced on nutrient agar.

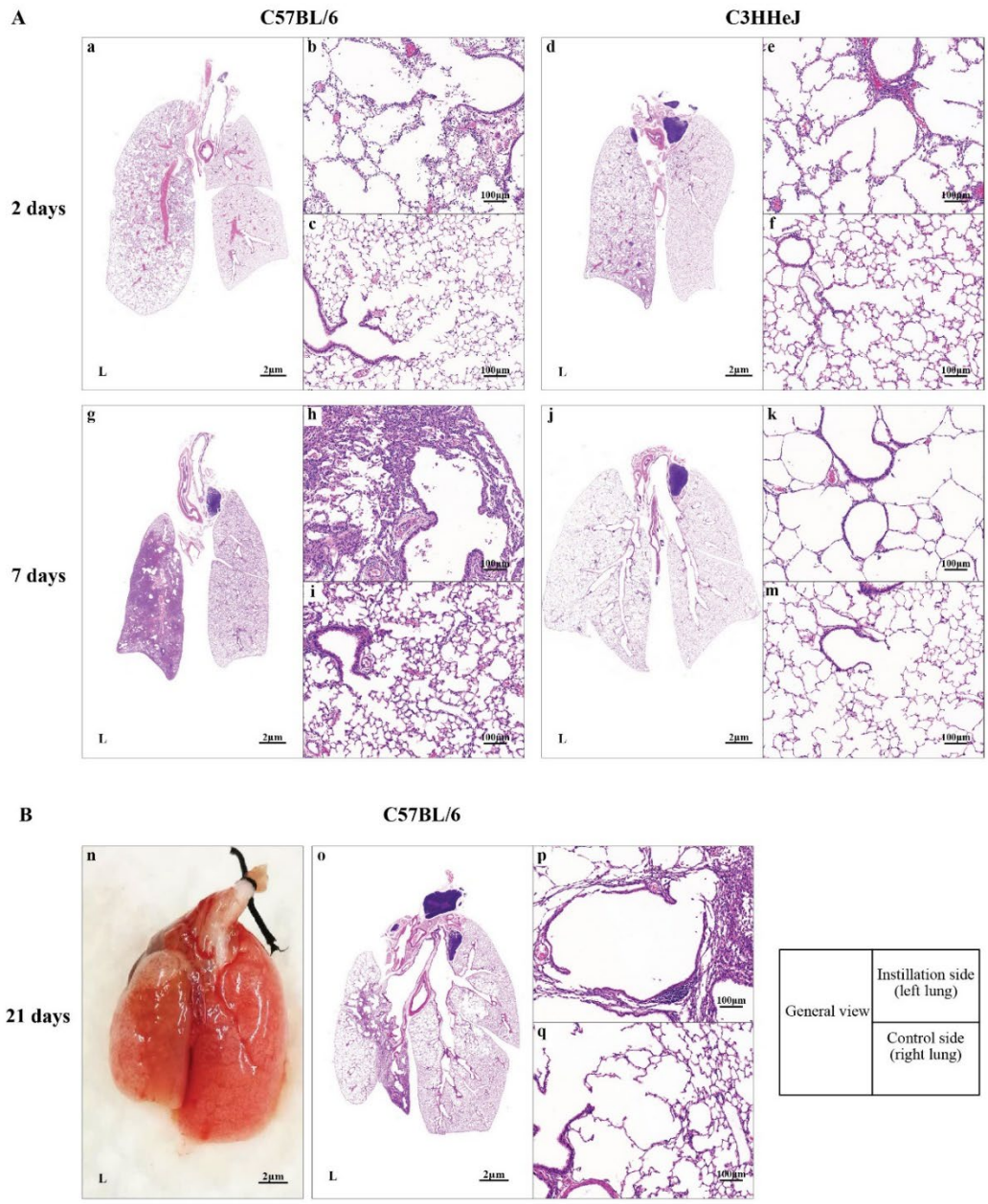

Figure 2 Unilateral pulmonary instillation of *P. aeruginosa* secretion: 2 days after *P. aeruginosa* secretion instillation, prominent panacinar emphysema with acute inflammation were developed in the left lung of both C57BL/6 mice (b) and C3HHeJ mice (e). 7 days after instillation, panacinar emphysema was maintained in C3HHeJ without obvious fibrosis (k), however, in C57BL/6 mice it changed to distal emphysema with lung consolidation (h). 21 days after instillation. C57BL/6 mice developed large apical and subpleural bullae (n). Histopathology showed a mixture of all four types of emphysema formed in the left lung (o, p) while compensatory emphysema developed in the right lung (q). All right lungs served as self-control (c, f, i, m, q).

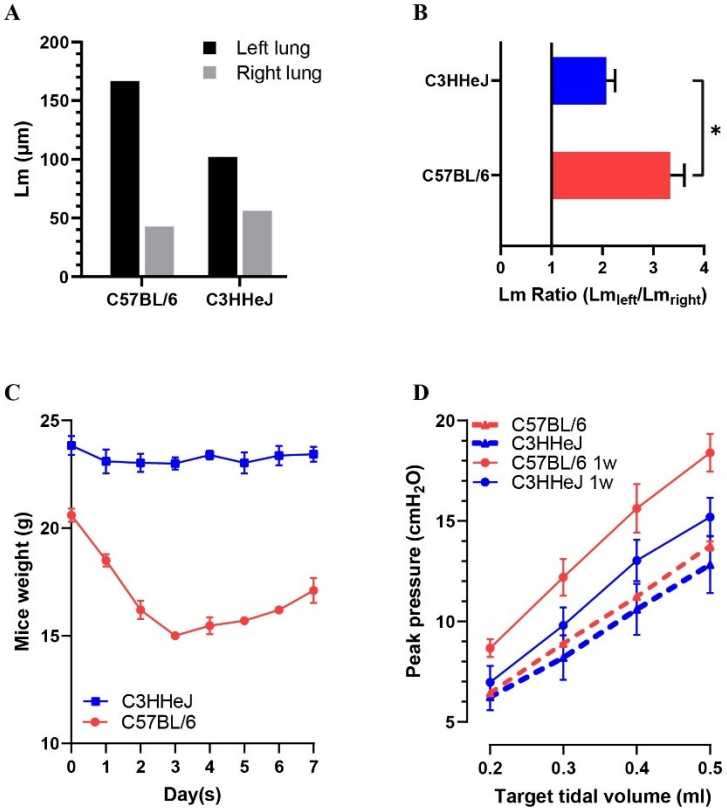

Figure 3: Representative Lm of one C57BL/6 mice (Figure 2, a) and one C3HHeJ mice (Figure 2, d) 2 days after the instillation exhibited (A). Lm ratio indicates the alveolar of left lung had enlarged more than three times in C57BL/6 group, and two times in C3HHeJ group(B). C57BL/6 mice went through severe weight loss during modeling in contrast to C3HHeJ mice (C). Dynamic lung compliance of both mice decreased after 7 days (D). The data represent the mean ± SEM of three animals. *P < .05; **P < .01; ***P< .001;

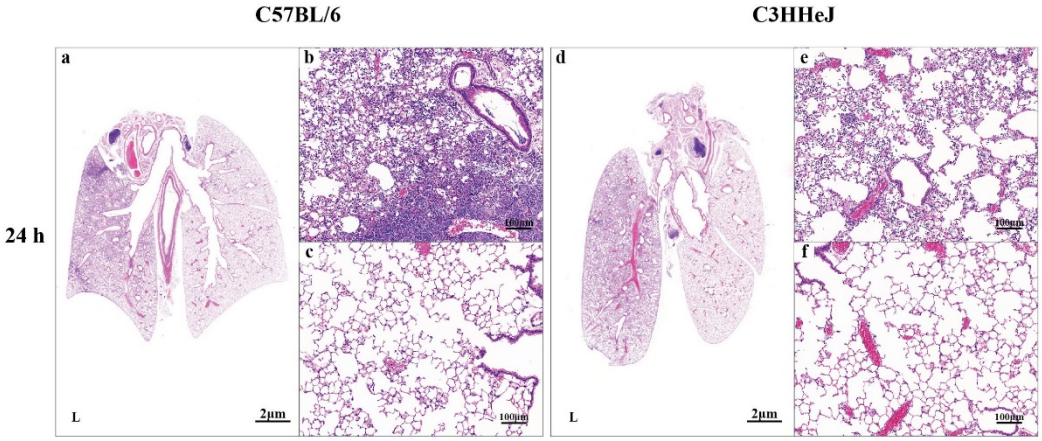

Figure 4 Unilateral live bacteria inoculation: C57BL/6 mice received 15μl of 5 MCF *P. aeruginosa*, a prominent abscess full of *P. aeruginosa* bacteria at the apex of the left lung was formed 24 hours later, but only bronchiectasis like pathology change developed (a, b). On the contrary, 15μl of 0.5 MCF *P. aeruginosa* inoculation had caused a prominent centriacinar emphysema in C3HHeJ mice.

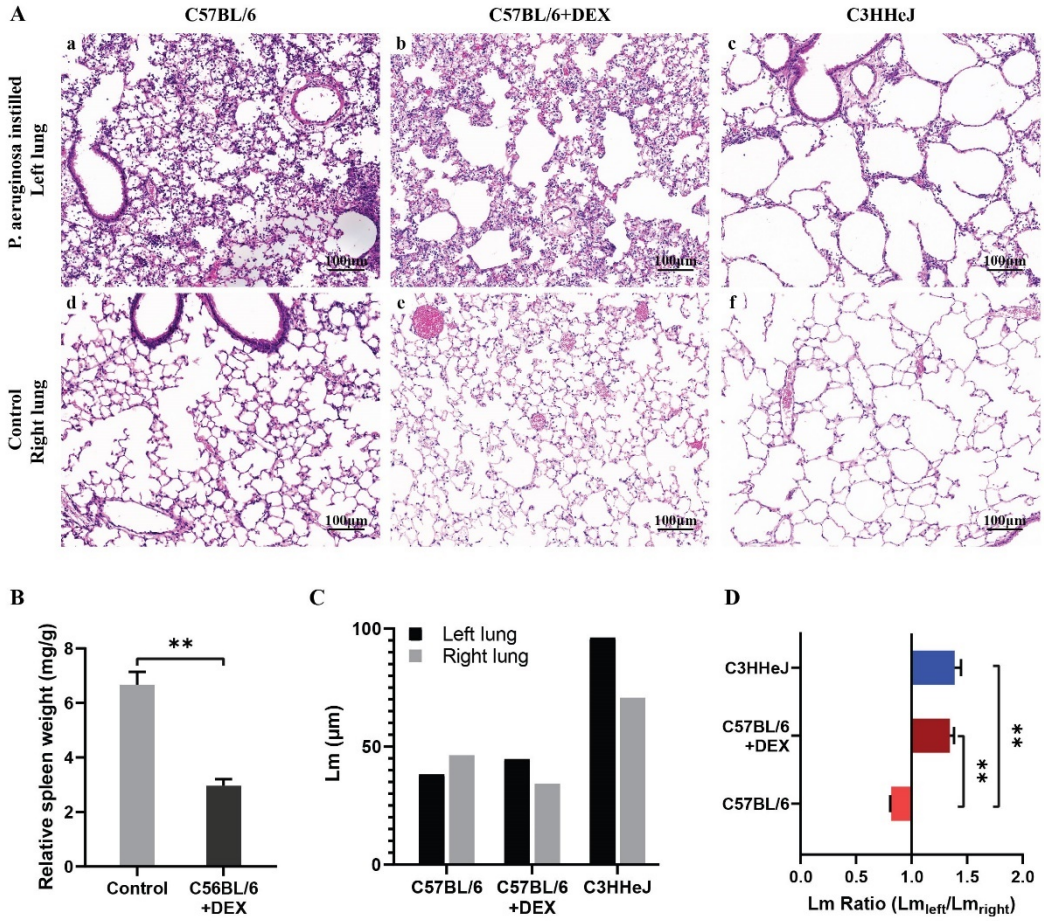

Figure 5 Unilateral live bacteria inoculation in immunosuppressed C57BL/6: C57BL/6 mice were treated with dexamethasone (DEX) for a consecutive 5 days, an obvious decrease of the relative spleen weight meant successful modeling of hypoimmunity (B). Normal C57BL/6 mice, C57BL/6 + DEX mice and C3HHeJ mice were inoculated with 30μl of 2 MCF *P. aeruginosa* and sacrificed 9 hours later (A). Centriacinar pulmonary emphysema appeared in both C57BL/6+DEX mice and C3HHeJ mice, but not in normal C57BL/6 mice. Representative Lm of three mice (A) revealed that the alveolar diameter had decreased in left lung of C57BL/6 (C). A comparison of Lm ratios between different groups shows *P. aeruginosa* infection caused airspace enlargement in two immunocompromised mice group but alveolar collapse and lung compression in normal C57BL/6 group. The data represent the mean ± SEM of four animals. *P < .05; **P < .01; ***P< .001;