Evaluation of the antiviral effect of chlorine dioxide (ClO_2) using a vertebrate model inoculated with avian coronavirus

Zambrano-Estrada, Xóchitl[a], Domínguez-Sánchez, Carlos[b], Banuet-Martínez, Marina[b], Guerrero de la Rosa, Fabiola[b], García-Gasca, Teresa[c], Prieto-Valiente, Luis[d], Acevedo-Whitehouse, Karina[b]

[a] Laboratory of Veterinary Diagnostic Pathology. School of Natural Sciences. Autonomous University of Queretaro. Av. De las Ciencias S/N. Juriquilla, Queretaro. Qro. C.P.76230. Mexico

[b] Unit for Basic and Applied Microbiology. School of Natural Sciences. Autonomous University of Queretaro. Anillo Vial Fray Junípero Serra, Querétaro, Qro. C.P. 76140, Mexico

[c] Laboratory of Cellular Biology. School of Natural Sciences. Autonomous University of Queretaro. Av. De las Ciencias S/N. Juriquilla, Queretaro. Qro. C.P. 76230. Mexico

[d] Bioestadística Médica y Metodología de la Investigación, Análisis Estadístico y Big Data, Universidad Católica de Murcia. Av. de los Jerónimos, 135 Guadalupe de Maciascoque Murcia, 30107. Spain

Corresponding author: Karina Acevedo-Whitehouse (karina.acevedo.whitehouse@uaq.mx)

Abstract

Background: The need for safe and effective antiviral treatments is pressing given the number of viral infections that are prevalent in animal and human populations, often causing devastating economic losses and mortality. Informal accounts of anecdotal use of chlorine dioxide (ClO_2), a well-known disinfectant and antiseptic, in COVID-19 patients has raised concern about potential toxicity, but also raises the question that ClO_2 might elicit antiviral effects, a possibility that has never been examined *in vivo* in any animal model. Here, we challenged the hypothesis that ClO_2 decreases the viral load and virus-induced mortality in a vertebrate model. For this, we determined viral load, virus-induced lesions and mortality in 10-day old chick embryos inoculated with 10^4 mean EID_{50}/mL of attenuated Massachusetts and Connecticut avian coronavirus (IBV) strains.

Results: The ClO_2 treatment had a marked impact on IBV infection. Namely, viral titres were 2.4-fold lower and mortality was reduced by half in infected embryos that were treated with ClO_2. Infection led to developmental abnormalities regardless of treatment. Lesions typical of IBV infections were observed in all inoculated embryos, but severity tended to be significantly lower in ClO_2-treated embryos. We found no gross or microscopic evidence of toxicity caused by ClO_2 at the doses used herein.

Conclusions: Our study shows that ClO_2 could be a safe and viable way of treating and mitigating the effects of avian coronavirus infections, and raises the possibility that similar effects could be observed in other organisms.

Keywords

Chlorine dioxide, ClO_2, coronavirus, IBV, antiviral, chick embryo

Background

To date, despite advances in the identification of compounds with antiviral activity, the available repertoire of antiviral drugs is insufficient. Given the number of endemic viruses that impact the health of wild and domestic animals as well as human populations the need for effective and safe antivirals is urgent. The COVID19 pandemic has evidenced this need; since its start in January 2020, a steep rise in cases and associated mortality, mounting pressure on health services worldwide, and a marked damage to the economy of most countries [1, 2] warrants rigorous, unbiased investigation of compounds with potential antiviral action.

The surge in COVID19 cases and the lack of effective treatments have led to a growing number of informal reports and testimonials across social networks regarding the oral and intravenous use of chlorine dioxide (ClO_2) solution as an efficacious treatment of COVID19. In an unprecedented move, the Senate of Bolivia authorized the extraordinary use of ClO_2 to "manufacture, sell, supply and use ClO_2 to prevent and treat COVID19" (law PL N° 219/2019-2020 CS approved 15 July 2020). This situation has sparked concern from health agencies of various countries regarding the potential toxicity of using this disinfectant as a treatment, given that ClO_2 has strong oxidative properties. Chlorine dioxide has been known since 1946 for its broad antimicrobial properties [3], and it is commonly used to purify water for human consumption, decontaminate produce and other food items [4], and disinfect surgical instruments [5]. According to the Food and Drug Administration (FDA) of the US, consuming ClO_2 can lead to adverse effects such as 'vomiting, diarrhoea, dehydration, abdominal pain, metahemaglobinemia and systemic failures that could potentially lead to death'. However, an impartial review of the scientific peer-reviewed literature reveals few case reports of human patients presenting adverse effects after consumption of ClO_2, none of which were fatal, and reversed completely after treatment [6–9]. Published studies on

ClO_2 toxicity have reported null to mild effects in adult humans and other animals [10–12] and have stressed that toxicity is strongly dose-dependent [12–14].

There is evidence of virucidal activity of ClO_2 against echovirus [15], enterovirus [16], poliovirus [17], rotavirus [18], norovirus [19, 20], calicivirus [19], and coronavirus [21]. However, there are few publications that explore antiviral effects *in vitro* and *in vivo*. One of the few published studies found that mice exposed to influenza A virus in an environment that contained aerosolized ClO_2 had significantly lower mortality than mice that were solely exposed to Influenza A virus [22]. The authors reported that the antiviral effect was due to denaturation of hemagglutinin and neuraminidase glycoproteins, a finding that concurs with previous studies that explain the virucidal mechanism of action of ClO_2 due to oxidation of amino acid residues that are key for cell entry [23–25]. More recently, the antiviral mechanism of action of ClO_2 was investigated *in vitro* using pig alveolar macrophages and MARC-145 cells exposed to the porcine reproductive and respiratory syndrome virus (PRRSV1), finding that the chemical also inhibits the synthesis of pro-inflammatory molecules that contribute to the pathogenesis of this disease [26]. The authors concluded that viral synthesis of RNA and proteins was impeded by ClO_2, leading to a reduction in viral replication. Despite these studies, to date there has been no published report of an *in vivo* assessment of the antiviral effect of ClO_2. Here, we have investigated the effect of a ClO_2 solution in 10-day old chick embryos inoculated with attenuated avian infectious bronchitis coronavirus (IBV) Massachusetts and Connecticut vaccine strains, which are pathogenic for birds during their embryonic stages of development [27].

Results

Avian coronavirus RNA was detected in all of the embryos that were inoculated with the vaccine (n=15, in all cases Cq <40). The viral load decreased significantly with increasing ClO_2 (p=**0.009** for

linear trend; Fig. 1), doses being 2.4 times higher in the untreated embryos. The average viral load of ClO_2-treated chicks was $10^{4.3}$/mL, range: $10^{3.66}$ – $10^{5.03}$ and of untreated chicks was $10^{4.83}$/mL, range: $10^{4.52}$ – $10^{5.01}$, respectively (Tukey HSD, Group E *vs*. F, p = 0.03). There were no differences in the viral load between both ClO_2-treated groups (p>0.05).

Mortality differed significantly between virus-inoculated (46.7%) and virus-free embryos (6.7%) (Fisher's exact p = 0.018), (Fig. 2). In the viral-inoculated groups, 3/10 (30 %) embryos treated with ClO_2 and 4/5 (80 %) untreated embryos died (Groups D, E and F, respectively). (Fisher's exact p = 0.119).

Body mass, embryonic axis length and femur length differed between the virus-inoculated and virus free-groups, regardless of ClO_2 treatment. All of the virus-inoculated embryos exhibited dwarfing and had, on average, 38% lower mass (t = 21.15, df = 29.40, p = 2.2 x 10^{-16}; Fig. 3A), 10% shorter axis length (t = 58.43, df = 29.26, p = 2.2 x 10^{-16}; Fig. 3B), and 20% shorter femur length (t = 8.49, df = 23.34, p = 1.4 x 10^{-8}; Fig 3C) than the virus-free groups. When analysing growth in the virus-inoculated groups, mass was significantly higher in embryos that were treated with ClO_2 (t = -2.74, df = 12.98, p = 0.017). Body length of virus-inoculated chicks did not vary according to ClO_2 treatment (p > 0.1). See supplementary material for photographs of the embryos.

Lesions previously described in embryos infected with avian coronavirus were observed at post mortem examination. Namely, curling, the presence of white caseous material (urates), thickened amnion and allantoic membranes that adhered to the embryos, oedematous serous membranes, epidermal congestion, and subcutaneous haemorrhage (Table 2). Virus-inoculated embryos treated with ClO_2 had a lower risk of epidermal congestion (RR = 0.4; Wald 95% CI: 0.187- 0.855; p = 0.04), haemorrhage (RR = 0.1; Wald 95% CI: 0.016 - 0.642; p = 0.002), curling (RR = 0.019; Wald 95% CI: 0.125 - 0.844; p = 0.017) and thickened membranes (RR = 0; p = 0.003) than untreated

infected embryos. All the embryos had a pale liver and mildly congested lungs, regardless of their experimental group. Pale enlarged kidneys were observed in the virus-inoculated groups but not in the virus-free groups, regardless of ClO_2-treatment (see Table 2).

Microscopic lesions compatible with avian IBV infection were observed in various organs in all virus-inoculated groups (Fig. 4). The severity of the lesions was either similar or slightly lower in the embryos that had been treated with ClO_2 than in the embryos that did not receive any treatment (Table 3). Two exceptions were the kidneys and the duodenum. In the kidneys, swelling and degeneration of renal tubular epithelium was more common and more severe in the infected chicks that were administered ClO_2 than in the infected embryos that did not receive ClO_2, although the former presented mitotic cells. The duodenal villi of the embryos in the IBV-infected groups were longer (ANOVA; $F_{5,18} = 5.62$, $p = 0.003$), and their base was wider (ANOVA; $F_{5,18} = 13.65$, $p = 1.39 \times 10^{-05}$) than embryos from the none-infected groups, and they were moderately congested. Duodenal villous atrophy varied amongst groups (ANOVA; $F_{5,18} = 5.71$, $p = 0.003$) and *post-hoc* comparisons revealed that the significant differences were E *vs.* B ($p = 0.021$) and E *vs.* C ($p = 0.001$). The percent of bursal lymphoid tissue decreased markedly in the virus-inoculated embryos (ANOVA; $F_{5,12} = 3.58$, $p = 0.033$; see Fig. 4). Virus-inoculated embryos showed mild apoptosis in the thymus and heterophilic infiltration. Amongst the six experimental groups, all of the embryos examined presented subacute heterophilic bursitis, and pulmonary interstitial multifocal heterophilic foci with congestion (Table 3).

There were no observable alterations to the architecture and integrity of the tissues of non-infected embryos that were administered ClO_2 (Experimental groups B and C), nor was any difference in the area (μm^2) of the thyroid ($p>0.1$). ClO_2-treated groups showed a slightly higher myeloid to erythroid ratio in the bone marrow than the experimental control group and the viral

control group, although the difference was not statistically significant (ANOVA; $F_{5,15} = 2.33$, $p = 0.094$).

Discussion

We have investigated the antiviral effect of chlorine dioxide (ClO_2) using avian infectious bronchitis coronavirus (IBV)-infected chick embryos as models. At the concentrations used (30 ppm and 300 ppm), both below the reported NOAEL [13], we observed a reduction in viral titre in infected embryos that were treated with ClO_2. Furthermore, mortality decreased substantially in the ClO_2-treated embryos, although alterations to chick development were prevalent regardless of treatment.

Virulent avian IBV strains typically have a burst size of 10 to 100 infective units per cell [28], which can reach peak virus titres of $10^{6.5}$–$10^{8.5}$ $TCID_{50}$ after 36 hours [29]. The vaccine strains used here have lower replication efficiencies as they are attenuated [30], but they are capable of replicating and causing damage in chick embryos [27]. With 2,000 infective units (200 µl of 10^4 infective units/mL) inoculated into each embryo, the ClO_2 treatments decreased viral load 2.4-fold compared to the infected non-treated embryos, representing an average difference of 42,711 infective units. This result could be explained by two non-mutually exclusive mechanisms. Firstly, direct destruction or neutralization of the virions exposed to ClO_2 could have occurred by denaturing of envelope glycoproteins following oxidation of amino acid residues [22, 23, 25]. Secondly, viral replication efficiency could have decreased due to ClO_2–induced biochemical changes in the extra- or intracellular milieu, impeding the synthesis of viral RNA and proteins [26, 31].

The effects of reduced viral titres in the infected embryos were evident, with a 50 to 75% reduction in mortality in the treated embryos treated with 300 ppm and 30 ppm of ClO_2,

respectively. However, developmental abnormalities were observed in the majority of the infected embryos, including those that received ClO_2 treatment. Namely, dwarfing, assessed by body mass, axis length, and femur length were significantly lower in all infected embryos, as expected to occur in IBV infections [32]. In contrast, curling [33, 34] was virtually absent in the embryos that received ClO_2 after infection. Lesions associated con IBV infection [35, 36] were observed in most of the infected embryos, including those that were administered ClO_2. However, for most of these lesions, severity was lower or similar in the ClO_2-treated groups. One exception was in the kidneys, where nephrosis was more severe and frequent in the IBV-infected embryos treated with ClO_2. Nephrosis is unlikely to have occurred due to ClO_2 treatment *per se*, given that none of the uninfected embryos that were administered ClO_2 showed kidney abnormalities. Similarly, atrophy of the duodenal villi was highest in the inoculated group that was administered a high dose of ClO_2, but absent in the non-infected groups that only received ClO_2. If duodenal atrophy and nephropathogenicity in IBV-infected embryos are mitigated by inflammatory responses [37], it is possible that the observed damage is due to ClO_2-driven downregulation of acute inflammation that allowed virion replication in the tubular epithelium and in the duodenal villi. This scenario could be plausible if we consider that ClO_2-treated pig alveolar macrophages and African green monkey kidney cells infected with the porcine reproductive and respiratory syndrome virus (PRRSV1) downregulate pro-inflammatory cytokines IL-1, IL-6 and TNF-α [26]. There are two drugs, based on chlorite, whose describe mechanism of action might be similar to that elicited by ClO_2. One is the drug NP001 (a pH-adjusted stabilized form of $NaClO_2$) exerts strong anti-inflammatory responses by inhibiting macrophage activation in humans, even after a single dose [38]. In turn, WF10 (tetrachlorodecaoxyde, $Cl_4H_2O_{11}$), an oxidizing agent that contains 63.0 mmol/L chlorite and 56.4 mmol/L chloride [39] induces apoptosis of inflammatory cells and downregulates pro-inflammatory genes [40, 41]. More studies will be needed to establish whether the effect of ClO_2

on IBV-infected chicks is due to similar mechanisms. Interestingly, the affected renal tubules of the chick embryos had mitotic cells, suggestive of regeneration as a reparative response to damage of the renal tubular epithelium [42–44]. This possibility will need to be explored further in the animal model used in our study. Unfortunately, knowledge of IBV pathogenesis, immune responses and tissue reparation in the embryonated egg is limited. In hatched birds, IBV can impact lymphocyte populations by inducing apoptosis, thus impeding virus clearance [45]. We found some evidence of this effect, as the virus-inoculated embryos had a reduced percent of bursal lymphoid tissue.

It is plausible that even though ClO_2 limited viral replication, given that the embryos were only administered a single dose of ClO_2 solution, not all virions were eliminated. The viruses that remained viable after administration of the ClO_2 were able to replicate, yielding lower viral titres, and the damage that they caused to the embryos was less severe and ultimately led to less mortality than in the untreated infected embryos. Repeated administrations of ClO_2 solution might have reduced the viral load further, plausibly leading to even less virus-induced damage, a possibility that we could not explore in this model. However, an important result of our study was the lack of evidence of tissue damage caused by ClO_2 itself. Only one (20%) of the uninfected embryos treated with the high dose of ClO_2 died, and this difference was not statistically significant to the experimental control. It is possible that the death was due to other causes, as a 20% embryo mortality rate is considered normal in aviculture [46, 47].

Conclusions

Chlorine dioxide had an unequivocal antiviral effect in the model system used in this study, with a reduction in viral RNA, virus-induced lesions and mortality and no evidence of toxicity at the doses used herein. Further studies should aim to test the antiviral effect of ClO_2 in hatched chicks, which have a more mature immune system, and where repeated administrations are easier to procure.

However, it is promising that we found an evident effect against IBV without any significant adverse effect or evidence of toxicity to the chick embryos. Much research needs to be done before it is possible to generalize and extrapolate our findings to other viruses and animal hosts.

Methods

We aimed to examine whether chlorine dioxide elicits a measurable antiviral effect *in vivo*, and investigate toxicity associated with the administration of this chemical compound. For this, we selected the chicken embryo as a vertebrate model and avian infectious bronchitis coronavirus (IBV) as a virus model. The protocol that is described below was registered at the School of Natural Sciences of the Autonomous University of Queretaro (Mexico). The study was carried out in compliance with the American Veterinary Medical Association (AVMA) guide for humane treatment of chick embryos and approved by the Autonomous University of Queretaro Research Ethics Committee

Ultrapure ClO_2 solution (3,000 ppm) was prepared by electrolysis of $NaClO_2$, according to the following reaction:

$$NaClO_2 + H_2O + e^- \rightarrow ClO_{2(gas)} + \frac{1}{2}H_{2(gas)}$$

The solution was kept at 4 °C and was used within 5 days of production. Two working solutions were prepared with sterile 0.9% saline solution: a high dose (HD, 300 ppm) and a low dose (LD, 30 ppm). Final concentration was verified using test strips (LaMotte Insta-Test 3002) which allowed qualitative detection between 0 and 500 ppm.

We used 30 10-day old SPF RossxRoss chick embryos (Pilgrims, Mexico) incubated at 38°C and 65-70% humidity [48]. Five chick embryos were assigned to each of the six experimental groups at random and treated according to their group (Table 1). Total sample size in the experimental

group was determined in order to achieve power 80% (type II error: 0.20) with allocation ratio 2/1, effect size of 0.7 and a significance level < 0.05. Embryos were placed at random in the incubator to avoid potential variations in temperature and humidity between the edges and the centre of the incubator. All embryos were inoculated via the chorioallanotic sac, as recommended for avian coronavirus replication [49, 50]. Details on inoculation can be seen as Supplementary Materials.

Seven days after inoculation, embryos were sacrificed according to guidelines on humane treatment and euthanasia of chick embryos over 13 days of age (AVMA 2020). The embryos were placed at 4 °C for 4 h to ensure blood coagulation and avoid contamination of the allantoic fluid [48]. The eggshell over the air chamber was disinfected with 70% ethanol and 3.5% iodine [48] and removed together with the chorioallantoic membrane. Allanotic fluid (750 µl) was collected and stored at −70 °C.

Each embryo was cleaned with distilled water to remove any remaining albumin, vitellus and amniotic fluid. Body mass was determined with a precision scale (±0.1 mg). Embryonic axis length was measured with digital callipers (± 0.1 cm). The body was examined for macroscopic lesions typically caused by avian coronavirus, such as cutaneous haemorrhages, stunting, curving, urate deposits in the kidney and feather alterations [49, 51]. Chick embryos were considered to have died during the experiment when there was evidence of disconnected or detached blood vessels of the chorioallantoic membrane or their organs exhibited imbibition of haemoglobin. Further evidence of mortality was determined by examining the presence of autolysis at microscopic examination.

Both femurs were dissected and their length was determined and averaged with a digital calliper as a surrogate measure of chick development. Samples of all organs and tissues were collected, including those known to be affected by the Massachusetts and Connecticut strains of avian

coronavirus, namely trachea, lung, proventricle, duodenum, liver, kidneys and the Bursa of Fabricius [27, 49, 52, 53], and those reportedly affected by exposure to ClO_2 [13, 54, 55].

Samples were cut longitudinally, immersed in 10% buffered formalin (pH 7.4), paraffin-embedded and sectioned at 3 µm, stained with haematoxylin-eosin and observed under the microscope at 40X and 100X. To assess haematopoietic status, bone marrow preparations were used for a 200-cell differential count to classify the marrow precursors and to determine the myeloid:erythroid (M/E) ratio for each embryo. This ratio was obtained by dividing the sum of all the granulocytic cells by the sum of all the erythrocytic cells [56].

The virus was quantified in the allantoid fluid with an RT-qPCR protocol that targeted a 100 bp fragment of the avian coronavirus N gene with primers IBV-pan_FW-1 (5'-CAG TCC CDG ATG CNT GGT A) and IBV-pan_RV (5'-CC TTW SCA GMA ACM CAC ACT)[57]. Details on the protocol can be seen as Supplementary Materials. We used a cDNA sample extracted from 500 µL of the vaccine as a positive control (the vaccine contained 10^4 mean embryo infective dose (EID_{50})/mL of coronavirus strains Massachusetts and Connecticut). A linear regression was used to calculate the correlation coefficient ($R^2 = 0.99$) and the slope value ($b = -5.062$) of the RNA copy number and Cq values using a 10-fold dilution of the vaccine (10^4 to 10^{-1}; see standard curve in Supplementary material). The number of viral RNA copies (hereafter viral load) was determined by comparing the Cq against this standard curve [57].

Contingency tables were built to investigate differences in the proportion of dead *vs*. live chick embryos between experimental groups. The risk of developing virus-related lesions between treated and un-treated embryos was calculated using Fisher exact tests. Body mass, morphometrics, viral load, and lesion severity were compared among groups by one-way ANOVA and post-hoc Tukey HSD tests. All analyses were performed in R version 3.6.3 [58].

Statement of conflict of interest

The authors declare they do not have any conflict of interest regarding this submission.

Acknowledgments

We thank Luis A. Soto-García and Karla Zamora y Cuevas for their help with photographic and video documentation of the experiment.

Funding

This research did not receive any specific grant from funding agencies in the public, commercial, or not-for-profit sectors.

Author contributions

K.A-W. and T.G-G. conceived the idea. K.A-W. supervised the experiments and wrote the manuscript. X.Z-E. performed all gross examinations and histopathology analyses. C.D-S. conducted molecular assays and artwork. M.B-M. and F.G-D performed the inoculation experiments and assisted during necropsies. K.A-W. and L.P-V conducted the statistical analyses. All authors participated in the discussion of results.

References

1. Duan H, Wang S, Yang C. Coronavirus: limit short-term economic damage. Nature. 2020.

2. Nicola M, Alsafi Z, Sohrabi C, Kerwan A, Al-Jabir A, Iosifidis C, et al. The socio-economic implications of the coronavirus pandemic (COVID-19): A review. International Journal of Surgery. 2020.

3. Sigstam T, Rohatschek A, Zhong Q, Brennecke M, Kohn T. On the cause of the tailing phenomenon during virus disinfection by chlorine dioxide. Water Res. 2014;48:82–9.

4. López-Gálvez F, Randazzo W, Vásquez A, Sánchez G, Decol LT, Aznar R, et al. Irrigating Lettuce with Wastewater Effluent: Does Disinfection with Chlorine Dioxide Inactivate Viruses? J Environ Qual. 2018;47:1139–45.

5. Doona CJ, Feeherry FE, Setlow P, Malkin AJ, Leighton TJ. The Portable Chemical Sterilizer (PCS), D-FENS, and D-FEND ALL: novel chlorine dioxide decontamination technologies for the military. J Vis Exp. 2014;:e4354.

6. Loh JMR, Shafi H. Kikuchi-Fujimoto disease presenting after consumption of "Miracle Mineral Solution" (sodium chlorite). BMJ Case Rep. 2014;2014.

7. Bathina G, Yadla M, Burri S, Enganti R, Prasad Ch R, Deshpande P, et al. An unusual case of reversible acute kidney injury due to chlorine dioxide poisoning. Ren Fail. 2013;35:1176–8.

8. Romanovsky A, Djogovic D, Chin D. A case of sodium chlorite toxicity managed with concurrent renal replacement therapy and red cell exchange. J Med Toxicol Off J Am Coll Med Toxicol. 2013;9:67–70.

9. Kishan H. Chlorine dioxide-induced acute hemolysis. Journal of medical toxicology : official journal of the American College of Medical Toxicology. 2009;5:177.

10. Lubbers JR, Chauan S, Bianchine JR. Controlled clinical evaluations of chlorine dioxide, chlorite and chlorate in man. Environ Health Perspect. 1982;46:57–62.

11. Akamatsu A, Lee C, Morino H, Miura T, Ogata N, Shibata T. Six-month low level chlorine dioxide gas inhalation toxicity study with two-week recovery period in rats. J Occup Med Toxicol. 2012;7:2.

12. Ma J-W, Huang B-S, Hsu C-W, Peng C-W, Cheng M-L, Kao J-Y, et al. Efficacy and Safety Evaluation of a Chlorine Dioxide Solution. Int J Environ Res Public Health. 2017;14.

13. Bercz JP, Jones L, Garner L, Murray D, Ludwig DA, Boston J. Subchronic toxicity of chlorine dioxide and related compounds in drinking water in the nonhuman primate. Environ Health Perspect. 1982;46:47–55.

14. Hose JE, Di Fiore D, Parker HS, Sciarrotta T. Toxicity of chlorine dioxide to early life stages of marine organisms. Bull Environ Contam Toxicol. 1989;42:315–9.

15. Zhong Q, Carratalà A, Ossola R, Bachmann V, Kohn T. Cross-Resistance of UV- or Chlorine Dioxide-Resistant Echovirus 11 to Other Disinfectants. Front Microbiol. 2017;8:1928.

16. Jin M, Shan J, Chen Z, Guo X, Shen Z, Qiu Z, et al. Chlorine dioxide inactivation of enterovirus 71 in water and its impact on genomic targets. Environ Sci Technol. 2013;47:4590–7.

17. Simonet J, Gantzer C. Degradation of the Poliovirus 1 genome by chlorine dioxide. J Appl Microbiol. 2006;100:862–70.

18. Chen YS, Vaughn JM. Inactivation of human and simian rotaviruses by chlorine dioxide. Appl Environ Microbiol. 1990;56:1363–6.

19. Montazeri N, Manuel C, Moorman E, Khatiwada JR, Williams LL, Jaykus L-A. Virucidal Activity of Fogged Chlorine Dioxide- and Hydrogen Peroxide-Based Disinfectants against Human Norovirus and Its Surrogate, Feline Calicivirus, on Hard-to-Reach Surfaces. Front Microbiol. 2017;8:1031.

20. Lim MY, Kim J-M, Ko G. Disinfection kinetics of murine norovirus using chlorine and chlorine dioxide. Water Res. 2010;44:3243–51.

21. Wang X-W, Li J-S, Jin M, Zhen B, Kong Q-X, Song N, et al. Study on the resistance of severe acute respiratory syndrome-associated coronavirus. J Virol Methods. 2005;126:171–7.

22. Ogata N, Shibata T. Protective effect of low-concentration chlorine dioxide gas against influenza A virus infection. J Gen Virol. 2008;89 Pt 1:60–7.

23. Ison A, Odeh IN, Margerum DW. Kinetics and mechanisms of chlorine dioxide and chlorite oxidations of cysteine and glutathione. Inorg Chem. 2006;45:8768–75.

24. Stewart DJ, Napolitano MJ, Bakhmutova-Albert E V, Margerum DW. Kinetics and mechanisms of chlorine dioxide oxidation of tryptophan. Inorg Chem. 2008;47:1639–47.

25. Noss CI, Olivieri VP. Disinfecting capabilities of oxychlorine compounds. Appl Environ Microbiol. 1985;50:1162–4.

26. Zhu Z, Guo Y, Yu P, Wang X, Zhang X, Dong W, et al. Chlorine dioxide inhibits the replication of porcine reproductive and respiratory syndrome virus by blocking viral attachment. Infect Genet Evol J Mol Epidemiol Evol Genet Infect Dis. 2019;67:78–87.

27. Tsai C-T, Tsai H-F, Wang C-H. Detection of infectious bronchitis virus strains similar to Japan in Taiwan. J Vet Med Sci. 2016;78:867–71.

28. Robb JA, Bond CW. Coronaviridae. In: Fraenkel-Conrat H, Wagner RR, editors. Comprehensive Virology. Boston: Springer; 1979.

29. Otsuki K, Noro K, Yamamoto H, Tsubokura M. Studies on avian infectious bronchitis virus (IBV). II. Propagation of IBV in several cultured cells. Arch Virol. 1979;60:115–22.

30. Tsai C-T, Wu H-Y, Wang C-H. Genetic sequence changes related to the attenuation of avian infectious bronchitis virus strain TW2575/98. Virus Genes. 2020;56:369–79.

31. Enjuanes L, Almazán F, Sola I, Zuñiga S. Biochemical aspects of coronavirus replication and virus-host interaction. Annu Rev Microbiol. 2006;60:211–30.

32. Balasubramaniam A, Sukumar K, Suresh P, Puvarajan B. Molecular characterisation of membrane glycoprotein and 5b protein of nephropathogenic infectious bronchitis virus. Vet World. 2013.

33. Wickramasinghe INA, de Vries RP, Gröne A, de Haan CAM, Verheije MH. Binding of avian coronavirus spike proteins to host factors reflects virus tropism and pathogenicity. J Virol. 2011;85:8903–12.

34. Mork A-K, Hesse M, Abd El Rahman S, Rautenschlein S, Herrler G, Winter C. Differences in the tissue tropism to chicken oviduct epithelial cells between avian coronavirus IBV strains QX and B1648 are not related to the sialic acid binding properties of their spike proteins. Vet Res. 2014;45:67.

35. Butcher GD, Winterfield RW, Shapiro DP. Pathogenesis of H13 nephropathogenic infectious bronchitis virus. Avian Dis. 1990;34:916–21.

36. Cook JKA, Jackwood M, Jones RC. The long view: 40 years of infectious bronchitis research. Avian Pathol. 2012;41:239–50.

37. Chhabra R, Ball C, Chantrey J, Ganapathy K. Differential innate immune responses induced by classical and variant infectious bronchitis viruses in specific pathogen free chicks. Dev Comp Immunol. 2018;87:16–23.

38. Miller RG, Zhang R, Block G, Katz J, Barohn R, Kasarskis E, et al. NP001 regulation of macrophage activation markers in ALS: a phase I clinical and biomarker study. Amyotroph Lateral Scler Frontotemporal Degener. 2014;15:601–9.

39. Veerasarn V, Khorprasert C, Lorvidhaya V, Sangruchi S, Tantivatana T, Narkwong L, et al. Reduced recurrence of late hemorrhagic radiation cystitis by WF10 therapy in cervical cancer patients: a multicenter, randomized, two-arm, open-label trial. Radiother Oncol J Eur Soc Ther Radiol Oncol. 2004;73:179–85.

40. Giese T, McGrath MS, Stumm S, Schempp H, Elstner E, Meuer SC. Differential effects on innate

versus adaptive immune responses by WF10. Cell Immunol. 2004;229:149–58.

41. Yingsakmongkol N, Maraprygsavan P, Sukosit P. Effect of WF10 (immunokine) on diabetic foot ulcer therapy: a double-blind, randomized, placebo-controlled trial. J foot ankle Surg Off Publ Am Coll Foot Ankle Surg. 2011;50:635–40.

42. Fujigaki Y. Different modes of renal proximal tubule regeneration in health and disease. World J Nephrol. 2012;1:92–9.

43. Lombardi D, Becherucci F, Romagnani P. How much can the tubule regenerate and who does it? An open question. Nephrol Dial Transplant Off Publ Eur Dial Transpl Assoc - Eur Ren Assoc. 2016;31:1243–50.

44. Toback FG. Regeneration after acute tubular necrosis. Kidney Int. 1992;41:226–46.

45. Caron LF. Etiology and immunology of infectious bronchitis virus. Rev Bras Cienc Avic. 2010.

46. Romanoff AL. Spontaneous malformations. In: Romanoff AL, editor. Pathogenesis of the avian embryo: an analysis of causes of malformations and prenatal death. New York: Wiley Interscience; 1972.

47. Fasenko GM, O'Dea EE. Evaluating broiler growth and mortality in chicks with minor navel conditions at hatching. Poult Sci. 2008.

48. Guy JS. Isolation and propagation of coronaviruses in embryonated eggs. Methods Mol Biol. 2015.

49. Escorcia M, Fortoul TI, Petrone VM, Galindo F, López C, Téllez G. Gastric gross and microscopic lesions caused by the UNAM-97 variant strain of infectious bronchitis virus after the eighth passage in specific pathogen-free chicken embryos. Poult Sci. 2002;81:1647–52.

50. Jordan FT, Nassar TJ. The combined influence of age of embryo and temperature and duration of incubation on the replication and yield of avian infectious bronchitis (IB) virus in the developing chick embryo. Avian Pathol. 1973;2:279–94.

51. Alexander DJ, Senne DA. A Laboratory Manual for the Isolation, Identification and Characterization of Avian Pathogens. 2008.

52. Cavanagh D. Severe acute respiratory syndrome vaccine development: experiences of vaccination against avian infectious bronchitis coronavirus. Avian Pathol. 2003;32:567–82.

53. Cavanagh D. Coronavirus avian infectious bronchitis virus. Vet Res. 2007;38:281–97.

54. Harrington RM, Shertzer HG, Bercz JP. Effects of chlorine dioxide on thyroid function in the African green monkey and the rat. J Toxicol Environ Health. 1986;19:235–42.

55. Environmental Protection Agency. Toxicological Review of Chlorine dioxide and Chlorite. Washington, D.C.; 2000. http://www.epa.gov/iris.

56. Schalm OW, Jain NC. Schalm's veterinary hematology. 4th editio. Philadelphia: Lea & Febiger; 1986.

57. Naguib MM, El-Kady MF, Lüschow D, Hassan KE, Arafa A-S, El-Zanaty A, et al. New real time and conventional RT-PCRs for updated molecular diagnosis of infectious bronchitis virus infection (IBV) in chickens in Egypt associated with frequent co-infections with avian influenza and Newcastle Disease viruses. J Virol Methods. 2017;245:19–27.

58. R Core Team. R Development Core Team. R A Lang Environ Stat Comput. 2016.

Figure legends

Figure 1. Virus RNA copy number in the allantoic fluid of the infected embryos per treatment group. Virus copy number was calculated by the geometric mean of the triplicate Cq value referred to the standard curve (see methods). Experimental groups D to F contained virus-inoculated embryos (D: Low dose of ClO_2, E: High dose of ClO_2, F. Viral control). For details on treatments, see Table 1.

Figure 2. Chick embryo mortality during the experiment. Experimental groups A to C contained virus-free embryos (A: Experimental control, B: Low dose of ClO_2, C: High dose of ClO_2); experimental groups D to F contained virus-inoculated embryos (D: Low dose of ClO_2, E: High dose of ClO_2, F. Viral control). For details on treatments, see Table 1.

Figure 3. Chick embryo development at the end of the experiment (day 17 of incubation). A) mass, B) body axis, C) femur length. Experimental groups A to C contained virus-free embryos (A: Experimental control, B: Low dose of ClO_2, C: High dose of ClO_2); experimental groups D to F contained virus-inoculated embryos (D: Low dose of ClO_2, E: High dose of ClO_2, F. Viral control). For details on treatments, see Table 1.

Figure 4. Histology of selected tissues from 17-day-old chick embryos. In each row, microphotograph pairs show H&E-stained representative tissues of non-infected (left) and infected embryos (right), A) Bursa of Fabricio (100X). Infected embryos showed severe lymphoid depletion, with approximately 10% of active lymphoid tissue and abundant heterophils. B) Bone marrow (400 X). Infected embryos showed an increase in erythroid cellularity ne, C) Spleen (400 X), Infected embryos showed reticuloendothelial hyperplasia, D) Duodenum (400 X). Infected embryos showed mild villous atrophy, E) Proventricle (40X). Infected embryos showed epithelial hyperplasia with desquamation and hyaline material, F) Proventricle (400X). Image shows the increased length of the proventricular folds and mitotic cells indicative of epithelial regeneration, G) Kidney (400X). Infected embryos showed swelling, cell detritus and protein within the tubules, and basophilic material compatible with urate crystals, H) Liver (400X). Infected embryos showed glucogenic degeneration, I) Trachea (400X). Infected embryos showed hyperplasia and epithelial degeneration. Scale = 50 µm in all panels except for E (scale = 500 µm).

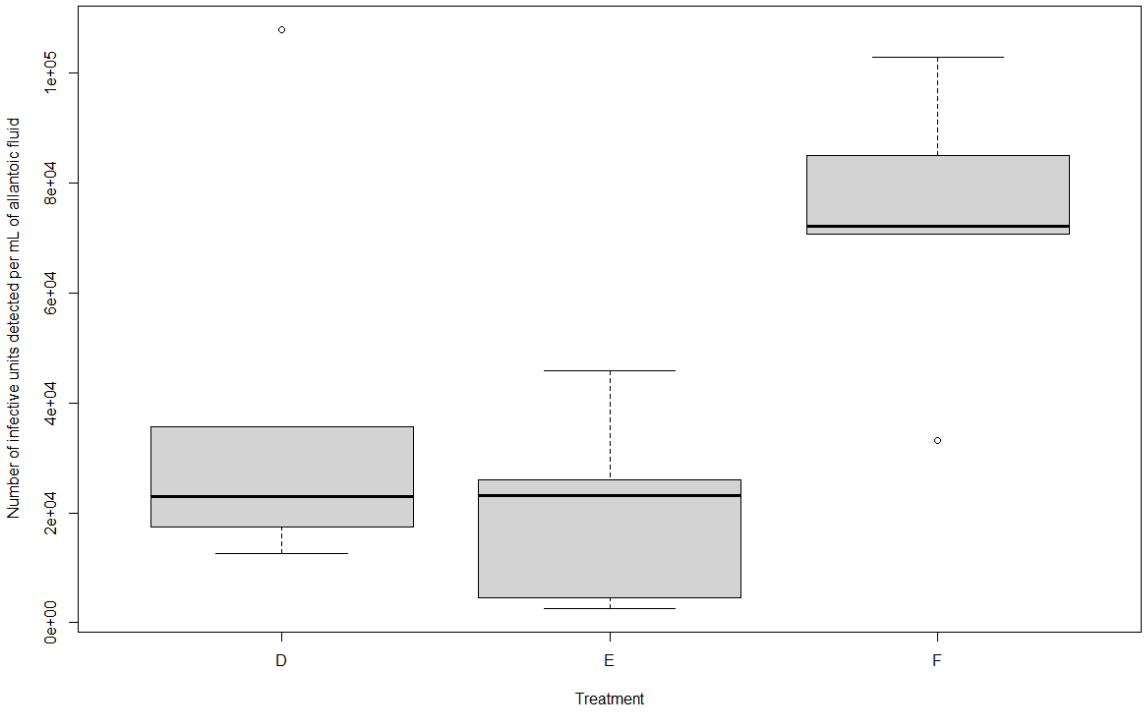
Number of infective units detected per mL of allantoic fluid
0e+00
2e+04
4e+04
6e+04
8e+04
1e+05
D
E
F
Treatment

Fig. 1

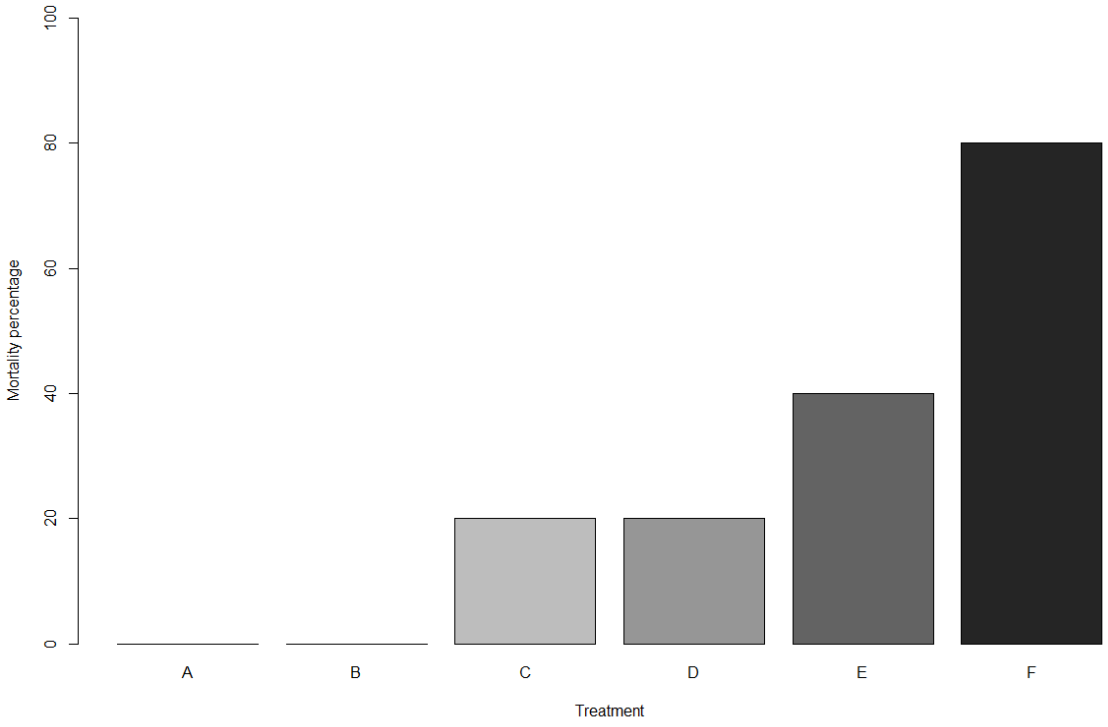

Fig. 2

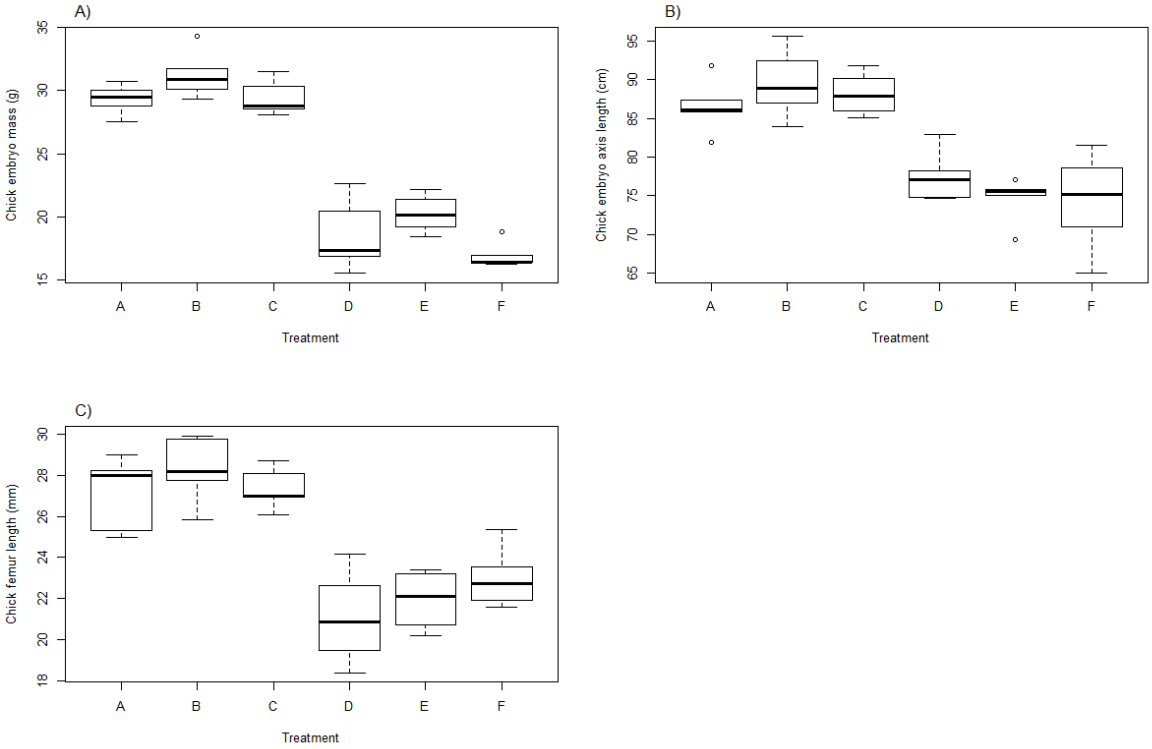
A)
Chick embryo mass (g)
35
30
25
20
15
A
B
C
D
E
F
Treatment
B)
Chick embryo axis length (cm)
95
90
85
80
75
70
65
A
B
C
D
E
F
Treatment
C)
Chick femur length (mm)
30
28
26
24
22
20
18
A
B
C
D
E
F
Treatment

Fig. 3

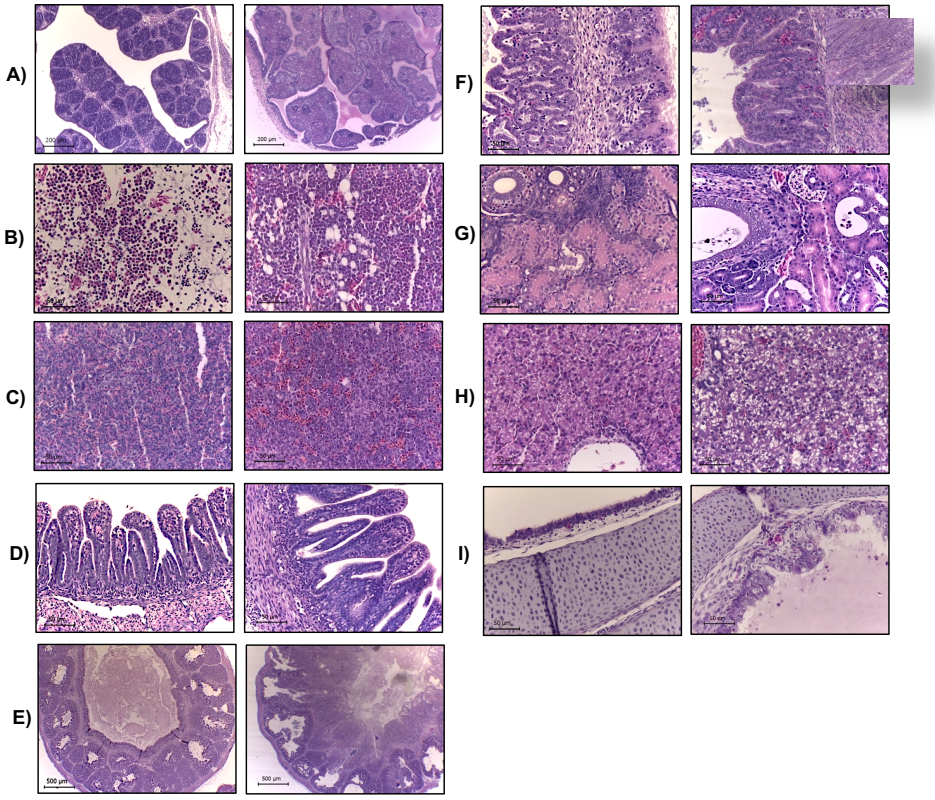

Fig. 4

Table 1. Experimental groups used to assess the *in vivo* antiviral effect of high and low concentrations of ClO2 solution in chick embryos. The table shows the number of embryos included in each group. (LD: Low dose, HD: High dose)

Group	N	Treatment
Group A (Experimental control)	5	200 µl of sterile 0.9% saline solution
Group B (ClO_2 LD)	5	100 µl of sterile ClO_2 solution (30 ppm[1]) and 100 µl of sterile 0.9% saline solution
Group C (ClO_2 HD)	5	100 µl of sterile ClO_2 solution (300 ppm[2]) and 100 µl of sterile 0.9% saline solution
Group D (Virus + ClO_2 LD)	5	100 µl of resuspended avian coronavirus vaccine and 100 µl of sterile ClO_2 solution (30 ppm)
Group E (Virus + ClO_2 HD)	5	100 µl of resuspended avian coronavirus vaccine and 100 µl of sterile ClO_2 solution (300 ppm)
Group F (Viral control)	5	100 µl of resuspended live attenuated avian coronavirus vaccine (Bron Blen® Merial, containing 10^4 of mean embryo infective dose (EID_{50})/mL of coronavirus strains Massachusetts and Connecticut) and 100 µl of sterile 0.9% saline solution

[1] This concentration is 10 times below the no-observed-adverse-effect level (NOAEL; 3.5 mg/kg per day) determined for ClO_2 (Bercz et al. 1982), considering an embryonic mass of 10 g at the time of inoculation.
[2] This concentration is equal to the NOAEL considering an embryonic mass of 10 g at the time of inoculation.

Table 2. Macroscopic abnormalities observed at necropsy in the chick embryos. The table shows the number of embryos in each group that presented each lesion. (LD: Low dose, HD: High dose)

	Dwarfing	Curling	White caseous material	Thickened membranes	Oedema	Epidermal congestion	Pale and enlarged kidneys
Group A (Experimental control)	0/5[f]	0/5[f]	0/5[f]	0/5[f]	0/5	0/5[f]	0/5
Group B (ClO_2 LD)	0/5[f]	0/5[f]	0/5[f]	0/5[f]	0/5	0/5[f]	0/5
Group C (ClO_2 HD)	0/5[f]	0/5[f]	1/5[f]	0/5[f]	0/5	2/5	0/5
Group D (Virus + ClO_2 LD)	5/5[a]	1/5	1/5[f]	0/5[f]	0/5	2/5	5/5[f,a]
Group E (Virus + ClO_2 HD)	5/5[a]	0/5[f]	1/5[f]	0/5[f]	0/5	2/5	3/5[a]
Group F (Viral control)	5/5[a]	4/5[a]	4/5[a]	4/5[a]	1/5	5/5[a]	1/5

[a]: Indicates a significant difference to the experimental control

[f]: Indicates a significant difference to the viral control

Table 3. Microscopic abnormalities related to avian coronavirus infection in the chick embryos. (LD: Low dose, HD: High dose)

	A (Exp. control)	B (ClO_2 LD)	C (ClO_2 HD)	D (Virus + ClO_2 LD)	E (Virus + ClO_2 HD)	F (Viral control)
Trachea	-	Mild hyperplasia	Mild hyperplasia	Karyorexis, focal hyperplasia	Moderate congestion	Mild hyperplasia
Lung	Mild to moderate congestion	Moderate congestion, interstitial oedema	Mild to moderate congestion, interstitial oedema	Moderate to severe congestion, karyolysis	Mild to moderate congestion, moderate oedema	Mild to moderate congestion, severe to moderate oedema
Proventricle	-	-	-	Moderate hyperplasia	Mild hyperplasia	Moderate hyperplasia, mild congestion
Duodenum	-	-	-	Moderate congestion		Mild diffuse congestion, atrophy of intestinal villi
Liver	-	-	-	Gluogenic degeneration, mild congestion	Gluogenic degeneration, mild congestion	Gluogenic degeneration, moderate congestion, periportal eosinophilic material
Kidneys	-	-	-	Degeneration w/ regeneration, congestion, mild heterophilic infiltration, urates	Degeneration w/ regeneration, congestion, mild heterophilic infiltration, urates	Haemorrhage, multifocal heterophilic infiltration, urates
Spleen	-	-	-	Reticuloendothelial hyperplasia	Reticuloendothelial hyperplasia	Reticuloendothelial hyperplasia
Bursa of Fabricius	Subacute heterophilic bursitis	Subacute heterophilic bursitis	Subacute heterophilic bursitis	Subacute heterophilic bursitis	Subacute heterophilic bursitis	Subacute heterophilic bursitis

Evaluation of the antiviral effect of chlorine dioxide (ClO2) using a vertebrate model inoculated with avian coronavirus

Zambrano-Estrada, X.*et al*.

Highlights

- Chlorine dioxide (ClO_2) reduces mortality in chick embryos inoculated with avian infectious bronchitis coronavirus.
- Viral RNA was 2.4-fold lower in the embryos that were treated with ClO_2.
- Microscopic lesions were less severe in ClO_2-treated embryos.
- There was no evidence of toxicity caused by ClO_2 at the doses used.
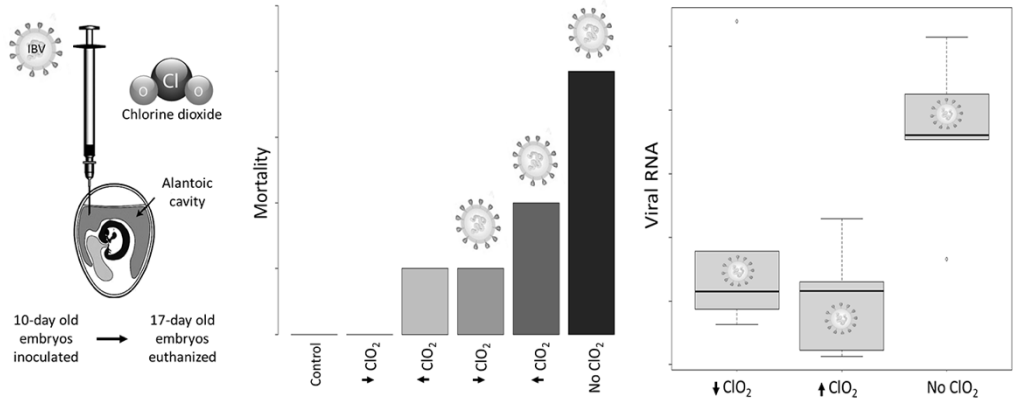
Graphical abstract