Neural substrates of verbal repetition deficits in primary progressive aphasia

Hilary E. Miller[1], Claire Cordella[2], Jessica A. Collins[2], Rania Ezzo[2], Megan Quimby[2], Daisy Hochberg[2], Jason A. Tourville[1], Bradford C. Dickerson[2, 3], & Frank H. Guenther[1,4,5]

[1]Department of Speech, Language, & Hearing Sciences, Boston University, Boston, MA 02215

[2]Frontotemporal Disorders Unit, Department of Neurology, Massachusetts General Hospital & Harvard Medical School, Charlestown, MA 02129

[3]Martinos Center for Biomedical Imaging, Department of Radiology, Massachusetts General Hospital, Charlestown, MA 02129

[4]Department of Biomedical Engineering, Boston University, Boston, MA 02215

[5]The Picower Institute for Learning and Memory, Massachusetts Institute of Technology, Cambridge, MA 02139

Corresponding Author:

Frank H. Guenther

Boston University

Department of Speech, Language, and Hearing Sciences

677 Beacon Street

Boston, MA 02215

guenther@bu.edu

Key words: primary progressive aphasia, phonological working memory, GODIVA model, repetition, cortical thickness

Abstract:

This study examined the relationship between cortical thickness and performance on several verbal repetition tasks in patients with primary progressive aphasia (PPA) in order to test predictions generated by theoretical accounts of phonological working memory (PWM) that predict phonological content buffers in left posterior inferior frontal sulcus (pIFS) and supramarginal gyrus (SMG). Cortical surfaces were reconstructed from magnetic resonance imaging scans from 42 participants diagnosed with PPA. Cortical thickness was measured in a set of anatomical regions spanning the entire cerebral cortex. Correlation analyses were performed between cortical thickness and average score across three PWM related tasks: the Repetition subtest from the Western Aphasia Battery, a forward digit span task, and a backward digit span task. Significant correlations were found between average PWM score across tasks and cortical thickness in left SMG and left pIFS, in support of prior theoretical accounts of PWM. Exploratory whole-brain correlation analyses performed for each of the three behavioral tasks individually revealed a distinct set of positively-correlated regions for each task. Comparison of cortical thickness measures from different PPA subtypes to cortical thickness in age-matched controls further revealed unique patterns of atrophy in the different PPA subtypes.

Introduction

Primary progressive aphasia (PPA) is a neurodegenerative syndrome, usually arising from Alzheimer's disease or Frontotemporal Lobar Degeneration, in which language impairment is the most prominent and initial presenting feature (Mesulam, 2003). Subtypes of PPA further characterize specific patterns of language impairment and expected disease progression (Mesulam et al., 2009; Gorno-Tempini et al., 2011): *semantic-variant PPA (svPPA)* patients demonstrate anomia and impaired single word comprehension; *nonfluent-variant PPA (nfvPPA)* patients demonstrate agrammatism with or without co-occurring apraxia of speech; and *logopenic-variant PPA (lvPPA)* patients demonstrate deficits in lexical retrieval and phonological processing. Cortical thickness measures reveal differential patterns of atrophy across PPA variants (Mesulam et al., 2009, 2012; Rohrer et al., 2010; Sapolsky et al., 2010; Rogalski et al., 2014; Collins et al., 2017), and have been employed to identify neural regions underlying core speech and language domains including articulatory rate, fluency, and semantic and syntactic processing (Sapolsky et al., 2010; Rogalski et al., 2011; Mesulam et al., 2015; Cordella et al., 2019). For example, the characteristic anterior temporal atrophy in svPPA is associated with single-word comprehension abilities, while distinctive left inferior frontal atrophy in nfvPPA correlates with measures of syntactic processing (Amici et al., 2007; Sapolsky et al., 2010; Rogalski et al., 2011). LvPPA is associated with cortical thinning in the temporoparietal junction, with atrophy here also correlated with sentence repetition abilities (Amici et al., 2007; Rogalski et al., 2011; Lukic et al., 2019).

Verbal repetition tasks, such as sentence repetition and digit span tasks, are often used for clinical characterization of the core phonological impairment in lvPPA (Gorno-Tempini et al., 2008, 2011; Foxe et al., 2013; Meyer et al., 2015). However, contradictory evidence suggests that these tasks may not always differentiate lvPPA from other PPA variants or Alzheimer's

disease (Leyton et al., 2014; Beales et al., 2019). Differences in the various verbal repetition tasks used across studies likely contribute to the divergent results. Thus, further investigation of the neural bases of phonological working memory is critical to differentiate underlying neural mechanisms predictive of repetition impairment in PPA patients on common diagnostic tasks.

In this study, we focus on working memory-related predictions based on the Gradient Order Directions into Velocities of Articulators (GODIVA) model, which is a neurocomputational model of the processes involved in the planning and sequencing of multisyllabic utterances (Bohland et al., 2010; Guenther, 2016). According to the model, the content of an upcoming utterance is temporarily stored in two distinct sub-regions of prefrontal cortex: a *metrical structure buffer* in bilateral pre-supplementary motor area (preSMA) and a *phonological content buffer* in left posterior inferior frontal sulcus (pIFS; Bohland & Guenther, 2006). The phonological content buffer is responsible for buffering of phonemes in working memory while earlier portions of the utterance are being articulated. We further posit that the phonological content buffer in left pIFS is distinct from a second phonological buffer located in the left supramarginal gyrus (SMG) that is heavily involved in speech perception and language recognition. We will thus refer to the phonological content buffer in GODIVA as the *phonological output buffer* and the buffer in SMG as the *phonological input buffer*, as shown in Figure 1.

Previous studies investigating repetition in PPA support the involvement of this phonological input buffer in verbal repetition tasks (Amici et al., 2007; Rogalski et al., 2011; Leyton et al., 2012; Lukic et al., 2019). The current study seeks to extend this work to test for the involvement of a phonological output buffer in left pIFS in sentence repetition and digit span working memory tasks, as predicted by GODIVA model. Successful repetition of sentences or

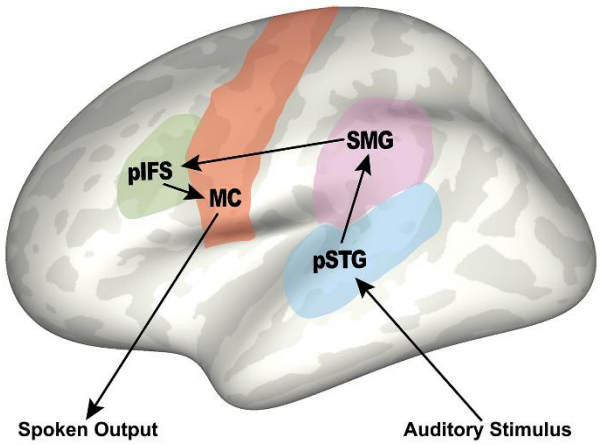

Figure 1. A simplified account of neural processing in verbal repetition tasks showing key left hemisphere brain regions involved: auditory perception in posterior superior temporal gyrus (pSTG), phonological input buffer in supramarginal gyrus (SMG), phonological output buffer in posterior inferior frontal sulcus (pIFS), and generation of movement commands in motor cortex (MC), resulting in spoken output of the presented auditory stimulus.

digit sequences during these tasks requires accurate buffering and sequencing of each phoneme for subvocal rehearsal and eventual spoken output. The proposed phonological output buffer should therefore be heavily involved in these diagnostic tasks. We also include exploratory whole-brain analyses for each of the three repetition tasks to compare the neural correlates of each task.

Methods

The study was approved by the Partners Human Research Committee, the Institutional Review Board of Partners HealthCare. All participants provided written informed consent prior to enrollment in the study.

Diagnostic criteria

Forty-two patients meeting the criteria for PPA were selected from the PPA Longitudinal Cohort of the Massachusetts General Hospital (MGH) Frontotemporal Disorders Unit's Primary Progressive Aphasia Program. Participants in this cohort undergo a comprehensive clinical evaluation as previously described (Sapolsky et al., 2011, 2014). For each participant, we

perform an extensive multidisciplinary assessment including a structured interview of the participant by a neurologist or psychiatrist covering cognition, mood/behavior, sensorimotor function, and daily activities; a neurologic examination, including office-based cognitive testing (for cases in this report, BCD); a speech-language assessment performed by a speech-language pathologist (for cases in this report, MQ or DH), including the Progressive Aphasia Severity Scale (PASS) to specifically assess language impairment from a patient's premorbid baseline (Sapolsky et al., 2014); an MRI scan with T1- and T2-weighted sequences inspected visually by a neurologist. For each participant, a clinician also performs a structured interview with an informant who knows the participant well, augmented with standard questionnaires. For most of the participants in this report, the protocol included the National Alzheimer's Coordinating Center (NACC) Uniform Data Set measures (using version 2.0 previously and currently version 3.0), as well as supplementary measures.

Cases selected for this study had been diagnosed with PPA according to consensus guidelines (Mesulam, 2001; Gorno-Tempini et al., 2011). In accordance with these criteria, all participants exhibited a progressive language impairment with a relative preservation of other cognitive functions. Visual inspection of a clinical MRI ruled out other causes of focal brain damage. No participants harbored a pre-existing psychiatric disorder, other neurological disorder or developmental cognitive disorder. This study included nonfluent variant PPA patients (nfvPPA; N=13), logopenic variant PPA patients (lvPPA; N=14), and semantic variant PPA patients (svPPA; N=15). For 10 of the 13 patients diagnosed with nfvPPA, both of the two primary inclusion criteria (i.e., apraxia of speech and agrammatism) were met (with 2 presenting only with agrammatism and 1 with only apraxia of speech). Detailed speech/language characteristics per diagnostic group are reported in Table 1. For the purposes of

Table 1. Demographic and speech/language characteristics by group, for logopenic variant (lvPPA), nonfluent variant (nfvPPA), and semantic variant (svPPA) patients. CDR = Clinical Dementia Rating; PASS = Progressive Aphasia Severity Score; SD = standard deviation. Differences in group means (post-hoc t-test, $p < 0.05$) from [a]lvPPA, [b]nfvPPA, [c]svPPA
[d]Indicates time in years between diagnosis date and initial study visit
[e]CDR Language subscore and all PASS subtest scores are clinician-rated scores on an interval score where 0 = no impairment; 0.5 = very mild impairment; 1 = mild impairment; 2 = moderate impairment; and 3 = severe impairment.

	lvPPA (n = 14)	**nfvPPA (n = 13)**	**svPPA (n = 15)**
Female, number (%)	8 F (57%)	6 F (46%)	9 F (60%)
Age, y (SD)	71.3 (8.1)	69.4 (8.4)	64.7 (7.3)
Education, y (SD)	16.2 (3.2)	15.8 (3.4)	16.3 (1.9)
Time from Diagnosis[d], y (SD)	0.7 (1.1)	1.0 (2.3)	0.9 (1.1)
Mean CDR Language Box Score[e] (SD)	0.8 (0.4)	0.8 (0.6)	1.1 (0.5)
Mean PASS subdomain scores[e] (SD)			
Articulation	0.1 (0.3)[b]	1.0 (0.9)[a,c]	0.0 (0.1)[b]
Fluency	0.5 (0.3)[b]	1.0 (0.6)[a,c]	0.2 (0.3)[b]
Syntax	0.4 (0.3)	0.7 (0.5)[c]	0.3 (0.3)[b]
Word Retrieval	1.0 (0.4)[b]	0.6 (0.2)[a,c]	1.1 (0.5)[b]
Repetition	0.8 (0.3)[b,c]	0.4 (0.3)[a]	0.3 (0.3)[a]
Auditory Comprehension	0.7 (0.5)	0.4 (0.3)	0.5 (0.5)
Single-Word Comprehension	0.2 (0.2)[c]	0.0 (0.1)[c]	1.0 (0.5)[a,b]
Mean PASS score, combined subtests	0.5 (0.2)	0.6 (0.3)	0.5 (0.2)
WAB- Repetition score (SD)	71.3 (15.2)[b,c]	88.8 (14.0)[a]	86.5 (7.6)[c]
Forward Digit Span score (SD)	4.2 (1.6)[c]	5.5 (1.3)	6.7 (1.2)[a]
Backward Digit Span score (SD)	2.5 (1.6)[c]	3.3 (0.9)	4.0 (1.6)[a]

the current study, PPA participant selection criteria were (1) an assessment of repetition and working memory (digit span) performance, and (2) the availability of an MRI scan.

Behavioral measures

Participants completed the Repetition subtest of the Western Aphasia Battery-Revised (WAB-R; Kertesz, 2007), which included 15 stimuli items that vary in length. The subtest includes seven single words (1-3 syllables), and eight phrases/sentences (5-14 syllables). Each word, phrase or sentence was read aloud to the participant and participants were instructed to repeat. Points per item were determined based on the standardized scoring guidelines. Points were deducted for omissions of phonemes, syllables or entire words, as well as for phonemic substitutions and additions. Points were not deducted in the case of a timely self-correction of phonemic error or an intelligible sound distortion (i.e., motor speech impairment was not penalized). Stimuli were eligible for scoring only after the first administration. In the current study, the reported total score for the WAB Repetition subtest refers to the overall percent correct (out of 100 possible points) across all stimuli.

Participants also completed Digit Span Forward and Digit Span Backward subtests from the Uniform Data Set (UDS v3.0) neuropsychological test battery (Weintraub et al., 2009). The Digit Span subtests each comprise 14 stimuli digit sets varying in span length (3-9 digits for Forward subtest; 2-8 digits for Backward subtest). For each span length, there are two stimuli digit sets. Each digit set was read aloud to the participant and the participant was instructed to repeat those numbers in either the exact order they heard them (Digit Span Forward) or to repeat them back in the reverse order (Digit Span Backward). Responses for each digit set were scored as correct/incorrect, and no partial points were awarded. In these subtests, patients were not

penalized for either phonological or articulatory errors, provided that the response was intelligible. Testing was discontinued after two consecutive failures on the same span length. In this study, the reported total score refers to the length of the longest correctly repeated sequence. If a participant was unable to correctly repeat the shortest length sequence at least once, they received a total score of zero.

Structural MRI acquisition and analysis

Imaging data for the all PPA patients were acquired on a 3T Magnetom Tim Trio system at MGH (Siemens), using a 12-channel phased-array head coil. For each patient a structural image was obtained using a standard T1-weighted 3D MPRAGE sequence that varied slightly across individuals. 19 patients were scanned using the following parameters: TR = 2530.00 ms, TE = 3.48 ms, flip angle = 7.00 degrees, number of interleaved sagittal slices = 176, matrix dimensions = 256 x 256, FOV = 256 mm, voxel size = 1.00 mm isotropic. 9 patients had the parameters: TR = 2530.00 ms, TE = 1.64 ms, flip angle = 7.00 degrees, number of interleaved sagittal slices = 176, matrix dimensions = 256 x 256, FOV = 256 mm, voxel size = 1.00 mm isotropic. 5 patients with TR = 2300.00 ms, TE = 2.98 ms, flip angle = 9.00 degrees, number of interleaves sagittal slices = 160, matrix = 240 x 256, FOV = 256 mm, voxel size = 1.00 mm isotropic; and 2 patients had identical parameters with the exception of number of interleaved sagittal slices = 192. 2 patients were scanned with TR = 2530.00 ms, TE = 1.61, flip angle = 7.00 degrees, number of interleaved sagittal slices = 208, matrix dimensions = 256 x 256, FOV = 256, mm, voxel size = 1.00 mm isotropic; and 1 patient had identical parameters with the exception matrix = 280 x 280 FOV = 280 mm, and TE = 1.63 ms. 3 patients were scanned with TR = 2200.00 ms, TE = 1.54 ms, flip angle = 7.00 degrees, number of interleaved sagittal slices = 144,

matrix = 192 x 192, FOV = 230 mm, voxel size = 1.198mm x 1.198mm x 1.200mm. 1 remaining patient was scanned with the following: TR = 2400.00 ms, TE = 2.22 ms, flip angle = 8.00 degrees, number of interleaved sagittal slices = 208, matrix dimensions = 300 x 320, FOV = 256 mm, voxel size = 0.80 mm isotropic.

MRI structural images were also obtained for age-matched control participants who did not exhibit any cognitive impairment (n = 25; mean age = 67.4 years, SD = 4.9; 12 female). MRI data for control participants were obtained using the following scan parameters: TR = 2300.00 ms, TE = 2.95 ms, flip angle = 9.00 degrees, number of interleaved sagittal slices = 176, matrix dimensions = 256 x 256, FOV = 270 mm, voxel size = 1.1mm x 1.1mm x 1.200mm.

Cortical reconstructions were generated for each participant's T1-weighted image using FreeSurfer version 6.0 (https://surfer.nmr.mgh.harvard.edu, Dale, Fischl, & Sereno, 1999; Fischl & Dale, 2000; Fischl, Sereno, & Dale, 1999; Salat et al., 2004). This method has been shown to be reliable in older adults for both spatial localization and absolute magnitude of measurements across multiple scan sessions for the identification of brain-behavior relationships (Dickerson et al., 2008). Each cortical reconstruction was inspected for accuracy and any errors in the grey/white matter boundary or pial surface segmentation were manually corrected. Each patient's reconstructed cortical surface was then parcellated using the SpeechLabel cortical labeling system, which parcellates each hemisphere into 66 anatomically-based regions-of-interest (ROIs) for fine-scale subdivision of cortical regions involved in the speech network and is described in greater detail in previous work from our labs (Cai et al., 2014; Cordella et al., 2019). Average cortical thickness within each ROI of the SpeechLabel atlas was calculated for each patient.

To identify ROIs demonstrating significant atrophy for each PPA variant compared to controls, independent-sample one-tailed t-tests were conducted for each ROI, using a one-tailed

statistical threshold of $p < 0.001$ with FDR corrections. Separate ANOVA analyses were completed to identify differences in cortical thickness in the hypothesized phonologic buffer ROIs in left pIFS and left posterior supramarginal gyrus (pSMG) between each PPA variant.

Experimental design and statistical analysis

A principal components analysis was first performed for the three working memory scores, which revealed that the three working memory measures contributed essentially equally to the first principal component (coeff = 0.56, 0.60, 0.57 respectively for backward digit span, forward digit span, and the WAB-Repetition subscores). Therefore, an average working memory score for each subject was obtained by averaging standard z-score values for each of the three tests. This average working memory score followed a normal distribution, per Shapiro-Wilk test. There were no significant effects for age, gender, or total brain volume for either of the hypothesized brain regions or for performance on any of the three working memory tasks.

First, our primary hypothesis as to the association between working memory performance and cortical thickness in left pIFS and left pSMG was assessed using one-tailed Pearson bivariate correlation analyses, with a Bonferroni correction applied to account for multiple comparisons resulting in an α level of 0.025. A one-tailed analysis was performed due to the unidirectional hypothesis of reduced working memory performance with cortical thinning in these two ROIs.

Next, an exploratory uncorrected whole-brain analysis was performed to identify additional cortical regions that demonstrate a significant relationship with overall working memory performance. Again, one-tailed Pearson bivariate correlations were performed due to the unidirectional hypothesis of cortical thinning associated with reduced working memory performance. Separate whole-brain one-tailed Spearman correlation analyses were also

conducted for each working memory task in order to evaluate task differences. All exploratory correlation analyses used an α level set at 0.05 due to the exploratory nature of the analyses and were performed in IBM SPSS Statistics 25 for Windows.

Results

Brain Atrophy Patterns by Clinical Subtype

Cortical thickness measures in this study revealed differential patterns of left hemisphere atrophy across PPA variants (see Figure 2 for atrophy maps), largely in line with previously

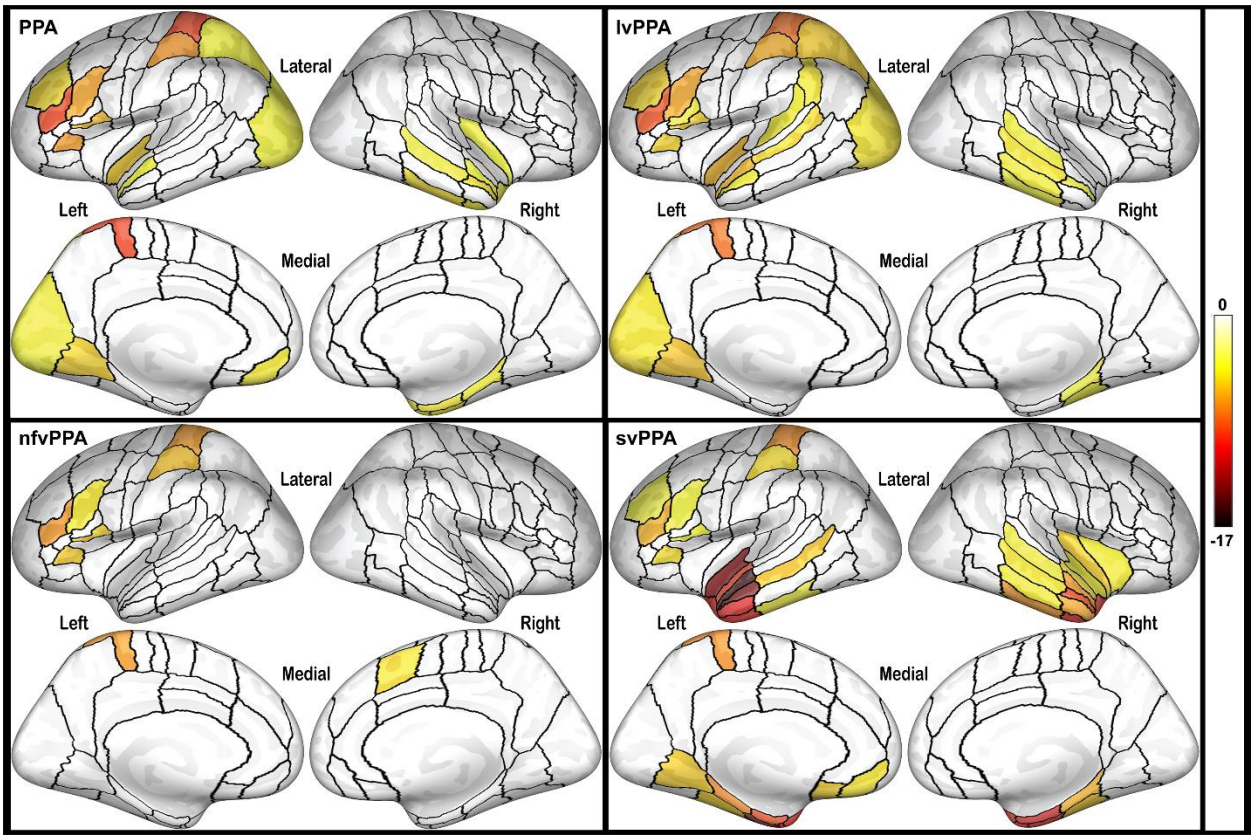

Figure 2. Inflated cortical surfaces showing regions-of-interest with significantly thinner cortex compared to controls. The color scale represents t-statistic of the effect, with false discovery rate correction set at 0.001 for each comparison. PPA = primary progressive aphasia, all variants combined; lvPPA = logopenic variant primary progressive aphasia; nfvPPA = nonfluent variant primary progressive aphasia; svPPA = semantic variant primary progressive aphasia

gyrus for nfvPPA patients, and in the temporoparietal junction for lvPPA patients (Rohrer et al., 2010; Sapolsky et al., 2010; Gorno-Tempini et al., 2011; Mesulam et al., 2012; Rogalski et al., 2014). No significant temporal lobe atrophy was observed in the nfvPPA group.

ANOVA analysis revealed a significant group effect in both left pIFS [$F(2, 39) = 5.55$, $p = 0.008$] and left pSMG [$F(2,39) = 10.46$, $p < 0.001$]. Bonferroni post-hoc comparisons revealed a significant difference in left pIFS cortical thickness only between lvPPA and svPPA patients ($p = 0.006$; lvPPA: 2.03 ± 0.15; svPPA: 2.23 ± 0.12; nfvPPA: 2.12 ± 0.21). Differences in left pSMG thickness were present between lvPPA and nfvPPA patients ($p = 0.002$; lvPPA: 2.02 ± 0.05; nfvPPA: 2.30 ± 0.05) and lvPPA and svPPA patients ($p = 0.001$; svPPA: 2.32 ± 0.05).

Brain-Behavior Correlations

Pearson correlations revealed significant correlations between the average working memory score and cortical thickness in left pIFS (hypothesized site of the phonological output buffer; $r = 0.397$, $p = 0.005$) and left SMG (hypothesized site of the phonological input buffer; $r = 0.411$, $p = 0.003$). Scatter plots displaying cortical thickness in each of these two regions as compared to average working memory score for each subject are shown in Figure 3.

Results for exploratory whole brain correlation analyses with the average working memory score, the WAB-Repetition subtest score, forward digit span, and backward digit span are summarized in Table 2, with significant ROIs displayed in Figure 4. Uncorrected results for the average working memory score revealed correlations with cortical thickness in right Heschl's gyrus ($r = 0.415$, $p = 0.003$), right posterior dorsal superior temporal sulcus ($r = 0.387$, $p = 0.006$), left planum temporale (PT; $r = 0.385$, $p = 0.006$), right anterior middle frontal gyrus ($r = 0.412$, $p = 0.007$), in addition to the hypothesized regions. WAB-Repetition scores were most

strongly correlated with bilateral posterior dorsal superior temporal sulcus (L: r_s = 0.461, p = 0.001; R: r_s = 0.438, p = 0.002), left PT (r_s = 0.479, p = 0.0007), and left posterior superior temporal gyrus (pSTG; r_s = 0.452, p = 0.001). WAB-Repetition scores were significantly correlated with cortical thickness in left pSMG (r_s = 0.341, p = 0.014), but not left pIFS (r_s = 0.249, p = 0.056). Backward digit span was mostly strongly correlated with right Heschl's gyrus (r_s = 0.418, p = 0.003) and right frontal regions including superior frontal gyrus (r_s = 0.454, p = 0.001), anterior dorsal premotor cortex (r_s = 0.419, p = 0.003), anterior middle frontal gyrus (r_s = 0.389, p = 0.005), and frontal pole (r_s = 0.373, p = 0.007). The two hypothesized ROIs were also correlated with backward digit span (pIFS: r_s = 0.317, p = 0.02; pSMG: r_s = 0.282, p = 0.035). The strongest correlations with forward digit span were observed in the two hypothesized phonological buffers (left pIFS: r_s = 0.458, p = 0.001; left pSMG: r_s = 0.427, p = 0.002), and left

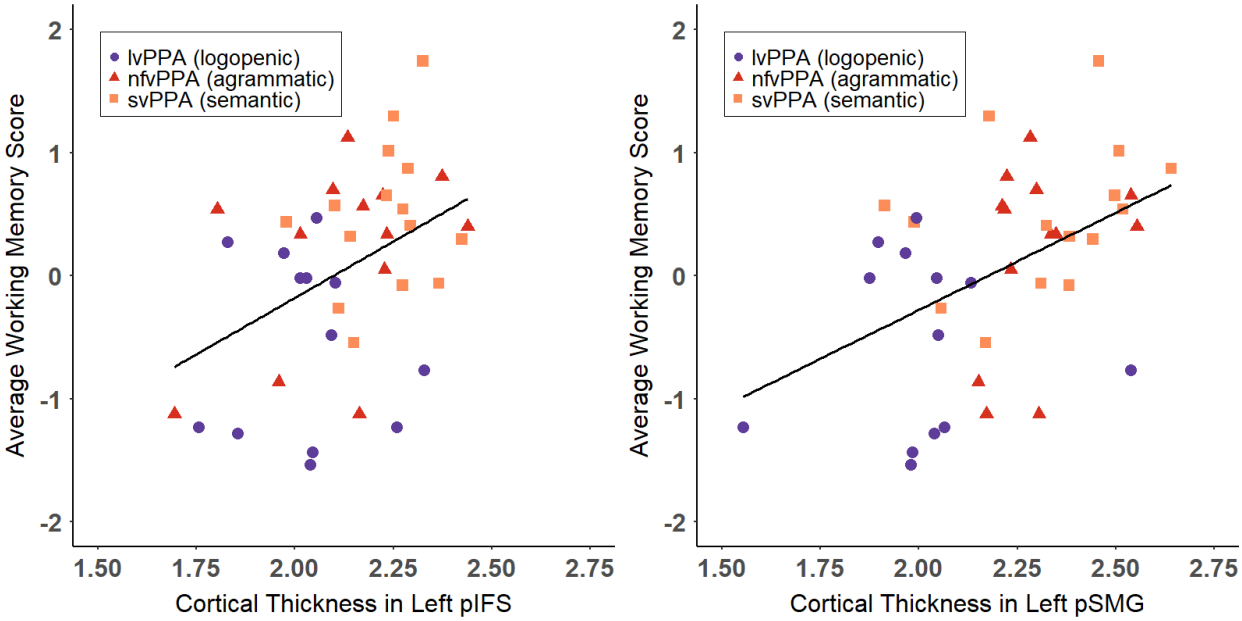

Figure 3: Scatter plot showing relationship between each subject's mean cortical thickness in left posterior inferior frontal sulcus (pIFS, left panel) and left posterior supramarginal gyrus (pSMG, right panel) as compared to their average working memory score obtained from the mean of z-scores from forward digit span, backward digit span, and the Western Aphasia Battery- Sentence Repetition subscores. Logopenic variant individuals (lvPPA) are shown as purple circles, nonfluent variant individuals (nfvPPA) are shown as red triangles, and semantic variant individuals (svPPA) are shown with orange squares. Solid line shows linear trend for combined group.

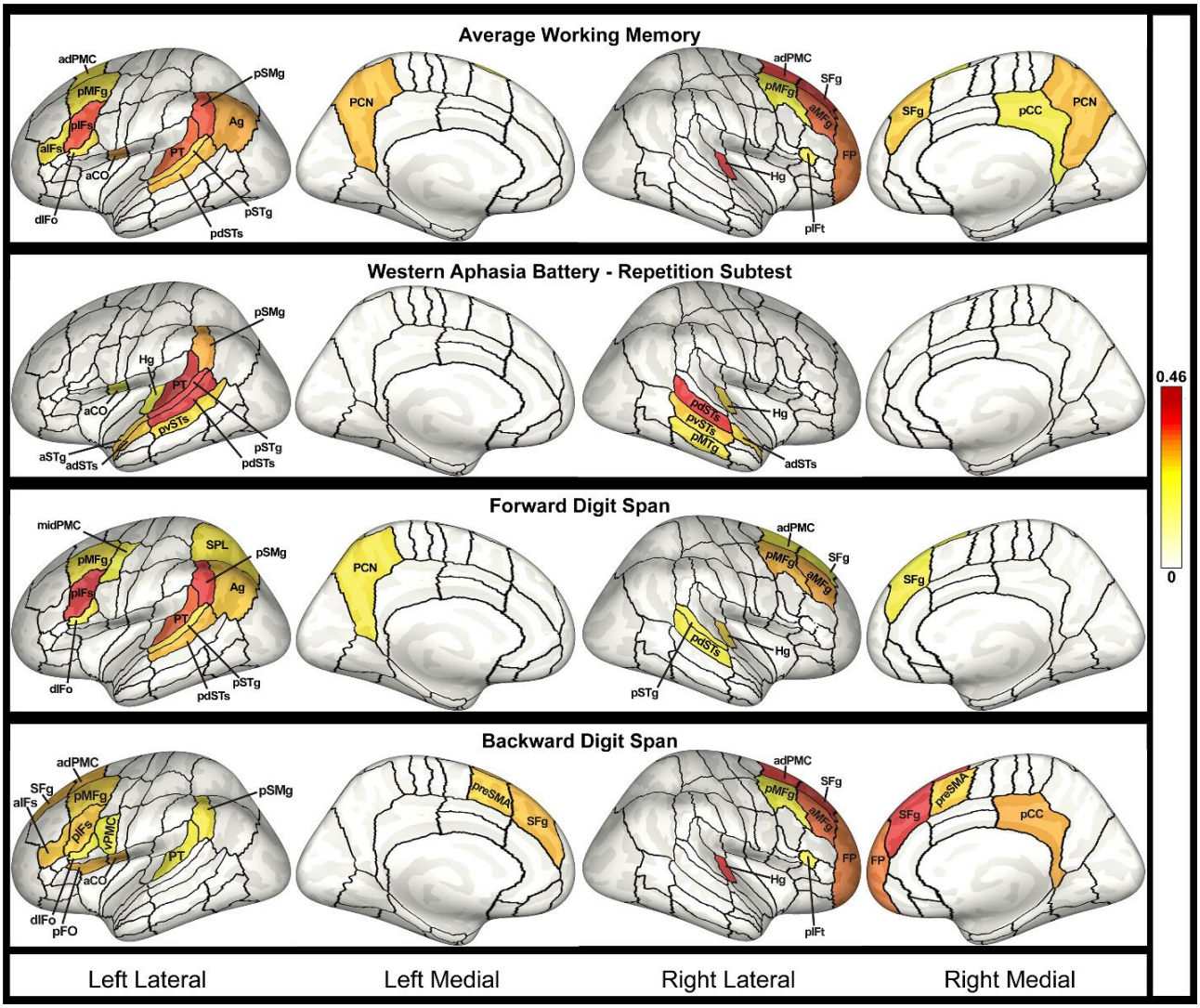

Figure 4: Inflated cortical surfaces showing regions-of-interest (ROIs) with significant correlations with (a) the average working memory score, obtained from an average of z-scored values from each of the three individual tests with each of the three repetition tasks; (b) score on the Western Aphasia Battery-Repetition subtest; (c) forward digit span score; and (d) backward digit span score. Medial and lateral surfaces of both left and right hemispheres are shown, with color map reflecting the strength of the correlation coefficient, thresholded at $p < 0.05$, uncorrected. Abbreviations: aCO = anterior central operculum, adPMC = anterior dorsal premotor cortex, adSTs = anterior dorsal superior temporal sulcus, Ag = angular gyrus, aIFs = anterior inferior frontal sulcus, aMFg = anterior middle frontal gyrus, aSTg = anterior superior temporal gyrus, dIFo = dorsal inferior frontal gyrus, pars opercularis, FP = frontal pole, Hg = Heschl's gyrus, midPMC = middle premotor cortex, pCC = posterior cingulate cortex, PCN = precuneus, pdSTs = posterior dorsal superior temporal sulcus, pFO = posterior frontal operculum, pIFs = posterior inferior frontal sulcus, pIFt = posterior inferior frontal gyrus, pars triangularis, pMFg = posterior middle frontal gyrus, pMTg = posterior middle temporal gyrus, preSMA = pre-supplementary motor area, pSMg = posterior supramarginal gyrus, pSTg = posterior superior temporal gyrus, PT = planum temporale, pvSTs = posterior ventral superior temporal sulcus, SFg = superior frontal gyrus, SPL = superior parietal lobule, vPMC = ventral premotor cortex

ROI	*Average WM*		*WAB Repetition*		*Forward Span*		*Backward Span*	
Left hemisphere	**r**	***p***	**r**	***p***	**r**	***P***	**r**	***P***
Posterior inferior frontal sulcus	0.397	0.005			0.458	0.001	0.317	0.020
Anterior central operculum	0.343	0.013	0.265	0.045			0.321	0.019
Dorsal IFG, pars opercularis	0.299	0.027			0.28	0.036	0.261	0.047
Posterior middle frontal gyrus	0.284	0.034			0.282	0.035	0.298	0.028
Anterior inferior frontal sulcus	0.287	0.033					0.32	0.019
Anterior dorsal premotor cortex	0.277	0.038					0.327	0.017
Mid premotor cortex					0.259	0.049		
Posterior frontal operculum							0.329	0.017
Superior frontal gyrus							0.325	0.018
Pre-supplementary motor area							0.313	0.022
Ventral premotor cortex							0.274	0.040
Planum temporale	0.385	0.012	0.479	0.0007	0.388	0.006	0.269	0.042
Posterior dorsal STS	0.325	0.018	0.461	0.001	0.330	0.016		
Posterior STG	0.317	0.020	0.452	0.001	0.29	0.031		
Anterior dorsal STS			0.319	0.020				
Anterior STG			0.312	0.022				
Posterior ventral STS			0.300	0.027				
Heschl's gyrus			0.263	0.046				
Posterior supramarginal gyrus	0.411	0.003	0.341	0.014	0.427	0.002	0.282	0.035
Angular gyrus	0.340	0.014			0.315	0.021		
Precuneus	0.330	0.017						
Superior parietal lobule					0.281	0.036		
Right hemisphere								
Anterior middle frontal gyrus	0.412	0.003			0.337	0.014	0.389	0.005
Posterior middle frontal gyrus	0.329	0.017			0.327	0.017	0.271	0.041
Superior frontal gyrus	0.317	0.020			0.267	0.044	0.454	0.001
Anterior dorsal premotor cortex	0.265	0.045			0.271	0.041	0.419	0.003
Frontal pole							0.373	0.007
Pre-supplementary motor area							0.309	0.023
Posterior IFG, pars triangularis							0.261	0.047
Anterior inferior frontal sulcus	0.286	0.033						
Heschl's gyrus	0.415	0.003	0.303	0.026	0.291	0.031	0.418	0.003
Posterior dorsal STS	0.387	0.006	0.438	0.002	0.261	0.048		
Posterior STG	0.331	0.016			0.262	0.047		
Planum temporale	0.264	0.045						
Posterior ventral STS			0.316	0.021				
Anterior dorsal STS			0.310	0.026				
Posterior middle temporal gyrus			0.282	0.035				
R posterior cingulate gyrus	0.267	0.044					0.344	0.013
R precuneus	0.325	0.018						

Table 2: Regions-of-interest (ROIs) with significant ($p < 0.05$) correlation coefficients (r) and *p-values* with each of the three repetition tasks: Western Aphasia Battery (WAB)- Repetition subtest; forward digit span; and backward digit span, as well as ROIs significantly correlated with the average working memory (WM) score, obtained from an average of z-scored values from each of the three individual tests. IFG = inferior frontal gyrus, STG = superior temporal gyrus, STS = superior temporal sulcus

PT ($r_s = 0.388$, $p = 0.006$; see Table 2 and Figure 4 for complete results). Because of the large number of ROIs tested in this exploratory analysis, none of these correlations survived FDR-correction for multiple comparisons.

Discussion

We investigated the neural substrates underlying performance on several clinical tests involving phonological working memory (PWM) by examining the relationship between cortical thickness and behavioral performance in PPA patients. Our results support the existence of a phonological output buffer in left pIFS, as proposed by the GODIVA model of speech sequencing (Bohland et al., 2010), in addition to a phonological input buffer in temporoparietal cortex. Specifically, we found correlations between average performance across three verbal repetition tasks and cortical thickness in both left pIFS and pSMG in PPA patients. Exploratory whole-brain analyses revealed distinct brain regions that were correlated with scores from each of the three tasks (in addition to some overlap), demonstrating fundamental differences in the neural correlates underlying successful performance on sentence repetition, forward digit span, and backward digit span tasks.

Evidence of a Phonological Output Buffer

The novel finding of correlations between left pIFS cortical thickness and PWM performance in patients with PPA supports the hypothesized role of left pIFS as a phonological

output buffer in the GODIVA model. In this model, left pIFS serves as part of a cortico-basal ganglia-thalamo-cortical planning loop and is specifically responsible for buffering and sequencing the individual phonological units in an upcoming utterance, which are then activated and executed in the correct serial order via projections to ventral premotor cortex (vPMC; Bohland et al., 2010; Guenther, 2016). This phonological output buffer should be highly involved in the commonly used tasks analyzed in this study. Specifically, impairment of the phonological output buffer should result in poorer verbal repetition performance due to difficulty buffering and sequencing each phoneme prior to motor execution.

Left inferior frontal regions have long been associated with the articulatory rehearsal component of Baddeley's working memory model (Paulesu et al., 1993; Awh et al., 1996; Baddeley, 2003; Baldo and Dronkers, 2006). Within the GODIVA model, left pIFS (in concert with left vPMC) plays a similar role to Baddeley's articulatory rehearsal process, sequencing through phonological units for either overt speech output or covert rehearsal (Bohland et al., 2010). Bohland & Guenther (2006) demonstrated increased activation in left pIFS during production of more complex syllable strings (e.g. increased number of phonemes per sequence), consistent with the region's proposed function in which additional neural resources are required to code the serial order of additional phonemes. Moreover, a prior meta-analysis of neuroimaging studies identified left pIFS as the only neural region with preferential activation in verbal (compared to nonverbal) working memory tasks (Rottschy et al., 2012).

Previous studies of verbal repetition in PPA have identified correlations between repetition deficits and atrophy in temporoparietal regions but not prefrontal regions such as pIFS (Amici et al., 2007; Rogalski et al., 2011; Leyton et al., 2012; Lukic et al., 2019). Our study differs from previous work in the use of an ROI-based analysis using the Speech Label

parcellation scheme. This parcellation scheme defines subject-specific ROIs to account for inter-subject anatomical variability and allows for finer-scale subdivisions of critical speech cortical regions, like pIFS, improving the localization of speech and language functions for more sensitive statistical analyses (Nieto-Castañon et al., 2003; Tourville and Guenther, 2012). Discrepant findings are also partly explained by differences in the selected repetition tasks; our individual task analyses demonstrated that left pIFS was not significantly correlated with sentence repetition performance on the WAB, consistent with previous literature.

Evidence of a Phonological Input Buffer

Average PWM task performance was also significantly correlated with cortical thickness in left pSMG, consistent with its proposed function as a phonological input buffer. This finding replicates recent work demonstrating correlations between sentence repetition accuracy and cortical thickness in temporoparietal regions, including left SMG, in patients with PPA (Lukic et al., 2019). In lvPPA patients, atrophy in left SMG is correlated with increased phonologic substitution errors (Petroi et al., 2020) and with impaired naming, presumably due to phonological impairment (Leyton et al., 2012). Similarly, substitution errors and repetition deficits in conduction aphasia have been linked to left SMG damage (Axer et al., 2001; Baldo and Dronkers, 2006; Fridriksson et al., 2010). Left SMG has also been implicated in functional neuroimaging of phonological working memory tasks as a phonological input buffer or the site of Baddeley's phonological store (Paulesu et al., 1993; Awh et al., 1996; Henson et al., 2000; Bohland and Guenther, 2006; Rottschy et al., 2012; Yue et al., 2019). Notably, our exploratory analysis of individual tasks suggests that the phonological input buffer extends from left pSMG into the superior temporal lobe, especially PT. This finding is in line with emergent property

models where pSTG and PT act as a sensorimotor interface linking acoustic and phonological representations (Jacquemot and Scott, 2006; Hickok and Poeppel, 2007; Buchsbaum and D'Esposito, 2008; Majerus, 2013).

Task Differences

A distinct set of neural regions (with some overlap) was correlated with each of the three common repetition tasks, with implications for the diagnostic utility of each measure in the clinical management of PPA. Forward digit span performance was most strongly correlated with cortical thickness in the hypothesized phonological input and output buffers in left pSMG and pIFS, respectively. This finding suggests that the forward digit span task may be a purer measure of the function of phonological input and output buffers, requiring less involvement of higher-level language or cognitive systems than other PWM tasks. Significant correlations between task performance and thickness of adjacent temporoparietal ROIs are consistent with previously reported correlations between left pSTG atrophy and digit span (Leyton et al., 2012). Additionally, bilateral middle frontal gyrus (MFG) correlations with both digit span tasks likely reflect this region's suggested role as part of a multi-domain cognitive system (Niendam et al., 2012; Fedorenko et al., 2013). Right MFG may also be involved in number manipulation (Menon et al., 2000; Zago et al., 2008).

The backward digit span task was unique in the contribution of right frontal regions to performance on this task. Bilateral superior frontal gyrus forms part of the frontoparietal control network engaged in sustained attention and executive control (Coull et al., 1996; Vincent et al., 2008; Niendam et al., 2012) with atrophy or lesion shown to impair working memory (Du Boisgueheneuc et al., 2006; Barbey et al., 2013; Nissim et al., 2017). Bilateral preSMA is also

considered a core working memory region (e.g., Bohland and Guenther, 2006; Rottschy et al., 2012; Perrachione et al., 2017). Our results support clinical concerns that attentional or executive functioning demands may drive performance on backward digit span tasks more than phonological processing ability (Foxe et al., 2013; Beales et al., 2019); backward digit span performance was less strongly correlated with cortical thickness in presumed phonology regions, instead requiring intact functioning of more general executive function regions.

Performance on the WAB-Repetition subtest was primarily associated with cortical thickness in left temporoparietal junction. This region is associated with repetition deficits in patients with both post-stroke aphasia and PPA (Damasio and Damasio, 1980; Axer et al., 2001; Baldo and Dronkers, 2006; Amici et al., 2007; Fridriksson et al., 2010; Buchsbaum et al., 2011; Rogalski et al., 2011; Lukic et al., 2019), and it is active during PWM tasks in typical speakers (McGettigan et al., 2011; Perrachione et al., 2017; Scott and Perrachione, 2019). The identified neural correlates of the WAB-Repetition task also extend into middle and anterior temporal gyri, which may reflect the semantic and syntactic processing involved in the task (Fedorenko et al., 2010; Friederici and Gierhan, 2013), with lesions here resulting in comprehension deficits and paragrammatism (Sapolsky et al., 2010; Rogalski et al., 2011; Turken and Dronkers, 2011; Matchin et al., 2020). The involvement of these regions suggests sentence recall may be facilitated by syntactic and semantic knowledge which may outweigh the contribution of the phonological output buffer to successful performance on the task (e.g., Baddeley et al., 2009); indeed, the WAB-Repetition task was the only task not significantly correlated with left pIFS. In support of this view, Lukic et al. (2019) found that the use of non-meaningful sentences provided increased diagnostic discrimination as it prevented compensatory use of intact semantic processing that may mask phonologic processing deficits in some lvPPA patients.

Limitations and Future Directions

A limitation of this work is the use of only cortical thickness measures in our brain-behavior analyses. White matter and functional connectivity studies have identified disruptions in the structure and function of key speech and language networks in patients with PPA (Galantucci et al., 2011; Whitwell et al., 2015; Mandelli et al., 2016). A more complete picture may emerge by combining multiple structural and functional measures in a single cohort of PPA patients. Also, our analyses identifying distinct neural correlates of the three repetition tasks are exploratory (i.e., not statistically corrected for the total number of ROIs analyzed), allowing for potential Type I errors. These exploratory results suggest significant task differences that should be further investigated in future work to validate these findings.

Acknowledgments: We are grateful to our patients and healthy volunteers for their participation in this research.

Funding: This work was supported by the National Institute on Deafness and other Communication Disorders (NIDCD) of the National Institutes of Health under award numbers R01 DC007683 and R01 DC002852 (PI: F. Guenther), R01 DC014296 (PI: B. Dickerson), and T32 DC013017 (PI: C. Moore).

Competing Interests: B. Dickerson receives research support from NIH and the Alzheimer's Drug Discovery Foundation. Dr. Dickerson serves on scientific advisory boards for Acadia, Arkuda, Axovant, Lilly, Biogen, Merck, Novartis, Wave LifeSciences and performs editorial duties with payment for Elsevier (Neuroimag: Clinical and Cortex). B. Dickerson also receives

royalties from Oxford University Press and Cambridge University Press. The other authors declare no competing financial interests relevant to the manuscript.

References

Amici S, Ogar J, Brambati SM, Miller BL, Neuhaus J, Dronkers NL, Gorno-Tempini ML (2007) Performance in specific language tasks correlates with regional volume changes in progressive aphasia. Cogn Behav Neurol 20:203–211.

Awh E, Jonides J, Smith EE, Schumacher EH, Koeppe RA, Katz S (1996) Dissociation of storage and rehearsal in verbal working memory : Evidence from positron emission tomography. Psychol Sci 7:25–31.

Axer H, von Keyserlingk AG, Berks G, von Keyserlingk DG (2001) Supra- and infrasylvian conduction aphasia. Brain Lang 76:317–331.

Baddeley A (2003) Working Memory: Looking back and looking forward. Nat Rev Neurosci 4:829.

Baddeley AD, Hitch GJ, Allen RJ (2009) Working memory and binding in sentence recall. J Mem Lang 61:438–456.

Baldo J, Dronkers NF (2006) The role of inferior parietal and inferior frontal cortex in working memory. Neuropsychology 20:529–538.

Barbey AK, Koenigs M, Grafman J (2013) Dorsolateral prefrontal contributions to human working memory. Cortex 49:1195–1205.

Beales A, Whitworth A, Cartwright J, Panegyres PK, Kane RT (2019) Profiling sentence

repetition deficits in primary progressive aphasia and Alzheimer's disease: Error patterns and association with digit span. Brain Lang 194:1–11.

Bohland JW, Bullock D, Guenther FH (2010) Neural representations and mechanisms for the performance of simple speech sequences. J Cogn Neurosci 22:1504–1529.

Bohland JW, Guenther FH (2006) An fMRI investigation of syllable sequence production. Neuroimage 32:821–841.

Buchsbaum BR, Baldo J, Okada K, Berman KF, Dronkers NF, D'Esposito M, Hickok G (2011) Conduction aphasia, sensory-motor integration, and phonological short-term memory - An aggregate analysis of lesion and fMRI data. Brain Lang 119:119–128.

Buchsbaum BR, D'Esposito M (2008) The search for the phonological store: from loop to convulution. J Cogn Neurosci 20:762–778.

Cai S, Tourville JA, Beal DS, Perkell JS, Guenther FH, Ghosh SS (2014) Diffusion imaging of cerebral white matter in persons who stutter: Evidence for network-level anomalies. Front Hum Neurosci 8:1–18.

Collins JA, Montal V, Hochberg D, Quimby M, Mandelli ML, Makris N, Seeley WW, Gorno-Tempini ML, Dickerson BC (2017) Focal temporal pole atrophy and network degeneration in semantic variant primary progressive aphasia. Brain 140:457–471.

Cordella C, Quimby M, Touroutoglou A, Brickhouse M, Dickerson BC, Green JR (2019) Quantification of motor speech impairment and its anatomic basis in primary progressive aphasia. Neurology 92:e1992–e2004.

Coull JT, Frith CD, Frackowiak RSJ, Grasby PM (1996) A fronto-parietal network for rapid

visual information processing: a PET study of sustained attention and working memory. Neuropsychologia 34:1085–1095.

Dale AM, Fischl B, Sereno MI (1999) Cortical surface-based analysis I: Segmentation and surface reconstruction. Neuroimage 9:179–194.

Damasio H, Damasio AR (1980) The anatomical basis of conduction aphasia. Brain 103:337–350.

Dickerson BC, Fenstermacher E, Salat DH, Wolk DA, Maguire RP, Desikan R, Pacheco J, Quinn BT, Van der Kouwe A, Greve DN, Blacker D, Albert MS, Killiany RJ, Fischl B (2008) Detection of cortical thickness correlates of cognitive performance: Reliability across MRI scan sessions, scanners, and field strengths. Neuroimage 39:10–18.

Du Boisgueheneuc F, Levy R, Volle E, Seassau M, Duffau H, Kinkingnehun S, Samson Y, Zhang S, Dubois B (2006) Functions of the left superior frontal gyrus in humans: a lesion study. Brain 129:3315–3328.

Fedorenko E, Duncan J, Kanwisher N (2013) Broad domain generality in focal regions of frontal and parietal cortex. PNAS 110:16616–16621.

Fedorenko E, Hsieh P-J, Nieto-Castañon A, Whitfield-Gabrieli S, Kanwisher N (2010) New method for fMRI investigations of language: Defining ROIs functionally in individual subjects. J Neurophysiol 104:1177–1194.

Fischl B, Dale AM (2000) Measuring the thickness of the human cerebral cortex from magnetic resonance images. PNAS 97:11050–11055.

Fischl B, Sereno MI, Dale AM (1999) Cortical surface-based analysis inflation II: Inflation,

flattening, and a surface-based coordinate system. Neuroimage 9:195–207.

Foxe DG, Irish M, Hodges JR, Piguet O (2013) Verbal and Visuospatial Span in Logopenic Progressive Aphasia and Alzheimer's Disease Self-referential memory View project Semantic neighourhood View project. J Int Neuropsychol Soc 19:247–253.

Fridriksson J, Kjartansson O, Morgan PS, Hjaltason H, Magnusdottir S, Bonilha L, Rorden C (2010) Impaired speech repetition and left parietal lobe damage. J Neurosci 30:11057–11061.

Friederici AD, Gierhan SME (2013) The language network. Curr Opin Neurobiol 23:250–254.

Galantucci S, Tartaglia MC, Wilson SM, Henry ML, Filippi M, Agosta F, Dronkers NF, Henry RG, Ogar J, Miller BL, Gorno-Tempini ML (2011) White matter damage in primary progressive aphasias: a diffusion tensor tractography study. Brain 134:3011–3029.

Gorno-Tempini ML et al. (2011) Classification of primary progressive aphasia and its variants. Neurology 76:1006–1014.

Gorno-Tempini ML, Brambati SM, Ginex V, Ogar J, Dronkers NF, Marcone A, Perani D, Garibotto V, Cappa SF, Miller BL (2008) The logopenic/phonological variant of primary progressive aphasia. Neurology 71:1227–1234.

Guenther FH (2016) Neural Control of Speech. MIT Press.

Henson RN, Burgess N, Frith CD (2000) Recoding, storage, rehearsal and grouping in verbal short-term memory: an fMRI study. Neuropsychologia 38:426–440.

Hickok G, Poeppel D (2007) The cortical organization of speech processing. Nat Rev Neurosci 8:393–402.

Jacquemot C, Scott SK (2006) What is the relationship between phonological short-term memory and speech processing? Trends Cogn Sci 10:480–486.

Kertesz A (2007) Western Aphasia Battery (Revised). San Antonio, TX: The Psychological Corporation.

Leyton CE, Piguet O, Savage S, Burrell J, Hodges JR (2012) The neural basis of logopenic progressive aphasia. J Alzheimer's Dis 32:1051–1059.

Leyton CE, Savage S, Irish M, Schubert S, Piguet O, Ballard KJ, Hodges JR (2014) Verbal Repetition in Primary Progressive Aphasia and Alzheimer's Disease. J Alzheimer's Dis 41:575–585.

Lukic S, Mandelli ML, Welch A, Jordan K, Shwe W, Neuhaus J, Miller ZA, Hubbard HI, Henry ML, Miller BL, Dronkers NF, Gorno-Tempini ML (2019) Neurocognitive basis of repetition deficits in primary progressive aphasia. Brain Lang 194:35–45.

Majerus S (2013) Language repetition and short-term memory: An integrative framework. Front Hum Neurosci 7:1–16.

Mandelli ML, Vilaplana E, Brown JA, Hubbard HI, Binney RJ, Attygalle S, Santos-Santos MA, Miller ZA, Pakvasa M, Henry ML, Rosen HJ, Henry RG, Rabinovici GD, Miller BL, Seeley WW, Gorno-Tempini ML (2016) Healthy brain connectivity predicts atrophy progression in non-fluent variant of primary progressive aphasia. Brain 139:2778–2791.

Matchin W, Basilakos A, Stark BC, Den Ouden D-B, Fridriksson J, Hickok G (2020) Agrammatism and Paragrammatism: A Cortical Double Dissociation Revealed by Lesion-Symptom Mapping. Neurobiol Lang 1:208–225.

McGettigan C, Warren JE, Eisner F, Marshall CR, Shanmugalingam P, Scott SK (2011) Neural correlates of sublexical processing in phonological working memory. J Cogn Neurosci 23:961–977.

Menon V, Rivera SM, White CD, Glover GH, Reiss AL (2000) Dissociating prefrontal and parietal cortex activation during arithmetic processing. Neuroimage 12:357–365.

Mesulam MM (2001) Primary progressive aphasia. Ann Neurol 49:425–432.

Mesulam MM (2003) Primary Progressive Aphasia — A Language-Based Dementia. N Engl J Med 349:1535–1542.

Mesulam MM, Thompson CK, Weintraub S, Rogalski E (2015) The Wernicke conundrum and the anatomy of language comprehension in primary progressive aphasia. Brain 138:2423–2437.

Mesulam MM, Wieneke C, Rogalski E, Cobia D, Thompson CK, Weintraub S (2009) Quantitative template for subtyping primary progressive aphasia. Arch Neurol 66:1545–1551.

Mesulam MM, Wieneke C, Thompson CK, Rogalski E, Weintraub S (2012) Quantitative classification of primary progressive aphasia at early and mild impairment stages. Brain 135:1537–1553.

Meyer AM, Snider SF, Campbell RE, Friedman RB (2015) Phonological short-term memory in logopenic variant primary progressive aphasia and mild Alzheimer's disease. Cortex 71:183–189.

Niendam TA, Laird AR, Ray KL, Dean YM, Glahn DC, Carter CS (2012) Meta-analytic

evidence for a superordinate cognitive control network subserving diverse executive functions. Cogn Affect Behav Neurosci 12:241–268.

Nieto-Castañon A, Ghosh SS, Tourville JA, Guenther FH (2003) Region of interest based analysis of functional imaging data. Neuroimage 19:1303–1316.

Nissim NR, O'Shea AM, Bryant V, Porges EC, Cohen R, Woods AJ (2017) Frontal structural neural correlates of working memory performance in older adults. Front Aging Neurosci 8:328.

Paulesu E, Frith CD, Frackowiak RSJ (1993) The neural correlates of the verbal component of working memory. Nature 362:342–345.

Perrachione TK, Ghosh SS, Ostrovskaya I, Gabrieli JDE, Kovelman I (2017) Phonological working memory for words and nonwords in cerebral cortex. J Speech, Lang Hear Res 60:1959–1979.

Petroi D, Duffy JR, Borgert A, Strand EA, Machulda MM, Senjem ML, Jack CR, Josephs KA, Whitwell JL (2020) Neuroanatomical correlates of phonologic errors in logopenic progressive aphasia. Brain Lang 204:104773.

Rogalski E, Cobia D, Harrison TM, Wieneke C, Thompson CK, Weintraub S, Mesulam MM (2011) Anatomy of language impairments in primary progressive aphasia. J Neurosci 31:3344–3350.

Rogalski E, Cobia D, Martersteck A, Rademaker A, Wieneke C, Weintraub S, Mesulam MM (2014) Asymmetry of cortical decline in subtypes of primary progressive aphasia. Neurology 83:1184–1191.

Rohrer JD, Ridgway GR, Crutch SJ, Hailstone J, Goll JC, Clarkson MJ, Mead S, Beck J, Mummery C, Ourselin S, Warrington EK, Rossor MN, Warren JD (2010) Progressive logopenic/phonological aphasia: Erosion of the language network. Neuroimage 49:984–993.

Rottschy C, Langner R, Dogan I, Reetz K, Laird AR, Schulz JB, Fox PT, Eickhoff SB (2012) Modelling neural correlates of working memory: A coordinate-based meta-analysis. Neuroimage 60:830–846.

Salat DH, Buckner RL, Snyder AZ, Greve DN, Desikan RSR, Busa E, Morris JC, Dale AM, Fischl B (2004) Thinning of the cerebral cortex in aging. Cereb Cortex 14:721–730.

Sapolsky D, Bakkour A, Negreira A, Nalipinski P, Weintraub S, Mesulam MM, Caplan D, Dickerson BC (2010) Cortical neuroanatomic correlates of symptom severity in primary progressive aphasia. Neurology 75:358–366.

Sapolsky D, Domoto-Reilly K, Dickerson BC (2014) Use of the Progressive Aphasia Severity Scale (PASS) in monitoring speech and language status in PPA. Aphasiology 28:993–1003.

Sapolsky D, Domoto-Reilly K, Negreira A, Brickhouse M, McGinnis S, Dickerson BC (2011) Monitoring progression of primary progressive aphasia: current approaches and future directions. Neurodegener Dis Manag 1:43–55.

Scott TL, Perrachione TK (2019) Common cortical architectures for phonological working memory identified in individual brains. Neuroimage 202:116096.

Tourville JA, Guenther FH (2012) Automatic cortical labeling system for neuroimaging studies of normal and disordered speech. In: Society of Neuroscience Abstracts, pp Vol. 38, No. 681.06.

Turken AU, Dronkers NF (2011) The neural architecture of the language comprehension network: Converging evidence from lesion and connectivity analyses. Front Syst Neurosci 5:1.

Vincent JL, Kahn I, Snyder AZ, Raichle ME, Buckner RL (2008) Evidence for a frontoparietal control system revealed by intrinsic functional connectivity. J Neurophysiol 100:3328–3342.

Weintraub S, Salmon D, Mercaldo N, Ferris S, Graff-Radford NR, Chui H, Cummings J, DeCarli C, Foster NL, Galasko D, Peskind E, Dietrich W, Beekly DL, Kukull WA, Morris JC (2009) The Alzheimer's Disease Centers' Uniform Data Set (UDS): The neuropsychologic test battery. Alzheimer Dis Assoc Disord 23:91–101.

Whitwell JL, Jones DT, Duffy JR, Strand EA, Machulda MM, Przybelski SA, Vemuri P, Gregg BE, Gunter JL, Senjem ML, Petersen RC, Jack CR, Josephs KA (2015) Working memory and language network dysfunctions in logopenic aphasia: A task-free fMRI comparison with Alzheimer's dementia. Neurobiol Aging 36:1245–1252.

Yue Q, Martin RC, Hamilton AC, Rose NS (2019) Non-perceptual regions in the left inferior parietal lobe support phonological short-term memory: Evidence for a buffer account? Cereb Cortex 29:1398–1413.

Zago L, Petit L, Turbelin MR, Andersson F, Vigneau M, Tzourio-Mazoyer N (2008) How verbal and spatial manipulation networks contribute to calculation: An fMRI study. Neuropsychologia 46:2403–2414.