Individual structural abnormality indexes are associated with molecular, histological and cognitive indicators for glioma patients

Running title：A noninvasive way to glioma malignancy

Guobin Zhang[1#], Huawei Huang[2#], Yonggang Wang[1#], Xiaokang Zhang[1], Haoyi Li[1], Yunyun Duan[3], Hongyan Chen[3], Yaou Liu[3], Bin Jing[4*], Song Lin[1*]

[1]Department of Neurosurgery, China National Clinical Research Center for Neurological Diseases (NCRC-ND), Center of Brain Tumor, Beijing Institute for Brain Disorders, Beijing Key Laboratory of Brian Tumor, Beijing Tiantan Hospital, Capital Medical University, Beijing, 100070, P.R. China

[2]Department of Critical Care Medicine, Beijing Tiantan Hospital, Capital Medical University, Beijing, 100070, P.R. China

[3]Department of Radiology, Beijing Tiantan Hospital, Capital Medical University, Beijing, 100070, P.R. China

[4]School of Biomedical Engineering, Capital Medical University, Beijing,100069, P.R. China

#Joint first authors: Guobin Zhang, Huawei Huang and Yonggang Wang contributed equally as the first author.

***Corresponding author**

Name: Song Lin

Affiliation: Department of Neurosurgery, China National Clinical Research Center for Neurological Diseases (NCRC-ND), Center of Brain Tumor, Beijing Institute for Brain Disorders, Beijing Key Laboratory of Brain Tumor, Beijing Tiantan Hospital, Capital Medical University

Address: South 4th Ring West Road 119, Fengtai District, Beijing, 100070, P.R. China

E-mail: linsong_ttyy@sina.com

Tel: +86 10 59976509

Fax: +86 10 59976509

Name: Bin Jing

Affiliation: School of Biomedical Engineering, Capital Medical University, Beijing,100069, China

Address: No.10 Xi Tou Tiao, You'an Men Wai, Fengtai District, Beijing, 100069, P.R. China

E-mail: bjing@ccmu.edu.cn

Tel: (+86) 15011101291

Fax: +86 10 83911552

Acknowledgments: This work was supported by the National Natural Science Foundation of China (81801042), Beijing Hospital Authority Youth Programme (20190504), Beijing Outstanding Talent Training Foundation, Youth Backbone Individual Project (2018000021469G230) and Beijing Municipal Commission of Education (KM202010025025). The funds had no role in the study design, data collection and analysis, decision to publish, or manuscript preparation.

Conflict of Interest: The authors declare that they have no competing interests.

Author contributions: Study design: S.L, B.J, GB.Z. Clinical research execution: GB.Z, HW.H, XK.Z, HY.L, YG.W. Image research execution: GB.Z, HW.H, XK.Z, HY.C, YY.D, YO.L. Data analysis: B.J, GB.Z, HW.H, XK.Z. Manuscript writing: GB.Z, B.J, HW.H, XK.Z. Article review: All authors.

Ethics approval: The study was approved by the Institutional Review Board of Beijing Tiantan Hospital, Capital Medical University, Beijing, China (KY2020-048-01).

Data Availability Statement: The data that support the findings of this study are available from the corresponding author upon reasonable request.

Abstract

Molecular indicators are vital to glioma diagnosis and prognosis. The conventional examination of molecular characteristics requires surgical removal of tumor tissues, therefore could not be fully used in the surgery planning. 52 glioma patients in frontal lobe (mean age 43.2±9.3 years, 34 male) and 117 healthy controls (mean age 32.6±9.8 years, 83 male) participated in the study. All patients underwent neurocognitive test and molecular examinations, including 1p/19q co-deletion, isocitrate dehydrogenase (IDH) mutation, telomerase reverse transcriptase (TERT) promoter mutation and O6-methylguanine-DNA methyltransferase (MGMT) promotor methylation. A series of individual structural abnormality indexes based on preoperative structural MRI were proposed and explored the associations with these clinical indicators. Individual structural abnormality maps displayed that bilateral hippocampus, parahippocampus, insula, putamen and thalamus were constantly affected by glioma regardless of the histological grade, tumor hemisphere and molecular status. Higher grade glioma patients suffered more structural abnormalities, especially in the contralateral hemisphere and non-tumor regions. The molecular indicators, including IDH1 mutation, 1p/19q co-deletion, TERT promoter mutations and MGMT promoter methylation, as well as neurocognitive performance were all significantly correlated to individual structural abnormality indexes. Our proposed individual structural abnormality indexes show great potentials to access the glioma pathological, neurocognitive and molecular indicators, which is very helpful for neurosurgeons to determine the personalized treatment strategies.

Keywords: glioma, structural MRI, individual structural abnormality index, molecular indicators, neurocognitive performance

Abbreviations: IDH, isocitrate dehydrogenase; TERT, telomerase reverse transcriptase; MGMT, O6-methylguanine-DNA methyltransferase; MOCA, Montreal Cognitive Assessment; GLM, general linear model; TIV, total intracranial volume; CCA, Canonical Correlation Analysis; GBM, glioblastoma multiforme;

Introduction

Gliomas represent the majority of primary central nervous system (CNS) malignant tumors, and the surgical outcomes are dependent on the precise and comprehensive acquirement of various diagnostic information, which includes histological grades, molecular biomarkers and cognitive function. Since 2016, World Health Organization (WHO) updates the classification criteria for CNS tumors, and specific molecular biomarkers are included for gliomas beyond histological characteristics(Louis et al., 2016). For example, the incidence of isocitrate dehydrogenase (IDH) mutations, 1p/19q co-deletions, and telomerase reverse transcriptase (TERT) promoter mutations in glioma were predictors for better treatment outcome regardless of histological results(G. Cairncross et al., 2013; J. G. Cairncross et al., 1998; Shibahara et al., 2012). In light of the crucial roles of theses molecular parameters in glioma management, examinations of IDH mutations,1p/19q co-deletions, and TERT promoter mutations have become the routine diagnostic items in many neuropathology centers. However, the conventional determination of these molecular characteristics requires surgical removal of tumor tissues. Therefore, a noninvasive method that could access IDH-mutants, 1p/19q-co-deletions and TERT promoter mutations before surgery would be more helpful in the treatment strategy selection and the prognostic prediction, especially for initially diagnosed patients and patients who do not prefer surgery as the treatment.

Medical imaging technologies such as magnetic resonance imaging (MRI) and

computed tomography (CT) are routine ways to obtain macroscopic information about glioma for the advantages of low cost, low or no damage and convenience(Jin et al., 2020; Lasocki, Anjari, Örs Kokurcan, & Thust, 2020). Besides, the microscopic characteristics concealed in medical images have also been discovered, such as Radiomics, which has been widely used to predict histological and molecular biomarkers for glioma patients(Chen et al., 2018; Y. S. Choi et al., 2020; Smits & van den Bent, 2017). However, these studies have several intrinsic disadvantages: 1. extract group-level but not individual-level (patient-specific) features for classification or prediction; 2. only pay attention to the tumor regions, but the tumor related alterations in non-tumor regions are ignored. In this context, individualized imaging indexes that could delineate whole-brain alterations are highly desired for glioma patients before surgery.

Recently, Stoecklein et al. proposed a novel individual index based on the functional connectivity of resting state functional MRI (rs-fMRI), and found this individual index was positively correlated with WHO tumor grade and the IDH mutation status(Stoecklein et al., 2020). However, rs-fMRI is still not a clinical routine MRI scan, and its spatial resolution is commonly not very high. Moreover, rs-fMRI analysis is usually limited to gray matter (GM) but rarely within white matter (WM). In contrast, T1 sequence is a basic structural MRI scan, and plenty of analyzing tools have been developed for T1 images to extract morphological features such as cortical volume and thickness. If T1 could offer individualized diagnostic information about

genotype, histological grade, and neurocognitive score, it will be largely helpful to personalized presurgical planning and prognosis prediction. Inspired by the previous study(Perry et al., 2017) in measuring individual structural abnormality, we extend to quantify both GM and WM abnormality at individual level, and propose series of individual structural abnormality indexes based on extracted individual GM/WM abnormality map. The associations between these individual structural indexes and histological, molecular, and neurocognitive indicators are explored respectively, and these indexes were additionally combined together through canonical correlation analysis to improve the associations.

Materials and Methods

Patients

The study was approved by the Institutional Review Board of Beijing Tiantan Hospital, Capital Medical University, Beijing, China (KY2020-048-01). The study was also registered at Chinese ClinicalTrial Registry (ChiCTR2000031805). All study procedures were in accordance with the Declaration of Helsinki. Written informed consent was obtained from all patients. Fifty-two glioma patients and one hundred seventeen healthy controls participated this study, which were listed in Table 1. All gliomas in the cohort were diagnosed according to the criteria of the WHO classification system in the revised version of 2016. Inclusion criteria were suspected, newly diagnosed glioma with only one cancer region in the brain and age over 18 years. Exclusion criteria were previous cranial surgery, neuropsychiatric

comorbidities, and any contraindications to MR scanning such as metal implants. Neuropsychological testing was conducted prior to the first MRI scan using the *Montreal Cognitive Assessment* (MOCA) test. Histological confirmation of the diagnosis was obtained by surgical resection. Molecular markers, including 1p/19q codeletion, IDH1/2 mutation, TERT promoter mutation and O^6-methylguanine-DNA methyltransferase (MGMT) promotor methylation were all collected. Chromosomes 1 and 19 were analyzed by the fluorescence in situ hybridization method, and the IDH1/2 mutation and TERT promoter mutation were detected by sequence analysis, both following a previously described protocol(Suh, Kim, Jung, Choi, & Kim, 2019). MGMT promoter methylation was assessed by methylation-specific PCR as described previously by our team(G. B. Zhang et al., 2013). Patients were followed with routine clinical visits after initiation of therapy. All healthy controls were recruited from the local community and university students.

Structural MRI acquirement

All subjects were scanned with a Philips Ingenia 3.0T MRI scanner at Beijing Tiantan Hospital. For both glioma patients and healthy controls, T1 sequence was collected with the following parameters: TR: 6.5 ms, TE: 3.0 ms, Flip angle: 8°, voxel size: 1×1×1 mm^3, image dimension: 256×256×196. In addition, T2-flair was also scanned for glioma patients with the listed parameters: TR: 4.8 s, TE: 0.34 s, Flip angle: 90°, voxel size: 0.625×0.625×0.55 mm^3, image dimension: 400×400×300.

Image processing

The tumor region of every patient was extracted from T2-flair images with two sequential steps: 1. launch an automatic segmentation by ITK-SNAP software; 2. manually correct the segmentation by experienced neurosurgeons. After the segmentation, individual T2-flair image was co-registered to its corresponding T1 image by SPM software, and the transformation matrix was used on the segmented tumor to obtain the matched tumor region in T1 image space.

Individual T1 images were processed with CAT12 software to calculate the brain tissue volume. The skull stripping and correction for bias-field inhomogeneities were subsequently conducted. After that, the whole brain was segmented into different tissue types, e.g. gray matter and white matter. Then, the segmented GM and WM images were normalized to the MNI standard space with a modulation manner by DARTEL algorithm. Finally, the normalized GM and WM images were smoothed with 4-mm FWHM Gaussian kernel.

Individual structural abnormality index

Figure 1 illustrated the flowchart of the proposed individual structural abnormality map. In order to calculate individual structural abnormality maps for each glioma patient, all healthy controls were firstly used to construct the normative brain volume model. In this model, general linear model (GLM) was adopted to discover the relationship between voxel-wise volume and variables including age, sex, and total

intracranial volume (TIV) as the following equation.

$$volume = \beta_1 \times age + \beta_2 \times sex + \beta_3 \times TIV + residual \qquad (1)$$

Here, β_1, β_2, β_3 were weights for age, sex and TIV on the voxel-wise volume, and GM and WM volume models were respectively constructed.

Once the models had been created, the individual structural abnormality map for each glioma patient was calculated based on W score, which was calculated as following:

$$W\ score = \frac{volume_{patient} - \beta_1 \times age_{patient} - \beta_2 \times sex_{patient} - \beta_3 \times TIV_{patient}}{standard\ deviation\ of\ residuals\ in\ normative\ model} \qquad (2)$$

After the calculation of W score for each patient, a cutoff threshold (|W|>3) was set to the individual W score map to generate the individual structural abnormality map. Notably, an individualized explicit mask was generated for every patient which combined the corresponding tissue (GM/WM) prior probability template (threshold: 0.2) with individual tumor mask. Through the individual structural abnormality map, we proposed a series of abnormality indexes (8 GM indexes and 8 WM indexes, 16 in total) to reflect the characteristics of structural damages induced by glioma, which were listed in detail in Table 2. For GM/WM, there are respectively 8 individual structural abnormality indexes: GM atrophy ratio in tumor hemisphere (*GM-ART*), WM atrophy ratio in tumor hemisphere (*WM-ART*), GM atrophy ratio in contralateral hemisphere (GM-ARC), WM atrophy ratio in contralateral hemisphere (WM-ARC), GM enlargement ratio in tumor hemisphere (*GM-ERT*), WM enlargement ratio in tumor hemisphere (*WM-ERT*), GM enlargement ratio in contralateral hemisphere

(GM-ERC), WM enlargement ratio in contralateral hemisphere (WM-ERC), GM abnormality ratio in tumor hemisphere (*GM-ABRT*), WM abnormality ratio in tumor hemisphere (*WM-ABRT*), GM abnormality ratio in contralateral hemisphere (*GM-ABRC*), WM abnormality ratio in contralateral hemisphere (*WM-ABRC*), GM abnormality in non-cancer region in comparison to cancer region (*GM-ABNC*), WM abnormality in non-cancer region in comparison to cancer region (*WM-ABNC*), GM abnormality in non-cancer region in comparison to whole brain (*GM-ABNW*) and WM abnormality in non-cancer region in comparison to whole brain (*WM-ABNW*).

Associations with molecular, histological, and cognitive indicators

To explore the relationship between each of 16 abnormality indexes and IDH1, TERT mutation, 1p/19q deletion, MGMT methylation, histological grade and MOCA score, Spearman correlation was used and a $P < 0.05$ was thought as significance. Moreover, concerning the combinations of the proposed 16 individual structural abnormal indexes may further boost the correlation with these clinically concerned indicators, Canonical Correlation Analysis (CCA) was used to merge all indexes into a new canonical variable for each clinical indicator. CCA is in fact to seek the optimal linear combinations of these indexes that display the largest correlational relationship with these clinical indicators. Clearly, the weights (coefficients) of 16 abnormal indexes were different for each clinical indicator.

Results

Histology, molecular markers, and clinical course

There were 52 glioma patients (mean age 43.2±9.3 years, 34 male) and 117 healthy controls (mean age 32.6±9.8 years, 83 male) that participated in the study. All patients were prospectively included between May 2019 and July 2020. The WHO histological grade, IDH1, TERT mutation, 1p/19q deletion, MGMT methylation were acquired for every patient, and Montreal Cognitive Assessment (MOCA) score was also recorded. Table 1 summarized the demographic and clinical information for all subjects.

Individual structural abnormality map could discover structural alterations not only within the tumor but also outside the tumor.

It is no doubt that glioma could induce whole brain alterations. Figure 2 illustrated several patients' T1 images and corresponding personalized GM/WM abnormality maps (mapping back into T1 space). Obviously, the cerebral structural abnormalities not only lay in tumors but also in non-tumor regions, and all patients displayed both atrophies and enlargements in GM and WM. Although the patients varied in tumor sizes and tumor grades, the personalized GM abnormality maps could more precisely detect the tumor region than WM abnormality maps. In addition, high grade glioma patients were found with larger abnormalities in non-tumor regions. Figure 3 respectively displayed the overlapping regions for individual structural abnormality map, and it is clear that no matter the tumor is located at the left hemisphere or right hemisphere, several regions outside the tumor were consistently found abnormality,

including bilateral hippocampus, insula, putamen, parahippocampus, thalamus.

Individual structural abnormality indexes were associated with clinical indicators, and combinations of these indexes would promote the correlation.

Table 3 listed the correlation relationships between clinical indicators and proposed individual structural abnormality indexes. For WHO histological grade, 7 individual structural abnormality indexes correlated with it, and WM-ABRT achieved the highest correlation value (r=0.457). For IDH1 mutation, 3 indexes were significantly related with it, including GM-ART (r= -0.335), GM-ABRT (r= -0.326) and GM-ABNC (r= 0.330). For 1p19q deletion, 7 indexes displayed correlational relationship with it, and WM-ABNW obtained the highest correlational value (r=0.468). For TERT mutation, 6 indexes were found correlation with it, and GM-ABNW showed the highest correlational value (r=0.440). For MOCA score, WM-ARC (r=0.290) and WM-ERT (r=-0.284) were related with it. There was no single index that correlated with MGMT (all p>0.05).

Figure 4 summarized the scatter plots between corresponding canonical variable (linear combinations of 16 individual structural abnormality indexes) and these clinical indicators. It is obvious that combining the individual structural indexes together could achieve better correlations with these indicators, and the detected canonical variable displayed the highest correlational value (r=0.786) for histological grade and high correlations for IDH1 type (r=0.654), 1p/19q deletion status (r=0.619)

and TERT promoter type (r=0.615), while relatively lower correlational values were found for MOCA (r=-0.553) and MGMT (r=0.480). These results indicated individual structural abnormality indexes could serve as a promising way to access molecular, histological and cognitive indicators for preoperative glioma patients.

Discussion

In this study, we firstly depicted the structural abnormality characteristics for glioma patients through an individual level method, and proposed several quantitative indexes to reflect the individual abnormality severity, which were also found with high correlations with histological, molecular, and cognitive indicators. These findings demonstrated their enormous potentials in providing multiview information for the preoperative assessment of glioma patients, which may be finally used for individualized precision treatment and prognosis evaluation for glioma patients.

The non-invasiveness and convenience of imaging technologies make them act as indispensable tools for presurgical assessment of glioma patients. Among them, contrast-enhanced MRI is currently served as the diagnostic golden standard for patients with suspected brain neoplasms, which is often supplemented with spectroscopy, PET, or diffusion imaging. In contrast, T1 image is a basic structural imaging sequence that has been widely collected in various populations. Specially, it could be easily gained for healthy controls while contrast-enhanced MRI or PET is usually not applicable for healthy controls. Therefore, these imaging modalities are

usually used in a manner of visual inspection by experienced neurosurgeons. In addition, there are commonly two ways to analyze T1 images for glioma patients: 1. Use voxel/tensor/surface/deformation based morphometry methods to study the structural alterations, but these methods could be only conducted through statistical comparisons at the group level; 2. Use Radiomics methods to predict tumor phenotypes and clinical indicators, however, these methods only focus on the tumor region, hence couldn't provide information about non-tumor regions. Our method in the study solved the above-mentioned shortcomings, and further proposed a series of abnormality metrics at individual level to quantitatively delineate the structural alterations caused by glioma. Therefore, our method could offer comprehensive information about every glioma patient and may assist neurosurgeons to decide the most appropriate therapeutic strategy for every glioma patient.

Recently, Stoecklein et al. firstly demonstrated the feasibility of rs-fMRI to characterize individual glioma patient(Stoecklein et al., 2020). More importantly, this study manifested the tumor related changes in functional connectivity was unique for glioma patients with different histological grades, emphasizing the essentials of individual imaging biomarkers(Stoecklein et al., 2020). However, rs-fMRI is a type of technology with relatively low signal to noise ratio, and its test-retest reliability is also not high and dependent on the scanning durations, which makes it still challengeable for widespread applications for glioma patients. By contrast, structural MRI (sMRI) is with high image quality and test-retest reliability as well as appropriate scanning time.

Besides, fMRI is usually limited to the gray matter while sMRI could detect the morphological changes in both gray matter and white matter. Moreover, our results discovered white matter indexes are as informative as gray matter indexes, and combining them together could improve the associations with clinical indicators of glioma patients. Finally, our study actually demonstrated the structural alterations in the brain were also unique among glioma patients. Taken together, glioma may lead to patient specific alterations in both brain function and structure.

Although glioma patients display distinct structural abnormalities at the individual level, it is interesting to find they also share common structural abnormalities in regions such as bilateral hippocampus, insula, putamen, thalamus and parahippocampus. Specially, these abnormal regions are not dependent on the hemisphere of tumor, histological grade and molecular indicators. On the one hand, it implies tumor related structural abnormalities are not only limited in the tumor hemisphere but also in the contralateral hemisphere no matter whether the tumor hemisphere is the dominant hemisphere. On the other hand, why these regions rather than other regions show abnormalities needs additional consideration. We speculate one possible reason is that all glioma patients in the study are with tumor in the frontal lobe, which participates in some key function networks (e.g. default mode network, attention network, salience network, affective network) together with these abnormal regions. Once the frontal lobe suffers from the glioma, these abnormal regions have to undergo some compensatory alterations to maintain these functions. Previous

literatures have reported that as many as 90% of brain tumor patients would show tumor-related cognitive deficits (e.g., memory, attention, information processing, executive functioning impairments)(Gehring, Roukema, & Sitskoorn, 2012; Gehring, Sitskoorn, Aaronson, & Taphoorn, 2008), we infer this may be caused by the broken compensatory balance after the glioma surgery. At last, our findings show that the combination of all structural indexes achieved a high correlation (r=-0.553) with MOCA score, indicating the cognitive ability is actually related to the structural abnormalities in glioma patients.

For the prognosis of glioma patients, the histological grade and IDH mutation are two vital known factors. For example, lower grade gliomas with wild-type IDH were reported to show similar prognosis with glioblastomas, and IDH mutated glioblastomas were found with better prognosis than IDH wild-type glioblastomas(Darvishi et al., 2020; Hartmann et al., 2010). In addition, anaplastic gliomas with IDH wild-type have worse prognosis than glioblastomas with IDH mutation(Hartmann et al., 2010). However, it is still difficult to timely know genetic examination results during the surgery, therefore the analysis of preoperative images has become the most possible way to predict these indicators. Several studies(Bangalore Yogananda et al., 2020; K. S. Choi, Choi, & Jeong, 2019; Y. S. Choi et al., 2020; B. Zhang et al., 2017) using different modality images have been adopted for IDH prediction with high accuracy, but these models (e.g. deep learning) are hard to interpret intuitionally. Our individual structural abnormality indexes

provide new perspective to access both histological grade and IDH mutation, and several single indexes show high correlations with histological grade and IDH mutation. When all these indexes are combined together, the correlational values are further improved (r=0.786 and 0.654 respectively). Our results indicate the potential of these individual structural abnormality indexes in the IDH prediction, and could be integrated with other imaging biomarkers together to construct an interpretable model for IDH prediction.

Several molecular biomarkers (e.g. TERT, 1p/19q co-deletion, MGMT) are also found to be related with the treatment selection and prognosis prediction. Lower grade glioma with TERT mutation is reported to have better prognosis, and TERT mutation is also a promising indicator for the treatment response of radiotherapy and temozolomide in primary glioblastoma multiforme (GBM)(Eckel-Passow et al., 2015; Peng et al., 2020; Vuong et al., 2017; Yang et al., 2016; Yuan et al., 2016). 1p/19q co-deletion is a strong predictor of better prognosis for patients with oligodendroglioma after radiotherapy or alkylating chemotherapy(Jenkins et al., 2006; van der Voort et al., 2019). GBM patients with methylated MGMT are more sensitive to temozolomide and radiotherapy, resulting in better prognosis(Hegi et al., 2005; Lechapt-Zalcman et al., 2012; Urbschat et al., 2017). For predictions of these molecular markers, Radiomics models are usual ways with acceptable results, however, Radiomics features are also not intuitional and dependent on many factors (e.g. scanning image parameter, scanning machine type). In our study, several

abnormal indexes were found with direct correlational relationship with these molecular markers, and combination of all indexes could display high correlations with them (r=0.619,0.615 and 0.480 respectively). The results indicate that the intrinsic molecular characteristics of tumor could be reflected by the structural abnormal pattern in glioma patients.

Finally, one limitation should not be ignored: the study is with limited data from single-center. Future studies should include more patients from multicenter to verify the usefulness of the novel structural indexes.

Conclusion

We propose a series of structural indexes for glioma patients to quantify the individual structural abnormal characteristics, which are found to correlate with tumor-specific features such as WHO grade and molecular status as well as neurocognitive performance. The proposed indexes enhance the diagnostic information from conventional structural MRI, perhaps allowing for a more holistic assessment of disease severity for individual glioma patients and helping neurosurgeons to determine the personalized treatment strategies.

Reference

Bangalore Yogananda, C. G., Shah, B. R., Vejdani-Jahromi, M., Nalawade, S. S., Murugesan, G. K., Yu, F. F., . . . Maldjian, J. A. (2020). A novel fully automated MRI-based deep-learning method for classification of IDH mutation status in brain gliomas. *Neuro Oncol, 22*(3), 402-411. doi:10.1093/neuonc/noz199

Cairncross, G., Wang, M., Shaw, E., Jenkins, R., Brachman, D., Buckner, J., . . . Mehta, M. (2013). Phase III trial of chemoradiotherapy for anaplastic oligodendroglioma: long-term results of RTOG 9402. *J Clin Oncol, 31*(3), 337-343. doi:10.1200/jco.2012.43.2674

Cairncross, J. G., Ueki, K., Zlatescu, M. C., Lisle, D. K., Finkelstein, D. M., Hammond, R. R., . . . Louis, D. N. (1998). Specific genetic predictors of chemotherapeutic response and survival in patients with anaplastic oligodendrogliomas. *J Natl Cancer Inst, 90*(19), 1473-1479. doi:10.1093/jnci/90.19.1473

Chen, L., Zhang, H., Lu, J., Thung, K., Aibaidula, A., Liu, L., . . . Shen, D. (2018). Multi-Label Nonlinear Matrix Completion With Transductive Multi-Task Feature Selection for Joint MGMT and IDH1 Status Prediction of Patient With High-Grade Gliomas. *IEEE Trans Med Imaging, 37*(8), 1775-1787. doi:10.1109/tmi.2018.2807590

Choi, K. S., Choi, S. H., & Jeong, B. (2019). Prediction of IDH genotype in gliomas with dynamic susceptibility contrast perfusion MR imaging using an explainable recurrent neural network. *Neuro Oncol, 21*(9), 1197-1209. doi:10.1093/neuonc/noz095

Choi, Y. S., Bae, S., Chang, J. H., Kang, S. G., Kim, S. H., Kim, J., . . . Lee, S. K. (2020). Fully Automated Hybrid Approach to Predict the IDH Mutation Status of Gliomas via Deep Learning and Radiomics. *Neuro Oncol*. doi:10.1093/neuonc/noaa177

Darvishi, P., Batchala, P. P., Patrie, J. T., Poisson, L. M., Lopes, M. B., Jain, R., . . . Patel, S. H. (2020). Prognostic Value of Preoperative MRI Metrics for Diffuse Lower-Grade Glioma Molecular Subtypes. *AJNR Am J Neuroradiol, 41*(5), 815-821. doi:10.3174/ajnr.A6511

Eckel-Passow, J. E., Lachance, D. H., Molinaro, A. M., Walsh, K. M., Decker, P. A., Sicotte, H., . . . Jenkins, R. B. (2015). Glioma Groups Based on 1p/19q, IDH, and TERT Promoter Mutations in Tumors. *N Engl J Med, 372*(26), 2499-2508. doi:10.1056/NEJMoa1407279

Gehring, K., Roukema, J. A., & Sitskoorn, M. M. (2012). Review of recent studies on interventions for cognitive deficits in patients with cancer. *Expert Rev Anticancer Ther, 12*(2), 255-269. doi:10.1586/era.11.202

Gehring, K., Sitskoorn, M. M., Aaronson, N. K., & Taphoorn, M. J. (2008). Interventions for cognitive deficits in adults with brain tumours. *Lancet Neurol, 7*(6), 548-560. doi:10.1016/s1474-4422(08)70111-x

Hartmann, C., Hentschel, B., Wick, W., Capper, D., Felsberg, J., Simon, M., . . . von Deimling, A. (2010). Patients with IDH1 wild type anaplastic astrocytomas exhibit worse prognosis than IDH1-mutated glioblastomas, and IDH1 mutation status accounts for the unfavorable prognostic effect of higher age: implications for classification of gliomas. *Acta Neuropathol, 120*(6), 707-718. doi:10.1007/s00401-010-0781-z

Hegi, M. E., Diserens, A. C., Gorlia, T., Hamou, M. F., de Tribolet, N., Weller, M., . . . Stupp, R. (2005). MGMT gene silencing and benefit from temozolomide in glioblastoma. *N Engl J Med, 352*(10), 997-1003. doi:10.1056/NEJMoa043331

Jenkins, R. B., Blair, H., Ballman, K. V., Giannini, C., Arusell, R. M., Law, M., . . . Buckner, J. C.

(2006). A t(1;19)(q10;p10) mediates the combined deletions of 1p and 19q and predicts a better prognosis of patients with oligodendroglioma. *Cancer Res, 66*(20), 9852-9861. doi:10.1158/0008-5472.Can-06-1796

Jin, L., Shi, F., Chun, Q., Chen, H., Ma, Y., Hameed, N. U. F., . . . Wu, J. (2020). Artificial Intelligence Neuropathologist for Glioma Classification using Deep Learning on Hematoxylin and Eosin Stained Slide images and Molecular Markers. *Neuro Oncol*. doi:10.1093/neuonc/noaa163

Lasocki, A., Anjari, M., Örs Kokurcan, S., & Thust, S. C. (2020). Conventional MRI features of adult diffuse glioma molecular subtypes: a systematic review. *Neuroradiology*. doi:10.1007/s00234-020-02532-7

Lechapt-Zalcman, E., Levallet, G., Dugué, A. E., Vital, A., Diebold, M. D., Menei, P., . . . Guillamo, J. S. (2012). O(6) -methylguanine-DNA methyltransferase (MGMT) promoter methylation and low MGMT-encoded protein expression as prognostic markers in glioblastoma patients treated with biodegradable carmustine wafer implants after initial surgery followed by radiotherapy with concomitant and adjuvant temozolomide. *Cancer, 118*(18), 4545-4554. doi:10.1002/cncr.27441

Louis, D. N., Perry, A., Reifenberger, G., von Deimling, A., Figarella-Branger, D., Cavenee, W. K., . . . Ellison, D. W. (2016). The 2016 World Health Organization Classification of Tumors of the Central Nervous System: a summary. *Acta Neuropathol, 131*(6), 803-820. doi:10.1007/s00401-016-1545-1

Peng, H., Huo, J., Li, B., Cui, Y., Zhang, H., Zhang, L., & Ma, L. (2020). Predicting Isocitrate Dehydrogenase (IDH) Mutation Status in Gliomas Using Multiparameter MRI Radiomics Features. *J Magn Reson Imaging*. doi:10.1002/jmri.27434

Perry, D. C., Brown, J. A., Possin, K. L., Datta, S., Trujillo, A., Radke, A., . . . Seeley, W. W. (2017). Clinicopathological correlations in behavioural variant frontotemporal dementia. *Brain, 140*(12), 3329-3345. doi:10.1093/brain/awx254

Shibahara, I., Sonoda, Y., Kanamori, M., Saito, R., Yamashita, Y., Kumabe, T., . . . Tominaga, T. (2012). IDH1/2 gene status defines the prognosis and molecular profiles in patients with grade III gliomas. *Int J Clin Oncol, 17*(6), 551-561. doi:10.1007/s10147-011-0323-2

Smits, M., & van den Bent, M. J. (2017). Imaging Correlates of Adult Glioma Genotypes. *Radiology, 284*(2), 316-331. doi:10.1148/radiol.2017151930

Stoecklein, V. M., Stoecklein, S., Galiè, F., Ren, J., Schmutzer, M., Unterrainer, M., . . . Liu, H. (2020). Resting-state fMRI detects alterations in whole brain connectivity related to tumor biology in glioma patients. *Neuro Oncol, 22*(9), 1388-1398. doi:10.1093/neuonc/noaa044

Suh, C. H., Kim, H. S., Jung, S. C., Choi, C. G., & Kim, S. J. (2019). Imaging prediction of isocitrate dehydrogenase (IDH) mutation in patients with glioma: a systemic review and meta-analysis. *Eur Radiol, 29*(2), 745-758. doi:10.1007/s00330-018-5608-7

Urbschat, S., Sippl, C., Engelhardt, J., Kammers, K., Oertel, J., & Ketter, R. (2017). Importance of biomarkers in glioblastomas patients receiving local BCNU wafer chemotherapy. *Mol Cytogenet, 10*, 16. doi:10.1186/s13039-017-0317-5

van der Voort, S. R., Incekara, F., Wijnenga, M. M. J., Kapas, G., Gardeniers, M., Schouten, J. W., . . . Smits, M. (2019). Predicting the 1p/19q Codeletion Status of Presumed Low-Grade Glioma with an Externally Validated Machine Learning Algorithm. *Clin Cancer Res, 25*(24), 7455-7462. doi:10.1158/1078-0432.Ccr-19-1127

Vuong, H. G., Altibi, A. M. A., Duong, U. N. P., Ngo, H. T. T., Pham, T. Q., Chan, A. K., . . . Hassell, L.

(2017). TERT promoter mutation and its interaction with IDH mutations in glioma: Combined TERT promoter and IDH mutations stratifies lower-grade glioma into distinct survival subgroups-A meta-analysis of aggregate data. *Crit Rev Oncol Hematol, 120*, 1-9. doi:10.1016/j.critrevonc.2017.09.013

Yang, P., Cai, J., Yan, W., Zhang, W., Wang, Y., Chen, B., . . . Jiang, T. (2016). Classification based on mutations of TERT promoter and IDH characterizes subtypes in grade II/III gliomas. *Neuro Oncol, 18*(8), 1099-1108. doi:10.1093/neuonc/now021

Yuan, Y., Qi, C., Maling, G., Xiang, W., Yanhui, L., Ruofei, L., . . . Qing, M. (2016). TERT mutation in glioma: Frequency, prognosis and risk. *J Clin Neurosci, 26*, 57-62. doi:10.1016/j.jocn.2015.05.066

Zhang, B., Chang, K., Ramkissoon, S., Tanguturi, S., Bi, W. L., Reardon, D. A., . . . Huang, R. Y. (2017). Multimodal MRI features predict isocitrate dehydrogenase genotype in high-grade gliomas. *Neuro Oncol, 19*(1), 109-117. doi:10.1093/neuonc/now121

Zhang, G. B., Cui, X. L., Sui, D. L., Ren, X. H., Zhang, Z., Wang, Z. C., & Lin, S. (2013). Differential molecular genetic analysis in glioblastoma multiforme of long- and short-term survivors: a clinical study in Chinese patients. *J Neurooncol, 113*(2), 251-258. doi:10.1007/s11060-013-1102-x

Table 1 The demographic and clinical information of all subjects.

	Glioma patients	Healthy controls
Number	52	117
Sex (M/F)	34/18	83/34
Age	43.2±9.3	32.6±9.8
TIV	1484.1±116.2	1459.5±145.2
Tumor volume	59.6±66.1	-
Histological grade (II/III/IV)	35/11/6	-
IDH1 mutation (mutated/wild)	42/10	-
TERT promoter mutation (mutated/wild)	33/19	-
1p/19q deletion (both 1p/19q /only 19q/only 1p/none)	24/5/4/19	-
MGMT promoter methylation	0.25±0.16	-
MOCA	22.2±5.0	-

Abbreviation: IDH, isocitrate dehydrogenase; MGMT, O^6-methylguanine-DNA methyltransferase; MOCA, Montreal Cognitive Assessment; TERT, telomerase reverse transcriptase; TIV, total intracranial volume.

Table 2 The proposed 16 structural abnormality indexes.

Abnormality index	Description
GM/WM atrophy ratio in tumor hemisphere	$= \frac{number\ of\ GM/WM\ atrophy\ voxels\ in\ hemisphere\ with\ tumor}{number\ of\ all\ voxels\ in\ hemisphere\ with\ tumor}$
GM/WM atrophy ratio in contralateral hemisphere	$= \frac{number\ of\ GM/WM\ atrophy\ voxels\ in\ contralateral\ hemisphere}{number\ of\ all\ voxels\ in\ contralateral\ hemisphere}$
GM/WM enlargement ratio in tumor hemisphere	$= \frac{number\ of\ GM/WM\ increasement\ voxels\ in\ hemisphere\ with\ tumor}{number\ of\ all\ voxels\ in\ hemisphere\ with\ tumor}$
GM/WM enlargement ratio in contralateral hemisphere	$= \frac{number\ of\ GM/WM\ increasement\ voxels\ in\ contralateral\ hemispher}{number\ of\ all\ voxels\ in\ contralateral\ hemisphere}$
GM/WM abnormality ratio in tumor hemisphere	$= \frac{number\ of\ abnormal\ GM/WM\ voxels\ in\ hemisphere\ with\ tumor}{number\ of\ all\ voxels\ in\ hemisphere\ with\ tumor}$
GM/WM abnormality ratio in contralateral hemisphere	$= \frac{number\ of\ abnormal\ GM/WM\ voxels\ in\ contralateral\ hemisphere}{number\ of\ all\ voxels\ in\ contralateral\ hemisphere}$
GM/WM abnormality in non-cancer region compared with whole brain	$= \frac{number\ of\ abnormal\ GM/WM\ voxels\ in\ non-cancer\ region}{number\ of\ all\ abnormal\ voxels\ in\ whole\ brain}$
GM/WM abnormality in non-cancer region compared with cancer region	$= \frac{number\ of\ abnormal\ GM/WM\ voxels\ in\ non-cancer\ region}{number\ of\ abnormal\ GM/WM\ voxels\ in\ cancer\ region}$

Abbreviation: GM, gray matter; WM, white matter

Table 3 The correlation value between individual structural abnormality index and molecular indicators.

Molecular indicators	Individual structural abnormality index	Correlation value (Spearman)
WHO histological grade	GM-ART	0.304
	GM-ABRT	0.408
	WM-ART	0.375
	WM-ERT	0.322
	WM-ABRT	**0.457**
	GM-ABNW	-0.323
	GM-ABNC	-0.357
IDH1 mutation	GM-ART	-0.335
	GM-ABRT	-0.326
	GM-ABNC	**0.330**
1p/19q deletion	GM-ART	-0.396
	GM-ABRT	-0.422
	WM-ERT	-0.291
	GM-ABNW	0.465
	GM-ABNC	0.433
	WM-ABNW	**0.468**
	WM-ABNC	0.397
TERT mutation	GM-ART	-0.331
	GM-ABRT	-0.334
	GM-ABNW	**0.440**
	GM-ABNC	0.382
	WM-ABNW	0.435
	WM-ABNC	0.355
MOCA	**WM-ARC**	**0.290**
	WM-ERT	-0.284

Abbreviation: ABNC, abnormality in non-cancer region in comparison to cancer region; ABNW, abnormality in non-cancer region in comparison to whole brain; ABRT, abnormality ratio in tumor hemisphere; ARC, atrophy ratio in contralateral hemisphere; ART, atrophy ratio in tumor hemisphere; ERT, enlargement ratio in tumor hemisphere; GM, gray matter; IDH, isocitrate dehydrogenase; MOCA, Montreal Cognitive Assessment; TERT, telomerase reverse transcriptase; WHO, World Health Organization; WM, white matter.

Figures

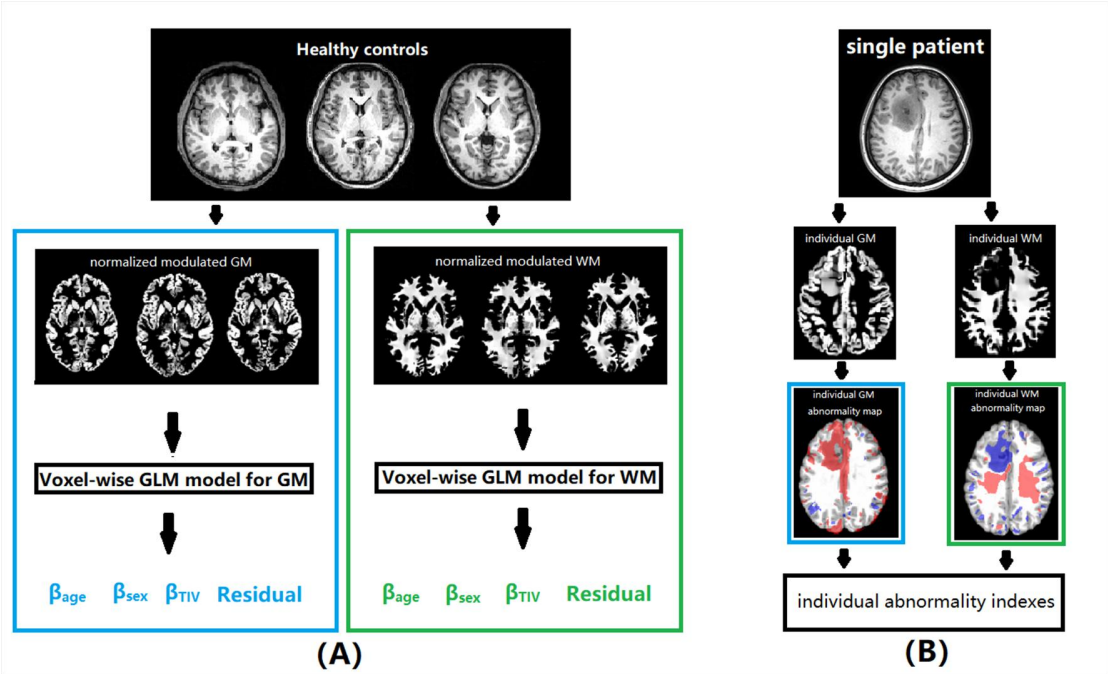

Figure 1 The flowchart of the proposed structural abnormality indexes: (A). the construction of normative brain volume model; (B). the calculation of the proposed individual abnormality indexes.

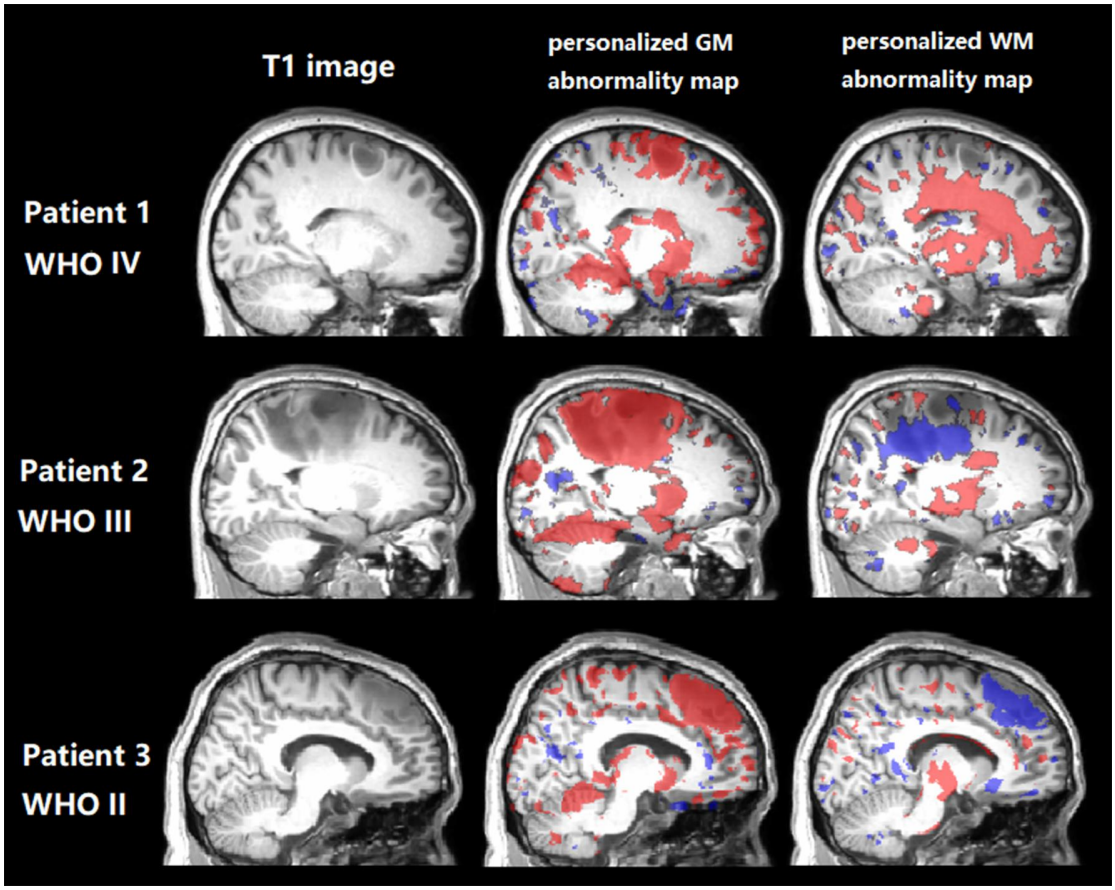

Figure 2 Several examples of personalized GM/WM abnormality maps.

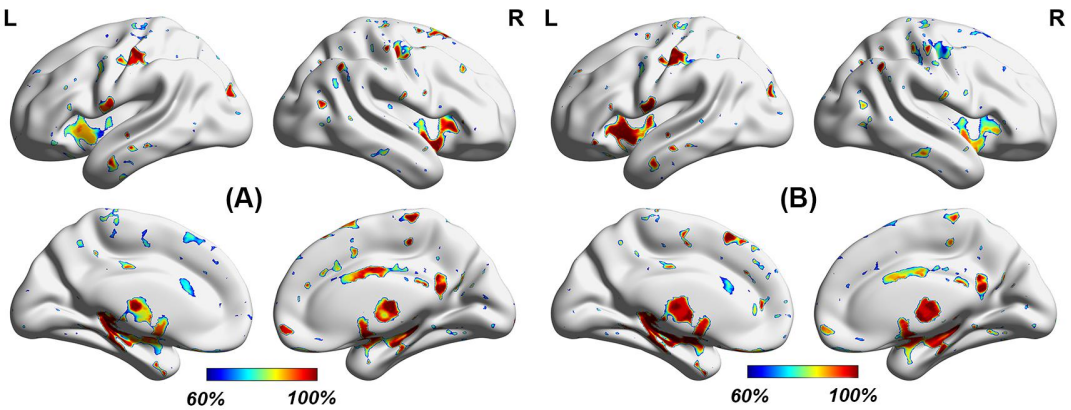

Figure 3 Overlapping gray matter abnormalities in non-tumor regions for all patients with tumor on (A) left hemisphere and (B) right hemisphere. Notably, 60% in the color-bar means 60% of all patients displayed abnormality in corresponding position.

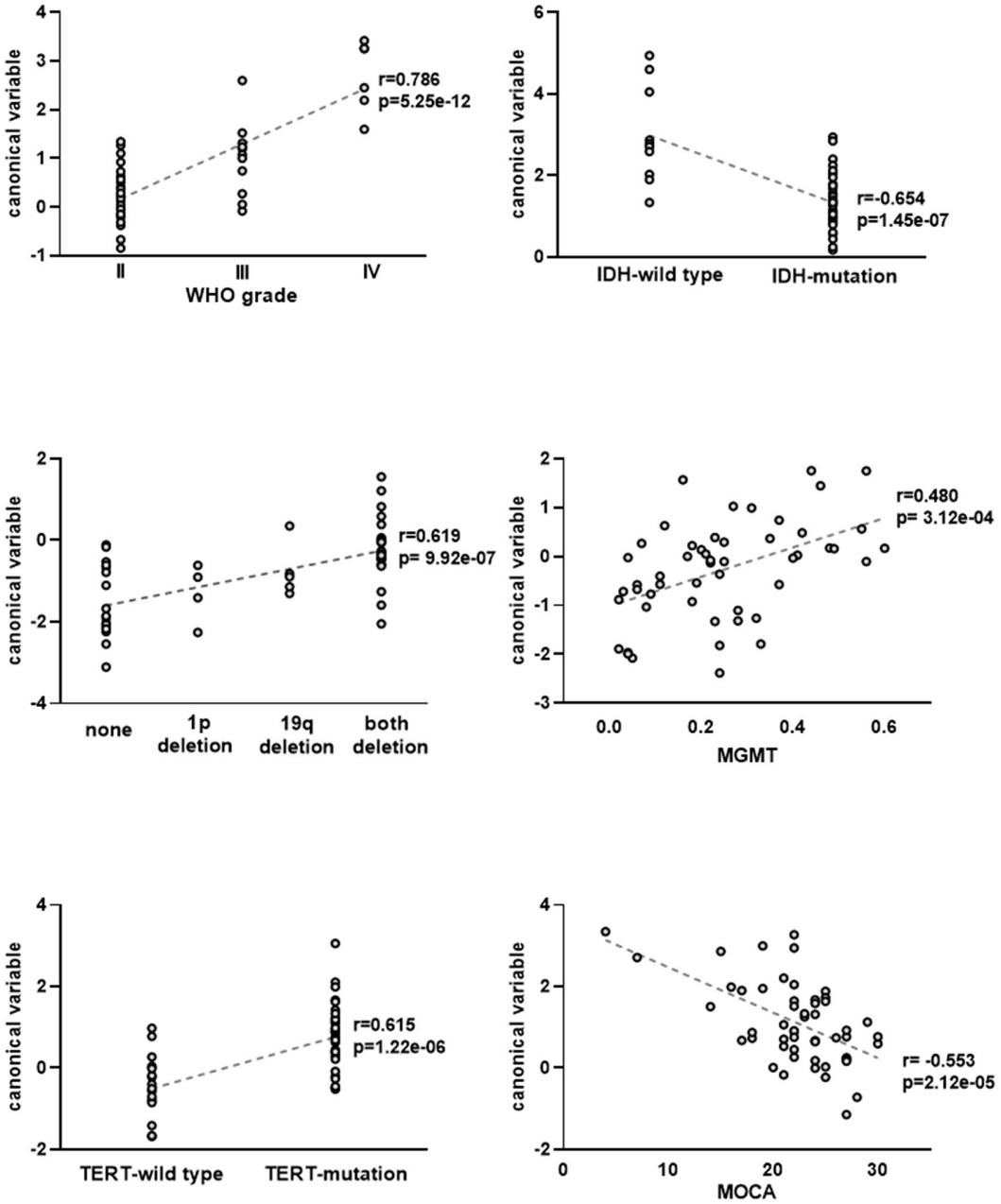

Figure 4 The scatter plot between the generated canonical variable (linear combination of individual structural abnormality indexes) and molecular, histological, and cognitive indicators