RUNNING TITLE: Dentate Connectivity Across Adulthood

Cerebellar Dentate Connectivity Across Adulthood: A Large-Scale Resting State Functional Connectivity Investigation

Jessica A. Bernard[1,2*], Hannah K. Ballard[2], & T. Bryan Jackson[1]

[1]Department of Psychological and Brain Sciences
[2]Texas A&M Institute for Neuroscience
Texas A&M University

***Corresponding Author**
Jessica A. Bernard, PhD
Department of Psychological and Brain Sciences
Texas A&M University
979-845-2581
Jessica.bernard@tamu.edu

Abstract

Cerebellar contributions to behavior in advanced age are of great interest and importance, given its role in motor and cognitive performance. There are differences and declines in cerebellar structure in advanced age, and cerebellar resting state connectivity is decreased. However, the work on this area to date has focused on the cerebellar cortex. The deep cerebellar nuclei provide the primary cerebellar inputs and outputs to the cortex, as well as the spinal and vestibular systems. In both human and non-human primate models, dentate networks can be dissociated such that dorsal region is associated with the motor cortex, while the ventral aspect is associated with the prefrontal cortex. However, whether or not dentato-thalamo-cortical networks differ across adulthood remains unknown. Here, using a large adult sample (n=591) from the Cambridge Center for Ageing and Neuroscience, we investigated dentate connectivity across adulthood. First, we replicated past work showing dissociable resting state networks in the dorsal and ventral aspects of the dentate. Second, in both seeds, we demonstrated connectivity decreases with age, indicating that connectivity differences extend beyond the cerebellar cortex. This expands our understanding of cerebellar circuitry in advanced age, and further underscores the potential importance of this structure in age-related performance differences.

Keywords: aging, cerebellum, dentate, resting state connectivity, sex differences

Introduction

In the last century we have seen a rapid increase in the human lifespan and demographic shifts, wherein aging individuals make up an increasingly large proportion of the population. As such, understanding the aging mind and brain is of increasing importance for the quality of life and health of older adults (OA). Even in the best cases of healthy aging without known neurological or somatic pathology, differences in both cognitive and motor performance are observed in OA (Park and Reuter-Lorenz 2009; Seidler et al. 2010; Reuter-Lorenz and Park 2014; Cabeza et al. 2018). Understanding normative differences in brain function and organization in young adults (YA) and OA provides critical insights into the underpinnings of the behavioral changes observed in healthy aging. Furthermore, understanding normative aging and the associated brain and behavioral trajectories across adulthood stand to provide important insights and points of comparison for investigations of age-related diseases, such as Alzheimer's Disease.

With this in mind, there have been significant advances in our understanding of age differences in brain structure and function, as well as changes over time. We know now that even in healthy aging there are marked differences in brain structure (e.g., Raz et al. 1997, 1998, 2013; Bernard and Seidler 2013; Bernard et al. 2015), patterns of functional activation (Reuter-Lorenz et al. 1999; Cabeza 2002; Cabeza et al. 2002, 2018; Reuter-Lorenz and Cappell 2008), and network connectivity (Andrews-Hanna et al. 2007; Tomasi and Volkow 2012; Ferreira and Busatto 2013; Bo et al. 2014; Ferreira et al. 2016). However, to this point much of the focus of research in understanding the aging mind and brain has focused on cortical contributions, and the cerebellum has been relatively understudied. Work over the past two decades has increasingly pointed to the cerebellum as a contributor to age-related performance differences when investigating volume (MacLullich et al. 2004; Bernard and Seidler 2013; Miller et al. 2013; Koppelmans et al. 2015, 2017), and we have known for quite some time that cerebellar volume is smaller in older adults and declines in volume over time (Raz et al. 1998, 2005, 2010, 2013; Han et al. 2020). Furthermore, there are age differences in lobular cerebellar connectivity as well (Bernard et al. 2013), and subcortically, differing patterns of connectivity between the cerebellum and basal ganglia (Hausman et al. 2020).

Within the cerebellum are a series of nuclei, which are the primary output nodes of the structure. The largest of these nuclei, the dentate, provides the primary output to the cerebral cortex. Work in non-human primates has demonstrated that there are two dissociable circuits connecting the dentate with the cerebral cortex. The more dorsal aspects of the dentate are associated with motor cortical regions, while the ventral aspect of the dentate is connected (via the thalamus) with the lateral prefrontal cortex (Dum and Strick 2003a). In the human brain, we used resting state functional connectivity (fcMRI) to investigate these dissociable circuits (Bernard et al. 2014). We used cerebellar-specific normalization methods (Diedrichsen 2006; Diedrichsen et al. 2009) in conjunction with single-voxel seeds, and we demonstrated that the dorsal and ventral dentate networks can in fact be dissociated in the human brain using fcMRI (Bernard et al. 2014). This dissociation has been further confirmed using high-resolution diffusion tensor imaging in the human brain (Steele et al. 2017). Most recently, Guell and colleagues suggested that the human dentate may optimally be divided into three unique functional sub-regions (Guell et al. 2020). To this point, there are no anatomical data to support this three-way dissociation and it is based on fcMRI data; however, such a dissociation with white matter is also likely to be highly technically challenging.

Though our understanding of cerebellar connectivity, particularly that of the cerebellar dentate nucleus has greatly expanded in recent years, it remains unknown whether networks of the dentate nucleus are different across the lifespan. While prior work has demonstrated that connectivity of the cerebellar lobules is lower in OA (Bernard et al. 2013; Hausman et al. 2020), to date, the dentate nucleus has not been investigated across the adult lifespan. While cerebellar lobular approaches are informative and reflect purported changes in processing and communication with the cerebral cortex, given that the dentate nucleus is a critical aspect of this circuit as the primary output region to the cerebral cortex, further investigation is warranted. As such, we used a large data set including individuals across adulthood from ages 18 to 88 available from the Cambridge Center for Ageing Neuroscience (CamCAN) repository (Shafto et al. 2014; Taylor et al. 2017). We tested the hypothesis that dentate connectivity is impacted with advanced age and predicted that connectivity of both the dorsal and ventral dentate would be lower with increased age. In parallel, we were also interested in whether or not our initial findings using cerebellar specific methods would replicate in a large sample such as this, using more general analysis approaches. That is, can we still effectively dissociate dorsal and ventral dentate networks in the human brain with standard imaging analysis pipelines?

Finally, when looking at associations between age and cerebellar metrics, to this point, investigations of sex differences are relatively limited, despite evidence to suggest that there may be sex differences in cerebellar structure (Raz et al. 1998; Bernard et al. 2015; Han et al. 2020). In our own work investigating lobular cerebellar volume across adolescence through middle age we found that associations between regional volume and age differed in males and females. In the posterior cerebellum, females were best fit using a quadratic function such that volumes were largest in those in their late 20s and 30s, and there was a sharp decrease in volume in early middle age (Bernard et al., 2015). This is in contrast to males that showed linear relationships with age. More generally, Steele and Chakravarty (Steele and Chakravarty 2018) demonstrated sex differences in adults in lobular volume. Critically however, though females live longer than males, they experience poorer later life outcomes, including a higher incidence of Alzheimer's disease (Carter et al. 2012), and risk of falls and associated impairment is higher (Stevens and Sogolow 2005; Hartholt et al. 2011). While the latter is no doubt compounded by peripheral changes in musculature and the incidence of osteoporosis, health outcomes in older females underscore the importance of detailed investigation into factors that may contribute to these trajectories. Given that the cerebellum has been implicated in a variety of motor and cognitive domains (e.g., Stoodley et al. 2012; King et al. 2019), and more recently has been implicated in Alzheimer's disease (Tabatabaei-Jafari et al. 2017; Jacobs et al. 2018; Toniolo et al. 2018; Olivito et al. 2020), understanding sex differences in dentate connectivity with age will provide important new insights into sex differences in cerebellar connectivity across adulthood. Though literature in this area is relatively limited, we hypothesized that females would show greater effects of age such that there are more extensive negative correlations between age and dentate connectivity in both the dorsal and ventral dentate, relative to males.

Methods

Data

Data used in the preparation of this work were obtained from the CamCAN repository (available at http://www.mrc-cbu.cam.ac.uk/datasets/camcan/)(Shafto et al. 2014; Taylor et al.

2017). Participants included in this investigation had both resting state and structural brain imaging data available. After excluding individuals with missing resting state data, the final sample included 591 people (289 females) between the ages of 18 and 88 (mean age 54.54 $\pm$ 18.65 years). Data were collected using a 3T Siemens TimTrio. Complete data collection details can be found online (see link above), and are outlined by Shafto and colleagues (2014) and Taylor and colleagues (2017). The former also includes data on participant sampling approaches. For our analyses here, we used the T1 MPRAGE along with the resting state EPI scans. The resting state scan was approximately 8:30 minutes. The voxel size of the acquired resting state data was 3x3x4.4mm. Raw data were acquired and used here.

Processing and Analysis

Methods for data processing used here parallel those from our recent work (Bernard et al. 2017; Hausman et al. 2020) and have been reported here for the sake of completeness and transparency. All data were processed and analyzed using the CONN toolbox version 18b ((Whitfield-Gabrieli and Nieto Castañón 2012). We followed the standard preprocessing pipeline in CONN, including functional realignment and unwarping, functional centering of the image to (0, 0, 0) coordinates, slice-timing correction, structural centering to (0, 0, 0,) coordinates, structural segmentation and normalization to MNI space, functional normalization to MNI space, and spatial smoothing with a smoothing kernel of 6mm FWHM. This paralleled the approach taken in recent investigations conducted by our group (Bernard et al. 2017; Hausman et al. 2020). Because of the potential confounding effects of motion and signal outliers (Power et al. 2012; Van Dijk et al. 2012) these procedures also included processing using the Artifact Rejection Toolbox (ART). This was set using the 95th percentile settings and allowed for the quantification of participant motion in the scanner and the identification of outliers based on the mean signal. These effects, as well as white matter and cerebral-spinal fluid signals, were included as confounds and regressed out during denoising, prior to first level analysis. Data were denoised using a band-pass filter of .008 - .09 Hz. With these settings, the global-signal z-value threshold was set at 9, while the subject-motion threshold was set at 2 mm. 6-axis motion information and frame-wise outliers were included as covariates in our subsequent first-level analyses. Notably however, these frame-wise outliers are not removed, but the signal is de-spiked to bring it closer to the global mean during the denoising process. The 6 motion covariates were reduced to one variable by averaging the absolute value of each axes' average and the frame-wise time-series was averaged across each participant, resulting in one value for each measure for each participant for group comparison.

Seeds used for analysis were placed in both the dorsal and ventral dentate using regions defined in our earlier work investigating dissociable human dentate circuits (Bernard et al. 2014). The dorsal dentate seed was centered on (12, -57, -30) while the ventral seed was centered on (17, -65, -35) (Figure 1). Spherical seeds corresponding in size to a single voxel (3mm diameter) were created and used in all analyses. While recent work has suggested there may be a third sub-region in the dentate nucleus (Guell et al. 2020), we focused here on only two sub-regions. Primarily, this is due to the known anatomical underpinnings of these particular circuits. While Guell and colleagues used a parcellation approach with resting state data (2020), to this point, there are no known white matter circuits subserving a third region. While future work may resolve additional white matter tracts in the non-

human and human primate brains, our aim here was to stick with functional networks known to map on to underlying structural circuitry. In addition, given the voxel size of the images available through the CamCAN repository, our goal was to eliminate overlap between the seed territories, and as such we limited ourselves to these two regions.

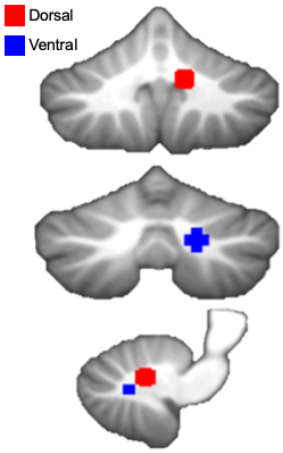

Figure 1. Dorsal and ventral dentate seeds locations. These seeds parallel those used by Bernard and colleagues (2014) and were chosen to be non-overlapping as pictured here.

After pre-processing we completed first-level and group-level analysis, also using CONN. At the whole group level, we first replicated our prior analyses comparing dorsal and ventral dentate connectivity using standard imaging analysis approaches. Next, we conducted a regression with participant age to determine the relationship between age and dentate network connectivity. Finally, we conducted exploratory analyses to investigate whether and how these patterns may differ in males and females across adulthood. We conducted correlation analyses between age and dentate seed connectivity in males and females separately. Further, we directly compared dentate connectivity patterns between the two sexes. In all cases, analyses were evaluated using a voxel threshold of $p<.001$, followed by a cluster threshold that was FDR corrected at $p<.05$.

Results

Dorsal and Ventral Networks

First, across the whole sample we investigated the dorsal and ventral dentate networks. While we have previously shown a dissociation between the dorsal and ventral networks in a small sample using cerebellar-specific methods (Bernard et al. 2014), our findings here suggest that these networks can be dissociated across large representative adult samples using more traditional brain imaging analysis approaches. First, the dorsal dentate seed shows robust connectivity with primary and premotor areas bilaterally (Figure 2, Supplementary Table 1). Notably however in the right hemisphere, there were also areas of correlation with the lateral prefrontal cortex. Second, in contrast, the ventral dentate showed robust connectivity with the lateral prefrontal cortex, parietal, and temporal cortices (Figure 2; Supplementary Table 1). These findings are consistent with our prior work (Bernard et al. 2014), and other replications (Steele et al. 2017; Guell et al. 2020).

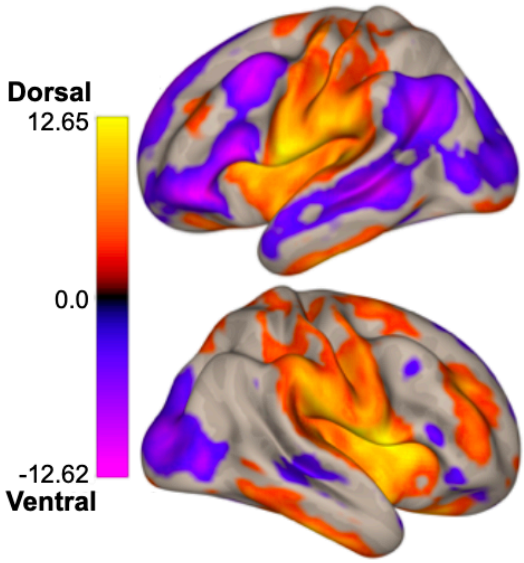

Figure 2. Functional connectivity patterns for the dorsal (yellow/orange) and ventral (blue/purple/pink) dentate seeds. The patterns of connectivity for the two seeds parallel the dissociation seen in non-human primates and in human work, even when using traditional whole-brain processing and analysis approaches.

Associations With Age Across Adulthood

After replicating the dorsal and ventral dentate connectivity dissociation in this large adult sample, we investigated the age-associations for each seed. Though we predicted lower connectivity with increasing age, both negative and positive correlations were investigated. When investigating the dorsal dentate, we found that connectivity does in fact get lower with increasing age in pre-motor, motor, and somatosensory regions of the network (Figure 3, Table 1). Though the most extensive and robust findings are negative correlations, several positive correlations were also revealed. With increasing age connectivity between the dorsal dentate and occipital lobe, inferior temporal gyrus, temporal fusiform junction, and frontal pole is higher. Notably however, these areas of higher connectivity with age are outside of the primary dorsal dentate nucleus network which typically consists of motor cortical regions (e.g., Dum and Strick 2003; Strick et al. 2009; Bernard et al. 2014)

Investigations of the ventral dentate nucleus seed also primarily revealed negative correlations with age. With increasing age, connectivity is lower in the dorsal pre-motor, parietal, and anterior temporal lobe regions. Notably however, the negative correlations are qualitatively less extensive than those for the dorsal dentate.

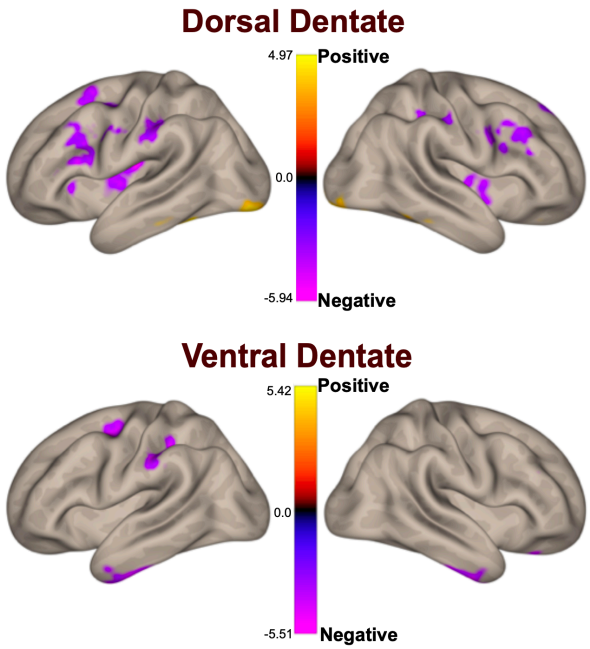

Figure 3. Associations between connectivity and age for the dorsal (top) and ventral (bottom) dentate seeds. While there are some positive associations reported (see Table 1), the views here primarily demonstrate negative associations between connectivity strength and age (purple), though some small regions of positive correlation (yellow/orange) with the dorsal dentate seen are visible in the temporal lobe.

Sex Differences

Finally, we completed exploratory analyses of sex differences in cerebellar dentate connectivity. A growing literature indicates sexual dimorphism of the cerebellum that is present in older adulthood (e.g., Raz et al. 1998; Bernard et al. 2015; Han et al. 2020). While the literature to date has primarily focused on cerebellar structure and volume, here we investigated dentate connectivity with respect to age in both males and females, as well as sex differences in dentate connectivity when collapsing across the entire sample. Most notably, qualitatively, the results are much more robust in females when investigating negative correlations between connectivity and age. With increasing age in females there is significantly lower connectivity between the dorsal dentate and premotor cortical regions (superior frontal gyrus), the putamen, and also in the anterior cingulate cortex. In the ventral dentate, connectivity is lower in older females again in the anterior cingulate, the caudate, as well as temporal lobe regions, including the parahippocampal gyrus. In males, in addition to showing associations with age that appear less extensive, they are also different in region. Older males show decreased connectivity between the dorsal dentate and the inferior frontal gyrus *pars opercularis,* central opercular cortex, and supramarginal gyrus, while with the ventral dentate there are decreases with age in connectivity in the temporal lobe (inferior and superior temporal gyrus, temporal fusiform), post-central gyrus, superior frontal gyrus, posterior cingulate, and orbitofrontal cortex. In both sexes, there were also some patterns of increased connectivity for each of the dentate seeds, and again, these are qualitatively more extensive in females. Detailed findings are presented in Tables 2 and 3, and are visualized in Figure 4.

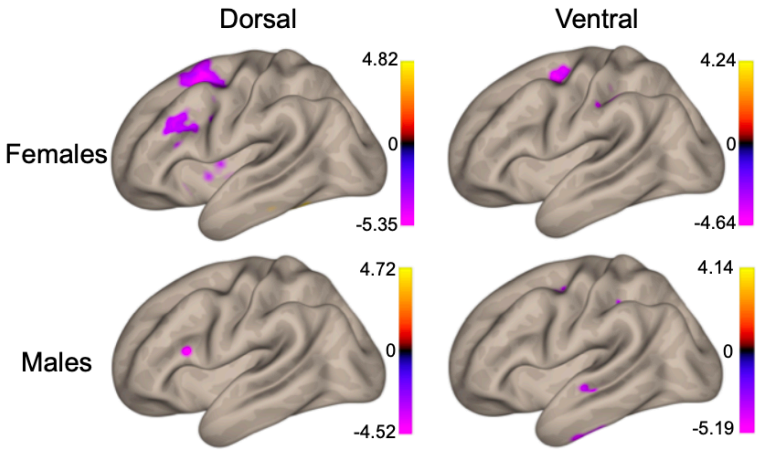

Figure 4. Correlations between the dorsal (left) and ventral (right) regions of the dentate nucleus with age in females (top) and males (bottom). Notably, the negative correlations are more extensive in females, particularly for the dorsal dentate seed.

When collapsing across the sample to look at sex differences in network connectivity, several small differences were observed. Males showed greater connectivity relative to females between the dorsal dentate and both the lingual gyrus and cerebellar lobule X, and between the ventral dentate and cerebellar lobule V. Females showed greater connectivity relative to males between the dorsal dentate and the supramarginal gyrus, angular gyrus, and inferior temporal gyrus (Table 4). Thus, in this sample, collapsing across the adult lifespan, there are some small sex differences in connectivity in the dorsal and ventral dentate networks. However, when looking at sex differences in the relationships with age, the patterns and extent of these relationships are much more robust. Generally, the associations with age in females are qualitatively more extensive than those in males, suggesting sex differences in patterns of aging with respect to these networks.

Discussion

Here, using a large sample of adults, representing the adult lifespan, we investigate patterns of resting state connectivity in the dorsal and ventral dentate nucleus. First, we demonstrated that we can replicate prior results computed with cerebellar-specific analyses when using more standard imaging analysis protocols. We demonstrated a clear dissociation in the patterns of dorsal and ventral dentate connectivity, such that the dorsal dentate was robustly connected with primary and pre-motor cortical regions, while the ventral dentate was more strongly correlated with pre-frontal and association areas of the cerebral cortex. Furthermore, we demonstrated that across adulthood, connectivity between both seeds and their associated cortical networks was lower in advanced age. As individuals get older, connectivity between dentate sub-regions decreases. Finally, we demonstrated that in females and males, we see distinct patterns of connectivity associations with age. Females showed more extensive patterns of age associations, indicating that perhaps these networks are particularly vulnerable across adulthood in females.

Dentate Dissociation Replication

Work in non-human primates elegantly demonstrated that the dorsal and ventral dentate nucleus territories are part of parallel circuits with the motor and prefrontal regions of the cortex,

respectively (Dum and Strick 2003b). Initial work seeking to map these same circuits functionally at rest in the human brain relied upon data processing approaches that were optimized for cerebellar imaging (Bernard et al. 2014). While this work demonstrated that the human dentate nucleus does have at least two distinct territories with dissociable circuits in the human brain, whether or not these circuits can be dissociated using whole-brain methods was to this point, unknown. Here, we used traditional processing and whole-brain methods while investigating the dissociability of the dorsal and ventral dentate nucleus sub-regions. Consistent with our prior work, as well as subsequent work replicating this pattern of dissociation in the human brain (Steele et al. 2017; Guell et al. 2020), we further demonstrated that the dorsal dentate region is more robustly correlated with motor cortical regions, while the ventral dentate is more robustly correlated with prefrontal and association cortices. Together, this demonstrates that more general processing parameters may be sufficient for dissociating these networks, at least in larger samples, such as the one used here.

Dentate Network Connectivity Across Adulthood

The primary goal of our work here was to determine whether networks of the cerebellar dentate nucleus follow patterns with age that parallel those of the cerebellar cortex. Across both seed regions, we saw robust negative correlations with age, consistent with our prior work demonstrating lower cerebellar connectivity in advanced age (Bernard et al. 2013; Hausman et al. 2020). Notably, these negative correlations with age correspond to the key areas of the dorsal and ventral dentate networks themselves. That is, in the dorsal dentate, as individuals get older, connectivity is lower in primary motor and somatosensory regions, while in the ventral dentate connectivity is lower in prefrontal and temporal lobe regions. More broadly, this is consistent with widespread differences in resting state network dynamics as individuals age, seen across cortical networks (Andrews-Hanna et al. 2007; Tomasi and Volkow 2012; Ferreira and Busatto 2013; Ferreira et al. 2016). Further, longitudinal evidence suggests that there are in fact changes over time in cortical resting state connectivity in OA (Oschmann and Gawryluk 2020). However, it is also critical to note the multi-directionality in these results. While there are negative associations between connectivity and age in the core areas associated with the dorsal and ventral dentate networks, both seeds also showed positive correlations with brain regions outside the core networks themselves. Though somewhat surprising, these connectivity increases may be reflective of an attempt at compensation or use of neural scaffolding to maintain function (Park and Reuter-Lorenz 2009; Reuter-Lorenz and Park 2014; Cabeza et al. 2018). Alternatively, this may be indicative of a decreased efficiency in brain network organization. However, without behavioral data and associations we can only speculate.

Critically, these results provide further insights as to the extent to which cerebellar networks are impacted in older adulthood. Perhaps not surprisingly, the cerebellar dentate nucleus is also negatively impacted in advanced age, as quantified by resting state connectivity. There are two key considerations for these findings. First, there is an open question as to the mechanism driving these negative relationships with age. That is, why do OA show decreased cerebellar connectivity, relative to young? With respect to the cerebellum specifically, we and others have previously demonstrated age differences in lobular volume (Bernard and Seidler 2013; Koppelmans et al. 2015, 2017; Han et al. 2020), and more recent investigations have confirmed these differences and also noted volumetric declines over time (Han et al. 2020). We have speculated that differences in volume as well as

connectivity may negatively impact cerebellar processing in advanced age (Bernard and Seidler 2014), which in turn may contribute to the performance differences seen across the motor and cognitive domains in OA. Here however, we have extended findings to indicate that dentate connectivity is also negatively impacted in aging. With that in mind, given that these nuclei serve as the output region of the cerebellum, and receive input from the cerebellar cortex, the age differences in dentate connectivity reported here may reflect differences in lobular processing. Investigating the relative associations between lobular and dentate connectivity respectively in the context of behavior and functional outcomes in the future, may begin to tease apart the relative contributions of age differences in lobular and dentate connectivity.

However, changes in neurotransmitter systems may also contribute to the age differences in dentate connectivity. Previously, we have demonstrated marked differences in connectivity between the cerebellum and basal ganglia in OA relative to YA (Bernard et al. 2013; Hausman et al. 2020) using lobular cerebellar seeds. We speculated that age differences in dopamine may be contributing, at least in part, to the differences in connectivity in advanced age. As noted, work by Kelly and colleagues (Kelly et al. 2009) demonstrated that the administration of l-dopa increased connectivity between the striatum and cerebellum in healthy YA. Here, though we are looking at dentate connectivity, we suggest that normative age-differences in dopamine (McGeer et al. 1977; Fearnley and Lees 1991) may be contributing in part to the differences seen here. In parallel, other neurotransmitter differences in advanced age may also be impacting cerebellar connectivity patterns. Serotonin, GABA, and acetylcholine all act in the cerebellum (Oostland and van Hooft 2016) and are impacted in advanced age. Normative age-differences in neurotransmitter action may in turn impact cerebellar processing (as well as cerebral cortical processing) and associated connectivity patterns at rest. Targeting these neurotransmitters, in conjunction with investigations of connectivity in the future stands to provide new insights into these age differences.

The second area of consideration for these findings is with respect to their implications for our understanding of age-related disease, particularly mild cognitive impairment and dementia. Though historically the cerebellum has not been a major target of investigation in dementia, and more specifically in Alzheimer's Disease (AD), in recent years, this has changed (for a review see Jacobs et al. 2018). Notably, converging evidence indicates that the cerebellum is impacted in AD. Cerebellar decline has been linked to functional decline in advanced AD (Tabatabaei-Jafari et al. 2017), and there is additional evidence to indicate that there are relationships between the cerebellar volume and cognition in mild cognitive impairment (Lin et al. 2020). In a recent meta-analysis Gellersen and colleagues (Gellersen et al. 2020) demonstrated that in the cerebellum, there are some overlapping areas of cerebellar structural loss when comparing AD to normative healthy aging. However, differences were also observed between the two groups wherein atrophy in AD was primarily lateralized to the right hemisphere (Gellersen et al. 2020). Broadly, this work suggests an increasing need for further investigation of the cerebellum in AD, as it may not be entirely spared structurally. With respect to functional networks, in patients with AD, cerebellar connectivity with the cortex is decreased (Zheng et al. 2017), and patterns of atrophy in the cerebellum are in areas associated with the default mode and salience networks, perhaps impacting general network coherence (Guo et al. 2016). Further, the dentate itself has been investigated in AD. Interestingly, Olivito and colleagues

(2020) found *increased* connectivity between the dentate and regions of the medial temporal lobe in patients with AD relative to controls. However, they did not investigate the distinct dentate sub-regions (Olivito et al. 2020), which may have impacted their findings. This is somewhat surprising, given work on the cerebellar cortex (Zheng et al. 2017). We suggest that the work presented here represents an important point of comparison for that in clinical populations, particularly dementia, as we have characterized patterns of dentate connectivity across the adult life span with both the dorsal and ventral regions dissociated. Additional follow up work comparing AD and mild cognitive impairment samples to this work in healthy adults will provide further insights into diverging trajectories in healthy aging and disease.

Sex Differences in Dentate Connectivity

In addition to quantifying the associations between dorsal and ventral dentate nucleus connectivity and age across adulthood, we also investigated sex differences in dentate connectivity. Our results support sex differences in dentate connectivity, and notably, our results suggest that in females the regions of decreased connectivity with age are qualitatively more extensive than those in males. Notably, the size of the clusters showing negative correlations in females particularly for the dorsal dentate seed, are substantially larger than for males. This suggests potential sex differences in the process of aging with respect to cerebellar functional networks. Sexual dimorphism in cerebellar structure has been reported (Oguro et al. 1998; Raz et al. 2001; Tiemeier et al. 2010; Bernard et al. 2015; Steele and Chakravarty 2017), though the results have been somewhat mixed to this point, particularly when looking at broad anatomical swaths of the cerebellum, such as an entire hemisphere, or the cerebellar vermis in its entirety. These different patterns however, are consistent with our own work showing sex differences age-volume relationships when investigating regional cerebellar volume across adolescence through late middle age (Bernard et al. 2015). While these differences were in volume of the cerebellar lobules, it suggests that cerebellar relationships with age may differ between the sexes as we see here.

With respect to fcMRI, sex differences in connectivity patterns have been previously reported (e.g., Biswal et al. 2010; Tomasi and Volkow 2012; Alaerts et al. 2016; Engman et al. 2016; Weis et al. 2019), though the direction of these differences is somewhat variable across studies and samples. In addition, in studies of aging sex differences have also been reported. Tomasi and Volkow (2012) found that in females default mode network connectivity was higher than males, but it was weaker in somatosensory networks. Scheinost and colleagues (Scheinost et al. 2015) looked across multiple cortical and subcortical networks and also found age by sex interactions, though the patterns of the interaction vary across networks. While there is converging evidence to indicate that there are sex differences in functional networks, particularly in the cortex, work on cerebellar networks is relatively limited to this point, and has been focused on clinical groups that show sex differences in prevalence, such as Autism spectrum disorder (e.g., Smith et al. 2019). Thus, our findings here are novel in that they provide insights into sex differences in cerebellar dentate connectivity when looking at the whole sample, and with respect to sex differences in the relationships between connectivity in age.

Limitations

This investigation has provided important new insights into cerebellar dentate connectivity across the lifespan. However, this work is not without limitations. First, as we relied up on a publicly

available dataset, we were unable to investigate targeted behaviors of interest, and the data collection parameters were outside of our control. Regarding the former, without targeted behavioral assessments, we are unable to make any inferences as to the functional implications of these age-associations with connectivity. Further this makes it especially challenging to understand the increases in connectivity with age. We have suggested two possibilities; that is this may be a compensatory increase or indicative decreased network efficiency. Behavioral associations would provide some insight as to the role of these increases in connectivity with age. Relatedly, the imaging data was collected using a set of parameters optimized for whole-brain imaging, with a voxel size slightly larger than what we would have aimed to use in an investigation targeting the dentate nucleus. With that said, the large sample represents an important advance relative to prior work, and critically, we replicated the dissociation in dorsal and ventral seed connectivity. This suggests that we were measuring the targeted networks in question, and though not optimal, the data used here were sufficient to address our questions of interest.

Most notably, though we investigated sex differences in connectivity, we did not investigate menopause or have information about hormone levels in this sample. Menopause is associated with changes in the brain (e.g., Morrison et al. 2006; Robertson et al. 2009; Weber et al. 2013). Specifically, there is evidence to indicate that estrogen may have neuroprotective effects (Erickson et al. 2005; Boccardi et al. 2006; Robertson et al. 2009), and this includes the cerebellum. Further, we know that estrogen acts on the cerebellum (Hedges et al. 2012), and the hormonal changes of menopause may in fact be contributing to the sex differences in connectivity-age relationships seen here. Indeed, recent work looking at hormonal fluctuations during the menstrual cycle has demonstrated that over the course of the menstrual cycle, as sex steroid hormones fluctuate, increases in network coherence are related to levels of estradiol, and when progesterone rose, network coherence declines (Pritschet et al. 2020). Interestingly, when investigating the cerebellum, the dynamics were changed wherein the impacts of progesterone where larger, and those for estradiol were minimal as compared to the cortex (Fitzgerald et al. 2020). While the menstrual cycle is distinct from the hormonal changes of menopause and associated hormonal milieu, this work indicates that both cortical and cerebellar functional connectivity are sensitive to circulating sex steroid hormones. As such, further more detailed work across adulthood, taking into account reproductive status, and optimally, sex steroid hormone levels, is warranted.

Acknowledgments

Data collection and sharing for this project was provided by the Cambridge Centre for Ageing and Neuroscience (CamCAN). CamCAN funding was provided by the UK Biotechnology and Biological Sciences Research Council (grant number BB/H008217/1), together with support from the UK Medical Research Council and University of Cambridge, UK. This work was further supported by R01AG065010 to J.A.B.

References

Alaerts K, Swinnen SP, Wenderoth N. 2016. Sex differences in autism: A resting-state fMRI investigation of functional brain connectivity in males and females. Soc Cogn Affect Neurosci. 11:1002–1016.

Andrews-Hanna JR, Snyder AZ, Vincent JL, Lustig C, Head D, Raichle ME, Buckner RL. 2007. Disruption of large-scale brain systems in advanced aging. Neuron. 56:924–935.

Bernard JA, Goen JRM, Maldonado T. 2017. A case for motor network contributions to schizophrenia symptoms: Evidence from resting-state connectivity. Hum Brain Mapp. 38:4535–4545.

Bernard JA, Leopold DR, Calhoun VD, Mittal VA. 2015. Regional Cerebellar Volume and Cognitive Function From Adolescence to Late Middle Age. Hum Brain Mapp. 1120:1102–1120.

Bernard JA, Peltier SJ, Benson BL, Wiggins JL, Jaeggi SM, Buschkuehl M, Jonides J, Monk CS, Seidler RD. 2014. Dissociable functional networks of the human dentate nucleus. Cereb Cortex. 24.

Bernard JA, Peltier SJ, Wiggins JL, Jaeggi SM, Buschkuehl M, Fling BW, Kwak Y, Jonides J, Monk CS, Seidler RD. 2013. Disrupted cortico-cerebellar connectivity in older adults. Neuroimage. 83.

Bernard JA, Seidler RD. 2013. Relationships between regional cerebellar volume and sensorimotor and cognitive function in young and older adults. Cerebellum. 12.

Bernard JA, Seidler RD. 2014. Moving forward: Age effects on the cerebellum underlie cognitive and motor declines. Neurosci Biobehav Rev. 42:193–207.

Biswal BB, Mennes M, Zuo X-N, Gohel S, Kelly C, Smith SM, Beckmann CF, Adelstein JS, Buckner RL, Colcombe S, Dogonowski A-M, Ernst M, Fair D, Hampson M, Hoptman MJ, Hyde JS, Kiviniemi VJ, Kötter R, Li S-J, Lin C-P, Lowe MJ, Mackay C, Madden DJ, Madsen KH, Margulies DS, Mayberg HS, McMahon K, Monk CS, Mostofsky SH, Nagel BJ, Pekar JJ, Peltier SJ, Petersen SE, Riedl V, Rombouts S a RB, Rypma B, Schlaggar BL, Schmidt S, Seidler RD, Siegle GJ, Sorg C, Teng G-J, Veijola J, Villringer A, Walter M, Wang L, Weng X-C, Whitfield-Gabrieli S, Williamson P, Windischberger C, Zang Y-F, Zhang H-Y, Castellanos FX, Milham MP. 2010. Toward discovery science of human brain function. Proc Natl Acad Sci U S A. 107:4734–4739.

Bo J, Lee C-M, Kwak Y, Peltier SJ, Bernard JA, Buschkuehl M, Jaeggi SM, Wiggins JL, Jonides J, Monk CS, Seidler RD. 2014. Lifespan differences in cortico-striatal resting state connectivity. Brain Connect. 4.

Boccardi M, Ghidoni R, Govoni S, Testa C, Benussi L, Bonetti M, Binetti G, Frisoni GB. 2006. Effects of hormone therapy on brain morphology of healthy postmenopausal women: A Voxel-based morphometry study. Menopause. 13:584–591.

Cabeza R. 2002. Hemispheric asymmetry reduction in older adults: The HAROLD model. Psychol Aging. 17:85–100.

Cabeza R, Albert M, Belleville S, Craik FIM, Duarte A, Grady CL, Lindenberger U, Nyberg L, Park DC, Reuter-lorenz PA, Rugg MD, Steffener J. 2018. neuroscience of healthy ageing. Nat Rev Neurosci.

Cabeza R, Anderson ND, Locantore JK, McIntosh AR. 2002. Aging Gracefully: Compensatory Brain Activity in High-Performing Older Adults. Neuroimage. 17:1394–1402.

Carter CL, Resnick EM, Mallampalli M, Kalbarczyk A. 2012. Sex and Gender Differences in Alzheimer's Disease: Recommendations for Future Research. J Women's Heal. 21:1018–1023.

Diedrichsen J. 2006. A spatially unbiased atlas template of the human cerebellum. Neuroimage. 33:127–138.

Diedrichsen J, Balsters JH, Flavell J, Cussans E, Ramnani N. 2009. A probabilistic MR atlas of the human cerebellum. Neuroimage. 46:39–46.

Dum RP, Strick PL. 2003a. An Unfolded Map of the Cerebellar Dentate Nucleus and its Projections to the Cerebral Cortex. J Neurophysiol. 89:634–639.

Dum RP, Strick PL. 2003b. An unfolded map of the cerebellar dentate nucleus and its projections to the cerebral cortex. J Neurophysiol. 89:634–639.

Engman J, Linnman C, Van Dijk KRA, Milad MR. 2016. Amygdala subnuclei resting-state functional connectivity sex and estrogen differences. Psychoneuroendocrinology. 63:34–42.

Erickson KI, Colcombe SJ, Raz N, Korol DL, Scalf P, Webb A, Cohen NJ, McAuley E, Kramer AF. 2005. Selective sparing of brain tissue in postmenopausal women receiving hormone replacement therapy. Neurobiol Aging. 26:1205–1213.

Fearnley JM, Lees AJ. 1991. Ageing and Parkinson ' S Disease : Substantia Nigra Regional Selectivity. Brain, A J Neurol. 114:2283–2301.

Ferreira LK, Busatto GF. 2013. Resting-state functional connectivity in normal brain aging. Neurosci Biobehav Rev. 37:384–400.

Ferreira LK, Regina ACB, Kovacevic N, Martin MDGM, Santos PP, Carneiro CDG, Kerr DS, Amaro E, Mcintosh AR, Busatto GF. 2016. Aging effects on whole-brain functional connectivity in adults free of cognitive and psychiatric disorders. Cereb Cortex. 26:3851–3865.

Fitzgerald M, Pritschet L, Santander T, Grafton ST, Jacobs EG. 2020. Cerebellar network organization across the human menstrual cycle. Sci Rep. 10:1–11.

Gellersen HM, Guell X, Sami S. 2020. Differential vulnerability of the cerebellum in healthy ageing and Alzheimer's disease. medRxiv.

Guell X, D'Mello AM, Hubbard NA, Romeo RR, Gabrieli JDE, Whitfield-Gabrieli S, Schmahmann JD, Anteraper SA. 2020. Functional Territories of Human Dentate Nucleus. Cereb Cortex. 30:2401–2417.

Guo CC, Tan R, Hodges JR, Hu X, Sami S. 2016. Network-selective vulnerability of the human cerebellum to Alzheimer ' s disease and frontotemporal dementia. 1527–1538.

Han S, An Y, Carass A, Prince JL, Resnick SM. 2020. NeuroImage Longitudinal analysis of regional cerebellum volumes during normal aging. Neuroimage. 220:117062.

Hartholt K a, van Beeck EF, Polinder S, van der Velde N, van Lieshout EMM, Panneman MJM, van der Cammen TJM, Patka P. 2011. Societal consequences of falls in the older population: injuries, healthcare costs, and long-term reduced quality of life. J Trauma. 71:748–753.

Hausman HK, Jackson TB, Goen JRM, Bernard JA. 2020. From Synchrony to Asynchrony: Cerebellar-Basal Ganglia Functional Circuits in Young and Older Adults. Cereb Cortex. 30:718–729.

Hedges VL, Ebner TJ, Meisel RL, Mermelstein PG. 2012. The cerebellum as a target for estrogen action. Front Neuroendocrinol. 33:403–411.

Jacobs HIL, Hopkins DA, Mayrhofer HC, Bruner E, Leeuwen FW Van, Raaijmakers W, Schmahmann JD. 2018. The cerebellum in Alzheimer ' s disease : evaluating its role in cognitive decline. 37–47.

Kelly C, De Zubicaray G, Di Martino A, Copland DA, Reiss PT, Klein DF, Castellanos FX, Milham MP, McMahon K. 2009. L-dopa modulates functional connectivity in striatal cognitive and motor networks: A double-blind placebo-controlled study. J Neurosci. 29:7364–7378.

King M, Hernandez-castillo CR, Poldrack RA, Ivry RB, Diedrichsen J. 2019. Functional boundaries in the human cerebellum revealed by a multi-domain task battery. Nat Neurosci. 22:1371–1378.

Koppelmans V, Hirsiger S, Susan M, Seidler RD. 2015. Cerebellar Gray and White Matter Volume and Their Relation With Age and Manual Motor Performance in Healthy Older Adults. 2363:2352–2363.

Koppelmans V, Hoogendam YY, Hirsiger S, Mérillat S, Jäncke L, Seidler RD. 2017. Regional cerebellar volumetric correlates of manual motor and cognitive function. Brain Struct Funct. 222:1929–1944.

Lin CY, Chen CH, Tom SE, Kuo SH. 2020. Cerebellar Volume Is Associated with Cognitive Decline in Mild Cognitive Impairment: Results from ADNI. Cerebellum. 19:217–225.

MacLullich AMJ, Edmond CL, Ferguson KJ, Wardlaw JM, Starr JM, Seckl JR, Deary IJ. 2004. Size of the neocerebellar vermis is associated with cognition in healthy elderly men. Brain Cogn. 56:344–348.

McGeer PL, McGeer EG, Suzuki JS. 1977. Aging and Extrapyramidal Function. Arch Neurol. 34:33–35.

Miller TD, Ferguson KJ, Reid LM, Wardlaw JM, Starr JM, Seckl JR, Deary IJ, Maclullich AMJ. 2013. Cerebellar vermis size and cognitive ability in community-dwelling elderly men. Cerebellum. 12:68–73.

Morrison JH, Brinton RD, Schmidt PJ, Gore AC. 2006. Estrogen, Menopause, and the Aging Brain: How Basic Neuroscience Can Inform Hormone Therapy in Women. J Neurosci. 26:10332–10348.

Oguro H, Okada K, Yamaguchi S, Kobayashi S. 1998. Sex differences in morphology of the brain stem and cerebellum with normal ageing. Neuroradiology. 40:788–792.

Olivito G, Serra L, Marra C, Di Domenico C, Caltagirone C, Toniolo S, Cercignani M, Leggio M, Bozzali M. 2020. Cerebellar dentate nucleus functional connectivity with cerebral cortex in Alzheimer's disease and memory: a seed-based approach. Neurobiol Aging. 89:32–40.

Oostland M, van Hooft J. 2016. Serotonin in the cerebellum. In: Essentials of Cerebellum and Cerebellar Disorders. p. 243–247.

Oschmann M, Gawryluk JR. 2020. A Longitudinal Study of Changes in Resting-State Functional Magnetic Resonance Imaging Functional Connectivity Networks during Healthy Aging. Brain Connect. 10:377–384.

Park DC, Reuter-Lorenz P. 2009. The adaptive brain: aging and neurocognitive scaffolding. Annu Rev Psychol. 60:173–196.

Power JD, Barnes K a, Snyder AZ, Schlaggar BL, Petersen SE. 2012. Spurious but systematic correlations in functional connectivity MRI networks arise from subject motion. Neuroimage. 59:2142–2154.

Pritschet L, Santander T, Taylor CM, Layher E, Yu S, Miller MB, Grafton ST, Jacobs EG. 2020. Functional reorganization of brain networks across the human menstrual cycle. Neuroimage. 220:117091.

Raz N, Dupuis JH, Briggs SD, McGavran C, Acker JD. 1998. Differential effects of age and sex on the cerebellar hemispheres and the vermis: a prospective MR study. AJNR Am J Neuroradiol. 19:65–71.

Raz N, Ghisletta P, Rodrigue KM, Kennedy KM, Lindenberger U. 2010. Trajectories of brain aging in middle-aged and older adults: regional and individual differences. Neuroimage. 51:501–511.

Raz N, Gunning-Dixon F, Head D, Williamson a, Acker JD. 2001. Age and sex differences in the cerebellum and the ventral pons: a prospective MR study of healthy adults. AJNR Am J Neuroradiol. 22:1161–1167.

Raz N, Gunning FM, Head D, Dupuis JH, McQuain J, Briggs SD, Loken WJ, Thornton a E, Acker JD. 1997. Selective aging of the human cerebral cortex observed in vivo: differential vulnerability of the prefrontal gray matter. Cereb Cortex. 7:268–282.

Raz N, Lindenberger U, Rodrigue KM, Kennedy KM, Head D, Williamson A, Dahle C, Gerstorf D, Acker JD. 2005. Regional brain changes in aging healthy adults: general trends, individual differences and modifiers. Cereb Cortex. 15:1676–1689.

Raz N, Schmiedek F, Rodrigue KM, Kennedy KM, Lindenberger U, Lövdén M. 2013. Differential brain shrinkage over 6months shows limited association with cognitive practice. Brain Cogn. 82:171–180.

Reuter-Lorenz PA, Cappell K a. 2008. Neurocognitive Aging and the Compensation Hypothesis. Curr Dir Psychol Sci. 17:177–182.

Reuter-Lorenz PA, Stanczak L, Miller a. C. 1999. Neural Recruitment and Cognitive Aging: Two Hemispheres Are Better Than One, Especially as You Age. Psychol Sci. 10:494–500.

Reuter-Lorenz PA, Park DC. 2014. How Does it STAC Up? Revisiting the Scaffolding Theory of Aging and Cognition. Neuropsychol Rev. 24:355–370.

Robertson D, Craig M, Van Amelsvoort T, Daly E, Moore C, Simmons A, Whitehead M, Morris R, Murphy D. 2009. Effects of estrogen therapy on age-related differences in gray matter concentration. Climacteric. 12:301–309.

Scheinost D, Finn ES, Tokoglu F, Shen X, Papademetris X, Hampson M, Constable RT. 2015. Sex differences in normal age trajectories of functional brain networks. Hum Brain Mapp. 36:1524–1535.

Seidler RD, Bernard JA, Burutolu TB, Fling BW, Gordon MT, Gwin JT, Kwak Y, Lipps DB. 2010. Motor control and aging: Links to age-related brain structural, functional, and biochemical effects. Neurosci Biobehav Rev. 34.

Shafto MA, Tyler LK, Dixon M, Taylor JR, Rowe JB, Cusack R, Calder AJ, Marslen-Wilson WD, Duncan J, Dalgleish T, Henson RN, Brayne C, Bullmore E, Campbell K, Cheung T, Davis S, Geerligs L, Kievit R, McCarrey A, Price D, Samu D, Treder M, Tsvetanov K, Williams N, Bates L, Emery T, Erzinçlioglu S, Gadie A, Gerbase S, Georgieva S, Hanley C, Parkin B, Troy D, Allen J, Amery G, Amunts L, Barcroft A, Castle A, Dias C, Dowrick J, Fair M, Fisher H, Goulding A, Grewal A, Hale G, Hilton A, Johnson F, Johnston P, Kavanagh-Williamson T, Kwasniewska M, McMinn A, Norman K, Penrose J, Roby F, Rowland D, Sargeant J, Squire M, Stevens B, Stoddart A, Stone C, Thompson T, Yazlik O, Barnes D, Hillman J, Mitchell J, Villis L, Matthews FE. 2014. The Cambridge Centre for Ageing and Neuroscience (Cam-CAN) study protocol: A cross-sectional, lifespan, multidisciplinary examination of healthy cognitive ageing. BMC Neurol. 14:1–25.

Smith REW, Avery JA, Wallace GL, Kenworthy L, Gotts SJ, Martin A. 2019. Sex differences in resting-state functional connectivity of the cerebellum in autism spectrum disorder. Front Hum Neurosci. 13:1–13.

Steele CJ, Anwander A, Bazin P, Trampel R, Schaefer A, Turner R, Ramnani N, Villringer A. 2017. Human Cerebellar Sub-millimeter Diffusion Imaging Reveals the Motor and Non-motor Topography of the Dentate Nucleus. 4537–4548.

Steele CJ, Chakravarty MM. 2017. Gray-matter structural variability in the human cerebellum: Lobule-specific differences across sex and hemisphere. Neuroimage.

Steele CJ, Chakravarty MM. 2018. Gray-matter structural variability in the human cerebellum: Lobule-specific differences across sex and hemisphere. Neuroimage. 170:164–173.

Stevens J a, Sogolow ED. 2005. Gender differences for non-fatal unintentional fall related injuries among older adults. Inj Prev. 11:115–119.

Stoodley CJ, Valera EM, Schmahmann JD. 2012. Functional topography of the cerebellum for motor and cognitive tasks: An fMRI study. Neuroimage. 59:1560–1570.

Strick PL, Dum RP, Fiez JA. 2009. Cerebellum and Nonmotor Function. Annu Rev Neurosci. 32:413–434.

Tabatabaei-Jafari H, Walsh E, Shaw ME, Cherbuin N. 2017. The cerebellum shrinks faster than normal ageing in Alzheimer's disease but not in mild cognitive impairment. Hum Brain Mapp. 00.

Taylor JR, Williams N, Cusack R, Auer T, Shafto MA, Dixon M, Tyler LK, Cam-CAN, Henson RN. 2017. The Cambridge Centre for Ageing and Neuroscience (Cam-CAN) data repository: Structural and functional MRI, MEG, and cognitive data from a cross-sectional adult lifespan

sample. Neuroimage. 144:262–269.
Tiemeier H, Lenroot RK, Greenstein DK, Tran L, Pierson R, Giedd JN. 2010. Cerebellum development during childhood and adolescence: A longitudinal morphometric MRI study. Neuroimage. 49:63–70.
Tomasi D, Volkow ND. 2012. Aging and functional brain networks. Mol Psychiatry. 17:549–558.
Toniolo S, Serra L, Olivito G, Marra C, Bozzali M. 2018. Patterns of Cerebellar Gray Matter Atrophy Across Alzheimer ' s Disease Progression. 12:1–8.
Van Dijk KR a, Sabuncu MR, Buckner RL. 2012. The influence of head motion on intrinsic functional connectivity MRI. Neuroimage. 59:431–438.
Weber MT, Rubin LH, Maki PM. 2013. Cognition in perimenopause: the effect of transition stage. Menopause. 20:511–517.
Weis S, Hodgetts S, Hausmann M. 2019. Sex differences and menstrual cycle effects in cognitive and sensory resting state networks. Brain Cogn. 131:66–73.
Whitfield-Gabrieli S, Nieto Castañón A. 2012. Conn: a functional connectivity toolbox for correlated and anticorrelated brain networks. Brain Connect. 2:125–141.
Zheng W, Liu X, Song H, Li K, Wang Z. 2017. Altered functional connectivity of cognitive-related cerebellar subregions in alzheimer's disease. Front Aging Neurosci. 9:1–9.

Tables

Table 1. Dentate Connectivity Across the Adult Lifespan. Positive and negative correlations with age for both the dorsal and ventral dentate nucleus seeds. Anatomical locations were determined using Harvard-Oxford max probability atlas. Cerebellar locations were determined using the SUIT atlas.

Region	Cluster Size	MNI Coordinates			$P_{(FDR)}$
		X	Y	Z	
DORSAL SEED					
Negative Correlations					
Thalamus	6298	-8	-20	14	0.00
Inferior Frontal Gyrus, pars opercularis	841	-56	20	20	0.00
Precentral Gyrus	634	56	10	32	0.00
Middle Frontal Gyrus	611	-26	16	54	0.00
Heschl's Gyrus	524	46	-10	4	0.00
Submarginal Gyrus	488	-52	-28	38	0.00
Precentral Gyrus	149	34	-8	58	.0008
Postcentral Gyrus	137	34	-38	42	.001
Brainstem	119	10	-20	-12	.002
Lingual Gyrus	101	2	-50	0	.005
Positive Correlations					
Lobules I-IV	1373	8	-50	-22	0.00
Occipital Pole	624	18	-94	-16	0.00
Inferior Temporal Gyrus	342	48	-30	-18	0.00
Frontal Pole	251	22	36	-4	0.00s
Frontal Pole	216	-36	-86	-14	.00002
Temporal Fusiform Cortex	204	-18	32	-8	.0001
Temporal Occipital Fusiform Cortex	152	-44	-48	-20	.0007
Inferior Temporal Gyrus	91	-50	-32	-16	.01
VENTRAL SEED					
Negative Correlations					
Temporal Fusiform Cortex	1075	-38	-2	-46	0.00
Inferior Temporal Gyrus	961	48	-16	-34	0.00
Lobule VIIb	805	30	-72	-58	0.00
Supramarginal Gyrus	682	-50	-28	32	0.00
Lobule VIIb	553	-12	-76	-56	0.00
Middle Frontal Gyrus	398	-28	-2	46	0.00
Frontal Pole	256	48	36	36	.00002
Thalamus	232	-2	2	-4	.00004
Putamen	204	-22	22	0	.0001

Posterior Cingulate Gyrus	142	-8	-36	34	.001
Caudate	140	-8	8	16	.001
Precentral Gyrus	128	14	-30	44	.002
Frontal Orbital Cortex	128	22	30	-28	.002
Putamen	113	18	6	-6	.003
Postcentral Gyrus	995	34	-30	38	.007
Frontal Pole	75	-28	42	44	.020
Angular Gyrus	71	34	-54	36	.023
Precuneus	70	-4	-50	54	.023
Temporal Pole	61	-38	14	-30	.037
Frontal Pole	57	-16	66	24	.044
Positive Correlations					
Vermis VI	2229	2	-60	-26	0.00
Posterior Cingulate Gyrus	424	2	-34	6	0.00
Caudate	268	18	30	0	.00001
Intracalcarine Cortex	174	28	-70	6	.0003
Temporal Occipital Fusiform Cortex	159	40	-36	-10	.0006
Temporal Occipital Fusiform Cortex	142	-32	-50	0	.001
Precuneus	98	-22	-48	22	.006
White Matter	95	-22	24	18	.006
Caudate/White Matter	94	22	2	28	.006
Lobule V	61	-20	-44	-26	.031

Table 2. Dorsal and Ventral Dentate Connectivity associations with Age in Females. Positive and negative correlations with age for both the dorsal and ventral dentate nucleus seeds. Anatomical locations were determined using Harvard-Oxford max probability atlas. Cerebellar locations were determined using the SUIT atlas.

Region	Cluster Size	MNI Coordinates			$P_{(FDR)}$
		X	Y	Z	
DORSAL SEED					
Negative Correlations					
Thalamus	3853	-8	-18	14	.0000
Superior Frontal Gyrus	739	-22	10	54	.0000
Superior Frontal Gyrus	731	28	4	60	.0000
Insular Cortex	696	-30	-10	-6	.0000
Middle Frontal Gyrus	546	-46	12	32	.0000
Brainstem	163	4	-18	-12	.0004
Insular Cortex/Putamen	95	28	-18	-2	.009
Middle Frontal Gyrus	76	28	22	52	.023
Supramarginal Gyrus (Superior)	68	-52	-36	44	.032
Anterior Cingulate Cortex	63	0	38	16	.035
Anterior Cingulate Cortex	63	4	-36	-4	.035
Anterior Cingulate Cortex	59	14	28	22	.041
Positive Correlations					
Subcallosal Cortex	490	-8	20	0	.0000
Middle Temporal Gyrus (Posterior)	404	-42	-28	-10	.0000
Inferior Temporal Gyrus (Posterior)	196	46	-26	-20	.0002
Postcentral Gyrus	156	48	-24	66	.0008
Vermis Crus II	152	0	-70	-34	.0008
Lobule V	121	20	-42	-28	.002
Lobule V	120	-14	-44	-26	.002
Frontal Pole	74	12	50	-22	.02
Inferior Temporal Gyrus (Posterior)	62	48	-12	-32	.04
VENTRAL SEED					
Negative Correlations					
Caudate	294	-8	8	16	.00002
Anterior Cingulate Cortex	236	-2	6	44	.00007

Supramarginal Gyrus (Anterior)	233	-44	-36	40	.00007
Superior Frontal Gyrus	212	-24	-2	50	.0001
Caudate	185	8	12	10	.0003
Parahippocamapal Gyrus (Anterior)	76	-18	-14	-42	.03
Temporal Fusiform Cortex (Posterior)	74	-38	-10	-34	.03
Positive Correlations					
Vermis VIIIa	1041	-6	-66	-38	
Caudate	148	18	30	0	
Intracalcarine Cortex	118	30	-68	6	
Caudate/White Matter	114	22	2	28	
Precuneus	114	20	-42	20	
Posterior Cingulate Gyrus	86	-2	-34	8	
Temporal Fusiform Cortex (posterior)	75	-40	-34	-8	
Precuneus	72	-20	-40	28	
Lobule VI	57	-20	-64	-32	
Parahippocampal Gyrus (anterior)	53	20	-14	-30	

Table 3. Dorsal and Ventral Dentate Connectivity associations with Age in males. Positive and negative correlations with age for both the dorsal and ventral dentate nucleus seeds. Anatomical locations were determined using Harvard-Oxford max probability atlas. Cerebellar locations were determined using the SUIT atlas.

Region	Cluster Size	MNI Coordinates			$P_{(FDR)}$
		X	Y	Z	
DORSAL SEED					
Negative Correlations					
Posterior Cingulate Gyrus*	1123	14	-18	30	.0000
Supramarginal Gyrus (anterior)	138	-38	-30	34	.004
Precentral Gyrus	120	62	6	36	.007
Inferior Frontal Gyrus (pars opercularis)	101	-56	18	20	.01
Central Opercular Cortex	87	-32	-12	20	.02
Central Opercular Cortex	79	40	-6	16	.03
Suparmarginal Gyrus (posterior)	74	44	-38	44	.03
Planum Temporale	69	32	-32	10	.04
Positive Correlations					
Occipital Pole	514	4	-100	-2	.0000
Vermis VIIIa	365	-4	-62	-32	.0000
Dentate Nucleus/White Matter	167	26	-56	-44	.0005
Lateral Occipital Cortex (inferior division)	96	-48	-80	-16	.01
VENTRAL SEED					
Negative Correlations					
Lobule VIIb	701	30	-72	-56	.0000
Inferior Temporal Gyrus (posterior)	454	44	-10	-42	.0000
Crus II	397	-8	-84	-48	.0000
Inferior Temporal Gyrus (posterior)	187	-54	-12	-40	.0003
Postcentral Gyrus	119	-26	-38	46	.005
Superior Frontal Gyrus	103	-22	-8	42	.008
Superior Temporal Gyrus (posterior)	86	-46	-24	-6	.01
Crus I	86	-52	-64	-40	.01

Temporal Fusiform Cortex (posterior)	85	-34	-16	-32	.01
Posterior Cingulate Gyrus	79	-8	-36	34	.02
Frontal Orbital Cortex	66	-14	34	-24	.03
Positive Correlations					
Lobule IX	443	14	-54	-40	.0000
Posterior Cingulate Gyrus	91	4	-36	8	.01

Table 4. Sex Differences in Dentate Connectivity. Anatomical locations were determined using Harvard-Oxford max probability atlas. Cerebellar locations were determined using the SUIT atlas.

Region	Cluster Size	MNI Coordinates			$P_{(FDR)}$
		X	Y	Z	
DORSAL SEED					
Males>Females					
Lingual Gyrus	2474	22	-56	-18	.0000
Lobule IX	267	12	-54	-40	.0000
Females>Males					
Supramarginal Gyrus (posterior)	220	-36	-50	20	.0003
Angular Gyrus	129	42	-54	22	.006
Inferior Temporal Gyrus (posterior)	81	60	-22	-34	.04
VENTRAL SEED					
Males>Females					
Lobule V	340	2	-64	-20	.00005
Females>Males					
n/a					

Figure Captions

Figure 1. Dorsal and ventral dentate seeds locations. These seeds parallel those used by Bernard and colleagues (2014) and were chosen to be non-overlapping as pictured here.

Figure 2. Functional connectivity patterns for the dorsal (yellow/orange) and ventral (blue/purple/pink) dentate seeds. The patterns of connectivity for the two seeds parallel the dissociation seen in non-human primates and in human work, even when using traditional whole-brain processing and analysis approaches.

Figure 3. Associations between connectivity and age for the dorsal (top) and ventral (bottom) dentate seeds. While there are some positive associations reported (see Table 1), the views here primarily demonstrate negative associations between connectivity strength and age (purple), though some small regions of positive correlation (yellow/orange) with the dorsal dentate seen are visible in the temporal lobe.

Figure 4. Correlations between the dorsal (left) and ventral (right) regions of the dentate nucleus with age in females (top) and males (bottom). Notably, the negative correlations are more extensive in females, particularly for the dorsal dentate seed.