Co-infection of *Candidatus* Piscichlamydia trichopodus (order Chlamydiales) and *Henneguya* sp (Myxosporea, Myxobolidae) in snakeskin gourami *Trichopodus pectoralis* (Regan 1910)

Nguyen Dinh-Hung[1,2], Ha Thanh Dong[3], Chayanit Soontara[4], Channarong Rodkhum[1,2], Sukkrit Nimitkul[4], Prapansak Srisapoome[4,5], Satid Chatchaiphan[4*], Pattanapon Kayansamruaj[4,5*]

[1]The International Graduate Program of Veterinary Science and Technology (VST), Faculty of Veterinary Science, Chulalongkorn University, Bangkok, Thailand

[2]Center of Excellent in Fish Infectious Diseases (CE FID), Department of Veterinary Microbiology, Faculty of Veterinary Science, Chulalongkorn University, Bangkok, Thailand

[3]Department of Food, Agriculture and Bioresources, Aquaculture and Aquatic Resources Management Program, Asian Institute of Technology (AIT), School of Environment, Klong Luang, Pathumthani, Thailand

[4]Department of Aquaculture, Faculty of Fisheries, Kasetsart University, Bangkok, Thailand

[5]Center of Excellence in Aquatic Animal Health Management, Faculty of Fisheries, Kasetsart University, Bangkok, Thailand

***Correspondence:**

Corresponding Authors

P Kayansamruaj and S Chatchaiphan, satid.ch@ku.th

Running head: *Chlamydia*-like organism and *Henneguya* sp. in snakeskin gourami

Keywords: *Chlamydiales*, *Chlamydia*-like organism, *Henneguya* sp., snakeskin gourami, *Candidatus* Piscichlamydia trichopodus, 16S rRNA.

DATA AVAILABILITY STATEMENT

The data that support the findings of this study are available on request.

CONFLICT OF INTEREST

The authors declare that the research was conducted in the absence of any commercial or financial relationships that could be construed as a potential conflict of interest.

ETHICS STATEMENT

The animal study was reviewed and approved by the Institutional Animal Care and Use Committee of Kasetsart University (Approval ID: ACKU63-FIS-009).

AUTHOR CONTRIBUTIONS

PK and HTD involved in conceptualization. ND-H, CS, SN and PK underwent investigation. SN resources, ND-H, HTD, and PK performed formal analysis and wrote the original draft. ND-H, HTD, CS, CR, SN, PS, SC and PK reviewed and edited. All authors have read and agreed to the current version of the manuscript. Dr. Pattanapon Kayansamruaj, one of the lead authors, was deceased prior to the submission of this manuscript.

ACKNOWLEDGEMENTS

The work was carried out with support from the Center of Excellence in Aquatic Animal Health Management, Faculty of Fisheries, Kasetsart University.

Abstract

The present study describes a simultaneous infection of a novel *Chlamydia*-like organism (CLO) with a Myxozoa parasite, *Henneguya* sp. in snakeskin gourami *Trichopodus pectoralis* in Thailand. A new CLO is proposed "*Candidatus* Piscichlamydia trichopodus" (CPT) based on 16S rRNA phylogenetic analysis. Systemic intracellular CPT infection was confirmed by histological examination, *in situ* hybridization, PCR assay, and sequencing of 16S rRNA. This novel pathogen belongs to the order *Chlamydiales* but differs in certain aspects from other species. The histopathological changes associated with CPT infection were different from the typical pathological lesions of epitheliocystis caused by previously known CLO. Unlike other CLO, CPT localized in the connective tissue rather than in the epithelial cells and formed smaller clumps of intracellular bacteria that stained dark blue with hematoxylin. On the other hand, typical myxospores of the genus *Henneguya* with tails were observed in the gill sections. Infection with *Henneguya* sp. resulted in extensive destruction of the gill filaments, most likely leading to respiratory distress. Due to the frequency of co-infections and the unavailability of culture methods for CLO and *Henneguya* sp, it was difficult to determine which pathogens were directly responsible for the associated mortality. However, co-infections may increase the negative impact on the host and the severity of the disease. Given the commercial importance of the snakeskin gourami and its significant aquaculture potential, the findings of this study are important for further studies on disease prevention.

61 **1. Introduction**

62 Snakeskin gourami, *Trichopodus pectoralis,* is native to Southeast Asia and commonly found
63 in the Mekong and Chao Phraya basins of Cambodia, Thailand, Southern Vietnam, and Laos
64 [1]. In Thailand, the snakeskin gourami is a highly economic species and has become one of
65 the five most important freshwater species in aquaculture [2, 3]. Increased incidence of
66 parasitic and bacterial diseases is one of the major obstacles to the farming of this species [4].
67 However, studies on the occurrence of diseases in *T. pectoralis* are still very scarce [5]. The
68 pathogen fauna of this species is poorly understood and may contain pathogens that have not
69 yet been described in the literature.

70 Myxosporeans are diverse and widespread parasites that cause severe economic damage to fish
71 worldwide [6-8]. The genus *Henneguya* includes more than 200 species and is one of the most
72 diverse myxosporean genera in the family *Myxobolidae* [8]. Some species of the genus
73 *Henneguya* are responsible for diseases leading to high mortality rates, but most species are
74 thought to have little or no negative impact on fish health [6, 9]. Infection from *Henneguya* sp.
75 usually occurs in the gills and is characterized by the presence of cyst-like structures on the gill
76 filaments [6, 7, 10]. Infection can devastate fish populations when the parasites multiply in
77 high densities on the gills and leads to respiratory failure, especially in juvenile fish [11, 12].
78 Other commonly known pathogens that cause gill cysts in fish are bacteria from the order
79 *Chlamydiales*. These bacteria typically cause epithelial cysts in the skin and gills called
80 epitheliocystis [13-15]. However, it is noteworthy that different *Chlamydia*-like organisms
81 (CLOs) have been found to have different pathology upon infection, possibly depending on the
82 chlamydial species, the infected host, and the affected tissue [16]. To date, unavailability of
83 culture techniques for chlamydial pathogens has been a major obstacle for *in vitro* studies [13,
84 16].

85 In the present study, we described for the first time a systemic pathology caused by a novel
86 *Chlamydia*-like organism, *Candidatus* Piscichlamydia trichopodus (order *Chlamydiales*) and a
87 gill parasite *Henneguya* sp. (Myxosporea, Myxobolidae) infecting the same fish population.
88 Pathogen characterization was performedbased on molecular analyses with detailed
89 histopathological observations and confirmation by *in situ* hybridization (ISH).

2. Materials and methods

2.1. Fish and case history

In March 2021, higher than average mortality was observed in snakeskin gourami fingerlings in two nursery ponds in central Thailand. History entails that snakeskin gourami fingerlings (0.3g ± 0.05) reared by traditional methods [17] were purchased from a hatchery. Male and female broodstock were naturally mated in an earthen pond. Eggs were spawned in natural bubble nests made by male gourami in the same pond. Offspring were harvested at the size of 3.0 cm (weight 0.2-0.3 g) and 150,000 fish were delivered to the two ponds mentioned above. The fish were kept in a 5 m^2 net in the pond and fed daily with a commercial pellet diet containing 28% protein (Betagro, Thailand), administered at a rate of 3% of body weight. Mortality was recorded on the second day after the fry were introduced. Daily mortality recorded from 1 to 5 days after onset of disease (dao) were 20, 50, 150, 200, and 400 fish, respectively. Affected fish showed lethargy, gasping at the water surface and loss of appetite followed by mortality. At 3 dao, sea salt was added daily to the pond (total 200 kg), but no reduction in mortality was observed. Subsequently, oxytetracycline (OTC) (200 mg/g active ingredient, Pharmatech, Thailand) was continuously administered to the fish via feed admixture (5g OTC per 1 kg of feed) for 7 days.

2.2. Gross necropsy and histopathology

Representative 10 fingerlings were collected at 6 dao for further examination approved by the Institutional Animal Care and Use Committee of Kasetsart University (Approval ID: ACKU63-FIS-009). After euthanasia with clove oil (150ppm/l), fresh skin mucus and gill samples were collected for microscopic examination. Bacteriological examination of brain, liver and kidney tissue samples was performed by streaking on tryptic soy agar and brain-heart infusion agar (BHIA) (Himedia, India) and incubation at 28°C for 48 hours. Samples from whole body fish (n=5) and detached gills (n=10) were fixed in 10% neutral buffered formalin

115 and processed routinely for histology. Paraffin-embedded gills were sectioned at 5 µm, stained
116 with haematoxylin and eosin and examined under a light microscope.

117 **2.3. DNA extraction, 16S rRNA amplification and sequencing**

118 Genomic DNA was isolated from infected gills using the Tissue Genomic DNA Mini kit
119 (Geneaid, Taiwan) according to the manufacturer's instructions. The presence of chlamydial
120 DNA was first examined using primers 16SIGF (5'-CGGCGTGGATGAGGCAT-3') and
121 16SIGR (5'-TCAGTCCCAGTGTTGGC-3') described in the previous study [18]. All positive
122 samples were subjected to further PCR with *Chlamydiales*-specific primers 16SIGF (5'-
123 CGGCGTGGATGAGGCAT-3') and 806R (5'-GGAC TACCAGGGTATCTAAT-3')
124 according to Relman [19]. PCR amplification reaction and cycling conditions for these assays
125 were as previously described by Sood et al [20] and Draghi et al [21]. The expected amplicons
126 of the first and second PCR methods were 300 bp and 766 bp, respectively. Amplified PCR
127 products (766 bp) from each fish were isolated using NucleoSpin™ Gel PCR Clean-up Kit
128 (Fisher Scientific, Sweden) according to the manufacturer's protocol and then submitted for
129 sequencing service (U2Bio, Thailand).

130 **2.4. Phylogenetic analyses.**

131 A BLASTn query against available nucleotide sequences was deposited in the GenBank
132 database (www.ncbi.nlm.nih.gov) to determine taxonomic identity. The closest known
133 relatives and several sequences from related species of *Chlamydia*-like organisms were
134 obtained from the NCBI database and used for phylogenetic analysis. The phylogenetic tree
135 was constructed using the neighbour-joining method with 1,000 bootstraps after multiple
136 alignments against the closely related *Chlamydia* bacteria using ClustalW in MEGA X version
137 10.2.4 [22]. To root the tree, sequences from a Betaproteobacterium, *Candidatus*
138 Branchiomonas cysticola (Accession number JQ723599.1), were used as outgroup.

139 **2.5. *In situ* hybridization**

140 To confirm localization of CPT in the infected tissues, *in situ* hybridization (ISH) with a CLO-
141 specific probe was performed on tissues from five representative diseased fish. A 766 bp probe
142 was produced firstly by PCR using DNA extracted from infected fish as DNA template and the
143 primers 16SIGF and 806R [19]. The product was labelled with digoxigenin (DIG) using a
144 commercial PCR DIG labelling mixture (Roche Molecular Biochemicals, Germany) according
145 to the manufacturer's instructions. *In situ* hybridization was performed as previously described
146 by Dinh-Hung et al [23] with some modifications. Briefly, unstained 4-µm sections on
147 HistoGrip-coated slides (Fisher Scientific, Sweden) were deparaffinized 2 times for 5 minutes
148 in xylene and then rehydrated through a graded series of ethanol and distilled water. After rapid
149 treatment with cold acetic acid for 20 seconds and washing in distilled water, each section was
150 covered with prehybridization buffer (4× SSC contain 50% [v/v] deionized formamide) for at
151 least 10 minutes at 37°C. The probe was diluted in hybridization buffer (50% deionized
152 formamide, 50% dextran sulphate, 50× Denhardt's solution [Sigma-Aldrich, Germany], 20×
153 SSC, 10 mg per ml salmon sperm DNA [Invitrogen, USA]), heated to 95°C for 10 minutes,
154 and then cooled on ice. The specific probe was added to the slides, then covered with coverslips
155 and incubated overnight at 42°C in a humidity chamber. For control slides, no probe was added
156 to the hybridization solution. After hybridization, slides were washed in a series of graded
157 sodium citrate solutions for 5 minutes in 2× SSC at room temperature (RT), 15 minutes in 2×
158 SSC (37°C), 15 minutes in 1× SSC (37°C), 30 minutes in 0.5× SSC (37°C), and then
159 equilibrated for 5 minutes in buffer I (1 M Tris-HCl, 1.5 M NaCl, pH 7.5). The tissue sections
160 were then blocked with blocking solution buffer II (containing 0.1% Triton X-100 and 2%
161 normal sheep serum) at room temperature for 30 minutes before being covered with anti-
162 digoxigenin, Fab fragments (Roche Molecular Biochemicals, Germany, diluted 1:500 in buffer
163 II) for 1 hour at 45°C. After washing twice for 10 minutes each with buffer I, sections were
164 treated for 10 minutes in buffer III (100 mM Tris-HCl, 1.5 M NaCl, 50 mM $MgCl_2$, pH 9.5).

165 Signals were developed using the BCIP/NBT substrate, followed by counterstaining with
166 nuclear fast red. The slides were then mounted, observed and photographed under a digital
167 microscope.

168 **3. Results**

169 **3.1. Initial diagnosis**

170 Disease diagnosis carried out in the field on 6 dao showed no external lesions on the body
171 surface of the fish **(Figure 1A)**. Wet-mount examination of the skin mucus and gills showed
172 no external parasites, although the formation of several characteristic cysts in the gill filaments
173 was prevalent **(Figure 1B)**. The infected fish exhibited lethargy, fish gasping at the water
174 surface, and loss of appetite followed by mortality. This observation initially led us to a
175 preliminary misdiagnosis as an "epitheliocystis" case. After treatment with OTC, there was a
176 significant decrease in daily mortality of 150, 50 and 16 fish at 7, 8 and 9 dao, respectively. No
177 mortality (0 dead fish) was observed after treatment with OTC for 4 days (10 dao).

178 **3.2. Histopathology and *in situ* hybridization**

179 Histological examination revealed colonization by intracellular bacteria in several organs,
180 including the gill filaments **(Figure 2A.1)**, submucosa of the intestine **(Figure 2B.1)**, and
181 caudal fin tissue **(Figure 2C.1)**. Dense, roundish to oval intracellular bacteria with a great
182 affinity for connective tissue rather than epithelial cells were observed **(Figure 2A.2, B.2, and**
183 **C.2)**. Apparently, the bacteria infected the primary gill filaments rather than the secondary gill
184 filaments. In particular, the cartilaginous junctions between primary and secondary gill
185 filaments were apparently more susceptible to infection than others, resulting in the separation
186 of the two components **(Figure 2A.2)**. Similar changes were also observed at the cartilaginous
187 junction of the caudal fin (data not shown). With respect to ISH, the DIG-labeled probe was
188 specifically bound to intracellular bacterial foci **(Figure 2A.3, B.3, and C.3)**, whereas no
189 binding signal was observed in tissue sections incubated with no probe **(Figure 2A.4, B.4, and**
190 **C.4)**. Furthermore, no culturable bacteria were isolated from the internal organs on nutrient
191 agar plates as well as on brain-heart infusion agar plates even after 48 hours of incubation.

192 Interestingly, histological analysis showed that the "cysts" found in the infected fish were not
193 epitheliocystis, as tentatively diagnosed and later identified as plasmodia of a myxosporean.
194 The presence of numerous plasmodia was observed on the gill filaments **(Figure 3A)**.
195 Myxospores and plasmodia demonstrated asynchronous development with young round
196 plasmodia encased in a wall of epithelial cells of the gill filaments **(Figure 3B)**. As the
197 plasmodium grew, the envelope ruptured and released myxospores into the adjacent tissue
198 **(Figure 3C)**. The myxospores exhibited typical features of the genus *Henneguya*: two equal
199 polar caps, sporoplasm at the posterior pole of the spore, and two long, superimposed caudal
200 processes **(Figure 3D)**. Histological analysis of the infected gills of *Henneguya* showed that
201 the plasmodia caused severe distortion of the lamellar structure and obstruction of the gills by
202 compression of the cysts **(Figure 4A, B, and C)**. The plasmodia occupied the part extent of
203 the gill lamellae and produced marked dilatation and discrete epithelial hyperplasia **(Figure**
204 **4D and E)**. The extensive dilatation of the infected lamellae caused displacement and
205 deformation of the adjacent lamellae. As the plasmodia grew, they compressed the adjacent
206 tissue and caused tissue necrosis in the infected area **(Figure 4E and F)**.

207 **3.3. Molecular analyses**

208 All collected samples (n=4) were positive after repeated PCR amplification of the 16S rRNA
209 gene of *Chlamydiales* **(Figure S1)**. Multiple sequence alignment of the partial 16S rRNA gene
210 sequence of the *T. pectoralis* chlamydial pathogen from 4 representative infected fish, showed
211 that the sequences were identical, and the consensus sequence (766bp) was deposited in
212 GenBank under accession number MW832782. BLAST-n search of consensus sequence in the
213 NCBI database revealed closest sequence similarity (93.5%) with the partial 16S rRNA gene
214 of a non-cultured bacterium (Accession number LN612734.1) obtained from a case of gill
215 disease in Mediterranean Sea bream, followed by *Candidatus* Piscichlamydia sp. (92.3%)
216 (Accession number KY380090.1), which is associated with epitheliocystis infections in

217 cyprinids. These bacteria formed a clade as an unclassified family belonging to the genus
218 *Candidatus* Piscichlamydia within the order *Chlamydiales*. The accession numbers and
219 taxonomic identities, as well as the origin of the organisms included in this phylogenetic
220 analysis, are shown in **Figure 5**. This phylogenetic analysis confirmed that the bacterial
221 pathogen in the case of the snakeskin gourami separated in a unique branch, representing a
222 novel species, proposed name "*Candidatus* Piscichlamydia trichopodus", a new member of the
223 order *Chlamydiales*.

224 **4. Discussion**

225 Members of the order *Chlamydiales* are a diverse group of Gram-negative, obligate
226 intracellular bacteria that are distributed worldwide and cause a wide variety of diseases in
227 humans, livestock, domestic animals, wildlife, and exotic species [16, 24, 25]. *Chlamydia*-like
228 organisms (CLOs), commonly found in aquatic environments, have been identified as causing
229 disease in at least 90 fish species in both freshwater and marine environments [14-16]. A
230 common feature of these bacteria is the infection of epithelial cells of fish, causing typical
231 lesions in the form of epitheliocystis [13-16, 26, 27]. Epitheliocystis as a result of CLOs
232 infection have been described in several farmed fishes, including common carp *Cyprinus*
233 *carpio* [28], red seabream *Pagrus major* [13], African catfish *Clarias gariepinus* [29],
234 yellowtail kingfish *Seriola lalandi* [30], striped trumpeter *Latris lineata* [31] barramundi *Lates*
235 *calcarifer* [32], striped catfish *Pangasius hypophthalmus* [33], and rohu *Labeo rohita* [20]. In
236 contrast to previous studies, our result showed that the histopathological changes associated
237 with CPT infection revealed massive intracellular colonization but not obvious as
238 epitheliocystis. Interestingly, the microbial pathogen in this study likely shares similarities with
239 the CLO pathogen that causes systemic microbial disease in the Dungeness crab, *Cancer*
240 *magister* [34]. Both pathogens show systemic infection with numerous colonies of the
241 organism having strong affinity for connective tissue and connective tissue cells, while rarely
242 infecting epithelial cells. Several previous studies reported that CLOs can infect other cell
243 types, including mucous cells in common carp *Cyprinus carpio L.* [35], pillar cells in tiger
244 puffer *Takifugu rubripes* [36], macrophages in brown bullhead *Ictalurus nebulosus* [37] and
245 chloride cells in Atlantic salmon *Salmo salar* [38]. These studies have also indicated that
246 epitheliocystis due to CLO is typical but not always observed. Moreover, the localization of
247 CPT near the damaged cartilaginous tissue suggests that these bacteria may require cartilage
248 for their metabolism. This histopathological feature could be considered in the presumptive

249 diagnosis of this new pathogen. It is increasingly recognized that these pathogens are actually
250 diverse in their morphology, e.g., the morphology of CLO organisms in the epithelial cysts and
251 their staining characteristics, as well as the morphology of their capsules and their location in
252 fish tissue [39-41]. This is the first detection of CLO in snakeskin gourami and may represent
253 another *Chlamydia* that is not associated with epitheliocystis. Since CLO pathogens cannot be
254 distinguished by morphology or conventional culture methods, molecular methods are widely
255 used to detect and characterize the causative pathogen. Apart from histopathological lesion of
256 the bacterial foci, CLO infection was confirmed by ISH and specific PCR assay. Although the
257 short 16S rRNA signature sequence detected in infected tissue is not ideal for detailed
258 phylogenetic analysis, it is unique. Our sequence showed only a distant similarity of 93.5%
259 and 92.3%, respectively, with a query coverage of 98% to the uncultured bacterium from
260 gilthead sea and *Candidatus* Piscichlamydia sp. associated with epitheliocystis infections in
261 cyprinids [27]. There bacteria formed a clade as an unclassified family belonging to the genus
262 *Candidatus* Piscichlamydia within the order *Chlamydiales* and also shared >90% sequence
263 similarity with other members of the family *Candidatus* Piscichlamydiaceae, suggesting that
264 these pathogens belong to the same family [18] or are closely related. Since the causative agent
265 shared < 95% similarity with other previously reported *Chlamydia*-like 16S rRNA sequences,
266 the sequenced bacteria are new to the order *Chlamydiales* [18]. These results highlight the wide
267 genetic diversity within this bacterial group and are consistent with previous findings [26] that
268 each new fish host indicates the existence of a phylogenetically distinct and novel *Chlamydia*
269 infection.
270 In the present case, the diagnosis was challenging due to mixed infection of CPT along with a
271 *Henneguya* sp parasite in the affected gill tissues. Myxospore taxonomy is based primarily on
272 morphology and spore structure, therefore, the myxosporids found in this study can be
273 morphologically classified into the genus *Henneguya* based on certain morphological criteria.

274 *Henneguya* sp. has the characteristic morphological feature of two equal polar caps,
275 sporoplasm at the posterior pole and 2 independent caudal processes, which distinguishes it
276 from the other genus of the family *Myxobolidae* [7, 42, 43]. The species of the genus
277 *Henneguya* interact with the gill structures of fish in different manners, resulting in varying
278 degrees of disease [9, 10, 44]. The clinical signs noted by the farmer in the snakeskin gourami,
279 particularly lethargy, gasping for oxygen at the water surface, and loss of appetite, are
280 comparable with those previously documented in fish affected by *Henneguya* sp. [45-47]. The
281 most common histological lesions found in this case were distortion of the lamellar structure
282 and obstructions of the gills due to compression of the cysts, which most likely caused
283 respiratory distress and contributed to the observed mortality. Histopathological features
284 similar to those described in this study have been observed in previous studies [48-50], in which
285 parasitism by *Henneguya* sp. resulted in marked dilatation and discrete epithelial hyperplasia,
286 and continued growth of the parasitic cyst resulted in tissue necrosis in the surrounding infected
287 area. The observation of areas of cystic lesions associated with tissue necrosis caused by the
288 compression of cysts in the epithelial cells of the gill lamellae in this study has also been
289 reported in previous studies [51]. The growth of *Henneguya* plasmodia results in a
290 displacement and distortion of the lamellar structures, possibly adversely affecting gas
291 exchange and associated with mortality in the fish population
292 Unfortunately, due to the occurrence of co-infections and the unavailability of culture methods
293 for fish CLOs, it was not possible to determine which pathogens were directly responsible for
294 the associated mortality. Interestingly, the disease is sensitive to tetracyclines, since the
295 antibiotic treatment with oxytetracycline in the field was effective, hence we assumed that the
296 disease might have been caused primarily by the CLO. As previously reported by Goodwin et
297 al. [52], OTC significantly reduced mortality due to chlamydial infection and supported this
298 treatment regimen for future outbreaks. The cause and pathogenesis of this dual infection

remain speculative and await the development of a culture technique and isolation of the *Chlamydia*-like organism before further *in vitro* studies. It is unclear whether *Henneguya* sp. and CPT has the potential of causing a significant impact on snakeskin gourami aquaculture. Given the commercial importance of the snakeskin gourami *Trichopodus pectoralis* and its great aquaculture potential, the results of this study highlight the need of follow up investigations on ultrastructural morphology, host range, prevalence, risk factors for disease, and mode of transmission. This could lead to a better understanding of the pathogen's biology and disease epidemiology for development of effective control measures.

In conclusion, the presence of pathogenic potential of mixed infection of a novel intracellular CLO (*Candidatus* Piscichlamydia trichopodus) and a gill parasite *Henneguya* sp. in snakeskin gourami in Thailand is reported for the first time. This study expands the knowledge of the pathology of snakeskin gourami, an important fish species in Asian aquaculture, and contributes to initial understanding of diseases in this fish species.

REFERENCE

1. Paepke H. The Nomenclature of *Trichopodus pectoralis* Regan, 1910*; Trichopus cantoris* Sauvage*,* 1884 *and Osphronemus saigonensis* Borodin*,* 1930 *(*Teleostei: Peciformes*: Osphronemidae)*. *Vertebr Zool.* (2009) 59:49–56.
2. FAO. Fishery and Aquaculture Statistics. Global aquaculture production 1950-2019 (FishstatJ). In: FAO Fisheries Division [online]. Rome. Updated 2021. Retrieved from http://www.fao.org/fishery/countrysector/naso_thailand/en.
3. DOF. Statistics of Freshwater Aquaculture Production 2016. Fisheries Development Policy and Strategy Division No. 8/2018, Department of Fisheries. Ministry of Agriculture and Cooperatives, Bangkok, Thailand (2018).
4. Kanchan C, Imjai P, Kanchan N, Chaiyara A, Panchai K. Occurrence of parasitic and bacterial diseases in Thai freshwater fish*. J Agric Crop Resh*. (2020) 8:210-214. doi: 10.33495/jacr_v8i10.20.168
5. U.S Fish & Wildlife Service. Snakeskin gourami (*Trichopodus pectoralis*) Ecological Risk Screening Summary (2019). Retrieved from https://www.fws.gov/fisheries/ans/erss/uncertainrisk/ERSS-Trichopodus-pectoralis_Final.pdf.
6. Lom J, Dyková I. Myxozoan genera: definition and notes on taxonomy, life-cycle terminology and pathogenic species. *Folia Parasitol.* (2006) *53*:1-36. doi: 10.14411/fp.2006.001
7. Molnár K. Site preference of fish myxosporeans in the gill. *Dis Aquat Organ*. (2002) 48:197-207. doi: 10.3354/dao048197
8. Eiras JC, Adriano EA. A checklist of new species of *Henneguya* Thélohan, 1892 (Myxozoa: Myxosporea, Myxobolidae) described between 2002 and 2012. *Syst Parasitol.* (2012) *83*:95-104. doi.org/10.1007/s11230-012-9374-7

337 9. Kent ML, Andree KB, Bartholomew JL, El-Matbouli M, Desser SS, Devlin RH, et al.
338 Recent advances in our knowledge of the Myxozoa. *J Eukaryot Microbiol*. (2001)
339 48:395-413. doi: 10.1111/j.1550-7408.2001.tb00173.x.
340 10. Dykova I, Lom J. Histopathological changes in fish gills infected with myxosporidian
341 parasites of the genus *Henneguya. J Fish Biol*. (1978) 12:197-202.
342 doi.org/10.1111/j.1095-8649.1978.tb04165.x
343 11. Whitaker JW, Pote LMW, Hanson LA. Assay to detect the actinospore and myxospore
344 stages of proliferative gill disease in oligochaetes and pond water. *N Am J Aquac*.
345 (2005) 67:133-137. doi: 10.1577/a03-059.1
346 12. Haaparanta A, Valtonen ET, Hoffmann RW. Pathogenicity and seasonal occurrence of
347 *Henneguya-creplini* (Protozoa, Myxosporea) on the gills of perch *Perca-Fluviatilis* in
348 central Finland. *Dis Aquat Organ.* (1994) 20:15-22. doi: 10.3354/dao020015
349 13. Nowak BF, LaPatra SE. Epitheliocystis in fish. *J Fish Dis*. (2006) 29:573-588. doi:
350 10.1111/j.1365-2761.2006.00747.x
351 14. Blandford MI, Taylor-Brown A, Schlacher TA, Nowak B, Polkinghorne A.
352 Epitheliocystis in fish: An emerging aquaculture disease with a global impact.
353 *Transbound Emerg Dis*. (2018) 65:1436-1446. doi: 10.1111/tbed.12908
354 15. Pawlikowska-Warych M, Deptula W. Characteristics of *Chlamydia*-like organisms
355 pathogenic to fish. *J Appl Genet. (*2016) 57:135-41. doi: 10.1007/s13353-015-0303-8
356 16. Borel N, Polkinghorne A, Pospischil A. A review on chlamydial diseases in animals:
357 still a challenge for pathologists? *Vet Pathol.* (2018) 55:374-390. doi:
358 10.1177/0300985817751218
359 17. Yoonpundh R, Little D. Trends in the farming of the snakeskin gourami (*Trichogaster*
360 *pectoralis*) in Thailand. Naga, The WorldFish Center (1997) vol. 20:18-20.

361 18. Everett KDE, Bush RM, Andersen AA. Emended description of the order
362 *Chlamydiales*, proposal of *Parachlamydiaceae* fam. nov. and *Simkaniaceae* fam. nov.,
363 each containing one monotypic genus, revised taxonomy of the family *Chlamydiaceae*,
364 including a new genus and five new species, and standards for the identification of
365 organisms. *Int J Syst Bacteriol.* (1999) 49:415-440. doi: 10.1099/00207713-49-2-415
366 19. Relman D, Universal bacterial 16S rRNA amplification and sequencing. Persing DH,
367 Smith TF, Tenover FC, White TJ, (editors.). *Diagnostic Molecular Biology, Principles*
368 *and Applications*. (1993) 489–495.
369 20. Sood N, Pradhan PK, Verma DK, Gupta S, Ravindra, Dev AK, et al. Epitheliocystis in
370 rohu *Labeo rohita* (Hamilton, 1822) is caused by novel *Chlamydiales*. *Aquaculture.*
371 (2019) 505:539-543. doi.org/10.1016/j.aquaculture.2019.03.007
372 21. Draghi AII, Popov VL, Kahl MM, Stanton JB, Brown CC, Tsongalis GJ, et al.
373 Characterization of "C*andidatus* piscichlamydia salmonis" (order *Chlamydiales*), a
374 chlamydia-like bacterium associated with epitheliocystis in farmed Atlantic salmon
375 (*Salmo salar*). *J Clin Microbiol.* (2004) 42:5286-5297. doi: 10.1128/JCM.42.11.5286-
376 5297.2004.
377 22. Kumar S, Stecher G, Li M, Knyaz C, Tamura K. MEGA X: Molecular Evolutionary
378 Genetics Analysis across Computing Platforms. *Mol Biol Evol.* (2018) 35:1547-1549.
379 doi: 10.1093/molbev/msy096
380 23. Dinh-Hung N, Sangpo P, Kruangkum T, Kayansamruaj P, Rung-Ruangkijkrai T,
381 Senapin S, et al. Dissecting the localization of *Tilapia tilapinevirus* in the brain of the
382 experimentally infected Nile tilapia, *Oreochromis niloticus* (L.). *J Fish Dis*. (2021)
383 44:1053-1064. doi: 10.1111/jfd.13367
384 24. Corsaro D, Valassina M, Venditti D. Increasing diversity within *Chlamydiae*. *Crit Rev*
385 *Microbiol.* (2003) 29:37-78. doi: 10.1080/713610404

386 25. Horn M. *Chlamydiae* as symbionts in eukaryotes. *Annu Rev Microbiol.* (2008) 62:113-
387 31. doi: 10.1146/annurev.micro.62.081307.162818
388 26. S Stride MC, Polkinghorne A, Nowak BF. Chlamydial infections of fish: diverse
389 pathogens and emerging causes of disease in aquaculture species. *Vet Microbiol.* (2014)
390 170:19-27. doi: 10.1016/j.vetmic.2014.01.022
391 27. Sellyei B, Molnár K, Székely C. Diverse *Chlamydia*-like agents associated with
392 epitheliocystis infection in two cyprinid fish species, the common carp (*Cyprinus*
393 *carpio* L.) and the gibel carp (*Carassius auratus gibelio* L.). *Acta Vet Hung.* (2017)
394 65:29-40. doi: 10.1556/004.2017.003
395 28. Kim DJ, Park JH, Seok SH, Cho SA, Baek MW, Lee HY, et al. Epitheliocystis in carp
396 (*Cyprinus carpio*) in South Korea. *J Vet Med Sci.* (2005) 67:119-20. doi:
397 10.1292/jvms.67.119
398 29. Steigen A, Nylund A, Karlsbakk E, Akoll P, Fiksdal IU, Nylund S, et al. '*Cand.*
399 Actinochlamydia clariae' gen. nov., sp. nov., a unique intracellular bacterium causing
400 epitheliocystis in catfish (*Clarias gariepinus*) in Uganda. *PLoS One.* (2013) 8:e66840.
401 doi: 10.1371/journal.pone.0066840
402 30. Stride MC, Polkinghorne A, Miller TL, Groff JM, Lapatra SE, Nowak BF. Molecular
403 characterization of "*Candidatus* Parilichlamydia carangidicola," a novel *Chlamydia*-
404 like epitheliocystis agent in yellowtail kingfish, *Seriola lalandi* (Valenciennes), and the
405 proposal of a new family, "*Candidatus* Parilichlamydiaceae" fam. nov. (order
406 *Chlamydiales*). *Appl Environ Microbiol.* (2013) 79:1590-7. doi: 10.1128/AEM.02899-
407 12
408 31. Stride MC, Polkinghorne A, Miller TL, Nowak BF. Molecular characterization of
409 "*Candidatus* Similichlamydia latridicola" gen. nov., sp. nov. (*Chlamydiales*:
410 "*Candidatus* Parilichlamydiaceae"), a novel *Chlamydia*-like epitheliocystis agent in the

411 striped trumpeter, *Latris lineata* (Forster). *Appl Environ Microbiol.* (2013) 79:4914-20.
412 doi: 10.1128/AEM.00746-13
413 32. Stride MC, Polkinghorne A, Powell MD, Nowak BF. "*Candidatus* Similichlamydia
414 laticola", a novel *Chlamydia*-like agent of epitheliocystis in seven consecutive cohorts
415 of farmed Australian barramundi, *Lates calcarifer* (Bloch). *PLoS One.* (2013)
416 8:e82889. doi: 10.1371/journal.pone.0082889
417 33. Sood N, Pradhan PK, Verma DK, Yadav MK, Ravindra, Dev AK, et al. *Candidatus*
418 Actinochlamydia pangasiae sp. nov. (*Chlamydiales, Actinochlamydiaceae*), a
419 bacterium associated with epitheliocystis in P*angasianodon hypophthalmus*. *J Fish Dis.*
420 (2018) 41:281-290. doi: 10.1111/jfd.12711
421 34. Sparks AK, Morado JF, Hawkes JW. A systemic microbial disease in the Dungeness
422 crab, *Cancer magister*, caused by a *Chlamydia*-like organism. *J Invertebr Pathol.*
423 (1985) 45:204-217. doi: 10.1016/0022-2011(85)90010-2
424 35. Paperna I, Alves de Matos AP. The developmental cycle of epitheliocystis in carp,
425 *Cyprinus carpio* L. *J Fish Dis.* (1984) 7:137-147. doi: 10.1111/j.1365-
426 2761.1984.tb00916.x
427 36. Miyazaki T, Fujimaki Y, Hatai K, A light and electron microscopic study on
428 epitheliocystis disease in cultured fishes. *Nippon suisan gakkaishi.* (1986) 52:199-202.
429 doi: 10.2331/suisan.52.199
430 37. Desser S, Paterson W, Steinhagen D. Ultrastructural observations on the causative
431 agent of epitheliocystis in the brown bullhead, *Ictalurus nebulosus Lesueur*, from
432 Ontario and a comparison with the *Chlamydiae* of higher vertebrates. *J Fish Dis.* (1988)
433 11:453-460. doi: 10.1111/j.1365-2761.1988.tb00744.x

38. Nylund A, Kvenseth AM, Isdal E. A morphological study of the epitheliocystis agent in farmed Atlantic Salmon. *J Aquat Anim Health*. (1998) 10:43-55. doi: 10.1577/1548-8667(1998)010<0043:AMSOTE>2.0.CO;2

39. Work TM, Rameyer RA, Takata G, Kent ML. Protozoal and epitheliocystis-like infections in the introduced bluestripe snapper *Lutjanus kasmira* in Hawaii. *Dis Aquat Organ.* (2003) 57:59-66. doi: 10.3354/dao057059

40. Crespo S, Zarza C, Padrós F, Marín de Mateo M. Epitheliocystis agents in sea bream *Sparus aurata*: morphological evidence for two distinct *Chlamydia*-like developmental cycles. *Dis Aquat Organ.* (1999) 37:61-72. doi: 10.3354/dao037061

41. Guevara Soto M, Vaughan L, Segner H, Wahli T, Vidondo B, Schmidt-Posthaus H. Epitheliocystis distribution and dharacterization in brown trout *(Salmo trutta)* from the headwaters of two major European rivers, the Rhine and Rhone. *Front Physiol.* (2016) 7:131. doi: 10.3389/fphys.2016.00131

42. Lom J, Arthur JR. A guideline for the preparation of species descriptions in Myxosporea. *J Fish Dis.* (1989) 12:151-156. doi: 10.1111/j.1365-2761.1989.tb00287.x

43. Eiras JC. Synopsis of the species of the genus *Henneguya* Thélohan, 1892 (Myxozoa: Myxosporea: Myxobolidae. *Syst Parasitol.* (2002) 52:43-54. doi: 10.1023/a:1015016312195

44. Molnár K, Eszterbauer E. Specificity of infection sites in vertebrate hosts, in Myxozoan evolution, ecology and development. Okamura B, Gruhl A, Bartholomew JL, (editors). *Springer International Publishing* (2015):295-313.

45. Sabri DM, Eissa IAM, Danasoury MA, Khouraiba HM. Prevalence of Henneguya branchialis in Catfish *(Clarias gariepinus)* in Ismailia, Egypt. *Int J Agric Biol.* (2010) 12:897-900.

46. Videira M, Velasco M, Malcher CS, Santos P, Matos P, Matos E. An outbreak of myxozoan parasites in farmed freshwater fish *Colossoma macropomum* (Cuvier, 1818) (Characidae, Serrasalminae) in the Amazon region, Brazil. *Aquac.* (2016) 3:31-34. doi: 10.1016/j.aqrep.2015.11.004

47. Stilwell JM, Camus AC, Leary JH, Khoo LH, Griffin MJ. Pathologic changes associated with respiratory compromise and morbidity due to massive interlamellar *Henneguya exilis* infection in Channel × Blue Hybrid Catfish. *J Parasitol.* (2019) 105:686-692.

48. Özer A, Özkan H, Gürkanlı CT, Yurakhno V, Çiftçi Y. Morphology, histology and phylogeny of *Henneguya sinova* sp. nov. (Myxobolidae: Myxozoa) infecting gills of *Parablennius tentacularis* in the Black Sea, Turkey. *Dis Aquat Organ.* (2016) 118:207-15. doi: 10.3354/dao02968

59. Úngari LP, Vieira DHMD, da Silva RJ, Santos ALQ, de Azevedo RK, O'Dwyer LH. A new myxozoan species *Henneguya unitaeniata* sp. nov. (Cnidaria: Myxosporea) on gills of *Hoplerythrinus unitaeniatus* from Mato Grosso State, Brazil. *Parasitol Res.* (2019) 118:3327-3336. doi: 10.1007/s00436-019-06533-1

50. Yokoyama H, Itoh N, Tanaka S. *Henneguya pagri* n. sp. (Myxozoa: Myxosporea) causing cardiac henneguyosis in red sea bream, *Pagrus major* (Temminck & Schlegel). *J Fish Dis.* (2005) 28:479-87. doi: 10.1111/j.1365-2761.2005.00655.x

51. Figueredo RTA, de Oliveira JEF, Vilhena MPSP, Berredo J, dos Santos WJP, Matos E, et al. Henneguyosis in gills of *Metynnis hypsauchen*: an Amazon freshwater fish. *J Parasit Dis.* (2020) 44:213–220. doi.org/10.1007/s12639-019-01183-7

52. Goodwin AE, Park E, Nowak BF. Successful treatment of largemouth bass, *Micropterus salmoides* (L.), with epitheliocystis hyperinfection. *J Fish Dis.* (2005) 28:623-5. doi: 10.1111/j.1365-2761.2005.00662.x

483 **FIGURES**



484

485 **FIGURE 1 (A)** Snakeskin gourami (*Trichopodus pectoralis*), no external lesions on the body

486 surface of the fish. **(B)** Wet mount preparations of infected fish gill showing numerous

487 morphological characteristics of "cysts" (arrowheads). Scale bars are shown in the pictures.

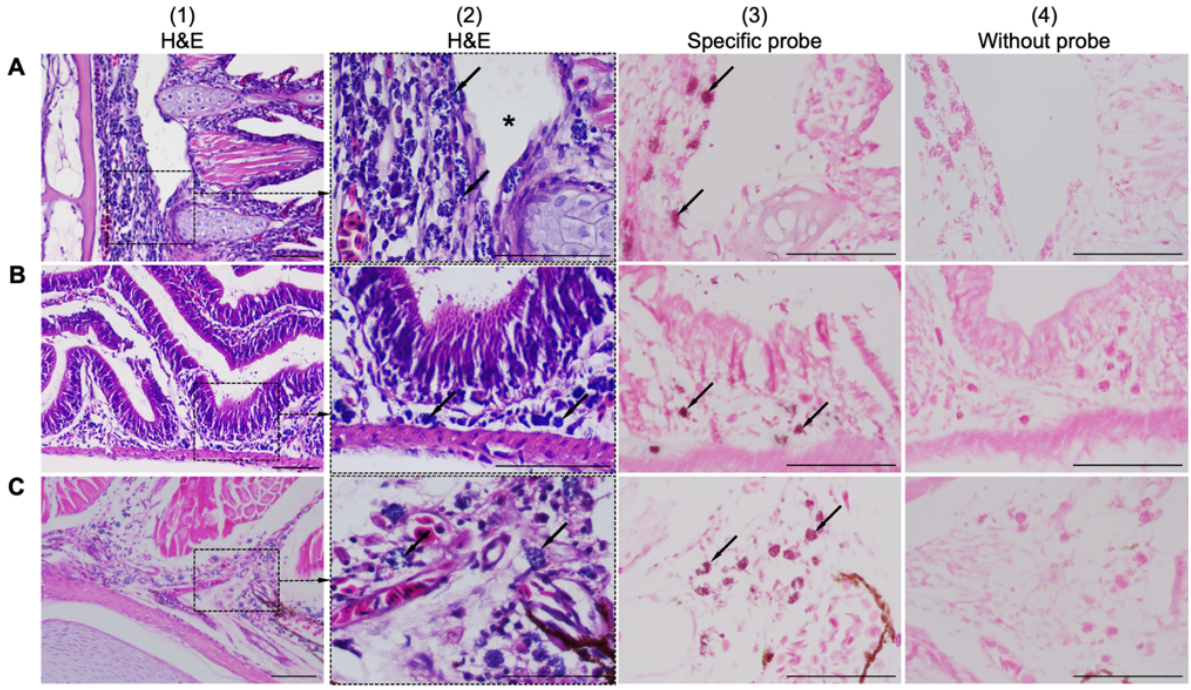

FIGURE 2 Comparison of consecutive gill sections of infected fish stained with H&E **(A.1 - C.1; A.2-C.2)**, ISH with a specific probe **(A.3-C.3)** and ISH without probe **(A.4-C.4)** as control. Infected fish showed the presence of a novel intracellular bacterium in the gill **(A.1)**, intestinal submucosa **(B.1)** and caudal/tail fin **(C.1)**. Higher magnification showed that the connective tissue was more susceptible to infection than others due to colonization by dense, roundish to oval, blue-stained intracellular bacteria (arrows in Figure **A.2, B.2,** and **C.2**). The bacteria were observed near the cartilaginous junctions of the primary and secondary gill filaments, resulting in disruption of the tissue junction (asterisk in Figure **A.2**). ISH positive reactivity of intracellular bacterial foci is indicated by distinct dark signals (arrows in Figure **A.3-C.3**). Scale bar = 50 µm.

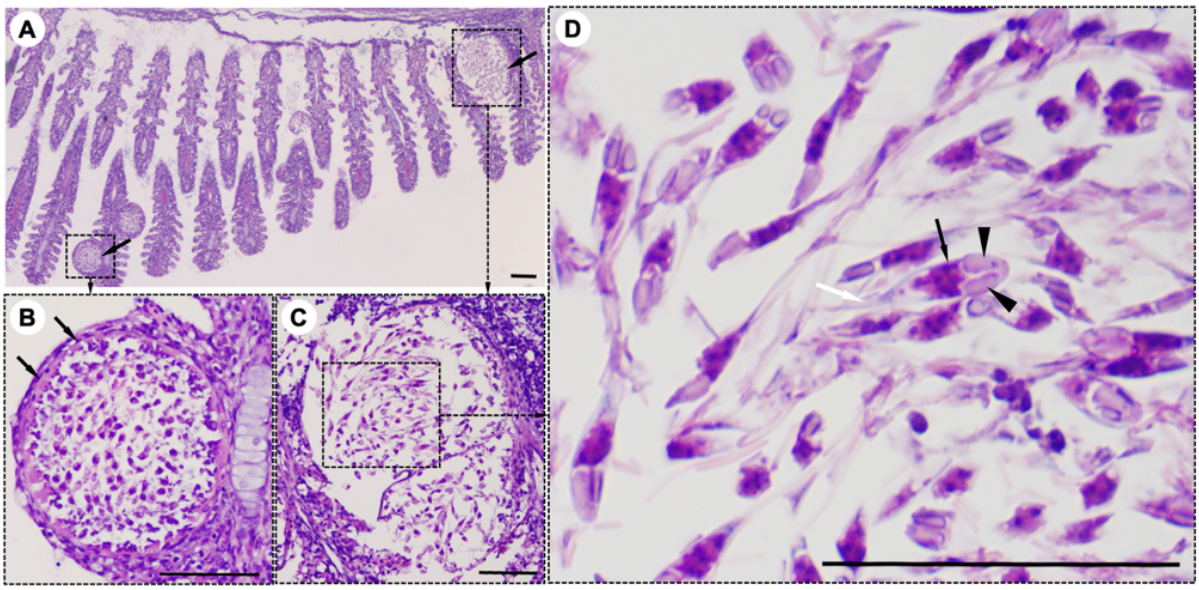

FIGURE 3 Histological lesions in the gills of the snakeskin gourami (*Trichopodus pectoralis*) infected with *Henneguya* sp. **(A)** Plasmodia (arrows) showing different developmental stages. **(B)** Young plasmodium was roundish and encased in a wall of epithelial cells (arrows). Immature myxospores were located in the periphery of the plasmodia and mature myxospores in the centre. **(C)** A grown plasmodium ruptured the envelope. **(D)** The myxospores have typical features of a *Henneguya* sp. including two equal polar caps (arrowheads), sporoplasm at the posterior pole of the spore (black arrow), and two long, superimposed caudal processes (white arrow). Slides were stained with hematoxylin and eosin (H&E), scale bar = 50 µm.

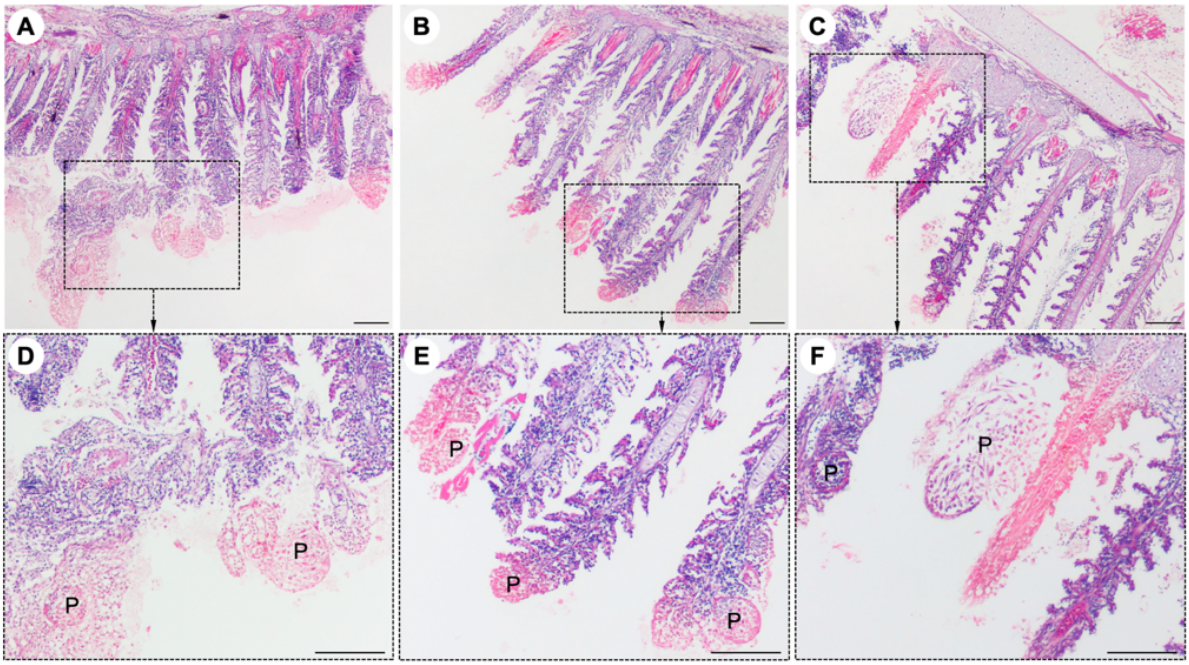

FIGURE 4 Histological lesions in the gills of the snakeskin gourami (*Trichopodus pectoralis*) infected with *Henneguya* sp. The plasmodia (P) caused severe distortion of the lamellar structure and obstruction of the gills by compression of the cysts **(A, B, C)**. Higher magnification indicated plasmodia occupied part of the gill lamellae and caused marked dilation and discrete epithelial hyperplasia **(D, E)**. The plasmodia grew and compressed the adjacent tissue and caused tissue necrosis in the infected area **(E, F)**. Slides were stained with hematoxylin and eosin (H&E), scale bar = 100 µm.

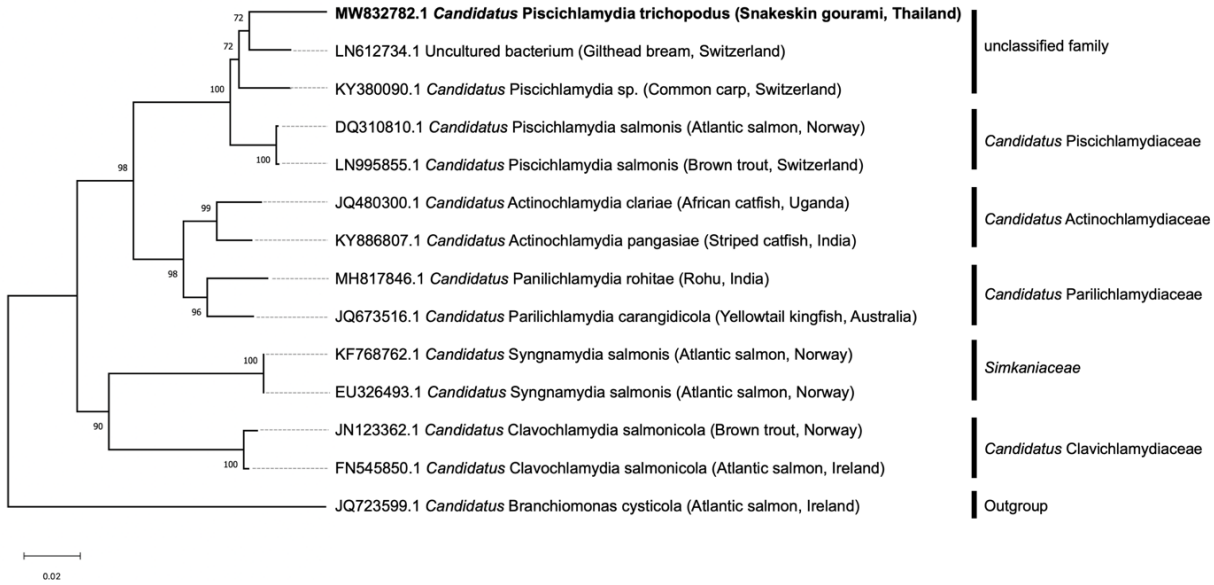

FIGURE 5 The phylogenetic tree was constructed based on the partial 16S rRNA sequence (766 bp) of the snakeskin gourami (*Trichopodus pectoralis*) from this study (MW832782) and closely related species. The accession numbers and taxonomic identities, as well as the host origin of the organisms included in this phylogenetic analysis, are shown. *Candidatus* Branchiomonas cysticola was selected as the outgroup. The tree was constructed using the neighbour-joining method. The scale bar represents 0.02 - nucleotide substitution per site, while the number at the node of the tree indicates the bootstrap value in percent.

524 **Supplementary data**

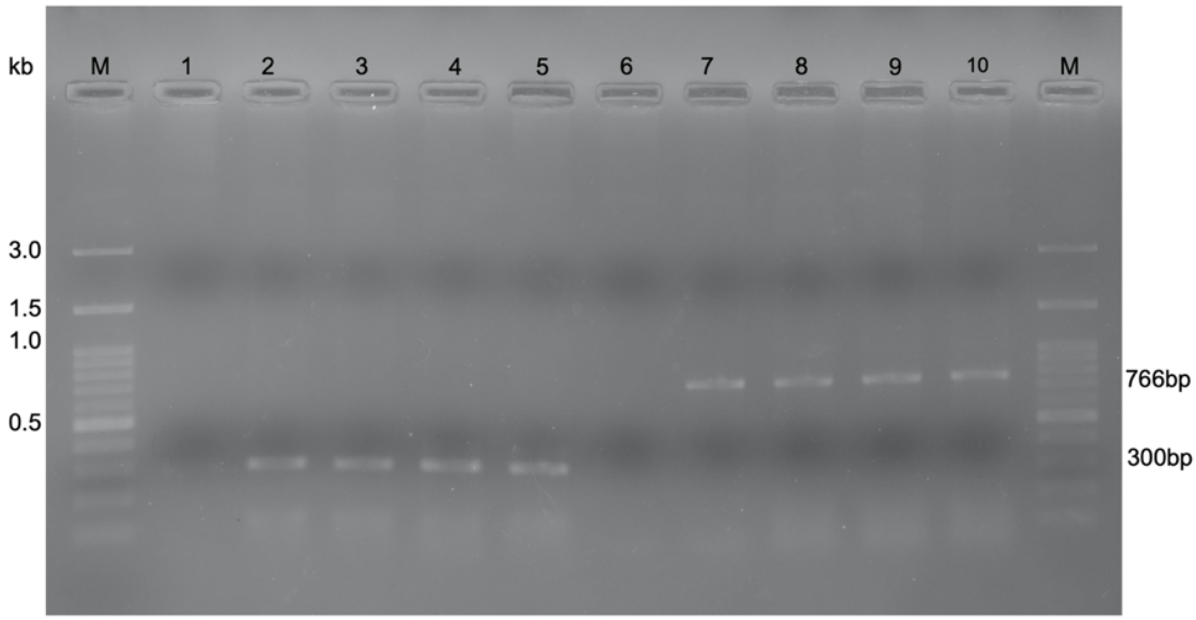

525

526 **FIGURE S1** Confirmation of PCR test results under agarose gel electrophoresis of samples
527 from four representative fish. Lanes 1 and 6 were amplified without DNA template using
528 primer set 1 and 2, respectively, as negative controls. Lanes 2, 3, 4 and 5 were amplified with
529 the DNA template from primer set 1 (300bp). Lanes 7, 8, 9 and 10 were amplified with the
530 DNA template from primer set 2 (766bp). Lane M was a DNA marker (Himedia, India).