# Morphological aspects of opossum (*Didelphis aurita*) pancreas during intramarsupial development.

Priscila Izabel Santos de Tótaro[a,*,1], Tarcísio De Souza Duarte[b], Clóvis Andrade Neves[a], Cláudio Cesar Fonseca[c] & Silene Souza Rodrigues Sartori[b].

[a]Department of General Biology. Federal University of Viçosa.Avenida Peter Henry Rolfs, s/n. Campus Universitário, Viçosa 36570-000, MG, Brazil

[b]Department Of Animal Biology. Federal University of Viçosa.

[c]Department Of Veterinary Medicin. Federal University of Viçosa.

[*] Corresponding author. Tel.: +55 31 991759048

Email adress: priscilatotaro@finom.edu.br

Abstract

The development degree of mammals at birth is markedly variable especially between placental and non-placental species. In marsupial mammals the organogenesis is completed during a period called external gestation, when the young animal remains at the maternal pouch being breastfed for, on average 90 days. This study reported the relevant morphological features found in the pancreas of the Brazilian opossum *Didelphis aurita*, a marsupial mammal, during its intramarsupial development. Newborns and young opossums removed from the pouch were divided into groups according to their average body length. The animals with few hours of intramarsupial life had visibly immature pancreas, due to the presence of early arrangement of endocrine and exocrine components. There was an only very large pancreatic duct, and blood vessels full of nucleated erythrocytes. In the individuals who were in the second third of intramarsupial development, the exocrine components were arranged in developing acini and endocrine cells were found arranged in early islets. The

Corresponding author current address: Faculdade do Noroeste de Minas. MG-188 - Fazendinha, Paracatu Minas Gerais, Brazil. Postal code: 38600-000.

presence of connective tissue and the division of the organ into lobes became more evident at this stage. In the last third of the external gestation, we found better structured acini with relatively small lumens. The islets were well-organized, and the presence of connective tissue around them was the most evident. Morphometric analyses showed considerable variations in the proportion of pancreatic structural components between the stages of intramarsupial development, indicating that marsupial pancreas undergoes morphological modifications and grows during the period of external gestation.

KEYWORDS: Embryo; marsupials; digestive system; organogenesis.

# 1 INTRODUCTION

The pancreas development in mammals has been discussed in some reviews, especially about mice, and other vertebrates. On the other hand, human pancreatic development has been less comprehensively reviewed (Jennings et al., 2015).

Because of their reproductive strategy, the marsupial mammals are a very interesting group, in which many development aspects are relevant to mammary evolution. The main characteristic about marsupials reproduction is the very short gestation period (12-38 days) that finishes at a very immature neonate born (Tyndale-Biscoe, 2001). Other remarkable aspect on marsupials development is the period called "external gestation", in which the new born remains about 90 days in the marsupial pouch (King et al., 1978).

The “pouch period” is extremely important because the most of growth and organs development occurs during these 90 days (Ferner & Mess, 2011). In marsupial mammals, the pancreas is one of the organs that are immature at birth and complete their development in the pouch period (King et al, 1978).

These facts made the genus *Didelphis* a prominent taxon on mammalian development and organogenesis research, especially due to the external gestation. Developing embryos located outside of the uterus are more easily reached without chirurgical procedures on a pregnant female (Dos Santos et al., 2014).

It is known that in the North American opossum, *Didelphis virginiana*, the newborn (approximately 12mm crown-rump length - CR) pancreas is composed of primitive endocrine and exocrine structures in an early structural arrangement (King et al., 1978).

A similar study with one of the South American opossum species, *Didelphis albiventris*, showed that pancreas exocrine acini and endocrine islets can be seen for the first time at different stages of external gestation (Coutinho et al., 1982).

Thus, the findings about pancreas development of another South American marsupial, also known as black-ear opossum, *Didelphis aurita* can be compared to available information about other species of the genus and adults of the same species.

Therefore, this study aimed to describe the main external and morphological changes observed in *Didelphis aurita* opossum during intramarsupial life, relating their body size to the dimensions of the pancreas. We also described the pancreas histology in three different points of the pouch period, quantifying the proportion of developing pancreas components during the intramarupial development.

## 2 MATHERIAL AND METHODS

### 2.1 Animals and ethical aspects

Three *D. aurita* female opossums (body weight 0.7±0.05kg), considered adults by having complete dentition (Macedo et al., 2006) were captured in hook-type traps (75x31x31cm) baited with a banana and cod liver oil. The capture took place in a small fragment of forest, located in the Zoology Museum João Moojen - Vila Gianetti, UFV, in Viçosa, Minas Gerais. The catches of animals were authorized by Brazilian Institute of Environment and Renewable Natural Resources (IBAMA, under license number: 31328-1), and the experimental procedures were approved by the Institutional Ethics Committee for Animal Research (approval protocol 98/2011).

### 2.2 Euthanasia and biometric analysis

The captured females were mechanically hold with the aid of a scraped glove and anesthetized with Thiopental Sodium (30mg/mL) intraperitoneally. The marsupial cavity was opened for exposure of puppies that were removed and sexed. After the puppies been removed, the females were returned to the collect site. We obtained a mean of six puppies per female, which were weighed and measured in their CR lengths to verify the stage of development in which they were. Subsequently, the euthanasia of the obtained puppies was performed with intracardiac administration of potassium chloride (0.25%). After the exposure of the abdominal cavity, pancreas was removed under a magnifying glass, and fixed in 10% Bouin's solution for 24 hours.

## 2.3 Experimental Groups

The animals removed from the marsupial pouch were divided into three groups according to their CR length:

● Group 1: approximately in the first days of intramarsupial life and in the initial third of external gestation (mean size 10mm CR);

● Group 2: approximately 30 days of intramarsupial life and in the middle third of external gestation (mean size 50mm CR);

● Group 3: approximately 90 days of intramarsupial life and in the final third of external gestation (mean size 100mm CR).

For the biometric and morphometry analyzes, 4 specimens of each one of the groups were used.

## 2.4 Histological processing and analyses

After been fixed during 24 hours, pancreas fragments were embedded in histological paraffin and methacrylate resin (Historesin Leica®). The paraffin embedded fragments were sectioned (5 µm thick) in a hand rotary microtome (Leica Multicut 2045; Reichert-Jung Products, Germany) and the sections were stained according to Hematoxylin and Eosin technique (Bancroft & Stevens, 1996). The fragments embedded in methacrylate were sectioned (3 µm thick) in a rotary microtome (Leica Multicut 2045; Reichert-Jung Products, Germany) and stained according to the technique of Toluidine Blue - Sodium Borate (Ghnenis et al., 2018).

## 2.5 Images acquisition and morphometry

The photographic documentation of the preparations was performed under a CX31 light microscope (Olympus, Tokyo, Japan) with an SC020 digital camera (Olympus, Tokyo, Japan). Pancreas components were quantified using the software Image-Pro Plus 3.5 (MediaCybernetics, Inc., Rockville, Maryland,

USA). In the obtained pictures, ten fields were analyzed per region (duodenal, body and splenic) of the pancreas of each animal by points counting, using a grid with 225 intersections. The analyze results in 2250 points per pancreas region and 6750 points per animal.

Ten pancreatic islets were measured for each one of the three regions of the pancreas of each animal of the different groups, and the two largest diameters were obtained for the calculation of the islet mean diameter.

## 2.6 Analyzed parameters

Morphometry analyses quantified the following pancreatic parameters: exocrine acini, islets, ducts, connective tissue and blood vessels. In the case of Group 1 animals, proacinar cells and endocrine cells were quantified, since no acini and islets were identified at this stage of intramarsupial development. The percentage of the quantified components was compared between the three intramarsupial stages.

## 2.7 Statistical analyzes

The data were organized in an electronic spreadsheet for analysis of variance (Anova), using th software GraphPad Prism 5.0 statistical software (GraphPadSoftware, Inc., La Jolla, CA, USA). Data were expressed as mean ± standard error and statistical significance was set at $p < 0.05$. The means of the groups were compared by using Tukey Test.

# 3 RESULTS

## 3.1 External and internal morphology

Group 1 animals (newborns) have a visibly immature appearance, with total absence of hair, eyes not fully formed and hind limbs similar to that of the

embryo. Sexual differentiation is not complete, and the external reproductive system is represented by the cloaca (Figure 1 A and Figure 1B).

The abdominal cavity is composed of the stomach, small and large intestines, covered by a rather large structure that fills almost all the space: the mesonephrous, which at this stage of development is considerably larger than the adult animal's kidney. The liver is also present, and the pancreas could be found due to its location between the duodenum and the spleen.

In group 2 animals, the main change is the visibly increased body size. At this stage the eyes remain closed. The hind and forelimbs are present and had the characteristic conformation of the adult animal, and it is already possible to notice the presence of claws. The hairs, however, are still absent and the body shape remains to the fetal position (Figure 1C).

The abdominal cavity has the same components already described for group 1, but it is possible to note the involution of the mesonephrous.

In the animals of group 3 the external appearance is marked by the occurrence of the coat already in the characteristic pattern of the adult animal (Figure 1D). The animals removed from the marsupial have a reduced ability to move. The abdominal cavity resembles that of the adult animal, and the presence of kidneys with adult morphology can be identified.

### 3.2 Biometric parameters

*Didelphis aurita* body weight (BW) increased during intramarsupial development, as did the pancreas weight (PW). The ratio of body weight to pancreas weight (a measurement parameter called pancreatosomatic index – PI), however, decreased over the period (Table 1).

### 3.3 Quantification of pancreatic histological components

*Didelphis aurita* developing specimens showed a significant increase in the pancreas exocrine cells perceptual when compared the newborns to the animals of final third of pouch period. The inverse pattern was observed to endocrine cells perceptual. The blood vessels occurrence decreased during the pouch period progression. The proportion of connective tissue was significantly

higher between the newborn and middle third animals. Interesting, this perceptual decreased from the middle to the final third of pouch life (Table 2).

The findings finding make it clear that, the pancreas of the opossum *Didelphis aurita* is immature at birth and the endocrine and exocrine portions require a considerable time to reach structural maturity (Figure 2). Another remarkable feature about *Didelphis aurita* pancreas, is the increase in exocrine components percentage during the organ development (Figure 2D and Figure 2G). The connective tissue proportion increase is much stronger between the newborn and intermediary stages (Figure 2A and Figure 2D), (Table 2). The growing connective tissue perceptual is possibly due the gradual lobes formation in the organ. However, as the exocrine tissue expands, the proportion of connective tissue tends to decrease at the last group (Figure 2G).

The higher percentage of blood vessels in the newborn opossum can be justified by the great size of the blood vessels found at the pancreas at this stage (Figure 2A and Figure 2C). During the development, the vessels tend to decrease in size and present enucleated erythrocytes, as in the adult specimens (Figure 2F and Figure 2I).

The pancreas of *Didelphis aurita* newborn presents a single duct, lined by cubic epithelial cells (Figure 2A). As the development progress to the final third of external gestation, the ductal structures tend decrease in size, and assume an organization pattern similar to that found in adults specimens (Figure 2H).

The present study also showed that there are no islets in the pancreas of the newborn *Didelphis aurita* (Figure 2A, Figure 2B and Figure 2C). On the other hand, the diameter of the pancreatic islets during the middle and final thirds were not significantly different (Table 3).

## 4 DISCUSSION

Commonly, in mammals, the degree of development of neonates has a strong relationship with their reproductive aspects. The main factor that separates marsupials from other mammals is the immature or incomplete development of neonates. It is even known that the most altricial of placental

mammals is much more developed, at birth, that any marsupial newborn. (Ferner et al., 2017).

The external morphology and anatomy of developing *Didelphis aurita* reported on this is study is consistent with the observations made by Dezone-Mota (1984). Similar observations were made also in *Monodelphis domestica* neonates. These newborns also had an embryonic appearance (Ferner et al., 2017). The external anatomical and structural aspect of the newborn *Didelphis aurita* opossums is consistent with the characteristics pointed out for other marsupials, and confirms the thesis that at this moment, the well-developed structures are those fundamental ones for the animal to reach the marsupial pouch and to its adherence to the mother's breast (facial region, and forelimbs) (Borthwick and Old, 2016).

The morphologically mature pancreas of mammals has two basic functional units: the exocrine pancreas, producing digestive enzymes, and the endocrine pancreas, which is functional in the synthesis of hormones with key regulatory functions in food uptake and metabolism. The major part of the organ is the exocrine components, divide into secretory acinar and ductular cells. About 1-2% of the mature pancreas mass comprises the endocrine portion, organized into functional structures called islets of Langerhans (Pieler and Chen, 2006).

This work results confirm the findings of King et al. (1978) which reported that the pancreas of the North American opossum (*Didelphis virginiana*) does not reach the mature stage before the pre-pubertal period of animal life. In a similar way, the liver of the marsupial *Phascogale calura* only reaches ultrastructural maturity at the end of the intramarsupial period (Borthwick and Old, 2016).

Our findings also are in agreement with the results found by Fonseca et al. (2004) in *Didelphis albiventris.* The authors reported an increase in the exocrine components when compared young and adult animals (Fonseca et al., 2004). In fact, Van Suylichem et al. (1995) found that in young pigs the amount of pancreatic connective tissue (stroma) was higher when compared to adults.

The exocrine components of *Didelphis aurita* newborn pancreas are very similar to *Didelphis virginiana* newborn submandibular gland. At birth, both consist of a series of primitive tubules that finishes in "blind" ends, and both

show the development of acini and ducts during the first week of life, followed by considerable changes that occur during the long post natal period. The late differentiation of the submandibular gland occurs in according to the maturation of the pancreas and the rest of the digestive tract (Leeson et al., 1978).

The developing *Didelphis*, during the pouch period, is fed by the female milk that has a variable composition as the young opossum develops (Green et al., 1996). The marsupial milk composition is studied in several species, such as tammar wallaby (*Macropus eugenii*). In this specie the marsupial milk is first produced at low volumes, in a diluted form. The milk carbohydrate content is higher than protein and lipid amounts at birth and during the first weeks of the pouch period. As the developing proceeds, the concentration of lipid and protein increases, until the final of the intramarsupial life, when lipid amount is the highest (Pharo, 2019). These changes in the marsupial milk composition may be a reflection of the digestive glands progressive development during the pouch period, including the pancreas.

A similar study with another South American opossum, *Didelphis albiventris* showed that pancreatic islets appear at the beginning of the second third of pouch life (Coutinho et al., 1982).These observations are in agreement with those made by King et al. (1978) who observed the first appearance of the pancreatic islets during the second third of *Didelphis virginiana* intramarsupial life (King et al., 1978).

Laguesse (1896) described two generations of islets in the sheep pancreas. Primary "islets" would originate from isolated endocrine cells along the primitive pancreas or developing pancreatic tubules. According to this author, the primary islets would suffer degeneration, concomitantly with the differentiation of the secretory acini. Therefore, the primary islets would be those formed before the differentiation of acini from the exocrine portion of the pancreas. Laguesse (1896) also considered that secondary islets would be formed from adult acinar cells, after a process of de-differentiation (Laguesse, 1896). King et al. (1978) observed similar islets in the pancreas of the newborn North American opossum and reported that in several species of opossum occur two generations of islets.

However, primary or degenerating islets was not observed at any stage of pancreas development in *Didelphis aurita*, which suggests a non-functional endocrine pancreas at birth.

For the opossum *Didelphis albiventris*, Fonseca et al. (2004) found a decrease in the proportion of islets in the pancreas of adult animals compared to those of the last month of intramarsupial life. In fact, the present study found significance decreased of endocrine components (pancreatic islets beyond the second and last third of marsupial time) along the *Didelphis aurita* intramarsupial development.

The developing pancreatic islets of opossum *Didelphis aurita* have a small diameter, as much as observed to *Didelphis albiventris* (Fonseca et al., 2002).

## 5 CONCLUSION

The pancreas of *Didelphis aurita* newborn is morphologically immature presenting early structural components. The period of external gestation in *D. aurita* is crucial in the development of these animals, since *D. aurita* pancreas completes its structural and functional development during the external gestation period.

The findings showed on this study bring relevant information about the morphological development in marsupial mammals and pancreas organogenesis.

## ACKNOWLEDGEMENTS

This work was financially supported by Coordenação de Aperfeiçoamento de Pessoal de Nível Superior (CAPES), Brazil.

## CONFLICT OF INTERESTS

The authors declare no conflict of interest.

## ORCID

Priscila Izabel Santos de Tótaro https://orcid.org/0000-0002-0102-5811

## REFERENCES


Bancroft, J.D., Stevens, A. (1996) Theory and Practice of Histological Techniques. 4th Edition, Churchill Livingstone, New York.

Borthwick, C. R., & Old, J. M. (2016). Histological Development of the Immune Tissues of a Marsupial, the Red-Tailed Phascogale (Phascogale calura). *Anatomical record (Hoboken, N.J. : 2007)*, *299*(2), 207–219. https://doi.org/10.1002/ar.23297

Coutinho, H. B., Beck, F., Santiago, M. A., Pessoa, R. G., Pinheiro, P. B., & Coutinho, V. B. (1982). Some aspects of the development of the pancreas in the marsupial Didelphis albiventris. *Revista brasileira de biologia*, *42*(1), 15–19.

Dezzone, M.F.M, Carreira, J.C.A., Franco, A.M.R. (1984). Estudo do desenvolvimento extra uterino de Didelphis marsupialis e estabelecimento de uma tabela de classes etárias. *Anais do XI Congresso Brasileiro de Zoologia.*

Ferner, K., Schultz, J. A., & Zeller, U. (2017). Comparative anatomy of neonates of the three major mammalian groups (monotremes, marsupials, placentals) and implications for the ancestral mammalian neonate morphotype. *Journal of Anatomy*, *231*(6), 798–822. https://doi.org/10.1111/joa.12689

Ferner, K., Schultz, J. A., & Zeller, U. (2017). Comparative anatomy of neonates of the three major mammalian groups (monotremes, marsupials, placentals) and implications for the ancestral mammalian neonate morphotype. *Journal of anatomy*, *231*(6), 798–822. https://doi.org/10.1111/joa.12689

Fonseca, C.C., Nogueira, J.C., Barbosa, A.J.A. 2002. Diâmetro das ilhotas pancreáticas do gambá *Didelphis abiventris* em desenvolvimento intramarsupial. *Archives of Veterinary Science* 7: 129-134.

Fonseca, C.C; Nogueira, J.C.; Barbosa. A.J.A. 2004. Histometria do pâncreas do gambá sul-americano. *Revista Ceres* 51(297): 565-574

Ghnenis, A. B., Czaikowski, R. E., Zhang, Z. J., & Bushman, J. S. (2018). Toluidine Blue Staining of Resin-Embedded Sections for Evaluation of Peripheral Nerve Morphology. *Journal of visualized experiments: JoVE*, (137), 58031. https://doi.org/10.3791/58031

Green, B., Krause, W. J., & Newgrain, K. (1996). Milk composition in the North American opossum (Didelphis virginiana). *Comparative Biochemistry and*

*Physiology - B Biochemistry and Molecular Biology*, *113*(3), 619–623. https://doi.org/10.1016/0305-0491(95)02034-9

Jennings, R. E., Berry, A. A., Strutt, J. P., Gerrard, D. T., & Hanley, N. A. (2015). Human pancreas development. *Development (Cambridge)*, *142*(18), 3126–3137. https://doi.org/10.1242/dev.120063

King, F. C., Krause, W. J., & Cutts, J. H. (1978). Postnatal development of the pancreas in the opossum. Light microscopy. *Acta anatomica*, *101*(3), 259–274. https://doi.org/10.1159/000144976

Laguesse, E. (1896) Recherches sur l'histogénie du pancréas chez le mouton. II. Formation et remaniement des cavités sécrétantes. *Journal of Anatomy and Physiology*, 32, 171-198, 209-255.

Leeson, C. R., Cutts, J. H., & Krause, W. J. (1978). Postnatal development and differentiation of the opossum submandibular gland. *Journal of anatomy*, *126*(Pt 2), 329–351.

Macedo, J., Loretto, D., Vieira, M. V., & Cerqueira, R. (2006). Classes de desenvolvimento em marsupiais: um método para animais vivos. *Mastozoología neotropical*, *13*(1),133-136. http://www.scielo.org.ar/scielo.php?script=sci_arttext&pid=S032793832006000100011&lng=es&tlng=pt.

Pharo, E. A. (2019). Marsupial milk: A fluid source of nutrition and immune factors for the developing pouch young. *Reproduction, Fertility and Development*, *31*(7), 1252–1265. https://doi.org/10.1071/RD18197

Pieler, T., & Chen, Y. (2006). Forgotten and novel aspects in pancreas development. *Biology of the Cell*, *98*(2), 79–88. https://doi.org/10.1042/bc20050069

Santos, D. C. M. dos, Cupertino, M. do C., Fialho, M. do C. Q., Barbosa, A. J. A., Fonseca, C. C., Sartori, S. S. R., & Matta, S. L. P. da. (2014). Quantification of endocrine cells and ultrastructural study of insulin granules in the large intestine of opossum Didelphis aurita (Wied-Neuwied, 1826). *Tissue and Cell*, *46*(1), 70–77. https://doi.org/10.1016/j.tice.2013.11.004

Tyndale-Biscoe CH, Janssens PA (1988) Introduction. In: The Developing Marsupial. Models for Biomedical Research. (eds Tyndale-Biscoe CH, Janssens PA), pp. 1–7. Berlin: Springer. (n.d.).

van Suylichem, P. T. R., van Deijnen, J. E. H. M., Wolters, G. H. J., & van Schilfgaarde, R. (1995). Amount and distribution of collagen in pancreatic tissue of different species in the perspective of islet isolation procedures. *Cell Transplantation*, *4*(6), 609–614. https://doi.org/10.1016/0963-6897(95)00026-T

TABLES

TABLE 1

Biometric parameters of *Didelphis aurita* during the initial, middle and final phases of intramarsupial development. Data expressed as mean ± standard deviation.

| | **G1** | **G2** | **G3** |
|---|---|---|---|
| **BW** | 0.1±0.50 | 7.69±1.20 | 53.7±3.60 |
| **CR** | 10.25±0.30 | 46.25±0.80 | 93.25±1.10 |
| **PW** | 0.0005±0.000012 | 0.12±0.002 | 0.28±0.03 |
| **PI** | 0.05±0.001 | 0.015±0.003 | 0.005±0.002 |

BW = body weight (g); CR, = length CR (mm); PW = pancreas weight (g); PI = pancreatosomaticindex. G1, G2, G3, respectively: initial, middle and final stages of intramarsupial development.

TABLE 2

Histometric parameters of the pancreas of the opossum *Didelphis aurita* during intra-marsupial development stages. Data expressed as mean ± standard deviation.

| | **G1** | **G2** | **G3** |
|---|---|---|---|
| **AC** | 27.56±0.244 [a] | 40.53±2.34 [ab] | 65.23±0.1 [b] |
| **EC** | 29.61±0.12 [a] | 5.32±0.23 [ab] | 2.87±0.04 [b] |
| **D** | 6.82±0.12 [a] | 4.25±1.15 [ab] | 1.93±0.08 [b] |
| **BV** | 8.4±0.2 [a] | 4.22±1.62 [b] | 1.40±0.87 [c] |
| **CT** | 27.61±0.07 [a] | 46.18±2.38 [b] | 28.57±0.10 [c] |

G1 = Group 1 (initial stage), G2 = Group 2 (middle stage), G3 = Group 3 (final stage); Proportion of pancreatic structures (%): AC = acini, EC = endocrine cells, D = ducts, BV = blood vessels, CT = connective tissue. Different letters on the same line indicate statistical difference between groups by the Tukey Test.

TABLE 3

Diameter of pancreatic islets of opossum *D. aurita* during intramarsupial development stages. Data expressed as mean ± standard deviation.

| | **G2** | **G3** |
|---|---|---|
| **PID** | 39.52 ± 5.104 µm [a] | 34.86 ± 3.101 µm [a] |

PID = Pancreatic islet diameter, G2 = Group 2 (middle stage), G3 = Group 3 (final stage).. Different letters on the same line indicate statistical difference between groups by the Tukey Test.

FIGURES

FIGURE 1 External appearance of the opossum *Didelphis aurita.* (A) Newborn or initial third of intramarsupial period; (B) at the middle (C) and last third of intramarsupial period (D). Bars: (A) 10mm; (B) 3,5mm; (C) 5mm; (D) 92mm.

FIGURE 2 Pancreas of *Didelphis aurita* during the intramarsupial development. (A), (B), and (C) newborn pancreas, the initial third of intramarsupial period. (D), (E), and (F) Middle third of intramarsupial period. (G), (H), and (I) Final third of intramarsupial period. Bv = blood vessel; Ct = connective tissue; D = duct; Pi = pancreatic islet; point of arrow = endocrine cell nucleus. Arrow = epithelial cell nucleus. Arrow head = exocrine proacinar cell nucleus. Magnification: (A) 100X; (B) 200X; (C) 100X; (D) 100X; (E) 200X; (F) 200X; (G) 100X; (H) 100X; (I) 400X. Staining: (A - F) Toluidine Blue – Sodium Borate;(G - I) Hematoxylin - Eosin.

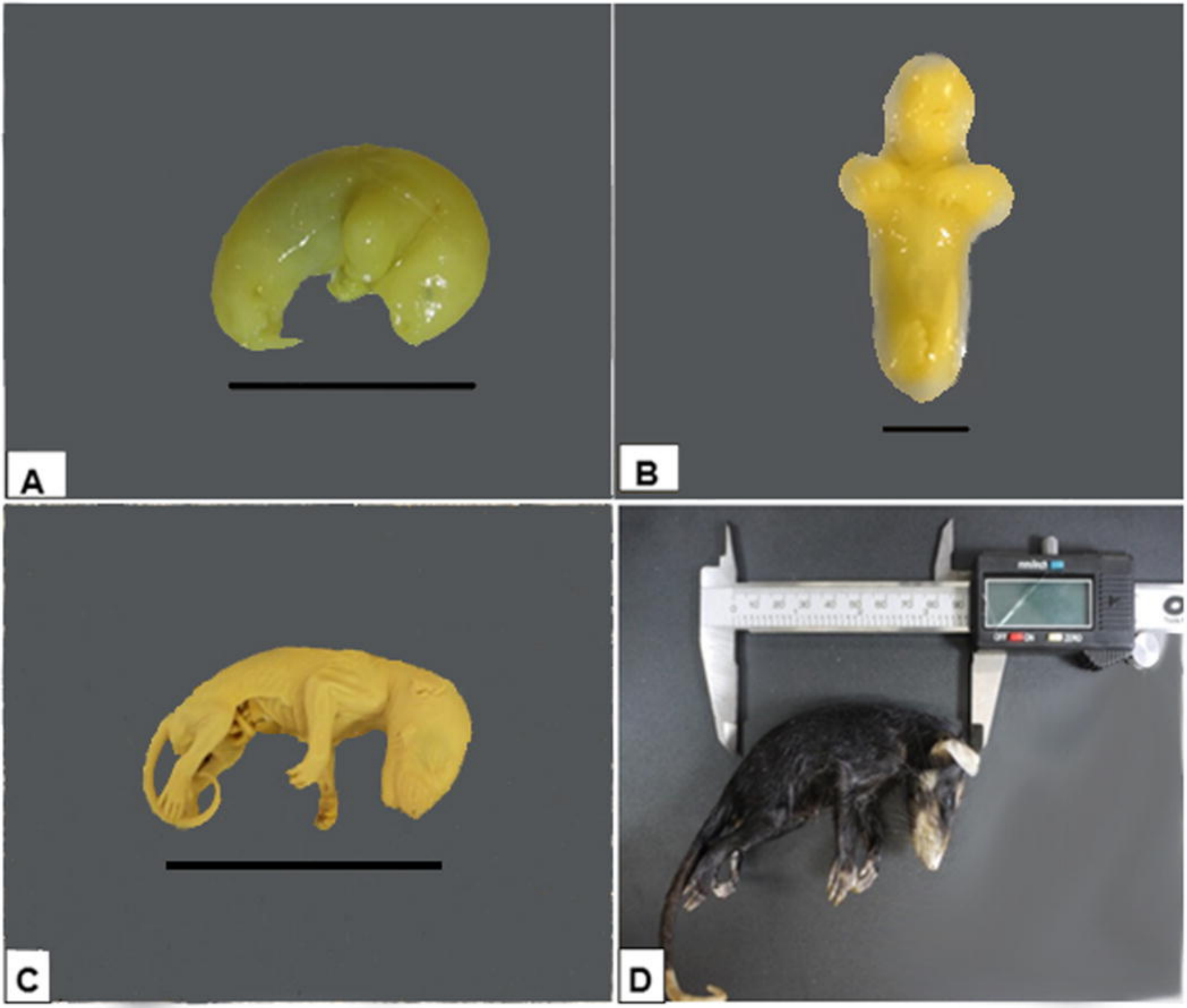
A
B
C
D

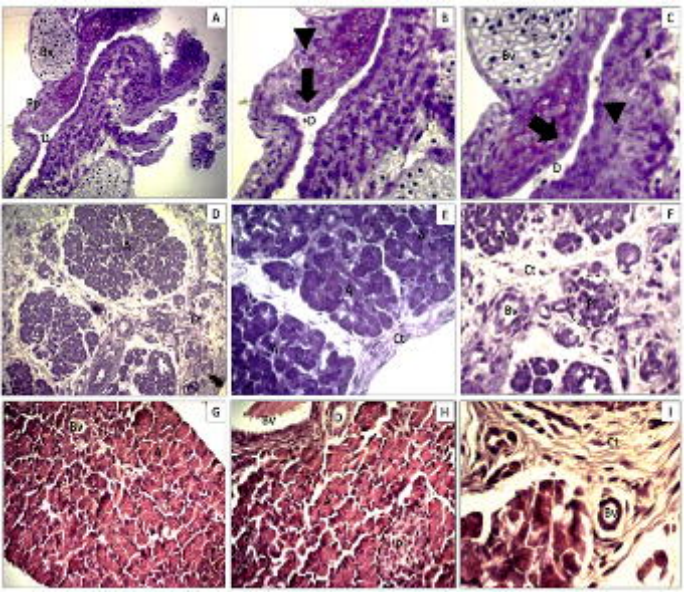
A
Bv
Ep
Ct
B
D
C
Bv
D
D
E
A
Ct
F
Ct
Bv
G
Bv
H
Bv
D
I
Ct
Bv