Manuscript Title:

Auditory corticostriatal connections in the human brain

Authors & Affiliations:

Kevin R. Sitek, University of Pittsburgh

Leah B. Helou, University of Pittsburgh

Bharath Chandrasekaran, University of Pittsburgh

Joint corresponding authors:

Kevin R. Sitek: kevin.sitek@pitt.edu

Bharath Chandrasekaran: b.chandra@pitt.edu

Abstract

Auditory learning critically depends on sensory, decisional, and reward-based processes that are supported by the dorsal striatum. Auditory corticostriatal connections have been well-characterized in animal models including non-human primates, where primary auditory cortex preferentially connects to putamen, and caudate head receives most of its inputs from anterior superior temporal cortex. However, the extent to which human auditory corticostriatal connectivity follows similar organizational principles is challenging to assess due the small, deep anatomy of these striatal structures. We leveraged high-quality diffusion-weighted MRI tractography to 'virtually' dissect structural pathways between auditory cortical regions and dorsal striatal regions in a sub-millimeter resolution single-subject dataset. Across most of

auditory cortex, putamen connections were more frequent than caudate connections; only anterior-most superior temporal cortex had strong connectivity with caudate, specifically the caudate head. Putamen streamline endpoints were largely along the ventral portion of the structure, ranging from caudal to middle putamen. Consistent with these results, caudate connections were largely confined to an anterior pathway, whereas putamen connections were more equally spread between anterior and posterior pathways to temporal cortex. In contrast to the auditory findings, visual corticostriatal streamlines did not preferentially reach putamen. We replicate these results in an independent sample of near-millimeter resolution single-session diffusion MRI from the Human Connectome Project. Overall, our results suggest strong structural connectivity between primary and association auditory cortices with putamen but not with any subdivision of caudate. Prioritized connectivity between superior temporal cortex and putamen is highly suggestive of distinct functional roles for striatal subdivisions in auditory perception.

Introduction

Dorsal striatum (or basal ganglia) is extensively involved in mediating learning and decision-making across motor, auditory, visual and cognitive domains (Groenewegen 2003; Lim et al. 2014; Ell 2011; Seger and Cincotta 2005; Seger 2013; Brovelli et al. 2011). Within the auditory system, corticostriatal pathways are argued to be key intermediaries involved in perceptual learning, categorization, and decision making (Znamenskiy and Zador 2013; Xiong et al. 2015; Lee et al. 2015). Corticostriatal pathways are hypothesized to underlie human auditory

behaviors such as speech learning in adults (Chandrasekaran et al. 2014; Feng et al. 2019; Feng et al. 2021), language more broadly (Ullman 2001), and music (Zatorre and Salimpoor 2013).

Despite more recent interest in human auditory corticostriatal function, very little is known about the anatomical pathways that connect the auditory system to the striatal sub-structures. Existing information about auditory striatal circuits largely comes from non-human animal models (Yeterian and Pandya, 1998; Znamenskiy and Zador, 2013; Ponvert and Jaramillo 2019). Rodents are frequently used as model systems in neuroscience research (Hintiryan et al. 2016; Hunnicutt et al. 2016), including the auditory corticostriatal network (Ghosh and Zador 2021; Xiong et al. 2015; Znamenskiy and Zador 2013; Lee et al. 2015). However, neuroanatomical differences between rodents and humans make it challenging to translate striatal findings from rodents to humans; in contrast, humans are thought to retain much of the neuroanatomy of our non-human primate relatives, including dorsal striatal organization (Balsters et al. 2020). Indeed, some striatal differences across humans and macaques are clearly documented (Liu et al. 2021). To our knowledge, no focused mapping of human corticostriatal connectivity exists in the extant literature which can be compared to the extensive non-human primate literature.

To the extent that macaque and human striatum share similarities in organization, we can make some predictions about the connectivity of the superior temporal cortical regions with both caudate and the putamen based on early neuroanatomical tracing literature in macaques (Yeterian and Pandya 1998; Yeterian and Van Hoesen 1978). In a series of experiments, investigators used anterograde autoradiographic tracers to map the corticostriatal pathways. In particular, temporal neocortical regions that are cortico-cortically connected with frontal cortex were also preferentially linked to the caudal portions of the putamen, above and beyond what

is seen in other regions of interest in the frontal, parietal, and occipital lobes (Yeterian and Van Hoesen 1978). Later research took a more finely parcellated approach by distinguishing between anatomical regions within the superior temporal plane versus the physiologically-defined regions of primary and association auditory cortices (Galaburda and Pandya 1983). These studies verified prior findings (Kemp and Powell, 1970) that primary auditory cortex (AI) has limited projections to the dorsomedial portion of the tail of the caudate and the adjacent caudoventral segment of the putamen (Yeterian and Pandya 1998). Injections of tracer into associative auditory cortex (AII) revealed substantially more widespread corticostriatal projections that were distributed along the ventral aspect of the body of the caudate, the medial sector of its tail, and the putamen both rostro-ventrally and caudo-ventrally. With placement of tracer caudal to AI in the supratemporal plane, striatal labeling occurred in the head and body of the caudate and in rostral and caudal aspects of the putamen. Labeling patterns differed from the superior temporal gyrus compared to these regions in the supratemporal plane. Of all the regions studied, AI showed the most modest corticostriatal connectivity and the belt areas showed more robust connections. This pattern was similar to what was shown in neuroanatomical studies of primary visual corticostriatal connections (Kemp and Powell, 1970), supporting the conclusion that the functions of primary auditory cortex might have limited dependence on the striatum as compared to the belt regions and superior temporal gyrus. The tail of the caudate nucleus and the caudal putamen occupied the most substantial projection zone of the superior temporal cortex, implicating corticostriatal connections in the functionality of these regions, e.g., sound recognition, encoding vocalizations of conspecifics, sensorimotor association, and localization of sound sources. More

recent work has described this “tail of the striatum” as a unique subdivision of dorsal striatum with an integrative role in sensory processing (Valjent and Gangarossa 2021; Cox and Witten 2019).

In contrast to the post mortem tract-tracing methods available in non-human primates and other animal models, investigating human corticostriatal connectivity predominantly necessitate non-invasive approaches, particularly diffusion MRI tractography. Diffusion MRI is sensitive to the motion of water molecules in the brain, which is constrained by white matter and thus allows us to infer the orientation of white matter within each diffusion MRI voxel. We can then traverse from voxel to voxel to estimate pathways of white matter connectivity, an approach known as tractography. While diffusion MRI in general and tractography in particular have made tremendous progress over the past two decades, investigations into human corticostriatal connectivity have been more limited (Ford et al. 2013; Avecillas-Chasin et al. 2016; Marrakchi-Kacem et al. 2013; Calabrese et al. 2022; Zhang et al. 2017; Waugh et al. 2022; Feng et al. 2019). This is in large part due to methodological challenges of non-invasively imaging small brain structures deep within the cranium (such as the basal ganglia), particularly when using conventional 3T MRI. Another consideration is that the rich interconnectedness of striatal subregions provides a challenge to diffusion MRI data with lower spatial and angular resolution, as well as to tractography methods that estimate only a single white matter orientation (such as diffusion tensor imaging, or DTI). Lastly, studies that do touch upon connectivity between superior temporal cortex (where auditory cortex resides) and dorsal striatum tend to focus on specific superior temporal sub-regions (Waugh et al. 2022; Feng et al. 2019), as opposed to fine-grained parcellations of all of superior temporal cortex similar to the

macaque literature (Yeterian and Pandya 1998); striatal segmentations are also typically coarse-grained (although see (Tian et al. 2020) for a recent gradient-based approach to striatal sub-segmentation). Thus, with growing recognition of the importance of corticostriatal connections for human audition (and more broadly, communication)—and their dysfunction in autism (Abrams et al. 2016; Di Martino et al. 2011), developmental language disorders (Krishnan et al. 2016), persistent developmental stuttering (Giraud et al. 2008; Alm 2004; Chang and Zhu 2013), and Parkinson's Disease (Jafari et al. 2020)—we need to better understand the basic connectivity patterns between auditory cortex and dorsal striatum.

In the current study, we overcome the methodological limitations hindering the investigation of human auditory corticostriatal connectivity by using high resolution diffusion MRI tractography to virtually dissect auditory cortical–striatal connections in human participants. In particular, we analyzed one of the highest quality in vivo human datasets publicly available, collected over eighteen hours in a single individual on the diffusion MRI-optimized Siemens Connectom scanner with over 2800 diffusion directions and spatial resolution below 1 mm isotropic. We first mapped connections between subdivisions of auditory cortex in superior temporal cortex with the principal dorsal striatal input regions: caudate and putamen. We considered both tractography endpoints as well as white matter pathways of corticostriatal networks. Based on animal literature (Yeterian and Pandya 1998), we predicted strong tractography connectivity between primary and secondary auditory cortices in posterior superior temporal cortex and caudal striatal subdivisions (posterior putamen and caudate tail), while increasingly associative anterior superior temporal regions would be better connected with rostral striatum (anterior putamen and caudate head). Next, we compared corticostriatal connectivity in the auditory

system with homologous visual corticostriatal connectivity. Previous research in animal models suggests a greater proportion of caudate (vs. putamen) connectivity with visual cortex compared to auditory cortex (Seger 2013; Yeterian and Pandya 1995). Finally, to confirm these auditory corticostriatal findings in a larger dataset, we replicated our auditory corticostriatal analyses in a set of thirteen individuals from the Human Connectome Project with near-millimeter spatial resolution and high angular resolution (128 diffusion directions) collected in a single 7-Tesla MRI session. In total, this work delineates the structural pathways between human auditory cortex and dorsal striatum and suggests a privileged position for putamen in the larger auditory processing network. Over the last two decades, tremendous progress has been made in understanding the functional role of cortical pathways that map learned sounds (e.g., native speech) onto meaning (ventral pathway) and articulation/location (dorsal pathway). We posit that auditory-putamen streams are likely an important substrate underlying behaviorally-relevant auditory learning, and our results here provide a useful starting point for more extensive physiological examination.

Methods

Diffusion MRI data acquisition

We investigated auditory–striatal connectivity in two public diffusion MRI datasets. The first was collected in a single individual (male, approximately 30 years of age) over 18 hours of scanning on the MGH Connectome scanner. This machine has a 3 Tesla (3T) magnetic field but is optimized for diffusion MRI data acquisition, with high maximum gradient strength and slew rate enabling unparalleled diffusion MRI data quality in living human participants (Wang et al. 2021). 2808 volumes of diffusion MRI data were collected at 760 µm isotropic resolution, with

b=0, 1000, and 2500 s/mm^2. This data collection was approved by the Institutional Review Board of Partners Healthcare, and the participant provided written, informed consent. Preprocessed data used in the present study are available from https://brain.labsolver.org/mgh_760.html (courtesy of F.-C. Yeh); data from the original authors are available at https://doi.org/10.5061/dryad.nzs7h44q2 (Wang et al. 2020).

The second dataset is a subset of 13 participants (8 female, 5 male, age range: 22–35 years of age) from the Human Connectome Project (HCP) Young Adult 7T dataset (Vu et al. 2015; Elam et al. 2021). We selected the lowest-numbered subject IDs in the 7T database without consideration of any demographic or other participant information. Data were acquired over approximately 1 hour of scanning at 1.05 mm isotropic resolution with a two-shell diffusion scheme (b=1000 and 2000 s/mm^2) in 64 directions acquired twice at each shell, plus 15 b=0 volumes. Data collection for the HCP WU–Minn Consortium was approved by the institutional review boards of Washington University and the University of Minnesota, and participants provided written, informed consent.

Diffusion MRI processing

Preprocessed data from the sub-millimeter single-subject dataset was reconstructed in MNI space using q-space diffeomorphic reconstruction (QSDR) to obtain the spin distribution function, while the near-millimeter HCP 7T data were reconstructed in subject space with generalized q-sampling imaging (Yeh et al. 2010; Yeh et al. 2021).

We then ran deterministic tractography using auditory cortical and striatal regions of interest (see below) as endpoints, generating 100,000 total tractography streamlines. For tractography,

we defined the termination threshold at quantitative anisotropy = 0.01, angular threshold = 45°, step size = 0.5, minimum streamline length = 5 mm, and maximum streamline length = 300 mm (Yeh et al. 2010; Yeh et al. 2021).

Connectivity analysis

We computed unthresholded connectivity matrices in DSI Studio using the whole brain tractography streamlines and our predefined regions of interest as endpoints (see below). We then plotted connectivity heatmaps using Python's matplotlib and seaborn packages (Hunter 2007; Waskom 2021).

Region of interest segmentation

Striatal and cortical regions of interest were selected to mirror prior work examining region-specific connections between dorsal striatum and auditory cortex in non-human primates (Yeterian and Pandya 1998). We extracted MNI-space subcortical segmentations from FreeSurfer (Dale et al. 1999) using dorsal striatal segmentations of the caudate and putamen.

Cortical segmentations of superior temporal cortex were extracted using the from the Human Connectome Project Multi-Modal Parcellation atlas (Glasser et al. 2016) (Figure 1). The regions were from early auditory cortex: A1, lateral belt (LBelt), medial belt (MBelt), posterior belt (PBelt), and retro-insular area (RI); auditory association cortex: A4, A5, dorsal anterior superior temporal sulcus (STSda), dorsal posterior superior temporal sulcus (STSdp), ventral anterior superior temporal sulcus (STSva), ventral posterior superior temporal sulcus (STSvp), anterior superior temporal gyrus (STGa), and anteromedial planum polare (TA2), and temporal pole

(TGd). We also extracted visual regions of interest (V1, V2, V3, and V4) for a cross-modal comparison.

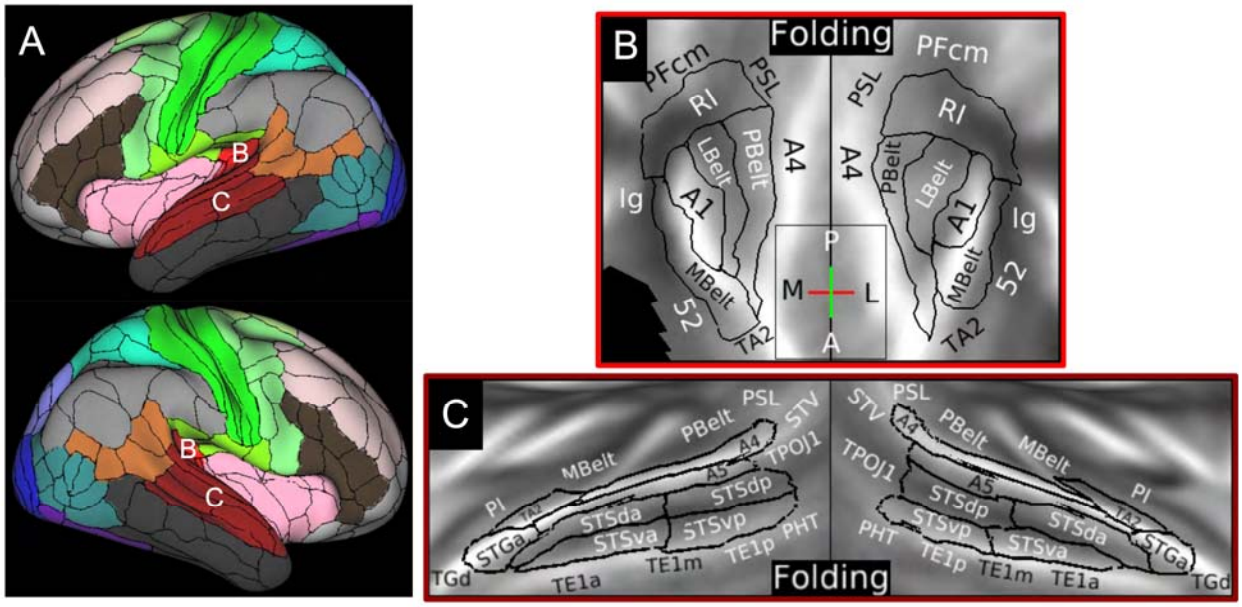

Figure 1. Cortical regions of interest derived from the Human Connectome Project Multi-Modal Parcellation (MMP) atlas (reproduced from the Neuroanatomical Supplementary Results in Glasser et al., 2016). A: cortical surface MMP representation. Auditory and superior temporal regions are denoted as B and C. B: Early auditory cortical regions included in the present analysis. C: associative and higher-order auditory and superior temporal regions included in the present analysis.

Results

Sub-millimeter single subject results

In the single-subject MGH 760 µm dataset, 100,000 streamlines were generated that had endpoints in the auditory cortical and striatal regions of interest (Figure 2). There were significantly more connections between superior temporal cortex and putamen than between superior temporal cortex and caudate (paired t-test: $t = 4.061$, $p = 0.0004$). Caudate was connected most strongly with anterior superior temporal cortex and temporal pole as compared to primary and secondary auditory cortex more posteriorly (Figure 3). Meanwhile,

putamen was broadly connected with regions across superior temporal cortex, from primary auditory cortex regions posteriorly to associative regions more anteriorly. Streamlines to sulcal regions of superior temporal cortex tended to be more minimal than to gyral portions of the cortex. Interhemispheric connections between homologous auditory cortical regions were minimal.

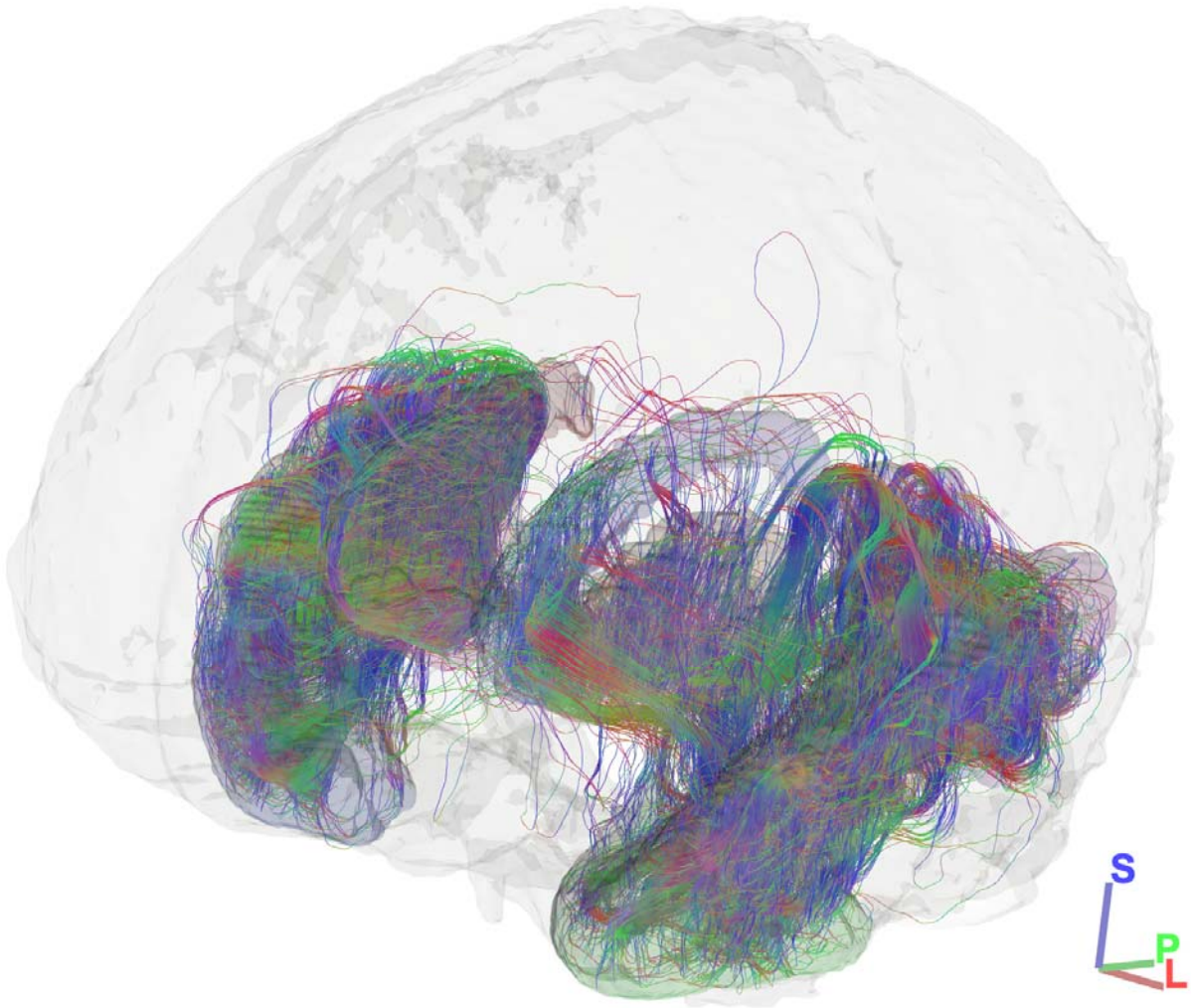

Figure 2. Auditory corticostriatal tractography streamlines in the sub-millimeter single-subject dataset. Streamlines are color-coded by local orientation: Red = left–right; blue = superior–inferior; green = anterior–posterior.

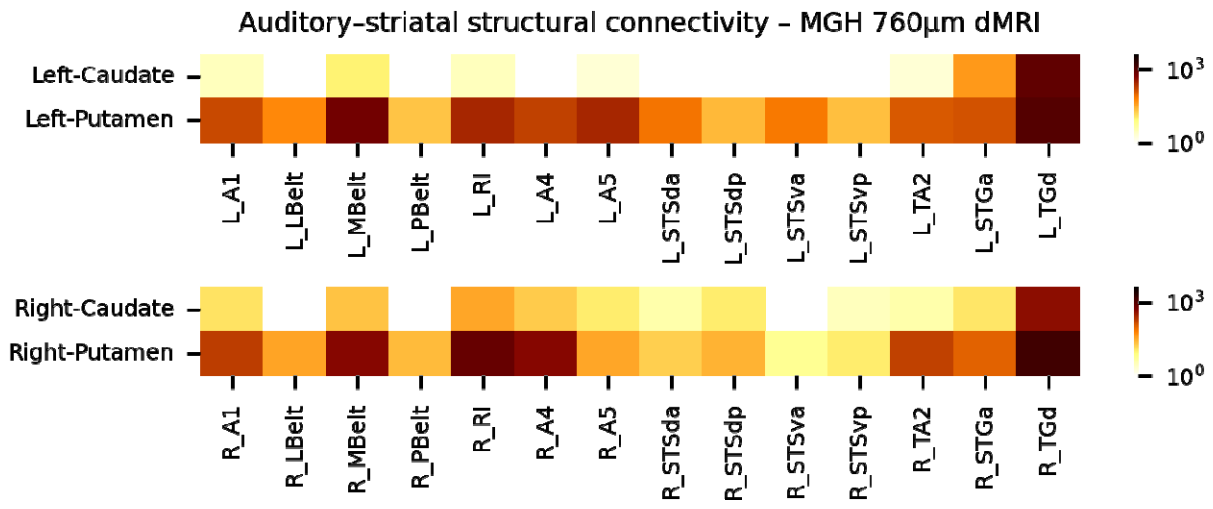

Figure 3. Auditory corticostriatal tractography streamline counts from the sub-millimeter single-subject dataset. Cortical regions (x-axis) are arranged from posterior to anterior. Values are plotted on a log scale.

Striatal termination points of auditory cortical streamlines

We investigated the specific endpoints of auditory corticostriatal streamlines. When looking at striatal terminations, only anterior superior temporal cortex exhibited meaningful connections with caudate head and rostral putamen (Figure 4). The other divisions of superior temporal cortex were strongly connected with caudal putamen but showed limited connectivity with rostral putamen or caudate.

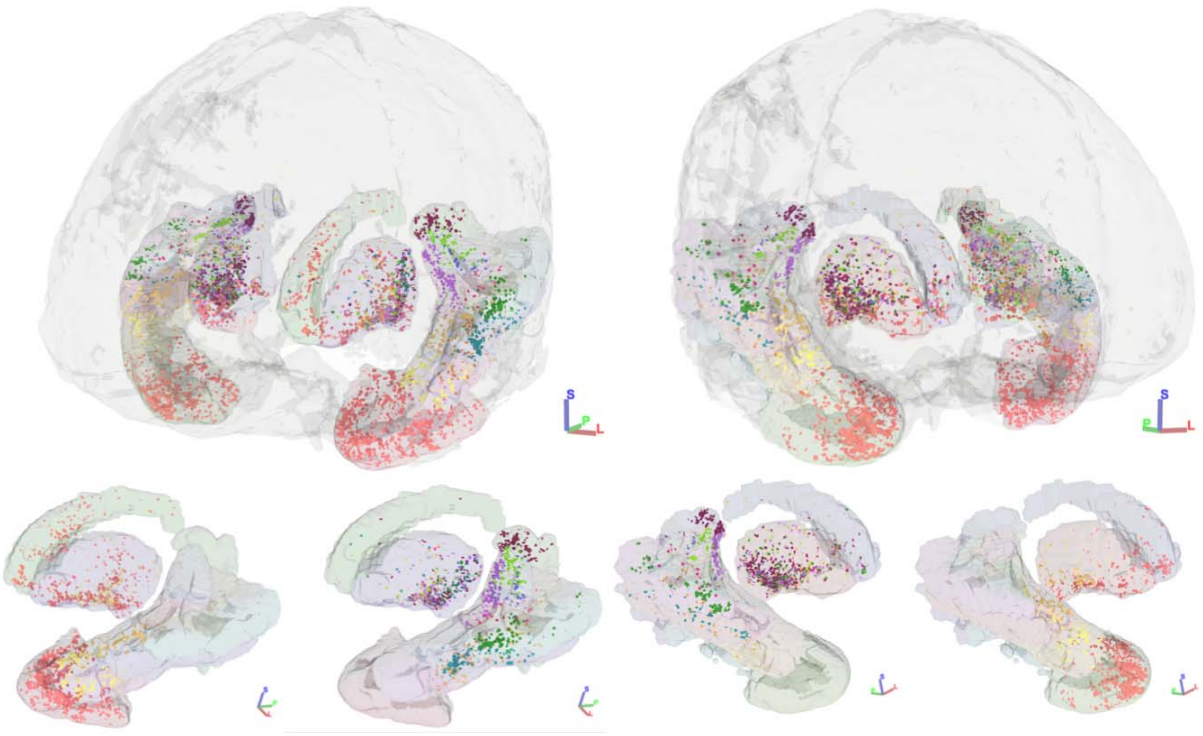

Figure 4. Tractography streamline endpoints in the sub-millimeter single-subject dataset. Endpoints are color-coded by cortical endpoint. Top: all corticostriatal endpoints, angled so that the left hemisphere (top left) and right hemisphere (top right) are visible. Bottom: endpoints from anterior superior temporal cortex and temporal pole (bottom far left and bottom far right) and from posterior and medial superior temporal cortex (bottom second from left and second from right).

Looking more focally at the auditory core and its surrounding structures, we visualized the dorsal striatal endpoints of streamlines that ended specifically in posteromedial superior temporal cortex (Figure 5). Within putamen most streamlines ended in the caudal half, with many of these terminating on the ventral aspect of putamen. Minimal streamlines reached caudate.

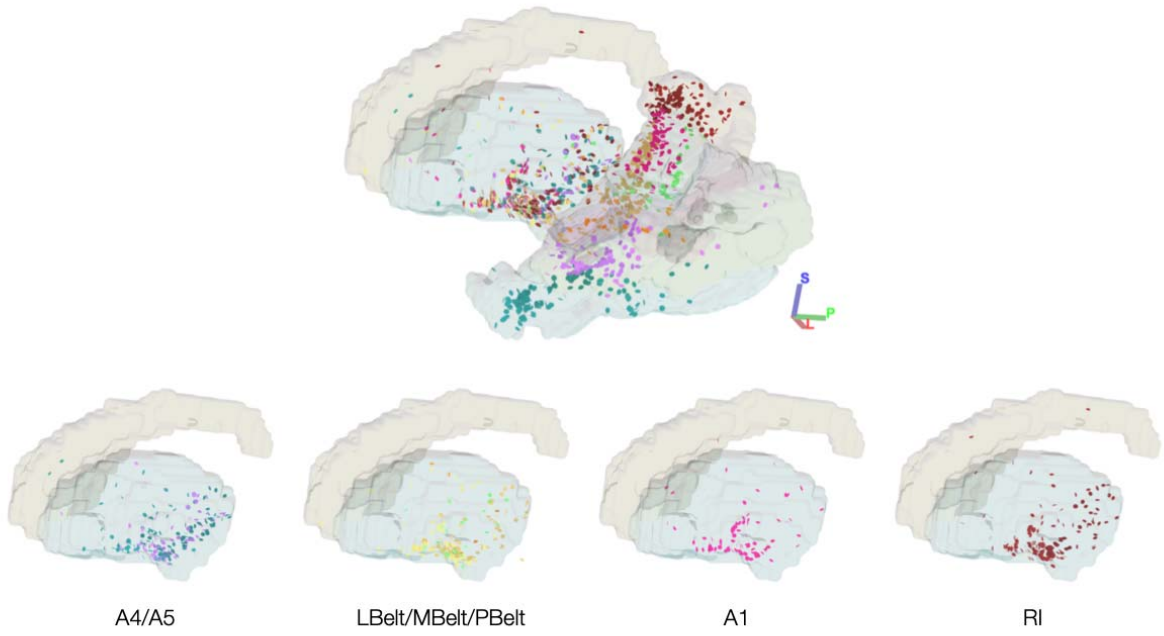

Figure 5. Tractography endpoints between dorsal striatum and posteromedial superior temporal cortex (auditory core and belt) in the sub-millimeter single-subject dataset. Endpoints are color-coded by cortical endpoint (visible in the lower panel).

Anatomical pathways

We next looked at the anatomical trajectory of auditory corticostriatal streamlines in the sub-millimeter single-subject dataset (Figure 6). Caudate connections with auditory cortical regions in superior temporal cortex were primarily through anterior pathways. In contrast, putamen connections were more equally shared between anterior and posterior pathways.

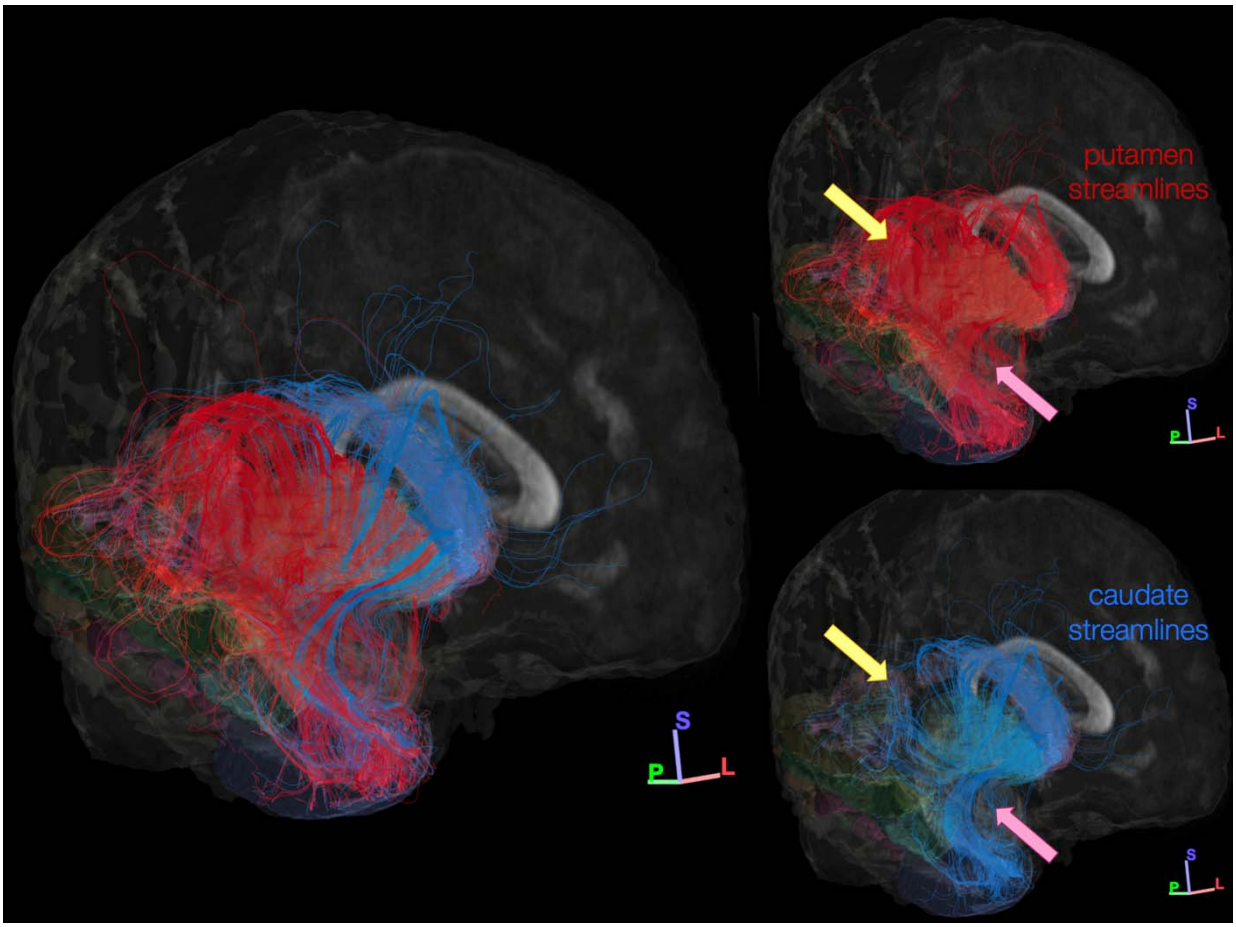

Figure 6. Tractography streamlines ending in right putamen (red) and right caudate (blue) from the sub-millimeter single-subject dataset. Note streamlines passing posteriorly for just putamen streamlines (yellow arrow) and anteriorly for both putamen and caudate streamlines (purple arrow).

Visual corticostriatal results

To assess the similarity of striatal projections across cortical sensory systems, we mapped corticostriatal connectivity in the visual system by generating tractography streamlines between major visual cortical regions and dorsal striatal structures (Figure 7). In comparison to auditory corticostriatal connectivity, visual corticostriatal streamline counts were greatly reduced. Additionally, there were no significant differences between putamen and caudate

visual corticostriatal streamline counts (paired t-test: t = 1.014, p = 0.3444). Visual corticostriatal streamlines reached more mixed striatal endpoints than auditory corticostriatal connections, with left V1–V3 reaching left striatal subdivisions fairly equally, while right V1–V3 had more limited connectivity with right putamen.

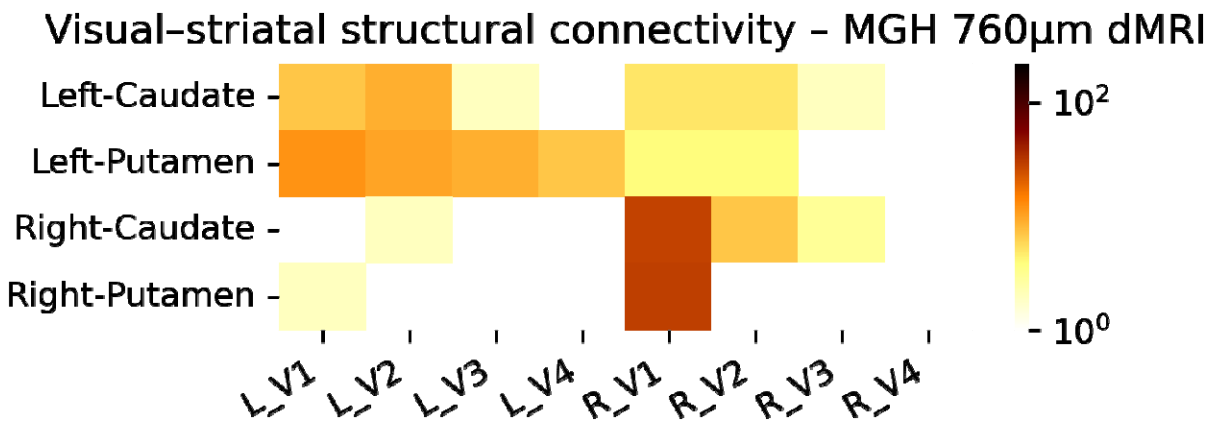

Figure 7. Streamline counts ending in striatal regions of interest and visual cortical regions of interest in the sub-millimeter single-subject dataset. Values are plotted on a log scale.

Near-millimeter group results

Finally, we sought to replicate key findings in a separate high-quality dataset collected with 7T MRI as a part of the Human Connectome Project (HCP). Similar to the sub-millimeter connectivity results, when averaging across the near-millimeter HCP 7T group, auditory corticostriatal connectivity was much denser to putamen than to caudate (Figure 8). Again, superior temporal sulcus was less connected with putamen than other regions of superior temporal cortex.

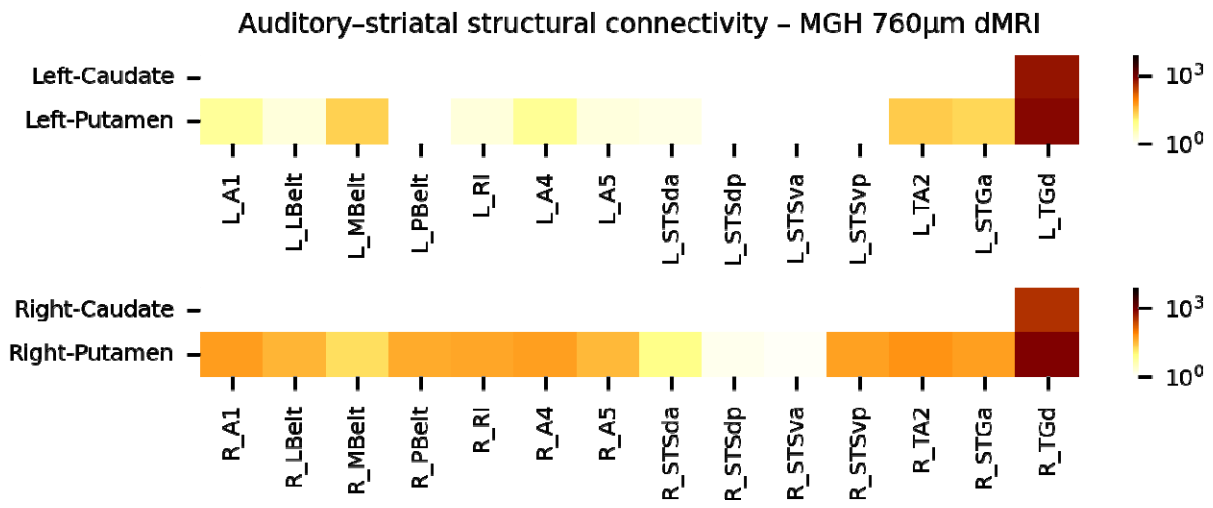

Figure 8. Mean streamline connectivity across 13 participants from the Human Connectome Project 7T dataset. Values are plotted on a log scale.

Across individuals, connectivity patterns were highly consistent (Fig. 9). Connectivity with putamen was higher across superior temporal cortex. Interestingly, right hemisphere streamline counts were higher than left hemisphere counts across individuals.

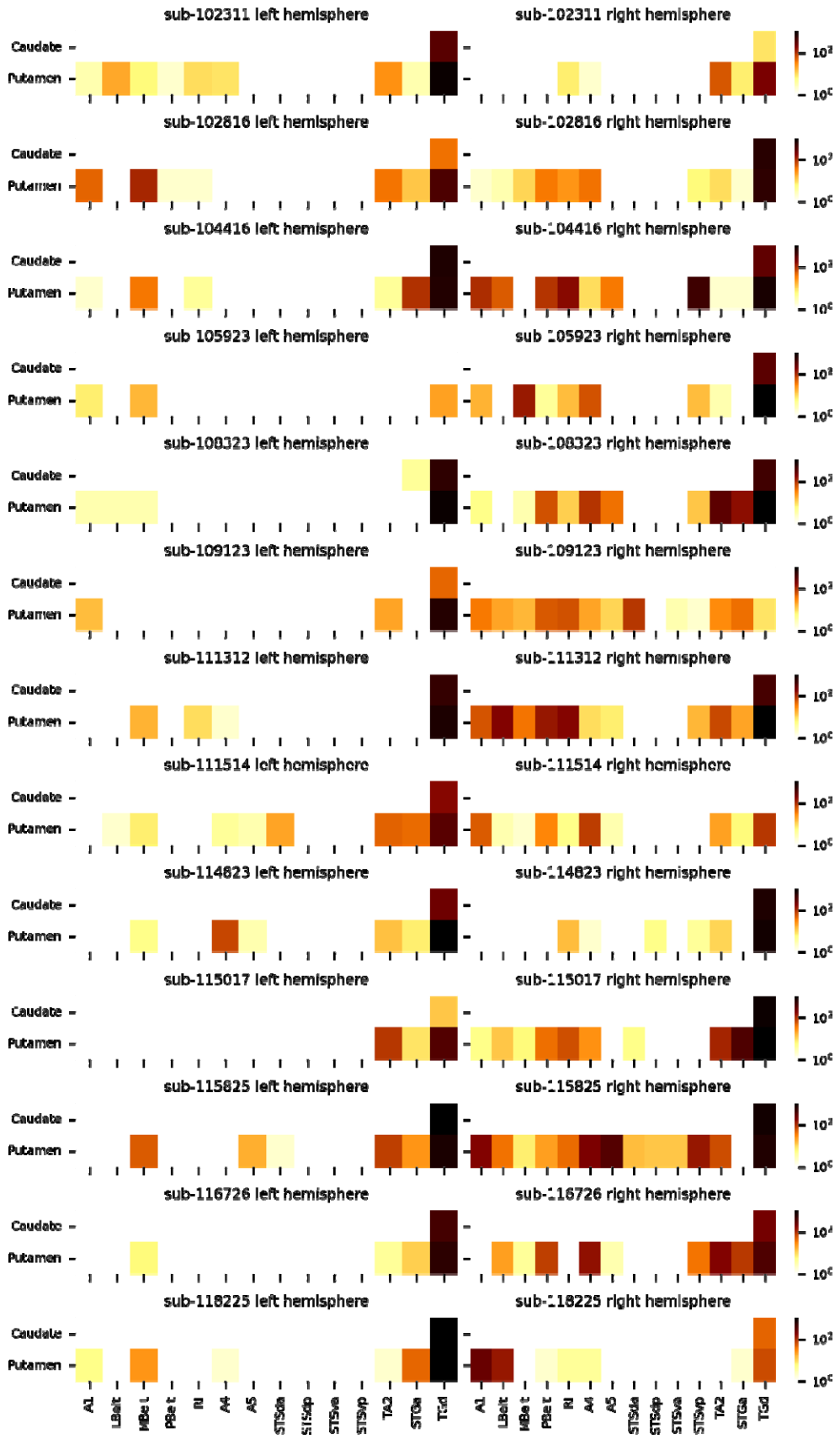
sub-102311 left hemisphere
sub-102311 right hemisphere
sub-102816 left hemisphere
sub-102816 right hemisphere
sub-104416 left hemisphere
sub-104416 right hemisphere
sub-105923 left hemisphere
sub-105923 right hemisphere
sub-108323 left hemisphere
sub-108323 right hemisphere
sub-109123 left hemisphere
sub-109123 right hemisphere
sub-111312 left hemisphere
sub-111312 right hemisphere
sub-111514 left hemisphere
sub-111514 right hemisphere
sub-114823 left hemisphere
sub-114823 right hemisphere
sub-115017 left hemisphere
sub-115017 right hemisphere
sub-115825 left hemisphere
sub-115825 right hemisphere
sub-116726 left hemisphere
sub-116726 right hemisphere
sub-118225 left hemisphere
sub-118225 right hemisphere
Caudate
Putamen
A1
LBelt
MBelt
PBelt
RI
A4
A5
STSda
STSdp
STSva
STSvp
TA2
STGa
TGd

Figure 9. Streamline count heatmaps for each individual included in the near-millimeter Human Connectome Project 7T dataset. Values are plotted on a log scale.

Discussion

Building on animal evidence for the auditory corticostriatal pathway (Yeterian and Pandya 1998; Znamenskiy and Zador 2013), we used high resolution diffusion-weighted MRI tractography to estimate auditory corticostriatal connectivity in living humans. In two distinct high-quality, high-resolution datasets, we found greater connectivity between putamen and superior temporal cortex than between caudate and superior temporal cortex. Further, specific subdivisions of dorsal striatum— putamen and head of the caudate—had divergent connectivity patterns with superior temporal cortex, with caudate head mainly connecting to anterior superior temporal cortex, and posterior auditory cortical regions preferentially connecting to caudal and ventral putamen. Perhaps unsurprisingly, then, most caudate streamlines took an anterior pathway to superior temporal cortex, while putamen streamlines to superior temporal cortex were spread across both anterior and posterior routes. The general medial-lateral organization of corticostriatal topography in the present data reinforce the concept of "functional mosaicism" described by Selemon and Goldman-Rakic (Selemon and Goldman-Rakic 1985). Overall, the consistency of our connectivity findings across hemispheres, datasets, and individuals suggests that high-quality, high-resolution diffusion MRI tractography is sensitive to fine-grained auditory corticostriatal connectivity patterns.

Our assessment of structural connectivity between superior temporal cortex and dorsal striatum closely matches tract tracing results in macaque (Yeterian and Pandya 1998). Generally, our findings reaffirm that striatal connections are more plentiful with auditory association cortical regions as compared to primary auditory cortex. Further, we found that the auditory core and belt regions were more strongly connected with putamen than with caudate. Indeed, while auditory core and belt exhibited streamlines to caudal and ventral putamen in our results, they showed almost no connectivity with caudate. Yeterian and Pandya (Yeterian and Pandya 1998) did observe limited auditory core and belt connections to caudate in macaque, but only to the medial caudate and caudal-most tail, respectively. The tail of the caudate is challenging to segment in human T1-weighted MR images and is largely absent from standard brain atlases, including the FreeSurfer segmentation used in this study (Fischl et al. 2002), which may explain some of the lacking auditory cortical–caudate streamlines. In animal models, the caudal-most "tail of the striatum"—encompassing both the caudate tail and posterior putamen—has been hypothesized as a functionally distinct unit receiving multisensory inputs (Valjent and Gangarossa 2021; Cox and Witten 2019), which aligns with the Yeterian and Pandya results (Yeterian and Pandya 1998) and suggests that finer spatial resolution and more accurate caudate tail segmentation with human MRI could reveal similar tractography connections between the auditory core and tail of the caudate. Meanwhile, Yeterian and Pandya (Yeterian and Pandya 1998) noted some auditory belt connections with caudate body; similarly, in our single-subject sub-millimeter dataset, we found limited but present connections between auditory belt and body of the caudate.

When looking more broadly across superior temporal cortex, Yeterian and Pandya (Yeterian and Pandya 1998) described heavy connections between anterior superior temporal lobe and anterior dorsal striatum (head of the caudate and rostral putamen). We found similar patterns in the single-subject sub-millimeter tractography results—namely from temporal pole and anterior superior temporal gyrus to anterior caudate and putamen. In the macaque, middle and posterior superior temporal cortex exhibited reduced but present caudate connections, which were largely absent in both of our datasets. Thus, while our diffusion MRI tractography estimates of auditory corticostriatal connectivity broadly align with tract-tracing work in non-human primates (Yeterian and Pandya 1998), without the availability of ground-truth connectivity methods in humans, we cannot be certain whether the differences in our results are due to methodological limitations in human diffusion MRI tractography or due to evolutionary distinctions between primate species. Indeed, a recent diffusion MRI tractography comparing human and chimpanzee cortical language networks suggests an expansion of posterior temporal connectivity in humans, while anterior temporal connectivity is similar between species but with some expanded cortical targets such as through the uncinate fasciculus (Sierpowska et al. 2022). It is possible that corticostriatal connectivity would similarly retain core connectivity features over the course of primate evolution while also developing human-specific connections that support human auditory learning and decision-making.

In this work, we mapped structural connectivity between human superior temporal cortex and dorsal striatum using diffusion MRI tractography. While tractography can provide us with estimates of white matter *orientation*, it cannot tell us the *direction* of a given white matter tract. However, previous neuroanatomical investigations into corticostriatal systems in

nonhuman primates provide evidence for closed loops between cerebral cortex and dorsal striatum (Middleton and Strick 2000). While dorsal striatum receives input from across the cortex (Selemon and Goldman-Rakic 1985), in the temporal lobe, only inferotemporal cortex has been established as a recipient of basal ganglia outputs by way of substantia nigra pars reticulata (Middleton and Strick 1996). Thus, diffusion MRI tractography connections between superior temporal cortex and dorsal striatum in the present study are likely to represent corticostriatal white matter pathways as opposed to striatocortical pathways.

While literature in non-human primates and other animal models is highly suggestive of a central role for posterior putamen in auditory processing (Clarey and Irvine 1986; Zhong et al. 2014), in humans, the literature on auditory corticostriatal connectivity is limited. One study that focused on auditory learning using fMRI also estimated auditory corticostriatal using diffusion MRI (Feng, Yi, & Chandrasekaran, 2019). By using functional activation clusters in anterior STG and putamen as probabilistic tractography seeds, the investigators found strong connectivity between the two regions implicated in novel speech sound category learning.

Additionally, auditory corticostriatal connectivity may be affected by disorders that impact communication. With resting state functional MRI approaches, Gordon et al. (Gordon et al. 2021) mapped cortical functional connectivity with striatum, finding a putamen cluster that strongly connects functionally to the cortical language network. Hinkley et al. (Hinkley et al. 2015; Hinkley et al. 2021) similarly used functional connectivity to investigate corticostriatal interactions and found *ventral* striatal connectivity effects in tinnitus participants. A follow up study (Hinkley et al. 2021) found that targeted electrical stimulation of the caudal-most caudate tail provided significant benefits to participants with tinnitus. In children with developmental

stuttering, a disorder with both motor and perceptual deficits, decreased functional and structural connectivity with motor, speech, and auditory cortical regions has been observed (Chang and Zhu 2013). Developmental language disorders and dyslexia may similarly be impacted by abnormal striatal function during auditory behavior (Krishnan et al. 2016). Individuals with autism spectrum disorders exhibit functional underconnectivity between posterior auditory cortical regions and striatal regions, including putamen (Abrams et al. 2013). Parkinson's disease, which is characterized by degradation of dopaminergic neural function in striatum, also results in auditory processing deficits (Jafari et al. 2020). However, despite broad consensus that dorsal striatal dysfunction can contribute to auditory deficits in humans, the precise pathways between auditory cortex and dorsal striatum that underlie such auditory function have, until now, not been clearly delineated.

Across two high quality, high resolution human diffusion MRI datasets, the present results suggest a privileged position for putamen in auditory processing and learning. Indeed, previous functional research in humans identified a key role for putamen in learning new sound categories, whether they be speech or non-speech stimuli (Lim et al. 2014; Yi et al. 2016; Feng et al. 2019; Lim et al. 2019). Despite a lack of ground truth human connectivity and functional mapping, as well as some evidence that macaque and human striatum are not fully homologous (Liu et al. 2021), the non-invasive human imaging literature aligns well with research in animal models. Our own results closely follows tract-tracing work in non-human primates that distinguished anterior from posterior superior temporal connectivity with dorsal striatum (Yeterian and Pandya 1998). Future work will map specific auditory functions within human dorsal striatum, allowing us to probe the relationship between precise auditory corticostriatal

connections and communication-related disorders such as autism spectrum disorders, developmental stuttering, and tinnitus.

Acknowledgements

We thank Fuyixue Wang and coauthors for making their sub-millimeter single-subject diffusion MRI data publicly available, and Fang-Cheng Yeh for releasing the data in DSI Studio. Human Connectome Project data were provided [in part] by the Human Connectome Project, WU-Minn Consortium (Principal Investigators: David Van Essen and Kamil Ugurbil; 1U54MH091657) funded by the 16 NIH Institutes and Centers that support the NIH Blueprint for Neuroscience Research; and by the McDonnell Center for Systems Neuroscience at Washington University.

Bibliography

Abrams, D.A., Chen, T., Odriozola, P., et al. 2016. Neural circuits underlying mother's voice perception predict social communication abilities in children. *Proceedings of the National Academy of Sciences of the United States of America* 113(22), pp. 6295–6300.

Abrams, D.A., Lynch, C.J., Cheng, K.M., et al. 2013. Underconnectivity between voice-selective cortex and reward circuitry in children with autism. *Proceedings of the National Academy of Sciences of the United States of America* 110(29), pp. 12060–12065.

Alm, P.A. 2004. Stuttering and the basal ganglia circuits: a critical review of possible relations. *Journal of Communication Disorders* 37(4), pp. 325–369.

Avecillas-Chasin, J.M., Rascón-Ramírez, F. and Barcia, J.A. 2016. Tractographical model of the cortico-basal ganglia and corticothalamic connections: Improving Our Understanding of Deep Brain Stimulation. *Clinical Anatomy* 29(4), pp. 481–492.

Balsters, J.H., Zerbi, V., Sallet, J., Wenderoth, N. and Mars, R.B. 2020. Primate homologs of mouse cortico-striatal circuits. *eLife* 9.

Brovelli, A., Nazarian, B., Meunier, M. and Boussaoud, D. 2011. Differential roles of caudate nucleus and putamen during instrumental learning. *Neuroimage* 57(4), pp. 1580–1590.

Calabrese, J.R., Goetschius, L.G., Murray, L., et al. 2022. Mapping Frontostriatal White Matter Tracts and their Association with Reward-Related Ventral Striatum Activation in Adolescence. *Brain Research*, p. 147803.

Chandrasekaran, B., Koslov, S.R. and Maddox, W.T. 2014. Toward a dual-learning systems model of speech category learning. *Frontiers in Psychology* 5, p. 825.

Chang, S.-E. and Zhu, D.C. 2013. Neural network connectivity differences in children who stutter. *Brain: A Journal of Neurology* 136(Pt 12), pp. 3709–3726.

Clarey, J.C. and Irvine, D.R. 1986. Auditory response properties of neurons in the claustrum and putamen of the cat. *Experimental Brain Research* 61(2), pp. 432–437.

Cox, J. and Witten, I.B. 2019. Striatal circuits for reward learning and decision-making. *Nature Reviews. Neuroscience* 20(8), pp. 482–494.

Dale, A.M., Fischl, B. and Sereno, M.I. 1999. Cortical surface-based analysis. I. Segmentation and surface reconstruction. *Neuroimage* 9(2), pp. 179–194.

Di Martino, A., Kelly, C., Grzadzinski, R., et al. 2011. Aberrant striatal functional connectivity in children with autism. *Biological Psychiatry* 69(9), pp. 847–856.

Elam, J.S., Glasser, M.F., Harms, M.P., et al. 2021. The Human Connectome Project: A retrospective. *Neuroimage* 244, p. 118543.

Ell, S.W. 2011. Contributions of the putamen to cognitive function.

Feng, G., Gan, Z., Yi, H.G., et al. 2021. Neural dynamics underlying the acquisition of distinct auditory category structures. *Neuroimage* 244, p. 118565.

Feng, G., Yi, H.G. and Chandrasekaran, B. 2019. The role of the human auditory corticostriatal

network in speech learning. *Cerebral Cortex* 29(10), pp. 4077–4089.

Fischl, B., Salat, D.H., Busa, E., et al. 2002. Whole brain segmentation: automated labeling of neuroanatomical structures in the human brain. *Neuron* 33(3), pp. 341–355.

Ford, A.A., Triplett, W., Sudhyadhom, A., et al. 2013. Broca's area and its striatal and thalamic connections: a diffusion-MRI tractography study. *Frontiers in Neuroanatomy* 7, p. 8.

Galaburda, A.M. and Pandya, D.N. 1983. The intrinsic architectonic and connectional organization of the superior temporal region of the rhesus monkey. *The Journal of Comparative Neurology* 221(2), pp. 169–184.

Ghosh, S. and Zador, A.M. 2021. Corticostriatal Plasticity Established by Initial Learning Persists after Behavioral Reversal. *eNeuro* 8(2).

Giraud, A.-L., Neumann, K., Bachoud-Levi, A.-C., et al. 2008. Severity of dysfluency correlates with basal ganglia activity in persistent developmental stuttering. *Brain and Language* 104(2), pp. 190–199.

Glasser, M.F., Coalson, T.S., Robinson, E.C., et al. 2016. A multi-modal parcellation of human cerebral cortex. *Nature* 536(7615), pp. 171–178.

Gordon, E.M., Laumann, T.O., Marek, S., et al. 2021. Individualized functional subnetworks connect human striatum and frontal cortex. *Cerebral Cortex*.

Groenewegen, H.J. 2003. The basal ganglia and motor control. *Neural plasticity* 10(1–2), pp. 107–120.

Hinkley, L.B., Mizuiri, D., Hong, O., Nagarajan, S.S. and Cheung, S.W. 2015. Increased striatal functional connectivity with auditory cortex in tinnitus. *Frontiers in Human Neuroscience* 9, p. 568.

Hinkley, L.B.N., Larson, P.S., Henderson Sabes, J., et al. 2021. Striatal networks for tinnitus treatment targeting. *Human Brain Mapping*.

Hintiryan, H., Foster, N.N., Bowman, I., et al. 2016. The mouse cortico-striatal projectome. *Nature Neuroscience* 19(8), pp. 1100–1114.

Hunnicutt, B.J., Jongbloets, B.C., Birdsong, W.T., Gertz, K.J., Zhong, H. and Mao, T. 2016. A comprehensive excitatory input map of the striatum reveals novel functional organization. *eLife* 5.

Hunter, J.D. 2007. Matplotlib: A 2D Graphics Environment. *Computing in science & engineering* 9(3), pp. 90–95.

Jafari, Z., Kolb, B.E. and Mohajerani, M.H. 2020. Auditory dysfunction in parkinson's disease. *Movement Disorders* 35(4), pp. 537–550.

Krishnan, S., Watkins, K.E. and Bishop, D.V.M. 2016. Neurobiological basis of language learning difficulties. *Trends in Cognitive Sciences* 20(9), pp. 701–714.

Lee, A.M., Tai, L.-H., Zador, A. and Wilbrecht, L. 2015. Between the primate and "reptilian" brain: Rodent models demonstrate the role of corticostriatal circuits in decision making. *Neuroscience* 296, pp. 66–74.

Lim, S.-J., Fiez, J.A. and Holt, L.L. 2014. How may the basal ganglia contribute to auditory

categorization and speech perception? *Frontiers in Neuroscience* 8, p. 230.

Lim, S.-J., Fiez, J.A. and Holt, L.L. 2019. Role of the striatum in incidental learning of sound categories. *Proceedings of the National Academy of Sciences of the United States of America* 116(10), pp. 4671–4680.

Liu, X., Eickhoff, S.B., Caspers, S., et al. 2021. Functional parcellation of human and macaque striatum reveals human-specific connectivity in the dorsal caudate. *Neuroimage* 235, p. 118006.

Marrakchi-Kacem, L., Delmaire, C., Guevara, P., et al. 2013. Mapping cortico-striatal connectivity onto the cortical surface: a new tractography-based approach to study Huntington disease. *Plos One* 8(2), p. e53135.

Middleton, F.A. and Strick, P.L. 2000. Basal ganglia output and cognition: evidence from anatomical, behavioral, and clinical studies. *Brain and Cognition* 42(2), pp. 183–200.

Middleton, F.A. and Strick, P.L. 1996. The temporal lobe is a target of output from the basal ganglia. *Proceedings of the National Academy of Sciences of the United States of America* 93(16), pp. 8683–8687.

Seger, C.A. 2013. The visual corticostriatal loop through the tail of the caudate: circuitry and function. *Frontiers in Systems Neuroscience* 7, p. 104.

Seger, C.A. and Cincotta, C.M. 2005. The roles of the caudate nucleus in human classification learning. *The Journal of Neuroscience* 25(11), pp. 2941–2951.

Selemon, L.D. and Goldman-Rakic, P.S. 1985. Longitudinal topography and interdigitation of corticostriatal projections in the rhesus monkey. *The Journal of Neuroscience* 5(3), pp. 776–794.

Sierpowska, J., Bryant, K.L., Janssen, N., et al. 2022. Comparing human and chimpanzee temporal lobe neuroanatomy reveals modifications to human language hubs beyond the frontotemporal arcuate fasciculus. *Proceedings of the National Academy of Sciences of the United States of America* 119(28), p. e2118295119.

Tian, Y., Margulies, D.S., Breakspear, M. and Zalesky, A. 2020. Topographic organization of the human subcortex unveiled with functional connectivity gradients. *Nature Neuroscience*.

Ullman, M.T. 2001. A neurocognitive perspective on language: the declarative/procedural model. *Nature Reviews. Neuroscience* 2(10), pp. 717–726.

Valjent, E. and Gangarossa, G. 2021. The tail of the striatum: from anatomy to connectivity and function. *Trends in Neurosciences* 44(3), pp. 203–214.

Vu, A.T., Auerbach, E., Lenglet, C., et al. 2015. High resolution whole brain diffusion imaging at 7T for the Human Connectome Project. *Neuroimage* 122, pp. 318–331.

Wang, F., Dong, Z., Tian, Q., et al. 2020. Data from: In vivo human whole-brain Connectom diffusion MRI dataset at 760 µm isotropic resolution (PART I). *Dryad*.

Wang, F., Dong, Z., Tian, Q., et al. 2021. In vivo human whole-brain Connectom diffusion MRI dataset at 760 µm isotropic resolution. *Scientific data* 8(1), p. 122.

Waskom, M. 2021. seaborn: statistical data visualization. *The Journal of Open Source Software* 6(60), p. 3021.

Waugh, J.L., Hassan, A., Kuster, J.K., et al. 2022. An MRI method for parcellating the human

striatum into matrix and striosome compartments in vivo. *Neuroimage* 246, p. 118714.

Xiong, Q., Znamenskiy, P. and Zador, A.M. 2015. Selective corticostriatal plasticity during acquisition of an auditory discrimination task. *Nature* 521(7552), pp. 348–351.

Yeh, F.-C., Irimia, A., Bastos, D.C. de A. and Golby, A.J. 2021. Tractography methods and findings in brain tumors and traumatic brain injury. *Neuroimage*, p. 118651.

Yeh, F.-C., Wedeen, V.J. and Tseng, W.-Y.I. 2010. Generalized q-sampling imaging. *IEEE transactions on medical imaging* 29(9), pp. 1626–1635.

Yeterian, E.H. and Pandya, D.N. 1995. Corticostriatal connections of extrastriate visual areas in rhesus monkeys. *The Journal of Comparative Neurology* 352(3), pp. 436–457.

Yeterian, E.H. and Pandya, D.N. 1998. Corticostriatal connections of the superior temporal region in rhesus monkeys. *The Journal of Comparative Neurology* 399(3), pp. 384–402.

Yeterian, E.H. and Van Hoesen, G.W. 1978. Cortico-striate projections in the rhesus monkey: the organization of certain cortico-caudate connections. *Brain Research* 139(1), pp. 43–63.

Yi, H.-G., Maddox, W.T., Mumford, J.A. and Chandrasekaran, B. 2016. The role of corticostriatal systems in speech category learning. *Cerebral Cortex* 26(4), pp. 1409–1420.

Zatorre, R.J. and Salimpoor, V.N. 2013. From perception to pleasure: music and its neural substrates. *Proceedings of the National Academy of Sciences of the United States of America* 110 Suppl 2, pp. 10430–10437.

Zhang, Y., Larcher, K.M.-H., Misic, B. and Dagher, A. 2017. Anatomical and functional organization of the human substantia nigra and its connections. *eLife* 6.

Zhong, R., Qin, L. and Sato, Y. 2014. Auditory response properties of neurons in the putamen and globus pallidus of awake cats. *Journal of Neurophysiology* 111(10), pp. 2124–2137.

Znamenskiy, P. and Zador, A.M. 2013. Corticostriatal neurons in auditory cortex drive decisions during auditory discrimination. *Nature* 497(7450), pp. 482–485.