Degenerative changes are associated with severity of anterior cruciate ligament injury within the skeletally immature joint

Danielle Howe[1,2], Jacob D. Thompson[1,2], Stephanie D. Teeter[1], Olivia Barlow[3], Emily H. Griffith[4], Lauren V. Schnabel[2,5], Jeffrey T. Spang[6], Matthew B. Fisher[1,2,6*]

Affiliations:

[1]Joint Department of Biomedical Engineering, North Carolina State University and the University of North Carolina at Chapel Hill; Raleigh, NC, 27695, USA

[2]Comparative Medicine Institute, North Carolina State University; Raleigh, NC, 27607, USA

[3]Department of Mechanical Engineering, North Carolina State University; Raleigh, NC, 27607, USA

[4]Department of Statistics, North Carolina State University; Raleigh, NC 27695

[5]Department of Clinical Sciences, North Carolina State University; Raleigh, NC, 27695, USA

[6]Department of Orthopaedics, University of North Carolina at Chapel Hill; Chapel Hill, NC, 27599, USA

*Corresponding author. Email: mbfisher@ncsu.edu

Abstract

Pediatric anterior cruciate ligament (ACL) injuries are a major problem in the pediatric and adolescent populations. Approximately one-quarter of these injuries only extend through only part of the tissue cross-section. Yet, there is very limited data to inform clinical treatments for pediatric partial ACL tears. In particular, understanding how injury severity impacts long-term degenerative changes in the joint is unknown. In this study, we leverage a skeletally immature preclinical porcine model to evaluate joint biomechanics, tissue remodeling, and degeneration after partial (isolated anteromedial (AM) or posterolateral (PL) bundle) or complete (full thickness) ACL injury. Six months after injury, joint laxity increases were minimal for PL bundle injury, minor for AM bundle injury, and major for ACL injury. In both partial injury cases, the remaining bundle remodeled through an increase in CSA to attempt to restore ACL function and stabilize the knee joint. Joint degeneration (evaluated by cartilage T1 relaxation, macroscopic cartilage degeneration, and meniscal hypertrophy) was minimal after PL bundle injury, moderate after AM bundle injury, and substantial after ACL injury. Further analysis with subjects grouped by Lachman grade (indicating the extent of joint destabilization) indicated that degeneration was associated with the extent of biomechanical destabilization, irrespective of the injury type. These findings point to the importance of considering the results of joint laxity exams when creating treatment plans for young patients with significant growth remaining, particularly those with partial ACL injuries.

INTRODUCTION

Injuries to the anterior cruciate ligament (ACL) of the knee, particularly those occurring in children and adolescents, are a significant clinical and societal concern (*1*). While the total number of ACL injuries is substantial (200,000-250,000 yearly in the United States alone) (*2, 3*), a specific concern is the 2-4 times increase in the rate of injury and subsequent surgical treatment in the pediatric population compared to adults (*4-6*). In the pediatric population, full-thickness ACL tears result in two-fold increases in knee laxity (*7*) and 3-4 times greater risk of developing meniscal and cartilage lesions with delayed intervention (*8*). As a result, surgical reconstruction is the standard practice to restore joint stability for young, active patients with complete ACL tears (*9*), despite some concern over growth plate disruption. However, for partial-thickness ACL tears, which account for approximately 25% of diagnosed ACL injuries (*10*) and result in a more minor (~30% on average) increase in knee laxity (*11*), the choice of operative or non-operative treatment is less evidence-based. The current lack of data on partial ACL injuries in the pediatric population may lead to unnecessary surgeries, which can exacerbate degenerative changes (*12*), or non-surgical treatment in cases where surgery is actually needed to limit degenerative changes (*13*). Preventing degeneration is a major concern. Subsequent meniscal and chondral pathologies after non-surgical treatment of partial tears are reported in young patients, with a similar incidence compared to reports in patients with full thickness tears after ACL reconstruction (*14*). Moreover, approximately 50% of young patients who undergo ACL reconstruction develop osteoarthritis after 10 years (*15*), leaving a growing population of patients aged 20-30 years decades away from eligibility for a knee replacement with few treatment options.

A major complicating factor in determining the best clinical treatment is that not all partial tears and not all patients are the same. The ACL has two major subregions, the

anteromedial (AM) bundle and the posterolateral (PL) bundle, and partial tears can occur in either. Tear location may impact functional outcomes after partial injury, and the results may differ between children and adults. Specifically, a study in adult patients reported similar joint stability after isolated AM and PL bundle injuries (*11*), while a study in pediatric patients reported better outcomes for AM bundle injuries (*16*). Furthermore, the biomechanical function of the AM and PL bundles of the ACL depends on age and sex in a skeletally immature pig model, such that the AM bundle plays a larger functional role in older versus younger subjects and males compared to females (*17, 18*). Since evidence regarding treatment of bundle-specific partial injuries in children and adolescents is sparse, there is a need for further investigation of long-term outcomes and degenerative changes in skeletally immature subjects. Large exploratory studies are challenging to perform in the pediatric patient population. However, the pig is a valuable preclinical model with similar ACL anatomy and function to humans (*19-21*), which can be used to control injury severity and assess functional outcomes and degenerative changes after injury.

In the present study, we investigated biomechanics, remodeling, and degeneration in the knee joint after isolated AM bundle, PL bundle, and complete ACL tears in a juvenile porcine model. We hypothesized firstly that partial (AM and PL bundle) tears would result in small levels of instability and degeneration, which would be more minor compared to complete ACL tears. Secondly, we hypothesized that remaining soft tissues in the joint would remodel in response to changes in biomechanical loading after ACL injury, corresponding to the injury severity. At 6 months after injury, joint laxity showed no change after PL bundle injury, minor increases after AM bundle injury and major increases after ACL injury. Similarly, PL bundle injury resulted in minimal degeneration, AM bundle injury resulted in moderate degeneration,

and complete ACL injury led to substantial degeneration, where the change in laxity was associated with degree of degenerative changes.

RESULTS

Joint kinematics after partial and complete ACL Injury

To evaluate the impact of AM and PL bundle tears on knee function and degeneration in skeletally immature subjects, we performed arthroscopic transection and removal of the AM bundle (AM-), PL bundle (PL-) or ACL (ACL-) in juvenile Yorkshire crossbreed pigs, and assessed biomechanics and joint health after 24 weeks (Fig. 1A). A sham operation was performed in contralateral joints. Joint kinematics were evaluated using a robotic testing system first under applied anterior-posterior (AP) drawer to simulate clinical exams (Fig. 1B). Force-translation curves from PL- joints were nearly indistinguishable from sham-operated controls, while curves from AM- joints extended further in the anterior direction, and ACL- joints extended far beyond the others (Fig. 1C). AP tibial translation (APTT) was greater in AM- joints (46%, $P<0.0001$) and ACL- joints (195%, $P<0.0001$) compared to contralateral controls, while PL- joints showed no significant difference ($P=0.22$) (Fig. 1D). Between injury groups, the inter-limb difference in APTT was significantly different ($P\leq0.0061$ for all comparisons), with largest values for ACL- joints and smallest values for PL- joints. Under applied compression (Fig. 1F-I) (to simulate weight bearing) and varus-valgus moments (Fig. 1J-M) (to simulate rotational loads), differences between force-translation curves for PL- and AM- joints are less striking, but curves for ACL- joints remain distinct. Under compression, anterior tibial translation (ATT) was only greater in ACL- joints compared to contralateral controls (327%, $P=0.0005$) (Fig. 1H), and the interlimb difference in ATT was greater for the ACL- group compared to AM- and PL-

groups (P<0.0001 for each) (Fig. 1I). Likewise, varus-valgus (VV) rotation was greater in ACL-joints compared to contralateral controls (33%, P=0.012) (Fig. 1L), with a larger interlimb difference compared to AM- and PL- groups (P≤0.0037) (Fig. 1M). Sex did not significantly affect kinematics under AP or VV loads, but under compression, ATT was significantly greater in males than females within the AM- group (P=0.003) (Fig. S1). Overall, PL bundle injury induced minimal joint instability, AM bundle injury induced moderate joint instability, and complete ACL injury induced major joint instability.

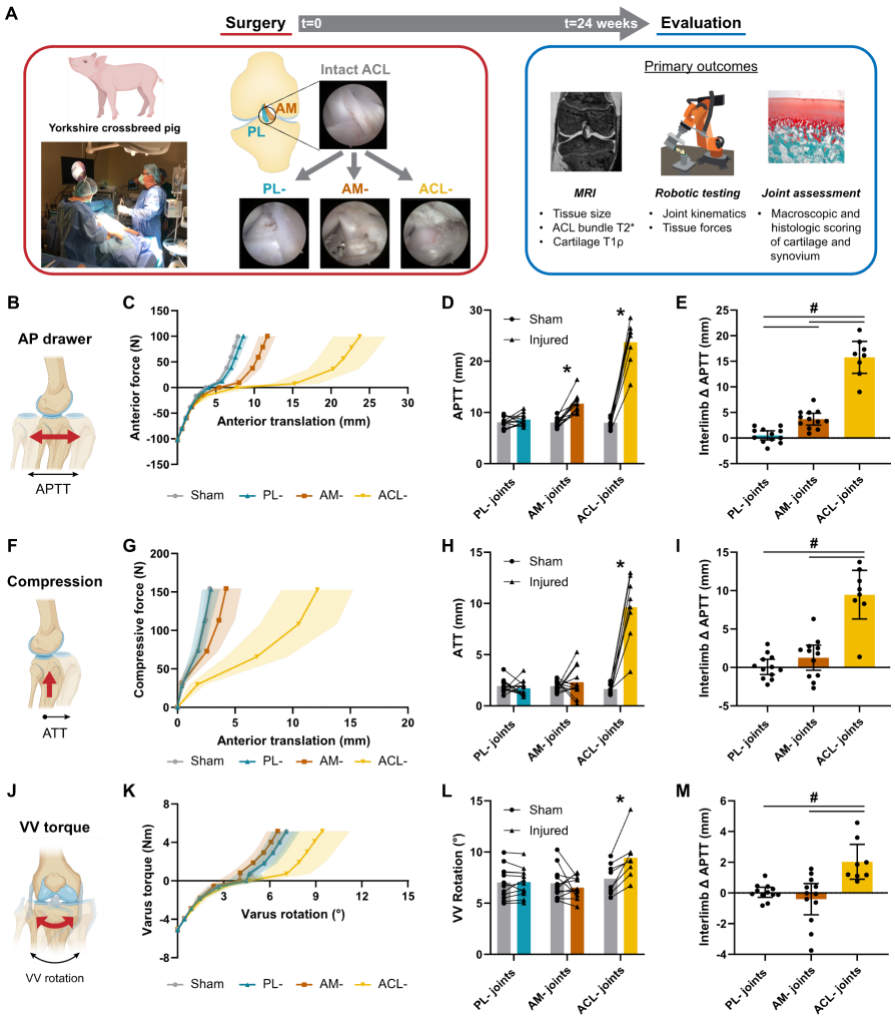

Fig. 1. Biomechanical assessment of porcine joints 6 months after partial and complete ACL transection. (A) Schematic of arthroscopic transection of the AM bundle, PL bundle, or

entire ACL, followed by evaluation after 24 weeks. (B) Diagram of anterior-posterior (AP) loads applied to the tibia. (C) Resulting mean force-translation curves. AP tibial translation (APTT) shown as (D) absolute values and (E) interlimb differences. (F) Diagrams of compressive load applied to the tibia. (G) Resulting mean force-translation curves. Anterior tibial translation (ATT) shown as (H) absolute values and (I) interlimb differences. (J) Diagram of varus-valgus (VV) moments applied to the tibia. (K) Resulting mean torque-rotation curves. VV rotation shown as (L) absolute values and (M) interlimb differences. Red arrows indicate the direction of the applied load, and black arrows indicate the direction of measured translation (B, F, J). Shaded area represents 95% CI (C, G, K). Lines connect paired joints (D, H, L). * $P<0.05$ between injured and contralateral, from paired t-test with Holm-Sidak correction. #$P<0.05$ between injury type, from one-way ANOVA with Tukey post hoc test. Individual data points (n=12 for PL- and AM- groups, n=8 for ACL- group) presented with mean ± 95% CI.

Remodeling of the uninjured bundle of the ACL

In partial injury (AM- and PL-) joints, the in-situ force (Fig. 2A) carried by the remaining ACL bundle was greater compared to the corresponding bundle force in contralateral controls under applied anterior drawer ($P\leq0.00019$ for both injury types) (Fig. 2B). However, under joint compression, the remaining bundle force was elevated only for AM- joints ($P=0.0016$) (Fig. 2C). Remaining bundle in-situ force did not differ under varus or valgus moments (Fig. S2). This biomechanical data indicates that functional loss of the AM bundle caused altered loading under more scenarios than the PL bundle. To assess structural remodeling of the ACL driving functional changes, the cross-sectional area (CSA), measured from MRI, of the remaining bundle in injured joints was compared to contralateral controls (Fig. 2D). The remaining bundle was

larger in CSA compared to contralateral controls for PL- joints by 13% and AM- joints by 60% ($P \leq 0.022$, for both) (Fig. 2E). In addition, bundle collagen organization was assessed through T2* mapping using MRI (Fig. 2F), and no differences were found in median T2* value of the remaining bundle in injured joints compared to the corresponding bundle in contralateral joints for either injury group (Fig. 2G). These data indicate that after partial ACL injury, the remaining bundle adjusted to loss of function of the injured bundle by increasing in functional load contribution and CSA while maintaining tissue quality (inferred from T2* values) compared to contralateral controls.

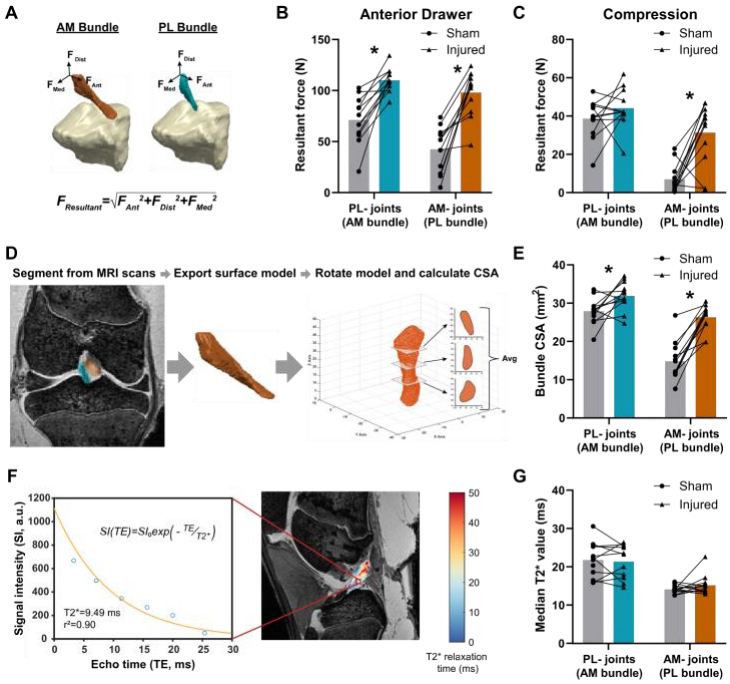

Fig. 2. Remodeling of the remaining bundle after transection of the AM or PL bundle of the ACL. (A) In-situ bundle forces measured under applied loads. Resultant force in the uninjured bundle under applied (B) anterior drawer and (C) compression. (D) Schematic demonstrating methods used to measure bundle cross-sectional area (CSA) from segmented MRI scans. (E) CSA of the uninjured bundle. (F) Schematic showing representative sagittal MR image overlaid with the T2* map of the ACL. Plot shows signal intensity at the six measured echo times (blue

circles) and fitted monoexponential decay curve (yellow) for a representative voxel. Calculated T2* relaxation time and goodness-of-fit (r^2) shown in graph. (G) Median T2* value of the uninjured bundle. Lines connect paired joints. *P<0.05 between injured and contralateral, from paired t-test with Holm-Sidak correction. Individual data points (n=12 per injury group) presented with mean.

Cartilage and Synovium Degeneration

To assess if the type of injury impacted degeneration of articular cartilage in the joint, T1ρ mapping was performed via MRI, and the median T1ρ value was calculated for the medial and lateral femoral and tibial articular cartilage (Fig. 3A). Higher T1ρ values are linked to lower proteoglycan content (*22, 23*). T1ρ values relative to the contralateral control were not significantly elevated in any compartment for the PL- group, but were elevated in the medial femoral and lateral tibial compartments for the AM- group and the lateral femoral and lateral tibial compartments for the ACL- group (P≤0.022 for all, Fig. 3B-E). Furthermore, the interlimb difference in T1ρ values were significantly greater in the AM- group relative to the PL- group for the medial femoral compartment and in the ACL- group relative to the PL- group for the lateral femoral and lateral tibial compartments (P≤0.012 for all). Macroscopic articular cartilage damage was scored from 0 to 4 according to Osteoarthritis Research Society International (OARSI) guidelines (*24*) for the four compartments (Fig. 3F, Fig. S3) and summed for a composite joint score. The composite joint scores were significantly elevated compared to contralateral controls for only the ACL- group (P=0.016 Fig. 3G). Synovium pathology was similarly evaluated through macroscopic scoring, though no significant differences were found in synovium scores between groups (Fig. 3H). Overall, minimal cartilage degradation was observed

in PL- joints, similar increases in cartilage T1ρ values (an early indicator of cartilage degradation) were observed in AM- and ACL- joints, however macroscopic cartilage degeneration was elevated only in ACL- joints.

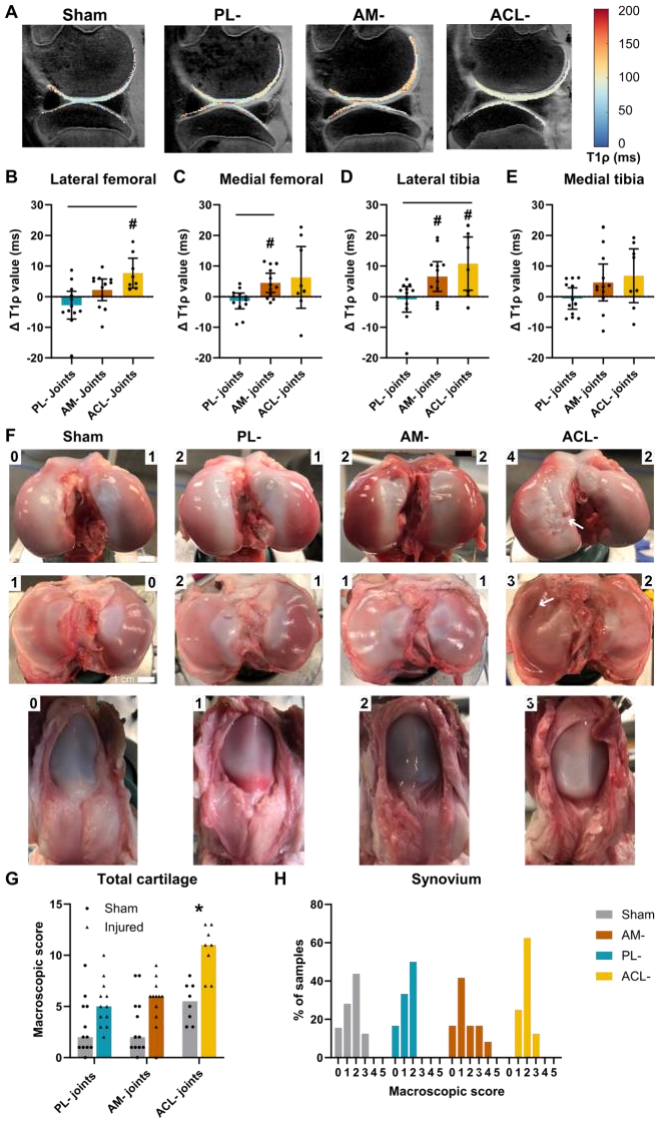

Fig. 3. Cartilage degeneration and synovium inflammation. (A) Representative sagittal MR images overlayed with T1ρ maps of articular cartilage. Interlimb differences in T1ρ value for (B) lateral femoral, (C) medial femoral, (D) lateral tibial, and (E) medial tibial articular cartilage. #P<0.05 compared to 0 from one sample t-test; bars indicate P<0.05 between injury type, from one-way ANOVA with Tukey post hoc test or Welch ANOVA with Dunnett post hoc test for

data sets with unequal variance. (F) Representative images of articular cartilage and synovium, with macroscopic scores shown in the corner of each image. White arrows indicate cartilage erosions to subchondral bone. (G) Composite macroscopic OARSI scores summed from the four articular cartilage compartments. *P<0.05 compared contralateral controls from Wilcoxon matched-pairs test. (H) Histogram of macroscopic OARSI scores for synovium, presented as a percent of samples for each group. Individual data points (n=12 for PL- and AM- groups, n=8 for ACL- group) presented with mean ± 95% CI (B-E) or median ± IQR (G).

Meniscus and collateral ligaments

The biomechanical effect of injury on the menisci and collateral ligaments of the knee joint was assessed by measuring the in-situ load carried by each tissue under the applied loading conditions. The load carried in the medial meniscus under applied anterior drawer was 33% greater for AM- joints and 3.7-fold greater for ACL- joints compared to contralateral joints ($P \leq 0.029$ for each) (Fig. 4A), while no significant differences were measured under applied compression (Fig. 4B). The load carried in the lateral meniscus was greater compared to contralateral joints for AM- joints under applied anterior drawer (by 2.7-fold, P=0.025, Fig. 4C) and for ACL- joints under applied compression (by 2.1-fold, P=0.045, Fig. 4D). No differences in meniscal loads were measured in PL- joints. Next, the volume of the menisci were measured from MRI (Fig. 4D) and compared between injured and control joints. The medial and lateral menisci were 11% and 7% larger in AM- joints and 28% and 30% larger in ACL- joints, respectively ($P \leq 0.048$ for all, Fig. 4F-G).No differences in meniscal size were measured in PL- joints. However, for ACL- joints, in addition to the measurable increases in size, the menisci qualitatively developed an oblique shape, and medial menisci developed an unorganized fibrous

posterior outgrowth, evident macroscopically and on MRI (Fig. S4). Overall, both in-situ loading and volume of the menisci showed no change in PL- joints, moderate increases in AM- joints, and substantial increases in ACL- joints.

In the medial and lateral collateral ligaments, the in-situ load under applied anterior drawer was greater compared to contralateral controls for only ACL- joints (79N vs. 2.5N for MCL and 11.7N vs. 1.1N for LCL on average for the ACL- and contralateral joints, respectively), indicating that the collateral ligaments play a large role in stabilizing the knee after complete ACL injury ($P \leq 0.0080$, Fig. S5A and B). The CSA of the MCL only was significantly larger compared to contralateral controls in ACL- joints ($P=0.048$, Fig. S5C and D). Therefore, the collateral ligaments greater loads and remodeled by increasing in CSA in ACL- joints but not AM- or PL- joints.

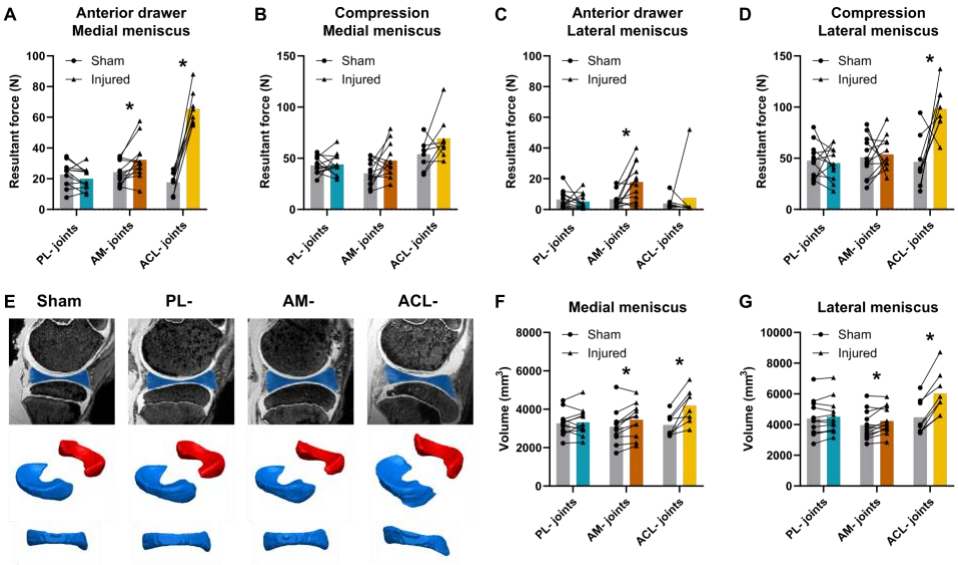

Fig. 4. Changes in meniscal loading and size after partial and complete ACL transection. In-situ forces in the medial meniscus under applied (A) anterior drawer and (B) axial compression. In-situ forces in the lateral meniscus under applied (C) anterior drawer and (D) axial compression. (E) Representative 3D models of menisci from each injury group, generated

from MRI scans. Medial menisci shown in blue, lateral menisci in red. Volume of the (F) medial meniscus and (G) lateral meniscus. Lines connect paired joints. *P<0.05 between injured and contralateral, from paired t-test with Holm-Sidak correction. Individual data points (n=12 for PL- and AM- groups, n=8 for ACL- group) presented with mean.

Extension to adolescent animals

To investigate whether findings were similar for partial injuries in different ages during skeletal growth, AM and PL bundle injuries were created in a small subset of adolescent (6-month-old) pigs. Joint biomechanics, cartilage health, and meniscus volume were evaluated after 24 weeks. Interlimb differences in joint laxity were similarly elevated for AM- joints under AP drawer (P<0.05) in the adolescent injury group compared to the juvenile injury group, with no significant difference in laxity for the PL- group (Fig. 5A, Fig. S6A). Laxity results were also similar between the two age groups under applied axial compression and varus-valgus torque (Fig. S6B and C). Cartilage T1ρ values appeared similarly elevated in femoral compartments of AM- joints but not PL- joints, though significance was not reached (Fig. 5B and Fig. S6G-J). Median composite macroscopic cartilage scores of injured joints trended higher in the adolescent group, compared to the juvenile group, though differences were insignificant (Fig. 5C, Fig. S6F). Lastly, the interlimb differences in medial and lateral meniscus volume were elevated, but insignificant in the adolescent age group, with similar means between AM- and PL- groups (Fig. 5D and E, Fig. S6D and E).

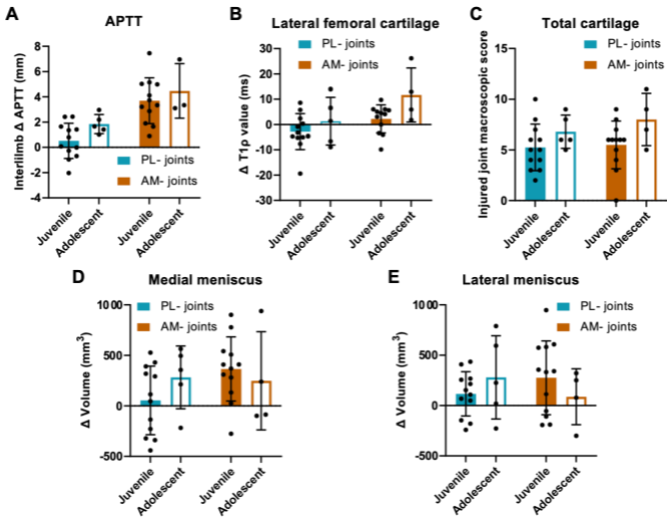

Fig. 5. Joint laxity and cartilage T1ρ data for partial injuries created in adolescent (6-month) compared to juvenile (3-month) pigs. (A) Interlimb differences in APTT under applied AP drawer. (B) Interlimb differences in T1ρ value for lateral femoral articular cartilage. (C) Interlimb differences in macroscopic cartilage. Interlimb difference in volume of the (D) medial and (E) lateral meniscus. Individual data points (n=5 for PL- and n=4 for AM- adolescent groups, n=12 for PL- and AM- juvenile groups) presented with mean ± 95% CI.

Clinical Implications and Associations

To place the observed degenerative outcomes in a clinically relevant framework, specimens were grouped by equivalent Lachman test grade (Fig. 6A-D), which is a common clinical exam to assess joint stability after ACL injury. Generally, mean side-side differences in cartilage T1ρ values (P=0.0058), macroscopic cartilage scores (P=0.16), and medial (P=0.0003) and lateral (P<0.0001) meniscus volume increased progressively for increasing Lachman test grades. Significant interlimb differences were measured for cartilage T1ρ and macroscopic scores only for specimens with Lachman test grade D (P≤0.0086, each), but significant increases in medial and lateral meniscus volume were measured for specimens with grade B as well as

grade D (P≤0.012 for each). Linear regressions were performed to investigate associations between joint stability and degeneration in a continuous manner. Interlimb differences in joint laxity were significantly associated with interlimb differences in cartilage T1ρ values, macroscopic cartilage scores, and meniscal volume across all injury types (r^2=0.11-0.79, P≤0.035 each) (Fig. S7, Fig. S8). Within injury type, significant associations were measured for the AM- group (Figs. 8E-G, Fig. S8), specifically for macroscopic cartilage score (r^2=0.37, P=0.036) and medial meniscus volume (r^2=0.45, P=0.016). Such associations were not observed for either the PL- or ACL- groups. These findings indicate that Lachman test results may be predictive of the extent of joint degradation, where greater joint destabilization is predictive of greater degradation.

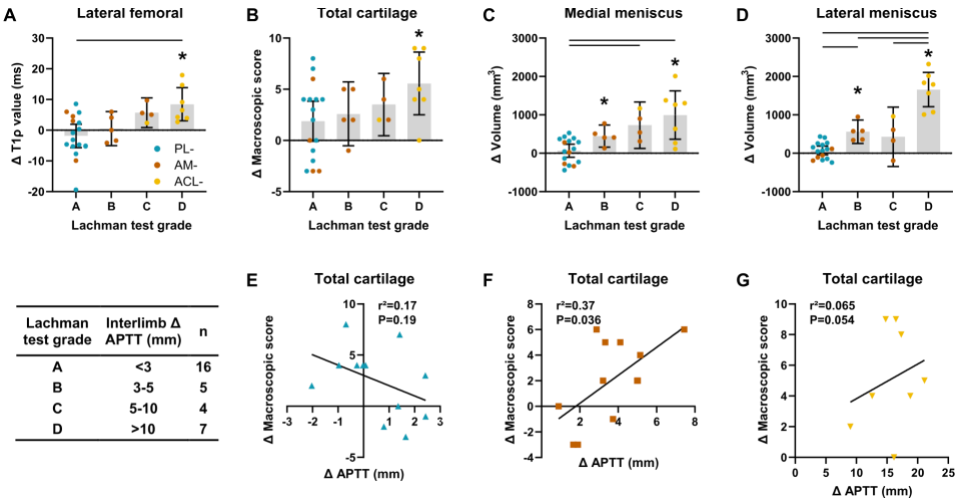

Lachman test grade	Interlimb Δ APTT (mm)	n
A	<3	16
B	3-5	5
C	5-10	4
D	>10	7

Fig. 6. Degenerative outcomes as a function of changes in laxity. Interlimb difference in (A) lateral femoral joint cartilage T1ρ, (B) composite macroscopic cartilage score, (C) medial meniscus volume and (D) lateral meniscus volume, grouped by the equivalent Lachman test grade from applied anterior-posterior drawer in biomechanical testing. *P<0.05 compared to 0 from one sample t-test; bars indicate P<0.05 between injury type, from one-way ANOVA with Tukey post hoc test. Continuous plots of interlimb difference in macroscopic cartilage score

versus interlimb difference in APTT for the (E) PL- group, (F) AM- group, and (G) ACL- group. Statistical results from linear regression analyses shown in graph. Individual data points (n=12 for PL- and AM- groups, n=8 for ACL- group) presented with mean ± 95% CI (A-D).

DISCUSSION

There is presently a lack of data to inform clinical treatment of partial ACL injury in young patients, and large exploratory clinical studies are difficult to perform in this patient population. The present study provides a comprehensive analysis of functional and degenerative changes in the knee joint after partial (isolated AM or PL bundle) and complete ACL injury in skeletally immature subjects using a preclinical porcine model and clinically relevant outcome measures. Our results indicate that ACL injury severity (partial or complete) impacts outcomes, and equally importantly, that partial injury location (AM or PL bundle) also impacts outcomes. Joint laxity increases were minimal for PL bundle injury, minor for AM bundle injury, and major for ACL injury. In both partial injury cases, the remaining bundle remodeled through an increase in CSA to attempt to restore ACL function and stabilize the knee joint. Cartilage degeneration and meniscal hypertrophy were observed to a minor degree after AM bundle injury and to a major degree after ACL injury, but not after PL bundle injury. Generally, sex did not impact degenerative outcomes. Across all injury groups, the degree of degenerative changes was associated with the extent of joint destabilization.

The joint laxity findings in this study are consistent with studies in humans, which report minor (0-6 mm) increases in laxity after partial ACL tears (*7, 11, 13, 16*) compared to major (6-12 mm) increases in laxity after complete ACL tears (*7, 11*). ACL injuries are most commonly diagnosed through physical examination using a Lachman test, which assesses tibial translation

under anterior loads, or a pivot shift test, which evaluates tibial subluxation under compressive and rotational loads (*25*). Therefore, the small differences in laxity for partial ACL injuries point to challenges in diagnosis, particularly for PL bundle tears. This is supported by a clinical study in adults which found that 50% of partial tears confirmed through arthroscopy were diagnosed as a false negative using a KT-1000 arthrometer (*26*). In the current study, no significant difference in side-to-side laxity was measured under anterior or rotational loads for the PL bundle injury group. In fact, all specimens from the PL bundle injury group fell within the Lachman grade A (indicative of a "normal" joint), suggesting that many of these injuries likely go undiagnosed and untreated. Imaging, primarily MRI, may be valuable as a complementary diagnostic tool in cases where physical examination is inconclusive. Therefore, physical exams paired with MRI appear to be the best current process for diagnosing partial ACL tears, although there remains space for improvement of diagnostic sensitivity and specificity (*11, 27*). Diagnostic accuracy has the potential for improvement through implementing higher resolution MRI protocols or newer sequences capable of better contrast for ligaments (*28*). There also remains the potential for development of new clinical exams which can detect partial injuries.

Our functional data is consistent with clinical studies in adults which reported that a greater number of PL bundle injuries were biomechanically functional than AM bundle injuries (*11*). Data is less definitive in pediatric patients, since currently only two studies evaluate outcomes after partial injury in young patients (*13, 16*). Kocher et al. found patients with a PL bundle injury were more likely to require a subsequent surgery (*16*), which is contradictory to findings in this study. However, survivor bias may be a source for this discrepancy. In that study, patients with Lachman grade C or D underwent surgical reconstruction and were not included, which would exclude more AM bundle injuries than PL bundle injury based on our laxity

findings. Additionally, it is possible that a greater percentage of AM bundle tears progress to complete ACL tears before receiving treatment. Fayard et al. found a substantial number of meniscal tears after partial ACL injuries, most of which occurred in patients whose injuries progressed to complete tears (*13*). This is partially consistent with our results of minor meniscal and chondral pathologies in partial injury groups, though we saw no progression to complete ACL tear or development of meniscal tears. These differences are likely due to more limited activity of pigs housed in a barn compared to human patients, many of whom return to pivoting sports. In the literature, human studies often gauge the need for surgery by progression from partial to complete tear, but this idea may need to be reconsidered, since our data shows that degenerative changes without progression to complete ACL tear may be a concern.

Our findings are consistent with preclinical in-vivo studies of partial ACL injury as well. A study in skeletally mature sheep found gross and histological cartilage degradation and meniscal damage 40 weeks after AM bundle injury (*29*). Another study in skeletally mature rabbits found histological evidence of meniscal degeneration 8 weeks after both AM and PL bundle injuries (*30*). Although factors including skeletal maturity and time from injury differ between these studies and our study, the consistent findings show that partial ACL injury alone leads to long-term joint degeneration across different preclinical small and large animal models. Furthermore, our study extends these prior findings to show that degeneration occurs even in the context of skeletally immature joints, despite the potential for higher healing/remodeling capacity.

Interestingly, the cartilage degeneration that we measured macroscopically and from MRI did not necessarily correspond to one another, particularly in the AM bundle injured group which showed significantly elevated cartilage T1ρ values but not significant macroscopic cartilage damage. These two metrics inherently measure different outcomes, since macroscopic scoring

reflects large structural damage and loss of tissue, while T1ρ values reflects cartilage matrix proteoglycan content of existing tissue. While elevated T1ρ values are often used as an early predictor of future degeneration (*31*), macroscopic scoring reflects later-stage structural degeneration. These two metrics may capture different phases of degeneration, and we would predict that macroscopic scores for the AM bundle injury group would be increased for a longer follow-up timepoint.

In addition to cartilage, changes in the meniscus were also associated with joint instability, suggesting meniscal hypertrophy may be an early indicator of joint degeneration. This is supported by data from a guineapig model, where meniscal hypertrophy was tied to cartilage damage after ACL injury (*32*). Although little to no data exist regarding meniscal size changes after ACL injury in humans, larger meniscus volume in middle-aged women was tied to later development of structural OA (*33*). While it is common to evaluate meniscal tears after ACL injury, meniscal size, independent of the presence of injury, is often overlooked. However, meniscus size may be an important indicator of overall joint health. Furthermore, meniscus size may be a more repeatable metric across time and may not require specialized MRI sequences, such as T1ρ.

This study has implications for treatment of partial ACL tears, since we showed significant meniscal and chondral pathology after partial ACL injury at the equivalence of a grade B or higher Lachman test. Although we saw differences in outcomes due to injury type, the extent of destabilization may be a better metric as a basis for treatment, since we saw significant associations between cartilage degeneration and joint laxity even within AM bundle injuries. Our results suggest that surgical intervention may be appropriate for patients with Lachman grade B or above, and more likely to be necessary in patients with an AM bundle tear rather than PL

bundle tear. Additionally, the increase in remaining bundle CSA with no change in T2* value indicates that there substantial viable tissue remains after a partial ACL injury. This points to advantages in surgical techniques which preserve the intact tissue. Single bundle augmentation techniques which repair or reconstruct only the injured bundle are relatively new but gaining in popularity (*34-38*). These techniques have the advantage of preserving the functional remaining tissue and may cause less donor site morbidity since smaller grafts would be required.

This study includes several limitations, including the use of an animal model. While the pig is an established preclinical model for musculoskeletal studies (*19*) and the ACL bundles function similarly between pigs and humans (*20*), there are some differences in knee anatomy (*21*) and physiological loading compared to humans. Furthermore, human patients are prescribed physical therapy and activity restrictions, while we did not attempt to restrict animal activity or acquire metrics for physical activity. Moreover, our evaluation of joint stability does not account for active stabilization provided by the muscles, so it is possible that the joint is more stable in-vivo. Nevertheless, the degenerative changes we detected occurred in the presence of muscle function in-vivo. Additionally, our surgical model of ACL injury does not account for damage to other tissues that may occur during the high impact of a naturally occurring ACL injury. However, our model does isolate the effects of progressive degeneration caused by the loss of joint stability. The injured bundle or entire ACL was removed in our surgical model. This prevents any healing, which has been observed in a limited capacity in clinical cases (*39*). An additional limitation includes the use of contralateral limbs as a control. These may differ from joints in healthy animals due to altered gait or limb compensation after injury of the ipsilateral joint. Lastly, the conclusions in this study are limited to only one timepoint after injury and do not capture the time course of degenerative changes. Future longitudinal studies to assess the

progression of the degenerative outcomes would be useful for distinguishing early predictors of degeneration and identifying an ideal window for implementing treatment interventions to prevent degenerative changes.

This study fills key gaps in knowledge about degenerative changes after partial ACL injury in skeletally immature subjects. We leverage a large animal model to collect detailed data about joint biomechanics, tissue remodeling, and cartilage degeneration which are not possible to collect in clinical studies. Our data show that the extent of destabilization after an ACL injury may serve as a predictor of degeneration, irrespective of the injury type (partial or complete) or partial injury location (AM or PL bundle). Associations in this study also imply that there may not be a key threshold beyond which degenerative changes occur, but instead, a continuous gradient where even small increases in laxity can cause minor degeneration. Overall, this study provides a fundamental basis for informing clinical treatments in young patients with partial ACL tears.

MATERIALS AND METHODS

Study design

The objective of this study was to evaluate the outcomes of partial ACL injury as a function of tear location (AM or PL bundle), with covariates of sex and age, in a skeletally immature surgical porcine model. All animals were bred at the North Carolina State University Swine Educational Unit, and all experimental protocols were approved by the North Carolina State University Institutional Animal Care and Use Committee. Sample sizes were calculated using a power analysis described in the “Statistical analysis” section. A total of 32 juvenile Yorkshire crossbreed pigs (age: 13 ± 1 week, weight: 34 ± 5 kg) underwent unilateral

arthroscopic transection of the AM bundle (n=6 female, n=6 male), the PL bundle (n=6 female, n=6 male), or the complete ACL (n=4 female, n=4 male) with a sham operation performed on the contralateral joint. Injury type and injured limb side were randomized. To confirm findings in an older age group, a small subset of 9 adolescent pigs (age: 25 ± 1 week, weight: 129 ± 21 kg) underwent unilateral arthroscopic transection of the AM bundle (n=3 female, n=1 male) or PL bundle (n=4 female, n=1 male). One adolescent animal which was meant to undergo AM bundle transection was excluded due to a pre-existing partial ACL tear to the PL bundle. The endpoint was set at 24 weeks to experimentally evaluate joint biomechanics, cartilage health, and remodeling of soft tissues in the knee joint. Data were collected blindly, where possible. No outliers were excluded in the presented data.

Surgical procedure

Prior to surgery, all pigs were sedated and received analgesics and antimicrobials. Operations were performed arthroscopically (Arthrex Synergy System) under general anesthesia. The knee joints were accessed through medial and lateral parapatellar incisions (~0.5 cm long). The infrapatellar fat pad was partially removed using a 3.5 mm motorized shaver (SabreTooth, Arthrex) to visualize the ACL. A freer elevator was inserted between the AM and PL bundles near the tibial insertion and used to bluntly separate the bundles. A triangle knife (Ectra II Knife 4448, Smith & Nephew) was inserted into the separation and (1) turned anteriorly to transect the AM bundle, (2) turned posteriorly to transect the PL bundle, or (3) used to transect the full cross-section of the ACL. The remnant of the transected bundle or complete ligament was debrided using the shaver to ensure loss of function and prevent healing. On the contralateral sham limb, the infrapatellar pad was similarly partially removed, following which the ACL bundles were

separated with a freer elevator but not transected. Following the operation, skin incisions were suture closed, a local analgesic was administered through subcutaneous injection at the portal sites, and the joint was covered with an antimicrobial adhesive drape. Animals were given analgesics and antimicrobials for 3 days post-operatively. Animals were allowed full weight bearing immediately following surgery and housed in pens with no restriction of movement. After 6 months (23.9 ± 0.3 weeks), all animals were euthanized, and hind limbs were collected. Skin and excess muscle were removed, and knee joints were wrapped in saline-soaked pads and stored at -20 °C.

Magnetic resonance imaging

Prior to scanning, joints were stored at -20 °C. They were thawed one day prior to MRI and imaged at full extension. Imaging was performed using a Siemens Magnetom Prisma 3T MRI system and a knee coil. Joints were scanned using a T1ρ fast low-angle shot (FLASH) sequence (FOV: 128x128x84mm, voxel size: 0.4x0.4x1.5mm, FA: 10°, TR: 8.74ms, TE: 4.60ms, spin-lock frequency: 500 Hz, TSL: 0, 10, 20, 30, 40ms) and a T2 susceptibility weighted imaging (SWI) sequence (FOV: 160x160x128mm, voxel size: 0.4x0.4x0.8mm, FA: 12°, TR: 31.0ms, TE: 3.3,7.1,11.4,15.7,20.0,24.4ms). Following scanning, joints were stored at -20 °C for subsequent biomechanical testing. T1ρ and T2* relaxation maps were created by fitting monoexponential decay function on a voxel-by-voxel basis to the 5 spin-lock times and 6 echo times, respectively, using a custom MATLAB script.

Articular cartilage from the medial and lateral condyles of the femur and tibia were manually segmented by a single user from T1ρ images with 0 ms spin-lock time using commercial software (Simpleware ScanIP). Using a MATLAB script, the segmented areas were

transposed onto T1ρ relaxation maps described above, and the median T1ρ relaxation time was calculated for each of the four segmented cartilage compartments.

Similarly, the AM bundle, PL bundle, complete ACL, MCL, LCL, and medial and lateral meniscus were manually segmented by a single user from T2* images with 15.7ms echo time. The median T2* relaxation time was calculated for each ACL bundle. Additionally, the volume of each segmented tissue was recorded, and the cross-sectional area (CSA) of the AM and PL bundles, the complete ACL, MCL, and LCL were calculated as previously described (*17, 18*). Briefly, each segmented tissue was exported as a surface mesh, and analyzed using a MATLAB script. Each mesh was rotated such that a line of best fit through the mesh vertices aligned with the z-axis. The CSA was calculated for slices of the mesh in 1 mm increments along the z-axis, then averaged over the middle 50% of slices.

Biomechanical testing

Biomechanics of the knee joint were evaluated using a 6 degree-of-freedom (DOF) robotic testing system (KR300 R2500, KRC4, Kuka) equipped with a universal force-moment sensor (Omega160 IP65, ATI Industrial Automation), and integrated through the simVitro software knee module (Cleveland Clinic). To prepare for testing, joints were thawed at room temperature and trimmed to expose the femoral and tibial diaphyses. The femoral head and the distal end of the tibia were removed using a bone saw, then bones were fixed using fiberglass-reinforced epoxy (Everglass, Evercoat) in molds designed to fit in custom clamps for testing. Fixed joints were stored at -20 °C and thawed at room temperature one day prior to robot testing.

The femoral end of the joint was fixed to a rigid testing platform, while the tibial end was fixed to the robotic system at 40° of flexion. A 3D digitizer (G2X MicroScribe) was used to

determine an anatomic coordinate system. Joints were sprayed with saline and lightly wrapped in a pad throughout testing to maintain hydration. A passive flexion path was determined by flexing the joint from 40° to 90° while minimizing forces/moments in the remaining 5 DOFs. Then, loads were applied to the tibia in the anterior-posterior (AP) (100 N), proximal (axial compression, 140 N), and VV (5 Nm) directions/rotations at 60° of joint flexion while recording kinematic paths. Kinematics were then replayed while recording forces. Next, the joint capsule was removed, and kinematics were replayed while recording forces. The difference in forces measured between the intact and capsule-deficient condition was calculated as the force carried by the joint capsule, by the principle of super position. This process was repeated after transection of the AM bundle (or any remnant), PL bundle (or any remnant), MCL, LCL, PCL, medial meniscus, lateral meniscus, medial femoral condyle, and lateral femoral condyle. Joint laxity was measured by anterior-posterior tibial translation (APTT) under AP drawer, anterior tibial translation (ATT) under axial compression, and VV rotation under VV moments. Load-transformation curves were plotted for each loading condition using data points collected at intervals of 20% of the maximum applied load.

Macroscopic scoring

During robotic testing and tissue dissection, gross images were taken of the synovium following joint capsule dissection, as well as femoral and tibial articular cartilage, following removal of all other tissues, during robotic testing. Synovium and cartilage were macroscopically scored using Osteoarthritis Research Society International (OARSI) guidelines for sheep and goat (*24*). Although are no scoring guidelines for pigs, this scoring system has been used to evaluate cartilage in previous porcine studies (*40, 41*). Synovial pathology was scored from 0

(normal) to 5 (severe), and articular cartilage of medial and lateral condyles of the femur and tibia were scored from 0 (normal) to 4 (large erosions down to subchondral bone) by two blinded reviewers. Disagreements between users were re-examined to determine a consensus. Scores from the four cartilage compartments were added to give a total joint score.

Statistical analyses

Sample sizes were determined using a power analysis based on prior work that demonstrated the ability of AM- and ACL- joints to generate joint instability (*42*). Using an overall α level of 0.05 (accounting for multiple comparisons), a power of 0.8, and an effect size of 1.5 for the AM- group, a sample size of n=12 was selected to measure a difference between injured and sham-operated joints. For complete loss of ACL function, much larger effect sizes are expected (>3), so a sample size of n=8 was used for this group.

Normality of all data sets was confirmed using Shapiro-Wilk test, and equal variance between data sets was tested using Brown-Forsythe test. Joint kinematics, tissue forces under applied loads, tissue size metrics, and bundle T2* values were compared between injured and sham-operated joints using paired t-tests with Holm-Sidak's correction for multiple comparisons. Interlimb differences in joint kinematics and cartilage T1ρ were compared between injury types using a one-way ANOVA with Tukey's post hoc comparison and compared to zero with one sample t-test. Interlimb differences in macroscopic cartilage scores were compared to zero using one sample Wilcoxon test and between injury groups using a Kruskal Wallis test. For data sets with unequal variance, Welch ANOVA with Dunnett post hoc comparison. To evaluate clinically relevant outcomes, samples were grouped into equivalent Lachman test grades according to IKDC guidelines (A: <3 mm, B: 3-5 mm, C: 5-10 mm, D: >10 mm) (*43*), based on joint

translations under AP drawer. Interlimb differences in cartilage T1ρ, macroscopic cartilage scores, and meniscal volume were compared between Lachman grades using one-way ANOVA and compared to zero with one sample t-test. Associations were assessed between interlimb differences in APTT and interlimb differences in cartilage scores and meniscal volume using linear regression across all injury types and within injury types. All statistical analyses were performed in Prism (GraphPad), with significance set at $\alpha=0.05$ for all analyses apart from one sample tests, where $\alpha=0.0167$ to correct for multiple comparisons. Adjusted P values are reported. Data presented as mean ± 95% CI, unless stated otherwise, and data are reported in supplemental material.

References and Notes

1. G. Kolata, in *The New York Times*. (2017), chap. D, pp. 1.
2. T. L. Sanders, H. Maradit Kremers, A. J. Bryan, D. R. Larson, D. L. Dahm, B. A. Levy, M. J. Stuart, A. J. Krych, Incidence of Anterior Cruciate Ligament Tears and Reconstruction: A 21-Year Population-Based Study. *Am J Sports Med* **44**, 1502-1507 (2016).
3. N. A. Mall, P. N. Chalmers, M. Moric, M. J. Tanaka, B. J. Cole, B. R. Bach, Jr., G. A. Paletta, Jr., Incidence and trends of anterior cruciate ligament reconstruction in the United States. *Am J Sports Med* **42**, 2363-2370 (2014).
4. B. C. Werner, S. Yang, A. M. Looney, F. W. Gwathmey, Jr., Trends in Pediatric and Adolescent Anterior Cruciate Ligament Injury and Reconstruction. *J Pediatr Orthop* **36**, 447-452 (2016).

5. D. Zbrojkiewicz, C. Vertullo, J. E. Grayson, Increasing rates of anterior cruciate ligament reconstruction in young Australians, 2000-2015. *Med J Aust* **208**, 354-358 (2018).

6. E. R. Dodwell, L. E. Lamont, D. W. Green, T. J. Pan, R. G. Marx, S. Lyman, 20 years of pediatric anterior cruciate ligament reconstruction in New York State. *Am J Sports Med* **42**, 675-680 (2014).

7. D. M. Daniel, M. L. Stone, R. Sachs, L. Malcom, Instrumented measurement of anterior knee laxity in patients with acute anterior cruciate ligament disruption. *Am J Sports Med* **13**, 401-407 (1985).

8. I. Kawashima, H. Hiraiwa, S. Ishizuka, R. Kawai, Y. Kusaka, K. Ohtomo, T. Tsukahara, Incidence of Medial and Lateral Meniscal Tears After Delayed Anterior Cruciate Ligament Reconstruction in Pediatric Patients. *Orthop J Sports Med* **8**, 2325967120964603 (2020).

9. C. L. Ardern, G. Ekas, H. Grindem, H. Moksnes, A. Anderson, F. Chotel, M. Cohen, M. Forssblad, T. J. Ganley, J. A. Feller, J. Karlsson, M. S. Kocher, R. F. LaPrade, M. McNamee, B. Mandelbaum, L. Micheli, N. Mohtadi, B. Reider, J. Roe, R. Seil, R. Siebold, H. J. Silvers-Granelli, T. Soligard, E. Witvrouw, L. Engebretsen, 2018 International Olympic Committee consensus statement on prevention, diagnosis and management of paediatric anterior cruciate ligament (ACL) injuries. *Knee Surg Sports Traumatol Arthrosc*, (2018).

10. P. Colombet, D. Dejour, J. C. Panisset, R. Siebold, S. French Arthroscopy, Current concept of partial anterior cruciate ligament ruptures. *Orthop Traumatol Surg Res* **96**, S109-118 (2010).

11. D. Dejour, P. G. Ntagiopoulos, P. R. Saggin, J. C. Panisset, The diagnostic value of clinical tests, magnetic resonance imaging, and instrumented laxity in the differentiation of complete versus partial anterior cruciate ligament tears. *Arthroscopy* **29**, 491-499 (2013).

12. E. R. Hunt, C. A. Jacobs, C. E. Conley, M. L. Ireland, D. L. Johnson, C. Lattermann, Anterior cruciate ligament reconstruction reinitiates an inflammatory and chondrodegenerative process in the knee joint. *J Orthop Res* **39**, 1281-1288 (2021).

13. J. M. Fayard, B. Sonnery-Cottet, G. Vrgoc, P. O'Loughlin, G. D. de Mont Marin, B. Freychet, T. D. Vieira, M. Thaunat, Incidence and Risk Factors for a Partial Anterior Cruciate Ligament Tear Progressing to a Complete Tear After Nonoperative Treatment in Patients Younger Than 30 Years. *Orthop J Sports Med* **7**, 2325967119856624 (2019).

14. P. N. Chalmers, N. A. Mall, M. Moric, S. L. Sherman, G. P. Paletta, B. J. Cole, B. R. Bach, Jr., Does ACL reconstruction alter natural history?: A systematic literature review of long-term outcomes. *J Bone Joint Surg Am* **96**, 292-300 (2014).

15. M. Group, J. S. Everhart, M. H. Jones, S. Yalcin, E. K. Reinke, L. J. Huston, J. T. Andrish, C. L. Cox, D. C. Flanigan, C. C. Kaeding, R. A. Magnussen, N. Obuchowski, R. D. Parker, A. D. Pedroza, R. A. Sanders, C. S. Winalski, K. P. Spindler, The Clinical Radiographic Incidence of Posttraumatic Osteoarthritis 10 Years After Anterior Cruciate Ligament Reconstruction: Data From the MOON Nested Cohort. *Am J Sports Med* **49**, 1251-1261 (2021).

16. M. S. Kocher, L. J. Micheli, D. Zurakowski, A. Luke, Partial tears of the anterior cruciate ligament in children and adolescents. *Am J Sports Med* **30**, 697-703 (2002).

17. S. G. Cone, E. P. Lambeth, H. Ru, L. A. Fordham, J. A. Piedrahita, J. T. Spang, M. B. Fisher, Biomechanical Function and Size of the Anteromedial and Posterolateral Bundles of the ACL Change Differently with Skeletal Growth in the Pig Model. *Clin Orthop Relat Res* **477**, 2161-2174 (2019).

18. D. Howe, S. G. Cone, J. A. Piedrahita, B. Collins, L. A. Fordham, E. H. Griffith, J. T. Spang, M. B. Fisher, Sex-specific biomechanics and morphology of the anterior cruciate ligament during skeletal growth in a porcine model. *J Orthop Res*, (2021).

19. S. G. Cone, P. B. Warren, M. B. Fisher, Rise of the Pigs: Utilization of the Porcine Model to Study Musculoskeletal Biomechanics and Tissue Engineering During Skeletal Growth. *Tissue Eng Part C Methods* **23**, 763-780 (2017).

20. J. W. Xerogeanes, R. J. Fox, Y. Takeda, H. S. Kim, Y. Ishibashi, G. J. Carlin, S. L. Woo, A functional comparison of animal anterior cruciate ligament models to the human anterior cruciate ligament. *Ann Biomed Eng* **26**, 345-352 (1998).

21. B. L. Proffen, M. McElfresh, B. C. Fleming, M. M. Murray, A comparative anatomical study of the human knee and six animal species. *Knee* **19**, 493-499 (2012).

22. R. R. Regatte, S. V. Akella, A. J. Wheaton, G. Lech, A. Borthakur, J. B. Kneeland, R. Reddy, 3D-T1rho-relaxation mapping of articular cartilage: in vivo assessment of early degenerative changes in symptomatic osteoarthritic subjects. *Acad Radiol* **11**, 741-749 (2004).

23. S. V. Akella, R. R. Regatte, A. J. Gougoutas, A. Borthakur, E. M. Shapiro, J. B. Kneeland, J. S. Leigh, R. Reddy, Proteoglycan-induced changes in T1rho-relaxation of articular cartilage at 4T. *Magn Reson Med* **46**, 419-423 (2001).

24. C. B. Little, M. M. Smith, M. A. Cake, R. A. Read, M. J. Murphy, F. P. Barry, The OARSI histopathology initiative - recommendations for histological assessments of osteoarthritis in sheep and goats. *Osteoarthritis Cartilage* **18 Suppl 3**, S80-92 (2010).

25. V. Musahl, I. D. Engler, E. M. Nazzal, J. F. Dalton, G. A. Lucidi, J. D. Hughes, S. Zaffagnini, F. Della Villa, J. J. Irrgang, F. H. Fu, J. Karlsson, Current trends in the anterior cruciate ligament part II: evaluation, surgical technique, prevention, and rehabilitation. *Knee Surg Sports Traumatol Arthrosc* **30**, 34-51 (2022).

26. J. Isberg, E. Faxen, S. Brandsson, B. I. Eriksson, J. Karrholm, J. Karlsson, KT-1000 records smaller side-to-side differences than radiostereometric analysis before and after an ACL reconstruction. *Knee Surg Sports Traumatol Arthrosc* **14**, 529-535 (2006).

27. P. Van Dyck, E. De Smet, J. Veryser, V. Lambrecht, J. L. Gielen, F. M. Vanhoenacker, L. Dossche, P. M. Parizel, Partial tear of the anterior cruciate ligament of the knee: injury patterns on MR imaging. *Knee Surg Sports Traumatol Arthrosc* **20**, 256-261 (2012).

28. N. C. Nacey, M. G. Geeslin, G. W. Miller, J. L. Pierce, Magnetic resonance imaging of the knee: An overview and update of conventional and state of the art imaging. *J Magn Reson Imaging* **45**, 1257-1275 (2017).

29. K. I. Barton, B. J. Heard, J. L. Sevick, C. R. Martin, S. M. M. Shekarforoush, M. Chung, Y. Achari, C. B. Frank, N. G. Shrive, D. A. Hart, Posttraumatic Osteoarthritis Development and Progression in an Ovine Model of Partial Anterior Cruciate Ligament Transection and Effect of Repeated Intra-articular Methylprednisolone Acetate Injections on Early Disease. *Am J Sports Med* **46**, 1596-1605 (2018).

30. D. Wang, Z. Wang, M. Li, S. Xu, The underlying mechanism of partial anterior cruciate ligament injuries to the meniscus degeneration of knee joint in rabbit models. *J Orthop Surg Res* **15**, 428 (2020).

31. H. F. Atkinson, T. B. Birmingham, R. F. Moyer, D. Yacoub, L. E. Kanko, D. M. Bryant, J. D. Thiessen, R. T. Thompson, MRI T2 and T1rho relaxation in patients at risk for knee osteoarthritis: a systematic review and meta-analysis. *BMC Musculoskelet Disord* **20**, 182 (2019).

32. G. Du, H. Zhan, D. Ding, S. Wang, X. Wei, F. Wei, J. Zhang, B. Bilgen, A. M. Reginato, B. C. Fleming, J. Deng, L. Wei, Abnormal Mechanical Loading Induces Cartilage Degeneration by Accelerating Meniscus Hypertrophy and Mineralization After ACL Injuries In Vivo. *Am J Sports Med* **44**, 652-663 (2016).

33. D. Xu, J. van der Voet, J. H. Waarsing, E. H. Oei, S. Klein, M. Englund, F. Zhang, S. Bierma-Zeinstra, J. Runhaar, Are changes in meniscus volume and extrusion associated to knee osteoarthritis development? A structural equation model. *Osteoarthritis Cartilage* **29**, 1426-1431 (2021).

34. B. Sonnery-Cottet, R. Zayni, J. Conteduca, P. Archbold, T. Prost, Y. Carrillon, J. Clechet, M. Thaunat, Posterolateral Bundle Reconstruction With Anteromedial Bundle Remnant Preservation in ACL Tears: Clinical and MRI Evaluation of 39 Patients With 24-Month Follow-up. *Orthop J Sports Med* **1**, 2325967113501624 (2013).

35. N. Shohat, D. Lindner, E. Tamir, Y. Beer, G. Agar, Prospective Comparison between Remnant-Preserving Augmentation and Double-Bundle Reconstruction in Anterior Cruciate Ligament Tears. *Isr Med Assoc J* **19**, 355-359 (2017).

36. A. M. Gipsman, N. Trasolini, G. F. R. Hatch, 3rd, Primary Anterior Cruciate Ligament Single-Bundle Repair With Augmentation for a Partial Anterior Cruciate Ligament Tear. *Arthrosc Tech* **7**, e367-e372 (2018).

37. G. Y. Ahn, T. H. Lee, K. J. Lee, S. Woo, Comparison of clinical outcomes and second-look arthroscopic evaluations between anterior cruciate ligament anteromedial bundle augmentation and single-bundle anterior cruciate ligament reconstruction. *Knee Surg Relat Res* **32**, 45 (2020).

38. T. Tajima, N. Yamaguchi, Y. Morita, T. Yokoe, M. Nagasawa, T. Ota, S. Kawagoe, Y. Nakamura, E. Chosa, Remnant-Preserved Single-Bundle Anterior Cruciate Ligament Augmentation in Multi-ligamentous Knee Reconstruction. *J Knee Surg*, (2022).

39. E. H. Crain, D. C. Fithian, E. W. Paxton, W. F. Luetzow, Variation in anterior cruciate ligament scar pattern: does the scar pattern affect anterior laxity in anterior cruciate ligament-deficient knees? *Arthroscopy* **21**, 19-24 (2005).

40. N. P. Karamchedu, M. M. Murray, J. T. Sieker, B. L. Proffen, G. Portilla, M. Q. Costa, J. Molino, B. C. Fleming, Bridge-Enhanced Anterior Cruciate Ligament Repair Leads to Greater Limb Asymmetry and Less Cartilage Damage Than Untreated ACL Transection or ACL Reconstruction in the Porcine Model. *Am J Sports Med* **49**, 667-674 (2021).

41. M. P. Pinette, J. Molino, B. L. Proffen, M. M. Murray, B. C. Fleming, Effects of Male and Female Sex on the Development of Posttraumatic Osteoarthritis in the Porcine Knee After Anterior Cruciate Ligament Surgery. *Am J Sports Med*, 3635465221102118 (2022).

42. D. Howe, S. G. Cone, J. A. Piedrahita, J. T. Spang, M. B. Fisher, Age and Sex-Specific Joint Biomechanics in Response to Partial and Complete ACL Injury in the Porcine Model. *J Athl Train*, (2021).

43. E. P. Mulligan, D. Q. McGuffie, K. Coyner, M. Khazzam, The reliability and diagnostic accuracy of assessing the translation endpoint during the lachman test. *Int J Sports Phys Ther* **10**, 52-61 (2015).

Acknowledgments: We would like to thank Laboratory Animal Resources (NC State) and the Biomedical Research Imaging Center (UNC-CH) for their contributions to this work.

Funding:

National Institutes of Health grant F31AR077997 (DH)

National Institutes of Health grant R01AR071985 (MBF, EHG, LVS, JTS)

National Science Foundation grant DGE-1746939 (JDT)

Author contributions:

Conceptualization: DH, LVS, JTS, MBF

Methodology: DH, JDT, SDT, EHG, LVS, JTS, MBF

Investigation: DH, JDT, OB, SDT, LVS, JTS, MBF

Formal analysis: DH, JDT, SDT, EHG, MBF

Data Curation: DH, SDT

Visualization: DH

Funding acquisition: DH, JDT, LVS, JTS, MBF

Project administration: DH, MBF

Supervision: MBF

Writing – original draft: DH

Writing – review & editing: DH, JDT, OB, SDT, EHG, LVS, JTS, MBF

Competing interests: Authors declare that they have no competing interests.

Data and materials availability: All data are available in the main text or the supplementary materials.

SUPPLEMENTAL MATERIAL

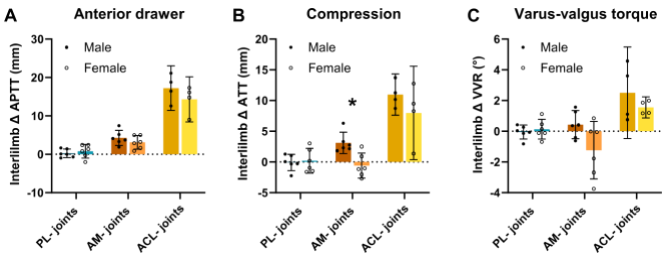

Figure S1. Sex-specific biomechanical outcomes. Interlimb differences in (A) anterior-posterior tibial translation (APTT) under applied AP drawer, (B) anterior tibial translation (ATT) under applied axial compression, and (C) varus-valgus (VV) rotation under applied VV moments. * P<0.05 between male and female, from one-way ANOVA with Tukey post hoc test. Individual data points presented with mean ± 95% CI.

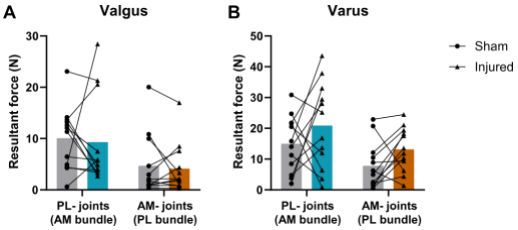

Figure S2. In-situ bundle forces under rotational loads. Resultant force in the uninjured bundle under applied (A) valgus moments and (B) varus moments. Lines connect paired joints. Individual data points presented with mean.

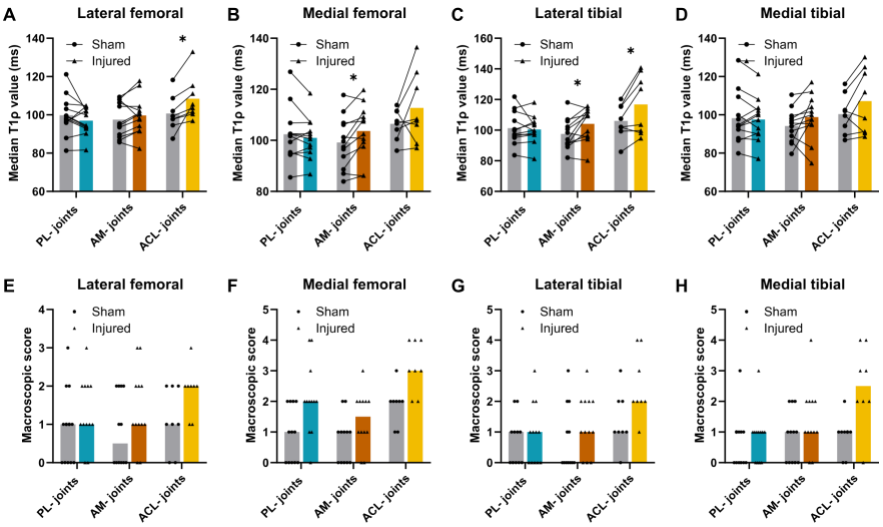

Figure S3. T1ρ values and macroscopic scores of cartilage compartments. T1ρ values of the (A) lateral femoral, (B) lateral tibial, (C) medial femoral, and (D) medial tibial cartilage compartments. Macroscopic OARSI score of the (E) lateral femoral, (F) lateral tibial, (G) medial femoral, and (H) medial tibial cartilage compartments. *P<0.05 between injured and contralateral, from paired t-test with Holm-Sidak correction. Individual data points presented with mean with lines connecting paired joints (A-D) or median ± IQR (E-H).

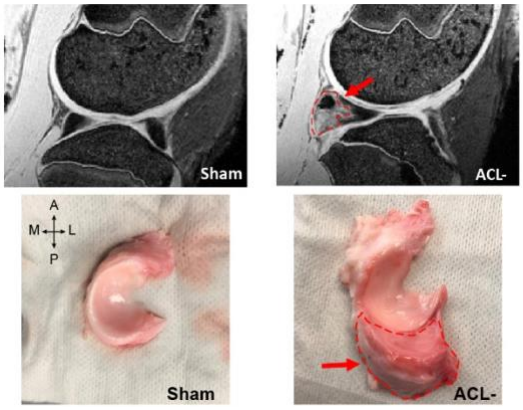

Figure S4. MRI and macroscopic images of medial menisci from sham-operated and ACL-joints. Red dotted lines indicate degenerative, fibrous outgrowth. Anterior-posterior and medial-lateral directions indicated.

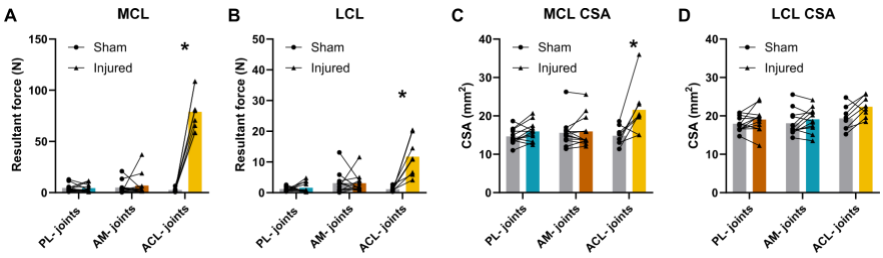

Figure S5. Collateral ligament remodeling after partial and complete ACL transection. In-situ forces in the (A) MCL and (B) LCL under applied anterior drawer. CSA of the (C) MCL and (D) LCL. Lines connect paired joints. *P<0.05 between injured and contralateral, from paired t-test with Holm-Sidak correction. Individual data points (n=12 for PL- and AM- groups, n=8 for ACL- group) presented with mean.

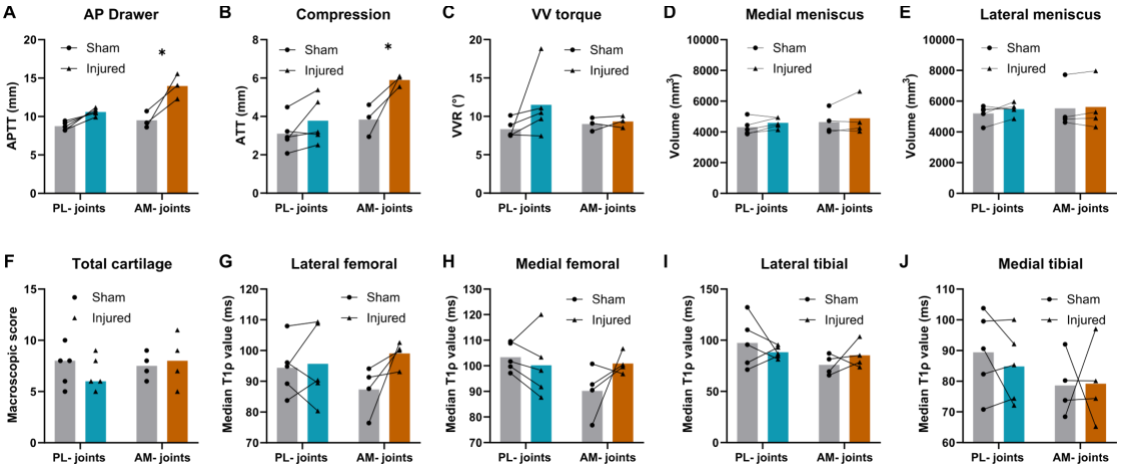

Figure S6. Biomechanical and degenerative outcomes after partial injuries created in adolescent (6 month) pigs. (A) APTT under applied AP drawer, (B) ATT under applied axial compression, and (C) VV rotation under applied VV moments. Volume of the (D) medial meniscus and (E) lateral meniscus. (F) Composite macroscopic OARSI scores summed from the four articular cartilage compartments. T1ρ value for (G) lateral femoral, (H) medial femoral, (I) lateral tibial, and (J) medial tibial articular cartilage. Lines connect paired joints. *P<0.05

between injured and contralateral, from paired t-test with Holm-Sidak correction. Individual data points (n=5 for PL- and n=4 for AM- groups) presented with mean.

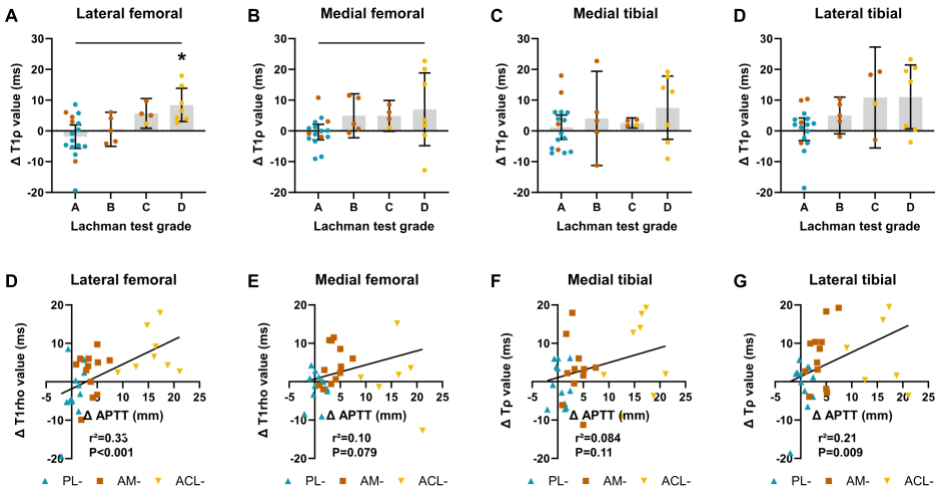

Figure S7. Interlimb difference in (A) lateral femoral, (B) medial femoral, (C) medial tibial, and (D) lateral tibial cartilage T1ρ value, grouped by the equivalent Lachman test grade. *P<0.05 compared to 0 from one sample t-test; bars indicate P<0.05 between injury type, from one-way ANOVA with Tukey post hoc test. Continuous plots of interlimb difference in (E) lateral femoral, (F) medial femoral, (G) medial tibial, and (H) lateral tibial cartilage T1ρ value versus interlimb difference in APTT across all injury groups. Statistical results from linear regression analyses shown in graph. Individual data points presented with mean ± 95% CI (A-D).

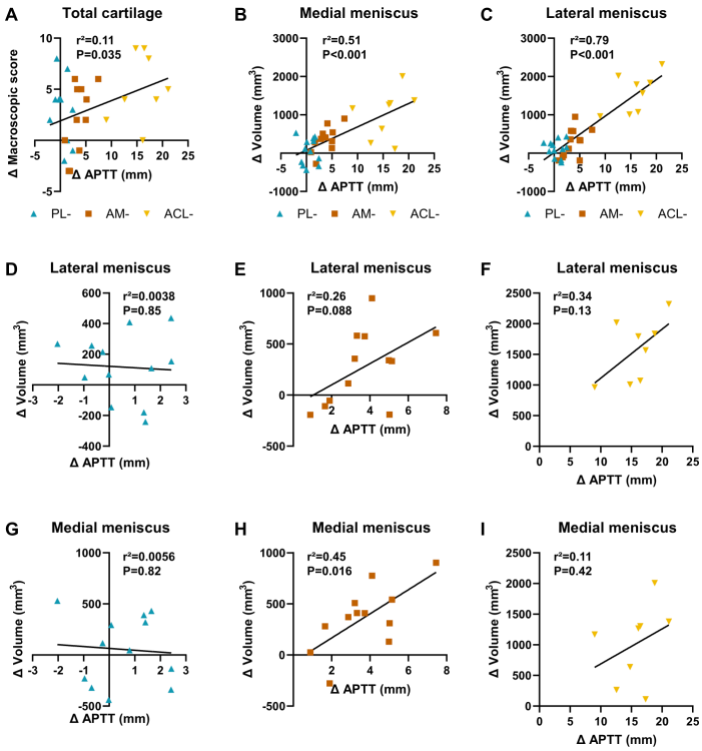

Figure S8. Interlimb difference in (A) composite macroscopic cartilage score, (B) medial meniscus volume and (C) lateral meniscus volume versus interlimb difference in APTT across all injury groups. Interlimb difference in medial meniscus volume versus interlimb difference in APTT for the (D) PL- group, (E) AM- group, and (F) ACL- group. Interlimb difference in lateral meniscus volume versus interlimb difference in APTT for the (G) PL- group, (H) AM- group, and (I) ACL- group. Statistical results from linear regression analyses shown in graph.