COMT inhibitor tolcapone represses the migration and invasion of trophoblast and results in preeclampsia-like phenotypes in mice

Lu Chen[1,2], Menglan Pang[1], Qiuling Jie[3], Fei Sun[1, 3], Liping Huang[1], Yanlin Ma[3], Xiaojing Yue[1*]

1. Department of Obstetrics and Gynecology, Nanfang Hospital, Southern Medical University
2. Department of Obstetrics and Gynaecology, The Chinese University of Hong Kong.
3. Hainan Provincial Key Laboratory for Human Reproductive Medicine and Genetic Research, The First Affiliated Hospital of Hainan Medical University, Hainan Medical University

***Correspondence to:** Xiaojing Yue, PhD (yuexj1986@163.com);

Mailing address: Southern Medical University, 1023 South Shatai Rd, Guangzhou 510515, China.

Word count

Abstract: 209 words

Article length: 4302 words

Abbreviations

YOPD, young onset Parkinson's disease; PD, Parkinson's disease; COMT, catechol O-methyltransferase; Tol, tolcapone; H-Tol, high-dose tolcapone; L-Tol, low-dose tolcapone; JZ, junction zone; LZ, labyrinth zone; SP, spongiotrophoblast; SBP, systolic blood pressure; CK8, cytokeratin 8; α-SMA, α-smooth muscle actin; EMT, epithelial–mesenchymal transition.

Abstract

Pregnancy in young onset Parkinson's disease (YOPD) does not often occur, yet the medication in this condition is critical for maternal and fetal health. Tolcapone is an effective antiparkinsonian drug whereas the safety studies on mother and fetus are rather limited. In this study, we aimed to investigate the effects of tolcapone on mother and developing fetus in different gestations. Tolcapone was administrated to pregnant mice at the dose of 60 mg/kg/day (H-Tol) or 30 mg/kg/day (L-Tol), in the early gestation or the mid-gestation. We demonstrated that tolcapone in early gestation caused abortion and delayed fetus development in a dose-dependent manner. Taking tolcapone in mid-gestation barely caused embryo lethality, however, the mice developed preeclampsia-like phenotypes, including maternal hypertension, proteinuria and fetal growth restriction. The histomorphology analysis of placentas from tolcapone treated mice exhibited abnormalities in trophoblast layer and the hampered trophoblast invasion in decidua. In mechanistic study, we revealed that tolcapone inhibited the invasion and migration of trophoblast *in vitro*, with the changes in protein expressions of Snail, Twist and E-cadherin. In conclusion, tolcapone causes embryo lethality and growth restriction in early gestation, while in mid-gestation tolcapone causes preeclampsia-like phenotypes in mice with defective trophoblast invasion. Our study provides novel insight in understanding the effects of tolcapone in pregnancy.

Introduction

Young onset Parkinson's disease (YOPD) is the Parkinson's disease (PD) diagnosed between ages of 21 and 40 years[1]. YOPD population comprises 5-7% of PD patients in western countries, while about 10% in Japan[2]. Unlike the late onset PD, YOPD progresses more slowly with regular and continuous good care and treatments[3]. The pregnancy in YOPD is rare, however, it is important for clinicians to be prepared to counsel the YOPD women with childbearing potential. Based on an observation of 74 pregnant women with PD, taking anti-parkinsonian medications benefited the improvement or status quo in PD symptoms, and reduced the incidence of deteriorated symptom from 67% to 36%[4]. The antiparkinsonian medications are effective for PD disease control in pregnancy, however, the difficulty is the limited knowledge on safety of medications, with particular regard to the mother's symptom during pregnancy and the potential risk to the fetus[5].

Tolcapone, an inhibitor of catechol O-methyltransferase (COMT), is indicated in the combination with levodopa/carbidopa therapy in PD[6-8]. The Food and Drug Administration (FDA) lists antiparkinsonian drugs in pregnancy category C[9]. The pregnancy category C means animal studies showed risk to fetus and studies on humans are unavailable, while potential benefits in maternal disease control may outweigh the potential risks to fetus. Administration of tolcapone in animal gestation has been implicated in fetal growth restriction and malformation, however, the studies are rather limited and the pathogenesis is unknown[10]. Meanwhile, the potential pregnancy complications on mothers are barely reported. Therefore, exploring the effects of tolcapone during gestation is necessary, and may provide additional information for clinicians in the care of pregnant women with PD.

Placenta is one of the important organs for the evaluation of tolcapone-mediated risks to fetuses. It is important to consider the changes in placental trophoblast layer, which provides an important tool for understanding the mechanism of reproductive and developmental toxicity[11]. As the main cell type consisting of placenta, trophoblast functions as anchoring fetus into uterine wall, synthesizing steroid and hormones, and exchanging nutrient and gas between mother and fetus. Invasion of trophoblast from placenta to maternal decidua is critical to remodel the uterine spiral artery to a dilated vessel. Failure of invasive trophoblast can lead to failed spiral artery transformation, ischemia and oxidative stress in placenta, with consequences for fetal growth restriction and other pregnancy complications, such as preeclampsia[12-14]. Therefore, the purpose of this paper aimed at revealing the trophoblast and placenta-derived pathophysiological changes in mother and fetus under the effect of tolcapone.

Methods

Animals and experimental protocol

C57BL/6 mice aged 8-10 weeks were housed overnight, and pregnancy was confirmed by the presence of vaginal spermatozoa. Pregnant mice at gestational day 0.5 or day 9.5 were administered tolcapone (A4383, APExbio, USA) once daily via gastric gavage till the end of gestation. The high level dosage (H-Tol, 60 mg/kg/day) of tolcapone for mice was converted from the daily recommended human dose (100-200 mg/day tid)[8,15]. The low dose (L-Tol) of tolcapone for mice was set as 30 mg/kg/day.

Mouse blood pressure measurement was recorded by Mouse Blood Pressure System (BP2010, Softron Biotechnology, China) through tail-cuff method. Mice were trained for 2-3 days until they accommodated to the cone animal holder and stayed quietly during the measurements. Blood pressure was recorded from the gestational Day 0 until the gestational Day 17.5.

All animal experiments were approved by the Department of Laboratory Animal Sciences, Southern Medical University.

Cell culture

The human first-trimester placenta trophoblast cell line HTR8/SVneo (ATCC CRL-3271, USA) were cultured in RPMI 1640 medium containing 2 mM Glutamine, 10% FBS, and 1% Penicillin-Streptomycin. The human choriocarcinoma trophoblast cell line BeWo (ATCC CCL-98, USA) were cultured in F-12K medium containing 2 mM Glutamine, 10% FBS, and 1% Penicillin-Streptomycin. The cells were maintained at 37°C with 5% CO_2.

Wound healing assay, transwell assay, cell viability assay and cell proliferation assay

Wound healing assay and transwell assay were performed with invasive trophoblast cell line HTR8/SVneo. Wound healing assay was conducted with ibidi culture-inserts silicone inserts (81176, ibidi, Germany). HTR8/SVneo cells were cultured to a 90% confluent and then the insert was removed. The cells were then maintained in the medium containing tolcapone and 1% FBS to minimize cell proliferation. Migration of cells were examined at 24 hours and 48 hours. For transwell migration assay, tolcapone treated HTR8/SVneo cells were suspended in serum-free medium and seeded into a transwell chamber with 8μm pores (353097-8EA, Corning, USA). Medium containing 10% FBS was supplied in the lower chamber to induce cell passing through the transwell pores. Transwell invasion assay was performed with the transwell chamber precoating with Matrigel (354234, Corning, USA). After 24 hours of incubation at 37℃ with 5% CO_2, the cells on the lower surface of the transwell membrane were fixed and labeled with crystal violet dye. Images were acquired by a microscopy (BX51 microscope, Olympus, Japan). A total of 20 staining pictures from each group were quantified by Image J Software (NIH, USA).

Cell viability assay was performed with HTR8/SVneo cells. The cells were exposed to 0 mM-350 mM tolcapone for 24 hours. The viable cells were assessed by the CCK-8 assay (C0039, Beyotime, China). For cell proliferation assay, HTR8/SVneo cells were cultured with the medium containing 0 mM-45 mM tolcapone for 72 hours, respectively. Live cells were determined by CCK-8 assays and the proliferating rates

were analyzed.

Western immunoblotting

Protein samples for western blotting were extracted as described previously[16]. Briefly, protein was extract from homogenized mouse placental tissues or cell samples with RIPA lysis buffer (89900, ThermoFisher, USA) containing protease inhibitor and phosphatase inhibitor (A32961, ThermoFisher, USA). Equal protein loading was verified by the intensity of the GAPDH blot. The western immunoblotting experiments were repeated three times. The densitometry of blots was quantified by Image J software (NIH, USA).

The primary antibodies used for the present study were from the following sources: anti-E-cadherin (3195), anti-Twist1 (31174), anti-Snail (3879) from Cell Signaling Technology, USA; and anti-GAPDH (sc-47724) from Santa Cruz, USA.

H&E staining, immunohistochemistry staining and fluorescence staining

Paraffin sections of the whole mouse placentas were used for hematoxylin & eosin staining (60524ES60, Yeasen, China). Consecutive cuttings of the mouse placental sections were used for the immunohistochemistry stainings of cytokeratin 8 (CK8) and α-smooth muscle actin (α-SMA). The primary antibodies anti-CK8 (ab154301) and anti-α-SMA (ab5694) were from Abcam, USA. BrdU stainings (6813S, Cell Signaling Technology, USA) of proliferating cells were performed with HTR8/SVneo cells and BeWo cells. Nuclei were visualized by DAPI staining. Images were acquired by fluorescence microscopy (BX51 system microscope, Olympus, Japan). A total of 20 staining pictures from each group were quantified by ImageJ Software (NIH, USA).

Statistical analysis

The data were expressed as the mean ± standard deviation (SD). An unpaired, two-tailed Student's *t*-test was used for two-group comparison. The one-way ANOVA, followed by the Student-Newman-Keuls method, was used for multiple-group

comparison. All analyses were conducted using GraphPad Prism 8.0 and SAS 9.4. A value of $P<0.05$ was considered for a significant difference.

Results

Tolcapone caused abortion, fetal growth restriction and placental abnormality in early gestation

Administration of tolcapone in pregnant mice started at gestational day 0.5 and lasted to the gestational day 17.5 (Fig. 1A). The dose of 60 mg/kg/day tolcapone in mice was converted from the daily recommended human dose 300 mg/day, which was set as the high dose (H-Tol) in our animal study. To explore the minimum safe dose of tolcapone in pregnancy, we also set the 30 mg/kg/day tolcapone in mice as the low dose (L-Tol). The body weights of L-Tol mice were increased as gestation developing, however, were significant lower from the gestational day 7.5 to the end of gestation when compared with the saline control (Fig. 1B). The H-Tol mice displayed no change in body weight, indicative of abortion or losing embryo (Fig. 1B). Therefore, we analyzed the placentas and fetuses from L-Tol mice in the following studies. The fetal size was decreased at gestational day 17.5 in L-Tol group compared with the saline control (Fig. 1C). The number of live pups was deceased and the fetal resorption rate was increased in L-Tol mice (Fig 1D). Consistent with the smaller fetal size, the fetal weights of L-Tol mice were decreased, however, the placental weights were elevated (Fig 1E). To explore the underlying mechanism, we examined the structure of placentas. Histomorphological analysis revealed a pathological change in the placentas from L-Tol mice, as the collagen deposit was observed in the junction zone (JZ), and endothelial hyperplasia with thrombus was observed in large blood vessel (Fig. 1F). The ratio between the labyrinth zone (LZ) and JZ, the two functional zone of mouse placenta, was decreased in the L-Tol group (Fig. 1G). A series of maternal mice blood pressure was detected during gestation and displayed no significant difference between the L-Tol and control (Fig. 1H). These data indicated that taking high dose tolcapone in early gestation caused mice abortion, while the low dose caused mice fetal growth restriction with placental damage.

Tolcapone caused preeclampsia-like phenotypes in mid-gestation

Considering the development toxicity of tolcapone in early gestation, we next examined the effects when administration of tolcapone from the mid to the end of gestation. Pregnant mice took high dose or low dose tolcapone starting at gestational day 9.5 and lasting to day 17.5 (Fig.2 A). The maternal body weight increased consistently and displayed no significant difference among the three groups (Fig. 2B). Meanwhile, the number of live pups and the fetal resorption rate showed no significant difference with or without tolcapone treatment (Fig. 2E, F), indicated that taking tolcapone in mid-gestation had no effect on mice abortion even with the high dose of 60 mg/kg/day. The tolcapone in mid-gestation, however, still caused fetal growth restriction, as evidenced by decreased fetal size and fetal weight (Fig. 2C, G). Fetal malformation was observed in H-Tol mice (Fig. 2D). Placental weight displayed no difference with tolcapone treatment (Fig. 2G), however, the morphologies of placentas changed significantly in response to H-Tol and L-Tol. Spongiotrophoblast, the main trophoblastic cell type consisting of junction zone, spread irregularly into the labyrinth zone in the placentas from tolcapone treated mice (Fig. 2H). In addition, the pathological change in placentas caused the ratios of the two functional zone decreased (Fig. 2I). To uncover the function of tolcapone on mothers, maternal blood pressure was examined. Notably, both two groups of H-Tol and L-Tol mice exhibited significantly higher systolic blood pressure (SBP) from the gestational day 11.5 to the end of gestation (Fig. 2J). Moreover, the H-Tol mice showed a significant higher urine protein concentration at the gestational day 17.5, whereas the L-Tol had no effect on the urinal protein excretion (Fig. 2K). These results indicated that tolcapone in mid-gestation led to fetal growth restriction, maternal gestational hypertension, and might be associated with proteinuria if high dose tolcapone was taken. These symptoms are similar to the typic phenotypes of preeclampsia disorder.

Tolcapone inhibited the invasion of placental trophoblast to maternal decidua in mice

The invasion of trophoblast from placenta to maternal decidua is critical for the processes of placentation and spiral artery transformation[12]. Thus, we investigated the invasion of trophoblast in placental and decidual tissues from mice with tolcapone treatment. Immunostainings of cytokeratin 8 (CK8) and α-smooth muscle actin (α-SMA) were conducted in consecutive sections of placental tissue, to label placental trophoblasts and maternal decidua, respectively (Fig. 3A). Compared with the saline control, the L-Tol mouse placentas showed a significant decrease in trophoblast invasion, and the invasion area was further reduced in the H-Tol mouse placentas (Fig. 3A, B). In addition to the histomorphology evidence, the protein expression of EMT marker E-cadherin was found elevated in the H-Tol mouse placentas (Fig. 3C). These results suggested that tolcapone inhibited the trophoblast invasion *in vivo*, might potentially through the E-cadherin-mediated EMT. To test the hypothesis, we next explored the effects of tolcapone in trophoblast HTR8/SVneo cell line.

Tolcapone repressed cell invasion in HTR8/SVneo trophoblast cell line

HTR8/SVneo trophoblast cells were exposed to different tolcapone concentrations and cell viabilities were examined (Fig. 4A). According to the cell viability curve, we next investigated cell invasion and migration with the tolcapone concentrations of 25mM and 35mM. In our studies, tolcapone showed migration-suppressive activity in the HTR8/SVneo cells tested in a dose- and time-dependent manner (Fig. 4B-D). We further investigated the invasion ability of HTR8/SVneo cells. As expected, tolcapone inhibited the cell invasion in the Matrigel coated transwells (Fig. 4E). The EMT signaling pathway is the classic regulator of trophoblast invasion and migration. Thus, we next explored the potential mechanism by examining the protein expressions of Snail, Twist and E-cadherin. Tolcapone-induced cell invasion inhibition was associated with increased E-cadherin expression and decreased expressions of Snail and Twist (Fig. 4F). These data were consistent with the observation seen in mouse placentas, and revealed that the EMT regulation might be involved in the tolcapone-repressed trophoblastic invasion and migration.

Low concentration of tolcapone induced proliferation in HTR8/SVneo and Bewo trophoblast cell lines

We next determined whether the tolcapone-induced cell invasion inhibition is followed by the suppression of cell proliferation. HTR8/SVneo cells were treated with 0 mM to 45 mM tolcapone for 72 h and analyzed by cell viability assays. Notably, the low concentrations of 5 mM, 15 mM and 25mM tolcapone exhibited the simulating proliferation activities, whereas the 35 mM tolcapone had no effect on cell viability and the 45 mM tolcapone showed obvious growth-suppressive activity (Fig. 5A). The HTR8/SVneo cells displayed strong active proliferation when exposed to 25 mM tolcapone (Fig. 5A). To confirm these findings, we performed the BrdU staining in HTR8/SVneo cells, and observed more BrdU incorporation in the proliferating nucleus with 25 mM tolcapone treatment (Fig. 5B). We also tested the effect of tolcapone using a different trophoblast cell line Bewo. Low concentration of tolcapone also induced the cell proliferation in Bewo cells (Fig. 5C).

Discussion

Pregnancy in YOPD disease is rare, and the clinical experience of taking care of pregnant women with PD is rather limited[17]. Yet, as the gestational age is increasing and the PD is an age-related disease, it may become a common occurrence[4]. Tolcapone is an effective antiparkinsonian drug used with the combination of levodopa/carbidopa therapy. The safety studies of tolcapone in human and animal focused on its potential hepatotoxicity whereas the risks to mother and fetus were not fully elucidated[10,18]. In our study, we demonstrated that tolcapone led to restricted fetal development and even embryo death in early gestation in a dose-dependent manner. The embryo could survive if the mother took tolcapone in mid-gestation, however, preeclampsia-like phenotypes associated with fetal growth restriction occurred. One possible mechanism might be involved with the EMT signaling-modulated trophoblast invasive dysfunction. Our study provides additional information for the usage of tolcapone in pregnancy, referring to the dosage, gestational stage and the adverse effects on mother and fetus.

People with YOPD are more predisposed to levodopa-induced dyskinesias (motor fluctuations)[19]. To overcome the losing effect of levodopa, two COMT inhibitors entacapone and tolcapone are used widely as the adjunctive therapy in the treatment of PD[6]. Based on the therapeutic evidence of PD patients with motor fluctuations, tolcapone displayed greater efficacy than entacapone[6]. However, there is little evidence on the use of tolcapone in pregnancy for women with PD, although entacapone has been used in some cases of medications of PD patients during pregnancy[9,17,20]. Referring to entacapone, animal studies have shown a teratogenic effect on fetal development[21]. Based on these results, women with PD were administered entacapone combined with levodopa/carbidopa, starting at week 21 of gestation after the fetal organogenesis period, and consequently delivered healthy babies[9,20]. Our study proved that tolcapone caused fetal malformation and delayed development in mice, however, depending on the dosage and the gestational stage. Our data showed that low dose tolcapone in mid-gestation might be safer for fetal formation, whereas smaller size of mouse fetus was observed. In addition, tolcapone induced hypertension in pregnancy, which has not been reported in the studies of antiparkinsonian drugs. The maternal preeclampsia-like complication needs to be pay special attention to in the future study.

Preeclampsia is a pregnancy associated disorder happened after 20 weeks of human gestation, with new-onset hypertension, proteinuria and most often with fetal intrauterine growth restriction[22]. It is widely accepted that preeclampsia is caused by shallow invasion of trophoblasts. The failure of trophoblast invasion to decidual arteries causes placental hypoxia and elevating anti-angiogenic cytokines released to maternal blood and consequently results in maternal hypertension[23,24]. We found preeclampsia-like phenotypes in tolcapone treated mice. The administration of tolcapone started at mid-gestation, which is the period of trophoblast invasion, and led to the hampered invasion of trophoblast in placenta and decidua. The *in vitro* experiments verified that tolcapone inhibited migration and invasion in trophoblasts

with changes in the EMT signaling. Consistently, excessive E-cadherin-mediated hampered trophoblast invasion has been implicated in patients with preeclampsia[25,26]. These findings suggest that the tolcapone-induced productive and development toxicity may share the similar mechanism of the preeclampsia etiology.

Placental morphological change is common in pregnant disorders. Severe placental defects were found in 68% of embryonic lethal genetic mutant mice, and the mutant gene functions in trophoblast cells caused more incidence of embryonic lethality[27]. We noted the abnormal spreading of spongiotrophoblast in tolcapone treated mouse placentas. Consistent with our observation, the infiltration of spongiotrophoblast cells in labyrinth zone was also detected in *Chtop*-/- and *Pth1r*-/- placentas with obvious fetal developmental delay[27,28], to date the pathogenesis is unknown. The biofunction of spongiotrophoblast layer is poorly understood, however, it could be supportive structure of the labyrinth and might change the vessels in placenta and modulate the exchange between mother and fetus[29]. In our study, the data indicated that tolcapone promoted cell proliferation in HTR8/SVneo and Bewo cells. Thus, one possible explanation could be that the hyperactivated proliferation of trophoblast resulted in the increased cell number of spongiotrophoblasts. However, to verify the hypothesis, detection of proliferating trophoblasts is necessary in the mouse placentas.

Conclusion

In the present study, we uncovered that tolcapone could cause abortion, fetal growth restriction and maternal hypertension and proteinuria in mice, depending on the dosage and the gestational stage when take tolcapone. Tolcapone inhibited the invasion of placental trophoblast *in vivo* and *in vitro*, which probably attributed to the regulation of Snail/Twist/E-cadherin signaling pathway. Our study provides information for using tolcapone in pregnancy with PD, and gives a new insight in understanding the pathogenesis of tolcapone mediated development toxicity.

Declaration of interest

The authors declare there is no conflict of interest that could be perceived as prejudicing the impartiality of the research reported.

Author Contributions

L.C., M.P., Q. J. and F. S. performed experiments and analyzed data. X.Y., Y. M., L. H. designed research and wrote the manuscript. All the authors have read and approved the final version of the manuscript.

Fundings

This work was supported by the National Natural Science Foundation of China (82271710, 82071669, 81960283, 82201874), the Natural Science Foundation of Guangdong Province (2022A1515010399, 2023A1515030222), the Science and Technology Program of Guangzhou (202102020282), the Natural Science Foundation of Hainan Province (822MS175), the Hainan Provincial Science and Technology Program for Clinical Medical Research Center (LCYX202102, LCYX202203, LCYX202301), the Hainan Province Clinical Medical Center and the specific research fund of The Innovation Platform for Academicians of Hainan Province.

References

1. Calne SM, Kumar A. Young onset Parkinson's disease. Practical management of medical issues. *Parkinsonism Relat Disord*. 2008;14:133-142. doi: 10.1016/j.parkreldis.2007.07.007
2. Golbe LI. Young-onset Parkinson's disease: a clinical review. *Neurology*. 1991;41:168-173. doi: 10.1212/wnl.41.2_part_1.168
3. Jankovic J, McDermott M, Carter J, Gauthier S, Goetz C, Golbe L, Huber S, Koller W, Olanow C, Shoulson I, et al. Variable expression of Parkinson's disease: a base-line analysis of the DATATOP cohort. The Parkinson Study Group. *Neurology*. 1990;40:1529-1534. doi: 10.1212/wnl.40.10.1529
4. Seier M, Hiller A. Parkinson's disease and pregnancy: An updated review. *Parkinsonism Relat Disord*. 2017;40:11-17. doi: 10.1016/j.parkreldis.2017.05.007
5. Mehanna R, Jankovic J. Young-onset Parkinson's disease: Its unique features and their impact on quality of life. *Parkinsonism Relat Disord*. 2019;65:39-48. doi: 10.1016/j.parkreldis.2019.06.001
6. Lees AJ. Evidence-based efficacy comparison of tolcapone and entacapone as adjunctive

therapy in Parkinson's disease. *CNS Neurosci Ther*. 2008;14:83-93. doi: 10.1111/j.1527-3458.2007.00035.x

7. Leegwater-Kim J, Waters C. Role of tolcapone in the treatment of Parkinson's disease. *Expert Rev Neurother*. 2007;7:1649-1657. doi: 10.1586/14737175.7.12.1649
8. Truong DD. Tolcapone: review of its pharmacology and use as adjunctive therapy in patients with Parkinson's disease. *Clin Interv Aging*. 2009;4:109-113. doi: 10.2147/cia.s3787
9. Basile S, Pinelli S, Garibaldi S, Altamura C, Calcagno M, Salerno MG. Cathecol-O-methyltransferase inhibitors: another possibly useful pharmacological tool for treating Parkinson's disease in pregnancy? *J Obstet Gynaecol*. 2017;37:381-382. doi: 10.1080/01443615.2016.1250735
10. Artusi CA, Sarro L, Imbalzano G, Fabbri M, Lopiano L. Safety and efficacy of tolcapone in Parkinson's disease: systematic review. *Eur J Clin Pharmacol*. 2021;77:817-829. doi: 10.1007/s00228-020-03081-x
11. Furukawa S, Kuroda Y, Sugiyama A. A comparison of the histological structure of the placenta in experimental animals. *J Toxicol Pathol*. 2014;27:11-18. doi: 10.1293/tox.2013-0060
12. Nardozza LM, Caetano AC, Zamarian AC, Mazzola JB, Silva CP, Marcal VM, Lobo TF, Peixoto AB, Araujo Junior E. Fetal growth restriction: current knowledge. *Arch Gynecol Obstet*. 2017;295:1061-1077. doi: 10.1007/s00404-017-4341-9
13. Chaiworapongsa T, Chaemsaithong P, Yeo L, Romero R. Pre-eclampsia part 1: current understanding of its pathophysiology. *Nature reviews Nephrology*. 2014;10:466-480. doi: 10.1038/nrneph.2014.102
14. Colson A, Sonveaux P, Debieve F, Sferruzzi-Perri AN. Adaptations of the human placenta to hypoxia: opportunities for interventions in fetal growth restriction. *Human reproduction update*. 2021;27:531-569. doi: 10.1093/humupd/dmaa053
15. Keating GM, Lyseng-Williamson KA. Tolcapone: a review of its use in the management of Parkinson's disease. *CNS Drugs*. 2005;19:165-184. doi: 10.2165/00023210-200519020-00006
16. Huang L, Ma Y, Chen L, Chang J, Zhong M, Wang Z, Sun Y, Chen X, Sun F, Xiao L, et al. Maternal RND3/RhoE deficiency impairs placental mitochondrial function in preeclampsia by modulating the PPARgamma-UCP2 cascade. *FASEB journal : official publication of the Federation of American Societies for Experimental Biology*. 2021;35:e21555. doi: 10.1096/fj.202002639RRR
17. Olivola S, Xodo S, Olivola E, Cecchini F, Londero AP, Driul L. Parkinson's Disease in Pregnancy: A Case Report and Review of the Literature. *Front Neurol*. 2019;10:1349. doi: 10.3389/fneur.2019.01349
18. Olanow CW, Watkins PB. Tolcapone: an efficacy and safety review (2007). *Clin Neuropharmacol*. 2007;30:287-294. doi: 10.1097/wnf.0b013e318038d2b6
19. Kostic V, Przedborski S, Flaster E, Sternic N. Early development of levodopa-induced dyskinesias and response fluctuations in young-onset Parkinson's disease. *Neurology*. 1991;41:202-205. doi: 10.1212/wnl.41.2_part_1.202
20. Serikawa T, Shimohata T, Akashi M, Yokoseki A, Tsuchiya M, Hasegawa A, Haino K, Koike R, Takakuwa K, Tanaka K, et al. Successful twin pregnancy in a patient with

parkin-associated autosomal recessive juvenile parkinsonism. *BMC Neurol*. 2011;11:72. doi: 10.1186/1471-2377-11-72

21. Hagell P, Odin P, Vinge E. Pregnancy in Parkinson's disease: a review of the literature and a case report. *Mov Disord*. 1998;13:34-38. doi: 10.1002/mds.870130110
22. Steegers EA, von Dadelszen P, Duvekot JJ, Pijnenborg R. Pre-eclampsia. *Lancet*. 2010;376:631-644. doi: 10.1016/S0140-6736(10)60279-6
23. Powe CE, Levine RJ, Karumanchi SA. Preeclampsia, a disease of the maternal endothelium: the role of antiangiogenic factors and implications for later cardiovascular disease. *Circulation*. 2011;123:2856-2869. doi: 10.1161/CIRCULATIONAHA.109.853127
24. Rana S, Lemoine E, Granger JP, Karumanchi SA. Preeclampsia: Pathophysiology, Challenges, and Perspectives. *Circulation research*. 2019;124:1094-1112. doi: 10.1161/CIRCRESAHA.118.313276
25. Li HW, Cheung AN, Tsao SW, Cheung AL, O WS. Expression of e-cadherin and beta-catenin in trophoblastic tissue in normal and pathological pregnancies. *International journal of gynecological pathology : official journal of the International Society of Gynecological Pathologists*. 2003;22:63-70.
26. Jie Q, Sun F, Li Q, Zhu J, Wei Y, Yang H, Long P, Wang Z, Yang X, Li D, et al. Downregulated ribosomal protein L39 inhibits trophoblast cell migration and invasion by targeting E-cadherin in the placenta of patients with preeclampsia. *FASEB journal : official publication of the Federation of American Societies for Experimental Biology*. 2021;35:e21322. doi: 10.1096/fj.202002061R
27. Perez-Garcia V, Fineberg E, Wilson R, Murray A, Mazzeo CI, Tudor C, Sienerth A, White JK, Tuck E, Ryder EJ, et al. Placentation defects are highly prevalent in embryonic lethal mouse mutants. *Nature*. 2018;555:463-468. doi: 10.1038/nature26002
28. Dickinson ME, Flenniken AM, Ji X, Teboul L, Wong MD, White JK, Meehan TF, Weninger WJ, Westerberg H, Adissu H, et al. High-throughput discovery of novel developmental phenotypes. *Nature*. 2016;537:508-514. doi: 10.1038/nature19356
29. Simmons DG, Cross JC. Determinants of trophoblast lineage and cell subtype specification in the mouse placenta. *Developmental biology*. 2005;284:12-24. doi: 10.1016/j.ydbio.2005.05.010

Figure 1. Administration of tolcapone at early gestation resulted in abortion, fetal growth restriction and placental damage. A. Schematic representation of administration of tolcapone. Tolcapone was applied by i.h. injection for 17 days starting at gestational D0.5. **B.** Maternal weight during pregnancy with or without tolcapone. H-Tol, high dosage tolcapone; L-Tol, low dosage tolcapone; * indicates $p<0.05$ in a comparison of saline group with L-Tol group; ** indicates $p<0.01$ in a comparison of saline group with L-Tol group. **C.** Smaller fetal size was observed in the mice with L-Tol comparing with the saline control group. **D.** Number of live pups and fetal resorption rate per litter. **E.** Fetal weight and placental weight in mice with

or without tolcapone. **F.** Representative H&E staining images of placental tissue sections. Labyrinth zone (LZ) and junction zone (JZ) were indicated by dotted line. The right panel images were zoomed from the left panel showing increased fibrin deposit (marked with arrows) and vascular thrombus (marked with a star) in the placentas from L-Tol group. **G.** Ratio of areas of labyrinth zone over junction zone of placentas. **H.** Maternal systolic blood pressure (SBP) of mice with or without tolcapone treatment was measured during the whole gestation.

Figure 2. Administration of tolcapone at mid-gestation resulted in fetal growth restriction, maternal gestational hypertension, proteinuria and placental abnormalities. A. Schematic representation of administration of tolcapone. Tolcapone was applied by i.h. injection starting at gestational D9.5 and lasting to D17.5. **B.** Maternal weight during pregnancy with or without tolcapone. **C.** Both L-Tol mice and H-Tol mice showed smaller fetal size when compared with the saline control group. **D.** Malformation of embryo from H-Tol mice. **E.** Number of live pups per litter. **F.** Quantification of fetal resorption rate per litter. **G.** Fetal weight and placental weight in the mice of the three groups. **H.** Representative H&E staining images of placental tissue sections. Labyrinth zone (LZ) and junction zone (JZ) were indicated by dotted line. The penetration of spongiotrophoblast cells (SP) in LZ were shown in the placentas from L-Tol and H-Tol mice at the lower panel. de: decidua, gc: trophoblast giant cell. **I.** Ratio of areas of labyrinth zone over junction zone of placentas. **J.** Maternal systolic blood pressure (SBP) of mice was evaluated among the three groups during the whole gestation. α indicates $p<0.05$ in a comparison of saline group with L-Tol group; β indicates $p<0.05$ in a comparison of saline group with H-Tol group. **K.** Urine protein concentration of maternal mice was examined among the three groups at the gestational day 17.5.

Figure 3. Tolcapone repressed placental trophoblast invasion in mice. A. Representative images for immunostainings of cytokeratin 8 (CK8) and α-smooth muscle actin (α-SMA) in a continuous series of placental sections. Stars indicated the

invasion distance of trophoblast (CK8 positive cells) in maternal decidua (α-SMA labeled zone). **B.** Relative invasion area of trophoblast into decidua was quantified. **C.** Protein expression level of E-cadherin was detected in placental tissues.

Figure 4. Tolcapone inhibited cell invasion in HTR8/SVneo cells. A. Cell viability assay. HTR8/SVneo cells were treated with various dose of tolcapone for 48 h. Cell viability was measured by CCK8 assay. **B.** Wound healing assay of HTR8/SVneo cells treated with 25mM or 35mM tolcapone for 48 h. **C.** Quantification of relative healing wound width is shown. **D.** Measurement of cell migration by transwell assay. HTR8/SVneo cells were treated with 25mM or 35mM tolcapone for 24 h. **E.** Measurement of cell invasion by transwell assay. HTR8/SVneo cells treated with 25mM or 35mM tolcapone for 24 h. **F.** Protein expression levels of E-cadherin, Snail and Twist were detected in cells treated with 35mM tolcapone.

Figure 5. Tolcapone induced proliferation in trophoblasts. A. Cell viability assay for the HTR8/SVneo cells treated with various dose of tolcapone for 72 h. α indicates $p<0.05$ in a comparison of 25 mM group with 0 mM group; β indicates $p<0.05$ in a comparison of 5 mM group with 0 mM group; γ indicates $p<0.05$ in a comparison of 15 mM group with 0 mM group. **B.** Representative BrdU staining images of HTR8/SVneo cells treated with tolcapone. **C.** Representative BrdU staining images of Bewo cells treated with tolcapone.

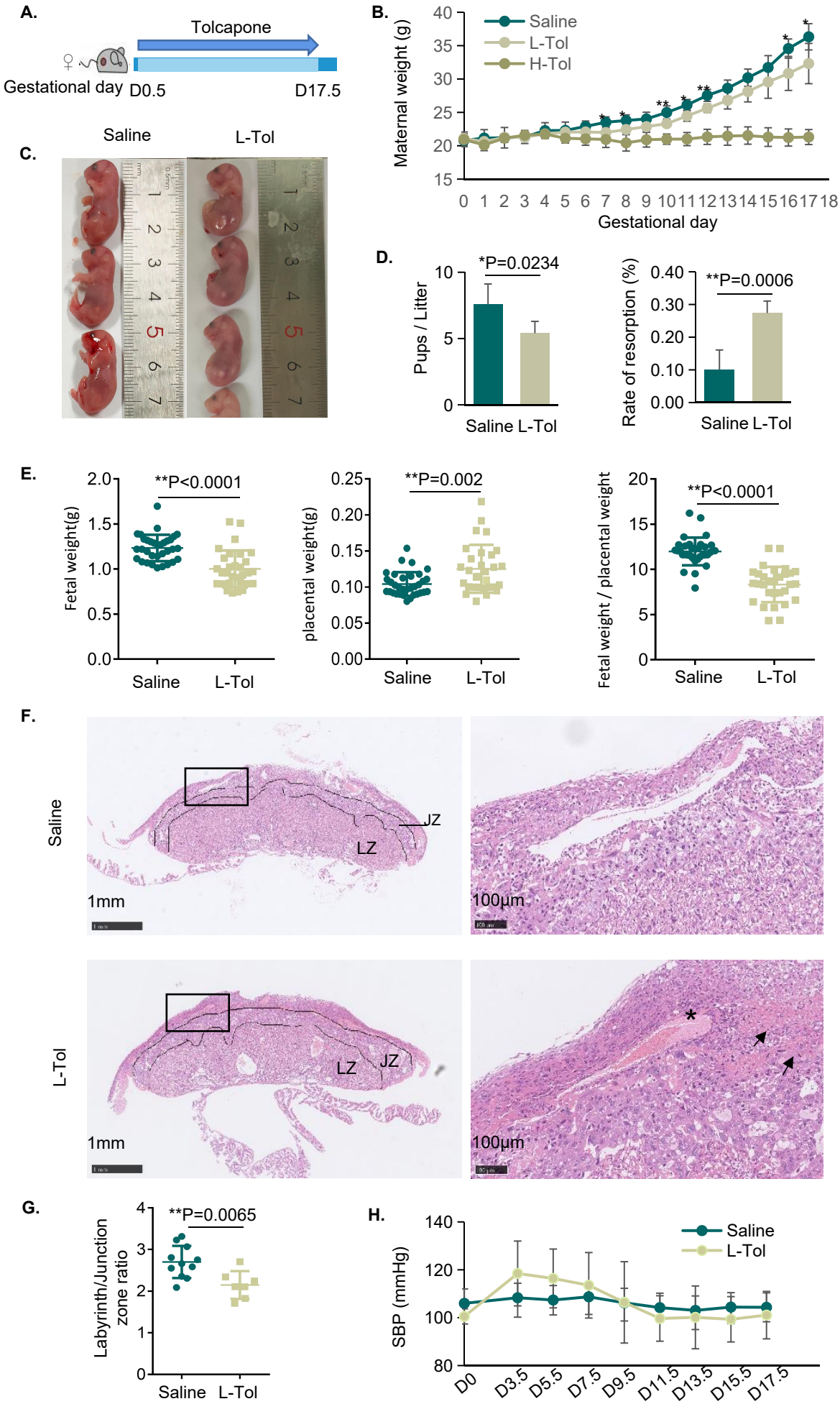
A.
Tolcapone
Gestational day D0.5
D17.5
B.
Saline
L-Tol
H-Tol
Maternal weight (g)
Gestational day
C.
Saline
L-Tol
D.
*P=0.0234
Pups / Litter
Saline L-Tol
**P=0.0006
Rate of resorption (%)
Saline L-Tol
E.
**P<0.0001
Fetal weight(g)
Saline
L-Tol
**P=0.002
placental weight(g)
Saline
L-Tol
**P<0.0001
Fetal weight / placental weight
Saline
L-Tol
F.
Saline
JZ
LZ
1mm
100μm
L-Tol
LZ
JZ
1mm
100μm
G.
**P=0.0065
Labyrinth/Junction zone ratio
Saline
L-Tol
H.
Saline
L-Tol
SBP (mmHg)
D0
D3.5
D5.5
D7.5
D9.5
D11.5
D13.5
D15.5
D17.5

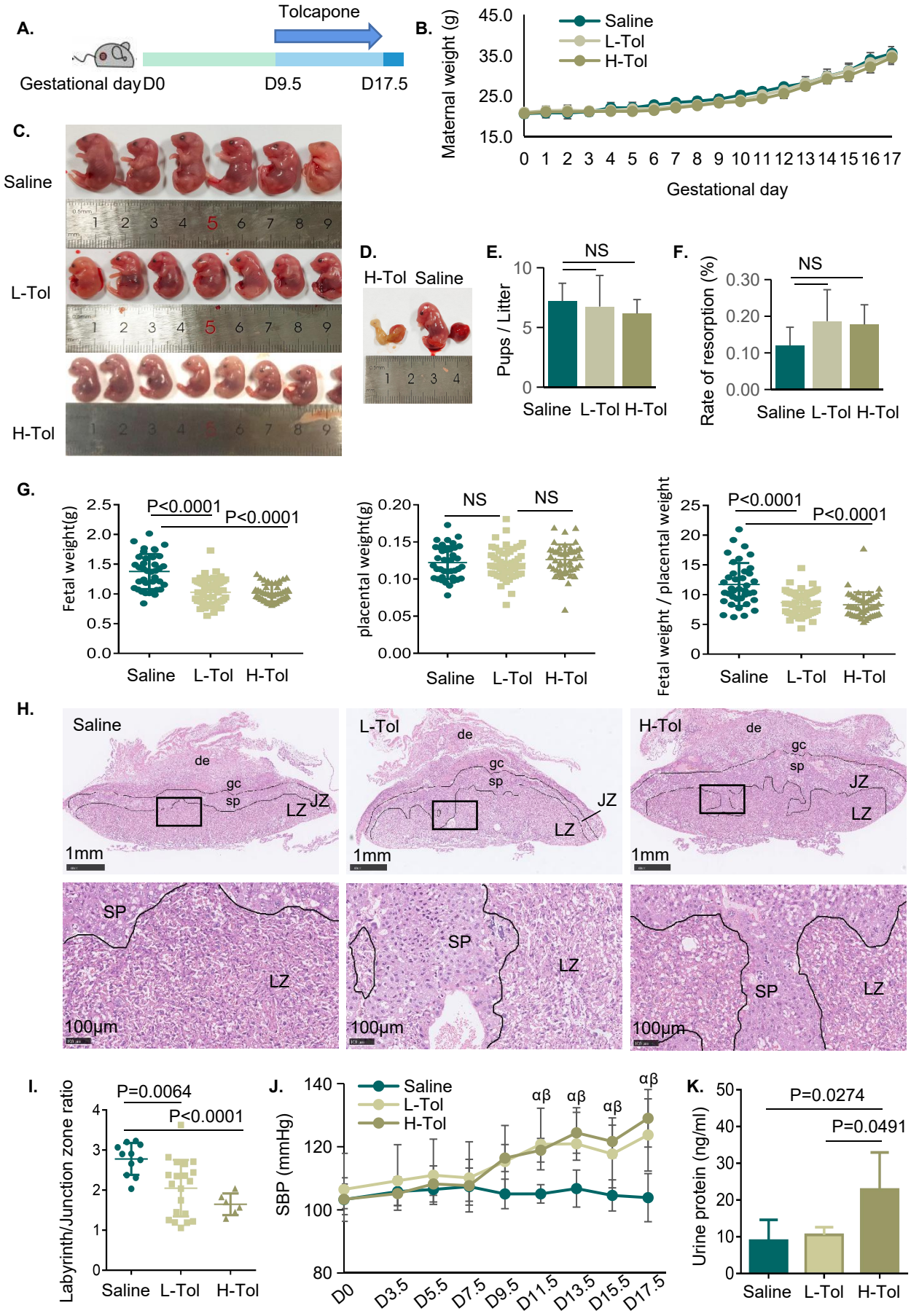
A.
Tolcapone
Gestational day D0
D9.5
D17.5
B.
Maternal weight (g)
Saline
L-Tol
H-Tol
Gestational day
C.
Saline
L-Tol
H-Tol
D.
H-Tol Saline
E.
NS
Pups / Litter
Saline L-Tol H-Tol
F.
NS
Rate of resorption (%)
Saline L-Tol H-Tol
G.
P<0.0001
P<0.0001
Fetal weight(g)
Saline L-Tol H-Tol
NS
NS
placental weight(g)
Saline L-Tol H-Tol
P<0.0001
P<0.0001
Fetal weight / placental weight
Saline L-Tol H-Tol
H.
Saline
de
gc
sp
LZ
JZ
1mm
L-Tol
H-Tol
SP
100μm
I.
P=0.0064
P<0.0001
Labyrinth/Junction zone ratio
Saline L-Tol H-Tol
J.
Saline
L-Tol
H-Tol
αβ
SBP (mmHg)
D0 D3.5 D5.5 D7.5 D9.5 D11.5 D13.5 D15.5 D17.5
K.
P=0.0274
P=0.0491
Urine protein (ng/ml)
Saline L-Tol H-Tol

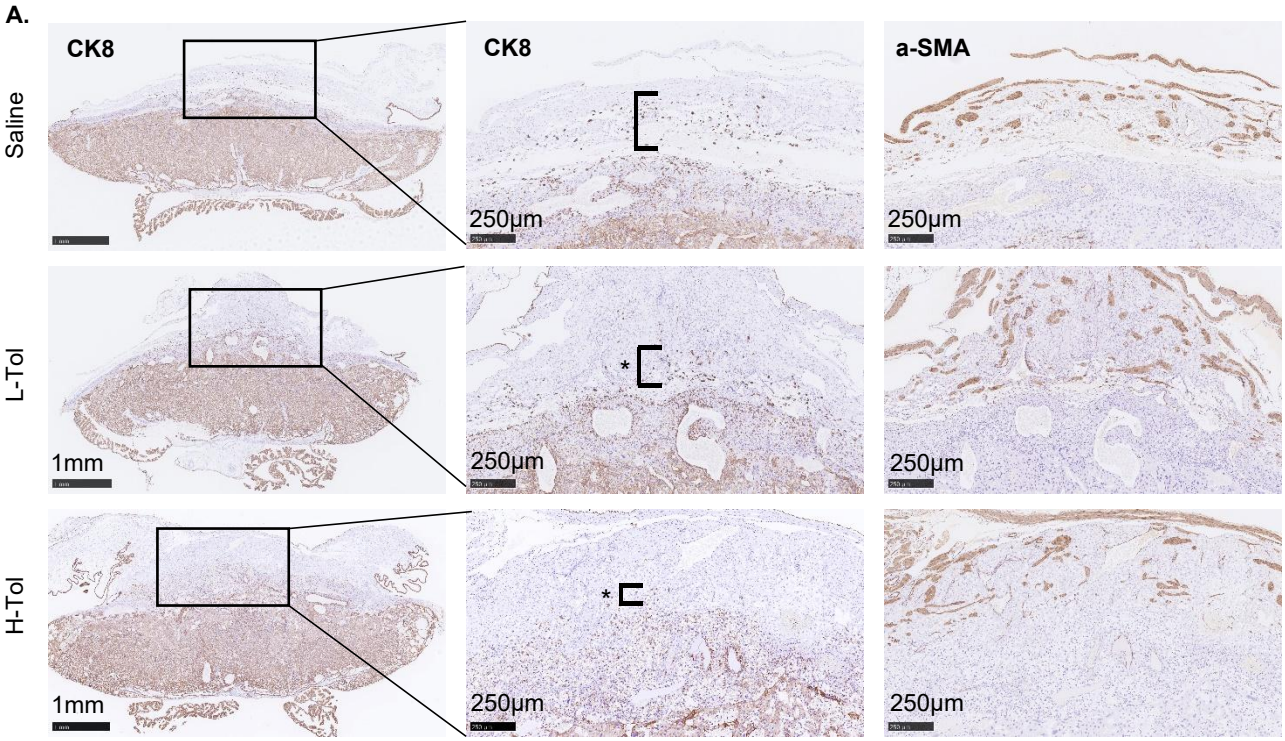
A.
CK8
CK8
a-SMA
Saline
L-Tol
H-Tol
250μm
250μm
250μm
1mm
250μm
250μm
1mm
250μm
250μm

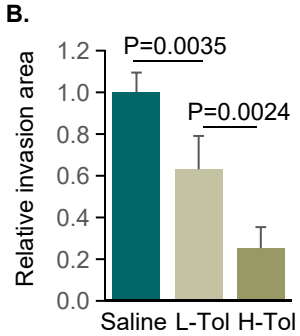
B.
Relative invasion area
1.2
1.0
0.8
0.6
0.4
0.2
0.0
P=0.0035
P=0.0024
Saline
L-Tol
H-Tol

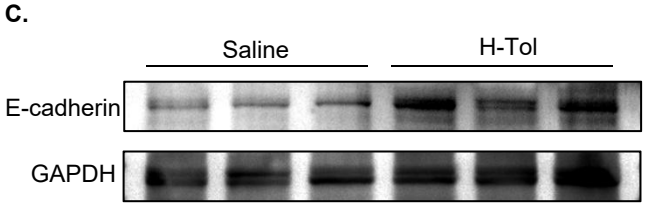
C.
Saline
H-Tol
E-cadherin
GAPDH

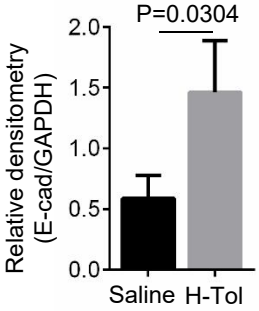
Relative densitometry
(E-cad/GAPDH)
2.0
1.5
1.0
0.5
0.0
P=0.0304
Saline
H-Tol

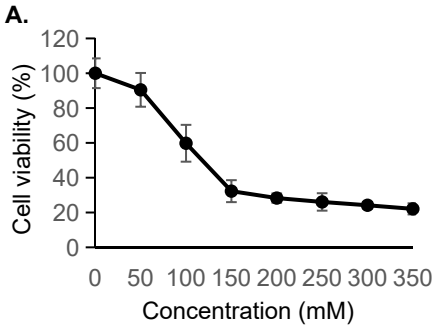
A.
Cell viability (%)
120
100
80
60
40
20
0
0 50 100 150 200 250 300 350
Concentration (mM)


B.
0 mM
25 mM
35 mM
0h
24h
48h
200μm

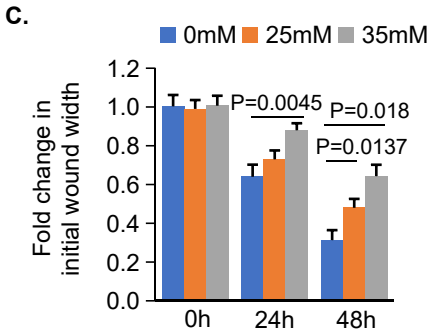
C.
0mM 25mM 35mM
Fold change in initial wound width
1.2
1.0
0.8
0.6
0.4
0.2
0.0
P=0.0045
P=0.018
P=0.0137
0h
24h
48h

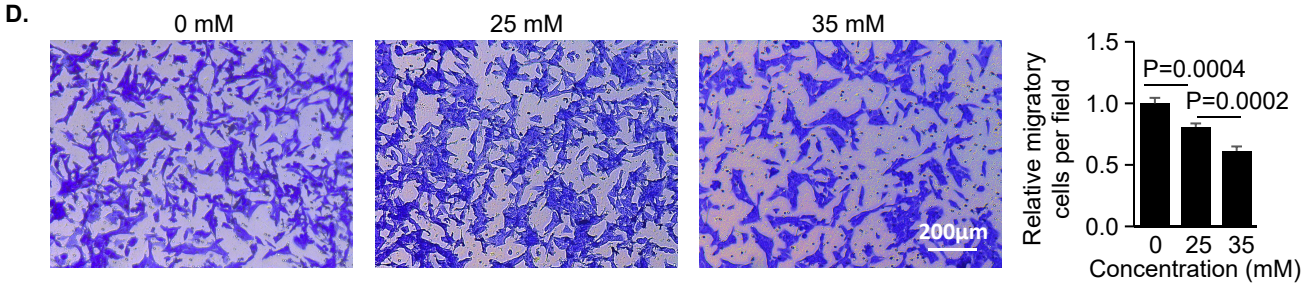
D.
0 mM
25 mM
35 mM
200μm
Relative migratory cells per field
1.5
1.0
0.5
0.0
P=0.0004
P=0.0002
0 25 35
Concentration (mM)

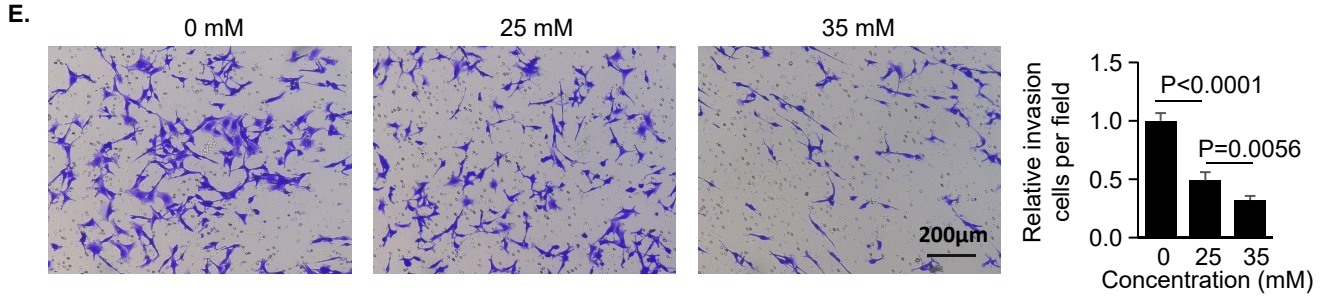
E.
0 mM
25 mM
35 mM
200μm
Relative invasion cells per field
1.5
1.0
0.5
0.0
P<0.0001
P=0.0056
0 25 35
Concentration (mM)

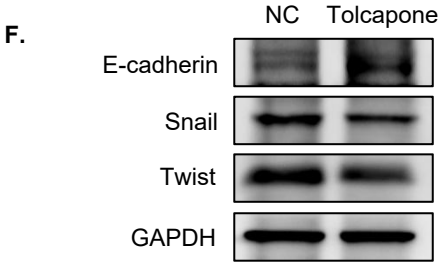
F.
NC
Tolcapone
E-cadherin
Snail
Twist
GAPDH

A.

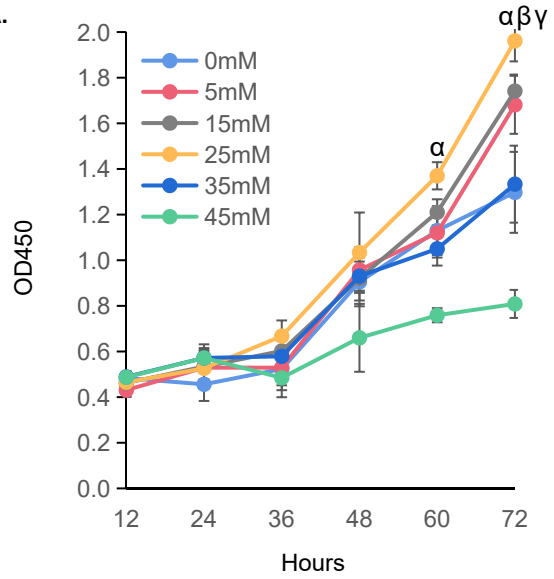
αβγ
α
0mM
5mM
15mM
25mM
35mM
45mM
OD450
2.0
1.8
1.6
1.4
1.2
1.0
0.8
0.6
0.4
0.2
0.0
12
24
36
48
60
72
Hours

B.

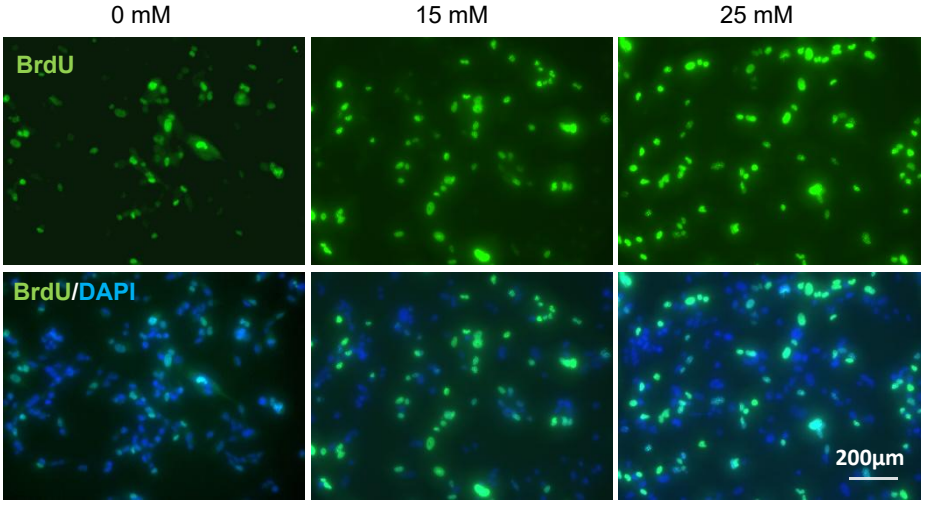
0 mM
15 mM
25 mM
BrdU
BrdU/DAPI
200μm

C.

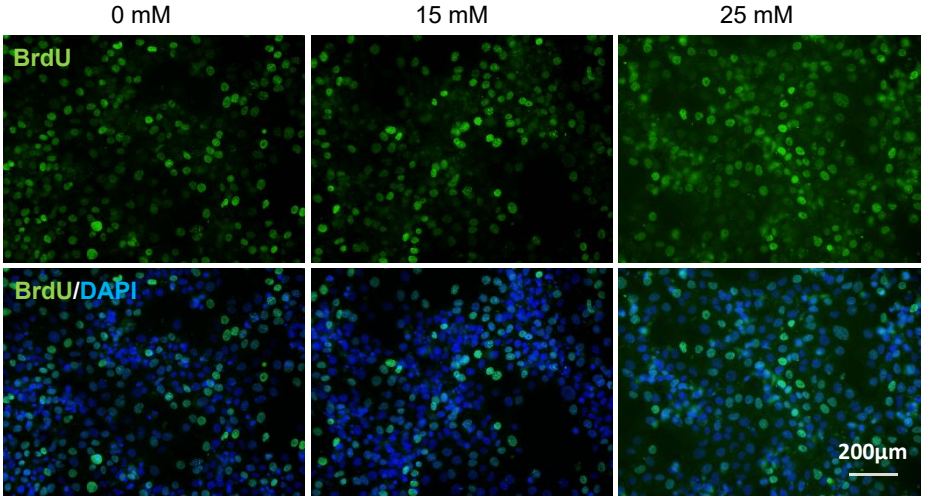
0 mM
15 mM
25 mM
BrdU
BrdU/DAPI
200μm