Angiogenic Steroids Induce Pathologic Scarring in a Preclinical Swine Model Via Dysfunctional Extracellular Matrix Deposition.

Erik Reiche, MD[1]*; Patrick R Keller, MD[2]; Vance Soares, MSE[2]; Calvin R Schuster, BA[2], Jessica Mroueh, MD[1]; Vanessa Mroueh, MD[1]; Yu Tan, PhD[1]; Seo Young Kim[3]; Marie Billaud, PhD[4]; Annie E Newell-Fugate, CVM, MSc, PhD[5]; Christine G Lian, MD[3]; Devin O'Brien-Coon, MD, MSE[1,2]*

(1) Division of Plastic Surgery, Brigham and Women's Hospital, Harvard Medical School; Boston, MA, USA.

(2) Departments of Plastic and Reconstructive Surgery and Biomedical Engineering, Johns Hopkins University School of Medicine; Baltimore, MD, USA.

(3) Department of Pathology, Brigham and Women's Hospital, Boston, Massachusetts, USA

(4) Division of Thoracic and Cardiac Surgery, Brigham and Women's Hospital and Harvard Medical School, Boston, MA, United States.

(5) Department of Veterinary Physiology and Pharmacology, 4466 TAMU, Texas A&M University, College Station, Texas 77845, USA.

*Corresponding authors. ereiche@bwh.harvard.edu and dcoon@bwh.harvard.edu

Abstract:

Background: Hypertrophic scarring is a major source of morbidity for surgery patients. An increasing number of transgender patients undergo surgery while on exogenous hormones. Based on clinical observations of increased frequency of post-op hypertrophic scarring in transgender males, we hypothesized that androgenic steroids lead to abnormal scarring and developed a preclinical swine model to characterize these observed effects.

Methods: A total of six male (XY) and female (XX) Hanford mini-swine underwent castration (ovariectomy/orchiectomy) and were randomly assigned to no testosterone (noT) or biweekly testosterone therapy (+T). Ten 3.5cm dorsal excisional wounds were created on each pig. To mimic a chronic wound, some wounds were re-excised at two weeks. Scars (POD42) and chronic wounds (POD28) were harvested six weeks after initial wounding and underwent analysis via histology, RNA seq, and tensile strength testing. Freshly excised tissue allocated for tensile testing was measured to obtain a cross-sectional area for normalization, loaded onto a 100N force-displacement apparatus, and subjected to a constant strain rate until burst failure.

Results: Histologic analysis of chronic POD28 wounds showed increased granulation tissue area ($0.52cm^2$ for XXnoT, $0.66cm^2$ for XX+T, $0.88cm^2$ for XY+T, $p=0.039$) as well as increased epithelial thickness in the testosterone-treated groups ($0.45cm^2$ for XXnoT, $0.62cm^2$ for XX+T, $0.68cm^2$ for XY+T, $p=0.05$). POD42 scars from the +T swine showed increased mean fibrosis area compared to XXnoT swine ($0.157cm^2$ noT, $0.290cm^2$ XX+T, $0.268cm^2$ XY+T; $p=0.007$). Mean fibrosis thickness was also increased in the scars from T-treated swine ($0.246cm^2$ noT, $0.389cm^2$ XX+T; $0.423cm^2$ XY+T; $p<0.001$). Scar tissue analyzed with mass spectrometry showed samples from noT swine had lower testosterone levels compared to the +T swine ($p< 0.001$). Scars in XX+T and XY+T pigs had greater tensile burst strength ($p=0.024$ and $p=0.013$ respectively) compared to scars in noT swine.

Conclusion: We developed a novel preclinical model to study the effects of the sex hormone testosterone on scarring. Testosterone induces early proliferation of excessive granulation tissue, which eventually leads to increased scar tissue. T appears to increase the physical strength of scars via supraphysiologic deposition of collagen and other ECM factors. The increase in burst strength observed for both XX and XY suggests that hormonal administration is a stronger influence on mechanical properties than karyotype. Anti-androgen topical therapies are a promising future area of research.

Introduction

There are nearly 25 million transgender and gender nonbinary (TGNB) individuals worldwide, and this number is rapidly increasing.[1–4] As gender-affirming care (GAC) becomes more accessible, there has been a growing utilization of gender-affirming surgeries (GAS).[1] Many TGNB patients use exogenous testosterone therapy (T) as part of GAC. Wound healing complications and hypertrophic scarring are major sources of morbidity for GAS. Despite this, little is currently known about the impact of exogenous testosterone on scarring. We have anecdotally observed an increased frequency of post-operative hypertrophic scarring in transgender men undergoing GAS. Following this observation, we conducted a blinded analysis of a single-institution prospective registry of chest masculinization surgery outcomes using the Manchester Scar Scale and SCARS scale to quantify the impact of preoperative testosterone level and weekly exogenous testosterone dose on scar outcome. We found that increasing testosterone levels correlate with hypertrophic scarring.

Our team previously developed a novel mouse model of the GAS hormonal milieu and studied the effects of exogenous testosterone on cutaneous wound healing (WH) in XX mice.[5] We demonstrated that T significantly impairs WH. We therefore hypothesized that T might affect scarring as well. However, there are significant limitations of small animal models to capture translationally relevant differences in scarring due to well-established histological skin differences between rodent models and humans.[6] We developed a GAS hormonal milieu model in swine, a more optimal option for modeling human scarring.

Understanding the impact of T on WH and scarring has the potential to rewrite perioperative guidelines for GAS. Traditional practices of holding testosterone perioperatively were based on concerns about thrombocytosis, hypertension and thromboembolic events, but recent studies suggest these concerns are largely theoretical.[7] Increasing trends therefore are towards continuation, but these studies do not address scar results, potentially resulting in perioperative

use of a medication that delays WH and increases scar hypertrophy. In this study, we hypothesized that exogenous testosterone therapy increases scarring.

Methods:

Swine model

A total of six, six-month-old Hanford miniature swine were included in the study (Sinclair BioResources, Auxvasse, MO, USA). A central venous indwelling catheter was surgically inserted into each swine under general anesthesia 14 days before cutaneous wounding. XX swine (n=4) also received bilateral ovariectomies (OVX) during this procedure, while XY swine (n=2) were offered by the vendor castrated before delivery.

Animals underwent dorsal wounding on POD0, two weeks after initial surgery and hormone induction. Excisional 3.5cm wounds (n=10) were created on the dorsum of each swine without excising fascia or muscle (**Fig. 1**). Wounds were dressed individually with Tegaderm (3M, Saint Paul, MN, USA) and subsequently collectively dressed with gauze pads, Ioban Antimicrobial Incise Drape (3M, Saint Paul, MN, USA), and Vetrap elastic bandages (3M, Saint Paul, MN, USA). Wounds were cleaned, and dressings were changed every 72 hours for the first two weeks and every 5 days afterward.

Four wounds on each swine were re-excised on POD14 with a 15-surgical blade to mimic a chronic wound environment. Six weeks after the initial wounding, scars (POD42) and chronic wounds (POD28) were harvested (**Fig. 1**). All protocols were approved by the Johns Hopkins ACUC.

Hormone dosing and measurement

The utilized testosterone regimen was based on our lab's previous small animal models as well as work conducted by Kothmann et al.[5,8] Testosterone cypionate (West-Ward Pharmaceuticals

Eatontown, NJ, USA) was diluted with pharmaceutical-grade sesame oil (Sigma-Aldrich, St. Louis, MO, USA) to reach a concentration of 100mg/ml. A total of four swine (two XX and two XY) received biweekly 1mg/kg/dose testosterone injections.

T levels were measured both in serum and scar tissue samples. Blood samples were collected twice a week and centrifuged to separate the serum. Serum was stored at -20°C and testosterone levels were analyzed via liquid chromatography-mass spectrometry (LC-MS) (Texas A&M University, College Station, TX, USA). Tissue samples of around 200mg were homogenized in hexane saturated with methanol. The collected extract was evaporated to dryness and reconstituted with the acidic aqueous solution. Standard liquid chromatography-mass spectrometry methods for sample preparation and determination of steroid levels were subsequently followed (BRAC Lab, Boston, MA, USA).

Tensile strength testing

Durometer readings for 28-day and 42-day peripheral and central wounds were taken prior to excision. Dimensions of excised scars were measured to normalize by cross-sectional area. Strips of excised scar were loaded onto a 100N load cell force-displacement apparatus. Samples were stretched at a constant strain rate (1mm/sec) until failure. Durometer, stress-strain curves, Young's Modulus (YM), and ultimate tensile burst strength were analyzed. Wilcoxon Mann-Whitney tests were performed and $p\text{-value}<0.05$ were considered statistically significant.

Histology

Sections of scar and wound tissue were fixed with 10% formalin for 48 hours and embedded in paraffin blocks. Four-micrometer sections of tissue were created and stained with H&E and Manson's Trichrome stain. Slides were scanned with a Vectra Polaris (Akoya, Marlborough, MA). The granulation tissue area and fibrosis tissue area on each slide were measured by three blinded

reviewers using Concentriq interphase (Proscia, Philadelphia, US). Analysis of variance was performed with significance set at <0.05.

Results:

Validation of a clinically relevant porcine testosterone dosing regimen.

Serum levels were consistent over time. Swine injected with exogenous testosterone therapy showed a significant increase in serum testosterone levels relative to the no-T group (5.9ng/dL XXnoT, 189.9ng/dL XX+T, 221.8ng/dL XY+T; p<0.01). Swine serum estradiol levels did not differ between hormone regimen experimental groups (5.07pg/ml XXnoT, 13.48pg/ml XX+T, 8.61pg/ml XY+T; TTest XXnoT vs XX+T p=0.203; TTest XXnoT vs XY+T p=0.471) (**Fig. 2).**

Scar tissue hormone levels correlate with serum levels.

Swine scar tissue (POD42) and chronic wound samples (POD28) from animals treated with T showed increased levels of testosterone compared to animals not treated with T (0.76ng/gr of tissue XXnoT, 1.60ng/gr XX+T, 1.97ng/gr; p=0.007). Estradiol tissue levels did not differ between groups (7.17pg/ml XXnoT, 10.23pg/ml XX+T, 6.39pg/ml XY+T; TTest XXnoT vs XX+T p=0.492, TTest XXnoT vs XY+T p=0.567)

Testosterone-exposed scars and chronic wounds demonstrate greater histologic thickness and width.

Histologic analysis of chronic POD28 wounds showed increased granulation tissue (GT) area (0.52cm^2 for XXnoT, 0.66cm^2 for XX+T, 0.88cm^2 for XY+T, p=0.039) as well as increased epithelial thickness in the testosterone-treated groups (0.45cm^2 for XXnoT, 0.62cm^2 for XX+T, 0.68cm^2 for XY+T, p=0.05).

POD42 samples from the +T swine showed increased mean scar area compared to XXnoT swine (0.157cm^2 noT, 0.290cm^2 XX+T, 0.268 cm^2 XY+T; p=0.007). Mean scar thickness was also

increased in the scars from T-treated swine (0.246cm^2 noT, 0.389 cm^2 XX+T; 0.423cm^2 XY+T; p<0.001) (**Fig. 3**).

T-exposed scars demonstrate greater tensile strength.

The centers, but not peripheries, of wounds had higher durometer at day 42 than day 28 (48.2 Shore OO hardness scale for day 42, 41.7 for day 28; p=0.03). The mean and standard deviation of YM of 42-day (0.01000 MPa, 0.00743 MPa) scars was slightly higher than 28-day (0.00738 MPa, 0.00548 MPa) wounds, but not significantly so. Adjusted burst strength of scars from swine exposed to T were higher compared to controls (0.81 MPa for all -T vs 1.30 MPa for all +T; p=0.001, 0.81 XXnoT vs 1.29 MPa XX+T p=0.02; 0.81 MPa XXnoT vs 1.31 MPa XY+T p=<0.01). There was no significant difference in burst strength between XX+T and XY+T. **(Fig. 3)**.

Discussion

In this study, we created a novel large animal cutaneous wound healing model that mimics the hormonal milieu associated with gender-affirming surgery to study the effects of exogenous testosterone therapy on scarring and fibrosis. Scarring is a major source of postsurgical morbidity, representing both a physical and economic burden for patients. An estimated 100 million patients annually acquire scars from surgery, which can result in psychological distress and complications such as pain.[9–11] Keloid and hypertrophic scarring in particular are associated with greater morbidity. In hypertrophic scars, myofibroblasts persist after epithelialization, leading to painful and functionally limiting skin contractures. Financially, there is an estimated $12 billion market in the United States for scar treatment.[12]

Gender-affirming surgery (GAS), a critically understudied subspecialty of reconstructive plastic surgery, is a vital component of life-saving care for transgender and gender diverse (TGD) individuals. An increasing number of TGD people are seeking GAS annually, making it even more

vital to address gaps in medical knowledge related to GAS. Many patients use exogenous testosterone therapy (T) as part of their care and scar-related morbidity is common after gender-affirming surgery. Despite this, while work has been published about the impact of testosterone on wound healing in rodent models, little is currently known about the impact of exogenous testosterone on scar formation.[5,13–15]

To address this issue, we investigated the impact of testosterone on scarring. First, we developed and validated a preclinical porcine model of exogenous testosterone therapy in swine. Swine were injected with exogenous testosterone to increase their serum testosterone levels to a desired consistent pattern over time.

We hypothesized that tissue hormone levels would be correlated to serum hormone levels and developed a protocol to test this. We demonstrated that scar tissue samples from noT swine had lower T levels compared to scar tissue samples from +T swine. Given that estrogen has been proven to improve wound healing, we tested estradiol levels from both serum and scar samples and found no differences between group 17-b-estradiol levels in both serum and tissue.

We used this novel swine model to characterize the effects of androgenic steroids on scarring. Chronic wounds showed increased granulation tissue area in +T compared to noT swine. Similarly, we demonstrated that +T swine showed increased mean scar area and thickness compared to noT swine.

This study is the first to elucidate how testosterone impacts the tensile strength and elasticity of scar. Using a 100N load cell force-displacement apparatus, we assessed the tensile strength of scar tissue from +T swine and noT swine. The observed increase in tensile burst strength of scars from both XX+T and XY+T swine compared to noT swine suggests that exogenous testosterone has a stronger influence on the mechanical properties of scars than karyotype. These findings

suggest that testosterone induces early excess angiogenesis and proliferation of granulation tissue which may then lead to increased scar tissue development.

Testosterone appears to increase the physical strength of scars, possibly via supraphysiologic deposition of collagen and other extracellular matrix factors. Scar formation and remodeling typically begins two to three weeks after injury occurs and can last for months to over a year. In remodeling, type III collagen and proteoglycans are replaced with type I collagen, and the orientation of collagen fibrils becomes more organized. This collagen rearrangement corresponds with an increase in wound tensile strength. Unlike collagen, elastin is absent from the granulation tissue deposited by fibroblasts. The lack of elastin, which provides elastic recoil for the dermal matrix, results in a more rigid and inelastic extracellular matrix.

The results of this project are important to human health. As more research is published on the complication rates of gender-affirming surgeries and the relative safety of continued exogenous testosterone use during the perioperative period, more and more surgeons do not require TGD patients to pause exogenous hormone therapy.[7] While the movement toward continuing exogenous hormone use circumvents any potential distress patients may experience when required to pause an important aspect of gender-affirming care, the continued use of exogenous testosterone during the perioperative period could bring greater scarring morbidity.[16] It is therefore important to find therapeutic approaches that might exert localized anti-androgenic properties without systemic effects. The development of topical antiandrogens that competitively bind to androgen receptors represents a promising area of future research as a novel approach to controlling the tissue repair cascade through the sex hormone axis.

Conclusions:

We developed a novel preclinical model to study the effects of the sex hormone testosterone on scarring. Testosterone induces early proliferation of excessive granulation tissue, which

eventually leads to increased scar tissue. T appears to increase the physical strength of scars via supraphysiologic deposition of collagen and other ECM factors.

Figure Legends:

Figure 1. Swine cutaneous scarring model. (**a**) Six male (XY) and female (XX) swine underwent castration (ovariectomy/orchiectomy) and were randomly assigned to no testosterone or biweekly testosterone therapy. (**b,c**) Ten 3.5 cm dorsal excisional wounds were created on each pig. (**d, e, f**) To mimic a chronic wound, four wounds on each swine were re-excised at POD14. Six weeks after initial wounding (**g**), POD42 scar tissue (**h**) and POD28 chronic wounds (**i**) were harvested six weeks after initial cutaneous wounding.

Figure 2. Steroid hormone levels in swine serum and tissue. (**a.**) +T swine showed a significant increase in serum testosterone levels relative to the no-T group (5.9ng/dL XXnoT, 189.9ng/dL XX+T, 221.8ng/dL XY+T; $p<0.01$). (**b)** Swine serum estradiol levels did not differ between hormone regimen experimental groups (5.07pg/ml XXnoT, 13.48pg/ml XX+T, 8.61pg/ml XY+T; TTest XXnoT vs XX+T $p=0.203$; TTest XXnoT vs XY+T $p=0.471$). (**c**) Swine scar tissue (POD42) and chronic wound samples (POD28) from animals treated with T showed increased levels of testosterone compared to animals not treated with T (0.76ng/gr of tissue XXnoT, 1.60ng/gr XX+T, 1.97ng/gr; $p=0.007$). (**d**) Estradiol tissue levels did not differ between groups (7.17pg/ml XXnoT, 10.23pg/ml XX+T, 6.39pg/ml XY+T; TTest XXnoT vs XX+T $p=0.492$, TTest XXnoT vs XY+T $p=0.567$).

Figure 3. Histology and burst strength analysis. POD42 Scars from (**a**) XXnoT, (**b**) XX+T, and (**c**) XY+T swine. (**d**) POD42 scars from the +T swine showed increased mean scar tissue area compared to XXnoT swine (0.157cm^2 noT, 0.290cm^2 XX+T, 0.268cm^2 XY+T; $p=0.007$). (e,f) Adjusted burst strength of scars from swine exposed to T were higher compared to controls (0.81

MPa for all -T vs 1.30 MPa for all +T; p=0.001, 0.81 XXnoT vs 1.29 MPa XX+T p=0.02; 0.81 MPa XXnoT vs 1.31 MPa XY+T p=<0.01).

Author Contributions

ER, PRK, ANF, DOC conceptualized the study. ER, PRK, DOC performed animal surgeries and care. VS, CRS designed and performed tensile strength tests. JM, VM, SYK, MB, CGL conceptualized Immunofluorescence and histology staining and quantification. ER, VS, CRS, JM, VM, YT, SYK, MB, CGL were responsible for data collection and analysis. ER, VS, CRS, DOC wrote the manuscript and prepared figures. DOC supervised the study. All authors edited the manuscript for intellectual content.

References:

1. Nolan, I. T., Kuhner, C. J. & Dy, G. W. Demographic and temporal trends in transgender identities and gender confirming surgery. *Transl. Androl. Urol.* **8**, 184–190 (2019).
2. Winter, S. *et al.* Transgender people: health at the margins of society. *The Lancet* **388**, 390–400 (2016).
3. Oles, N. *et al.* Gender Affirming Surgery: A Comprehensive, Systematic Review of All Peer-reviewed Literature and Methods of Assessing Patient-centered Outcomes (Part 1: Breast/Chest, Face, and Voice). *Ann. Surg.* **275**, e52–e66 (2022).
4. Oles, N. *et al.* Gender Affirming Surgery: A Comprehensive, Systematic Review of All Peer-reviewed Literature and Methods of Assessing Patient-centered Outcomes (Part 2: Genital Reconstruction). *Ann. Surg.* **275**, e67–e74 (2022).
5. Reiche, E. *et al.* A Novel Mouse Model for Investigating the Effects of Gender-affirming Hormone Therapy on Surgical Healing. *Plast. Reconstr. Surg. - Glob. Open* **10**, e4688 (2022).

6. Sullivan, T. P., Eaglstein, W. H., Davis, S. C. & Mertz, P. THE PIG AS A MODEL FOR HUMAN WOUND HEALING. *Wound Repair Regen.* **9**, 66–76 (2001).
7. Robinson, I. S. *et al.* Perioperative Hormone Management in Gender-Affirming Mastectomy: Is Stopping Testosterone before Top Surgery Really Necessary? *Plast. Reconstr. Surg.* **151**, 421–427 (2023).
8. Kothmann, K. H. *et al.* Virilizing doses of testosterone decrease circulating insulin levels and differentially regulate insulin signaling in liver and adipose tissue of females. *Am. J. Physiol.-Endocrinol. Metab.* **320**, E1107–E1118 (2021).
9. Kim, M. *et al.* Development of a reproducible in vivo laser-induced scar model for wound healing study and management. *Biomed. Opt. Express* **10**, 1965 (2019).
10. Brown, B. C., McKenna, S. P., Siddhi, K., McGrouther, D. A. & Bayat, A. The hidden cost of skin scars: quality of life after skin scarring. *J. Plast. Reconstr. Aesthet. Surg.* **61**, 1049–1058 (2008).
11. Lee, S.-S., Yosipovitch, G., Chan, Y.-H. & Goh, C.-L. Pruritus, pain, and small nerve fiber function in keloids: A controlled study. *J. Am. Acad. Dermatol.* **51**, 1002–1006 (2004).
12. Sen, C. K. *et al.* Human skin wounds: A major and snowballing threat to public health and the economy. *Wound Repair Regen.* **17**, 763–771 (2009).
13. Ashcroft, G. S. & Mills, S. J. Androgen receptor–mediated inhibition of cutaneous wound healing. *J. Clin. Invest.* **110**, 615–624 (2002).
14. Wang, Y. *et al.* Androgen actions in mouse wound healing: Minimal in vivo effects of local antiandrogen delivery. *Wound Repair Regen.* **24**, 478–488 (2016).
15. Gilliver, S. C., Ruckshanthi, J. P. D., Atkinson, S. J. & Ashcroft, G. S. Androgens influence expression of matrix proteins and proteolytic factors during cutaneous wound healing. *Lab. Invest.* **87**, 871–881 (2007).

16. Kuper, L. E., Stewart, S., Preston, S., Lau, M. & Lopez, X. Body Dissatisfaction and Mental Health Outcomes of Youth on Gender-Affirming Hormone Therapy. *Pediatrics* **145**, e20193006 (2020).

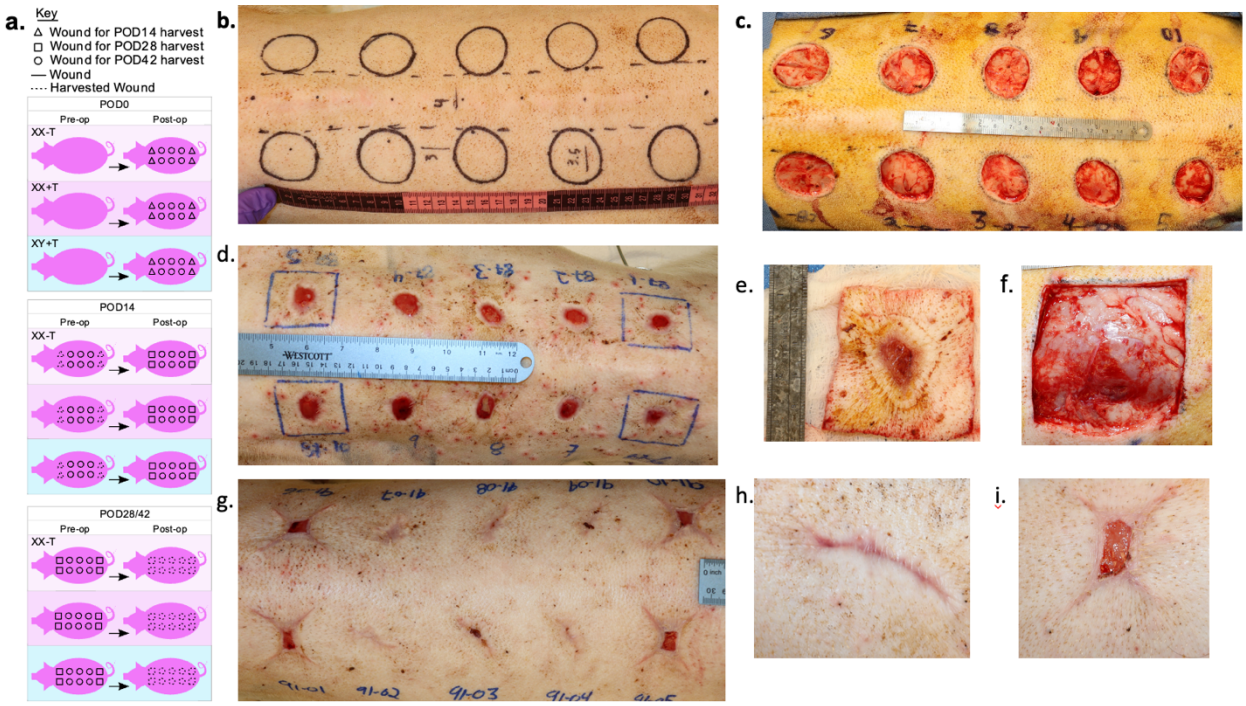

Figure 1. Swine cutaneous scarring model. (**a**) Six male (XY) and female (XX) swine underwent castration (ovariectomy/orchiectomy) and were randomly assigned to no testosterone or biweekly testosterone therapy. (**b,c**) Ten 3.5 cm dorsal excisional wounds were created on each pig. (**d, e, f**) To mimic a chronic wound, four wounds on each swine were re-excised at POD14. Six weeks after initial wounding (**g**), POD42 scar tissue (**h**) and POD28 chronic wounds (**i**) were harvested six weeks after initial cutaneous wounding.

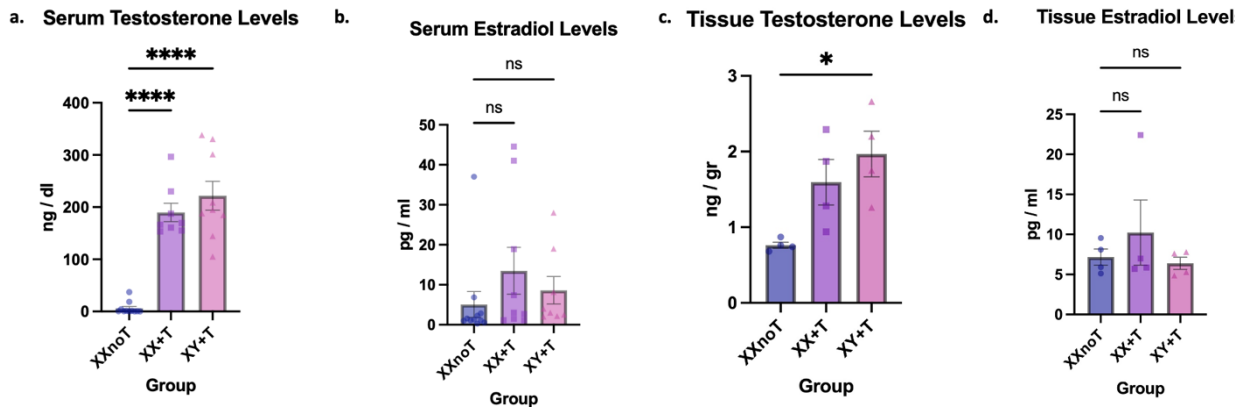

Figure 2. Steroid hormone levels in swine serum and tissue. (**a.**) +T swine showed a significant increase in serum testosterone levels relative to the no-T group (5.9ng/dL XXnoT, 189.9ng/dL XX+T, 221.8ng/dL XY+T; $p<0.01$). (**b)** Swine serum estradiol levels did not differ between hormone regimen experimental groups (5.07pg/ml XXnoT, 13.48pg/ml XX+T, 8.61pg/ml XY+T; TTest XXnoT vs XX+T $p=0.203$; TTest XXnoT vs XY+T $p=0.471$). (**c**) Swine scar tissue (POD42) and chronic wound samples (POD28) from animals treated with T showed increased levels of testosterone compared to animals not treated with T (0.76ng/gr of tissue XXnoT, 1.60ng/gr XX+T, 1.97ng/gr; $p=0.007$). (**d**) Estradiol tissue levels did not differ between groups (7.17pg/ml XXnoT, 10.23pg/ml XX+T, 6.39pg/ml XY+T; TTest XXnoT vs XX+T $p=0.492$, TTest XXnoT vs XY+T $p=0.567$).

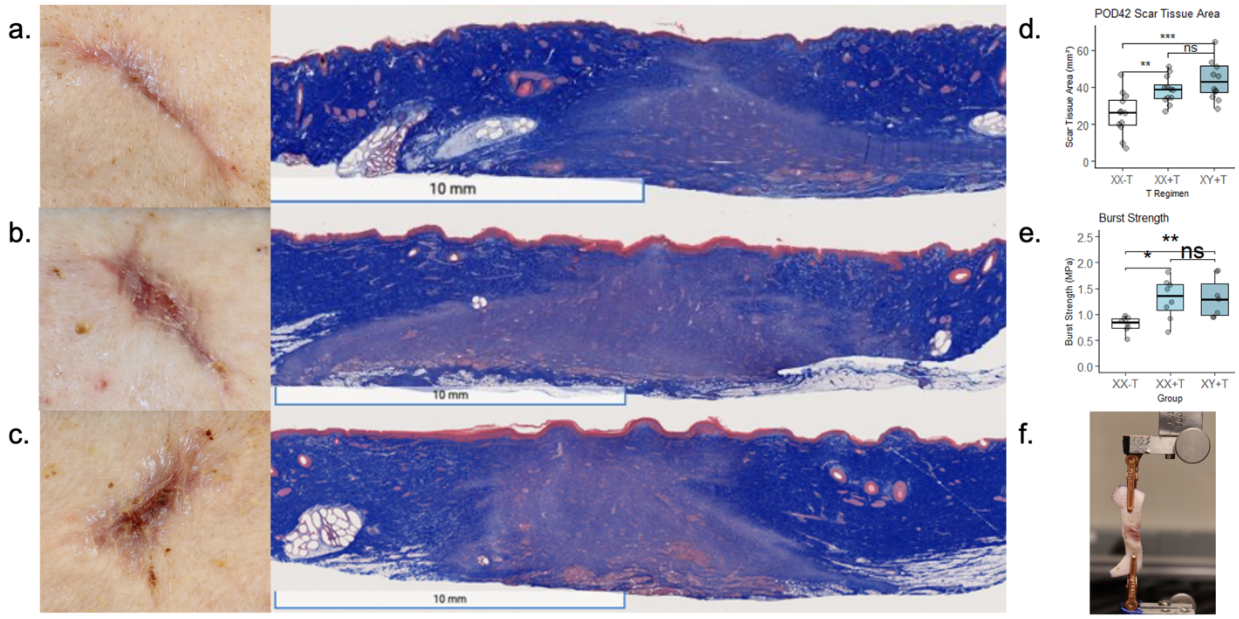

Figure 3. Histology and burst strength analysis. POD42 Scars from (**a**) XXnoT, (**b**) XX+T, and (**c**) XY+T swine. (**d**) POD42 scars from the +T swine showed increased mean scar tissue area compared to XXnoT swine (0.157cm^2 noT, 0.290cm^2 XX+T, 0.268cm^2 XY+T; p=0.007). (**e,f**) Adjusted burst strength of scars from swine exposed to T were higher compared to controls (0.81 MPa for all -T vs 1.30 MPa for all +T; p=0.001, 0.81 XXnoT vs 1.29 MPa XX+T p=0.02; 0.81 MPa XXnoT vs 1.31 MPa XY+T p=<0.01).