DIFFERENTIAL REORGANIZATION OF EPISODIC AND SEMANTIC MEMORY SYSTEMS IN EPILEPSY-RELATED MESIOTEMPORAL PATHOLOGY

Donna Gift Cabalo[1,2], Jordan DeKraker[1,2], Jessica Royer[1,2,3], Ke Xie[1,2], Shahin Tavakol[1,2], Raúl Rodríguez-Cruces[1,2], Andrea Bernasconi[2], Neda Bernasconi[2], Alexander Weil[4], Raluca Pana[2], Birgit Frauscher[2,3], Lorenzo Caciagli[5], Elizabeth Jefferies[6], Jonathan Smallwood[7], Boris C. Bernhardt[1,2]

[1]Multimodal Imaging and Connectome Analysis Laboratory, McConnell Brain Imaging Centre, Montreal Neurological Institute, McGill University, Montreal, QC, Canada; [2]Montreal Neurological Institute and Hospital, McGill University, Montreal, QC, Canada; [3]Analytical Neurophysiology Laboratory, Montreal Neurological Institute, McGill University, Montreal, Quebec, Canada; [4]CHU St Justine, Montreal, QC; [5] Department of Bioengineering, University of Pennsylvania, Philadelphia, USA; [6] University of York, North Yorkshire, United Kingdom; [7]Queens University, Kingston, Ontario, Canada;

CORRESPONDENCE TO:

Donna Gift Cabalo

McConnell Brain Imaging Centre, Montreal Neurological Institute, McGill University, Montreal, QC, Canada

donna.cabalo@mail.mcgill.ca

Boris Bernhardt, PhD

McConnell Brain Imaging Centre, Montreal Neurological Institute, McGill University, Montreal, QC, Canada

boris.bernhardt@mcgill.ca

ABSTRACT

Declarative memory encompasses episodic and semantic divisions. Episodic memory captures singular events with specific spatiotemporal relationships, while semantic memory houses context-independent knowledge. Behavioral and functional neuroimaging studies have revealed common and distinct neural substrates of both memory systems, implicating mesiotemporal lobe (MTL) regions and distributed neocortices. Here, we studied a population of patients with unilateral temporal lobe epilepsy (TLE) and variable degrees of MTL pathology as a human disease model to explore declarative memory system reorganization, and to examine neurocognitive associations. Our cohort included 20 patients with TLE as well as 60 age and sex-matched healthy controls, who underwent episodic and semantic retrieval tasks during a functional MRI session. Tasks were closely matched in terms of stimuli and trial design. Capitalizing on connectome gradient mapping techniques, we derived task-based functional topographies during episodic and semantic memory states, both in the MTL and in neocortical networks. Comparing neocortical and hippocampal functional gradients between TLE patients and healthy controls, we observed topographic reorganization during episodic but not semantic memory states, characterized by marked gradient compression in lateral temporal and midline parietal cortices in both hemispheres, cooccurring with an expansion of anterior-posterior hippocampal differentiation ipsilateral to the MTL pathology. These findings suggest that episodic processes are supported by a distributed network, implicating both hippocampus and neocortex, and such alterations can provide a compact signature of state-dependent reorganization in conditions associated with MTL damage such as TLE. Leveraging microstructural and morphological MRI proxies of MTL pathology, we furthermore observed that pathological markers selective to the hippocampus are associated with TLE-related functional reorganization. Moreover, correlation analysis and statistical mediation models revealed that these functional alterations contributed to behavioral deficits in episodic memory in patients. Altogether, our findings point to a selective mesiotemporal and neocortical functional reorganization of episodic memory systems in patients with TLE, which consistently affects behavioral memory deficits. These findings point to consistent structure-function relationships in declarative memory and reaffirm the critical role of the MTL in episodic memory systems.

KEYWORDS:

Declarative memory; Mesiotemporal lobe; Neuroimaging; Connectomics; Gradients; Epilepsy

INTRODUCTION

Declarative memory is commonly divided into episodic and semantic memory components. The former are unique events with specific spatiotemporal relationships, while semantic memory refers to context-invariant knowledge and facts about the world [1,2,3]. The relationship between both forms of memory is complex, with behavioral and neuroimaging studies suggesting shared and distinct substrates. Behavioral studies have shown a synergistic relationship between both memory types, where episodic memory for events and words processed with semantic categorization, exceeds those from non-semantic tasks [4,5,6]. Functional and structural neuroimaging evidence in healthy populations supports this finding, suggesting shared neural representations of both memory processes. In both memory types, key networks are situated in the medial and lateral temporal lobes [7, 8, 9, 10,11, 12,13-16,17, 18], alongside posterior parietal regions[19-21]. More broadly, networks involved in both memory types have been shown to engage similar intrinsic functional systems, notably the fronto-parietal network [22-24] (FPN) and the default mode network [10, 25, 26] (DMN). As such, consistent behavioral and neural evidence suggests shared processes implicated in both forms of declarative memory. On the other hand, findings point to a divergence between both. Generally, episodic processes appear to rely more on medial temporal lobe (MTL) systems, while anterior temporal lobe (ATL) regions are more heavily implicated in semantic processing [10, 16]. Similarly, prior work has suggested differential activations in middle frontal *vs* inferior temporal regions in episodic as compared to semantic retrieval [27]. A neural divergence between both memory systems is supported by the *(1)* controlled semantic cognition framework, which stipulates that the prefrontal cortex-based 'semantic' control' system dynamically supervises and adjusts the 'semantic representation' system, composed of a 'hub' in the ATL and various modality-specific 'spokes' [1, 28-30], and *(2)* hippocampus-neocortical connectivity, such that the hippocampus interacts closely with other regions through process-specific alliances to support episodic memory systems [13, 31, 32]. A systematic investigation of neocortical and MTL networks will help to understand substrates contributing to declarative memory function in the human brain.

Temporal lobe epilepsy (TLE) is a common pharmaco-resistant epilepsy in adults and can serve as a human disease model to study declarative memory system reorganization in young and middle-aged adults [32, 33]. Patients typically present with pathology of MTL structures, notably the hippocampus [34-37]and prior research has demonstrated marked impairments in episodic memory, in some patients even at a young age [32, 38-40]. Episodic memory impairment has been directly related to degrees of hippocampal structural alterations [41-46], together with widespread structural and functional imbalances in both temporal and extratemporal cortical networks[47, 48]. In contrast to the relatively consistent finding of episodic memory impairment in TLE, semantic memory has been less frequently studied, and reported results remain mixed. Semantic memory function appears to be rather mildly affected [46, 49], even in TLE patients with pronounced MTL hypometabolism [49]. Moreover, and in contrast to the frequent finding of episodic memory disruptions in patients undergoing selective MTL resection [50-52] there are less marked semantic memory impairments seen postsurgically [53, 54]. Such resilience suggests a more distributed cortical control network substrate for semantic memory, in contrast to MTL representations of episodic memory [55, 56]. Individuals with TLE may, therefore, have difficulty recalling specific events or episodes from their past while retaining their general knowledge of the world. However, other studies have found significant semantic memory deficits in patients with TLE [57-59], which have been associated with MTL [41] and ATL lesions[60]. Additionally, poor performance on semantic memory tasks has been demonstrated in TLE patients after unilateral ATL resection [57, 61, 62]. Nevertheless, as impairments in declarative

memory challenge day-to-day functioning and wellbeing of patients, it is critical to derive more mechanistic insights into these memory types and their differential vulnerabilities in TLE.

Contemporary system neuroscience has emphasized a key role of macroscale spatial patterns of cortical organization in human cognition [63-66]. Recent analytical and conceptual advances have notably emphasized the existence and utility of spatial *gradients* [63, 66-69] as low-dimensional axes of cortical organization, often reflective of established principles of cortical topography and hierarchy [63, 70, 71]. At the level of intrinsic function, the first/principal gradient anchors primary sensory and motor areas at one end and transmodal association systems, like the FPN and DMN, at the other end, whereas a second gradient differentiates visual and somatosensory/motor areas [63]. Gradients also compactly describe the subregional hippocampal organization, with a first gradient differentiating anterior-posterior (long axis) divisions and a second gradient the proximal-distal arrangement of different subfields along the infolding of this allocortical structure [72-75]. Beyond the application of gradient mapping techniques to study healthy brain organization [63, 74, 76-83], recent studies have interrogated gradient alterations in diseased cohorts, including TLE patients [84, 85]. A recent study from our group demonstrated microstructural gradient contractions in TLE in the neocortex, which were primarily localized in temporo-limbic systems and found to track deficits in episodic memory recall accuracy [85]. Another study demonstrated functional gradient expansion in subcortical structures during resting conditions, with notable differences in ipsilateral hippocampal gradient deviations between left *vs* right-lateralized TLE [84]. Additionally, patterns of cortical asymmetry and atrophy were shown to have been distinctively linked with microstructural and functional gradients [86]. Gradient mapping, therefore, offers a framework to interrogate global memory network topographies and their association with cognition in both health and disease.

The current study investigated declarative memory network organization in healthy individuals and a well-characterized cohort of TLE patients presenting with variable degrees of MTL pathology. All participants underwent episodic and semantic retrieval tasks inside the MRI scanner, with both tasks being closely matched for stimulus presentation, task design, and task structure[32, 46]. We studied the different memory states, and mapped spatial gradients of declarative memory state connectivity, both within the MTL and in macroscale neocortical networks. By adopting gradients as an analytical and conceptual framework, we were able to answer the following questions: (*i*) whether networks subserving episodic *vs* semantic memory in TLE undergo a shared or selective reorganization, *(ii)* whether memory network reorganization reflects structural alterations in the MTL, capitalizing on established in vivo proxies of mesiotemporal pathology [35, 87 88, 89] *(iii)* whether these findings reflect behavioral impairment in relational memory seen in patients.

RESULTS

We studied 20 patients with TLE and 60 age and sex-matched healthy controls, who all underwent structural (T1- and diffusion-weighted MRI) and multi-state functional MRI (episodic and semantic retrieval tasks, as well as resting state) at a 3T Siemens Magnetom Prisma MRI scanner equipped with a 64-channel head coil (for details on cohort selection, image acquisition, processing, and statistical analysis, ***see Methods***). Briefly, hippocampal and neocortical surface models were generated using automatic segmentation procedures[90, 91] based on T1-weighted MRI. Functional data were co-registered to these surfaces, and resulting neocortical and hippocampal timeseries were used to derive functional connectomes for resting, episodic, and semantic memory states for each participant. Diffusion map embedding[92], a non-linear dimensionality reduction

technique, was applied to estimate low-dimensional eigenvectors explaining spatial axes of connectivity variance. For consistency, reference gradients were derived from rs-fMRI data[93] and subject- and state-specific neocortical and hippocampal gradients were aligned to these using Procrustes rotations, as in previous work [94, 95].

Declarative memory topographies

Studying neocortical connectivity in healthy individuals, we derived the first eigenvectors (G1) during both episodic and semantic states separately (for findings of subsequent gradients, please see the ***Supplementary materials***). In episodic/semantic states, G1 explained 22/21% of functional connectome variance and described a sensory-to-transmodal neocortical gradient, echoing previous work in healthy adults based on rs-fMRI connectivity [63]. Studying hippocampal networks in controls, we also derived the first eigenvectors in episodic and semantic memory states (**Figure 1**). In episodic/semantic states, G1 accounted for 51/49% of functional connectome variance and described a canonical posteroanterior spatial pattern, echoing prior results [74]. State-specific neocortical and hippocampal gradients spatially correlated in healthy controls (r=0.99, p=0, n_{perm}=1000), suggesting a comparable organization of memory systems with both sensory-transmodal neocortical and posterior-anterior MTL trends.

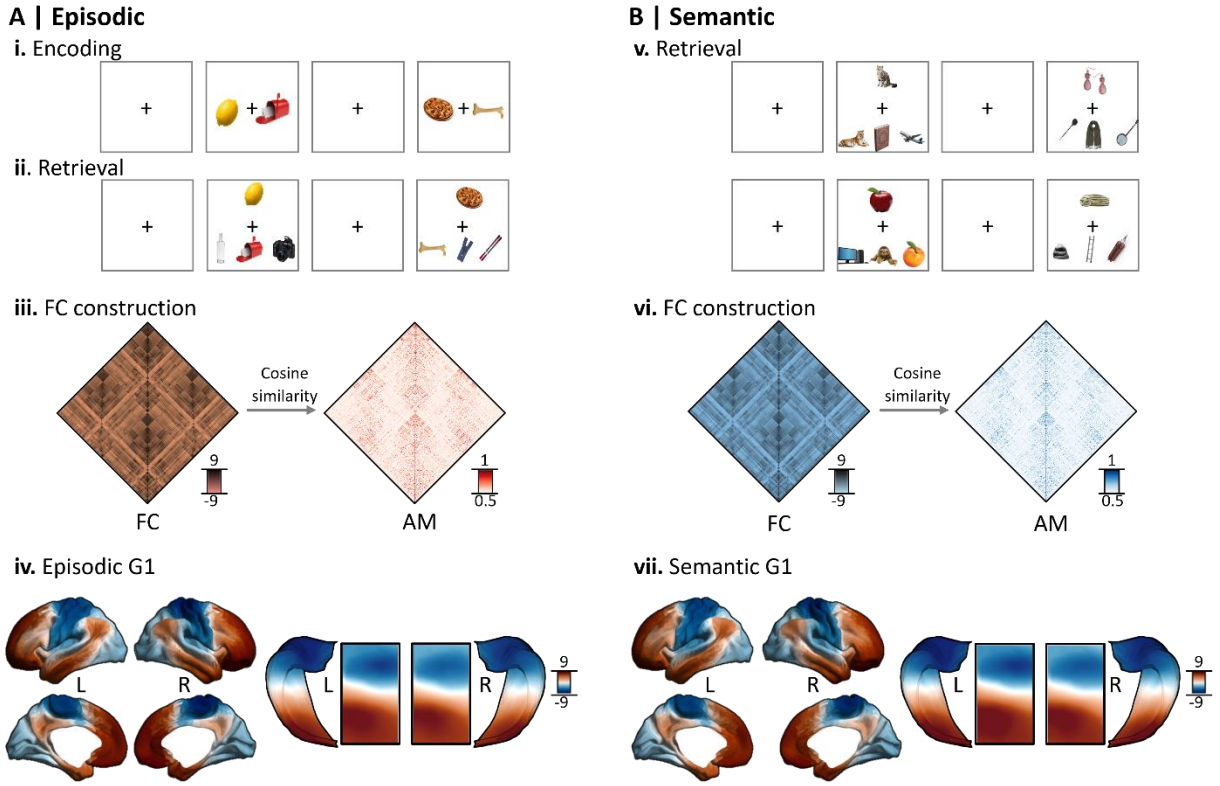

Figure 1 | Episodic and Semantic memory tasks. **A**. The episodic memory task included encoding **(i)** and retrieval phases **(ii)**, while **(B) the** semantic memory task only included a retrieval phase **(v)**. Both tasks were matched in terms of stimuli, number of trials, difficulty levels, and task structure, such that retrieval phases included three alternative forced-choice responses. Functional connectomes (FC; **iii, vi**) were independently derived from episodic and semantic task FC and affinity matrices (AM) were built based on cosine similarity, followed by gradient decomposition. **(iv, vii).** Neocortical and hippocampal principal gradients (G1) projected to the corresponding surfaces.

Atypical task-based gradients in patients with MTL pathology

Comparing neocortical topographies in TLE patients to controls, we found reduced G1 scores in the episodic memory state (p_{FWE}<0.05, mean effect sizes in significant regions d>0.54; **Figure 2A**). G1 alterations were primarily localized in the bilateral lateral temporal and posterior cingulate

regions. Between-group differences were also seen in the semantic memory state (**Figure 2B**), but only at uncorrected levels and they did not pass multiple comparisons correction. Considering the hippocampus, when comparing patients to controls, we observed atypical G1 scores in the episodic memory state, which were particularly significant in anterior divisions ipsilaterally ($p_{FWE}<0.05$, d=-0.90). Mirroring the neocortical findings, while semantic G1 expansion was also observed in TLE, no vertices survived multiple comparison corrections.

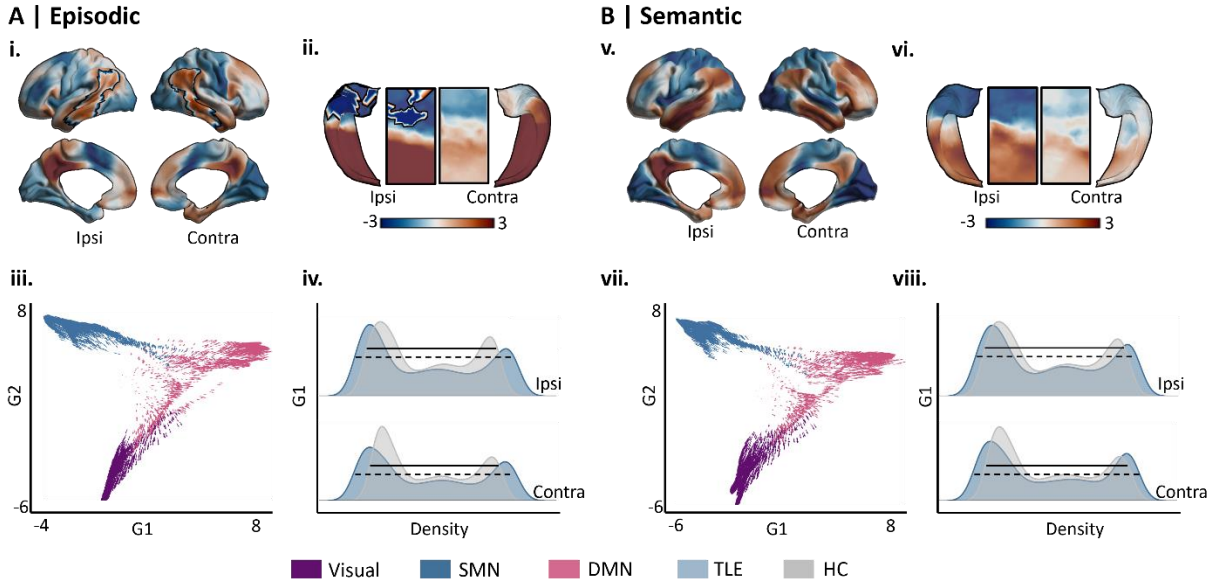

Figure 2 | Gradient alterations in patients with MTL pathology. Group differences in neocortical **(i,v)** and hippocampal **(ii, vi)** gradient scores for episodic **(A)** and semantic states **(B).** Significant *p*-values were highlighted after correcting for multiple comparisons ($p_{FWE}<0.05$, black outlines). Quiver plot of stratification of neocortical gradient scores along network communities, showing gradient contractions in the DMN for episodic (t=-1.83, p=0.03) **(iii)** and semantic states (t=-1.87, p=0.03) **(vii)**. Histogram of hippocampal G1 scores derived from hippocampal internal connectivity, showing gradient expansion, more significantly in episodic **(iv)** in comparison to semantic memory state **(viii). Abbreviations:** HC=healthy controls, TLE= temporal lobe epilepsy, G1 = Gradient 1, G2= Gradient 2, DMN=Default mode network, SMN= somatomotor network.

Relation to temporo-limbic structural alterations

An additional analysis explored how micro- and macrostructural proxies of TLE-related pathology contribute to episodic functional memory network reorganization. Structural proxies were derived from neocortical and hippocampal MRI-based measures of grey matter (*i.e.,* cortical thickness) and diffusion parameters (*i.e.,* mean diffusivity, MD). Comparing patients and controls using multivariate models based on these parameters, significant alterations were observed in patients ($p<0.05$, **Figure 3A, B;** for univariate findings, see ***Supplementary Materials***), mainly localized in ipsilateral tempo-limbic areas and anterolateral regions of the ipsilateral hippocampus. We next examined whether these structural disruptions are associated with previously observed functional alterations (**Figure 3C**). To this end, we computed the overall temporo-limbic structural changes in TLE patients and controls, both at the level of the neocortex and hippocampus, and conducted a correlation analysis. This analysis revealed an association between overall functional G1 changes and structural alterations (r=0.31, $p_{FDR}=0.01$). Further tests showed a more selective association with hippocampal (r=0.43, $p_{FDR}=0.003$), relative to the neocortical measures (r=0.058, $p_{FDR}=0.61$).

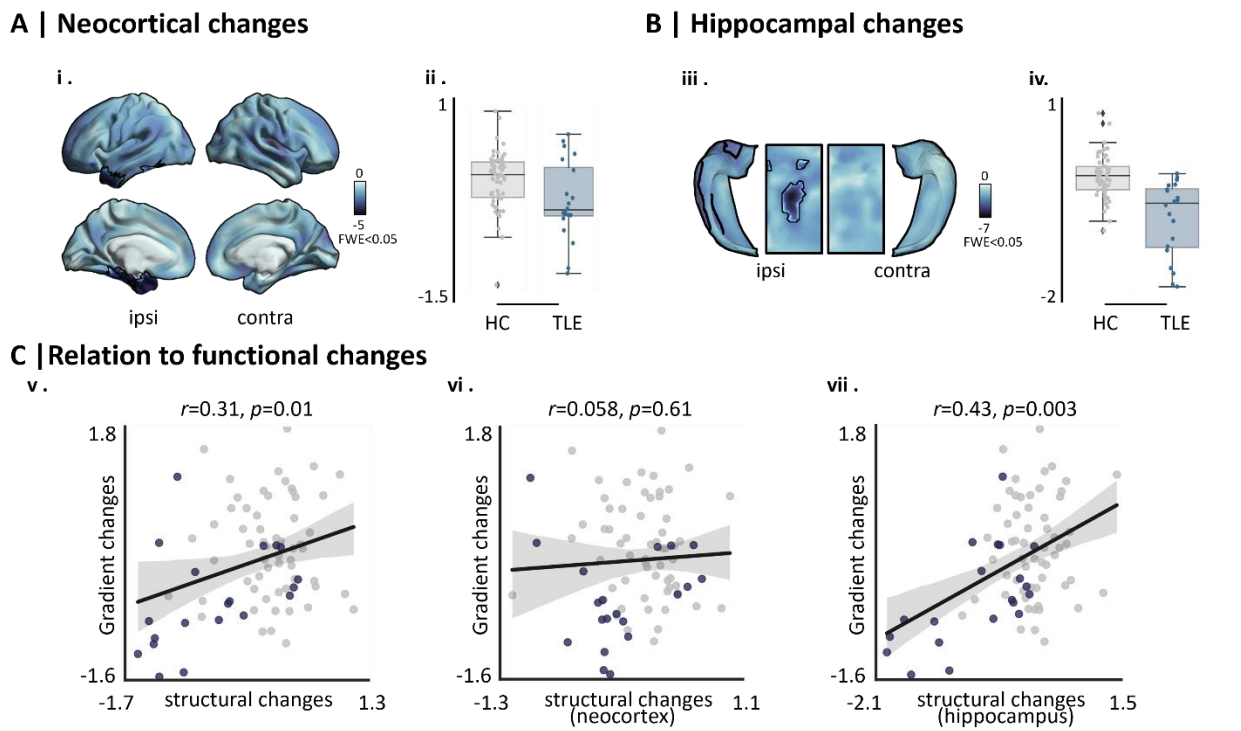

Figure 3 | Associations to temporo-limbic pathology. A-B) Differences in neocortical **(i)** and hippocampal **(iii)** MRI-proxies of pathology (using a multivariate aggregate of cortical thickness and MD) between TLE patients and controls. Regions showing alterations in TLE are highlighted (p_{FWE}<0.05, black outline), with mean values represented in **(ii, iv).** **C**) FDR-corrected relationship between overall functional changes to **(v)** overall structural changes, **(vi)** structural changes in the neocortex, and, **(vii)** hippocampus (HC=grey; TLE=dark purple). **Abbreviations:** ipsi= ipsilateral, contra=contralateral, HC=healthy controls, TLE=temporal lobe epilepsy.

Relation to behavioral indices of declarative memory

We finally examined the relations between participants' behavioral performance and functional memory network reorganization. Behaviorally, patients showed markedly reduced episodic memory accuracy relative to controls (t=4.18, p<0.001, d=-1.02), and only subthreshold impairment in semantic memory (t=1.53, one-tailed p=0.065, d=-0.39). We similarly observed faster reaction times for accurate recall in controls relative to patients (***Supplementary Figure S5***).

Notably, functional G1 scores in both neocortical (r_{ipsi}=0.32, p_{FDR}=0.018; r_{contra}=0.27, p_{FDR}=0.032) and hippocampal (r_{ipsi}=0.29, p_{FDR}=0.024) clusters of significant between-group differences (see *Figure 2*) correlated with episodic memory performance (**Figure 4A**). *Ad hoc* meta-analytical decoding[26] confirmed that TLE-related gradient contractions in the episodic state were enriched for memory-related terms, supporting the behavioral associations (**Figure S4**). In semantic memory states, hippocampal G1 (r_{ipsi}=0.25, p_{FDR}=0.05), but not neocortical G1 correlated with semantic task performance (r_{ipsi}=0.14, p_{FDR} =0.25; r_{contra}=0.04, p_{FDR}=0.69; **Figure 4B**).

To assess specificity, we also administered the EpiTrack[96] test to probe executive function and attention. Patients with TLE showed reduced EpiTrack (t=-2.98, p=0.003, d=-0.82) scores relative to controls. Controlling for individual Epitrack scores, we observed smaller, yet still significant functional G1 changes in our cohort, in both the hippocampus (p_{FWE}<0.05, d=-0.88, 2% decreased in mean effect size) and neocortex (p_{FWE}<0.05, d=-0.53).

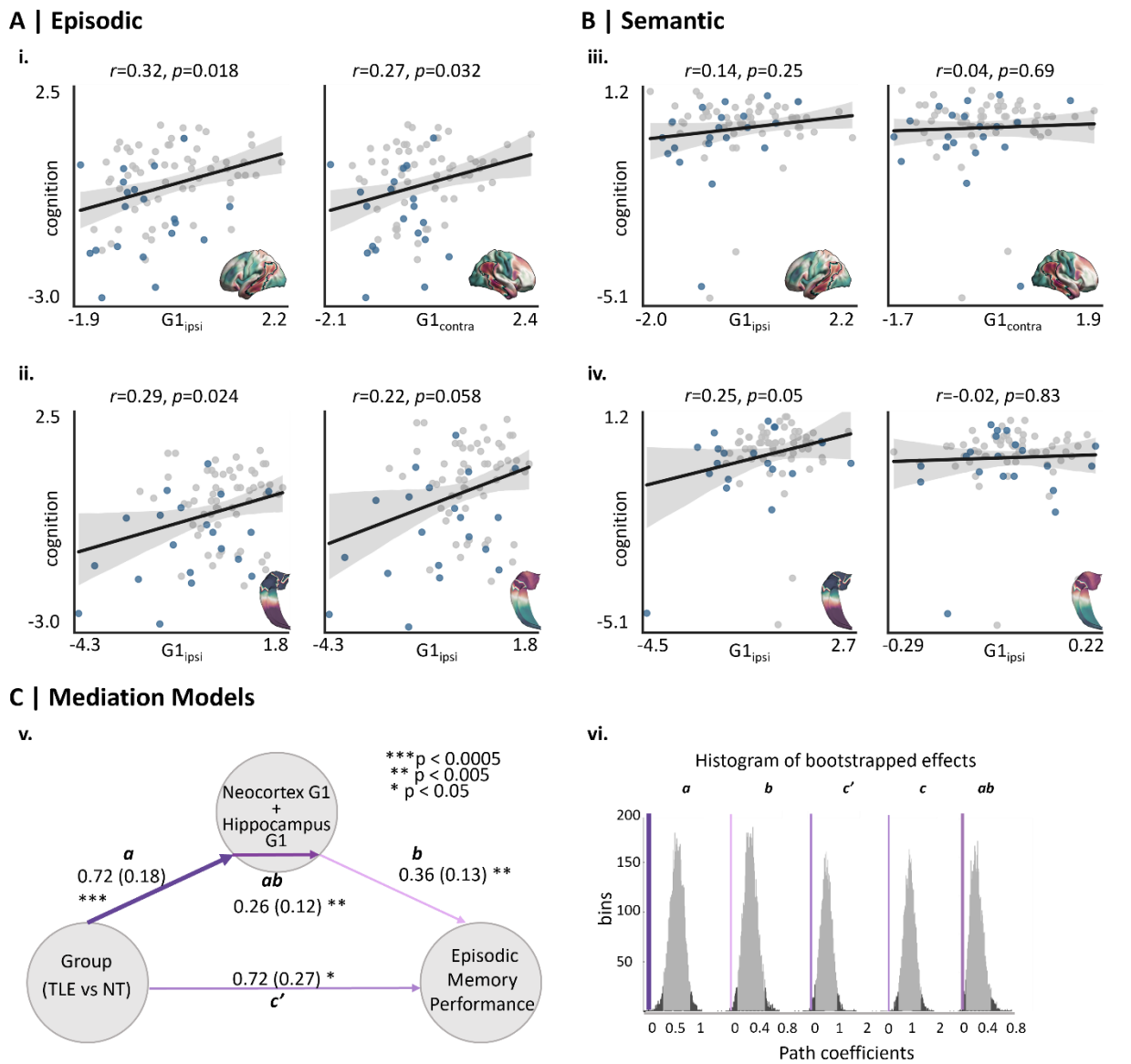

Figure 4 | Behavioral associations. Mean G1 scores of regions showing significant case-control differences in the ipsilateral and contralateral hemispheres for neocortical and hippocampal G1 in episodic **(A)** and semantic **(B)** memory states, correlated with overall behavioral performance. Controlling for the aggregate effects of morphology and superficial white matter properties (mean diffusivity), hippocampal episodic G1 (**ii;** *right panel)* correlated significantly with task performance, while hippocampal semantic G1 (**iv;** *right panel)* correlation to memory performance disappeared. (HC=grey; TLE=blue). **C.** Statistical mediation analysis revealed the relationship between group and episodic memory performance, transmitted via overall neocortical $G1_{ipsi}$ + hippocampal $G1_{ipsi}$ **(v)** scores. **(vi)** Histogram of effects (nboot=1000). **Abbreviations:** G1 = Gradient 1, Ipsi= ipsilateral, Contra= contralateral, a = Group ~ Gradient scores, b= Gradient scores ~ Episodic memory performance, c'= Group ~ Episodic memory performance(residual), ab= mediation effect.

In a final analysis, we assessed whether functional G1 alterations mediated the relationship between group (TLE *vs* controls) and episodic memory performance (**Figure 4C**). To this end, we first computed overall functional alterations by averaging G1 scores in significant regions and submitted this to a statistical mediation analysis. Group and functional gradient alterations correlated strongly (a, $p<0.0005$), as did functional gradient alterations and episodic memory performance (b, $p<0.005$), and group and episodic memory performance (c', $p<0.05$). Importantly, functional gradient alterations in hippocampal and neocortical regions mediated the relationship between group and episodic memory performance (ab, $p<0.005$). Overall, our statistical mediation

analysis thus revealed that the relationship between group and episodic memory performance is transmitted via neocortical and hippocampal gradients.

DISCUSSION

This study demonstrated *(i)* a selective reorganization of episodic functional memory networks in patients with TLE, *(ii)* a close association between functional reorganization and hippocampal, but not neocortical *in vivo* proxies of MTL pathology , and *(iii)* a contribution of atypical temporo-limbic functional organization to behavioral deficits in TLE patients. Our study harnessed *(i)* closely matched functional MRI tasks of episodic and semantic memory, *(ii)* state-of-the-art MRI segmentation and fMRI preprocessing methods, and *(iii)* unsupervised connectivity gradient mapping techniques in *(iv)* a well-characterized cohort of TLE patients. Altogether, this elucidated both large-scale and subregional functional topographic alterations of episodic memory networks in TLE that mediate cognitive impairment and emphasize a key role of the MTL in episodic over semantic memory processes.

Our work employed multi-task functional MRI profiling of relational memory systems in healthy individuals and patients with MTL damage due to drug-resistant focal epilepsy. Segregation of episodic and semantic memory systems [3], as suggested by our findings, has previously been supported by traditional neuropsychological tests dissociating list recall performance for episodic memory and picture naming for semantic memory[38, 58, 59]. Moreover, task-based neuroimaging studies have also pointed to distinct neural substrates of these task demands[9, 16]. However, mounting evidence suggests that both systems may nevertheless share some overlapping neural correlates[9, 22, 23]. The memory tasks[46] employed in this study were carefully designed to distinctly tap into episodic and semantic memory while being homogenous in low-level task structure. A recent behavioral study from our group supported the utility of these tasks as a cognitive assessment tool in both healthy and diseased cohorts, showing reduced episodic, but preserved semantic recall in TLE patients[46]. To study functional topographic patterns associated with these processes, the current work also analysed task-based fMRI data for the first time and capitalized on data-driven approaches for the compression of task-based connectomes into topographic *connectivity gradients* [63, 68]. Gradient mapping techniques have previously been applied to several modalities, in particular resting-state fMRI connectivity as well as structural and microstructural MRI measures [63, 68, 70, 80, 97, 98]. Complementing these task-free investigations, the current study derived topographic gradients during episodic and semantic memory states separately, yet it still found that they largely followed similar intrinsic organizational axes [10, 23, 25]. Specifically, connectivity patterns during both memory states followed topographic gradients including a sensory-transmodal neocortical and posterior-anterior hippocampal pattern, which are in line with previous observations[63, 68, 69, 72-74]. Transmodal core regions (*i.e.,* DMN) occupy a cortical territory that is maximally distant and separate from unimodal sensory systems, balancing segregated processing streams and integration[64, 66,63, 64, 99]. This is suggested to help decouple cognition (*e.g.,* self-generated thought processes and episodic representations) from the immediate environment [100-104]. Conversely, in the hippocampus, anterior segments have broader tuning properties and are suited to generalization, while the posterior units are narrowly tuned fields and are suited to memorizing specific instances (*i.e.,* contextualization) [105, 106]. This can be supported by preferential coupling of anterior divisions of the MTL with transmodal systems, and posterior segments to unimodal systems[73, 82, 107107, 108]. Together, our findings support this unified account of large-scale

hierarchical organization of the brain with reliable correlates to behavioral systems and phenotypes[75, 109, 110].

In TLE, previous work has mainly reported associations between structural compromise of the MTL and memory impairment measured behaviourally and shown atypical functional activation patterns in the MTL and beyond [111, 112]. Here, we extend this literature by showing a marked reorganization of functional networks during episodic retrieval states. These effects were strongest in bilateral neocortical regions and the MTL region ipsilateral to the seizure focus. Consistent with previous work based on rs-fMRI data[111], we found neocortical gradient compressions in regions susceptible to TLE-related compromise[111, 113], suggesting atypical functional topographic segregation in TLE. Prior rs-fMRI studies reported simultaneous increases in short- and decrease in long-range connections in temporo-limbic and dorsomedial regions in TLE[111, 112], a finding that is compatible with a large body of structural covariance and diffusion MRI studies suggesting reduced connectivity to regions beyond the temporo-limbic diseased epicentre[35, 111]. We also observed an extended hippocampal principal gradient, supporting the concept of subcortical gradient expansion as a functional connectome phenotype in TLE[84]. Our findings resemble task-activation studies showing widespread extratemporal connectivity reduction and intrinsic MTL connectivity increases[47], and less concordant fMRI activations between hippocampal long axis and sensory-transmodal gradients in TLE relative to controls[32]. Collectively, our findings validate the notion that episodic processes are supported by a distributed network, implicating the hippocampus and neocortex[13, 31,47]. More importantly, the neocortical gradient contraction and hippocampal gradient expansion reported herein provide a compact signature of functional activation and state-dependent reorganization of memory systems in TLE.

Prior studies have reported atypical microstructure and morphology in TLE in both the MTL as well as adjacent temporo-limbic, neocortical systems [47, 34, 35, 87, 88, 114-116], and have suggested that such changes could alter the spatial configuration of functional networks and influence hierarchical organization supporting episodic memory function. In line with previous work[35, 111, 117], superficial white matter disruptions and atrophy were observed in our TLE patient cohort, with most marked findings in temporo-limbic regions and hippocampal antero-lateral regions ipsilateral to the seizure focus. These findings could further reinforce earlier models that propose increased susceptibility of paralimbic regions to structural and functional changes, potentially due to a greater capacity for plasticity and connectivity rearrangement[86, 118]. Interestingly, while neocortical structural changes did not reflect functional changes, morphological and microstructural derangements of the hippocampus correlated with episodic memory network reorganization. This functional association with pathological markers selective to the hippocampus provides specificity and reinforces the crucial role of hippocampal integrity in episodic memory network-specific reorganization[119, 120].

Previous studies have also linked network alterations in TLE patients to cognitive impairment[47, 85, 112, 114, 116]. Consistent with a recent study from our group [46], distinct episodic task impairment was observed in TLE, while semantic task performance remained relatively intact. Additionally, neocortical, and hippocampal gradient alterations were found to be significant predictors of episodic impairments in TLE. While we acknowledge that our conservative patient inclusion criteria resulted in a relatively small sample size of 20 well-characterized TLE patients, the observed memory deficits and functional perturbations were unlikely influenced by neurodegenerative disorders[121,46], as functional alterations persisted even after controlling for overall measures of cognitive function (*i.e.* EpiTrack). Behavioral indices of cognitive impairment

in TLE were mediated by functional changes, confirming the already well-established literature on episodic impairment in TLE. In line with the hierarchical models of memory[122, 123], our findings lend support to the idea that semantic memory relies more on extra-hippocampal brain regions compared to hippocampal-dependent episodic systems. This is consistent with evidence from TLE patients who underwent anterior lobe resection[57], and corroborates the controlled semantic cognition framework with ATL as a central semantic hub[1, 16, 29]. Additionally, our findings are accounted by multiple trace theory [55, 56, 124], which stipulates that hippocampus-encoded semantic memories undergo a long-term consolidation process[125, 126] that renders the memory trace independent, and thus more resilient to hippocampal damage. Episodic memories are consistently mediated by the hippocampus allowing a vivid recollection of context-rich events[56, 127], and each instance of recalling an episodic memory triggers subsequent re-encoding, leading to the formation of multiple traces or engrams, that are mediated by hippocampo-neocortical neuron ensembles[55, 56, 127, 128,129, 130]. In contrast, successful semantic memory recall does not require rich contextual detail and therefore can be solely supported by extra-temporal regions[131].

Dimensional decomposition analysis of task-fMRI data reveals an atypical and state-dependent reorganization of declarative memory systems in TLE, with a consistent correlation with behavioral impairments and *in vivo* markers of hippocampal pathology. Our findings support the episodic theory[31, 132] which stipulates a more selective role of the hippocampus in the episodic processes, in contrast to the declarative theory[13, 133, 134], which posits that the hippocampus is critically involved in both episodic and semantic memory types. Collectively, this study provides novel insights into mechanisms of cognitive impairments in conditions associated with MTL pathology. As many drug-resistant patients undergo resective MTL surgery, future work could investigate whether gradient patterns will help predict post-operative memory deficits, and thus enrich patient-specific clinical decision-making.

METHODS

Participants

We studied 20 patients with drug-resistant TLE (10 females, age=35±12 years, left/right handed=1/19), and sixty healthy controls (30 males, age=33± 8 years, left/right handed=2/58). All participants were recruited between May 2018 and March 2022 at the Montreal Neurological Institute (MNI). Controls met the following inclusion criteria: (1) age between 18-65 years; (2) no neurological or psychiatric illness; (3) no MRI contraindication; (4) no drug/alcohol abuse problem; and (5) no history of brain injury and surgery. Patient demographics and clinical features were obtained through interviews with patients and their relatives. Seizure focus lateralization was determined through a comprehensive evaluation of medical history, neurological examination, seizure semiology, video-EEG, and clinical neuroimaging. Detailed clinical data, including location and Engel outcome, is available in **Table S1.** Fifteen patients were diagnosed with left-sided TLE. The mean age of seizure onset was 20.75±10.17 years (range= 8-49 years), with a mean epilepsy duration of 14.02±11.63 years (range=1-45 years). Five patients (25%) had a history of childhood febrile convulsion. At the time of the study, 10/20 patients underwent resective temporal lobe surgeries. In those, post-surgical seizure outcome was assessed using Engel's modified classification[135], with an average follow-up duration of 21±15.50 months. Post-surgery, 8 patients (80%) achieved complete seizure freedom (Engel-I), and 2 patients (20%) had recurrent seizures. A total of 6 specimens were available for histopathological analysis. Here, 4 patients showed

mesiotemporal/hippocampal sclerosis, one patient had evidence of mesiotemporal ganglioglioma, and one for mild dysplasia in the mesiotemporal structures. There were no significant differences in males/females (χ^2=0.1,p=0.88) and there were no significant differences in age (t=0.98, p=0.34) between patients and controls. The study was conducted in accordance with the Declaration of Helsinki, and the MRI data acquisition protocols were approved by the Research Ethics Board of the Montreal Neurological Institute and Hospital. All participants provided informed consent.

Declarative memory paradigm

All participants underwent episodic and semantic retrieval fMRI tasks (**Figure 1**). These tasks were carefully designed to be closely matched *i.e.,* they were based on (1) equivalent symbolic stimuli to accommodate a bilingual participant pool in the Montreal area; (2) the same number of trials that were presented in a pseudo-randomized manner; (3) an identical task structure with three alternative forced choice response at the retrieval phases; and (4) two difficulty levels.

A) Episodic Memory. The task had two phases. During the encoding phase, participants were shown paired images of objects and asked to memorize them. To ensure that the images were well-matched, we used the UMBC similarity index[136] to control for semantic relatedness. Specifically, we selected items where the similarity score remained below 0.3 on a scale of 0 to 1. The task comprised 56 pseudo-randomized trials, with 28 difficult (with paired images shown only once) and 28 easy (paired images shown twice) trials. In the retrieval phase, which took place after several minutes of delay, participants were presented with an image of an object at the top of the screen (*prime*) and three different objects at the bottom. From these choices, subjects were asked to identify the *target* that was paired with the *prime* during encoding. We only analyzed data from the retrieval phase.

b) Semantic Memory. The semantic task involved a retrieval phase only. In each trial, participants were presented with an image of an object at the top of the screen (*prime*) and three different objects at the bottom (1 *target*, 2 *foils*). From these choices, subjects were asked to identify the item (*target*) that was most conceptually related to the *prime*. The 56 pseudo-randomized trials were also modulated for difficulty (*i.e.,* there were 28 difficult trials where prime/target shared a similarity index ≥0.7, whereas prime/foils shared a similarity between 0.3 and 0.7, as well as 28 easy trials, where prime/target shared a similarity ≥0.7 and prime/foils shared a similarity between 0 and 0.3).

c) Performance metrics. Individual episodic and semantic performance was computed by averaging the scores in the difficult and easy trials. We also averaged reaction time.

Additional screening for executive function and general cognitive impairment

Participants also completed the EpiTrack[96] tests outside the scanner. The EpiTrack paradigm has been developed to identify dysfunctions in attention and executive control resulting from epileptic disorders.

MRI Acquisition

MRI data were acquired on a 3T Siemens Magnetom Prisma-Fit with the 64-channel head coil. T1-weighted scans were acquired with a 3D-magnetization-prepared rapid gradient-echo sequence (MPRAGE; 0.8mm isovoxels, matrix=320×320, 224, sagittal slices, TR=2300ms, TE=3.14ms, TI=900ms, flip=9°, iPAT=2, partial Fourier=6/8, FOV=256×256mm^2). The DWI data was obtained with a 2D spin-echo echo-planar imaging sequence with multi-band acceleration and

consists of three distinct shells, each with different b-values 300, 700, and 2000s/mm^2, with each shell acquired with 10, 40, and 90 diffusion weighting directions, respectively (1.6 mm isotropic voxels, TR = 3500 ms, TE = 64.40 ms, flip angle = 90°, refocusing flip angle = 180°, FOV = 224 × 224 mm^2, slice thickness = 1.6 mm, multi-band factor = 3, echo spacing = 0.76 ms). All fMRI were acquired with a 2D/BOLD echo-planar imaging sequence (3.0mm isovoxels, matrix= 80×80, 48 slices oriented to AC-PC-30 degrees, TR=600ms, TE=30ms, flip=50°, FOV=240×240mm^2, slice thickness=3mm, mb factor=6, echo spacing=0.54ms). During the resting-state functional MRI (rs-fMRI), participants were instructed to fixate on a grey cross and not think of anything in particular. All fMRI scans were presented via a back-projection system and responses were recorded using an MRI-compatible four-button box. The episodic and semantic retrievals both lasted approximately 6 minutes.

MRI Processing

Scans were pre-processed using *micapipe*[91] *version v0.1.4* (https://github.com/MICA-MNI/micapipe), an open-access multimodal preprocessing, surface-mapping, and data fusion software. T1-weighted data were de-obliqued and reoriented to ensure a consistent orientation across images. Next, a linear coregistration, intensity non-uniformity correction, and skull stripping were applied to extract the brain region from the surrounding non-brain tissues. DWI data underwent denoising, eddy current-induced distortion correction, and motion correction as well as non-uniformity bias field adjustment. The corrected DWI data was fitted with a diffusion tensor model[137], allowing for the computation of mean diffusivity[138] images (MD). Cortical surfaces were extracted with FreeSurfer *6.0* from each T1w scan, followed by manual surface generation. Resting-state and task-fMRI were preprocessed using a combination of FSL[139] *6.0*, ANTs[140] *2.3.4*, and AFNI[141] *20.3.0* software and involved the following steps: *(1)* removal of first five TRs, *(2)* image reorientation, *(3)* motion correction, *(4)* distortion correction based on AP-PA blip field maps, *(5)* high-pass filtering to 0.01,666 Hz, *(6)* MELODIC decomposition, *(7)* Linear/Non-linear co-registration to the T1-weighted scans, *(8)* nuisance signal regression with FMRIB's ICA-based Xnoiseifier[142] (ICA-FIX), *(9)* native cortical surface registration, *(10)* surface-based registration to the Conte69 surface template with 32k surface points (henceforth, *vertices*) per hemisphere, *(11)* surface-based smoothing with a Gaussian diffusion kernel with a full-width-at-half-maximum, FWHM, of 10mm, and *(12)* statistical regression of motion spikes. The hippocampus and surrounding structures were automatically segmented with a deep convolutional neural network using HippUnfold[90] *v1.0.0,* (https://hippunfold.readthedocs.io/). The task-fMRI and MD data were then sampled along the hippocampal midthickness surface and FWHM=2mm surface smoothing was applied.

Gradient identification and alignment

For computational efficiency, surface-mapped neocortical time series were downsampled to a mesh with 10k vertices using *connectome workbench*[143]. Intrahemispheric neocortical functional connectomes were generated for each functional state (episodic, semantic, rest) by calculating Pearson correlations between the time series for all vertices for each participant, resulting in a 5k by 5k connectome per hemisphere (**Figure 1**). Similar to the neocortex, internal hippocampal connectomes were generated from the extracted timeseries resulting in a 419 by 419 functional connectivity matrix per hippocampus. We applied Fisher r-to-z transformations to both neocortical and hippocampal functional connectomes and retained only the top 10% of row-wise connections. We constructed affinity matrices using a cosine similarity kernel to measure the similarity of connectivity patterns between regions. Diffusion map embedding[63, 92], a non-linear dimensionality

reduction technique implemented in *Brainspace*[95] *v0.1.3* (https://brainspace.readthedocs.io/; **Figure 1**), was applied to identify low-dimensional eigenvectors (*i.e.,* gradients) that accounted for the variance in neocortical and hippocampal connectomes. Diffusion mapping is a powerful and efficient tool to compress large-scale datasets. This algorithm uses the diffusion operator $P\alpha$ to create a new representation of data and is guided by two key parameters: α, which controls the influence of sampling point density on the manifold, and, t, which represents the scale of the data. To maintain global connections among data points in the embedded space, α was set to 0.5 ($\alpha=0$, *maximal influenc*e, $\alpha=1$ *no influence)* and t was set at 0, consistent with previous studies[63, 95]. To ensure that results were consistent with the prior literature that derived functional gradients mainly from rs-fMRI data[63, 68], we first generated intra-hemispheric reference gradients by averaging rs-fMRI connectomes across groups and aligning them to a normative gradient template derived from the rs-fMRI data of the Human ConnectomeProject[93]. We used Procrustes rotation to align individual and state-specific task-fMRI gradients with these normative reference gradients, thereby ensuring that gradients were consistent in ordering and sign across participants and memory states. Similar procedures were performed to align hippocampal gradients. Finally, we normalized neocortical and hippocampal gradient scores relative to the distribution in controls, and sorted gradients in patients relative to the hemisphere ipsilateral to the seizure focus, as in prior work[85].

Statistical Analysis

After gradient alignment, we inferred between-group differences using surface-based linear models implemented in *Brainstat*[144] *version 0.4.2* (https://brainstat.readthedocs.io). We additionally controlled for age and sex and corrected for vertex-wise multiple comparisons using random field theory for non-isotropic imaging[145], at a set family-wise error of $p_{FWE}<0.05$. We computed the association between gradient scores in regions showing significant between-group differences and cognitive scores. To investigate the association between gradients and memory, we examined the gradient scores while controlling for EpiTrack which indicated attention and executive functions. Finally, statistical mediation analyses tested whether the association between group and episodic memory performance is transmitted via gradients.

Morphological and microstructural substrate analysis

To assess TLE-related memory network reorganization beyond functional changes, we also compared the neocortical and hippocampal thickness and a diffusion parameter (MD) between controls and TLE patients. Using multivariate surface-based linear models, we assessed the morphological and microstructural properties while controlling the effects of age and sex. Cortex-wide thickness was quantified as the Euclidian distance between corresponding pial and white matter vertices. To establish an accurate spatial correspondence, thickness, and MD maps were registered to the Conte69 surface template and were subsequently downsampled from 32k vertices to 5k vertices/hemisphere. Hippocampal thickness was generated using a similar method and we used the surface meshes derived with HippUnfold[90] *v1.0.0,* (https://hippunfold.readthedocs.io/). Finally, we investigated the association between atypical patterns of morphology and microstructure and observed TLE-related gradient alterations. Specifically, we computed the mean thickness and MD scores in regions showing significant differences between healthy controls and TLE patients and correlated with overall functional changes.

Decoding analysis based on Neurosynth

We also conducted a functional decoding analysis based on Neurosynth (https://neurosynth.org/), a platform that allows for large-scale *ad hoc* meta-analysis of task-based fMRI data. To explore the cognitive associations, cortex-wide functional gradients showing TLE-related alterations were used as a surface decoder.

Funding

D.G.C. is funded in part by the Canada First Research Excellence Fund and Fonds de recherche du Québec, awarded to the Healthy Brains, Healthy Lives (HBHL) initiative at McGill University and Quebec Bio-Imaging Network (QBIN-RBIQ). J.D. is funded by the Natural Sciences and Engineering Research Council of Canada- Post-Doctoral Fellowship (NSERC-PDF). J.R. is funded by the Canadian Institutes of Health Research (CIHR). S.T. is funded by the Canadian Open Neuroscience Platform (CONP). K.X. is funded by the China Scholarship Council (CSC: 202006070175). R.R.C. is funded by the Fonds de la Recherche du Québec – Santé (FRQS). L.C. is supported by the Berkeley Fellowship jointly awarded by UCL and Gonville and Caius College, Cambridge, and by Brain Research UK (award 14181). A.B. and N.B. are supported by FRQS and CIHR. B.C.B. acknowledges research support from the NSERC Discovery-1304413, CIHR (FDN-154298, PJT-174995), SickKids Foundation (NI17-039), the Helmholtz International BigBrain Analytics and Learning Laboratory (HIBALL), HBHL, Brain Canada, and the Tier-2 Canada Research Chairs program.

Acknowledgments

We would like to thank all the TLE patients and controls who participated in this study.

References

1. Ralph MAL, Jefferies E, Patterson K, Rogers TT. The neural and computational bases of semantic cognition. Nature Reviews Neuroscience. 2017;18(1):42-55.
2. Patterson K, Nestor PJ, Rogers TT. Where do you know what you know? The representation of semantic knowledge in the human brain. Nature Reviews Neuroscience. 2007;8(12):976-87.
3. Tulving E. Episodic and semantic memory. Organization of memory. 1972;1(381-403):1.
4. Brown SC, Craik FIM. Encoding and retrieval of information. The Oxford handbook of memory. New York, NY, US: Oxford University Press; 2000. p. 93-107.
5. Craik FI, Lockhart RS. Levels of processing: A framework for memory research. Journal of verbal learning and verbal behavior. 1972;11(6):671-84.
6. Craik FI, Tulving E. Depth of processing and the retention of words in episodic memory. Journal of experimental Psychology: general. 1975;104(3):268.
7. Bartha L, Brenneis C, Schocke M, Trinka E, Köylü B, Trieb T, et al. Medial temporal lobe activation during semantic language processing: fMRI findings in healthy left-and right-handers. Cognitive Brain Research. 2003;17(2):339-46.
8. Binder JR, Frost JA, Hammeke TA, Cox RW, Rao SM, Prieto T. Human brain language areas identified by functional magnetic resonance imaging. Journal of Neuroscience. 1997;17(1):353-62.
9. Irish M, Vatansever D. Rethinking the episodic-semantic distinction from a gradient perspective. Current Opinion in Behavioral Sciences. 2020;32:43-9.
10. Irish M. On the interaction between episodic and semantic representations–constructing a unified account of imagination. The Cambridge handbook of the imagination. 2020:447-65.
11. Palacio N, Cardenas F. A systematic review of brain functional connectivity patterns involved in episodic and semantic memory. Reviews in the Neurosciences. 2019;30(8):889-902.
12. Rajah MN, McIntosh AR. Overlap in the functional neural systems involved in semantic and episodic memory retrieval. Journal of Cognitive Neuroscience. 2005;17(3):470-82.
13. Squire LR, Stark CE, Clark RE. The medial temporal lobe. Annu Rev Neurosci. 2004;27:279-306.
14. Menon V, Boyett-Anderson JM, Schatzberg AF, Reiss AL. Relating semantic and episodic memory systems. Cognitive brain research. 2002;13(2):261-5.
15. Barredo J, Öztekin I, Badre D. Ventral fronto-temporal pathway supporting cognitive control of episodic memory retrieval. Cerebral Cortex. 2015;25(4):1004-19.
16. Jefferies E. The neural basis of semantic cognition: converging evidence from neuropsychology, neuroimaging and TMS. Cortex. 2013;49(3):611-25.
17. Whitney C, Jefferies E, Kircher T. Heterogeneity of the left temporal lobe in semantic representation and control: priming multiple versus single meanings of ambiguous words. Cerebral cortex. 2011;21(4):831-44.
18. Whitney C, Kirk M, O'Sullivan J, Lambon Ralph MA, Jefferies E. The neural organization of semantic control: TMS evidence for a distributed network in left inferior frontal and posterior middle temporal gyrus. Cerebral cortex. 2011;21(5):1066-75.
19. Davey J, Cornelissen PL, Thompson HE, Sonkusare S, Hallam G, Smallwood J, et al. Automatic and controlled semantic retrieval: TMS reveals distinct contributions of posterior middle temporal gyrus and angular gyrus. Journal of Neuroscience. 2015;35(46):15230-9.

20. Ranganath C, Ritchey M. Two cortical systems for memory-guided behaviour. Nature reviews neuroscience. 2012;13(10):713-26.
21. Whitney C, Kirk M, O'Sullivan J, Lambon Ralph MA, Jefferies E. Executive semantic processing is underpinned by a large-scale neural network: revealing the contribution of left prefrontal, posterior temporal, and parietal cortex to controlled retrieval and selection using TMS. Journal of cognitive neuroscience. 2012;24(1):133-47.
22. Ramanan S, Strikwerda-Brown C, Mothakunnel A, Hodges JR, Piguet O, Irish M. Fronto-parietal contributions to episodic retrieval—Evidence from neurodegenerative disorders. Learning & memory. 2019;26(7):262-71.
23. Vatansever D, Smallwood J, Jefferies E. Varying demands for cognitive control reveals shared neural processes supporting semantic and episodic memory retrieval. Nature communications. 2021;12(1):2134.
24. Zhukovsky P, Coughlan G, Buckley R, Grady C, Voineskos AN. Connectivity between default mode and frontoparietal networks mediates the association between global amyloid-β and episodic memory. Human Brain Mapping. 2023;44(3):1147-57.
25. Kim H. Default network activation during episodic and semantic memory retrieval: a selective meta-analytic comparison. Neuropsychologia. 2016;80:35-46.
26. Yarkoni T, Poldrack RA, Nichols TE, Van Essen DC, Wager TD. Large-scale automated synthesis of human functional neuroimaging data. Nature methods. 2011;8(8):665-70.
27. Burianova H, Grady CL. Common and unique neural activations in autobiographical, episodic, and semantic retrieval. Journal of cognitive neuroscience. 2007;19(9):1520-34.
28. Chiou R, Humphreys GF, Jung J, Ralph MAL. Controlled semantic cognition relies upon dynamic and flexible interactions between the executive 'semantic control'and hub-and-spoke 'semantic representation'systems. cortex. 2018;103:100-16.
29. Jefferies E, Wang X. Semantic cognition: semantic memory and semantic control. Oxford Research Encyclopedia of Psychology2021.
30. Patterson K, Ralph MAL. The hub-and-spoke hypothesis of semantic memory. Neurobiology of language: Elsevier; 2016. p. 765-75.
31. Moscovitch M, Cabeza R, Winocur G, Nadel L. Episodic memory and beyond: the hippocampus and neocortex in transformation. Annual review of psychology. 2016;67:105-34.
32. Li Q, Tavakol S, Royer J, Larivière S, Vos De Wael R, Park B-y, et al. Atypical neural topographies underpin dysfunctional pattern separation in temporal lobe epilepsy. Brain. 2021;144(8):2486-98.
33. Giovagnoli AR, Avanzini G. Learning and memory impairment in patients with temporal lobe epilepsy: relation to the presence, type, and location of brain lesion. Epilepsia. 1999;40(7):904-11.
34. Bernasconi N, Duchesne S, Janke A, Lerch J, Collins DL, Bernasconi A. Whole-brain voxel-based statistical analysis of gray matter and white matter in temporal lobe epilepsy. Neuroimage. 2004;23(2):717-23.
35. Bernhardt BC, Bernasconi A, Liu M, Hong SJ, Caldairou B, Goubran M, et al. The spectrum of structural and functional imaging abnormalities in temporal lobe epilepsy. Annals of neurology. 2016;80(1):142-53.
36. Blümcke I, Thom M, Aronica E, Armstrong DD, Bartolomei F, Bernasconi A, et al. International consensus classification of hippocampal sclerosis in temporal lobe epilepsy: a Task Force report from the ILAE Commission on Diagnostic Methods. Epilepsia. 2013;54(7):1315-29.

37. Thom M, Eriksson S, Martinian L, Caboclo LO, McEvoy AW, Duncan JS, et al. Temporal lobe sclerosis associated with hippocampal sclerosis in temporal lobe epilepsy: neuropathological features. Journal of Neuropathology & Experimental Neurology. 2009;68(8):928-38.
38. Barrett Jones S, A. Miller L, Kleitman S, Nikpour A, Lah S. Semantic and episodic memory in adults with temporal lobe epilepsy. Applied Neuropsychology: Adult. 2022;29(6):1352-61.
39. Helmstaedter C. Effects of chronic epilepsy on declarative memory systems. Progress in brain research. 2002;135:439-53.
40. Viskontas IV, McAndrews MP, Moscovitch M. Remote episodic memory deficits in patients with unilateral temporal lobe epilepsy and excisions. Journal of Neuroscience. 2000;20(15):5853-7.
41. Messas CS, Mansur LL, Castro LHM. Semantic memory impairment in temporal lobe epilepsy associated with hippocampal sclerosis. Epilepsy & Behavior. 2008;12(2):311-6.
42. McDonald CR, Leyden KM, Hagler DJ, Kucukboyaci NE, Kemmotsu N, Tecoma ES, et al. White matter microstructure complements morphometry for predicting verbal memory in epilepsy. Cortex. 2014;58:139-50.
43. Rzezak P, Lima EM, Gargaro AC, Coimbra E, de Vincentiis S, Velasco TR, et al. Everyday memory impairment in patients with temporal lobe epilepsy caused by hippocampal sclerosis. Epilepsy & Behavior. 2017;69:31-6.
44. Saghafi S, Ferguson L, Hogue O, Gales JM, Prayson R, Busch RM. Histopathologic subtype of hippocampal sclerosis and episodic memory performance before and after temporal lobectomy for epilepsy. Epilepsia. 2018;59(4):825-33.
45. Silvia O, Patricia Ss, Damián C, Brenda G, Walter S, Estela C, et al. Mesial temporal lobe epilepsy and hippocampal sclerosis: cognitive function assessment in Hispanic patients. Epilepsy & Behavior. 2003;4(6):717-22.
46. Tavakol S, Kebets V, Royer J, Li Q, Auer H, DeKraker J, et al. DIFFERENTIAL MEMORY IMPAIRMENT ACROSS RELATIONAL DOMAINS IN TEMPORAL LOBE EPILEPSY. bioRxiv. 2022:2022.11. 01.514752.
47. Fleury M, Buck S, Binding LP, Caciagli L, Vos SB, Winston GP, et al. Episodic memory network connectivity in temporal lobe epilepsy. Epilepsia. 2022;63(10):2597-622.
48. Sidhu MK, Stretton J, Winston GP, Bonelli S, Centeno M, Vollmar C, et al. A functional magnetic resonance imaging study mapping the episodic memory encoding network in temporal lobe epilepsy. Brain. 2013;136(6):1868-88.
49. Tramoni E, Felician O, Barbeau EJ, Guedj E, Guye M, Bartolomei F, et al. Long-term consolidation of declarative memory: insight from temporal lobe epilepsy. Brain. 2011;134(3):816-31.
50. Boucher O, Dagenais E, Bouthillier A, Nguyen DK, Rouleau I. Different effects of anterior temporal lobectomy and selective amygdalohippocampectomy on verbal memory performance of patients with epilepsy. Epilepsy Behav. 2015;52(Pt A):230-5.
51. Helmstaedter C, Elger C, Hufnagel A, Zentner J, Schramm J. Different effects of left anterior temporal lobectomy, selective amygdalohippocampectomy, and temporal cortical lesionectomy on verbal learning, memory, and recognition. Journal of Epilepsy. 1996;9(1):39-45.
52. Tanriverdi T, Dudley RW, Hasan A, Al Jishi A, Al Hinai Q, Poulin N, et al. Memory outcome after temporal lobe epilepsy surgery: corticoamygdalohippocampectomy versus selective amygdalohippocampectomy. J Neurosurg. 2010;113(6):1164-75.

53. Fliessbach K, Witt J-A, Packheiser J, von Lehe M, Elger CE, Helmstaedter C. Depth-of-processing effects on memory encoding after selective amygdalohippocampectomy. Behavioural brain research. 2011;216(1):402-7.
54. Mansouri A, Fallah A, McAndrews MP, Cohn M, Mayor D, Andrade D, et al. Neurocognitive and Seizure Outcomes of Selective Amygdalohippocampectomy versus Anterior Temporal Lobectomy for Mesial Temporal Lobe Epilepsy. Epilepsy Res Treat. 2014;2014:306382.
55. Nadel L, Samsonovich A, Ryan L, Moscovitch M. Multiple trace theory of human memory: computational, neuroimaging, and neuropsychological results. Hippocampus. 2000;10(4):352-68.
56. Moscovitch M, Rosenbaum RS, Gilboa A, Addis DR, Westmacott R, Grady C, et al. Functional neuroanatomy of remote episodic, semantic and spatial memory: a unified account based on multiple trace theory. Journal of anatomy. 2005;207(1):35-66.
57. Lambon Ralph MA, Ehsan S, Baker GA, Rogers TT. Semantic memory is impaired in patients with unilateral anterior temporal lobe resection for temporal lobe epilepsy. Brain. 2012;135(Pt 1):242-58.
58. Bell BD, Hermann BP, Woodard AR, Jones JE, Rutecki PA, Sheth R, et al. Object naming and semantic knowledge in temporal lobe epilepsy. Neuropsychology. 2001;15(4):434-43.
59. Giovagnoli AR, Erbetta A, Villani F, Avanzini G. Semantic memory in partial epilepsy: verbal and non-verbal deficits and neuroanatomical relationships. Neuropsychologia. 2005;43(10):1482-92.
60. Poch C, Toledano R, García-Morales I, Alemán-Gómez Y, Gil-Nagel A, Campo P. Contributions of left and right anterior temporal lobes to semantic cognition: Evidence from patients with small temporopolar lesions. Neuropsychologia. 2021;152:107738.
61. Glosser G, Salvucci A, Chiaravalloti N. Naming and recognizing famous faces in temporal lobe epilepsy. Neurology. 2003;61(1):81-6.
62. Martin RC, Sawrie SM, Roth DL, Gilliam FG, Faught E, Morawetz RB, et al. Individual memory change after anterior temporal lobectomy: a base rate analysis using regression-based outcome methodology. Epilepsia. 1998;39(10):1075-82.
63. Margulies DS, Ghosh SS, Goulas A, Falkiewicz M, Huntenburg JM, Langs G, et al. Situating the default-mode network along a principal gradient of macroscale cortical organization. Proceedings of the National Academy of Sciences. 2016;113(44):12574-9.
64. Mesulam MM. From sensation to cognition. Brain. 1998;121 (Pt 6):1013-52.
65. Paquola C, Amunts K, Evans A, Smallwood J, Bernhardt B. Closing the mechanistic gap: the value of microarchitecture in understanding cognitive networks. Trends Cogn Sci. 2022;26(10):873-86.
66. Smallwood J, Bernhardt BC, Leech R, Bzdok D, Jefferies E, Margulies DS. The default mode network in cognition: a topographical perspective. Nature reviews neuroscience. 2021;22(8):503-13.
67. Murray JD, Bernacchia A, Freedman DJ, Romo R, Wallis JD, Cai X, et al. A hierarchy of intrinsic timescales across primate cortex. Nature neuroscience. 2014;17(12):1661-3.
68. Bernhardt BC, Smallwood J, Keilholz S, Margulies DS. Gradients in brain organization. Elsevier; 2022. p. 118987.
69. Huntenburg JM, Bazin P-L, Margulies DS. Large-scale gradients in human cortical organization. Trends in cognitive sciences. 2018;22(1):21-31.

70. Paquola C, Vos De Wael R, Wagstyl K, Bethlehem RA, Hong S-J, Seidlitz J, et al. Microstructural and functional gradients are increasingly dissociated in transmodal cortices. PLoS biology. 2019;17(5):e3000284.
71. Vázquez-Rodríguez B, Suárez LE, Markello RD, Shafiei G, Paquola C, Hagmann P, et al. Gradients of structure–function tethering across neocortex. Proceedings of the National Academy of Sciences. 2019;116(42):21219-27.
72. Borne L, Tian Y, Lupton MK, van der Meer JN, Jeganathan J, Paton B, et al. Functional re-organization of hippocampal-cortical gradients during naturalistic memory processes. NeuroImage. 2023;271:119996.
73. Strange BA, Witter MP, Lein ES, Moser EI. Functional organization of the hippocampal longitudinal axis. Nature Reviews Neuroscience. 2014;15(10):655-69.
74. Vos de Wael R, Larivière S, Caldairou B, Hong SJ, Margulies DS, Jefferies E, et al. Anatomical and microstructural determinants of hippocampal subfield functional connectome embedding. Proc Natl Acad Sci U S A. 2018;115(40):10154-9.
75. Genon S, Bernhardt BC, La Joie R, Amunts K, Eickhoff SB. The many dimensions of human hippocampal organization and (dys) function. Trends in neurosciences. 2021;44(12):977-89.
76. Bajada CJ, Jackson RL, Haroon HA, Azadbakht H, Parker GJM, Lambon Ralph MA, et al. A graded tractographic parcellation of the temporal lobe. Neuroimage. 2017;155:503-12.
77. Cerliani L, Thomas RM, Jbabdi S, Siero JC, Nanetti L, Crippa A, et al. Probabilistic tractography recovers a rostrocaudal trajectory of connectivity variability in the human insular cortex. Human brain mapping. 2012;33(9):2005-34.
78. Guell X, Schmahmann JD, Gabrieli J, Ghosh SS. Functional gradients of the cerebellum. Elife. 2018;7.
79. Haak KV, Marquand AF, Beckmann CF. Connectopic mapping with resting-state fMRI. Neuroimage. 2018;170:83-94.
80. Huntenburg JM, Bazin PL, Goulas A, Tardif CL, Villringer A, Margulies DS. A Systematic Relationship Between Functional Connectivity and Intracortical Myelin in the Human Cerebral Cortex. Cereb Cortex. 2017;27(2):981-97.
81. Paquola C, Bethlehem RA, Seidlitz J, Wagstyl K, Romero-Garcia R, Whitaker KJ, et al. Shifts in myeloarchitecture characterise adolescent development of cortical gradients. Elife. 2019;8.
82. Przeździk I, Faber M, Fernández G, Beckmann CF, Haak KV. The functional organisation of the hippocampus along its long axis is gradual and predicts recollection. Cortex. 2019;119:324-35.
83. Tian Y, Zalesky A. Characterizing the functional connectivity diversity of the insula cortex: Subregions, diversity curves and behavior. Neuroimage. 2018;183:716-33.
84. Lucas A, Mouchtaris S, Cornblath EJ, Sinha N, Caciagli L, Hadar P, et al. Subcortical functional connectivity gradients in temporal lobe epilepsy. NeuroImage: Clinical. 2023;38:103418.
85. Royer J, Larivière S, Rodriguez-Cruces R, Cabalo DG, Tavakol S, Auer H, et al. Cortical microstructural gradients capture memory network reorganization in temporal lobe epilepsy. Brain. 2023.
86. Park BY, Larivière S, Rodríguez-Cruces R, Royer J, Tavakol S, Wang Y, et al. Topographic divergence of atypical cortical asymmetry and atrophy patterns in temporal lobe epilepsy. Brain. 2022;145(4):1285-98.

87. Hatton SN, Huynh KH, Bonilha L, Abela E, Alhusaini S, Altmann A, et al. White matter abnormalities across different epilepsy syndromes in adults: an ENIGMA-Epilepsy study. Brain. 2020;143(8):2454-73.
88. Bernhardt BC, Bernasconi N, Concha L, Bernasconi A. Cortical thickness analysis in temporal lobe epilepsy: reproducibility and relation to outcome. Neurology. 2010;74(22):1776-84.
89. Bernhardt BC, Fadaie F, de Wael RV, Hong S-J, Liu M, Guiot MC, et al. Preferential susceptibility of limbic cortices to microstructural damage in temporal lobe epilepsy: A quantitative T1 mapping study. Neuroimage. 2018;182:294-303.
90. DeKraker J, Haast RAM, Yousif MD, Karat B, Lau JC, Köhler S, et al. Automated hippocampal unfolding for morphometry and subfield segmentation with HippUnfold. Elife. 2022;11.
91. Cruces RR, Royer J, Herholz P, Larivière S, Vos de Wael R, Paquola C, et al. Micapipe: A pipeline for multimodal neuroimaging and connectome analysis. Neuroimage. 2022;263:119612.
92. Coifman RR, Lafon S. Diffusion maps. Applied and computational harmonic analysis. 2006;21(1):5-30.
93. Van Essen DC, Ugurbil K, Auerbach E, Barch D, Behrens TE, Bucholz R, et al. The Human Connectome Project: a data acquisition perspective. Neuroimage. 2012;62(4):2222-31.
94. Langs G, Golland P, Ghosh SS, editors. Predicting activation across individuals with resting-state functional connectivity based multi-atlas label fusion. Medical Image Computing and Computer-Assisted Intervention--MICCAI 2015: 18th International Conference, Munich, Germany, October 5-9, 2015, Proceedings, Part II 18; 2015: Springer.
95. Vos de Wael R, Benkarim O, Paquola C, Lariviere S, Royer J, Tavakol S, et al. BrainSpace: a toolbox for the analysis of macroscale gradients in neuroimaging and connectomics datasets. Commun Biol. 2020;3(1):103.
96. Lutz MT, Helmstaedter C. EpiTrack: tracking cognitive side effects of medication on attention and executive functions in patients with epilepsy. Epilepsy Behav. 2005;7(4):708-14.
97. Wagstyl K, Ronan L, Goodyer IM, Fletcher PC. Cortical thickness gradients in structural hierarchies. Neuroimage. 2015;111:241-50.
98. Vos de Wael R, Royer J, Tavakol S, Wang Y, Paquola C, Benkarim O, et al. Structural connectivity gradients of the temporal lobe serve as multiscale axes of brain organization and cortical evolution. Cerebral cortex. 2021;31(11):5151-64.
99. Buckner RL, Krienen FM. The evolution of distributed association networks in the human brain. Trends in cognitive sciences. 2013;17(12):648-65.
100. Smallwood J. Distinguishing how from why the mind wanders: a process–occurrence framework for self-generated mental activity. Psychological bulletin. 2013;139(3):519.
101. Smallwood J, Schooler JW. The science of mind wandering: Empirically navigating the stream of consciousness. Annual review of psychology. 2015;66:487-518.
102. Ho NSP, Poerio G, Konu D, Turnbull A, Sormaz M, Leech R, et al. Facing up to the wandering mind: Patterns of off-task laboratory thought are associated with stronger neural recruitment of right fusiform cortex while processing facial stimuli. Neuroimage. 2020;214:116765.
103. Smallwood J, Turnbull A, Wang H-t, Ho NS, Poerio GL, Karapanagiotidis T, et al. The neural correlates of ongoing conscious thought. Iscience. 2021;24(3).
104. Kelley WM, Macrae CN, Wyland CL, Caglar S, Inati S, Heatherton TF. Finding the self? An event-related fMRI study. Journal of cognitive neuroscience. 2002;14(5):785-94.

105. Mok RM, Love BC. A multilevel account of hippocampal function in spatial and concept learning: Bridging models of behavior and neural assemblies. Science Advances. 2023;9(29):eade6903.
106. Koster R, Chadwick MJ, Chen Y, Berron D, Banino A, Düzel E, et al. Big-loop recurrence within the hippocampal system supports integration of information across episodes. Neuron. 2018;99(6):1342-54. e6.
107. Paquola C, Benkarim O, DeKraker J, Lariviere S, Frässle S, Royer J, et al. Convergence of cortical types and functional motifs in the human mesiotemporal lobe. elife. 2020;9:e60673.
108. Chase HW, Clos M, Dibble S, Fox P, Grace AA, Phillips ML, et al. Evidence for an anterior–posterior differentiation in the human hippocampal formation revealed by meta-analytic parcellation of fMRI coordinate maps: Focus on the subiculum. NeuroImage. 2015;113:44-60.
109. Sydnor VJ, Larsen B, Bassett DS, Alexander-Bloch A, Fair DA, Liston C, et al. Neurodevelopment of the association cortices: Patterns, mechanisms, and implications for psychopathology. Neuron. 2021;109(18):2820-46.
110. Poppenk J, Evensmoen HR, Moscovitch M, Nadel L. Long-axis specialization of the human hippocampus. Trends in cognitive sciences. 2013;17(5):230-40.
111. Larivière S, Weng Y, Vos de Wael R, Royer J, Frauscher B, Wang Z, et al. Functional connectome contractions in temporal lobe epilepsy: Microstructural underpinnings and predictors of surgical outcome. Epilepsia. 2020;61(6):1221-33.
112. Xie K, Royer J, Lariviere S, Rodriguez-Cruces R, Frassle S, Cabalo DG, et al. Atypical connectome topography and signal flow in temporal lobe epilepsy. bioRxiv. 2023:2023.05. 23.541934.
113. Morgan VL, Rogers BP, Sonmezturk HH, Gore JC, Abou-Khalil B. Cross hippocampal influence in mesial temporal lobe epilepsy measured with high temporal resolution functional magnetic resonance imaging. Epilepsia. 2011;52(9):1741-9.
114. Rodríguez-Cruces R, Bernhardt BC, Concha L. Multidimensional associations between cognition and connectome organization in temporal lobe epilepsy. NeuroImage. 2020;213:116706.
115. Dabbs K, Jones J, Seidenberg M, Hermann B. Neuroanatomical correlates of cognitive phenotypes in temporal lobe epilepsy. Epilepsy & Behavior. 2009;15(4):445-51.
116. Doucet G, Osipowicz K, Sharan A, Sperling MR, Tracy JI. Extratemporal functional connectivity impairments at rest are related to memory performance in mesial temporal epilepsy. Human brain mapping. 2013;34(9):2202-16.
117. Liu M, Bernhardt BC, Hong S-J, Caldairou B, Bernasconi A, Bernasconi N. The superficial white matter in temporal lobe epilepsy: a key link between structural and functional network disruptions. Brain. 2016;139(9):2431-40.
118. García-Cabezas MÁ, Zikopoulos B, Barbas H. The Structural Model: a theory linking connections, plasticity, pathology, development and evolution of the cerebral cortex. Brain Structure and Function. 2019;224(3):985-1008.
119. Goldstein FC, Mao H, Wang L, Ni C, Lah JJ, Levey AI. White matter integrity and episodic memory performance in mild cognitive impairment: a diffusion tensor imaging study. Brain Imaging and Behavior. 2009;3:132-41.
120. Witt J-A, Coras R, Schramm J, Becker AJ, Elger CE, Blümcke I, et al. Relevance of hippocampal integrity for memory outcome after surgical treatment of mesial temporal lobe epilepsy. Journal of neurology. 2015;262:2214-24.

121. Tromp D, Dufour A, Lithfous S, Pebayle T, Després O. Episodic memory in normal aging and Alzheimer disease: Insights from imaging and behavioral studies. Ageing research reviews. 2015;24:232-62.
122. Vargha-Khadem F, Gadian DG, Watkins KE, Connelly A, Van Paesschen W, Mishkin M. Differential effects of early hippocampal pathology on episodic and semantic memory. Science. 1997;277(5324):376-80.
123. Mishkin M, Suzuki WA, Gadian DG, Vargha–Khadem F. Hierarchical organization of cognitive memory. Philosophical Transactions of the Royal Society of London Series B: Biological Sciences. 1997;352(1360):1461-7.
124. Moscovitch M, Nadel L, Winocur G, Gilboa A, Rosenbaum RS. The cognitive neuroscience of remote episodic, semantic and spatial memory. Current opinion in neurobiology. 2006;16(2):179-90.
125. Klinzing JG, Niethard N, Born J. Mechanisms of systems memory consolidation during sleep. Nature neuroscience. 2019;22(10):1598-610.
126. Squire LR, Genzel L, Wixted JT, Morris RG. Memory consolidation. Cold Spring Harbor perspectives in biology. 2015;7(8):a021766.
127. Moscovitch M, Westmacott R, Gilboa A, Addis DR, Rosenbaum RS, Viskontas I, et al. Hippocampal complex contribution to retention and retrieval of recent and remote episodic and semantic memories: Evidence from behavioral and neuroimaging studies of healthy and brain-damaged people. Dynamic cognitive processes. 2005:333-80.
128. Eldridge LL, Knowlton BJ, Furmanski CS, Bookheimer SY, Engel SA. Remembering episodes: a selective role for the hippocampus during retrieval. Nature neuroscience. 2000;3(11):1149-52.
129. Moscovitch DA, McAndrews MP. Material-specific deficits in “remembering” in patients with unilateral temporal lobe epilepsy and excisions. Neuropsychologia. 2002;40(8):1335-42.
130. Yonelinas AP. The nature of recollection and familiarity: A review of 30 years of research. Journal of memory and language. 2002;46(3):441-517.
131. Rosenbaum RS, Priselac S, Köhler S, Black SE, Gao F, Nadel L, et al. Remote spatial memory in an amnesic person with extensive bilateral hippocampal lesions. Nature neuroscience. 2000;3(10):1044-8.
132. Burgess N, Maguire EA, O'Keefe J. The human hippocampus and spatial and episodic memory. Neuron. 2002;35(4):625-41.
133. Suzuki WA. Declarative versus episodic: two theories put to the test. Neuron. 2003;38(1):5-7.
134. Tulving E, Markowitsch HJ. Episodic and declarative memory: role of the hippocampus. Hippocampus. 1998;8(3):198-204.
135. J Jr E. Outocme with respect to epileptic seizures. Surgical treatment of the epilepsies. 1993:609-21.
136. Han L, Kashyap AL, Finin TW, Mayfield J, Weese J, editors. UMBC_EBIQUITY-CORE: Semantic Textual Similarity Systems. International Workshop on Semantic Evaluation; 2013.
137. Basser PJ, Mattiello J, LeBihan D. Estimation of the effective self-diffusion tensor from the NMR spin echo. J Magn Reson B. 1994;103(3):247-54.
138. Veraart J, Sijbers J, Sunaert S, Leemans A, Jeurissen B. Weighted linear least squares estimation of diffusion MRI parameters: strengths, limitations, and pitfalls. Neuroimage. 2013;81:335-46.

139. Jenkinson M, Beckmann CF, Behrens TE, Woolrich MW, Smith SM. FSL. Neuroimage. 2012;62(2):782-90.
140. Avants BB, Tustison NJ, Song G, Cook PA, Klein A, Gee JC. A reproducible evaluation of ANTs similarity metric performance in brain image registration. Neuroimage. 2011;54(3):2033-44.
141. Cox RW. AFNI: software for analysis and visualization of functional magnetic resonance neuroimages. Comput Biomed Res. 1996;29(3):162-73.
142. Salimi-Khorshidi G, Douaud G, Beckmann CF, Glasser MF, Griffanti L, Smith SM. Automatic denoising of functional MRI data: combining independent component analysis and hierarchical fusion of classifiers. Neuroimage. 2014;90:449-68.
143. Marcus DS, Harms MP, Snyder AZ, Jenkinson M, Wilson JA, Glasser MF, et al. Human Connectome Project informatics: quality control, database services, and data visualization. Neuroimage. 2013;80:202-19.
144. Larivière S, Bayrak Ş, Vos de Wael R, Benkarim O, Herholz P, Rodriguez-Cruces R, et al. BrainStat: A toolbox for brain-wide statistics and multimodal feature associations. Neuroimage. 2023;266:119807.
145. Worsley KJ, Taylor J, Carbonell F, Chung M, Duerden E, Bernhardt B, et al., editors. A Matlab toolbox for the statistical analysis of univariate and multivariate surface and volumetric data using linear mixed effects models and random field theory. NeuroImage Organisation for Human Brain Mapping 2009 Annual Meeting; 2009.

Supplementary Materials, Methods, and Results

DIFFERENTIAL REORGANIZATION OF EPISODIC AND SEMANTIC MEMORY SYSTEMS IN EPILEPSY-RELATED MESIOTEMPORAL PATHOLOGY

Donna Gift Cabalo[1,2], Jordan DeKraker[1,2], Jessica Royer[1,2,3], Ke Xie[1,2], Shahin Tavakol[1,2], Raúl Rodríguez-Cruces[1,2], Andrea Bernasconi[2], Neda Bernasconi[2], Alexander Weil[4], Raluca Pana[2], Birgit Frauscher[2,3], Lorenzo Caciagli[5], Elizabeth Jefferies[6], Jonathan Smallwood[7], Boris C. Bernhardt[1,2]

[1]Multimodal Imaging and Connectome Analysis Laboratory, McConnell Brain Imaging Centre, Montreal Neurological Institute, McGill University, Montreal, QC, Canada; [2]Montreal Neurological Institute and Hospital, McGill University, Montreal, QC, Canada; [3]Analytical Neurophysiology Laboratory, Montreal Neurological Institute, McGill University, Montreal, Quebec, Canada; [4]CHU St Justine, Montreal, QC; [5] Department of Bioengineering, University of Pennsylvania, Philadelphia, USA; [6] University of York, North Yorkshire, United Kingdom; [7]Queens University, Kingston, Ontario, Canada;

CORRESPONDENCE TO:

Donna Gift Cabalo

McConnell Brain Imaging Centre, Montreal Neurological Institute, McGill University, Montreal, QC, Canada

donna.cabalo@mail.mcgill.ca

Boris Bernhardt, PhD

McConnell Brain Imaging Centre, Montreal Neurological Institute, McGill University, Montreal, QC, Canada

boris.bernhardt@mcgill.ca

boris.bernhardt@mcgill.ca

ID	Age	Sex	HD	Laterality	Location	Engel outcome
PX005	26	F	R	L	L posterior quadrant, incl. Calcarine cortex	1a
PX006	34	M	R	L	L mesiotemporal, hippocampal formation	1a
PX008	20	F	R	L	L uncus mass	1a
PX009	25	F	R	L	n/a	2b
PX013	57	M	R	L	L temporal and hippocampal atrophy	1a
PX016	41	F	R	R	R mesiotemporal sclerosis	1a
PX019	31	M	R	L	Suspected L posterior fusiform/parahippocampal FCD + Lhippocampal atrophy	n/a
PX020	52	M	R	L	T2 hyperintensity on L hippocampus and amygdala	n/a
PX021	55	F	R	L	T2 hyperintensity on L hippocampus	1a
PX024	26	F	L	L	L hippocampal atrophy	n/a
PX032	53	F	R	L	T2 hyperintensity on L hippocampus	n/a
PX036	24	M	R	L	Hyperintensity in L MTL (uncus)	n/a
PX044	43	M	R	R	n/a	1a
PX050	32	M	R	R	R temporal atrophy	1a
PX053	41	M	R	L	Hyperintensity in L MTL and Linsular cortex	n/a
PX055	27	F	R	L	MRI-negative	n/a
PX060	25	F	R	R	Decrease WM differentiation in R fusiform and parahippocampal gyrus	2b
PX063	28	M	R	L	Lhippocampal atrophy and T2 hyperintensity	n/a
PX065	29	M	R	R	MRI-negative	n/a
PX066	27	F	R	L	MRI-negative	n/a

Table S1. **Patient's demographics and clinical features**. **Abbreviations**: L=left; R=right, MTL=medial temporal lobe, FCD=Focal cortical dysplasia, HD= Handedness, WM= white matter

	a	b	c’	c	ab
Neocortex					
$G1_{ipsi}$	0.58(0.20)*	0.25(0.11)*	0.84(0.27)**	0.99(0.26)***	0.14(0.08)*
$G1_{contra}$	0.57(0.18)**	0.19(0.12)	0.87(0.28)**	0.98(0.26)***	0.11(0.08)
$G2_{ipsi}$	0.57(0.24)*	0.11(0.12)	0.93(0.29)**	0.98(0.26)***	0.06(0.07)
$G2_{contra}$	0.53(0.2)**	0.21(0.14)	0.88(0.29)**	0.98(0.27)***	0.11(0.08)
$G3_{ipsi}$	0.76(0.27)**	0.07(0.14)	0.93(0.29)**	0.98(0.26)***	0.05(0.11)
Hippocampus					
$G1_{ipsi}$	1.08(0.35)***	0.12(0.1)	0.85(0.26)**	0.98(0.26)***	0.14(0.13)
Neocortex +	**Hippocampus**				
$G1_{ipsi}$	0.72(0.18)***	0.36(0.13)**	0.72(0.27)*	0.98(0.26)***	0.26(0.12)**

Table S2. **Individual mediation analysis for Episodic memory gradients**. The mean of significant regions showing significant episodic gradient scores were used as mediators for each analysis. **Abbreviations:** G1=Gradient1, G2=Gradient 2; G3=Gradient3,Ipsi=ipsilateral, Contra=contralateral, a = Group ~ Gradient scores (standard errors in parenthesis), b= Gradient scores ~ Episodic memory performance, c’= Group ~ Episodic memory performance, c’= Group ~ Episodic memory performance (residual), ab= mediation effect

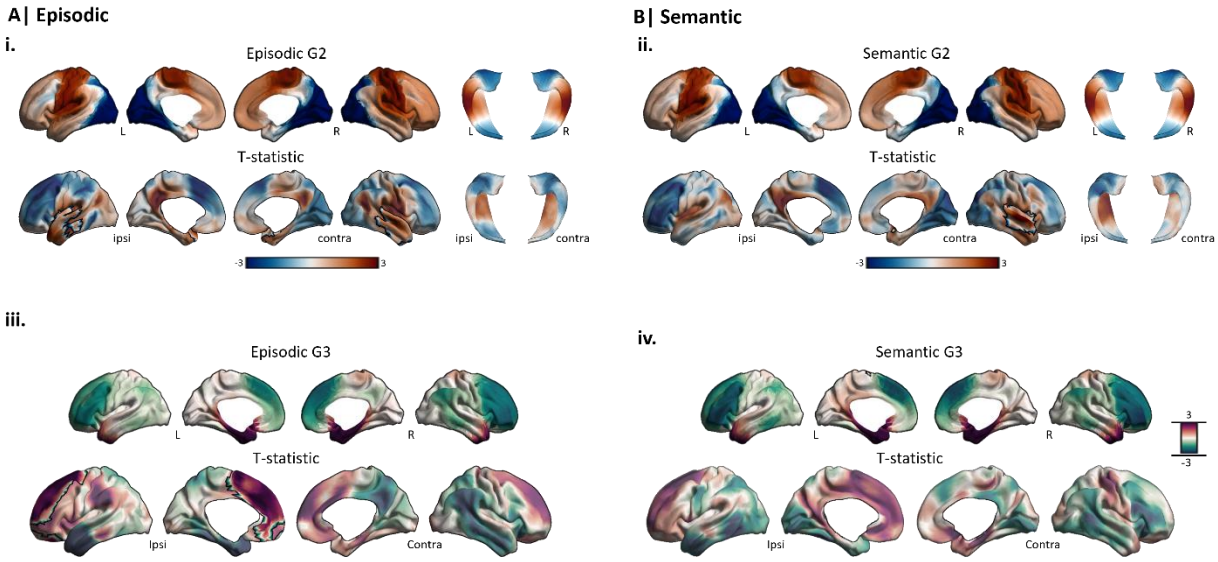

Figure S1. **(i,ii).** Episodic/Semantic G2 describing a visual-to-somatomotor topography and explained 15/14% of variance (top)**.** TLE-related G2 contractions in episodic memory, localized in temporal and insular regions, while semantic G2 contractions were confined in the contralateral temporal lobe (bottom). Significant *p*-values were highlighted after correcting for multiple comparisons ($p_{FWE} < 0.05$). In both memory states, hippocampal G2 reflected a proximal-distal representation and explained 13/12% of functional connectome variance. No significant differences were observed in both states. **(iii,iv).** Episodic/Semantic G3, dominated by networks involved in the declarative memory tasks and explained 11% of the total episodic and semantic variance. G3 suppression in TLE for episodic memory state were recorded in prefrontal cortices, ipsilateral to seizure focus. **Abbreviations**: G2= Gradient 2,G3 = Gradient 3, Ipsi= ipsilateral, Contra=contralateral, L=left, R=right.

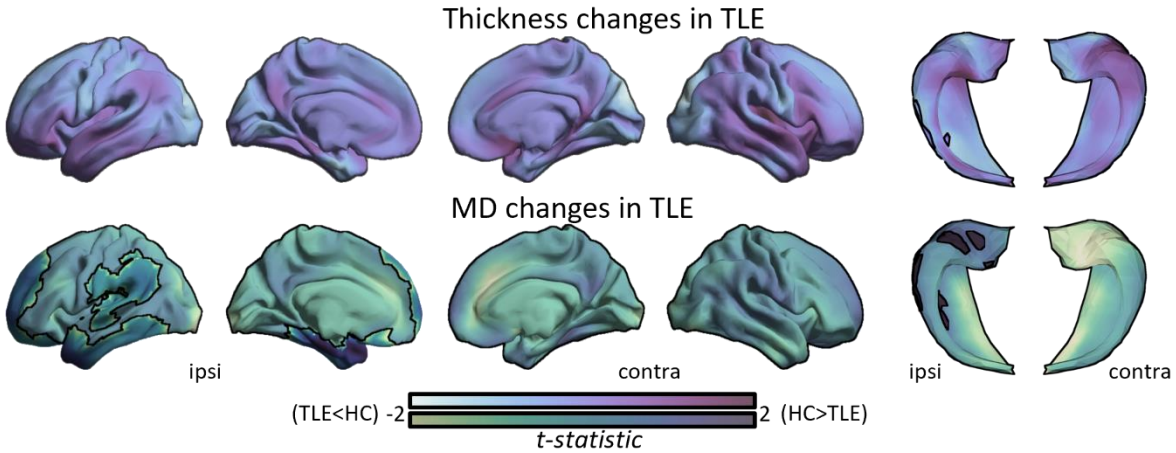

Figure S2. **Morphology and Microstructure.** Cortex-wide and subregional hippocampal univariate differences in thickness and mean diffusivity (MD) between healthy and TLE patients. Significant *p*-values were highlighted after correcting for multiple comparisons ($p_{FWE} < 0.05$). **Abbreviations:** TLE=temporal lobe epilepsy, HC= healthy controls, Ipsi= ipsilateral, Contra=contralateral

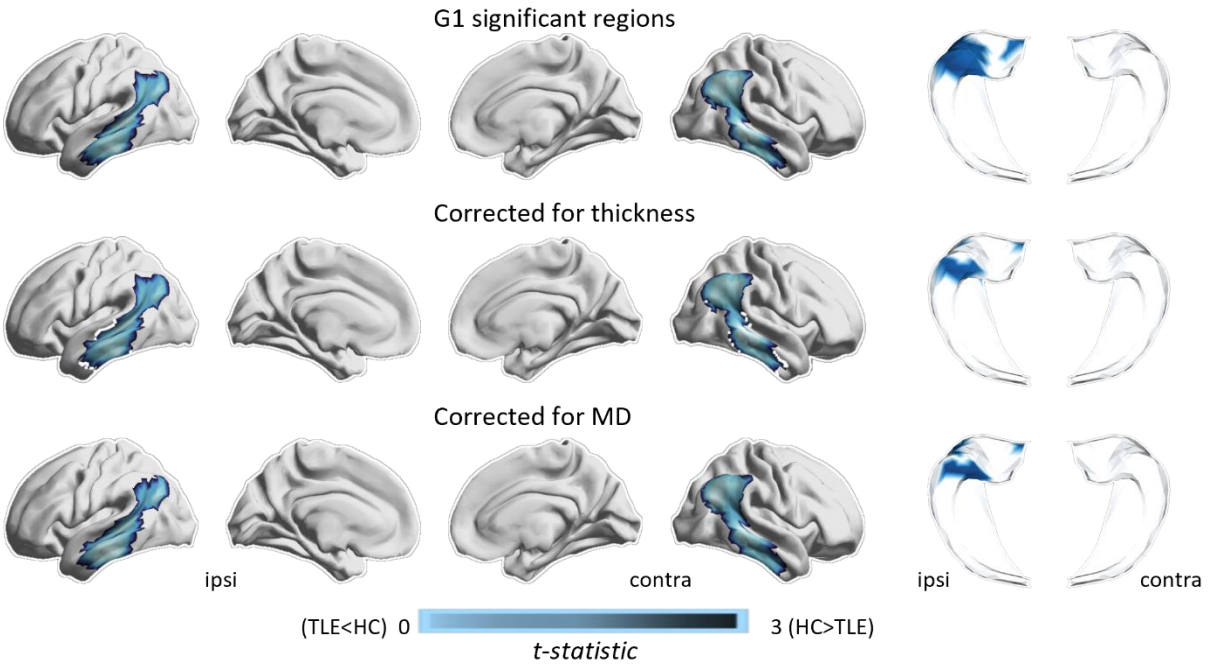

Figure S3. **Morphology, microstructure and gradients.** Cortex-wide and subregional hippocampal univariate differences in Episodic G1 after controlling for thickness and mean diffusivity (MD) between healthy and TLE patients. ($p_{FWE} < 0.05$). At the neocortical level, thickness and MD did not have a significant impact, while both morphology and microstructural properties weakened the G1 differences. **Abbreviations:** *TLE=temporal lobe epilepsy, HC= healthy controls, Ipsi= ipsilateral, Contra=contralateral*

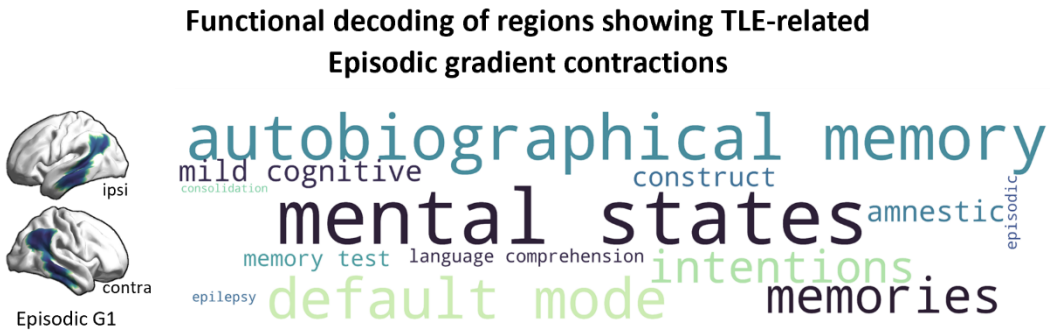

Figure S4. The associated cognitive terms were extracted using the Neurosynth decoder function and represented in a word-cloud plot. The size of the fonts used for each term reflects the correlation between the FDR-corrected maps and the Neurosynth-generated meta-analytic maps.

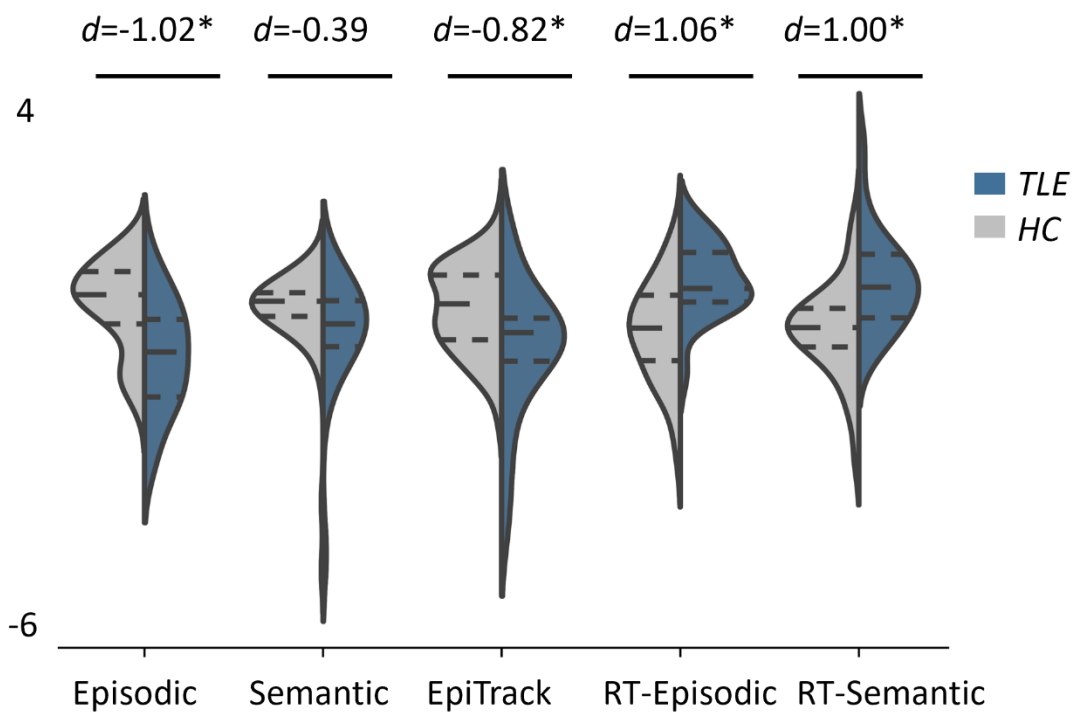

Figure S5. Differences in total episodic, semantic task, EpiTrack scores, and reaction times. **Abbreviations**: TLE=temporal lobe epilepsy, HC=healthy controls