Placental malaria is associated with a TLR–Endothelin-3–oxidative damage response in human placenta tissues

Samuel Chenge[1,2], Melvin Mbalitsi[1], Harrison Ngure[1], Moses Obimbo[3], Mercy Singoei[3], Mourine Kangogo[2], Bernard N. Kanoi[1], Jesse Gitaka[1,*,#], and Francis M. Kobia[1,*,#]

[1]Centre for Malaria Elimination, Mount Kenya University, Thika – Kenya.

[2]Department of Medical Microbiology, Jomo Kenyatta University of Agriculture and Technology, Nairobi – Kenya

[3]Department of Human Anatomy, University of Nairobi, Nairobi – Kenya

***Correspondence**: Francis M. Kobia (fkobia@associates.mku.ac.ke), Center for Malaria Elimination, Mount Kenya University, P.O. Box 342-01000, Thika – Kenya. Jesse Gitaka (jgitaka@mku.ac.ke), Center for Malaria Elimination, Mount Kenya University, P.O. Box 342-01000, Thika – Kenya.

[#]co-senior authorship

Abstract

Placental malaria, which is mainly caused by the sequestration of *Plasmodium falciparum*-infected erythrocytes in the placenta, is an important driver of poor pregnancy outcomes, including fetal growth restriction, preterm birth, and stillbirth. However, the mechanisms underlying its adverse outcomes are unclear. Mouse models have previously shown that placental malaria (PM) triggers a proinflammatory response in the placenta, which is accompanied by a fetal Toll-like receptor (TLR)4-mediated innate immune response associated with improved fetal outcomes. Here, we used hematoxylin and eosin staining to identify PM-positive and negative samples in our biobank of placentas donated by women living in a malaria-endemic region of Kenya and assessed the impact of PM on the expression of TLRs, Endothelins, and oxidative damage. RT-qPCR analysis revealed that PM was associated with an upregulation of TLR4, TLR7, and Endothelin-3. Moreover, immunohistochemistry showed that PM was associated with elevated expression levels of the oxidative DNA damage marker, 8-hydroxy-2'-deoxyguanosine, while RT-qPCR revealed that this was accompanied by an upregulation of p21, an inhibitor of cell cycle progression and marker of cellular response to DNA damage. These findings allude to a novel mechanism of PM pathogenesis driven by a TLR–Endothelin-3–oxidative DNA damage signaling axis.

Keywords: Placental malaria, malaria in pregnancy, poor pregnancy outcomes, innate immunity, *Plasmodium falciparum*

1. Introduction

According to the World Health Organization, globally, there were about 249 million malaria cases and 608,000 malaria-associated deaths in 2022, with sub-Saharan Africa accounting for most of the cases and deaths [1]. Pregnant women have a higher susceptibility to malaria infection [2] and it is estimated that in 2022, there were about 12.7 million cases of malaria in pregnancy (MiP) in sub-Saharan Africa [1]. MiP is associated with several adverse outcomes on the mother, the fetus, and neonate [3]. For the fetus, MiP severely worsens pregnancy outcomes and frequently leads to fetal growth restriction (including low birthweight, small for gestational age, and intrauterine growth restriction) and may result in preterm birth and stillbirth [3–5].

The adverse effects of MiP on the fetus are attributable to malaria infection of the placenta [1], leading to placental malaria (PM). PM is characterized by the sequestration of *Plasmodium*-infected erythrocytes in placental intervillous spaces. This phenomenon is most frequently associated with *Plasmodium falciparum* (*P*. *falciparum*), the species associated with the most severe form of malaria [6]. The sequestration of *P. falciparum*-infected erythrocytes to the placenta is mediated by the interaction between variant surface chondroitin surface antigen 2, a *Plasmodium falciparum* protein expressed on the surface of infected erythrocytes [7], and chondroitin sulfate A on the surface of the syncytiotrophoblast [7], the placental epithelial cell layer that contacts maternal blood [8].

The adverse impacts of PM on fetal well-being most likely results from the negative effects of PM on placental health and function since the vertical transmission of malaria to the fetus is rare [9]. Indeed, PM is reported to induce placental inflammation [10,11] and placental histological changes [12], which may contribute to placental insufficiency and poor pregnancy outcomes. However, the mechanisms underlying PM-driven placental pathobiology are not fully understood at the cellular and cell signaling levels.

Innate immune factors, such as Toll-like receptor (TLR)4, 7, and 9, which respond to infection by recognizing and clearing invading pathogens are reported to respond to malaria infection [13], although their role in PM is unclear. Although several studies have investigated maternal responses to PM, few have studied how the fetus responds to parasite sequestration in the placenta. Nonetheless, a mouse model of PM revealed that PM triggers a TLR4-mediated innate immune reaction that adversely affects fetal outcomes, which is countered by a fetal innate immune reaction that led to better pregnancy outcomes [14]. This suggests the presence of TLR-mediated innate immune responses to PM, although this has not been reported in the context of human PM. Here, considering that mouse data show that TLR4 modulates endothelin-1 expression [15], malaria is inflammatory and oxidative [16], oxidative DNA damage upregulates TLR4 [17], and TLR signaling is thought to promote DNA repair [18], we used biobank placenta samples donated by women living in a malaria-endemic region of Kenya to examine the hypothesis that human PM triggers a TLR–Endothelin–oxidative damage signaling response.

2. Materials and methods

2.1 The biobank and study participants

The study used biobank placenta samples donated by residents of Bungoma County, a malaria-endemic region of Western Kenya. The biobank was established by a previous prospective parent study. All placenta donors were aged ≥18 years and gave written informed consent to participate in the parent study. Based on questionnaire responses, participants with a known record of sexually transmitted disease infection during pregnancy, those with pregnancy-associated noncommunicable diseases (preeclampsia and gestational diabetes) during the current pregnancy, and those with twin pregnancies were excluded from our analyses. During participant recruitment and sample collection, participants were recorded as having MiP if they had at least one episode of hospital-diagnosed malaria during pregnancy. Maternal malaria

status was diagnosed using a rapid diagnostic test (Malaria Ag P.f, SD Biosensor). All data underlying the databank were deidentified. The characteristics of the biobank's placenta donors and samples are summarized in Table 1. Equal numbers of male and female placentas were analyzed. Demographic data (Table 1), including maternal age, history of malaria during pregnancy, and gravidity were collected using questionnaires, whereas pregnancy-associated data, including birthweight and placental weight, were recorded after birth. All participants gave written informed consent before joining the study and agreed to the collection and use of their placenta samples in the study.

2.2 Histological analysis

Formalin-fixed placenta tissues were embedded in paraffin blocks as previously described [19] using an automated tissue embedding system (MediMeas). H&E analysis was used to confirm the presence of PM, which is indicated by the presence of infected erythrocytes in the placenta. Briefly, formalin-fixed paraffin-embedded samples were sectioned onto charged microscope slides (Dako, Cat No. K8020) at a 5-µm thickness, dried at 37 °C overnight on a slide warmer, dewaxed in xylene (Finar Chemicals, Cat No. 21940LC250), rehydrated by dipping across an alcohol gradient of absolute, 95%, 70%, and 50% ethanol (Scharlau, Cat No. ET00052500), and then in distilled water. They were then submerged in hematoxylin (Loba Chemie, Cat No. 04023) for seven minutes, rinsed with running water, and then destained through 10 dips in acid alcohol (1% hydrochloric acid in 70% ethanol). Next, they were submerged in eosin (Griffchem, Cat No. 45380) for 45 seconds followed by dehydration in 95% ethanol and absolute ethanol (five minutes each) and then cleared in xylene baths (10 minutes each) before being cover-slipped using dibutylphthalate polystyrene xylene mountant (Finar Chemicals, Cat No. 10525LM250). The slides were then examined under a microscope (Richter Optica UX1, M2 Scientifics), followed by imaging in ≥10 fields of view per slide at a 40X magnification using a Moticam microscope camera (Motic Scientific). PM was then diagnosed as described before

(Odongo et al., 2016) based on the presence of infected erythrocytes. PM-associated histopathological features were assessed by counting the number of syncytial knots as described previously [20] and measuring the fibrin-occupied placental areas using imageJ. These analyses were done in at least 10 fields of view per sample. The levels of PM burden in the PM-positive samples were determined by counting the number of identified infected erythrocytes in at least 10 fields of view per slide imaged at a magnification of 40X.

2.4 RNA extraction and reverse transcription quantitative PCR (RT-qPCR)

Total RNA was extracted from placenta tissue using a HigherPurity™ Tissue Total RNA Purification kit as per the manufacturer's guidelines (Canvax, cat No. AN0152) and quantified using a NanoDrop Microvolume Spectrophotometer (ThermoFisher Scientific) following the manufacturer's instructions. For each sample, 500 ng of RNA were retrotranscribed into cDNA using a LunaScript™ RT SuperMix cDNA Synthesis Kit (NEB, Cat. No. E3010L) using the manufacturer's protocol. RT-qPCR analysis was done on a QuantStudio™ 5 Real-Time PCR System in a final volume of 20 µl containing 10 µl of GoTaq qPCR Master Mix (Promega, Cat No. PRA6001), 2 µl of the forward plus reverse primers (final primer concentration: 500 nM), 3 µl of nuclease free water (Promega, Cat No. P119E), and 5 µl of cDNA using the following program: 50 °C for two minutes, 95 °C for 10 minutes, followed by 40 cycles at 95 °C for 15 seconds and 60°C for 30 seconds. Relative gene expression was determined using the $2^{-\Delta\Delta ct}$ method [21], using β-actin as the reference gene. Primers were purchased from Macrogen and primer sequences are provided in Table 3.

2.5 *P. falciparum* detection PCR

The presence of *P. falciparum* in placenta samples was evaluated using One Taq® Quick-Load® 2X Master Mix with Standard Buffer (NEB, Cat No. M0486L) and the following thermocycler program: Initial denaturation at 95 °C for five minutes, followed by 35 cycles of denaturation at 95 °C for 30 seconds, annealing at 55 °C for 60 seconds, and extension at 72

°C for 75 seconds, and then a final extension at 72 °C for five minutes. Primer sequences are shown in Table 3. The PCR product was subjected to agarose (Sigma–Aldrich, Cat No. A9539) gel electrophoresis using 1X tris–borate–EDTA buffer alongside a 100 base pair ladder using SafeView™ Classic (Applied Biological Materials, Cat No. G108) nucleic acid stain and Gel Loading Dye, Purple (6X) (NEB, Cat No. B7024S). The bands were developed and imaged using a UVITEC Gel Documentation System (Cleaver Scientific).

2.6 Immunohistochemistry

The sections were deparaffinized by warming at 55 °C for 15 minutes followed by dipping in three xylene baths, about 10 dips each. They were then rehydrated and subjected to heat-induced epitope retrieval by boiling for 30 minutes in Citrate Buffer, pH 6.0 (Sigma–Aldrich, cat. No. C9999). They were then cooled to room temperature, rinsed with distilled water for five minutes and then blocked with 0.3% Triton-X in 1X phosphate-buffered saline (PBST). Next, they were blocked with 10% normal donkey serum (Abcam, cat. No. ab7475) in PBST for two hours followed by overnight incubation (4 °C) with anti-DNA/RNA damage antibody [15A3] (Abcam, cat. No. ab62623) at 1:2500 in blocking solution. Sections were then washed thrice (10 minutes each) using PBST and then incubated at room temperature for two hours with horseradish peroxidase-conjugated goat anti-mouse secondary antibody (Jackson ImmunoResearch, cat. No. 115-035-003) at 1:5000 in blocking solution. The sections were then washed thrice (10 minutes each) using PBST followed by signal development using an ImmPACT® DAB Substrate Kit (Vector, cat. No. SK-4105) as per the manufacturer's protocol. They were then dehydrated using 95%, 95%, 100%, and 100% ethanol (five minutes each), cleared by dipping in three xylene baths and then cover-slipped using a xylene-based mountant and allowed to dry. They were then examined under a light microscope and imaged at a magnification of 40X.

2.7 Data analyses

Statistical analyses were done using GraphPad Prism version 9. Data are presented as percentages, raw values, or mean ± standard deviation. Differences between two groups were compared using a t-test. Correlation analyses were done using nonparametric Spearman correlation analysis. For each placenta, the PM burden in placentas was indicated by the total number of infected erythrocytes in the placenta section. The birthweight-to-placenta weight (BW:PW) ratio was obtained by dividing the birthweight (grams) with the corresponding placenta's weight (grams). The correlation between PM status and birthweight, placental weight, and birthweight-to-placental weight ratio was assessed using GraphPad prism to examine the impact of PM on fetal outcomes. $P < 0.05$ indicates statistically significant differences.

3. Results

3.1 Main characteristics of the placenta donors and donated placentas

All placenta donors were ≥18-years-old and had received intermittent presumptive treatment with sulfadoxine pyrimethamine. The mean age, gravidity, birthweight (BW), placental weight (PW), and BW:PW ratio of the cohort of placenta donors was 24.7 years, 2.69, 3077.64 g, 470.04 g, and 6.51, respectively (Table 1). Grouping the placenta donors into those with a known history of MiP and those without (NoMiP), revealed that in the MiP vs NoMiP groups, maternal age and gravidity were not significantly different (mean age: 24.4 [range: 18–30] vs 25 [range: 18–40] years, $P = 0.45$; mean gravidity: 2.5 [range: 1–7] vs 2.9 [range: 1–7), $P = 0.12$). However, in the MiP vs NoMiP groups, BW (mean: 2870.5 [range: 1600–5000] vs 3272.3 [range: 2000–4500) g), PW (mean: 464.3 [range: 280.4–675) vs 492.9 [range: 342.3–715] g, and BW:PW ratio (mean: 6.27 [range: 3.2–10.2] vs 6.73 [range: 4.18–10], were significantly lower in the MiP group ($P < 0.0001$, = 0.009, and = 0.03, respectively). H&E analysis revealed that 92 placentas (51.4%) were PM-positive (had infected erythrocytes), 58 (32.4%) were PM-negative (no infected erythrocytes observed), 29 (16.2%) had past malaria infection (hemozoin present in the absence of infected erythrocytes [12]), 92 (51.4%) belonged to male fetuses, and

eight (4.5%) were preterm (Table 2). All downstream analyses were done on placenta samples that were confirmed to be PM-positive or PM-negative using H&E staining.

3.2 PM correlates negatively with birthweight and birthweight-to-placenta ratio

Representative images of PM-negative and PM-positive samples are shown on Figure 1A–B, and the presence of *P*. *falciparum* in PM-positive tissues was confirmed using PCR (Figure 1C). Analysis of the data underlying the placental biobank revealed that when compared with the PM-negative group, BW was significantly lower in the PM-positive group, which had more low BW cases (Figure 1A, $P = 0.03$, low birthweight: <2500 g), but PW did not differ between the two groups (Figure 2B, $P = 0.8$). However, the BW:PW ratio was lower in the PM-positive group, although the difference did not reach statistical significance (Figure 1F, $P = 0.08$). Next, we used the H&E images to determine the proportion of infected erythrocytes, IEs (%), in each placenta sample, and then used the obtained values to assess the correlation between the PM burden and BW, PW, and the BW:PW ratio, i.e., the fetal weight obtained per gram of the placenta, which is an indicator of placental efficiency, with higher BW:PW ratios indicating greater placental efficiency [22]. This analysis revealed negative correlation between IEs (%) (the proportion of infected erythrocytes), and BW (correlation coefficient [rs]: -0.22, $P < 0.005$, 95% confidence interval [CI]: -0.359 – -0.071), and IEs (%) and BW:PW ratio (rs: -0.20, $P = 0.007$, 95% CI: -0.338 – -0.048). Expectedly, PW had a positive correlation with birthweight (rs: 0.29, $P < 0.001$, 95% CI: 0.141 – 0.419) and a negative correlation with BW:PW ratio (rs: -0.42, $P < 0.001$, 95% CI: -0.539 – -0.290). However, the PM burden did not exhibit correlation with placental weight (rs: 0.01, $P = 0.94$, 95% CI: -0.156 – 0.146). Taken together, these findings indicate that PM impairs placenta function, leading to low birthweight via reduced placenta efficiency as indicated by the negative correlation between PM burden and the BW:PW ratios of PM-exposed neonates.

3.3 PM markedly alters placental histological features

Next, we assessed the impact of PM on syncytial knotting and fibrin deposition in our placenta samples. This analysis revealed that when compared with PM-negative samples (A), PM-positive samples had more syncytial knots (B, yellow arrowhead) and greater fibrin-occupied placental area (C, FD in the broken line-demarcated area). Quantification analyses revealed that when compared with PM-negative samples, the levels of these histological features were significantly higher in the PM-positive samples (D, SK: syncytial knots, $P = 0.047$ and E, fibrin area, $P < 0.0005$). These observations indicate that in our study cohort, PM may have adversely affected fetal outcomes at least in part, by altering normal placental histological features.

3.4 PM is associated with an upregulation of TLR4, TLR7, and Endothelin 3

We then sought to determine if PM altered the expression of TLRs. To this end, we focused on TLR4, TLR7, and TLR9, which have been associated with response to malaria infection in mice [23,24], and with mouse PM in the case of TLR4 [25], although this has not been reported in human PM. To evaluate the effect of PM on these innate immune system receptors, we assessed their expression levels using RT-qPCR. The analysis revealed that when compared with PM-negative controls, PM-positive samples expressed significantly higher levels of TLR4 and TLR7, but not TLR9 (Figure 3A–C, $P = 0.002$, 0.03, and 0.59, respectively). This is consistent with mouse data showing that PM upregulates TLR4-mediated expression of endothelin-1 [15]. We therefore wondered if human PM alters the expression of Endothelin genes. RT-qPCR analysis of Endothelin-1 and -3 gene expression revealed that only Endothelin-3 was detectable in our placenta samples and that when compared with PM-negative placentas, PM-positive samples had significantly higher levels of Endothelin-3 (Figure 3D, $P = 0.004$), indicating the presence of a TLR–Endothelin signaling axis in response to human PM.

3.5 PM is associated with high oxidative DNA damage

Since TLR4 was upregulated in PM-positive placenta samples, we wondered whether PM-driven activation of TLR4 is associated with a dysregulation of other signaling processes that may underlie or contribute to PM-mediated placental pathobiology. Because malaria is known to be strongly inflammatory and oxidative, which may drive host tissue damage [16], and because oxidative DNA damage is associated with TLR4 upregulation [17] and that TLR signaling is thought to promote DNA repair [18], we wondered if the TLR4 upregulation in the PM-positive samples might be associated with placental oxidative DNA damage. To assess this possibility, we used immunohistochemistry to assess the levels of 8-hydroxy-2'-deoxyguanosine, a marker of oxidative DNA stress [26]. This analysis revealed that when compared with PM-negative samples, PM-positive samples express markedly higher levels of 8-hydroxy-2'-deoxyguanosine (Figure 4A). Staining the same samples with the secondary antibody only (without the primary antibody) confirmed signal specificity (Figure 4B). To further assess the effect of PM on oxidative stress, we used RT-qPCR to examine the level of p21, a mediator of cell cycle arrest and indicator of cellular response to DNA damage [27]. This revealed that when compared with PM-negative samples, PM-positive samples had significantly higher levels of p21 (Figure 4C, $P = 0.02$). Taken together, these data indicate that PM triggers markedly high levels of placental oxidative DNA stress, placenta tissue damage, and cellular response to DNA stress, which may contribute to the pathobiology of PM, and that in response, at least in part, TLR signaling may be upregulated to counter these adverse effects through promotion of DNA repair.

4. Discussion

Malaria in pregnancy (MiP) often results in placental malaria (PM), where erythrocytes that are infected with *P. falciparum*, the parasite that most frequently causes PM, sequestrate in placental intervillous spaces [7]. PM may cause various adverse fetal outcomes, stillbirth, preterm birth, and fetal growth restriction [3–5] and because *P. falciparum* rarely undergoes vertical transmission [9], these effects are likely caused by PM-driven pathobiological effects in

the placenta, which may impair placental function. However, although studies have implicated effects like inflammation and histological changes in PM pathogenesis, the mechanisms underlying the adverse effects of human PM on the placenta are unclear. Moreover, because many MiP cases in malaria-endemic regions are asymptomatic [28,29] and the placenta is inaccessible during pregnancy, there are no ways of detecting and intervening against PM during pregnancy. Thus, there is an urgent need to better understand the placental pathobiology of PM to guide the development of effective diagnostic and therapeutic tools.

Mouse models indicate that PM triggers innate immune responses (mainly via TLR4) that are associated with poor fetal outcomes and that TLR4-mediated fetal responses to PM lead to improved outcomes [14]. However, the effect of human PM on TLR-mediated immunity in the placenta has not been examined. In this study, we leveraged our well-characterized biobank of placenta samples from a malaria endemic region of Kenya (Table 1) and found that in our study cohort, PM burden had a significant negative correlation with birthweight and BW:PW ratio, that it was associated with significantly higher placental histological lesions, higher levels of TLR4 and Endothelin-3 expression, and enhanced oxidative DNA damage when compared with samples without PM.

Consistent with previous findings implicating PM in fetal growth restriction [30], we observed that in our study cohort, relative to the PM-negative cases, PM was associated with low birthweight. Moreover, we observed that PM was associated with lower BW:PW ratios, an indicator of placental efficiency in which higher ratios indicate higher nutrient transfer for every gram of placenta and vice versa [22], an observation that to our knowledge, has not been previously reported in human PM, but not with lower placental weight (Figure 1D–F). Interestingly, our analyses also indicate that the PM burden (percentage of infected erythrocytes in a sample's intervillous spaces) correlates negatively with birthweight but not with placental weight. Taken together, these observations indicate that PM contributes to fetal growth

restriction primarily by impairing placental function and not via placental growth inhibition, although the precise mechanisms remain unclear. This possibility is crucial considering that women in malaria-endemic regions may experience multiple malaria reinfections throughout pregnancy, but further studies, such as using *in vitro* and organoid systems, are needed to comprehensively investigate this possibility.

Our analyses revealed that, PM-positive samples had markedly higher levels of fibrin deposition and syncytial knotting than PM-negative samples, which is in line with earlier findings [31]. These changes, which indicate placental injury and have been associated with placental malperfusion and poor fetal outcomes, including fetal growth restriction [32,33], may contribute to the low birthweight observed in our PM cohort. However, studies are needed to establish the mechanisms by which PM alters placental histological features, how these changes correlate with fetal outcomes and postnatal wellbeing, and whether they can predict fetal wellbeing in postnatal life.

TLRs are key innate immunity factors that sense host invasion by pathogens and activate host immune defenses [34]. Mouse models of malaria indicate that TLR4, TLR7, and TLR9 are involved in detecting and responding to malaria infection [23,24]. Moreover, mouse models indicate that at the fetal–maternal interface, PM activates TLR4-mediated immune responses that drive poor fetal outcomes, and that fetal TLR4-mediated counterresponses improve pregnancy outcomes [14,25,35]. However, this observation has not been previously made in human PM. Here, we observed that the expression levels of TLR4 and TLR7, but not TLR9, were significantly upregulated in PM-positive samples, indicating that placental infection triggers an innate immune reaction and that it is mainly driven by TLR4 and TLR7, although the status of other TLRs during PM warrants investigation. Considering that TLRs are important drivers of inflammation [36], which is implicated in PM pathogenesis [37], taken together with the observed changes in placental histological features, our findings indicate for the first time, that

TLR-mediated responses to PM may contribute to local placental inflammation, which may underlie the observed PM-associated low birth and placental weights, although the precise mechanisms remain unclear. Mouse data show that PM-driven TLR4 expression drives placental endothelin-1 expression [15], and for the first time, our findings show that PM is also associated with the upregulation of Endothelin-3. The Endothelin ligands 1, 2, and 3 are a family of vasoactive factors that influence a range of cellular processes, such as vascular remodeling and angiogenesis [38]. Moreover, Endothelin-3 has been reported to have anti-inflammatory effects [39,40], suggesting that its upregulation in the context of PM-mediated TLR4 upregulation is a mechanism of countering TLR4-dependent placenta inflammation. Collectively, these observations indicate that human placenta malaria may activate a TLR4–Endothelin-3 signaling axis, but further studies are needed to test this hypothesis and to determine its implications in PM pathobiology and fetal outcomes.

Based on reports that malaria is strongly oxidative [16], oxidative stress causes tissue damage [41], oxidative DNA damage upregulates TLR4 [17], and that the TLR pathway might promote DNA repair [18], we reasoned that our observation of TLR4 and TLR7 upregulation in PM-positive samples might be accompanied by placental oxidative DNA damage. This hypothesis was confirmed by our immunohistochemistry data, which showed that 8-hydroxy-2'-deoxyguanosine, a marker of oxidative DNA stress (Valavanidis et al., 2009), was markedly upregulated in PM samples. Moreover, gene expression analysis revealed that these events were accompanied by a significant upregulation of p21, a cell cycle inhibitor and marker of cellular response to DNA damage [27]. These observations align with previous findings that in a mouse model, PM is associated with placental oxidative damage [42]. Furthermore, p21 upregulation in the placenta may arrest the cell cycle to allow for oxidative damage resolution, which may contribute to the low placental weight observed in our cohort, but this possibility

requires further investigation. Together, our data suggest the presence of a previously unknown TLR–Endothelin–oxidative damage axis in human PM.

5. Conclusion

Despite its heavy burden and adverse effects on maternal and fetal outcomes, the mechanisms underlying the placental pathobiology of PM are unclear. Considering that malaria is rarely transmitted to the fetus [9], the adverse fetal outcomes of MiP are mainly driven by events that disrupt placenta physiology and function. Importantly, because of the placenta's inaccessibility, PM can only be confirmed via postnatal placental histopathology. These challenges highlight the urgent need to better understand the mechanisms underlying placental pathobiology of PM, which may inform the development of sensitive tools for diagnosing PM during pregnancy as well as effective therapeutic interventions. Our findings that PM may drive TLR-mediated responses in the placenta, raise the possibility that modulating innate responses to PM may improve fetal outcomes, as we previously discussed [13]. Moreover, our identification of an axis involving TLRs, Endothelins, and oxidative DNA damage during PM (Figure 5), highlights processes with the potential for intervention against human PM. However, further studies, such as using primary human trophoblasts, human placental organoids, or human placental *ex vivo* systems are needed to validate our observations. Such approaches can investigate the mechanisms of PM pathobiology more rigorously than can be done using term placentas.

Funding statement

F.M.K. is supported by the EDCTP2 programme supported by the European Union and Novartis Global Health, Basel – Switzerland, Grant Number TMA2019CDF-2736.

Acknowledgments

We thank our placenta donors and the staff at Webuye County and Mary Help of The Sick (Thika) Hospitals for their generous support. We thank the staff of the histopathology and

anatomy departments at the University of Nairobi and Mount Kenya University for their help with histopathology. We are grateful to Prof. Walter Jaoko, Prof. Omu Anzala, and Dr. Daniel Muema of KAVI–ICR for kindly sharing laboratory space and resources. We are thankful to Prof. Roger Smith and Dr. Kaushik Maiti, Mothers and Babies Research Centre, Hunter Medical Research Institute, Newcastle, NSW – Australia, for sharing antibodies and other resources.

Conflict of interest

The authors declare no conflicts of interest.

Ethics statement

This study was approved by Mount Kenya University's ethics review committee (approval number 1314).

Figures

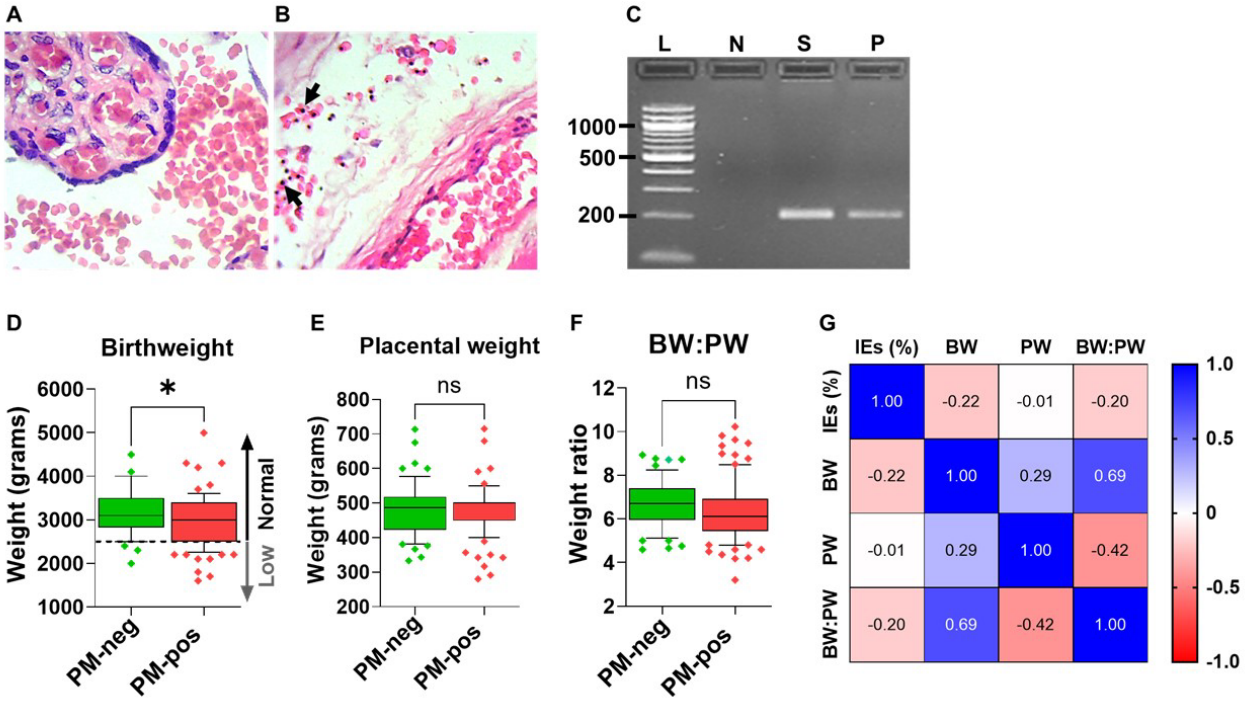

Figure 1. (A–B) Representative hematoxylin and eosin images of placental malaria (PM)-negative (A) and PM-positive samples (B). When compared with a PM-negative sample, the positive sample has malaria-infected erythrocytes (black arrowheads) in the placental intervillous space. (C) PCR confirmed the presence *of P. falciparum* in the PM-positive sample

in B. L: 100 base pair ladder, N: PM-negative sample, S: PM-positive sample in B (histology), P: positive control (*P. falciparum* strain 3D7 genomic DNA). Expected PCR band size: 205 base pairs. (D–F) PM was associated with lower birthweight (BW) (D, P = 0.03) and lower birthweight-to-placental weight (BW:PW) ratio, although the difference did not reach statistical significance (F, P = 0.08), but not with lower placental weight (PW) (E, P = 0.8). In D–F, whiskers are drawn from the 10th to 90th percentile. (G) A correlation matrix shows that the proportion of infected erythrocytes, IEs (%), in the placenta correlated negatively with BW (P < 0.005) and the BW:PW ratio (P = 0.007), but it did not correlate with PW (P = 0.94). PW correlated positively with BW and negatively with the BW:PW ratio (both P < 0.001).

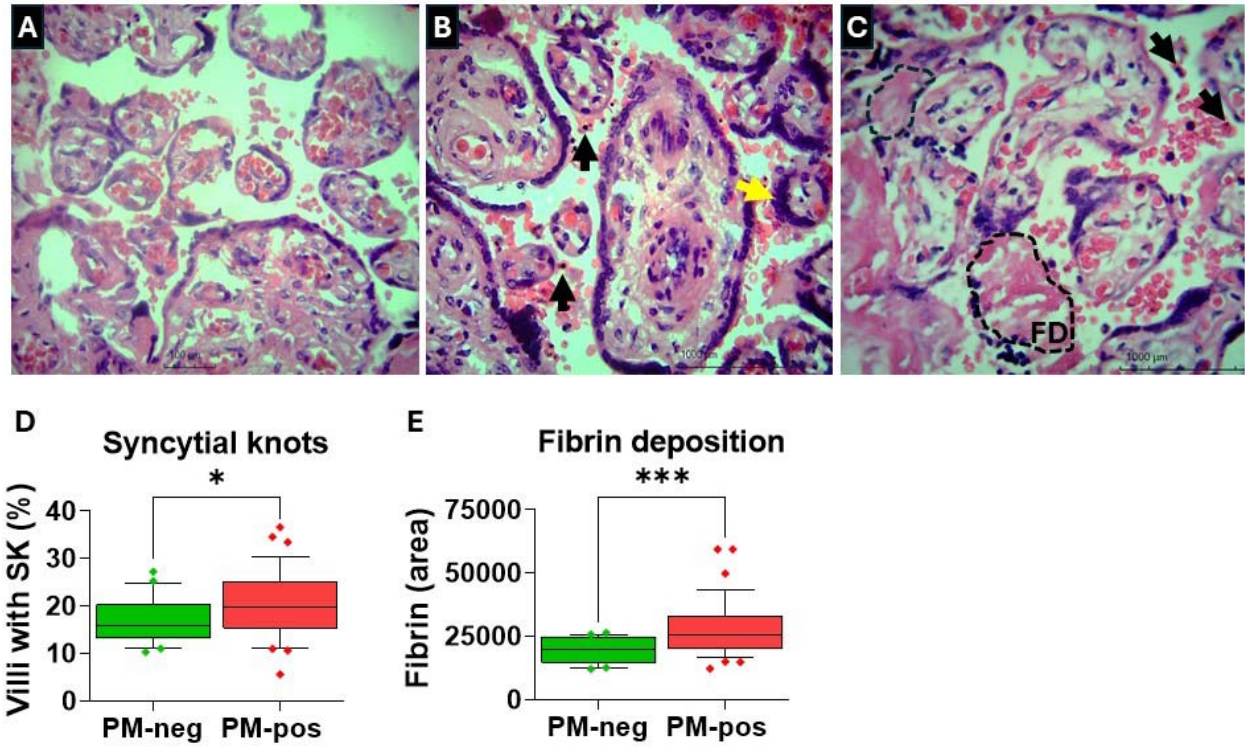

Figure 2. (A–C) In the samples from the biobank underlying our study, when compared with placental malaria (PM)-negative samples (A), PM was associated with significantly higher rates of syncytial knots (B, yellow arrowhead) and placental fibrin deposits (C; FD, marked with broken line). Black arrowheads indicate infected erythrocytes. (D–E) Quantification revealed that the levels of syncytial knots (SK [D], n = 21 and 38 for PM-neg and PM-pos, respectively; P

= 0.047) and the area of placenta intervillous space containing fibrin (E, n = 26 and 38 for PM-neg and PM-pos, respectively, $P < 0.0005$) were significantly higher in the PM-positive (PM-pos) samples than in the PM-negative (PM-neg) samples. Whiskers are drawn from the 10th to 90th percentile.

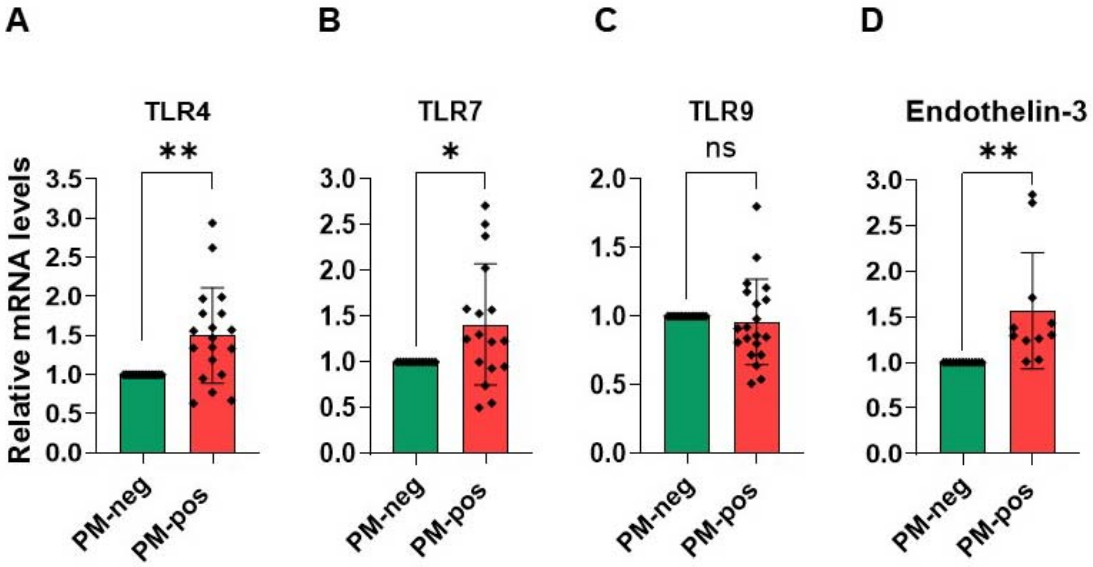

Figure 3. Placental malaria (PM) is associated with the upregulation of TLR4, TLR7, and Endothelin-3. (A–C) When compared with PM-negative (PM-neg) samples, PM-positive (PM-pos) samples expressed significantly higher levels of TLR4 and TLR7, but not TLR9 ($P = 0.002$, 0.03, and 0.59, respectively). (D) PM-positive samples also expressed higher levels of Endothelin-3 ($P = 0.004$).

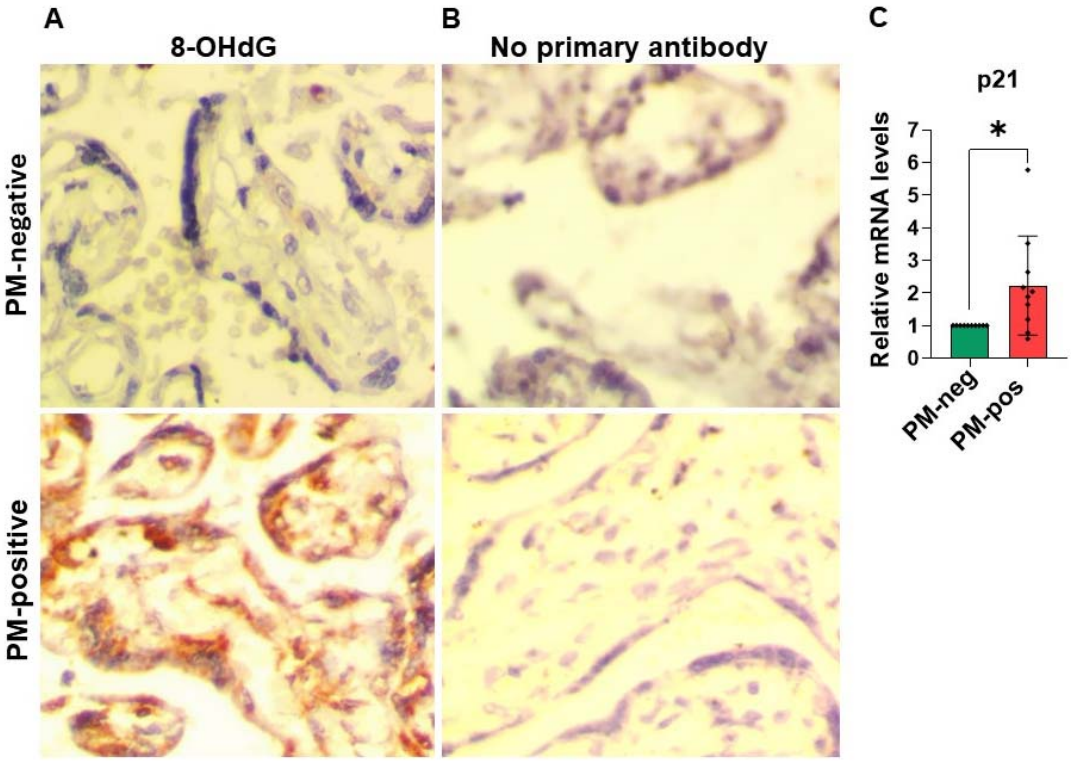

Figure 4. Analysis of oxidative DNA damage in placental malaria (PM)-negative vs PM-positive samples. (A–B) Immunohistochemistry revealed that when compared with PM-negative samples, PM-positive tissues had markedly higher levels of 8-hydroxy-2'-deoxyguanosine (8-OHdG), an indicator of oxidative damage. Staining the same samples with the secondary antibody only (B) confirmed signal specificity for this marker. (C) RT-qPCR showed that PM-positive samples express significantly higher levels of p21 (P = 0.02).

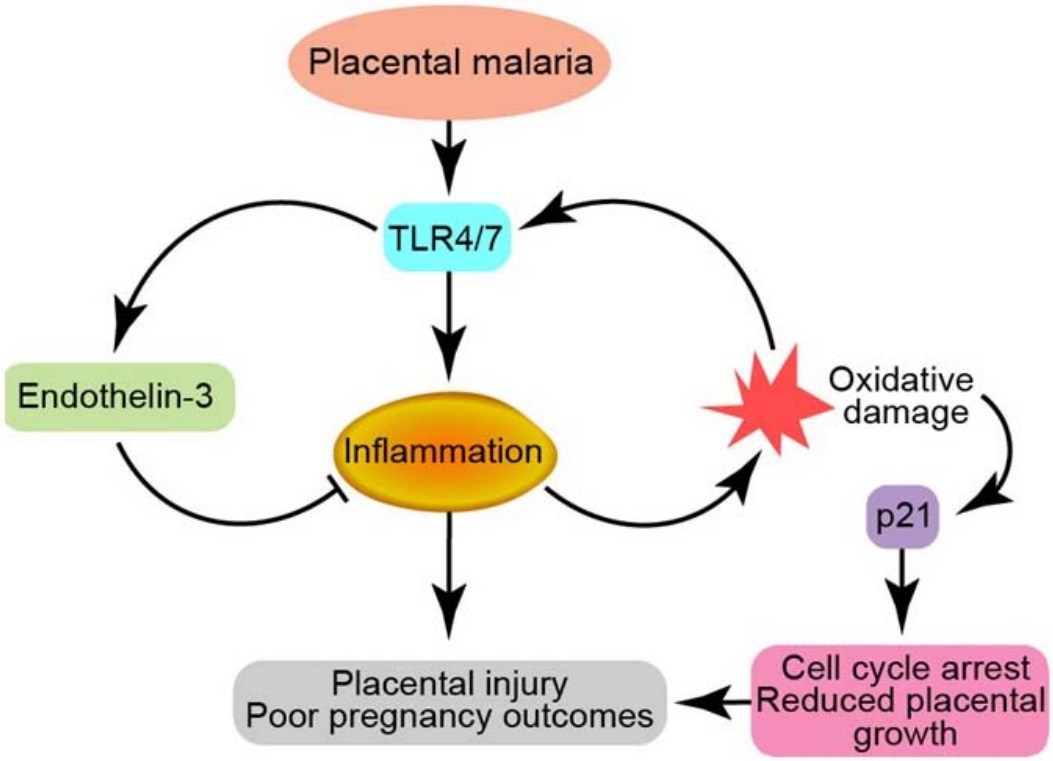

Figure 5. Schematic summary of the hypothesized TLR–Endothelin-3–oxidative stress axis in human placental malaria. Further investigation is needed to validate this axis and determine its potential for intervention against placental malaria.

Tables

Table 1. Summary of placenta donors' demographics

Group	Age (range)	Gravidity (range)	BW (g) (range)	PW (g) (range)	BW:PW (range)
All donors	24.7 years (18–40)	2.69 (1–7)	3077.64 (1600–5000)	479.04 (280.37–715)	6.51 (3.2–10.2)
MiP	24.4 years (18–30)	2.5 (1–7)	2870.5 (1600–5000) ****	464.3 (280.4–675) **	6.27 (3.2–10.2) *
NoMiP	25 years (18–40)	2.9 (1–7)	3272.3 (2000–4500)	492.9 (342.3–715)	6.73 (4.18–10)

Analysis of the placenta donors' data revealed that maternal age and gravidity were not significantly different in the MiP (group with known history of malaria in pregnancy) vs the NoMiP (group without known MiP history) groups (P = 0.45 and 0.12, respectively), whereas birthweight (BW), placental weight (PW), and BW:PW ratios were significantly lower in the MiP group when compared with the No MiP group (P = < 0.0001, 0.009, and 0.03, respectively). *, **, and **** indicate $P < 0.05$, 0.005, and 0.0005, respectively.

Table 2. Main characteristics of the donated placentas

No. of placenta samples	179
Placental malaria-positive placenta samples (infected erythrocytes present)	92 (51.4%)
Placental malaria-negative placenta samples	58 (32.4%)
Placentas with past placental malaria infection (hemozoin present)	29 (16.2%)
Placenta samples from male fetuses	92 (51.4%)
Placenta samples from female fetuses	87 (48.6 %)
Placenta samples from pre-term deliveries	8 (4.5%)

The general characteristics of the placentas used in this study are summarized. Placental malaria status was determined using hematoxylin and eosin (H&E) analysis.

Table 3. List of primers used in the study

Target	Forward primer	Reverse primer
TLR4	5’-AGACCTGTCCCTGAACCCTAT-3’	5’-CGATGGACTTCTAAACCAGCCA-3’
TLR9	5’-CTGCCTTCCTACCCTGTGAG-3’	5’-GGATGCGGTTGGAGGACAA-3’
TLR7	5’-TCCTTGGGGCTAGATGGTTTC-3’	5’-TCCACGATCACATGGTTCTTTG-3’
β-actin	5’-CATGTACGTTGCTATCCAGGC-3’	5’-CTCCTTAATGTCACGCACGAT-3’
p21	5’-TGTCCGTCAGAACCCATGC-3’	5’-AAAGTCGAAGTTCCATCGCTC-3’
Endothelin-3	5’-GGGACTGTGAAGAGACTGTGG-3’	5’-AGACACACTCCTTGTCCTTGTA-3‘
P. falciparum	5′-TTAAACTGGTTTGGGAAACCAAATATATT-3′	5′-ACACAATGAACTCAATCATGACTACCCGTC-3′

References

[1] World Health Organization. World malaria report 2023. 2023.

[2] Rogerson SJ, Mwapasa V, Meshnick SR. Malaria in pregnancy: Linking immunity and pathogenesis to prevention. American Journal of Tropical Medicine and Hygiene 2007;77:14–22.

[3] Bauserman M, Conroy AL, North K, Patterson J, Bose C, Meshnick S. An Overview of Malaria in Pregnancy. Semin Perinatol 2019;43:282. https://doi.org/10.1053/J.SEMPERI.2019.03.018.

[4] Fried M, Kurtis JD, Swihart B, Pond-Tor S, Barry A, Sidibe Y, et al. Systemic Inflammatory Response to Malaria During Pregnancy Is Associated With Pregnancy Loss and Preterm Delivery. Clin Infect Dis 2017;65:1729. https://doi.org/10.1093/CID/CIX623.

[5] Schmiegelow C, Matondo S, Minja DTR, Resende M, Pehrson C, Nielsen BB, et al. Plasmodium falciparum Infection Early in Pregnancy has Profound Consequences for Fetal Growth. J Infect Dis 2017;216:1601–10. https://doi.org/10.1093/infdis/jix530.

[6] Trampuz A, Jereb M, Muzlovic I, Prabhu RM. Clinical review: Severe malaria. Crit Care 2003;7:315. https://doi.org/10.1186/CC2183.

[7] Ayres Pereira M, Mandel Clausen T, Pehrson C, Mao Y, Resende M, Daugaard M, et al. Placental Sequestration of Plasmodium falciparum Malaria Parasites Is Mediated by the Interaction Between VAR2CSA and Chondroitin Sulfate A on Syndecan-1. PLoS Pathog 2016;12:e1005831. https://doi.org/10.1371/journal.ppat.1005831.

[8] Frank HG. Placental Development. Fetal and Neonatal Physiology, 2-Volume Set 2017:101–13. https://doi.org/10.1016/B978-0-323-35214-7.00010-X.

[9] Harrington WE, Duffy PE. Congenital malaria: Rare but potentially fatal. Ped Health 2008;2:235–48. https://doi.org/10.2217/17455111.2.2.235/ASSET/IMAGES/LARGE/GRAPHIC22.JPEG.

[10] Fried M, Duffy PE. Malaria during Pregnancy. Cold Spring Harb Perspect Med 2017;7:a025551. https://doi.org/10.1101/cshperspect.a025551.

[11] Rogerson SJ, Brown HC, Pollina E, Abrams ET, Tadesse E, Lema VM, et al. Placental Tumor Necrosis Factor Alpha but Not Gamma Interferon Is Associated with Placental Malaria and Low Birth Weight in Malawian Women. Infect Immun 2003;71:267. https://doi.org/10.1128/IAI.71.1.267-270.2003.

[12] Zakama AK, Ozarslan N, Gaw SL. Placental Malaria. Curr Trop Med Rep 2020;7:162–71. https://doi.org/10.1007/S40475-020-00213-2.

[13] Kobia FM, Maiti K, Obimbo MM, Smith R, Gitaka J. Potential pharmacologic interventions targeting TLR signaling in placental malaria. Trends Parasitol 2022;38:513–24. https://doi.org/10.1016/J.PT.2022.04.002.

[14] Rodrigues-Duarte L, Pandya Y, Neres R, Penha-Gonçalves C. Fetal and maternal innate immunity receptors have opposing effects on the severity of experimental malaria in pregnancy: Beneficial roles for fetus-derived Toll-like receptor 4 and type I interferon

receptor 1. Infect Immun 2018;86. https://doi.org/10.1128/IAI.00708-17/SUPPL_FILE/ZII999092383S1.PDF.

[15] Pandya Y, Marta A, Barateiro A, Bandeira CL, Dombrowski JG, Costa J, et al. TLR4-Endothelin Axis Controls Syncytiotrophoblast Motility and Confers Fetal Protection in Placental Malaria. Infect Immun 2021;89. https://doi.org/10.1128/IAI.00809-20/ASSET/283CE60E-5A6D-46F3-9439-7A889F86217A/ASSETS/IMAGES/LARGE/IAI.00809-20-F001.JPG.

[16] Vasquez M, Zuniga M, Rodriguez A. Oxidative Stress and Pathogenesis in Malaria. Front Cell Infect Microbiol 2021;11. https://doi.org/10.3389/FCIMB.2021.768182.

[17] Tawadros PS, Powers KA, Ailenberg M, Birch SE, Marshall JC, Szaszi K, et al. Oxidative Stress Increases Surface Toll-Like Receptor 4 Expression in Murine Macrophages Via Ceramide Generation. Shock 2015;44:157–65. https://doi.org/10.1097/SHK.0000000000000392.

[18] Harberts E, Gaspari AA. TLR Signaling and DNA Repair: Are They Associated? J Invest Dermatol 2013;133:296. https://doi.org/10.1038/JID.2012.288.

[19] Canene-Adams K. Preparation of Formalin-fixed Paraffin-embedded Tissue for Immunohistochemistry. Methods Enzymol 2013;533:225–33. https://doi.org/10.1016/B978-0-12-420067-8.00015-5.

[20] Senagore PK, Holzman CB, Parks WT, Catov JM. Working towards a Reproducible Method for Quantifying Placental Syncytial Knots. Http://DxDoiOrg/102350/15-08-1701-OA1 2016;19:389–400. https://doi.org/10.2350/15-08-1701-OA.1.

[21] Livak KJ, Schmittgen TD. Analysis of Relative Gene Expression Data Using Real-Time Quantitative PCR and the 2−ΔΔCT Method. Methods 2001;25:402–8. https://doi.org/10.1006/METH.2001.1262.

[22] Hayward CE, Lean S, Sibley CP, Jones RL, Wareing M, Greenwood SL, et al. Placental adaptation: What can we learn from Birthweight:placental weight ratio? Front Physiol 2016;7:177721. https://doi.org/10.3389/FPHYS.2016.00028/BIBTEX.

[23] Zhang Y, Zhu X, Feng Y, Pang W, Qi Z, Cui L, et al. TLR4 and TLR9 signals stimulate protective immunity against blood-stage Plasmodium yoelii infection in mice. Exp Parasitol 2016;170:73–81. https://doi.org/10.1016/J.EXPPARA.2016.09.003.

[24] Baccarella A, Fontana MF, Chen EC, Kim CC. Toll-Like Receptor 7 Mediates Early Innate Immune Responses to Malaria. Infect Immun 2013;81:4431. https://doi.org/10.1128/IAI.00923-13.

[25] Barboza R, Lima FA, Reis AS, Murillo OJ, Peixoto EPM, Bandeira CL, et al. TLR4-Mediated Placental Pathology and Pregnancy Outcome in Experimental Malaria. Sci Rep 2017;7. https://doi.org/10.1038/S41598-017-08299-X.

[26] Valavanidis A, Vlachogianni T, Fiotakis C. 8-hydroxy-2' -deoxyguanosine (8-OHdG): A critical biomarker of oxidative stress and carcinogenesis. J Environ Sci Health C Environ Carcinog Ecotoxicol Rev 2009;27:120–39. https://doi.org/10.1080/10590500902885684.

[27] Villeneuve NF, Sun Z, Chen W, Zhang DD. Nrf2 and p21 regulate the fine balance between life and death by controlling ROS levels. Cell Cycle 2009;8:3255. https://doi.org/10.4161/CC.8.20.9565.

[28] Salgado C, Ayodo G, Macklin MD, Gould MP, Nallandhighal S, Odhiambo EO, et al. The prevalence and density of asymptomatic Plasmodium falciparum infections among children and adults in three communities of western Kenya. Malar J 2021;20. https://doi.org/10.1186/S12936-021-03905-W.

[29] Idris ZM, Chan CW, Kongere J, Gitaka J, Logedi J, Omar A, et al. High and Heterogeneous Prevalence of Asymptomatic and Sub-microscopic Malaria Infections on Islands in Lake Victoria, Kenya. Scientific Reports 2016 6:1 2016;6:1–13. https://doi.org/10.1038/srep36958.

[30] Menendez C, Ordi J, Ismail MR, Ventura PJ, Aponte JJ, Kahigwa E, et al. The Impact of Placental Malaria on Gestational Age and Birth Weight. J Infect Dis 2000;181:1740–5. https://doi.org/10.1086/315449.

[31] Crocker IP, Tanner OM, Myers JE, Bulmer JN, Walraven G, Baker PN. Syncytiotrophoblast degradation and the pathophysiology of the malaria-infected placenta. Placenta 2004;25:273–82. https://doi.org/10.1016/j.placenta.2003.09.010.

[32] Lampi K, Papadogiannakis N, Sirotkina M, Pettersson K, Ajne G. Massive perivillous fibrin deposition of the placenta and pregnancy outcome: A retrospective observational study. Placenta 2022;117:213–8. https://doi.org/10.1016/J.PLACENTA.2021.12.013.

[33] Brink LT, Roberts DJ, Wright CA, Nel DG, Schubert PT, Boyd TK, et al. Placental pathology in spontaneous and iatrogenic preterm birth: Different entities with unique pathologic features. Placenta 2022;126:54. https://doi.org/10.1016/J.PLACENTA.2022.06.004.

[34] Takeda K, Kaisho T, Akira S. Toll-like receptors. Annu Rev Immunol 2003;21:335–76. https://doi.org/10.1146/annurev.immunol.21.120601.141126.

[35] Pandya Y, Penha-Gonçalves C. Maternal-fetal conflict during infection: Lessons from a mouse model of placental malaria. Front Microbiol 2019;10:1126. https://doi.org/10.3389/FMICB.2019.01126/BIBTEX.

[36] Fukata M, Vamadevan AS, Abreu MT. Toll-like receptors (TLRs) and Nod-like receptors (NLRs) in inflammatory disorders. Semin Immunol 2009;21:242–53. https://doi.org/10.1016/J.SMIM.2009.06.005.

[37] Chua CLL, Khoo SKM, Ong JLE, Ramireddi GK, Yeo TW, Teo A. Malaria in Pregnancy: From Placental Infection to Its Abnormal Development and Damage. Front Microbiol 2021;12:3452. https://doi.org/10.3389/FMICB.2021.777343/BIBTEX.

[38] Rodríguez-Pascual F, Busnadiego O, Lagares D, Lamas S. Role of endothelin in the cardiovascular system. Pharmacol Res 2011;63:463–72. https://doi.org/10.1016/J.PHRS.2011.01.014.

[39] Sato A, Ebina K. Common mechanism in endothelin-3 and PAF receptor function for anti-inflammatory responses. Eur J Pharmacol 2013;718:30–3. https://doi.org/10.1016/J.EJPHAR.2013.09.025.

[40] Sato A, Ebina K. Endothelin-3 at low concentrations attenuates inflammatory responses via the endothelin B2 receptor. Inflamm Res 2013;62:417–24. https://doi.org/10.1007/S00011-013-0594-3.

[41] Burton GJ, Jauniaux E. Oxidative stress. Best Pract Res Clin Obstet Gynaecol 2011;25:287. https://doi.org/10.1016/J.BPOBGYN.2010.10.016.

[42] Sarr D, Cooper CA, Bracken TC, Martinez-Uribe O, Nagy T, Moore JM. Oxidative Stress: A Potential Therapeutic Target in Placental Malaria. Immunohorizons 2017;1:29. https://doi.org/10.4049/IMMUNOHORIZONS.1700002.