Title

Early Braking of Abnormal Tibial Translation Determines Spontaneous Healing Success of the Anterior Cruciate Ligament in a Murine Model.

Author

Riku Saito[1], M.Sc., Kazuki Nakayama1, B.Sc., Yuna Usami[1], M.Sc., Saaya Enomoto[2], M.Sc., Koyo Nogi[1], M.Sc., Takanori Kokubun[1, 3], Ph.D.

1. Graduate School of Health, Medicine, and Welfare, Saitama Prefectural University, Saitama, Japan
2. Saitama Rehabilitation Center
3. Department of Physical Therapy, School of Health and Social Services, Saitama Prefectural University, Saitama, Japan

Name of institution

Graduate School of Saitama Prefectural University

Corresponding author & Author to whom requests for reprints

Takanori Kokubun, P.T., Ph.D.

Affiliation: Graduate School of Saitama Prefectural University

Postal address: 820 San-nomiya, Koshigaya-Shi, Saitama, 343-8540, Japan

Phone number: +81-48-973-4176

Fax number: +81-48-973-4176

Email address: kokubun-takanori@spu.ac.jp

Short running title

Braking force affects ACL healing.

Key terms:

Anterior cruciate ligament, Spontaneous healing, Braking, Mechanobiology, Wound Healing Response

Abstract

The anterior cruciate ligament (ACL) has been recognized to have no spontaneous healing capacity after complete rupture due to an intra-articular environment. Meanwhile, our group reported that a completely ruptured ACL could heal spontaneously by restabilizing the femur-tibia joint. The wound healing of connective tissue involves three phases: the inflammatory, proliferative, and remodeling phases, with the appropriate range of mechanical loading differing according to the healing stage. Understanding the mechanoresponsive feature of healing ACLs, which have difficulty regaining normal ligament function, is crucial for elucidating the mechanisms of ACL maturation and mechanical strengthening. Therefore, this study investigated the relationship between mechanical stress and the healing response during the early stages of ACL healing. Male and female C57BL/6 mice with ruptured ACLs were randomly assigned to the Tight-CATT, Loose-CATT, and ACL-Rupture groups. The Tight-CATT group showed a higher success rate of ACL healing than the Loose-CATT group at 4 and 8 weeks. However, collagen maturation and mechanical properties on the healed ACL did not differ between the Tight- and Loose-CATT groups. Our results suggested that loose ATT braking immediately after injury is a negative factor for the healing of the completely ruptured ACL. On the other hand,

tightly ATT in the early healing phase was insufficient to improve mechanical strength and collagen maturation. Therefore, our results suggest controlling mechanical stress tightly in the early phase leads to spontaneous healing of ACL, and it might be necessary to apply higher mechanical stress in the later stages to achieve greater healing.

Introduction

The anterior cruciate ligament (ACL) has been considered a non-typical connective tissue, unlike skin, because it never spontaneously recovers to a normal state once completely injured [1–4]. Nevertheless, we reported the possibility of spontaneous healing of a completely injured ACL using rodent models, controlling abnormal anterior tibial translation after ACL injury [5]. In addition, several clinical studies have shown that completely ruptured ACLs can heal spontaneously [6–9]. Thus, the ACL is now considered to be a ligament capable of spontaneous healing. However, the healed ACL remains mechanically fragile compared to normal ACLs, and the mechanism of mechanobiology that promotes ACL healing has not been elucidated.

In the wound healing of connective tissues such as skin and lung, ligament, tendon, etc., there are three phases: the inflammatory phase, in which inflammatory cells and macrophages are activated; the proliferative phase, in which fibroblasts are activated and extracellular matrix (ECM) synthesis progresses; and the remodeling phase, in which the initially deposited provisional ECM is modified over a long period, such as by replacing type III collagen with type I collagen [10]. But wound-repaired skins often exhibit fibrotic scar tissue with excessive deposition of extracellular matrix (ECM) such as collagen and fibronectin [11,12]. Additionally, since mechanical

stimulation can induce inflammation and fibrosis of the skin, the appropriate range of mechanical load likely varies depending on the healing phase [13,14].

Ligaments are also collagen-rich dense connective tissue and have the same three healing processes. However, in contrast to other connective tissues, collagen deposition remains low even several months to years after injury, resulting in the formation of mechanically fragile ligaments compared to intact ligaments [5,15]. Chamberlain et al. revealed that granulation tissue localized to the injured site in the very early stages of medial collateral ligament (MCL) wound healing spreads throughout the entire healing MCL, “creeping substitution” [16]. And the catabolism of normal tissue remaining in the injured ligament suggested that it causes a decrease in collagen deposition and mechanical weakness in the healed ligament [16]. However, another study has reported that mechanical load on the healing MCLs improves ECM deposition and mechanical strength [17]. In the healing process of tendons, which have a similar composition to ligaments, mechanical stress has also been reported to promote healing; thus, ligaments are likely to have the positive effects of mechanical.

In the ACL healing process, we have recently identified a key component of the ACL healing mechanisms. Braking abnormal movement of the tibia after ACL injury leads to spontaneous healing of the ACL, regardless of the injury site [18], and can

reduce MMPs that cause matrix degradation during the very early healing stage of the ACL [19]. Hence, we focused on the early stages of ligament healing, when the morphology of the healing tissue changes dynamically. It was reported that exercise after mouse Achilles tendon injury had a positive effect on the mechanical properties of the healed tendon even in the acute phase [20]. We hypothesized that during the early healing process, a mild increase in mechanical stress would promote collagen deposition and enhance mechanical strength in the healed ACLs. Because it is also known that excessive mechanical stress has the risk of inhibiting the healing response of tendons and ligaments [21–23], understanding the acceptable range of mechanical stress, during the early phase of the ACL healing, is essential for elucidating the mechanism of the improving the ACL healing.

Therefore, the purpose of this study was to elucidate the relationship between mechanical stress and wound repair response in the early phase of ACL spontaneous healing. To achieve this goal, we developed two types of controlled anterior tibial translation (CATT) models using nylon sutures of two different diameters. Suture differences provided different grades of anterior tibial translation stability to murine knees. We investigated the extent of controlling force of tibial translation on the ACL healing response and collagen maturation of the healed ACL.

Methods

Experimental Design

The University Animal Experiment Ethics Committee approved all experiments. We used male (n=66) and female (n=66) 8-9 weeks old C57BL/6 mice (n=132). A total of 132 mice were ruptured the left ACL and then were randomly classified into three groups: Tight-CATT group; controlled anterior tibial translation (ATT) with 3-0 nylon suture (n=57), Loose-CATT group; controlled ATT with 4-0 nylon suture (n=55), and ACL-R (ACL-Rupture) group; not controlled ATT (n=20). We used the right hindlimb as the intact group. All mice were housed in plastic cages under a 12-h light/dark cycle. The mice were allowed unrestricted movement within the cage and had free access to food and water. Three animals from both the Tight-CATT and Loose-CATT groups were excluded from the experiment due to tibial fractures when the ACL was ruptured and the abnormal findings during housing. Thus, a total of 126 mice were included in this study, and 20 mice were sacrificed immediately after injury for anterior drawer testing and histology, at 4 (n=52) and 8 weeks (n=54) for anterior drawer testing, histology, immunofluorescence, and mechanical testing (Figure 1A).

Nylon Suture Experiments

Before creating the CATT models, we measured the mechanical properties of each nylon suture using a mechanical testing machine (Univert. CellScale Biomaterial Testing, Canada). The purpose of this experiment was to investigate the differences in mechanical properties between 3-0 and 4-0 nylon sutures (Akiyama Medical MFG, Co., Ltd., Tokyo, Japan). Each nylon suture was measured in a double layer since a nylon suture was looped outside the joint to control ATT in the CATT model. In the failure testing, we stretched the nylon suture at a preload of 0.1 N and a rate of 20 mm/min until the sutures ruptured. During the test, the load (N) and displacement (mm) were recorded, and we measured the load to failure (N) and stiffness (N/mm). Then, we performed the cyclic test to evaluate viscoelasticity. Nylon sutures were repeated with 5 seconds of stretching up to 90%, 80%, 70%, and 60% of the failure load of each nylon suture, followed by 5 seconds of relaxation (1 cycle: 10 seconds). We recorded the number of cycles at the point of rupture.

Surgical Procedures for Creating the Model

All mice were anesthetized with a combination of anesthetics (medetomidine, 0.375 mg/kg; midazolam, 2.0 mg/kg; and butorphanol, 2.5 mg/kg) for sedation and pain control, and then we ruptured the ACL non-invasively according to a previous study[24].

We fixed the hindlimb with the knee joint at 90 degrees and ruptured the ACL by pushing the femur backward against the tibia (Figure 1B-C). Then, we created bone tunnels at the femoral condyle and proximal tibia using a 26G needle (Terumo Co., Ltd., Tokyo, Japan). In the Tight- and Loose-CATT groups, we tightly looped a single 3-0 or 4-0 nylon suture through the two tunnels to control the ATT (Figure 1D). In the ACL-R group, we loosely looped a 3-0 nylon suture through the two tunnels not to control the ATT.

Anterior Drawer Testing

We performed anterior drawer testing to evaluate the braking force to control the ATT of each knee, carefully removing the muscle from the knee while retaining the suture. Then, we fixed the knee joint at 90 degrees on the self-made anterior drawer testing device. The tibia was pulled forward with a 0.05 kgf constant force spring (Sanko Spring Co., Ltd., Fukuoka, Japan), and X-ray images of the sagittal plane of the knee joint were taken. We measured ATT from the X-ray images using Image J (Image J; National Institutes of Health, Bethesda, MD, USA) to evaluate the braking force by nylon sutures. The ATT was defined as the perpendicular line from the most prominent point of the femoral condyle to the long axis of the tibia. We then removed the nylon

suture and again measured the ATT to evaluate the potential characteristics of the knee stability with healed ACL. The knees in which ACL was not healed in histology were excluded from the latter analysis.

Histology

After anterior drawer testing, knee samples were immediately fixed (24-48h) in 4% paraformaldehyde and decalcified with 10% ethylenediaminetetraacetic acid (Sigma-Aldrich Japan, Tokyo, Japan) for 2 weeks. Finally, they were immersed in 5% and 30% sucrose for 4 and 12 hours, respectively, and then freeze-embedded using OCT compound (Sakura Finetek Japan Co., Ltd., Tokyo, Japan). Each sample was sectioned at 12μm using a Cryostar NX70 (Thermo Fisher Scientific, Kanagawa, Japan). We performed Hematoxylin & Eosin (HE) staining to observe ACL continuity and morphological features, and Picrosirius Red (PsR) staining to evaluate the collagen maturity of the healed ACL. We observed the stained sections with the BZ-X710 microscope (Keyence, Osaka, Japan). Whether the ACL was healed or not was defined based on HE images at 4 or 8 weeks after injury. We defined ACLs with observed continuity as “healed”, and those with lost continuity as “non-healed” (Figure 1E, F). The success rate of ACL healing in each group was calculated based on the HE images.

PsR images converted to grayscale images (256 degrees) showed collagenous tissue as 1-255 on the grayscale and non-collagenous tissue as 0 on the grayscale. A higher gray scale indicates higher ACL collagen maturation [25,26]. Using the BZ-X710 analysis software, the entire ACL areas of the PsR polarization images were specified as a Region of Interest (ROI) and then converted to grayscale images. We used the average grayscale value in the ROI as the representative value of the healed ACL.

Immunofluorescence

We performed immunofluorescence to evaluate the expression of type I collagen (COL1A1) in the healed ACL. ACL cryosections were blocked at room temperature for 1 hour using DAKO Antibody Diluent with Background Reducing Components (Agilent Technologies, Inc., CA, USA). The anti-COL1A1 primary antibody was incubated with Goat polyclonal antibody (1:200, AB758, Merck, Sigma Aldrich, Taufkirchen, Germany) at 4°C overnight. The secondary antibody was incubated with anti-Goat Rabbit antibody Alexa Fluor 488 (1:500, ab150141, Abcam, Cambridge, UK) for 4 hours at room temperature. All sections were observed macroscopically with a microscope BZ-X 710 under controlled imaging conditions.

Biomechanical Testing

The failure load testing was performed to evaluate the mechanical strength of the healed ACL. The harvested knee joints were dissected and frozen at -70°C. After thawing, all soft tissues were removed except the ACL, and the femur and tibia were fixed in 1.5-mm tubes. The tubes were then fixed to the mechanical testing machine Univert in the extended position. The ACL was stretched at a preload of 0.1 N and a rate of 10 mm/min until it was ruptured. We recorded the force of load to failure of the ACL.

Statistical Analysis

We performed statistical analysis on the results of nylon suture experiments, anterior drawer testing, grayscale, and mechanical testing using R. The Shapiro-Wilk test was used to verify the normality of all the analyzed data. Mann-Whitney U-tests were performed for the data from the nylon suture experiments. The two-way analysis of variance (ANOVA) was then performed to confirm significant differences among the groups and sex differences in the other results. Because all data were non-normally distributed, an Aligned Rank Transform (ART) [27,28] was performed before ANOVA. Based on the results of ANOVA, the Steel-Dwass test was performed as a multiple

comparison among all groups when the interaction was found. When no interaction was found, multiple comparisons were performed within factors for which a main effect was found. Statistical significance was set at $p < 0.05$.

Results

Mechanical Properties of Two Nylon Sutures

The results showed that the 3-0 nylon sutures had better mechanical properties. The load to failure and stiffness were significantly higher for 3-0 nylon sutures ($p < 0.05$) (Figure 2A, B). Also in cyclic testing, the 3-0 nylon sutures showed higher viscoelasticity and resistance to elongation. The 4-0 nylon sutures ruptured in 3 cycles at 90% of the failure load, 12 cycles at 80%, 107 cycles at 70%, and 791 cycles at 60%. The 3-0 nylon sutures ruptured in 6 cycles at 90% and in 197 cycles at 80%. 3-0 nylon sutures did not rupture even after 2,000 cycles at loads lower than 70% (Figure 2C).

Magnitude of Anterior Translation of Tibia

First, in the knee joints with nylon sutures for controlling ATT, interactions between groups and sex were observed at all timepoints ($p < 0.01$). Immediately after injury, the ATT was smallest in the intact and Tight-CATT groups. The Loose-CATT group showed a higher ATT than the Tight-CATT groups, and the ACL-R group

showed the highest ATT. However, there were no significant differences among all groups and sex (Figure 3C). In males at 4 and 8 weeks after injury, the ATT was smallest in the intact group, followed by the Tight-CATT and Loose-CATT groups, which showed similar ATT. The ACL-R group had the highest ATT. In contrast in females, the ATT of the Tight-CATT showed trend to smaller than Loose-CATT. However, there were no significant differences among all groups and sex (Figure 3D, E).

Secondly, for anterior tibial instability of the knees with healed ACL, fewer knees were included in the Loose-CATT group because we excluded knees with non-healed ACLs in the CATT group in this analysis. Interactions between groups and sex were observed at 4 weeks and 8 weeks ($p < 0.001$). In males at 4 and 8 weeks, intact had the smallest ATT, and the Tight-CATT and Loose-CATT groups had similar ATT but higher ATT than intact. ACL-R showed the highest ATT. In females, the ATT of the Tight-CATT showed a trend to be smaller than that of the Loose-CATT. However, there were no significant differences among all groups and sex (Figure 3F, G).

ACL Healing Success Rate and Collagen Maturation of the ACL

First, we showed the success rates of ACL healing with both Tight- and Loose-CATT groups at 4- and 8-week post-injury (Table 1). The Tight-CATT group

showed a higher healing rate for both males and females (42.9~100%), while the Loose-CATT group showed a lower healing rate (17~57.1%) and no healed ACL in the ACL-R group (0%). Next, we showed HE-stained images of the healed ACL. Compared to the intact ACL with parallel and regular nuclear arrangement, the healed ACL showed heterogeneous nuclear aggregation not only in the healed region but also in the ACL remnant region. It was also observed at 4- and 8-week post-injury (Figure 4A-H).

In collagen maturation of the healed ACL, there are no interactions observed at both 4- and 8-week post-injury. On the other hand, a significant main effect was observed in the group: the Tight-CATT group had a significantly lower grayscale than intact ($p < 0.001$) at 4 weeks, and the Tight- and Loose-CATT groups showed a significantly lower grayscale than intact ($p < 0.01$) at 8 weeks (Figure 5D, E).

Type I Collagen Content of Healing ACL

We performed immunofluorescence of COL1A1, the main component of the ECM, to evaluate the ECM maturity of the healed ACL. The green area indicates COL1A1, and the blue area indicates the nucleus. In the intact ACL, we observed COL1A1 expression at the entire ACL region and nuclei aligned longitudinally of the ACL (Figure 6A, B). On the other hand, the healed ACL of Tight- and Loose-CATT groups showed limited expression outside of the healed ACL and an irregular

orientation of COL1A1compared to the intact ACL. In addition, the Tight- and Loose-CATT groups showed higher and irregular nuclei aggregation throughout the ACL (Figure 6D-F). These collagen features of the ACL were commonly observed at 4- and 8-weeks post-injury (Shown in Figure 6 is at 8 weeks post-injury).

Mechanical Properties of Healed ACL

We fixed the femur and tibia in 1.5-mm tubes (Figure 7A) and performed mechanical testing to evaluate the mechanical strength of the healed ACL. The number of ACLs for testing in the Loose-CATT group was fewer because only the knees with confirmed ACL re-connections were included when the knees were dissected. No interaction was observed at both 4- and 8-week post-injury. On the other hand, a significant main effect was observed in the group: at 4 weeks, intact had a significantly higher mechanical strength than the Tight-CATT ($p < 0.01$) and Loose-CATT group ($p < 0.05$) (Figure 7B), and at 8 weeks, intact had a significantly higher mechanical strength than the Tight-CATT group ($p < 0.01$) (Figure 7C). However, the healed ACLs in the Tight- and Loose-CATT groups showed similar mechanical strength and were approximately 50% of the normal ACL.

Discussion

In this study, we indicate that loosening of the controlling ATT immediately after ACL injury is a negative factor for spontaneous healing of the ruptured ACL. The results of the Loose-CATT group showed that increased mechanical stress immediately after injury negatively affects ACL healing response. In contrast, the Tight-CATT group, which had a greater braking force of the ATT immediately after injury, showed a higher success rate of ACL healing. These findings suggest that controlling the tissue mechanical environment is a key factor for the success of the spontaneous healing of a completely injured ACL. Conversely, the healed ACL in both the CATT group showed fewer mechanical properties than the Intact group, and there were no significant differences in mechanical properties and histological features between tight- and loose-conditions. Overall, our results suggest that appropriate force control may raise the success rate of healing and the mechanical properties of healed ACL.

In this study, we created CATT models with different levels of ATT braking force using two types of nylon suture immediately after ACL injury. Results of the nylon suture experiment showed that the 4-0 nylon suture used in the Loose-CATT group had higher suture elasticity compared to the 3-0 nylon suture used in the Tight-CATT group. Subsequently, we confirmed in the anterior drawer test that the Loose-CATT group had a looser braking force compared to the Tight-CATT group

immediately after ACL injury. Therefore, the Loose-CATT group was defined as the group with early exposure to the higher mechanical stress immediately after ACL injury. Firstly, a physiological factor caused by mechanical stress is probably inhibiting ACL healing in the Loose-CATT group. Even if the ACL injury was untreated, the remnant tissue immediately after ACL injury showed high expression of genes related to ligament healing, such as Col1a1 and Tenascin C [29]. Furthermore, Scleraxis is highly expressed in acute remnant ACL tissue in rats [30]. Although ACLs' spontaneous healing capacity is lower than that of MCLs or other ligaments [2,3,31,32], ACLs would have a similar healing process with these ligaments. In the healing process of the MCL, vascular-rich granulation tissue invades the rupture area of the ligament, initially closing and then gradually replacing it with fibrous tissue [17]. The increase in ATT in Loose-CATT may have increased mechanical stress on the ACL immediately after injury and physiologically inhibited the formation of a fragile provisional matrix. Secondly, loosening of the ATT would induce abnormal mechano-transduction in the ACL healing. In the wound healing process, abnormal mechanical stress prolongs inflammation, delays wound closure, and is a significant factor leading to hypertrophic scar formation [13,33]. The large wounds or wound closure under high tension result in larger scar tissues [34]. Other connective tissues, such as skin, still enable wound

closure due to the presence of a scaffold. However, as reported by Murray et al., the ACL is present in synovial fluid, and the provisional matrix is washed away, prohibiting scaffold formation [4,31,35]. In our previous data, we reported that controlling abnormal motion of the tibia after ACL injury can reduce MMPs that cause matrix degradation on the ACL [5,19,36]. Thus, controlling of the ATT loosening may have reduced abnormal mechano-transduction and led to ACL healing. Therefore, increased ATT in the early post-injury period may have physiologically disrupted the fragile ligaments or biochemically promoted the catabolic process of the injured ACL. Our results suggested that the loose braking of ATT inhibit in the early ACL healing.

Interestingly, we found sex differences in the success rate of ACL healing. It is known that there are sex differences in ACL injury mechanisms, and the ACL injury rate in women is 2~6 times higher than that in men [37–39]. Surprisingly, our findings showed that the ACL healing success rate was higher in females than in males. Since there were no sex differences in collagen composition and mechanical strength of the healed ACLs, loosening of the ATT braking by the nylon suture in males may have had a negative effect on ACL healing. The similar ATT braking force in the male and female Tight-CATT group was observed immediately after injury. However, the ATT braking of the male Tight-CATT group decreased after 4 weeks post-injury, at a lower

rate than that of the females. These results might be caused by the difference in cage activity between male and female mice. Previous studies have reported that the amount of spontaneous exercise in wheel-running is higher in females among C57BL/6 mice [40]. Additionally, a study examining home-cage activity levels found that females exhibited significantly higher activity in the dark time [41].

In contrast, males exhibit more aggressive behaviors, such as fighting and mounting, when kept with two or more animals [42]. In this study, we housed 2-4 mice in one cage for both sexes. Based on this knowledge, male mice might show more intense activity than females in a cage. Additionally, standing on two limbs in a fighting or defensing motion is more unstable than walking on four limbs,[43,44] which would increase stress on the knee joints, particularly the healing ACL. Thus, the aggressive behavioral characteristics of male mice may have affected the reduced healing rate of the ACL. This finding implied the importance of the balance between the quality and quantity of exercise during ACL healing. Further study is needed to clarify the relationship between behavioral characteristics of the mice and ACL healing.

We hypothesized that the increasing mechanical stress on the healing ACL immediately after injury would promote collagen maturation and mechanical strength, even if it led to a low success rate of the ACL healing. In general, mechanical stress on

the ligaments promotes fibroblast activation and ECM synthesis, such as collagen [45], resulting in the mechanical strengthening of the ligaments. However, against our expectations, there was no difference in the quality of the healed ACL between the Tight- and Loose-CATT groups. The healed ACLs in Tight- and Loose-CATT groups showed similar collagen maturation and mechanical strength, and inferior properties compared to the intact ACL. In addition, the expression of COL1A1, which contributes to the mechanical properties of the ligaments and tendons, was localized along the ACL in the intact. Conversely, irregular and poor collagen localization was observed at healed ACL in both Tight- and Loose-CATT groups. The results of anterior drawer testing showed ATT was increased in both the Tight- and Loose-CATT groups after 4 weeks post-injury compared with immediately after injury. This suggests there was no difference in mechanical stress on the healed ACL between the two groups, at least after 4 weeks post-injury. Accordingly, tight braking of the ATT is important for higher success rate of the ACL healing during the early phase of ACL healing, on the other hand, it is suggested that an increase in mechanical stress at the level of loosening does not contribute to promoting ACL healing because loosening occurs in both Tight- and Loose-CATT, and as the quality of the healed ACL shows no difference. Previous study showed that low-intensity exercise during the healing process of the supraspinatus

tendon is reported to be beneficial in maintaining structure and promoting repair in the early stages of healing, but is insufficient to promote long-term healing [46]. In ACL-reconstructed mice, it was reported that proper timing of mechanical stress was more effective in promoting healing than immediate postoperative or delayed mechanical stress [47]. This study revealed that the mild increase in mechanical force induced by loosening is insufficient to improve ECM synthesis or mechanical strength of the healed ACL. Although our results suggest the importance of tight control of abnormal tibial translation in the early phase after ACL injury, the optimal mechanical force for promoting ACL healing remains unclear. Future study will focus on this point.

In this study, we have several limitations. First, mice are a commonly used model for wound healing research. However, the structure and alignment of the mouse knee, which is always in a flexed position, differs partially from that of the human knee, which is typically in an extended position. Therefore, the mice are not a model that completely reconstructs the human condition. Second, as mentioned above, the CATT model used in this study showed a decrease in ATT braking force after 4 weeks post-injury. It cannot be denied that the nylon threads were stretched or the knots loosened, due to repetitive knee joint movements of the mice. Therefore, the present results may not reflect the effect of mechanical stress intensity on ACL healing in the

late healing phase. Finally, the current study examined, for starters, how increased mechanical stress affects the healing and subsequent properties of the ACL. Hence, it was not able to elucidate in detail the mechanisms by which ACL healing was impaired by increased mechanical stress in the early stages of healing. In the future, we will analyze biochemical data and intracellular changes up to 4 weeks after ACL injury to elucidate the mechanism of mechanical transduction in ACL healing.

In this study, we investigated the relationship between mechanical force and wound repair response in the early phase of ACL spontaneous healing. The results showed that loose braking of the ATT immediately after injury is a negative factor for the healing of the completely injured ACL. Conversely, the increasing mechanical force induced by loosening is insufficient to improve the ECM synthesis or mechanical properties of the healed ACL. Still, the mechanism by which the spontaneous ACL healing remains unclear, controlling the mechanical force on the ACL should play a key role in the fate of ACL healing and maturation. We provided essential insights into understanding the mechano-transduction of ACL healing, which is critical for leading to ACL healing mechanisms, as well as rehabilitation in ACL conservative treatment.

Acknowledgments

This work was supported by JSPS KAKENHI (21H03306, 19KK0411), the grant from Tokyo Physical Therapist Association (05094) and the attack grant from Saitama Prefectural University.

Authorship: All authors approved the final version to be published. Study design: RS and TK; data collection and statistical analysis: RS, KN, YU, SE, KN; manuscript composition RS, and TK.

List of Abbreviations

ATT: Anterior Tibial Translation

ACL: Anterior Cruciate Ligament

ACL-R: Anterior Cruciate Ligament Rupture

ANOVA: Analysis of Variance

ART: Aligned Rank Transform

CATT: Controlled Anterior Tibial Translation

COL1A1: Type I Collagen

ECM: Extra-Cellular Matrix

HE: Hematoxylin and Eosin

MCL: Medial Collateral Ligament

PsR: Picrosirius Red

Reference

1. Haslauer CM, Proffen BL, Johnson VM, Murray MM. Expression of modulators of extracellular matrix structure after anterior cruciate ligament injury. Wound Repair Regeneration. 2014 Jan;22(1):103–10.

2. Bray RC, Leonard CA, Salo PT. Correlation of healing capacity with vascular response in the anterior cruciate and medial collateral ligaments of the rabbit. J Orthop Res. 2003 Nov;21(6):1118–23.

3. Menetrey J, Laumonier T, Garavaglia G, Hoffmeyer P, Fritschy D, Gabbiani G, et al. α-Smooth muscle actin and TGF-β receptor I expression in the healing rabbit medial collateral and anterior cruciate ligaments. Injury. 2011 Aug;42(8):735–41.

4. Murray MM, Spindler KP, Ballard P, Welch TP, Zurakowski D, Nanney LB. Enhanced histologic repair in a central wound in the anterior cruciate ligament with a collagen–platelet-rich plasma scaffold. J Orthop Res. 2007 Aug;25(8):1007–17.

5. Kokubun T, Kanemura N, Murata K, Moriyama H, Morita S, Jinno T, et al. Effect of Changing the Joint Kinematics of Knees With a Ruptured Anterior Cruciate Ligament on the Molecular Biological Responses and Spontaneous Healing in a Rat Model. Am J Sports Med. 2016 Nov;44(11):2900–10.

6. Ihara H, Miwa M, Deya K, Torisu K. MRI of anterior cruciate ligament healing. J Comput Assist Tomogr. 1996;20(2):317–21.

7. Fujimoto E, Sumen Y, Ochi M, Ikuta Y. Spontaneous healing of acute anterior cruciate ligament (ACL) injuries - conservative treatment using an extension block soft brace without anterior stabilization. Archives of Orthopaedic and Trauma Surgery. 2002 May 1;122(4):212–6.

8. Previ L, Monaco E, Carrozzo A, Fedeli G, Annibaldi A, Cantagalli MR, et al. Spontaneous healing of a ruptured anterior cruciate ligament: a case series and literature review. J EXP ORTOP. 2023 Feb 4;10(1):11.

9. Filbay SR, Roemer FW, Lohmander LS, Turkiewicz A, Roos EM, Frobell R, et al. Evidence of ACL healing on MRI following ACL rupture treated with rehabilitation alone may be associated with better patient-r-eported outcomes: a secondary analysis from the KANON trial.

10. Talbott HE, Mascharak S, Griffin M, Wan DC, Longaker MT. Wound healing, fibroblast heterogeneity, and fibrosis. Cell Stem Cell. 2022 Aug;29(8):1161–80.

11. Moretti L, Stalfort J, Barker TH, Abebayehu D. The interplay of fibroblasts, the extracellular matrix, and inflammation in scar formation. Journal of Biological Chemistry. 2022 Feb;298(2):101530.

12. DiGiovanni GT, Han W, Sherrill TP, Taylor CJ, Nichols DS, Geis NM, et al. Epithelial Yap/Taz are required for functional alveolar regeneration following acute lung injury. JCI Insight. 2023 Sept 7;8(19):e173374.

13. Harn HI, Ogawa R, Hsu C, Hughes MW, Tang M, Chuong C. The tension biology of wound healing. Experimental Dermatology. 2019 Apr;28(4):464–71.

14. Willenborg S, Schönborn K, Sawant M, Bornikoel A, Yamane T, Zeinert I, et al. Fibroblast□Derived TGFβ1 Regulates Skin Repair and Fibrosis. Wound Repair Regeneration. 2025 July;33(4):e70065.

15. Woo SLY, Vogrin TM, Abramowitch SD. Healing and Repair of Ligament Injuries in the Knee: Journal of the American Academy of Orthopaedic Surgeons. 2000 Nov;8(6):364–72.

16. Chamberlain CS, Crowley E, Vanderby R. The spatio-temporal dynamics of ligament healing. Wound Repair and Regeneration. 2009 Mar;17(2):206–15.

17. Gomez MA, Woo SLY, Amiel D, Harwood F, Kitabayashi L, Matyas JR. The effects of increased tension on healing medial collateral ligaments. Am J Sports Med. 1991 July;19(4):347–54.

18. Kano T, Kokubun T, Murata K, Oka Y, Ozone K, Arakawa K, et al. Influence of the site of injury on the spontaneous healing response in a rat model of total rupture of the anterior cruciate ligament. Connective Tissue Research. 2022 Mar 4;63(2):138–50.

19. Morishita Y, Kanemura N, Kokubun T, Murata K, Takayanagi K. Acute molecular biological responses during spontaneous anterior cruciate ligament healing in a rat model. Sport Sci Health. 2019 Dec;15(3):659–66.

20. Eliasson P, Andersson T, Aspenberg P. Achilles tendon healing in rats is improved by intermittent mechanical loading during the inflammatory phase: TENDON HEALING AND EARLY LOADING. J Orthop Res. 2012 Feb;30(2):274–9.

21. Chen Y, Zhang T, Wan L, Wang Z, Li S, Hu J, et al. Early treadmill running delays rotator cuff healing via Neuropeptide Y mediated inactivation of the Wnt/β-catenin signaling. Journal of Orthopaedic Translation. 2021 Sept;30:103–11.

22. Chen H, Li S, Xiao H, Wu B, Zhou L, Hu J, et al. Effect of Exercise Intensity on the Healing of the Bone-Tendon Interface: A Mouse Rotator Cuff Injury Model Study. Am J Sports Med. 2021 July;49(8):2064–73.

23. Wada S, Lebaschi AH, Nakagawa Y, Carballo CB, Uppstrom TJ, Cong G, et al. Postoperative Tendon Loading With Treadmill Running Delays Tendon to Bone Healing: Immunohistochemical Evaluation in a Murine Rotator Cuff Repair Model. J Orthop Res. 2019 July;37(7):1628–37.

24. Takahata K, Arakawa K, Enomoto S, Usami Y, Nogi K, Saitou R, et al. Joint instability causes catabolic enzyme production in chondrocytes prior to synovial cells in novel non-invasive ACL ruptured mouse model. Osteoarthritis and Cartilage. 2023 May;31(5):576–87.

25. Uezono K, Ide J, Tokunaga T, Arimura H, Sakamoto H, Nakanishi Y, et al. Effect of Postoperative Passive Motion on Rotator Cuff Reconstruction With Acellular Dermal Matrix Grafts in a Rat Model. Am J Sports Med. 2014 Aug;42(8):1930–8.

26. Koike Y, Trudel G, Uhthoff HK. Formation of a new enthesis after attachment of the supraspinatus tendon: A quantitative histologic study in rabbits. J Orthop Res. 2005 Nov;23(6):1433–40.

27. Wobbrock JO, Findlater L, Gergle D, Higgins JJ. The aligned rank transform for nonparametric factorial analyses using only anova procedures. In: Proceedings of the SIGCHI Conference on Human Factors in Computing Systems [Internet]. New York, NY, USA: Association for Computing Machinery; 2011 [cited 2023 Dec 18]. p. 143–6. (CHI ’11). Available from: https://doi.org/10.1145/1978942.1978963

28. Jordão S, Cortes N, Gomes J, Brandão R, Santos P, Pezarat-Correia P, et al. Synchronization performance affects gait variability measures during cued walking. Gait & Posture. 2022 July;96:351–6.

29. Novaretti JV, Astur DC, Casadio D, Nicolini AP, De Castro Pochini A, Andreoli CV, et al. Higher Gene Expression of Healing Factors in Anterior Cruciate Ligament Remnant in Acute Anterior Cruciate Ligament Tear. Am J Sports Med. 2018 June;46(7):1583–91.

30. Kawakami J, Hisanaga S, Yoshimoto Y, Mashimo T, Kaneko T, Yoshimura N, et al. Remnant tissue enhances early postoperative biomechanical strength and infiltration of Scleraxis-positive cells within the grafted tendon in a rat anterior cruciate ligament reconstruction model. Pagel CN, editor. PLoS ONE. 2023 Nov 8;18(11):e0293944.

31. Murray MM, Fleming BC. The Biology of Anterior Cruciate Ligament Injury and Repair: Kappa Delta Ann Doner Vaughn Award Paper 2013. J Orthop Res. 2013 Oct;31(10):1501–6.

32. Xie J, Jiang J, Zhang Y, Xu C, Yin L, Wang C, et al. Up-regulation expressions of lysyl oxidase family in Anterior Cruciate Ligament and Medial Collateral Ligament fibroblasts induced by Transforming Growth Factor-Beta 1. International Orthopaedics (SICOT). 2012 Jan;36(1):207–13.

33. Chiang RS, Borovikova AA, King K, Banyard DA, Lalezari S, Toranto JD, et al. Current concepts related to hypertrophic scarring in burn injuries. Wound Repair Regeneration. 2016 May;24(3):466–77.

34. Zhu KQ, Carrougher GJ, Couture OP, Tuggle CK, Gibran NS, Engrav LH. Expression of Collagen Genes in the Cones of Skin in the Duroc/Yorkshire Porcine Model of Fibroproliferative Scarring: Journal of Burn Care & Research. 2008 Sept;29(5):815–27.

35. Murray MM, Martin SD, Martin TL, Spector M. Histological Changes in the Human Anterior Cruciate Ligament After Rupture*. JBJS. 2000 Oct;82(10):1387.

36. Nishikawa Y, Kokubun T, Kanemura N, Takahashi T, Matsumoto M, Maruyama H, et al. Effects of controlled abnormal joint movement on the molecular biological response in intra-articular tissues during the acute phase of anterior cruciate ligament injury in a rat model. BMC Musculoskelet Disord. 2018 Dec;19(1):175.

37. Spindler KP, Wright RW. Anterior Cruciate Ligament Tear. N Engl J Med. 2008 Nov 13;359(20):2135–42.

38. Park SK, Stefanyshyn DJ, Loitz-Ramage B, Hart DA, Ronsky JL. Changing Hormone Levels during the Menstrual Cycle Affect Knee Laxity and Stiffness in Healthy Female Subjects. Am J Sports Med. 2009 Mar;37(3):588–98.

39. Ford KR, Myer GD, Hewett TE. Valgus Knee Motion during Landing in High School Female and Male Basketball Players. Medicine & Science in Sports & Exercise. 2003 Oct;35(10):1745.

40. Nigro P, Middelbeek RJW, Alves CRR, Rovira-Llopis S, Ramachandran K, Rowland LA, et al. Exercise Training Promotes Sex-Specific Adaptations in Mouse Inguinal White Adipose Tissue. Diabetes. 2021 June 1;70(6):1250–64.

41. Bains RS, Forrest H, Sillito RR, Armstrong JD, Stewart M, Nolan PM, et al. Longitudinal home-cage automated assessment of climbing behavior shows sexual dimorphism and aging-related decrease in C57BL/6J healthy mice and allows early detection of motor impairment in the N171-82Q mouse model of Huntington's disease. Front Behav Neurosci. 2023 Mar 22;17:1148172.

42. Lidster K, Owen K, Browne WJ, Prescott MJ. Cage aggression in group-housed laboratory male mice: an international data crowdsourcing project. Sci Rep. 2019 Oct 23;9(1):15211.

43. Adams D. Ventromedial tegmental lesions abolish offense without disturbing predation or defense. Physiology & Behavior. 1986 Jan;38(2):165–8.

44. Miczek KA, Maxson SC, Fish EW, Faccidomo S. Aggressive behavioral phenotypes in mice. Behavioural Brain Research. 2001 Nov;125(1–2):167–81.

45. Zhang J, Wang JHC. The Effects of Mechanical Loading on Tendons - An In Vivo and In Vitro Model Study. Roeder RK, editor. PLoS ONE. 2013 Aug 19;8(8):e71740.

46. Chen H, Li S, Xiao H, Wu B, Zhou L, Hu J, et al. Effect of Exercise Intensity on the Healing of the Bone-Tendon Interface: A Mouse Rotator Cuff Injury Model Study. Am J Sports Med. 2021 July;49(8):2064–73.

47. Camp CL, Lebaschi A, Cong GT, Album Z, Carballo C, Deng XH, et al. Timing of Postoperative Mechanical Loading Affects Healing Following Anterior Cruciate

Ligament Reconstruction: Analysis in a Murine Model. The Journal of Bone and Joint Surgery. 2017 Aug 16;99(16):1382–91.

Table

Table 1. We defined ACL spontaneous healing from HE stained images. Tight-CATT group showed higher healing success rate than Loose-CATT group at 4 and 8 weeks after injury.

	4 weeks				**8 weeks**			
	Tight-CATT		**Loose-CATT**		**Tight-CATT**		**Loose-CATT**	
	Male	**Female**	**Male**	**Female**	**Male**	**Female**	**Male**	**Female**
Healed	**5**	**4**	**2**	**1**	**3**	**4**	**1**	**4**
Non-healed	**2**	**1**	**3**	**3**	**4**	**0**	**5**	**3**
Success rates of ACL healing (%)	**71.4**	**80.0**	**40.0**	**25.0**	**42.9**	**100.0**	**16.7**	**57.1**

Figure

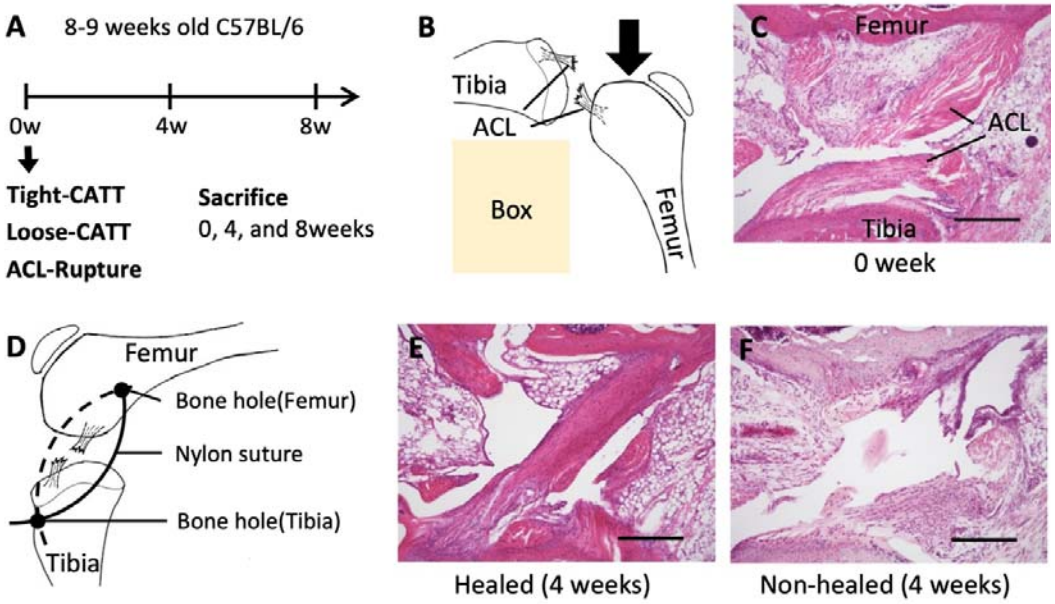

Figure 1. C57BL/6 mice were ruptured the ACL and classified to Tight-CATT, Loose-CATT and ACL-R group. Mice were sacrificed immediately after injury, and at 4- and 8-weeks post-injury (A). We fixed the hindlimb with the knee joint at 90 degrees and ruptured the ACL by pushing the femur backward against the tibia (B). HE images of the ACL immediately after ACL rupture (C). Controlled Anterior Tibial Translation (CATT) model. Tightly looped by single 3-0 or 4-0 nylon suture through the femoral and tibial bone holes to control the ATT (D). HE images of the healed ACL (E) and non-healed ACL (F) (Scale bar = 300 μm).

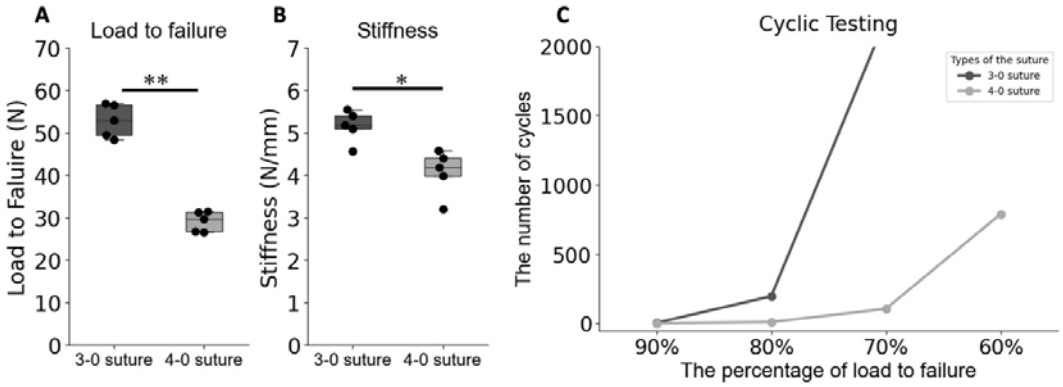

Figure 2. The load to failure (A) and stiffness (B) of the nylon suture in failure testing, and the number of cycles at the point of suture rupture in cyclic testing (C) were recorded (*$p < 0.05$, **$p < 0.01$).

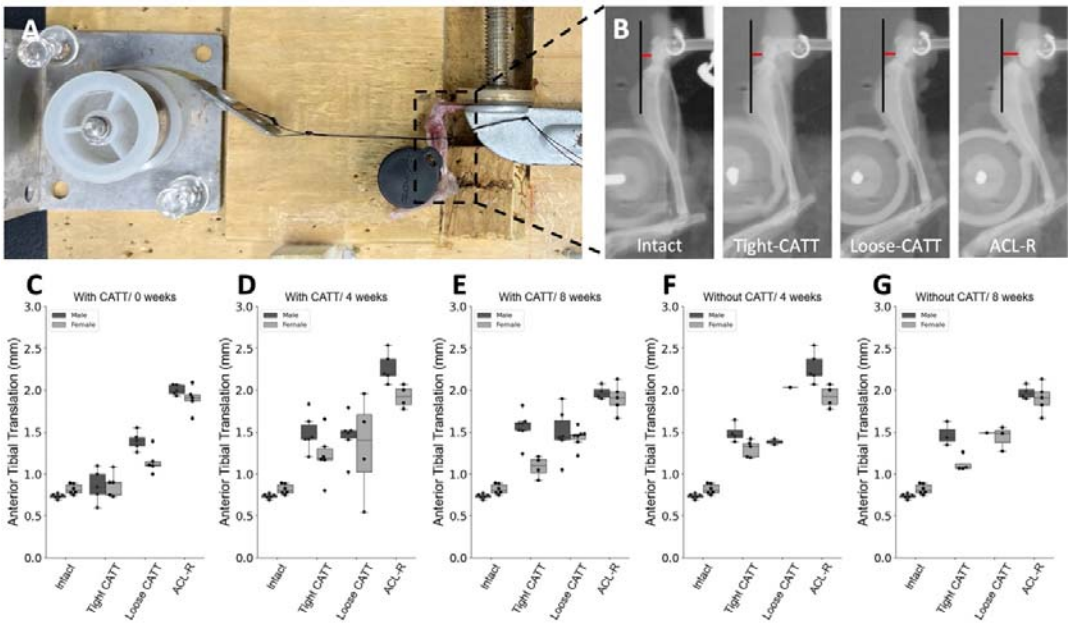

Figure 3. Anterior drawer testing was performed with the knee joint fixed at 90° via the self-made anterior drawer device (A). Representative X-ray images of each group (B). We evaluated the braking force of the ATT for each group immediately after injury (C) and at 4 (D) and 8 weeks (E), and anterior tibial instability of ACL healed knee at 4 (F) and 8 weeks (G).

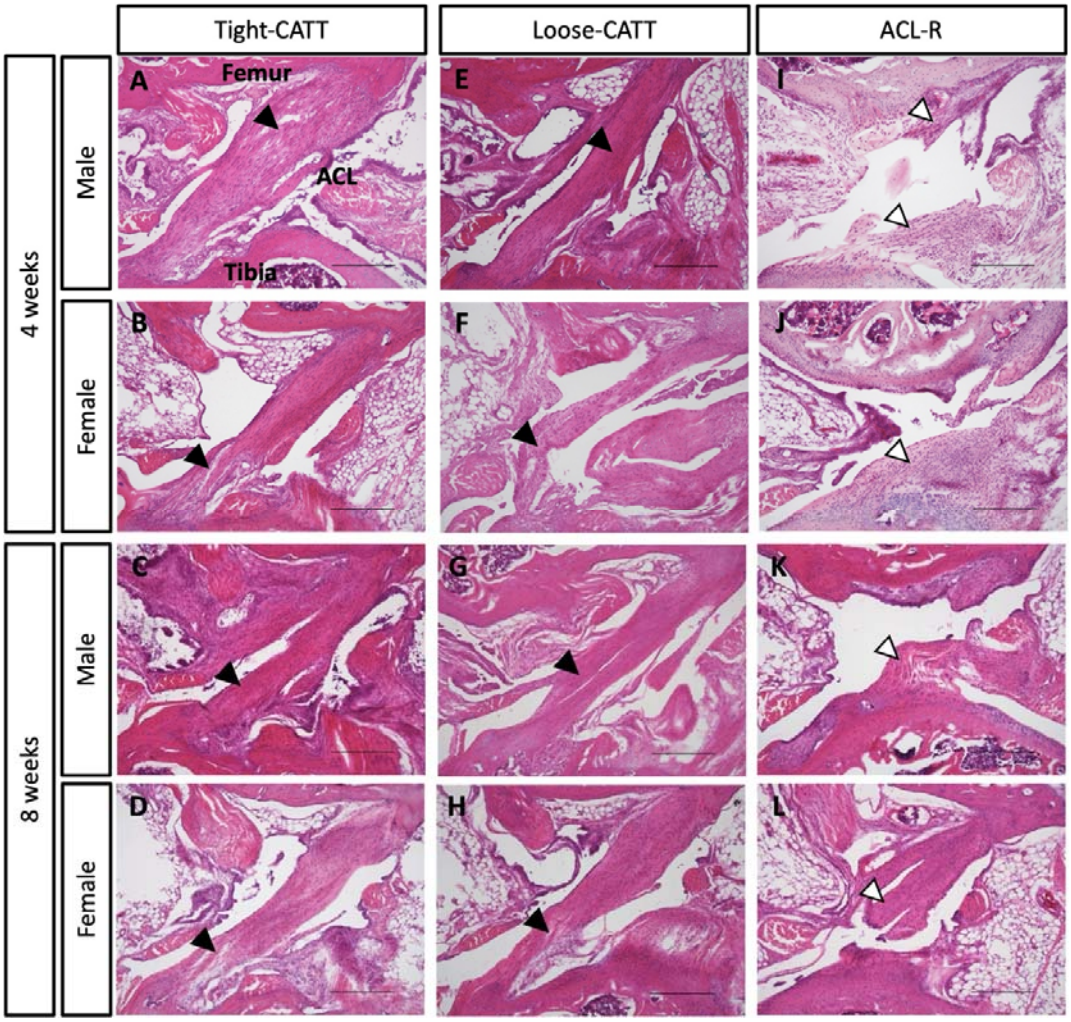

Figure 4. HE stained images of the Tight-CATT (A, B, C, and D), Loose-CATT (E, F, G, and H), ACL-R groups (I, J, K, and L) at 4 and 8 weeks (Scale bar = 300 μm). The black arrows point to the healing region of the healed ACL and white arrows point to the non-healed ACL.

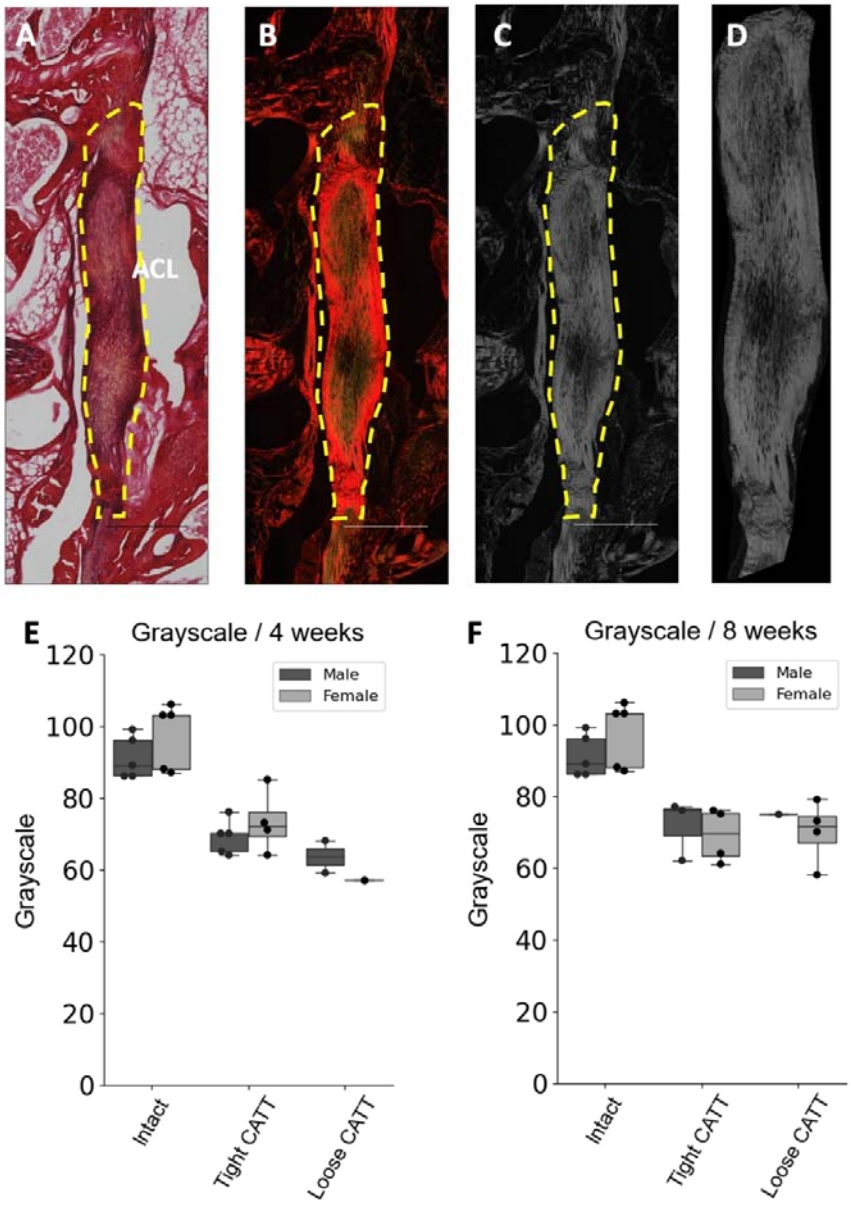

Figure 5. Picrosirius red stained (A) and polarized image (B) of the ACL. Picrosirius red images were converted to grayscale images (C) and specified ACL area as ROI (D). Collagen maturation of the ACL was evaluated at 4 (E) and 8 weeks (F) after injury (Scale bar = 300 μm).

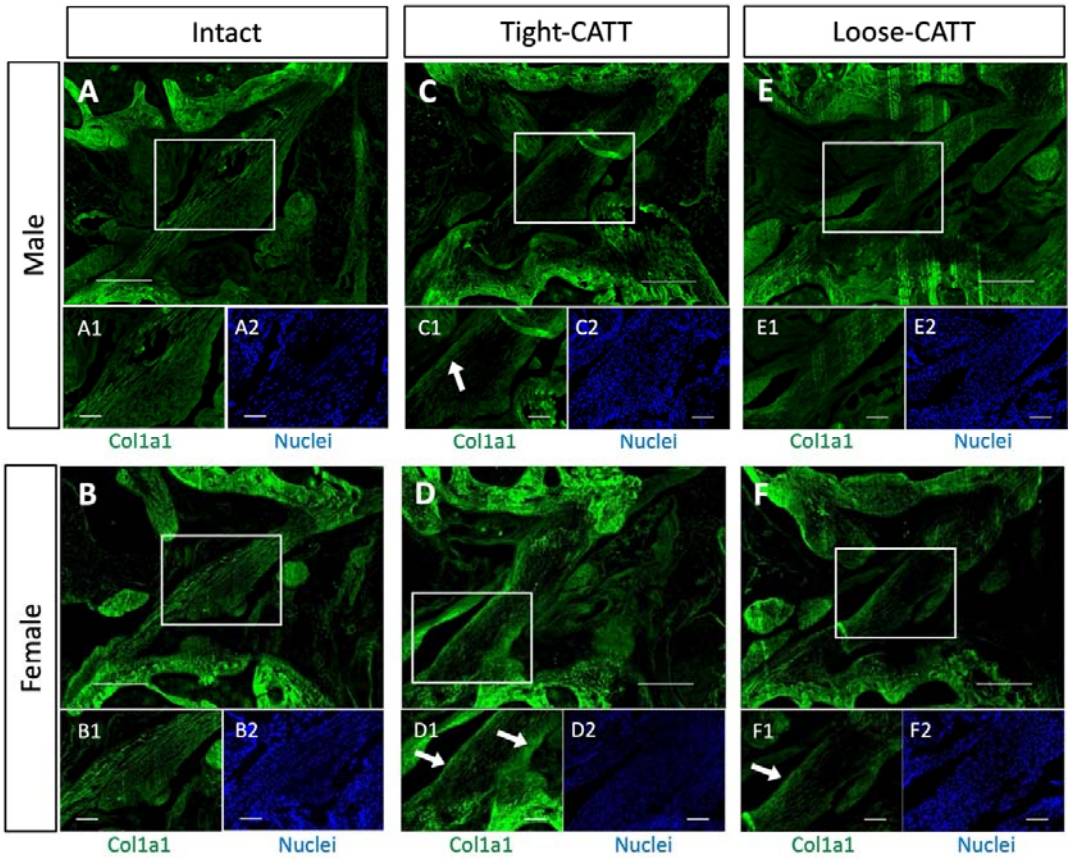

Figure 6. Immunofluorescence images targeted COL1A1 of the intact ACL (A, B), healed ACL of the Tight-CATT (C, D) and Loose-CATT (E, F) groups at 8 weeks (Scale bar = 300μm) and showing mid-substance of the ACL: COL1A1 (green) and DAPI (blue) (Scale bar = 100μm). Arrows pointed to areas of high COL1A1 expression.

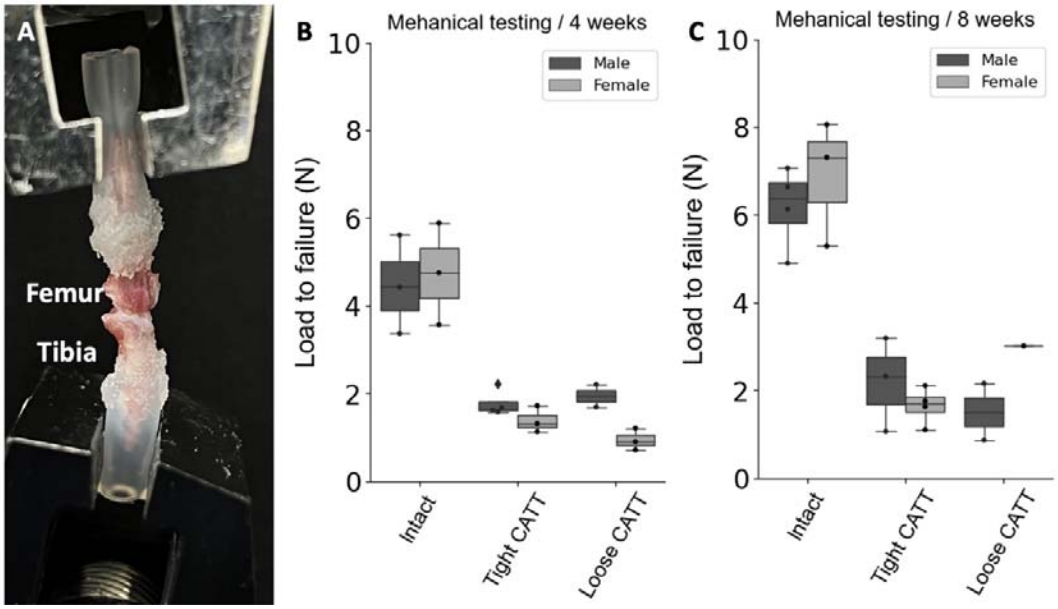

Figure 7. To perform biomechanical testing, the soft tissues of the knee except the ACL were dissected and the femur and tibia were fixed in tubes (A). The load to failure (A) of the healed ACL at 4 (B) and 8 (C) weeks after injury were recorded.