Congenital heart defects differ following left versus right avian cardiac neural crest ablation

Tatiana Solovieva, Marianne E. Bronner

California Institute of Technology

ABSTRACT

The cardiac neural crest is critical for the normal development of the heart, as its surgical ablation in the chick recapitulates common human congenital heart defects such as 'Common Arterial Trunk' and 'Double Outlet Right Ventricle' (DORV). While left-right asymmetry is known to be important for heart development, little is known about potential asymmetric differences between right and left cardiac neural folds with respect to heart development. Here, through surgical ablation of either left or right cardiac neural crest, we reveal that right ablation results in more varied and more severe heart defects. Embryos with Common Arterial Trunk and with missing arteries occur only in right-ablated embryos; moreover, embryos with DORV and with misalignment of the arteries were more prevalent following right versus left cardiac crest ablation. In addition, overall survival of right-ablated embryos was lower than left-ablated embryos, with embryos dying earlier in development. Together, these data implicate different functions for left versus right cardiac neural crest in heart development.

INTRODUCTION

Normal development of the heart requires an essential contribution from the cardiac neural crest. The cardiac neural crest is a migratory population of cells, first arising during neurulation, as the left and right neural folds meet in the dorsal midline of the embryo [1]. These cells then migrate through branchial arches 3, 4 and 6 [2] and through the truncus of the outflow tract toward the heart, laying down the truncal septum as they do so, thus dividing the outflow tract into two distinct vessels; the aorta and pulmonary trunk [3-5]. In addition to the outflow tract septum, cardiac neural crest has also been shown to contribute to the aortic arch arteries [3], subsequent carotid and other arteries [6] the ventricular septum [5], the cardiac ganglion cells [7] and some cardiomyocytes [8].

Importantly, ablation studies in the chick have demonstrated that absence of the cardiac neural crest gives rise to a range of heart defects [4, 9-13] reminiscent of common human congenital heart defects [14-15]. These include Common Arterial Trunk (also called 'Persistent Truncus Arteriosus', or PTA), 'Double Outlet Right Ventricle' (DORV), misalignment of arteries and abnormal myocardium function, among others. With a four chambered heart, like mammals, this makes the chick an appropriate model to better understand the specific roles of cardiac neural crest in congenital heart defects affecting humans [16].

While it is recognized that left-right asymmetry is important for heart development, the neural crest has generally been assumed to be a bilaterally symmetric population, given generally similar migration patterns on the left and right side of the embryo in cranial and trunk regions. There has therefore been almost no previous research on possible left-right differences in the neural crest. One notable exception was a study by Kirby and colleagues nearly 40 years ago, in which they ablated different unilateral portions of neural crest, including some sub-regions of the chick cardiac neural crest, and assessed subsequent effects on development [9]. They reported some variation in resulting heart defects between equivalent left and right neural crest ablated embryos. A more recent study remarked on the prevalence of different heart defects following left versus right cardiac neural crest ablation in chick [17] and another study in cavefish noted slight variations in gene expression between left and right cranial neural crest [18]. These data raise the intriguing possibility that left and right neural crest cells may have different roles in development at particular axial levels. Here, we expand and build upon the small amount of existing literature and present a detailed, comprehensive study of the

effects of unilateral ablation of the left versus right pre-migratory cardiac neural crest on heart development in the chick.

MATERIALS AND METHODS

Embryos: Chicken embryos were obtained from Rhode Island Red hens (Petaluma Farm). Eggs were incubated horizontally in humidified incubation chambers (38°C). Embryo staging was carried out according to Hamburger and Hamilton [19].

Micro-surgery: All ablations were performed *in ovo.* Following horizontal incubation to HH10 (˜1.5 days), the embryo was first 'lowered' in the egg by removing 2-3 ml of albumen from the blunt end of the egg via a syringe. The egg was then 'windowed' by cutting a small (~1-2 cm length) hole in the top of the shell. To provide contrast and help visualize the embryos, filtered black ink diluted in Ringer's solution was injected directly below the embryo. Only embryos at HH10, specifically those with 9.5-10.75 somites, and displaying typical anatomy were used for ablations. A pulled glass needle was used to cut a small hole in the vitelline membrane directly above the region of interest. The needle was then gently used to make an incision along the lateral length of the cardiac neural crest on one side of the embryo, followed by incisions at the rostral, caudal, and medial sides of the unilateral cardiac neural crest. The rostral limit of removed neural crest was equivalent to the level of the mid-otic vesicle, while the caudal limit was equivalent to the caudal level of somite three. Detached cardiac neural crest tissue was then removed from the egg. Throughout surgery, the embryo was kept hydrated with Ringer's solution. Post-surgery, a few drops of Ringer's with diluted penicillin-streptomycin were added to prevent infection. The egg was then sealed with electrical tape and immediately incubated for a further 7 days, to HH32-35.

Histology: After harvesting, embryos were fixed in 4 % Paraformaldehyde in phosphate buffer overnight (4 °C), rinsed 3X in PBS and then washed overnight in PBS (4 °C). Embryos were equilibrated in 5 % sucrose in PBS overnight (4 °C), 15 % sucrose in PBS overnight (4 °C), and finally in 7.5 % gelatin/15 % sucrose overnight (38 °C). Embryos were then snap-frozen in molds using liquid nitrogen and stored at -80 °C for at least one overnight prior to cryosectioning. 16 µm serial sections were cut and collected onto 'Superfrost' slides (every section was collected). These slides were kept at room temperature overnight before subsequent processing/storage at -20 °C.

Imaging and image processing: Serial sections were imaged using a Zeiss imager MZ with a black-and-white camera. Images of serial sections were assembled for each embryo into one figure (Affinity Designer), facilitating the identification and analysis of 3-dimentional anatomical structures throughout the depth of the heart.

RESULTS

Right ablated embryos die earlier and have a lower survival rate than left ablated embryos: Pre-migratory left or right cardiac neural crest was ablated from embryos at HH10 (specifically embryos with 9.5-10.75 somites), which corresponds to a time-point immediately prior to the cells' migration out from the neural folds (Fig. 1A). Following surgery, embryos were re-incubated for a further 7 days until they reached HH32-35, by which stage cardiac neural crest cells would have condensed to form the aorticopulmonary septum of the outflow tract [3-5], allowing septal defects such as DORV and Common Arterial Trunk to be detected.

Embryo survival to this stage was 16% for left ablated embryos (11/69 operated embryos), comparable to that of sham-ablated embryos (15%, 12/78 operated embryos) that had no embryonic tissue removed but had been prepared for ablation (window made in eggshell and hole made in the vitelline membrane above the embryo) (Fig. 1B). This suggests that at least by stage HH32, lacking a left cardiac crest is no more lethal to the embryo than having both cardiac neural crest populations intact. However, survival of right-ablated embryos was considerably lower, at 12%, with only 12 out of 103 operated embryos getting to at least stage HH32, suggesting that the absence of right rather than left cardiac neural crest has more severe consequences on development during these stages. Moreover, of all embryos that died before reaching HH32,

death of right-ablated embryos peaked at a slightly younger stage (HH26-27) compared to left- or sham-ablated embryos (HH28-29) (Fig.1C).

Collectively, this raises the possibility that right cardiac neural crest has a role in development that occurs earlier and is more crucial than the role of left cardiac neural crest.

Type and severity of septation defects varies between left and right cardiac neural crest ablated embryos: All operated embryos that survived to at least stage HH32 were embedded and sectioned (angle of whole-embryo sections shown in Fig. 1A) (Table 1, shows information on all embryos). Serial cross-sections were analyzed through the entire heart and septal defects categorized at four levels: outflow tract vessels distal to the valves (Fig. 2A-Ei), outflow tract at the level of the valves (Fig. 2A-Eii), root of the outflow tract (Fig. 2A-Eiii) and through the ventricles (Fig. 2A-Eiv).

The complete absence of an aorticopulmonary septum through the outflow tract at, and distal to the level of the outflow tract valves is indicative of Common Arterial Trunk (also termed Pulmonary Trunk Arteriosus) (Fig. 2E). This cardiac defect is known to be the result of a failure of cardiac neural crest to successfully septate the outflow tract, resulting in a single outflow tract vessel rather than two separate vessels, the aorta and pulmonary trunk (Fig. 2Ei-ii versus Fig. 2Ai-ii). Intriguingly, Common Arterial Trunk was observed only following right cardiac neural crest ablations, occurring in 17% of right-ablated embryos (Fig. 2F). In these embryos, the single outflow tract was overriding the right ventricle.

The most common septal defect found was an interventricular communication (Fig. 2G), with a full connection between left and right ventricles at the level of the outflow tract roots (Fig. 2Ciii). Of these, in embryos with a separate aorta and pulmonary trunk, the aorta was misaligned, either partially or completely overriding the right ventricle rather than the left ventricle, suggesting DORV (Fig. 3C-D) [20]. DORV was observed in 33% of right ablated embryos and only 18% of left-ablated embryos (Fig. 2H). In most observed cases of DORV, the interventricular communication was present only at the level of the outflow tract roots; however, in one case, there was a clear interventricular connection lower down in the ventricles of a left-ablated embryo (Fig. 2Div).

The third septal defect observed was that of a partial interventricular communication (Fig. 2B). This was characterized by the presence of a ‘seam’ or ‘hairline’ connection between the aortic and pulmonary roots, resulting from the incomplete fusion of the proximal outflow cushions, without complete septation *or* connection between the two sides (Fig. 2Biii compared to Fig. 2Aiii and Ciii). This phenotype was observed in 45% of left-ablated embryos and only 17% of right-ablated embryos (Fig. 2H).

Collectively, analysis of septal defects across all levels of the heart implies a more significant role for right cardiac neural crest in normal outflow tract and interventricular septation of the heart.

Artery development affected more severely by right than by left cardiac neural crest ablation: During development, cardiac neural crest contributes to the aortic arch arteries originating from branchial arches 3,4 and 6, which subsequently undergo a significant remodeling. By HH32, at the levels studied, there are three arch artery-derived vessels originating from the right side of the embryo (aorta; right brachiocephalic artery, RBA; right pulmonary artery, RPA) and two from the left (left brachiocephalic artery, LBC; left pulmonary artery, LPA) (Fig. 3A). Serial cross-sections through these arteries were analyzed by following a series of distal-to-proximal ‘fusion’ events in the embryo (Fig. 3A-D).

The most prominent defect observed was that of missing arteries (Fig. 3C). This occurred only following right cardiac neural crest ablation, in 33% of right-ablated embryos (Fig. 3E). In these cases, there were only four arteries where there should normally be five (Fig. 3Ci versus 3Bi).

The second defect observed in the arteries following unilateral cardiac neural crest ablation was the order in which arteries fused to one another along the distal-to-proximal axis (Fig. 3Diii-iv versus 3Biii-iv). The fusion order was abnormal in 75% of right-ablated embryos and only in 9% of left-ablated embryos (Fig. 3F).

Taken together, abnormal artery development appears to be an exclusively right cardiac neural crest related phenomenon.

DISCUSSION

Here, we have utilized unilateral cardiac neural crest ablations to reveal the asymmetric effects of left and right cardiac neural crest on heart development, thereby unraveling a more detailed perspective on the roles of cardiac neural crest in congenital heart defects.

The cardiac neural crest is a dynamic cell population that migrates from the neural folds, through the branchial arches and toward the truncus of the outflow tract, then further into the ventricular region of the heart. The peak in embryonic death of right-ablated embryos at HH26-7 corresponds to the time when cardiac neural crest cells surrounding the walls of the aortic arch arteries begin to move into the walls of the distal aorta and pulmonary trunk [5]. On the other hand, the peak in embryonic death of left- and sham-ablated embryos at HH28-9 corresponds to the time when the proximal limit of migrating cardiac neural crest cells (and thus the truncal septum) is closer to the heart, at the level of the future semilunar valves [5]. Together, this suggests a role for right cardiac neural crest earlier and at more distal levels to the heart, than for that of left cardiac neural crest.

When all types of observed septal defect were grouped together (Common Arterial Trunk, DORV and partial interventricular communications), a comparable percentage of right- and left-ablated embryos were affected (67% and 63% respectively) (Fig. 2H). However, in right ablated embryos these defects were made up of mostly complete rather than partial connections between left and right sides of the heart and occurred at more distal levels of the outflow tract than in left ablated embryos.

In comparing the present results to those of previous studies that performed variations of unilateral neural crest ablations, the results for cases of Common Arterial Trunk (PTA) are comparable, with a higher frequency reported following ablation of right cardiac neural crest [17]. Together these observations reinforce the case for right cardiac neural crest having a more significant role than left cardiac neural crest in the normal septation of the outflow tract. However, in a study by Kirby and colleagues [9], where a comparable yet shorter fragment of the unilateral cardiac neural crest was removed (rostro-caudal level equivalent to somites 1-3 only), the frequency of Common Arterial Trunk was reported to be higher following left rather than right neural crest ablations (83% and 60% respectively) and overall, was much more common than in the present study. Possible explanations for this difference could include the use of a different chicken breed, different rostro-caudal extent of neural folds removed, as well as the variation of stages at which ablations were performed. In the study by Kirby and colleagues [9], ablations were carried out between HH8-10, a range which spans over 10hrs of developmental time, compared to the present study where ablations were carried out at HH10, specifically on embryos with between 9.5-10.75 somites, which spans just ˜1hr30 of developmental [19]. During HH8-10, neural folds undergo significant changes [1], which may complicate interpretation of the resulting defects following ablation. The narrow developmental window used here allows focus specifically on ‘mature’ cardiac neural crest after its specification is complete, and immediately prior to its migration away form, the neural tube.

In the present study, the majority of embryos displayed ventricular septal defects, with a comparable incidence in both right (67%) and left (63%) ablated embryos. However, following right ablations, the phenotypes were more severe (mostly full connections) as compared to those following left ablation (mostly partial connections). In reports by Kirby and colleagues, ventricular septal defects were also present in the majority of ablated embryos, but with a slightly higher incidence following left versus right neural crest ablations [9]. A more substantial role for left versus right neural crest was also implied in the observations by Gandhi et al. in cases of DORV (which are always accompanied by a connection between the left and right ventricles) [17]. While apparent discrepancies may be a result of slight variations in experimental design, comparison of studies is not always accurate due to differences in anatomical analyses. Studies categorize defects in different ways (e.g. DORV versus interventricular defects), without always providing information on other

anatomical features (such as vessel alignment, level of septal defect within the heart or the extent of septal connections), making direct comparisons between studies difficult.

While previous studies of unilateral neural crest ablations have mentioned the presence of Common Arterial Trunk (PTA) [9, 17], interventricular septal defects [9] and DORV [17], to our knowledge, there are no previous detailed investigations into or findings of substantial differences in artery development following unilateral cardiac neural crest ablation. Here, a striking difference in the role of left versus right cardiac neural crest was observed in the normal development of aortic arch artery derivatives, suggesting an almost exclusive role for right versus left cardiac neural crest in ensuring development of all five arteries and their correct alignment at stages HH32-35. The current findings warrant further investigation into how this corresponds to the earlier extensive remodeling of aortic arch arteries during development, and the asymmetrical contribution in subsequent vessel numbers from the left (two vessels) and right (three vessels) sides of the embryo.

CONCLUSIONS:

In summary, in the present study we demonstrate that right pre-migratory cardiac neural crest has a more significant role in the normal septation of the outflow tract and interventricular septum than the left cardiac neural crest. Furthermore, when ablated, right cardiac neural crest is almost exclusively responsible for defects in artery number and alignment. Together, this implies a different role for left and right cardiac neural crest in heart development and contribution to congenital heart defects.

ACKNOWLEDGEMENTS:

We thank Prof. Robert H. Anderson for discussions on cardiac anatomy. This work was supported by grants from American Heart Association 1020751 to T.S., and NIH 1R01HL169287-01A1 and Additional Ventures 1011579 to M.E.B.

BIBLIOGRAPHY

1. Ezin AM, Fraser SE, Bronner-Fraser M. Fate map and morphogenesis of presumptive neural crest and dorsal neural tube. Dev Biol. 2009 Jun 15;**330**(2): p.221-36. doi: 10.1016/j.ydbio.2009.03.018. Epub 2009 Mar 28. PMID: 19332051; PMCID: PMC2717095.

2. Phillips MT, Kirby ML, Forbes G. Analysis of cranial neural crest distribution in the developing heart using quail-chick chimeras. Circ Res. 1987 Jan;**60**(1): p.27-30. doi: 10.1161/01.res.60.1.27. PMID: 3568286.

3. Le Lièvre CS, Le Douarin NM. Mesenchymal derivatives of the neural crest: analysis of chimaeric quail and chick embryos. J Embryol Exp Morphol. 1975 Aug;**34**(1): p.125-54. PMID: 1185098.

4. Kirby ML, Gale TF, Stewart DE. Neural crest cells contribute to normal aorticopulmonary septation. Science. 1983 Jun 3;**220**(4601): p.1059-61. doi: 10.1126/science.6844926. PMID: 6844926.

5. Waldo K, Miyagawa-Tomita S, Kumiski D, Kirby ML. Cardiac neural crest cells provide new insight into septation of the cardiac outflow tract: aortic sac to ventricular septal closure. Dev Biol. 1998 Apr 15;**196**(2): p.129-44. doi: 10.1006/dbio.1998.8860. PMID: 9576827.

6. Waldo KL, Kirby ML. Cardiac neural crest contribution to the pulmonary artery and sixth aortic arch artery complex in chick embryos aged 6 to 18 days. Anat Rec. 1993 Nov;**237**(3): p.385-99. doi: 10.1002/ar.1092370312. PMID: 8291692.

7. Kirby ML, Stewart DE. Neural crest origin of cardiac ganglion cells in the chick embryo: identification and extirpation. Dev Biol. 1983 Jun;**97**(2): p.433-43. doi: 10.1016/0012-1606(83)90100-8. PMID: 6852374.

8. Tang W, Martik ML, Li Y, Bronner ME. Cardiac neural crest contributes to cardiomyocytes in amniotes and heart regeneration in zebrafish. Elife. 2019 Aug 8;**8**: e47929. doi: 10.7554/eLife.47929. PMID: 31393264; PMCID: PMC6721792.

9. Kirby ML, Turnage KL 3rd, Hays BM. Characterization of conotruncal malformations following ablation of "cardiac" neural crest. Anat Rec. 1985 Sep;**213**(1): p.87-93. doi: 10.1002/ar.1092130112. PMID: 4073565.

10. Bockman DE, Redmond ME, Waldo K, Davis H, Kirby ML. Effect of neural crest ablation on development of the heart and arch arteries in the chick. Am J Anat. 1987 Dec;**180**(4): p.332-41. doi: 10.1002/aja.1001800403. PMID: 3425561.

11. Nishibatake M, Kirby ML, Van Mierop LH. Pathogenesis of persistent truncus arteriosus and dextroposed aorta in the chick embryo after neural crest ablation. Circulation. 1987 Jan;**75**(1): p.255-64. doi: 10.1161/01.cir.75.1.255. PMID: 3791607.

12. Waldo K, Zdanowicz M, Burch J, Kumiski DH, Stadt HA, Godt RE, Creazzo TL, Kirby ML. A novel role for cardiac neural crest in heart development. J Clin Invest. 1999 Jun;**103**(11): p.1499-507. doi: 10.1172/JCI6501. PMID: 10359559; PMCID: PMC408374

13. Farrell M, Waldo K, Li YX, Kirby ML. A novel role for cardiac neural crest in heart development. Trends Cardiovasc Med. 1999 Oct;**9**(7): p.214-20. doi: 10.1016/s1050-1738(00)00023-2. PMID: 10881754.

14. Keyte A, Hutson MR. The neural crest in cardiac congenital anomalies. Differentiation. 2012 Jul;**84**(1): p.25-40. doi: 10.1016/j.diff.2012.04.005. Epub 2012 May 15. PMID: 22595346; PMCID: PMC3389200.

15. Neeb Z, Lajiness JD, Bolanis E, Conway SJ. Cardiac outflow tract anomalies. Wiley Interdiscip Rev Dev Biol. 2013 Jul;**2**(4): p.499-530. doi: 10.1002/wdev.98. Epub 2013 Feb 19. PMID: 24014420; PMCID: PMC4021394.

16. Keyte AL, Alonzo-Johnsen M, Hutson MR. Evolutionary and developmental origins of the cardiac neural crest: building a divided outflow tract. Birth Defects Res C Embryo Today. 2014 Sep;**102**(3): p.309-23. doi: 10.1002/bdrc.21076. Epub 2014 Sep 16. PMID: 25227322; PMCID: PMC4288758.

17. Gandhi S, Ezin M, Bronner ME. Reprogramming Axial Level Identity to Rescue Neural-Crest-Related Congenital Heart Defects. Dev Cell. 2020 May 4;**53**(3): p.300-315. e4. doi: 10.1016/j.devcel.2020.04.005. PMID: 32369742; PMCID: PMC7255058.

18. Gross JB, Berning D, Phelps A, Luc H. An analysis of lateralized neural crest marker expression across development in the Mexican tetra, *Astyanax mexicanus*. Front Cell Dev Biol. 2023 Feb 15;**11**: 1074616. doi: 10.3389/fcell.2023.1074616. PMID: 36875772; PMCID: PMC9975491.

19. HAMBURGER V, HAMILTON HL. A series of normal stages in the development of the chick embryo. J Morphol. 1951 Jan;**88**(1): p.49-92. PMID: 24539719.

20. Mahle WT, Martinez R, Silverman N, Cohen MS, Anderson RH. Anatomy, echocardiography, and surgical approach to double outlet right ventricle. Cardiol Young. 2008 Dec;18 Suppl **3**: p.39-51. doi: 10.1017/S1047951108003284. PMID: 19094378.

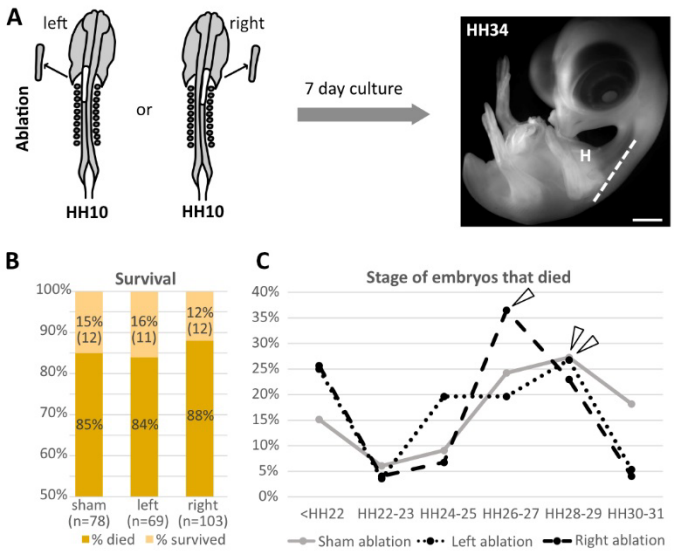

Figure 1: Experimental design and survival rates. A. Experimental design for surgical ablations of unilateral cardiac neural crest. Dashed line shows angle of sectioning. Scale bar = 5 mm. H = heart. **B.** Survival rate for all ablated and sham-ablated embryos after 7 days of culture following surgery/sham surgery (to at least HH32). **C.** HH stage at death of embryos that did not make it to HH32. Arrowheads point to stage at which deaths peaked for sham-, left- and right-ablated embryos.

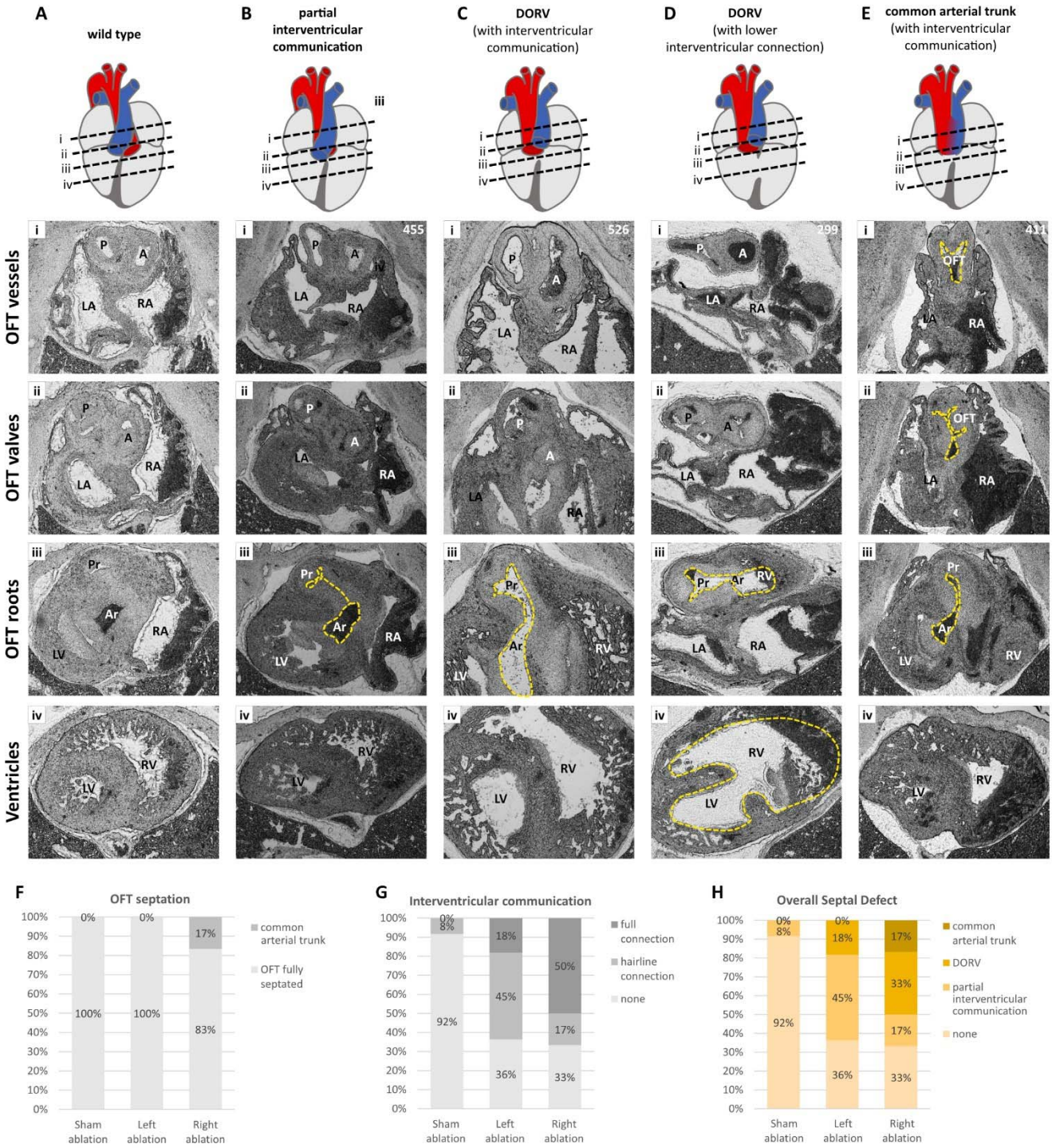

Figure 2: Septal defects. A-E. Serial cross-sections through hearts representing different heart defects. Corresponding diagrams of the hearts show levels for each section. Sections within a column come from a single heart. Sections from five hearts are shown. Yellow dashed lines show communication between left and right sides of the heart that should not be present at this stage of development. **A.** Wild type. **B.** Partial interventricular communication. **C-D.** DORV. **E.** Common Arterial Trunk (PTA). **F.** Incidence of embryos with abnormal OFT septation. **G.** Incidence of embryos with full or partial interventricular communication. **H.** Frequency of defects affecting septation. A = aorta, P = pulmonary trunk, OFT = outflow tract, LA = left atrium, RA = right atrium, LV = left ventricle, RV = right ventricle, Pr = pulmonary root, Ar = Aortic root.

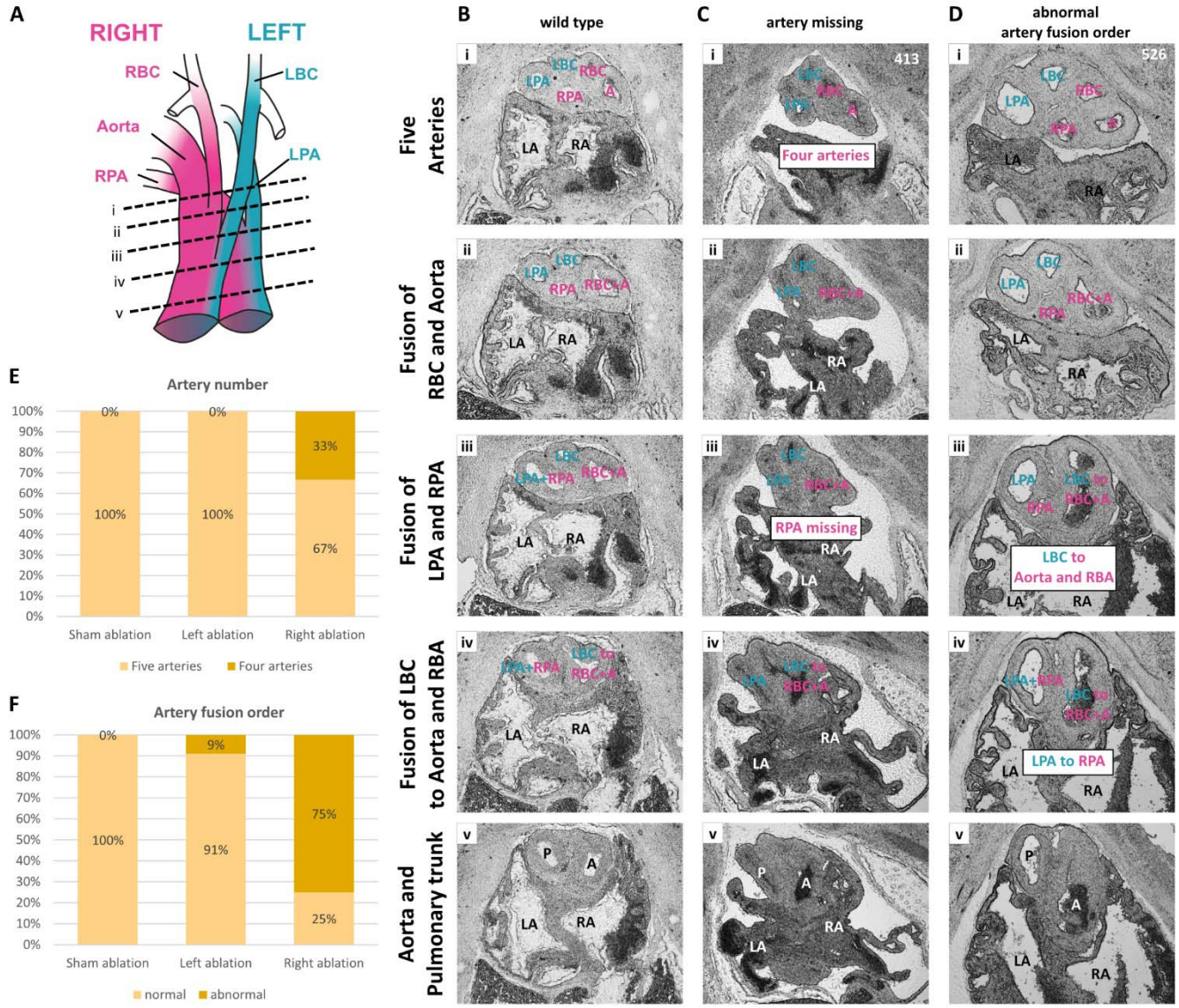

Figure 3: Artery defects. A. Diagram of arteries of the heart, illustrating levels of sections shown in B-D. **B-D.** Serial cross-sections through the heart's arteries, representing different defects in artery development. Sections within a column come from a single heart. Sections from three hearts are shown. **B.** Wild type. **C.** Artery missing. **D.** Abnormal fusion order of arteries along the proximal-distal axis. **E.** Incidence of embryos with a missing artery. **F.** Incidence of embryos with an abnormal artery fusion order. LBC/RBC = left and right brachiocephalic arteries, LPA and RPA = left and right pulmonary arteries, A = aorta, P = pulmonary trunk, LA = left atrium, RA = right atrium.

Embryo	Ablation type	Stage at ablation		Stage post culture	Septation defect	OFT septal defects		Interventricular communication		Arteries		Other abnormalities			
		Somite number	HH			connection of A and P	level	Type	level	number	fusion order	organs exposed	spina bifida	tail	eyes
310	right	9.5	HH10	HH34+	**Double outlet right ventricle**	none	na	**full**	OFT roots	5	**abnormal**	**yes**	no	normal	normal
317	right	9.5	HH10	HH34	**partial**	none	na	**hairline**	OFT roots	5	**abnormal**	**yes**	no	normal	normal
390	right	10	HH10	HH33+	**Double outlet right ventricle**	none	na	**full**	OFT roots	**4**	**abnormal**	**yes**	no	normal	normal
411	right	10	HH10	HH33	**Common arterial trunk**	**yes**	above OFT valves	**full**	OFT roots	**4**	**abnormal**	no	no	normal	normal
413	right	10.25	HH10	HH34	none	none	na	none	na	**4**	**abnormal**	no	no	normal	normal
423	right	10.5	HH10+	HH33	**partial**	none	na	**hairline**	OFT roots	5	normal	no	no	**stumpy**	normal
435	right	10.25	HH10	HH34	none	none	na	none	na	5	normal	no	no	normal	normal
459	right	10.75	HH10+	HH32	none	none	na	none	na	5	**abnormal**	no	no	normal	normal
492	right	10	HH10	HH34+	**Double outlet right ventricle**	none	na	**full**	OFT roots	5	normal	no	no	**absent**	normal
504	right	10.5	HH10+	HH34+	none	none	na	none	na	5	**abnormal**	**yes**	no	normal	normal
526	right	10.75	HH10+	HH34+	**Double outlet right ventricle**	none	na	**full**	OFT roots	5	**abnormal**	no	no	normal	normal
530	right	10.5	HH10+	HH33	**Common arterial trunk**	**yes**	at level of OFT valves	**full**	OFT roots	**4**	**abnormal**	no	**yes**	normal	normal
242	left	10	HH10	HH32	none	none	na	no	na	5	normal	no	**yes**	**absent**	**both-small**
285	left	10.5	HH10+	HH32	**Double outlet right ventricle**	none	na	**full**	OFT roots	5	**abnormal**	**yes**	**yes**	**stumpy**	**both-small**
299	left	10.5	HH10+	HH34+	**Double outlet right ventricle**	none	na	**full**	OFT roots to ventricles	5	normal	**yes**	no	normal	normal
300	left	10.5	HH10+	HH34	none	none	na	no	na	5	normal	no	no	normal	normal
409	left	10.75	HH10+	HH33	none	none	na	no	na	5	normal	no	no	normal	normal
412	left	10.75	HH10+	HH34	**partial**	none	na	**hairline**	OFT roots	5	normal	**yes**	no	normal	normal
414	left	10.5	HH10+	HH34	**partial**	none	na	**hairline**	OFT roots	5	normal	no	no	normal	normal
455	left	9.75	HH10	HH33	**partial**	none	na	**hairline**	OFT roots	5	normal	no	**yes**	normal	normal
495	left	9.75	HH10	HH34+	**partial**	none	na	**hairline**	OFT roots	5	normal	no	no	normal	normal
503	left	9.5	HH10	HH32	**partial**	none	na	**hairline**	OFT roots	5	normal	no	no	normal	normal
516	left	9.5	HH10	HH33	none	none	na	no	na	5	normal	no	no	**stumpy**	normal
Sham7	sham	na	na	HH32+	**partial**	none	na	**hairline**	OFT roots	5	normal	no	no	normal	normal
Sham18	sham	na	na	HH32+	none	none	na	none	na	5	normal	no	no	normal	normal
Sham27b	sham	na	na	HH34+	none	none	na	none	na	5	normal	no	no	normal	normal
Sham32	sham	na	na	HH34+	none	none	na	none	na	5	normal	no	no	normal	normal
Sham37	sham	na	na	HH35	none	none	na	none	na	5	normal	no	no	normal	normal
Sham40	sham	na	na	HH34	none	none	na	none	na	5	normal	no	no	normal	normal
Sham44	sham	na	na	HH34+	none	none	na	none	na	5	normal	no	no	normal	normal
Sham51	sham	na	na	HH33	none	none	na	none	na	5	normal	no	no	normal	normal
Sham64	sham	na	na	HH34	none	none	na	none	na	5	normal	**yes**	**yes**	normal	normal
Sham68	sham	na	na	HH33	none	none	na	none	na	5	normal	no	no	normal	normal
Sham75	sham	na	na	HH34	none	none	na	none	na	5	normal	no	no	normal	normal
Sham78	sham	na	na	HH33	none	none	na	none	na	5	normal	no	no	normal	normal

Table 1: All embryos. Information on embryo stage (at surgery and post-culture), observed cardiac defects and their locations, and other non-cardiac defects, identified for each processed embryo.