Running title: DEK Expression in the Uterus
Article title: Upregulation of DEK Expression in Uterine Myomas and Cervical Cancer as a Potential Prognostic Factor

Amelia Janiak [a], Xinyue Liu [a], Renata Koviazina [a], PengCheng Tan MS [a], Ferdinand Kappes PhD [a], Fangrong Sheng MD PhD [b], Felice Petraglia MD PhD [c], Chiara Donati PhD [c], Anastasia Tsigkou PhD [a]

a. Division of Natural and Applied Sciences, Duke Kunshan University, Kunshan, China
b. No 1 Affiliated Hospital Suzhou University, Department of Gynecology, Suzhou, China
c. Obstetrics and Gynecology, Department of Experimental and Clinical Biomedical Sciences, Obstetrics and Gynecology, University of Florence, Florence, Italy

Corresponding Author: Anastasia Tsigkou
Phone: +86 13451616704
Email: anastasia.tsigkou@dukekunshan.edu.cn
Co-corresponding Author: Fangrong Sheng
Email: 1597803637@qq.com

Article type: Laboratory based study

Funding Statement: This research was supported by Duke Kunshan University Undergraduate Studies through the Summer Research Scholars program and the Student Experiential Learning Fellow program, the Seed Wang foundation, and discretionary funds.

Disclosure Statement: None

CRediT Authorship Contribution Statement:

- Amelia Janiak: Conceptualization, Methodology, Formal Analysis, Investigation, Project Administration, Visualization, Writing - original draft
- Xinyue Liu: Validation
- Renata Koviazina: Writing - review & editing
- PengCheng Tan: Methodology, Investigation, Supervision, Validation, Writing – review & editing
- Ferdinand Kappes: Conceptualization, Methodology, Supervision, Writing - review & editing
- Fangrong Sheng: Resources, Writing - review & editing
- Felice Petraglia: Writing - review & editing
- Chiara Donati: Writing - review & editing

- Anastasia Tsigkou: Conceptualization, Methodology, Supervision, Project Administration, Funding Acquisition, Writing – review & editing

Attestation Statement:

- Data regarding any of the subjects in the study has not been previously published unless specified.
- Data will be made available to the editors of the journal for review or query upon request.

Word Count: 268 words for abstract and 3480 words for text

Capsule: DEK is significantly upregulated in cervical cancer tissues and moderately expressed in uterine myomas, suggesting its potential as a prognostic factor and biomarker for gynecological tumors.

Abstract

Objective: To investigate the role of DEK in uterine myomas and cervical cancer as a potential prognostic factor

Design: Laboratory based study

Subjects: Chinese women from the department of gynecology at No 1 Suzhou University Affiliated Hospital in Suzhou, China, experiencing menstrual and intermenstrual bleeding and intermenstrual pelvic pain. Ten patients underwent surgery for uterine myomas and four surgery for cervical cancer

Main Outcome Measures: Quantification of DEK protein expression in normal uterine tissue, uterine myoma tissue, and cervical cancer tissue using Western blot and immunohistochemistry; Analysis of DEK mRNA levels in the identical tissue types using Quantitative Real-Time Polymerase Chain Reaction; Patient symptom ratings using visual analog scores.

Results: Immunohistochemical analysis revealed significant upregulation of DEK protein in cervical carcinomas, moderate expression in uterine myomas, and negligible expression in normal uterine tissues. Western blot analysis supported these findings, showing high DEK protein levels in cervical carcinomas, intermediate levels in uterine myomas, and low levels in normal uterine tissues. qRT-PCR analysis demonstrated elevated DEK mRNA expression in uterine myomas compared to both normal uterine tissues and cervical carcinomas, suggesting transcriptional upregulation in uterine myomas. Statistical analysis with one-way ANOVA test, Kruskal-Wallis H test and following post-hoc tests confirmed significant differences in DEK expression among the groups.

Conclusion: Significant upregulation of DEK in cervical cancer tissues and uterine myomas, and negligible levels in normal uterine tissues suggest DEK's involvement in tumor development and

suppression. Further research is needed to elucidate DEK's mechanisms in gynecological tumorigenesis and its potential as an early biomarker, addressing critical need in women's health.

Keywords: DEK oncogene, uterine myoma, cervical cancer, gynecological cancers, fertility

Introduction

Tumors of the female reproductive system are very common, including uterine myomas as the most frequent benign tumor, while cervical cancer the most common malignancy (1, 2). Uterine myomas, also known as fibroids, arise from the overgrowth of smooth muscle layer and connective tissue in the uterus and can be found in about 50% of women in reproductive age (1, 3). While benign, they can cause symptoms such as pelvic pain, heavy menstrual bleeding and reproductive issues (4, 5). Cervical cancer, on the other hand, originates in the cells of the cervix and poses a serious threat if not detected and treated early (6).

Due to the prevalence of these tumors and their impact on the quality of life, encompassing not only physical health but also emotional and psychological well-being, both of these conditions pose substantial global health challenges (7). For instance, women with endometriosis, a chronic gynecological condition where tissue similar to the lining inside the uterus begins to grow outside of the uterus and often co-occurs with leiomyoma, frequently experience severe headaches, with a significant proportion receiving a diagnosis of migraine that precedes the diagnosis of endometriosis (8, 9).

As demographics shift and lifestyles change, these cancers are predicted to significantly increase in incidence (10). To address this concern and the need for new screening methods that could allow for tumor detection at an early stage, current research is increasingly investigating novel agents targeting DNA damage response (DDR). DDR comprises a set of signaling pathways for the detection and repair of DNA damage, including machinery mediating DNA repair, cell cycle regulation, replication stress responses and apoptosis (11). Indeed, the progression of cervical cancer is associated with an increased genetic instability, which is primarily caused by the DNA damage and breakage (12). Enhanced comprehension of DDR processes offers potential for cancer treatment by elucidating cellular and molecular signaling mediators pivotal in tumor development and progression.

One such promising marker within this context is the rather under-investigated, multifunctional chromatin-associated oncogene DEK. The DEK gene is located in the chromosome 6p22.3 band and encodes for a 43 kDa, highly conserved nuclear protein predominantly expressed in malignant and actively dividing cells (13, 14). Initially recognized for its role in chromatin organization and gene regulation, DEK has been implicated in various cellular processes such as DNA damage repair, RNA transcriptional regulation, mRNA splicing, and DNA replication (15, 16, 17, 18, 19, 20). Recent studies have also demonstrated that elevated DEK levels promote proliferation, motility, invasion, and tumorigenesis (19, 21, 22), prompting investigations into various cancer types, which showed that DEK is upregulated in acute myeloid leukemia,

retinoblastoma, glioblastoma, melanoma, and in a growing number of other tumor types (23, 24). In addition, suppressing DEK and nuclear factor kappa B has been shown to have the potential to arrest the cell cycle in the G0/G1 phase, resulting in fewer cells in the G2/M phase, and increased apoptosis and cell senescence in CaSki cervical cancer cells, suggesting that DEK may have an oncogenic function in the development and progression of tumors (25). Similar conclusions were drawn by Xu et al., who confirmed DEK as an oncoprotein in cervical cancer, correlating with FIGO staging and tumor type, and demonstrated that silencing DEK inhibited cancer cell proliferation, migration, and invasion by downregulating Wnt/β-catenin and MMP-9, increasing GSK-3β activity, and impairing tumorigenicity in a mouse xenograft model (26).

The oncogenic role of DEK is part of a broader mechanism where the buildup of genetic damage, including the activation of proto-oncogenes and the inactivation of tumor-suppressor genes, propels the transformation of healthy cells into malignant ones (27). Proto-oncogenes, such as DEK, which regulate cell differentiation and proliferation, can cause neoplastic transformation if mutated, a process known as activation (28). Activation occurs through various genetic pathways such as transduction, insertional mutagenesis, amplification, point mutations, and chromosomal translocations, resulting in deregulated proto-oncogenes that provide a proliferative benefit to the cell (28). As on oncogene, DEK has been shown to promote tumorigenesis by interfering with cell division, affecting DNA repair, inhibiting cell differentiation, senescence, apoptosis, and cooperating with other oncogenes (15, 29). Supporting this, studies have demonstrated DEK's significant role in tumorigenesis. Han et al. discovered that DEK is significantly involved in the proliferation of serous ovarian cancer cells, with high DEK expression levels correlating with an increased Ki-67 proliferation index (30), while Privette et al. demonstrated that DEK oncogene stimulates cellular proliferation via Wnt signaling in Ron receptor-positive breast cancers (31).

While DEK overexpression is frequently linked to malignant tumors, it is also observed in various benign tumors. For instance, studies with mouse models have shown that DEK knockout mice are partially resistant to the formation of benign skin papillomas, indicating DEK's role in early tumorigenesis and involvement in suppressing tumor growth (32). However, other studies, such as Riveiro-Falkenbach et al., have found negligible DEK expression in benign lesions, presenting conflicting evidence about DEK's role in non-malignant neoplasms (33). Additionally, research on DEK expression in melanocytic lesions found low or no DEK expression in most benign nevi and melanoma in situ (34). Despite these mixed findings, there is still limited information on DEK in benign tumors, and further research could provide valuable insights into its role in these tumors.

Recognizing the critical role of DNA damage repair pathways in cancer development along with the reported involvement of DEK in tumorigenesis and DNA repair, and considering the limited research on DEK in benign tumors, we sought to determine DEK's role in both benign gynecological tumors and malignant gynecological cancer. Immunohistochemical, Western blot, and Quantitative Real Time Polymerase Chain Reaction (qRT-PCR) analyses collectively

showed significant DEK upregulation in cervical carcinomas, moderate expression in uterine myomas, negligible expression in normal uterine tissues, and confirmed statistically significant differences in expression patterns among these tissues.

Materials and Methods

Tissue Samples

The study was approved by the IRB of Duke Kunshan University, and prior to surgery, informed written consent was obtained from all patients. Tissue samples of ten women with uterine myomas and four with cervical cancer were obtained during surgery, immediately frozen in liquid nitrogen, and stored at -80°C for investigation in this study. The pathological stage and histological subtype were determined for each surgical specimen according to the 1988 International Federation of Gynecology and Obstetrics (FIGO) criteria and were diagnosed in FIGO stage I, II (38).

Immunohistochemical Analysis

Immunohistochemical Studies of Tissue Explants

Immunohistochemical staining for DEK (1:1000, DEK (Abcam) proteins was performed using formalin-fixed and paraffin-embedded tissue slides, a detection kit (DAKO ChemMate, DAKO, Glostrup, Denmark) and a semi-automated stainer (DAKO TechMate, DAKO, Glostrup, Denmark) according to the specifications of the manufacturer. For antigen retrieval the slides were treated in a PT Link module (DAKO, Glostrup, Denmark) using the EnVision™ FLEX Target Retrieval Solution, Low pH (DAKO, Glostrup, Denmark). To quantify DEK expression immunohistochemical staining analysis was conducted. The IRS score was calculated by multiplication of the optical staining intensity (graded as 0, no staining; 1, weak; 2, moderate; and 3, strong staining) and the percentage of the positive stained cells (0, no staining; 1, <10%; 2, 11-50%; 3, 51-80%; and 4, >81% of the cells). The expression level of DEK was then categorized into three levels: negative (−), positive (+), and strongly positive (++).

Western Blot Analysis

Protein Extraction

Tissues were dissected on ice and transferred to microcentrifuge tubes. For 100 mg of tissue, 400 µL of ice-cold RIPA lysis buffer with PMSF (Beyotime, P0013B) was added, and the tissue was homogenized using a pestle and a mortar. Additional 600 µL of lysis buffer was added during the homogenization process. The sample was kept on ice and agitated on an orbital shaker for 1.5 hours. Subsequently, the tubes were centrifuged at 4°C. The supernatant containing extracted proteins was collected into a fresh tube and stored at -80°C.

Western Blot

Total protein concentration was determined using the Enhanced BCA Protein Assay Kit (Beyotime, China, P0009). The proteins and deionized water were mixed to make sure each sample had the same concentration with a total of 20 μL or 30 μL. 5 μL of 5x SDS-PAGE Loading Buffer (NCM Biotech,WB2001) was then added to each sample, followed by vortex, incubation at 95°C for 5 min and centrifugation at 1,000g for 10 seconds. Total protein (16 μg per lane) was separated using a SDS-polyacrylamide gel and transferred onto a nitrocellulose membrane. SeeBlue Plus2 Pre-Stained Standard (Invitrogen, Karlsruhe, Germany) was used as a marker. The membranes were incubated with primary anti-DEK (rabbit, 1:2000; Abcam) and anti-GAPDH (rabbit, 1:1000; Beyotime) followed by incubation with the corresponding secondary antibodies (HRP-conjugated goat anti-rabbit IgG, 1:5000, MULTISCIENCE). The bands were visualized by incubating the membrane with ECL solution (Tanon™ High-sig ECL Western Blotting Substrate (Biotanon,180-501) and examined in a pre-cooled chemiluminescence imaging system (Bio-Rad Laboratories, CA, USA) according to the manufacturer's instructions. Image analysis was performed with the ImageJ to obtain quantifiable DEK protein expression levels, normalized to the expression of the reference gene (GAPDH).

Statistical Analysis

To determine the statistical significance of DEK protein expression differences among the three tissue types, two statistical tests were utilized. First, one-way ANOVA test was performed to determine if there were any overall significant differences in DEK expression among the groups. Following a significant ANOVA result, post-hoc Tukey's Honest Significant Difference (HSD) test was conducted to identify specific pairwise differences between the groups.

qRT-PCR Analysis

RNA Extraction

Tissue samples stored at -80°C were crushed until a fine powder using a mortar and a pestle. Approximately 100 mg powder was recovered from each sample and placed into a new cold microtube. Then, RNA was extracted using the TRIzol reagent (ThermoFisher Scientific, 15596026) protocol provided by the manufacturer, using TRIzol reagent, chloroform (Titan,G75915B) and isopropanol (Titan, G75885B). After RNA extraction, 20 μL of DEPC water (DNase, RNase free) (damas life, G8010-500ml) was added to the sample and it was stored at -80°C.

cDNA Synthesis

cDNA synthesis was carried out using HiScript II 1st strand cDNA synthesis kit (Vazyme, R211-02). About 500 ng of total RNA were reverse transcribed with 200 U/μl of M-MLV reverse transcriptase (Invitrogen), RNase Out, 150 ng random hexamers and 10 mM dNTPs according to

the manufacturer's instructions. RNA was denatured at 65°C for 5 min and subsequently kept on ice for 1 min. After adding the enzyme to the RNA primer mixes, samples were incubated for 10 min at 25°C to allow annealing of the random hexamers. Reverse transcription was performed at 37°C for 50 min followed by inactivation of the reverse transcriptase at 70°C for 15 min.

qRT-PCR

qRT-PCR was utilized in human tissue samples to analyze gene expression levels of two proteins: DEK and GAPDH. Relative quantification of transcription levels was carried out by real-time PCR analyses using the Applied Biosystems 7300 real-time PCR system (Applied Biosystems) and ChamQ universal SYBR qPCR Master Mix kit (Vazyme,Q711-02) according to the manufacturer's instructions. Sequences for primers used in the procedure were found in the scientific literature and commercially synthesized by Sangon Biotech. Primer sequences for DEK were: 1) Forward: 5'-TGGGTCAGTTCAGTGGCTTTCC-3', 2) Reverse: 5'-CTCTCCAAATCAAGAACCTCACAG-3', and for GAPDH were: 1) Forward: 5'-ACAACTTTGGTATCGTGGAAGG-3', 2) Reverse: 5'-GCCATCACGCCACAGTTTC-3'. The amplification reaction mixture (total volume of 20 μL) contained 2 × ChamQ Universal SYBR qPCR Master Mix, 0.4 μL of forward primer (10 μM), 0.4 μL of reverse primer (10 μM), 2 μL of template cDNA, and DEPC-H2O (added to the final volume). Incubation conditions were: 1) initial denaturation: 95°C/30 sec; 2) cycling reaction: 40 cycles of 95°C/10 sec and 60°C/60 sec; 3) melting curve: 95°C/15 sec, 60°C/60 sec, 95°C/15 sec.

Statistical Analysis

The results of the qRT-PCR were expressed as 2^-ΔΔCt, which is the fold change in gene expression relative to the control (normal uterine tissue), calculated as the difference between the delta cycle threshold (ΔCt) of the target gene and the ΔCt of the reference gene (GAPDH). To compare gene expression patterns, relative gene expression was log-transformed to normalize and compress data, enabling clearer interpretation and comparison across samples, and then graphed in GraphPad Prism 10. Statistical analysis was conducted using Kruskal-Wallis H test and unpaired Mann-Whitney U test. Kruskal-Wallis H test was employed to assess the presence of overall differences in expression among normal uterine tissue, uterine myoma, and cervical carcinoma samples, while unpaired Mann-Whitney U test was used to further examine and identify specific group differences.

Results

The median patient's age at the time of diagnosis was 44. Cervical intraepithelial neoplasia (CIN) of different stages were obtained (CIN 1 = 3, CIN 2 = 5, and CIN 3 = 2). Squamous cervical cancer samples of well-differentiated (grade 1; n = 5), moderately differentiated (grade 2; n = 2) and poorly differentiated (grade 3; n = 3) grading were analyzed. The clinicopathological features of uterine myomas are summarized in Table I.

Immunohistochemical Analysis

Expression levels of DEK protein in normal uterine, uterine myoma and cervical carcinoma tissue samples were determined via immunohistochemical counterstaining. Representative immunohistochemical images are shown in Figure 1A-E and the IRS scores are presented in Figure 1F. The data indicates a significant upregulation in DEK protein expression in cervical cancer tissue, with a high final IRS score of 12, indicating strong positive expression. In uterine myoma tissue, DEK expression is present but at a lower level, with a final IRS score of 2, indicating positive expression. Normal tissue shows little to no DEK expression, with a final IRS score of 0.

Western Blot Analysis

Western blotting was used to investigate DEK protein expression levels in normal uterine tissue, uterine myoma tissue and cervical cancer tissue samples. The results were analyzed using a computer program (ImageJ) and were normalized to GAPDH expression.

As shown in Figure 2, relative DEK protein expression level is highest in cervical cancer tissue (~5.7), intermediate in uterine myoma tissue (~4.0), and lowest in normal uterine tissue (~1.0). Statistical analysis with ANOVA test showed a significant difference in DEK expression among the tissue types ($p = 0.0038$). Post-hoc analysis with Tukey's HSD test confirmed significant differences between normal and uterine myoma tissues ($p < 0.05$) and between normal and cervical cancer tissues ($p < 0.01$), but not between uterine myoma and cervical cancer tissues ($p > 0.23$).

qRT-PCR

To analyze DEK expression at the transcriptional level, mRNA was extracted from samples of cervical cancer, uterine myomas and normal uterine tissue, transcribed into cDNA, and followed by qRT-PCR analysis.

Figure 3 demonstrates that in normal uterine tissue, relative DEK mRNA expression is relatively low, with an average below 1. The uterine myoma tissue exhibits a significantly higher relative expression, with an average close to 3, indicating an upregulation in this tissue type. In cervical cancer tissue, the relative DEK mRNA expression returns to a lower level, similar to that of normal uterine tissue, averaging around 0.3. These results suggest that in contrast to protein levels, DEK mRNA is significantly upregulated in uterine myoma tissue compared to both normal uterine and cervical cancer tissues, which show similar expression levels. Statistical analysis using the Kruskal-Wallis H test demonstrated statistically significant differences in DEK expression levels among the three tissue types ($p = 0.005$). This analysis was followed by unpaired Mann-Whitney U test, which confirmed statistically significant differences between uterine myoma and cervical cancer tissues ($p = 0.002$), but not between normal and uterine myoma tissues ($p = 0.3$) or between normal uterine and cervical cancer tissues ($p = 0.8$).

Discussion

Our study's findings provide compelling evidence for the differential expression of DEK in normal uterine tissue, uterine myomas, and cervical cancer tissues, suggesting DEK's potential role in gynecological tumorigenesis and as a prognostic marker. Immunohistochemical analysis shows significant upregulation of DEK in cervical cancer tissues, moderate expression in uterine myomas, and negligible expression in normal uterine tissues. Western blot analysis, normalized to GAPDH, corroborates these findings with DEK protein expression highest in cervical cancer tissues, lower in uterine myomas, and lowest in normal tissues. qRT-PCR analysis indicates that DEK mRNA is significantly upregulated in uterine myomas compared to both normal and cervical cancer tissues, which show similarly low expression levels. Statistical analysis for qRT-PCR and Western blot data revealed significant differences in variances among the groups using one-way ANOVA and Kruskal-Wallis H tests, with majority of post-hoc tests (unpaired Mann-Whitney U and Tukey's HSD) also being statistically significant.

These findings suggest that DEK plays a distinct role in different gynecological tissues and tumor types. The marked upregulation of DEK in cervical cancer tissues underscores its potential as an oncogene. DEK's overexpression in cervical cancer cells aligns with previous studies demonstrating its involvement in promoting cell proliferation, motility, invasion, and tumorigenesis (19, 21, 22, 26). This upregulation may contribute to the genetic instability characteristic of cervical cancer by interfering with DNA repair mechanisms, cell cycle regulation, and apoptosis pathways. The role of DEK in these processes highlights its potential as a therapeutic target for cervical cancer treatment, where inhibiting DEK could suppress tumor progression and enhance the efficacy of existing therapies.

The intermediate levels of DEK expression in uterine myomas suggest that DEK may act as a tumor suppressor in these benign tumors. The upregulation of DEK mRNA in uterine myomas compared to normal uterine tissues and cervical cancer tissues indicates a unique regulatory mechanism at the transcriptional level in benign tumors. This elevated DEK expression in myomas may be linked to a compensatory response to control cellular proliferation and maintain tissue integrity, counteracting the potential for malignant transformation. The negligible expression of DEK in normal uterine tissues aligns with its predominant expression in rapidly dividing and cancerous cells, as previously reported (14). The low levels of DEK in normal tissues suggest that its upregulation is associated with pathological conditions, reinforcing the concept that DEK functions as an oncogene or tumor promoter in abnormal cellular environments.

Our study's differential expression patterns of DEK in normal, benign, and malignant gynecological tissues suggest that DEK could serve as a valuable biomarker for DNA damage in gynecological conditions, enabling early tumor detection and risk assessment. By monitoring DEK expression levels, it might be possible to detect early genetic instability associated with the onset of fibroids and cervical cancer. This capability opens up new possibilities for early

screening methods at the gene level, enabling timely intervention before tumors progress to advanced stages. Specifically, assessing DEK expression could help identify women at higher risk for developing these conditions, facilitating early diagnosis and improving patient outcomes. Incorporating DEK as a biomarker in early screening protocols, as suggested by other studies for various cancer types (35, 36, 37), could significantly advance the early detection and management of gynecological tumors, addressing a crucial need in women's health.

These findings also underscore the need for further research to elucidate the precise mechanisms by which DEK contributes to gynecological tumorigenesis. Such research could focus on the interplay between DEK, p53, TGF-β, and S1P with particular attention to how DEK influences p53 and TGF-β receptor stability as well as their downstream signaling (38, 39). Understanding these interactions is important since TGF-β signaling plays a critical role in cancer progression, influencing diverse cellular processes such as cell growth, differentiation, apoptosis, motility, angiogenesis, and immune responses, p53, one of the most important tumor suppressors, is inactivated in about half of all malignancies, and S1P has been implicated in tumor angiogenesis (40, 41, 42).

It would also be intriguing to explore whether DEK exerts differential effects on hormones such as estrogen, progesterone, and androgen in benign versus malignant gynecological tumors, considering these hormones' established roles in regulating DEK expression and activity through various signaling pathways (43). For instance, studies show that estrogen can directly bind to specific receptors in the nucleus, leading to enhanced transcription of the DEK gene (43). This investigation would be particularly compelling given the key roles of these hormones in uterine myomas. For example, progesterone receptor isoform B mRNA levels in uterine myoma tissue have been found to correlate with tumor number and correlate inversely with intermenstrual bleeding and dysmenorrhea intensity, suggesting a role in uterine myoma growth and symptom attenuation (4).

Declaration of generative AI and AI-assisted technologies in the writing process

During the preparation of this work the authors used ChatGPT in order to improve the readability and language of the manuscript. After using this tool, the authors reviewed and edited the content as needed and take full responsibility for the content of the published article.

Conclusions

In conclusion, the significant upregulation of DEK in cervical cancer tissues, intermediate expression in uterine myomas, and negligible levels in normal uterine tissues highlight DEK's potential role in tumor development and progression. These findings underscore the need for further research to elucidate the precise mechanisms by which DEK contributes to gynecological tumorigenesis and to explore its potential as a biomarker for early screening, thereby advancing the early detection and management of gynecological tumors and addressing a crucial need in women's health.

References

1. Kamthorn Pruksananonda, Artisa Wasinarom, Apiwat Mutirangura. Epigenetics in Human Reproduction and Gynecologic Diseases. Elsevier eBooks. 2018 Jan 1;781–802.
2. Weiderpass E, Labrèche F. Malignant Tumors of the Female Reproductive System. Safety and Health at Work. 2012 Sep;3(3):166–80.
3. Tsigkou A, Reis FM, Ciarmela P, Lee MH, Jiang B, Tosti C, et al. Expression levels of myostatin and matrix metalloproteinase 14 mRNAs in uterine leiomyoma are correlated with dysmenorrhea. Reprod Sci. 2015 Dec;22(12):1597-602.
4. Tsigkou A, Reis FM, Lee MH, Jiang B, Tosti C, Centini G, et al. Increased progesterone receptor expression in uterine leiomyoma: correlation with age, number of leiomyomas, and clinical symptoms. Fertil Steril. 2015 Jul 1;104(1):170-5.
5. Kim JJ, Sefton EC. The role of progesterone signaling in the pathogenesis of uterine leiomyoma. Molecular and Cellular Endocrinology. 2012 Jul;358(2):223–31.
6. Cohen PA, Jhingran A, Oaknin A, Denny L. Cervical cancer. The Lancet. 2019 Jan;393(10167):169–82.
7. Hersch J, Juraskova I, Price M, Mullan B. Psychosocial interventions and quality of life in gynaecological cancer patients: a systematic review. Psychooncology. 2009 Aug;18(8):795-810.
8. Nezhat C, Li A, Abed S, Balassiano E, Soliemannjad R, Nezhat A, et al. Strong Association Between Endometriosis and Symptomatic Leiomyomas. JSLS : Journal of the Society of Laparoendoscopic Surgeons. 2016;20(3):e2016.00053.
9. Pasquini B, Seravalli V, Vannuccini S, La Torre F, Geppetti P, Iannone L, et al. Endometriosis and the diagnosis of different forms of migraine: an association with dysmenorrhoea. Reprod Biomed Online. 2023 Jul 1;47(1):71-6.
10. Sung H, Ferlay J, Siegel RL, Laversanne M, Soerjomataram I, Jemal A, et al. Global cancer statistics 2020: Globocan estimates of incidence and mortality worldwide for 36 cancers in 185 countries. CA Cancer J Clin. 2021 Feb 4;71(3):209–49.
11. Pilié PG, Tang C, Mills GB, Yap TA. State-of-the-art strategies for targeting the DNA damage response in cancer. Nat Rev Clin Oncol. 2018 Oct 24;16(2):81–104.
12. Adam ML, Pini C, Tulio S, Cantalice JC, Torres RA, Correia MT. Assessment of the association between micronuclei and the degree of uterine lesions and viral load in women with human papillomavirus. Cancer Genomics Proteomics. 2015 Mar 1;12(2):67-71.
13. Liu K, Feng T, Liu J, Zhong M, Zhang S. Silencing of the DEK gene induces apoptosis and senescence in CaSki cervical carcinoma cells via the up-regulation of NF-κB p65. Biosci Rep. 2012 Jun 1;32(3):323-32.
14. Riveiro-Falkenbach E, SoengasMS. Control of Tumorigenesis and Chemoresistance by the DEK Oncogene. Clinical Cancer Research [Internet]. 2010 May 31 [cited 2023 Oct 9];16(11):2932–8.

15. Kavanaugh GM, Wise-Draper TM, Morreale RJ, Morrison MA, Gole B, Schwemberger S, et al. The human DEK oncogene regulates DNA damage response signaling and repair. Nucleic Acids Research. 2011 Jun 7;39(17):7465–76.
16. Sammons MA, Shan Shan Wan, Vogel NL, Mientjes E, Grosveld G, Ashburner BP. Negative Regulation of the RelA/p65 Transactivation Function by the Product of the DEK Proto-oncogene. Journal of Biological Chemistry. 2006 Sep 15;281(37):26802–12.
17. McGarvey T, Rosonina E, McCracken S, Li Q, Arnaout R, Mientjes E, et al. The Acute Myeloid Leukemia-Associated Protein, Dek, Forms a Splicing-Dependent Interaction with Exon-Product Complexes. The journal of cell biology/The Journal of cell biology. 2000 Jul 24;150(2):309–20.
18. Vassilios Alexiadis, Waldmann T, Andersen J, Mann M, Knippers R, Gruss C. The protein encoded by the proto-oncogene DEK changes the topology of chromatin and reduces the efficiency of DNA replication in a chromatin-specific manner. Genes & development. 2000 Jun 1;14(11):1308–12.
19. Yu L, Huang X, Zhang W, Zhao H, Wu G, Fenglin Lv, et al. Critical role of DEK and its regulation in tumorigenesis and metastasis of hepatocellular carcinoma. Oncotarget. 2016 Apr 4;7(18):26844–55.
20. Kappes F, Burger K, Baack M, Fackelmayer FO, Gruss C. Subcellular localization of the human proto-oncogene protein DEK. J Biol Chem. 2001 Jul 13;276(28):26317-23.
21. Yang M, Bai L, Lei L, Zheng Y, Wang Z, Li Z, et al. DEK promotes the proliferation and invasion of lung cancers and indicates poor prognosis in lung adenocarcinomas. Oncology Reports. 2020 Feb 3;
22. Privette M, McClaine RJ, Wagh PK, Wikenheiser-Brokamp KA, Waltz SE, Wells SI. The human DEK oncogene stimulates β-catenin signaling, invasion and mammosphere formation in breast cancer. Oncogene. 2011 Feb 14;30(24):2741–52.
23. Liu B, Sun Y, Zhang Y, Xing Y, Suo J. DEK modulates both expression and alternative splicing of cancer-related genes. Oncol Rep. 2022 Jun 1;47(6):1-4.
24. Hacker KE, Bolland DE, Tan L, Saha AK, Niknafs YS, Markovitz DM, et al. The DEK oncoprotein functions in ovarian cancer growth and survival. Neoplasia. 2018 Dec;20(12):1209–18.
25. Liu K, Feng T, Liu J, Zhong M, Zhang S. Silencing of the DEK gene induces apoptosis and senescence in CaSki cervical carcinoma cells via the up-regulation of NF-κB p65. Bioscience reports. 2012 Mar 29;32(3):323–32.
26. Xu Z, Zou L, Yao Q, Zhang Y, Gan L, Tang L. Silencing DEK downregulates cervical cancer tumorigenesis and metastasis via the DEK/p-Ser9-GSK-3β/p-Tyr216-GSK-3β/β-catenin axis. Oncol Rep. 2017;38(2):1035-42.
27. Anderson MW, Reynolds SH, You M, Maronpot RM. Role of proto-oncogene activation in carcinogenesis. Environ Health Perspect. 1992;98:13-24.
28. Torry DS, Cooper GM. Proto-oncogenes in development and cancer. Am J Reprod Immunol. 1991;25(3):129-32.

29. Feng K, Liu C, Wang W, Kong P, Tao Z, Liu W. Emerging proteins involved in castration-resistant prostate cancer via the AR-dependent and AR-independent pathways (Review). International journal of oncology [Internet]. 2023 Sep 20;63(5).
30. Han S, Xuan Y, Liu S, Zhang M, Jin D, Jin R, et al. Clinicopathological significance of DEK overexpression in serous ovarian tumors. Pathol Int. 2009 Jul;59(7):443-7.
31. Privette Vinnedge LM, Benight NM, Wagh PK, Pease NA, Nashu MA, Serrano-Lopez J, et al. The DEK oncogene promotes cellular proliferation through paracrine wnt signaling in Ron receptor-positive breast cancers. Oncogene. 2014 Jun 23;34(18):2325–36. doi:10.1038/onc.2014.173.
32. Wise-Draper TM, Mintz-Cole RA, Morris TA, Simpson DS, Wikenheiser-Brokamp KA, Currier MA, et al. Overexpression of the cellular DEK protein promotes epithelial transformation in vitro and in vivo. Cancer Res. 2009 Mar 1;69(5):1792-9.
33. Riveiro-Falkenbach E, Ruano Y, García-Martín RM, Lora D, Cifdaloz M, Acquadro F, et al. DEK oncogene is overexpressed during melanoma progression. Pigment Cell Melanoma Res. 2017 Mar;30(2):194-202.
34. Kappes F, Khodadoust MS, Yu L, Kim DS, Fullen DR, Markovitz DM, et al. DEK expression in melanocytic lesions. Hum Pathol. 2011 Jul 1;42(7):932-8.
35. Lee F, Tsai M, Tsai Y, Huang G, Ou H, Hsieh C, Hsieh L, Wang S, Lin H. DEK is a potential biomarker associated with malignant phenotype in gastric cancer tissues and plasma. Int J Mol Sci. 2019;20(22):5689.
36. Habiburrahman M, Wardoyo M, Sutopo S, Rahadiani N. Potential of DEK proto-oncogene as a prognostic biomarker for colorectal cancer: An evidence-based review. Molecular and Clinical Oncology. 2022 May 26;17(1).
37. Yang MQ, Bai LL, Wang Z, Lei L, Zheng YW, Li ZH, et al. DEK is highly expressed in breast cancer and is associated with malignant phenotype and progression. Oncology Letters. 2021 Apr 1;21(6).
38. Wise-Draper TM, Allen HV, Jones EE, Habash KB, Matsuo H, Wells SI. Apoptosis inhibition by the human DEK oncoprotein involves interference with p53 functions. Mol Cell Biol. 2006 Oct 1;26(20):7506-19.
39. Song Y, Wang Z, Jiang J, Piao Y, Li L, Xu C, et al. DEK-targeting aptamer DTA-64 attenuates bronchial EMT-mediated airway remodelling by suppressing TGF-β1/Smad, MAPK and PI3K signalling pathway in asthma. Journal of Cellular and Molecular Medicine. 2020 Oct 30;24(23):13739–50.
40. Shepherd JH. Revised FIGO staging for gynaecological cancer. Bjog: An International Journal Of Obstetrics And Gynaecology. 1989 Aug 1;96(8):889–92.
41. Zhang C, Liu J, Xu D, Zhang T, Hu W, Feng Z. Gain-of-function mutant p53 in cancer progression and therapy. J Mol Cell Biol. 2020 Sep 1;12(9):674-87.
42. Du W, Takuwa N, Yoshioka K, Okamoto Y, Gonda K, Sugihara K, et al. S1P2, the G Protein–Coupled Receptor for Sphingosine-1-Phosphate, Negatively Regulates Tumor

Angiogenesis and Tumor Growth *In vivo* in Mice. Cancer Research. 2010 Jan 13;70(2):772–81.

43. Privette Vinnedge LM, Ho SM, Wikenheiser-Brokamp KA, Wells SI. The DEK oncogene is a target of steroid hormone receptor signaling in breast cancer. PLoS One. 2012;7(10).

FIGURES

Table 1 Clinical Characteristics of Women With Uterine Myomas (n=10). VAS stands for visual analog scale.

Characteristic	**Median**	**Interquartile range**
Age (years)	42	37-45
Dysmenorrhea (VAS)	3	2-4
Intermenstrual pelvic pain (VAS)	3	2-5
Menstrual bleeding	3	3-5
Intermenstrual bleeding	2	1-2
Largest myoma diameter (mm)	65	50-80
Uterine volume (cm2)	126	65-198
Number of myomas	2	1-6

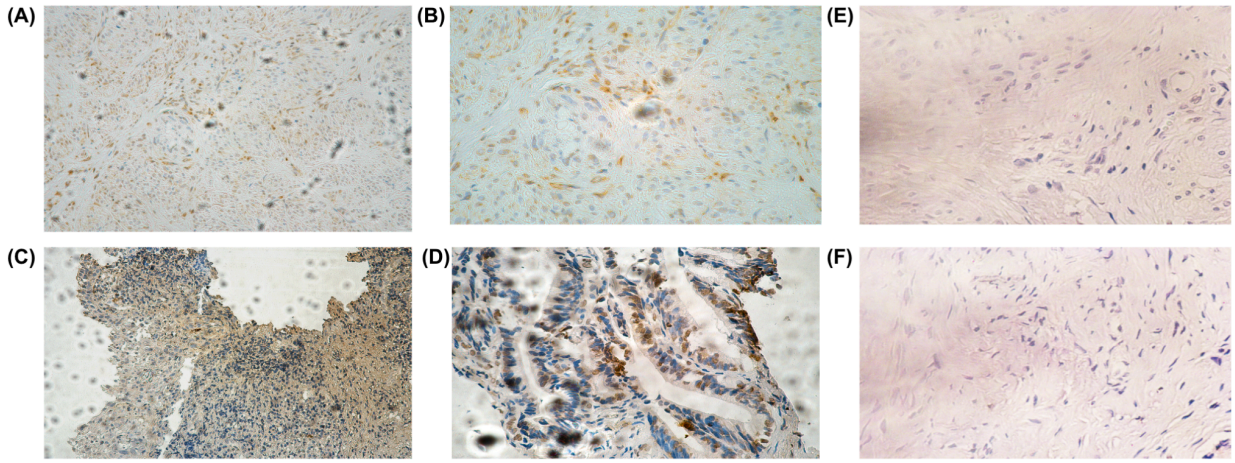

(G)

Tissue type	Percentage of Positive Cells	Positive Cells Score	Staining Intensity	Staining Intensity	Final IRS Score	Expression Level
Uterine Myoma	<10%	1	Weak	2	2	+
Cervical Cancer	>81%	4	Strong staining	3	12	++
Normal Uterine Tissue	No staining	0	No staining	0	0	−

Figure 1 Immunohistochemical Staining and Analysis of DEK Expression in Uterine Myomas and Cervical Cancer Tissues. Immunohistochemical staining for DEK (1 mg/ml, Abcam) was conducted on formalin-fixed, paraffin-embedded tissues using a detection kit (DAKO ChemMate) and a semi-automated stainer (DAKO TechMate) according to the specifications of the manufacturer. (A) Nuclear staining of DEK, uterine myoma (x20). (B) Nuclear staining of DEK, uterine myoma (x40). (C) Nuclear staining of DEK, cervical cancer (x20). (D) Nuclear staining of DEK, cervical cancer (x40). (E) Negative control for nuclear staining of DEK, uterine myoma (x40). (F) Negative control for nuclear staining of DEK, cervical cancer (x40). (G) To quantify DEK expression in uterine myomas and cervical cancer tissues immunohistochemical staining analysis was conducted. The IRS score was calculated by multiplication of the optical staining intensity (0, no staining; 1, weak; 2, moderate; 3, strong staining) and the percentage of the positive stained cells (0, no staining; 1, <10%; 2, 11-50%; 3, 51-80%; 4, >81% of the cells). The expression level of DEK was then categorized into three levels: negative (−), positive (+), and strongly positive (++).

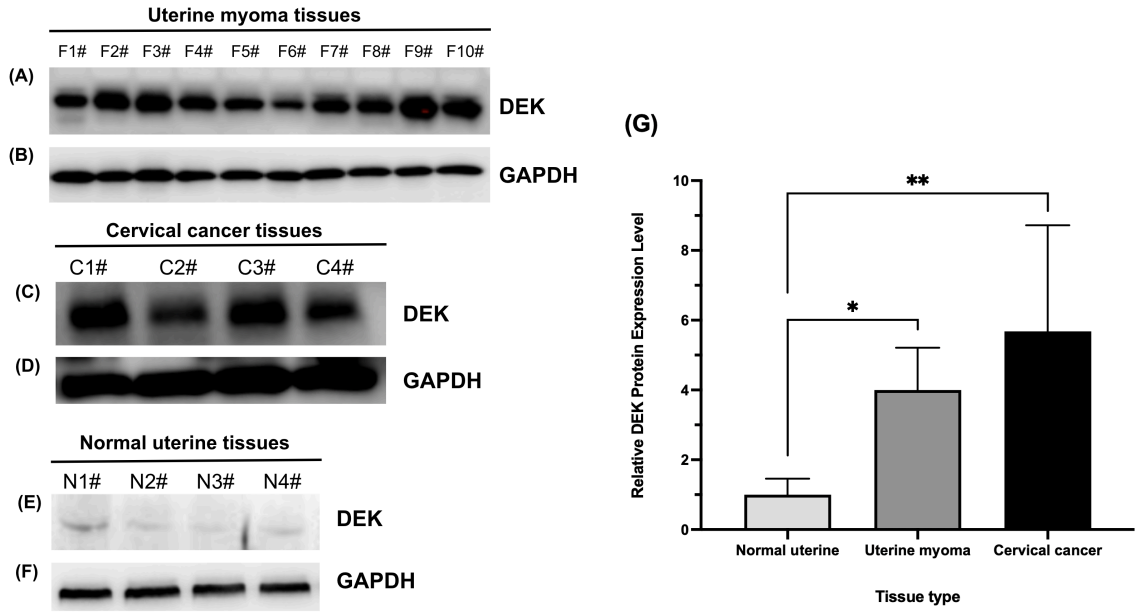

Figure 2 Relative DEK Protein Expression in Normal Uterine Tissue, Uterine Myoma Tissue, and Cervical Cancer Tissue. Western blot analysis of protein expression: (A) DEK in uterine myoma (F1#-F10#), (B) GAPDH in uterine myoma (F1#-F10#), (C) DEK in cervical cancer (C1#-C4#), (D) GAPDH in cervical cancer (C1#-C4#), (E) DEK in normal uterine (N1#-N4#), (F) GAPDH in normal uterine (N1#-N4#). Antibodies: DEK (rabbit, 1:2000, Abcam), GAPDH (rabbit, 1:1000, Beyotime). (G) Quantification of DEK and GAPDH protein levels from the Western blots in panels A-F using ImageJ gel analysis program. Data are presented as mean and standard deviation (error bars). Statistical analysis was performed using one-way ANOVA ($p = 0.0038$) and Tukey's HSD test for pairwise comparisons: normal vs. uterine myoma ($p < 0.05$), normal vs. cervical cancer ($p < 0.01$), uterine myoma vs. cervical cancer tissue ($p > 0.23$). *, $p < 0.05$; **, $p < 0.01$.

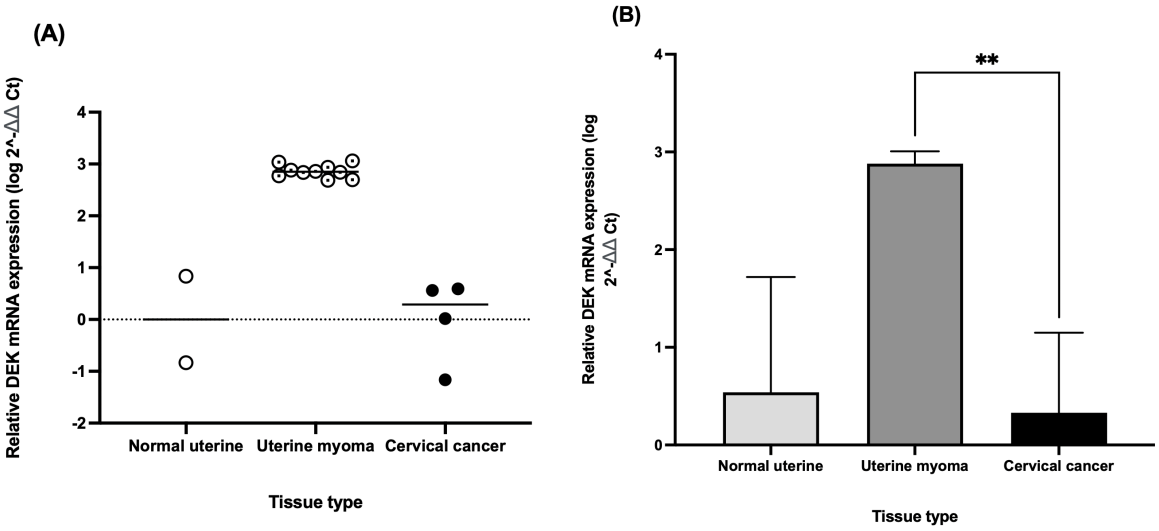

Figure 3 Relative DEK mRNA Expression Levels in Normal Uterine Tissue, Uterine Myoma tissue, and Cervical Cancer Tissue. Relative quantification was performed using the Applied Biosystems 7300 real-time PCR system and ChamQ Universal SYBR qPCR Master Mix. Primers for DEK and GAPDH were sourced from literature and synthesized by Sangon Biotech. (A) Relative DEK mRNA expression (log 2^-ΔΔCt). (B) Mean relative DEK mRNA expression (log 2^-ΔΔCt) with standard deviations (error bars). Statistical analysis with Kruskal-Wallis H (p = 0.005) and unpaired Mann-Whitney U test: normal vs. uterine myoma tissues (p = 0.3), normal uterine vs. cervical cancer tissues (p = 0.8), uterine myoma vs. cervical cancer tissues (p = 0.002). **, $p < 0.01$.