Frem2 Knockout Mice Exhibit Fraser Syndrome Phenotypes and Neonatal Lethality Due to Bilateral Renal Agenesis

Rubina G. Simikyan[1], Xinyuan Zhang[1], Olga Strelkova[1], Nathan Li[2], MengYu Zhu[1], Andreas Eckhard[1], Petr Y. Baranov[4], Xudong Wu[3], Lauren Richey[2], Artur A. Indzhykulian[1].

1. Department of Otolaryngology Head and Neck Surgery, Mass Eye and Ear, Harvard Medical School, Boston, MA, United States.
2. Tufts Comparative Medicine Services, Tufts University, Boston, MA, United States.
3. Department of Neurobiology, Harvard Medical School, Boston, MA, United States.
4. Schepens Eye Research Institute, Massachusetts Eye and Ear, Harvard Medical School, Boston, MA, United States.

Correspondence should be addressed to inartur@hms.harvard.edu

ABSTRACT

Fraser syndrome is a rare autosomal recessive disorder characterized by multiple congenital malformations, including cryptophthalmos, syndactyly, and renal agenesis, which can lead to severe complications beginning at the embryonic stage. Mutations in genes encoding extracellular matrix proteins such as FRAS1, FREM1, FREM2, and the associated trafficking protein GRIP1, are implicated in Fraser syndrome. These proteins are critical for maintaining epithelial integrity during embryogenesis, with deficiencies leading to tissue detachment and blistering phenotypes in mouse models. The FREM2 protein is a single-pass membrane protein of 3169 amino acids. While FREM2-deficient mouse models encoding missense variants found in patients, or a truncated FREM2 protein product were previously reported, it has not been studied in a constitutive knockout (KO) mouse model.

Here, we developed constitutive *Frem2-KO* mice exhibiting neonatal lethality, mainly due to bilateral renal agenesis, along with blood-filled blisters, cryptophthalmos, and syndactyly. Only one mouse survived to adulthood exhibiting unilateral renal agenesis and Fraser syndrome-like phenotypes. These findings confirm FREM2's crucial role in the development of the kidneys, skin, and eyes and provide an animal model for further studies of FREM2-related developmental disorders.

INTRODUCTION

Fraser syndrome is a rare autosomal recessive disorder characterized by developmental malformations evident before birth (Smyth et al., 2005). Individuals affected may exhibit various features such as cryptophthalmos (fused eyelids), syndactyly (fused fingers and toes), and unilateral or bilateral renal agenesis (failure of kidney development), alongside respiratory and ear abnormalities (Slavotinek et al., 2002). Despite its rarity, Fraser Syndrome may contribute to early-term miscarriages, mainly due to renal or pulmonary complications at the embryonic stage (Smyth et al., 2005). Patients without life-threatening phenotypes can survive into adulthood and may utilize surgical interventions to resolve skin malformations such as syndactyly.

FRAS1, FREM1, and FREM2 are structurally similar proteins shown to serve as important components of the extracellular matrix (ECM) protein complex (Pavlakis et al., 2011). These proteins are predominantly localized in the skin within the *sublamina densa* of basement membranes, playing a critical role in preserving epithelial-mesenchymal integrity. A protein that has a role in trafficking the ECM proteins to their correct location, GRIP1, which is crucial for mediating organ morphogenesis. Although it is not included in the ECM protein complex, it was suggested to play an important role in maintaining the structural integrity of tissues (Takamiya et al., 2004). Mutations in the *Fras1*, *Frem1*, *Frem2,* and *Grip1* genes cause epithelial detachment at the level of the sublamina densa (Pavlakis et al., 2011, Takamiya et al., 2004).

Previous studies reported that human mutations to *Fras1, Frem2, and Grip1* are causative of Fraser Syndrome, however mutations in *Frem1* alone do not induce the disorder (Short et al., 2007). Nonetheless, mutations in

these genes result in similar phenotypes. The severity of these phenotypes in patients, caused by deleterious mutations in or the absence of ECM proteins and GRIP1 highlights their requirement for assembling basement membranes across critical organs such as the skin, kidneys, testes, and trachea during embryogenesis (Pavlakis et al., 2008). Mouse models have proven an excellent tool for investigating the roles of key proteins in embryonic development and explaining their phenotypic correlations.

Previously reported mouse models carrying mutations in this group of genes have displayed mutual blistering phenotypes, often referred to as 'bleb' mutants (Pavlakis et al., 2011). Loss of function in *Grip1* results in blistering on the eyes of mice, mimicking the mutant strain for eye blebs (*eb*) (Short et al., 2007). Mutations of *Fras1* in mice produces blebs (*bl*) on the paws. Mutations in *Frem1* cause head blebs (*heb*) in mice, often appearing as blisters on the head along with absent or malformed eyes at birth (Smyth et al., 2004). Myelencephalic bleb (*my*) mutant mice are related to the *Frem2* gene (Jadega et al., 2005). *Fras1*- and *Grip1*-knockout mouse models were shown to display blistering phenotypes as early as 12-13 days of gestation and reported the deficiency of the genes led to embryonic lethality (Bladt et al., 2002; Vrontou et al., 2003). Mutations of *Frem2* in mice have reported cryptophthalmos, epithelial blebbing, blood-filled blisters, renal agenesis, and bony syndactyly (Jadeja et al., 2005; Zhang et al., 2019). Previously reported *Frem2* mouse models carry either point mutations ($Frem^{R2156W}$ corresponding to a variant seen in a cryptophthalmos patient) or missense mutations ($Frem2^{R725X}$, $Frem2^{my\text{-}F11}$), and gene trap mutations (my^{Ucl}/my^{KST}) (Zhang et al., 2019; Timmer et al., 2005; Jadeja et al., 2005). To the best of our understanding, these animal models carry variants predicted to produce either a truncated FREM2 protein, or one with a single amino acid substitution. These models are likely to result in milder phenotypes, as these *Frem2* variants seem to induce FREM2 protein deficit mainly within certain cell types or specific organs, such as the cryptophthalmos phenotype of the $Frem2^{R725X/R2156W}$ mouse model (Zhang et al., 2019). However, a constitutive *Frem2* knockout (*KO*) mouse model, lacking FREM2 expression throughout the body, has not been carefully characterized.

To assess whether the absence of FREM2 recapitulates the reported phenotypes in *Frem2* mutants, or perhaps, results in a more exacerbated phenotype, we developed and characterized a constitutive *Frem2-KO* mouse model. Upon anatomical and histological analysis, we found that the *Frem2-KO* mice exhibit neonatal mortality which we associate with bilateral renal agenesis. In addition, the *Frem2-KO* fetuses develop blood-filled blisters on the eyes and paws that progress into hemorrhages and missing eyelids. A single *Frem2-KO* mouse survived to adulthood and displayed unilateral renal agenesis while exhibiting syndactyly, cryptophthalmos, and microphthalmia. Our findings confirm FREM2's role as an important protein for the formation of the skin, kidneys, and eyes. This *Frem2-KO* mouse model provides a valuable tool for further, more detailed prenatal investigation of its critical roles in organ development and underlying phenotypes resulting from its absence.

RESULTS

Genetic analysis of Frem2-KO mouse model

Mouse ES cell clones were purchased from the European Conditional Mouse Mutagenesis Program and used to generate the $Frem2^{tm1a(EUCOMM)Hmgu}$ mouse line carrying the knockout-first allele with conditional potential (F2KCR allele) (**Fig. 1A**). First, the FRT-flanked Neo cassette was excised by crossing with a FLP deleted strain to generate the conditional $Frem2^{fl/fl}$ allele. Although the generated mouse line was designed to carry a floxed *Frem2* allele to enable cell-type specific FREM2 functional studies (**Fig. 1A**), following several breeding steps with pan-Cre and tissue-specific Cre lines (see *Methods*), we were unable to generate adult homozygous *Frem2*-floxed mice. Upon further investigation of the mouse genetics, and the sequencing results of the insertion part of the floxed-*Frem2* mouse, we discovered mutations within the targeted insertion site. These included two in-frame insertions (27 bp and 30 bp) and one in-frame deletion (9 bp) (**Fig. 1A**). Subsequently, we analyzed the open reading frame in exon 1 of the floxed *Frem2* allele. We identified a premature stop codon (**Fig. 1B**) within the fused intron sequence downstream of exon 1 in the Floxed-*Frem2*, which likely results in a truncated FREM2 protein, converting the floxed-*Frem2* allele by design into a constitutive null allele. All animals evaluated in this study were obtained from $Frem2^{+/-}$ x $Frem2^{+/-}$ crosses.

Frem2-KO mice have hemorrhagic blisters and skeletal malformations on their paws

Upon our examination of fetuses (E13-16), we immediately observed the skin deficit phenotype on their paws, in agreement with previous studies reporting FREM2's critical role in epidermis development. Hemorrhagic blisters were observed on the digits of *Frem2-KO* fetuses at E15 and E16 (**Fig. 2A** and **B**) and were often used to phenotype them. To observe the postnatal development of the limbs, newborn *Frem2* pups were collected. When we assessed blood-filled blisters on the digits of newborn *Frem2-KO* pups, they were still present but often appeared dry (**Fig. 2C**, arrowheads).

In newborn *Frem2-KO* pups, most hind paws revealed soft tissue syndactyly, independent of whether any blisters were observed. Affected paws often also display dorsal flexure, an anatomical malformation where the paws curl upwards (**Fig. 2D**). We next assessed the skeletal formation of the paws and other morphological features using histological sections, which were carried out using the same orientation across all samples (**Fig. 2E**). We determined that newborn *Frem2-KO* mice with paws that had blood-filled blisters, syndactyly, or dorsal flexure also exhibited skeletal malformations at the digits, with the skeletal structure around them often compromised. Interestingly, these regions of skeletal malformations typically occurred bilaterally on the hind limbs.

FREM2 deficiency causes ocular abnormalities in Frem2-KO mice

We often observed even larger blood-filled blisters over the eyes of *Frem2-KO* fetuses. At E13, the *Frem2-KO* fetuses can be identified by the pronounced bubble-like blisters over their eyes. Coronal head histology sections of E15 *Frem2-KO* fetuses revealed blisters localized near or within the eyelids (**Fig. 3B** and **C**). In some cases, the eyelids in *Frem2-KO* fetuses were thinned and hemorrhaged (**Fig. 3D** and **E**). Such hemorrhages and blood-filled blisters appeared bilaterally or unilaterally on the eyelids of *Frem2-KO* fetuses (**Fig. 3E**).

In newborn *Frem2-KO* pups, however, no blood-filled blisters were observed. Instead, *Frem2-KO* pups predominantly displayed missing eyelids, with some hemorrhages often observed on the skin around the eyes (**Fig. 3F**). The heads of newborn pups were sectioned coronally to assess eye morphology using standard histology techniques. In wild-type and heterozygous *Frem2* pups, the epidermal layers of the eyelids were properly formed (**Fig. 3G**). In *Frem2-KO* pups, however, the eyelids were often missing (**Fig. 3H** and **I**) or thinned (**Fig. 3I** and **J**). Periocular hemorrhages and the absence of eyelids were bilateral or unilateral in *Frem2-KO* pups. Blood-filled blisters on the eyelids that occur during embryonic stages, as well as the missing eyelids in newborn *Frem2*-deficient animals, suggest that proper FREM2 expression is critical for the epidermal development of the eyelids.

Frem2-KO mice die hours after birth

During routine genotyping of *Frem2* litters, no *Frem2-KO* mice were identified. Interestingly, the dam was observed giving birth to pups exhibiting phenotypes we observed in *Frem2-KO* embryos. However, a few hours after birth, the pups were discovered dead in the cage. We thus concluded that *Frem2-KO* pups do not survive after birth, and next sought to investigate the causes of this mortality. Multiple histological sections and post-mortem necropsies were performed in newborn *Frem2-KO* pups. In almost all newborn *Frem2-KO* pups we observed bilateral renal agenesis (**Fig. 4**). Likely a result of the lack of urine production from renal agenesis, *Frem2-KO* pups had empty urinary bladders. We also commonly observed the absence of one or both adrenal glands (**Fig. 4A** and **B**). Parasagittal sections further confirmed the renal agenesis and the empty urinary bladder in newborn *Frem2-KO* pups (**Fig. 4C-F**). We carried our serial transverse histological sections to gain better confidence in our macroscopic results (**Fig. 5** and **Supplementary Movies**). All *Frem2-KO* pups, but one, had bilateral renal agenesis, confirmed by the necropsies or with histological evaluation. A single newborn *Frem2-KO* pup displayed one small but developed kidney, confirming unilateral renal agenesis (**Fig. 5D**). *Frem2-KO* pups also had empty urinary bladders. No major defects in other vital organs, such as the lungs and heart, were seen in *Frem2-KO* pups upon examination with necropsy or histological analysis. We conclude that the likely cause of postnatal mortality of *Frem2-KO* pups is the renal agenesis.

A single case of Frem2-KO mouse surviving into adulthood

Over the years of breeding, only one female *Frem2-KO* mouse survived until adulthood during this study. Although no apparent health conditions were determined and the animal produced two litters, the female was euthanized at the age of 51 weeks due to ulcerative dermatitis, common in older mice. Interestingly, the mouse had displayed physical phenotypes, such as unilateral cryptophthalmos (**Fig. 6A**). The left eye of the mouse was closed, with no visible eyelid crease. The contralateral eye, however, appeared normal. A post-mortem incision through the skin of the closed eyelid, a significantly smaller eyeball was identified and sent for histological analysis along with the contralateral eye. The histological analysis revealed a normally developed right eye and a malformed left eye **(Fig. 6B**). The left eye was dramatically smaller in size, and the retina appeared to have folds, often observed in microphthalmia **(Fig. 6B'**).

Consistent with our observations in newborn *Frem2-KO* mice, the front paws of the adult mouse appeared normal (Fig. 6C), while both hind paws were affected by syndactyly (**Fig. 6D** and **E**). The hind paws were also slightly curled, similar to the paws observed in newborns. We next examined the renal system of this adult mouse and found that it had one functional kidney. There was no gross evidence of renal tissue on the right side (**Fig. 6F**). The left kidney was fully attached to the ureter along with the rest of the urinary system. Hematoxylin and eosin histological sections of the left kidney confirmed normal morphology of the adrenal gland and kidney (**Fig. 6G**). Higher magnification images of the histological sections reveal apparently the normal histology of the adrenal gland, as well as of the kidney, containing the normal appearance of tubules and nephrons (**Fig. 6H**). The histological evaluation also showed a missing right ureter (**Fig. 6I**). Although missing a kidney, the reproductive functions were not affected in the *Frem2-KO* female, allowing it to breed and produce litters. In the right uterine horn, a placenta-like tissue was found (**Fig. 6I**). The renal pelvis was also dilated, according to gross examination. As a result of the functional kidney, the urinary bladder was full (**Fig. 6K**). Although this female was able to survive with one functional kidney, the *Frem2-KO* adult mouse displayed other prominent Fraser Syndrome phenotypes, such as cryptophthalmos and syndactyly (**Fig. 6A, C** and **D**).

DISCUSSION

In this study, we developed a constitutive knockout (*KO*) *Frem2* mouse model to evaluate the associated phenotypes. Our findings reveal that the absence of the FREM2 protein results in significant Fraser Syndrome-like phenotypes, including cryptophthalmos, syndactyly, and blood-filled blisters, observable as early as during the embryonic stage. *Frem2-KO* pups could be easily identified in liters due to their obvious phenotypes, even before confirming their genotypes. Although *Frem2-KO* mice can survive until birth, they die shortly thereafter likely due to bilateral renal agenesis. To date, only one *Frem2-KO* mouse with unilateral renal agenesis from our animal colony has survived into adulthood. These results highlight the critical role of FREM2 in the development of the epidermis, eyes, skeletal structure, and kidneys.

The extracellular matrix (ECM) is well-known for its role in providing structural support. However, it also plays a crucial role in maintaining tissue integrity by regulating cell proliferation, differentiation, and survival. Specifically, the ECM includes basement membranes that form sheets underlying epithelial and endothelial cell layers. FREM2 is localized within the epithelial basement membrane. Previous studies using immunogold labeling have demonstrated the clustered localization of FREM2 within the *sublamina densa* of embryonic skin, highlighting its importance in tissue integrity (Pavlakis et al., 2011). Mouse models with a deficiency of ECM proteins, such as FREM2, reveal how disruptions in ECM components can lead to blistering phenotypes, highlighting the intricate relationship between genetic mutations and the assembly of essential basement membranes (Petrou et al., 2008). Unfortunately, our attempts to label FREM2 using several commercially available antibodies were not successful.

Our observations support previously reported evidence from other studies that use *Frem2* mouse models in reporting that mutations in *Frem2* can cause blood-filled blisters and hemorrhages on the skin. For instance, in a study involving a *Frem2* mouse model of the my^{Ucl} strain, homozygote mutant mice exhibited epithelial blebbing beginning at E11.5 (Jadeja et al., 2005). By E14, these blebs had progressed into hemorrhagic lesions. Another

study focused on embryonic development suggests that the onset of angiogenesis, the process of new blood vessel formation involving the growth and differentiation of endothelial cells, may explain the timing of these hemorrhages (Timmer et al., 2005). Inadequate adhesion of endothelial cells to adjacent structures, particularly in cells deficient in FREM2 protein, could explain deficits in angiogenesis (Timmer et al., 2005). Although FREM2 is not directly localized within vascular structures, and instead was located in the membrane that lines the blood vessels, its role in stabilizing blood vessels during development appears critical (Timmer et al., 2005). The absence of FREM2 in surrounding tissues likely contributes to the hemorrhages observed on the skin which aligns with the parallel occurrence of syndactyly and blood-filled blisters observed on the paws and eyes of *Frem2-KO* mice. This further supports the conclusion that FREM2 is essential not only for vascular stability but also for tissue remodeling and skeletal development during gestation. However, the potential relationship between these anomalies remains speculative, necessitating further experimental investigation to explain the precise mechanisms involved.

Patients with Fraser Syndrome who exhibit cryptophthalmos are born with skin covering their eyes or with fused eyelids. Instead in *Frem2*-deficient mice, this phenotype more often presents as the absence rather than the fusing of eyelids. We observed that *Frem2-KO* fetuses developed blood-filled blisters or hemorrhages that cover their eyes and give way to one or both eyelids' absence at birth. A study on *Frem2* mice carrying the my^{F11} mutation, which is predicted to result in a truncated protein, indicated that embryonic hemorrhages might lead to localized tissue necrosis, which could explain the absence of eyelids (Timmer et al., 2005). Given the proposed role of FREM2 in vascular stability, it is likely that the loss of FREM2 during key morphogenic events, like eyelid development, could lead to such hemorrhages. The subsequent blood-filled blisters and hemorrhages likely inhibit normal skin development, causing the observed phenotypes.

Moreover, a study utilizing a compound heterozygous mutation derived from a Fraser Syndrome patient to generate mice that mimic the human cryptophthalmos phenotype found significant abnormalities in eyelid development during the critical stages at E13-14 (Zhang et al., 2021). Specifically, the lower eyelid fold was poorly defined in *Frem2* mutant fetuses, in contrast to normal mice, where the grooves of the ectoderm that eventually form the upper and lower eyelids are visible. These mutants exhibited dysplasia and microphthalmia, with reductions in the eye's axial length and lens thickness. Eyes affected by microphthalmia typically have a thicker cornea, an absent or severely underdeveloped lens, and a retina prone to folding or filling the vitreous body. These features likely exert pressure on the lens, potentially exacerbated by the presence of blisters or hemorrhages (Graw et al., 2019). In our *Frem2-KO* model, we observed microphthalmia where one eye was smaller than the other, as well as retinal folding. In Fraser Syndrome patients, these ocular abnormalities often lead to impaired vision. This shows that FREM2 is not only important for eyelid development but also specifically for eye development.

FREM2 protein was reported to be expressed in the epithelia in the renal cortex, or the outer layer, of mouse kidneys (Kerecuk et al., 2012). FREM2 expression begins in the ureteric epithelia of the metanephros at E11.5, with peak expression at the tips of the ureteric buds (Jadeja et al., 2005). In adult mice, FREM2 is strongly expressed in the collecting ducts, proximal convoluted tubules, and arterioles within the kidneys (Jadeja et al., 2005). This expression pattern, along with the development of renal cysts in *Frem2* mutant animals, suggests that FREM2 is essential for maintaining renal integrity (Kerecuk et al., 2012). The absence of kidneys in *Frem2-KO* mice that fail to survive postnatally provides additional evidence of FREM2's critical involvement in renal development. Interestingly, over multiple years of breeding, the only *Frem2-KO* mouse that survived into adulthood had one functional kidney, suggesting that perhaps while FREM2 is critical for renal development, it is not absolutely indispensable. This partial necessity may be due to protein-protein interactions within the ECM protein complex, where other proteins such as FREM1 or FRAS1 may, at least partially, compensate for the loss of FREM2 in the formation of the basement membrane. Although Fraser Syndrome is associated with a risk of miscarriage, bilateral renal agenesis is a significant phenotype contributing to this, while patients with unilateral renal agenesis can survive with a single kidney (Smyth et al., 2005). Since kidneys contribute to the amniotic fluid in humans, by the second trimester of pregnancy, low amniotic fluid levels serve as an important indicator of renal agenesis in the fetus (Miller et al., 2023). Insufficient amniotic fluid, also known as oligohydramnios, in addition to the absence of kidneys, poses a significant risk for fetal death. In contrast, the impact of bilateral renal agenesis is markedly different in mice, resulting in death within 2 days after birth (Kamba et al., 2001). While the

mouse phenotype we observed in our *Frem2-KO* mice is clearly more severe when compared to other previously reported *Frem2* mouse lines, given the uncertain rate of miscarriages related to FREM2 dysfunction, it is difficult to directly compare the severity of the phenotype we observed to that of patients carrying pathogenic FREM2 variants.

In summary, to address the gap in Fraser Syndrome research, we have developed and characterized a constitutive *Frem2-KO* mouse model that lacks the FREM2 protein. While previous studies have utilized various *Frem2* mouse models, some of which have retained limited FREM2 function, here we report a mouse model predicted to lack FREM2 entirely. Our findings reveal that *Frem2-KO* pups die shortly after birth, limiting the opportunity for extensive study. Nevertheless, we have identified the most prominent phenotypes and the primary cause of neonatal mortality. We acknowledge the possibility of non-morphological phenotypes, particularly in the respiratory or cardiovascular systems, that have yet to be uncovered. Our study provides a unique, though severe, model of Fraser Syndrome that can be utilized in future embryonic studies to advance the understanding of Fraser Syndrome's pathophysiology. Critically, our work can help tease apart the crucial role the FREM2 has in the development of important organs and also in uncovering the underlying mechanisms that drive Fraser Syndrome.

MATERIALS AND METHODS

Animals

Mouse ES cell clones (*Frem2*$^{tm1a(EUCOMM)Hmgu}$; clones HEPD0988-1-E06 and HEPD0988-1-H08) were purchased from the European Conditional Mouse Mutagenesis Program (https://www.mousephenotype.org/about-impc/about-ikmc/eucomm/, Clone# HEPD0988_1_E06, HEPD0988_1_H08). The clones were then used to generate the *Frem2*$^{tm1a(EUCOMM)Hmgu}$ mouse line carrying the knockout-first allele with the conditional potential (F2KCR allele) (**Fig. 1A**) at the Harvard Transgenic Animal Core. For clone HEPD0988-1-E06, 36 blastocysts were injected, 8 pups were born (5 died), and no chimera pups obtained from this injection. For clone HEPD0988-1-H08, 48 blastocysts were injected, 15 pups were born (5 died), and two of the 10 surviving pups were chimeric mice (1 male was 15% and 1 female was 40% chimeric). The two chimera mice were bred to get germline transmission. The founder mice were then imported to the Mass Eye and Ear animal facility to set up an animal colony. To generate the conditional *Frem2*$^{fl/fl}$ allele the FRT-flanked Neo cassette was excised by crossing with a FLP deleter strain (The Jackson Laboratory, #003946).

The *knockout*-first mouse line (*Frem2-KO*-first allele with conditional potential, F2KCP) derived from these ES cells contains an "FRT-Exon2-LacZ-LoxP-NeoR-FRT-LoxP-Exon3-LoxP" cassette in the middle of exon 1 of the wildtype FREM2 gene. We found that the exon 2 named in the vendor's sequence is not present in the other published FREM2 wildtype gene (Ensembl.org). The F2KCR line was bred with the FLP mouse (Jax Cat# 003946) to delete the "FRT-Exon2-LacZ-LoxP-NeoR" part and obtain a floxed FREM2 line containing "Exon1-FRT-LoxP-Exon3 (or Exon1b)-LoxP" structure.

All procedures and protocols were approved by the Institutional Animal Care and Use Committee of Mass Eye and Ear and we have complied with all relevant ethical regulations for animal use. All mice were kept on a 12:12 hour light-dark cycle with unlimited access to food and water. The fetuses were collected by timed breedings or by keeping track of the pregnancy by weighing the dam. For the collection of newborn pups, the breeding cages with pregnant females were closely monitored for litter birth by an infrared webcam setup below the cage with a remote access functionality.

Phenotypic Analysis and Fixation of Fetuses

Mouse fetuses were collected by euthanizing pregnant adult females at the needed gestation stage. Fetuses were collected and fixed in Bouin's fixative (Electron Microscopy Sciences). E12.6-16.5 were fixed for 4 hours. E17.5-18.5 were fixed for 72 hours. The fetuses were then rinsed in three changes of 70% alcohol and stored at 70% alcohol until processing.

Collection and Fixation of Newborn Pups

Newborn mouse pups were collected at P0 once the litter was detected using an infrared webcam setup (ELP 1080p USB Camera). Pups were cryoanesthetized, weighed, imaged, and the tip of the tail was collected for genotyping. Pups were then euthanized by decapitation and fixed in Bouin's solution (Electron Microscopy Sciences, Cat# 15990-01) for 72 hours. After fixation, samples were rinsed in three changes of 70% alcohol and stored at 70% alcohol until processing. Pups used for gross anatomy evaluation were euthanized, and a median laparotomy was done from the pubic crest to the trachea.

Histology

Fetal and newborn pup bodies were trimmed into three sections with cuts at the diaphragm and pelvis to ensure adequate paraffin embedding and tissue processing. Heads were trimmed for coronal embedding to the area of interest. Samples were processed using a Microm STP-120 processor on a routine program for manual paraffin embedding with a Microm EC-350 embedding center. After paraffin embedding, 5μm sections were cut from the head and body for Hematoxylin and eosin staining. Sections from the bodies were collected distally every ~400 μm through the entire cavity. Slides were imaged with the Aperio AT2 automatic slide scanner (Leica Biosystems) using a 0.5x objective lens and processed with the Aperio ImageScope software.

ACKNOWLEDGEMENTS

We would like to thank Dr. David Corey for developing the *Frem2-KO* mouse line; Philip Seifert and the Schepens Eye Research Institute Morphology Core for sectioning eye samples for histology; Sarah Visconti for assistance in breeding and imaging mice; Dr. Frank Yeh for providing edits and critical feedback to the manuscript. This work was supported by NIH R01DC020190 (NIDCD) and R01DC017166 (NIDCD) to A.A.I. The funder had no role in study design, data collection and analysis, decision to publish, or preparation of the manuscript.

DATA AVAILABILITY

All data are included within the manuscript or are available upon request. All imaging data will be made available from a public data repository upon acceptance of the manuscript for publication.

COMPETING INTERESTS

The authors declare no competing interests.

AUTHOR CONTRIBUTIONS

RGS: Validation, Formal Analysis, Investigation, Writing – Original Draft, Writing – Review & Editing, Visualization, Project administration.
GZ: Validation, Formal Analysis, Investigation, Writing – Review & Editing.
OSS: Validation, Formal Analysis, Investigation, Writing – Review & Editing.
NL: Investigation, Resources, Writing – Review & Editing.
MZ: Resources, Writing – Review & Editing, Visualization.
AE: Resources, Writing – Review & Editing.
PYB: Validation, Resources, Writing – Review & Editing.
SW: Conceptualization, Methodology, Validation, Formal Analysis, Investigation, Writing - Review & Editing, Visualization.
LR: Methodology, Validation, Investigation, Resources, Writing – Review & Editing, Supervision.
AAI: Conceptualization, Methodology, Validation, Formal analysis, Investigation, Resources, Visualization, Writing – Original Draft, Supervision, Project administration, Funding acquisition.

320 **FIGURES**

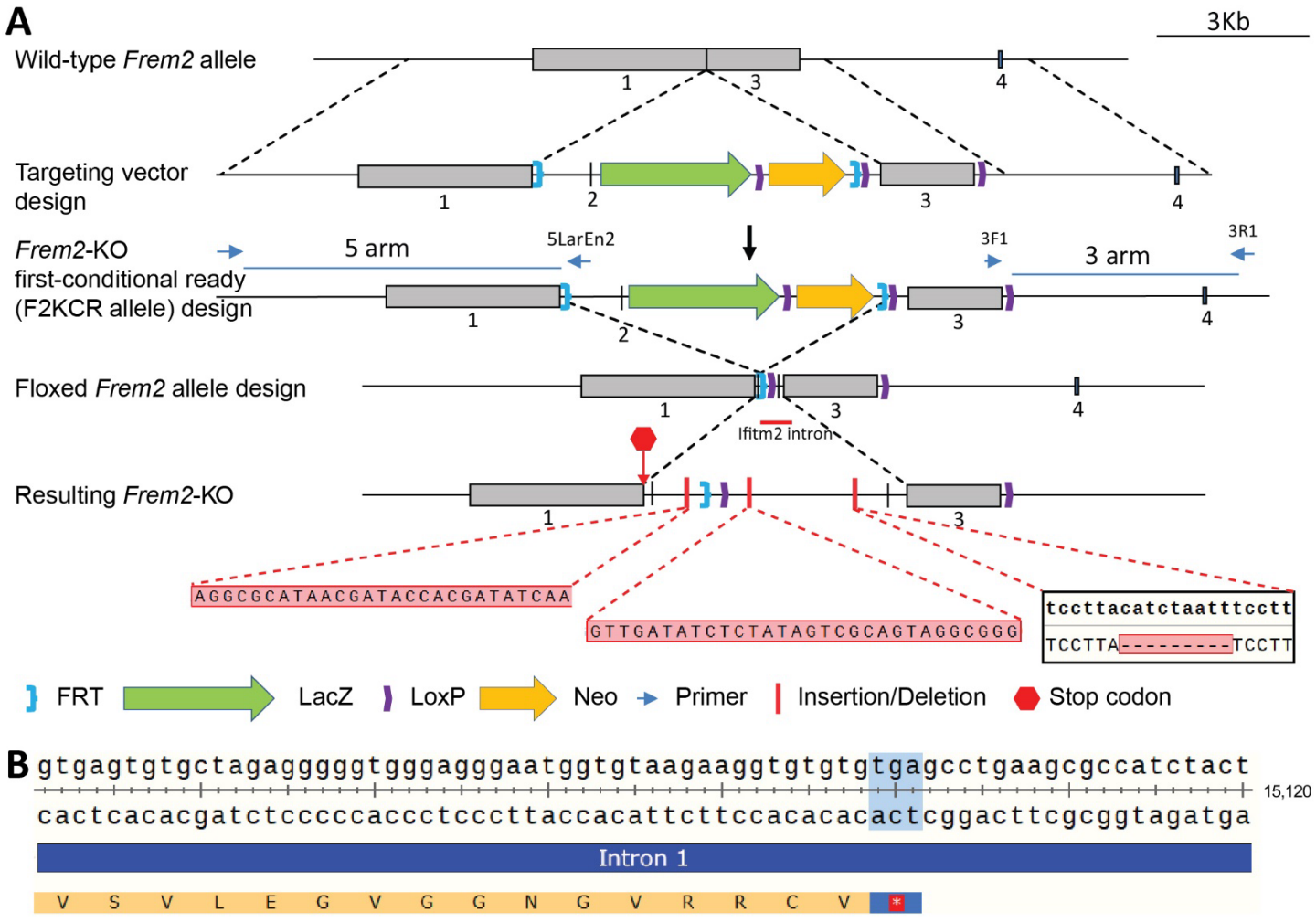

321

322 **Figure 1. *Frem2-KO* mouse design strategy. A,** ES cells were with a *Frem2-KO*-first conditional ready allele was used to
323 generate the Floxed-*Frem2* mouse line. The floxed allele shows exon 2 deleted as a result of the FLP and FRT system. The
324 conditional-KO mouse displays the in-frame mutations (shown as a red line) and their sequences: two insertions (27 bp and
325 30 bp) and one deletion (9 bp). **B,** A portion of the sequence (15100-15120 bp) for exon 1 of Floxed-*Frem2* is displayed.
326 The premature TGA stop codon sequence is highlighted in blue near the middle of the reading frame.

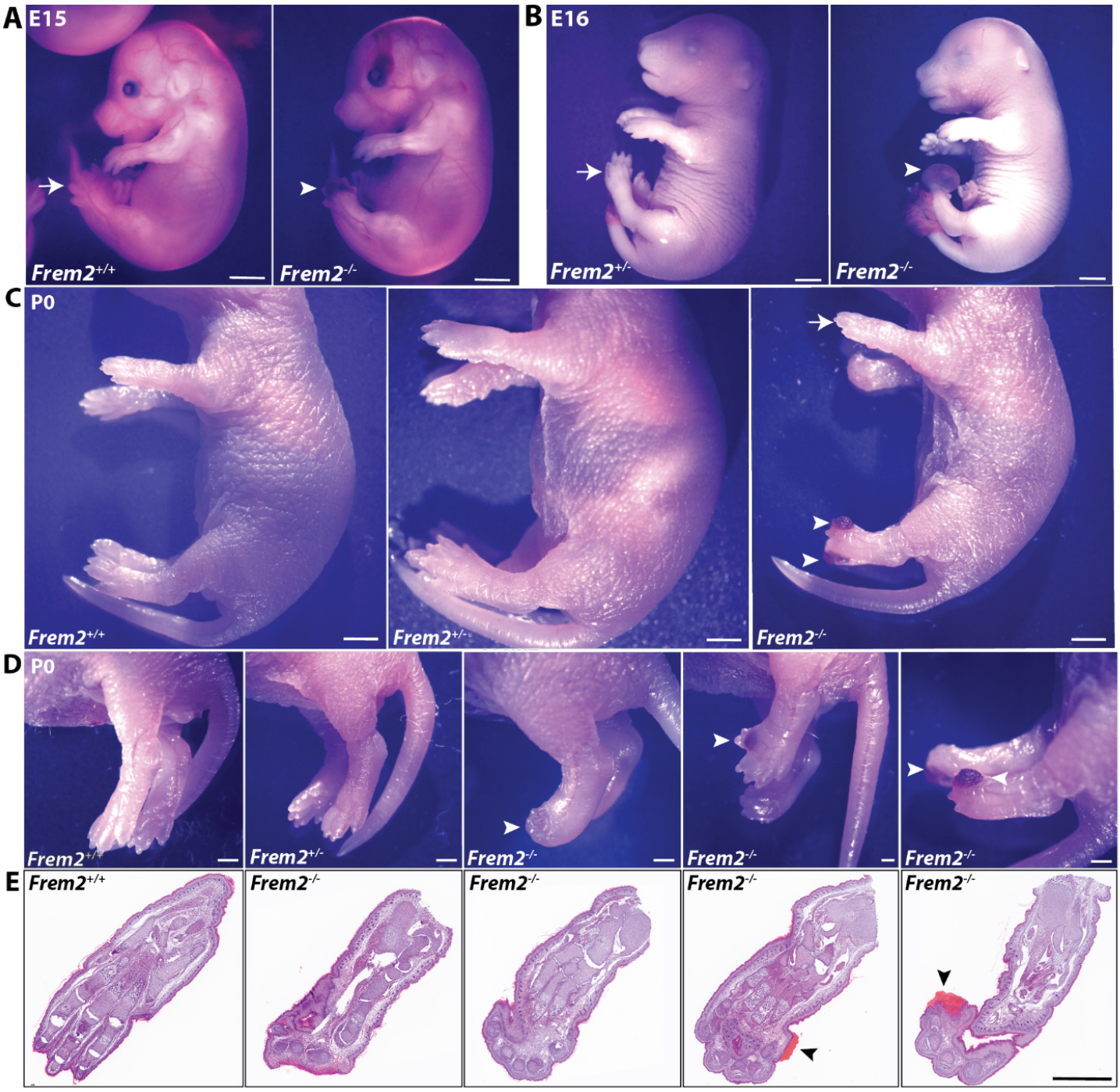

Figure 2. *Frem2-KO* fetuses and newborn pups exhibit hemorrhagic blisters and syndactyly. A, *Frem2*$^{+/+}$(wild-type) E15 fetus (*left*) with normal paws (*arrow*) and a *Frem2*$^{-/-}$ (KO) littermate (*right*) with a blood-filled blister over the digits (*arrowhead*). **B,** E16 heterozygous *Frem2*$^{+/-}$ fetus (*left*) with normal paws (*arrow*) and E16 *Frem2*$^{-/-}$ fetus littermate (*right*) with a large hemorrhagic bleb on the digits (*arrowhead*). **C,** P0 *Frem2*$^{+/+}$ (*left*) and *Frem2*$^{+/-}$ (*middle*) have normal paws, and a *Frem2*$^{-/-}$ (*right*) has dried blood-filled blisters on both hind paws. **D,** Newborn *Frem2*$^{-/-}$ pups with a malformation of hind limbs, soft-tissue syndactyly, and blood-filled blisters on digits. Reference *Frem2*$^{+/+}$ and *Frem2*$^{+/-}$ paws showing normal paw morphology. **E,** Hematoxylin and eosin-stained histology section of paws from wild-type (*Frem2*$^{+/+}$) and several knockout (*Frem2*$^{-/-}$) mice with limb malformation and blood-filled blisters (*arrowhead*). Scale bars: (*A*)-(*C*): 2 mm, (*D*, *E*): 1 mm.

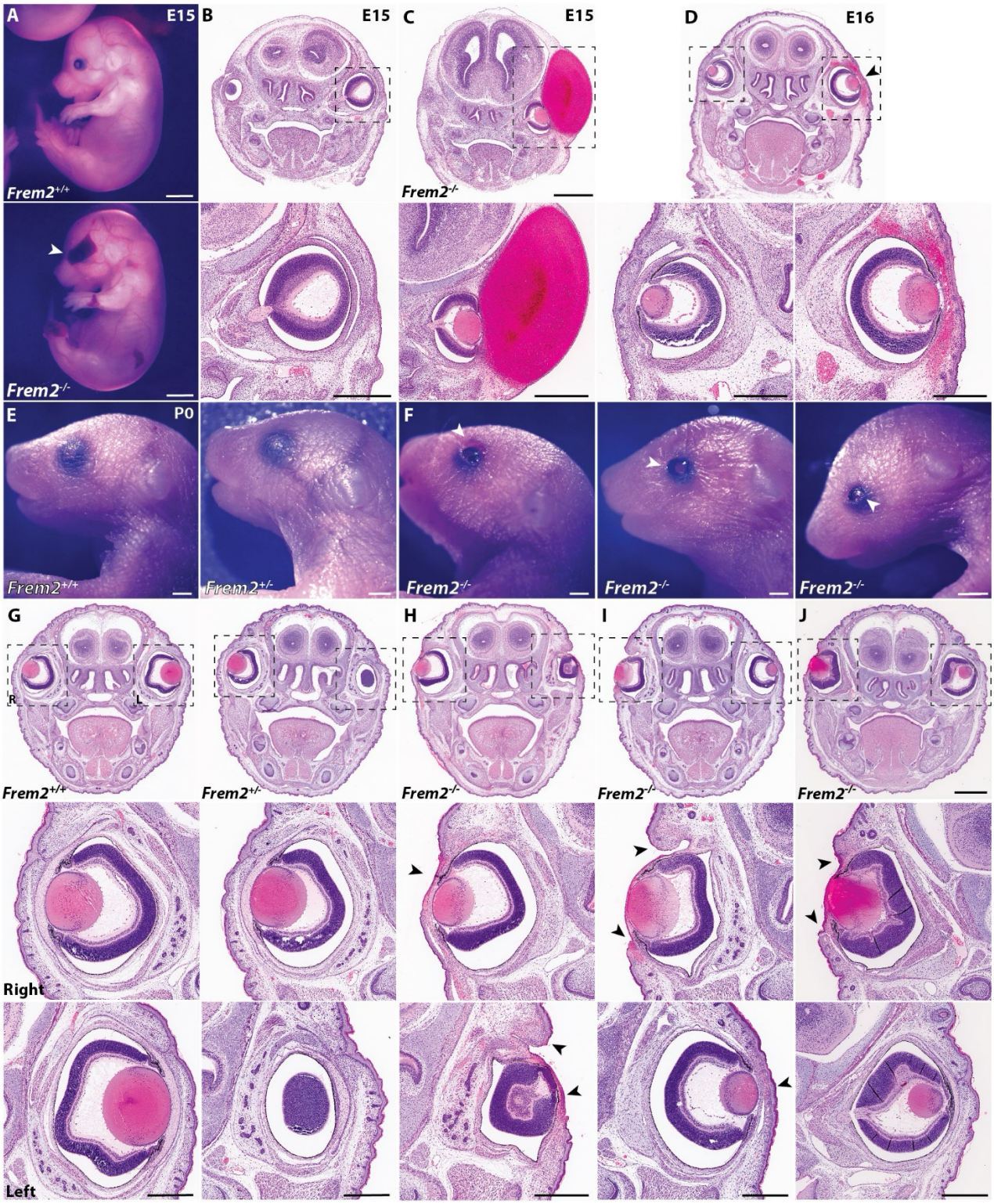

Figure 3. *Frem2-KO* mice lack eyelids and develop blood-filled blisters covering their eyes. **A,** Gross image of an E15 *Frem2*$^{+/+}$ fetus with a normal eye, and a *Frem2*$^{-/-}$ fetus (*below*) with a blood-filled blister (*arrowhead*) covering the eye. **B,** Hematoxylin and eosin-stained coronal head section of a *Frem2*$^{+/-}$ E15 fetus and a higher magnification image below displays normal eyelid morphology. **C,** Histological section of a *Frem2*$^{-/-}$ E15 fetus with a blood-filled blister and a higher magnification image displays the absence of the cornea and eyelid. **D**, Low and high magnification histology images of a *Frem2*$^{-/-}$ E16 fetus with a normal right eyelid and a hemorrhage covering the left eyelid. **E**, Gross images of *Frem2*$^{+/+}$ and *Frem2*$^{+/-}$ P0 pups show normal eyelids. **F**, Gross images of *Frem2*$^{-/-}$ P0 pups display missing eyelids (*arrowhead*). **G**, Histology sections of P0 *Frem2*$^{+/+}$ and *Frem2*$^{+/-}$ heads with normal eyelids and their corresponding higher magnification images of the right (*R*) and left (*L*) eyes presented below it. **H,** Histology section of a P0 *Frem2*$^{-/-}$ pup with the thinning of the eyelid (*R*) and a missing eyelid with a hemorrhage over the eye (*L*). **I,** A newborn *Frem2*$^{-/-}$ pup with a missing eyelid (*R*) and thinning of the eyelid (*L*). (*J Frem2*$^{-/-}$ pup with a missing eyelid (*R*) and a normal contralateral eyelid (*L*). *Scale bars:* (*A*): 2 mm, (*B-G*): 1 mm, (*H-J*): 1 mm.

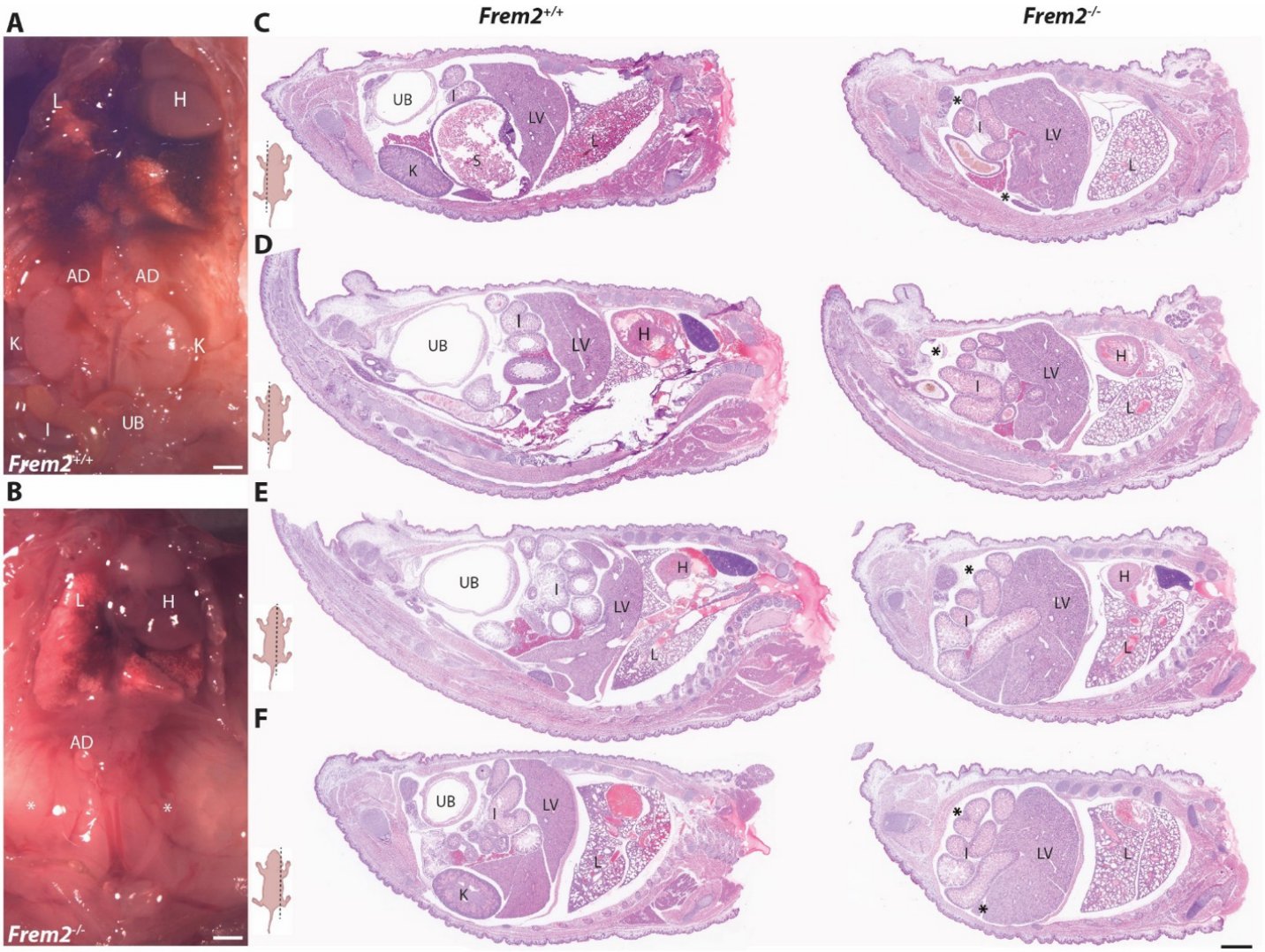

Figure 4. Renal agenesis in *Frem2-KO* pups. Macroscopic images of P0 pups show kidneys (K), adrenal glands (AD), and urinary bladder (UB) present in a *Frem2*$^{+/+}$ pup (*A*) and kidneys and inconspicuous urinary bladder in a *Frem2*$^{-/-}$ pup (*B*). Hematoxylin and eosin-stained parasagittal sections of a *Frem2*$^{+/+}$ (*left column*) and a *Frem2*$^{-/-}$ (*right column*) P0 pup show organs present to the left (*C, D*) and right (*E, F*) of the spinal cord. Locations of the deflated urinary bladders are labeled with asterisks. Sections are from similar regions to compare the presence and morphology of organs. Scale bars: (A, B); 1 mm, (C-F); 3 mm. Labels: AD, adrenal glands; K, kidney; H, heart; LV, liver; LUN, lung; I, intestines; S, stomach; UB, urinary bladder.

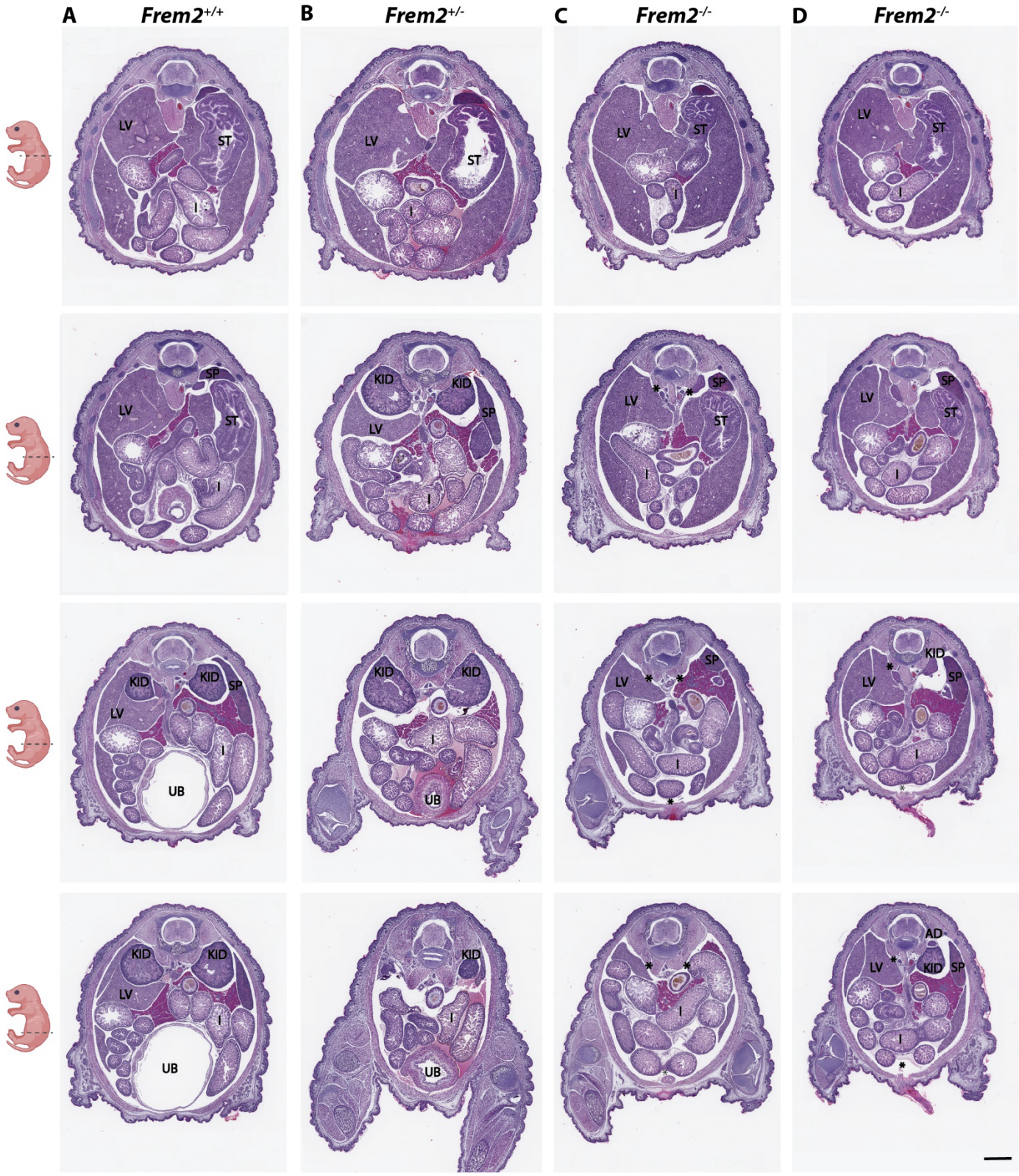

357

358 **Figure 5. Serial sectioning of newborn (P0) *Frem2* pups reveals renal agenesis in knockout mice.** Sections down the
359 columns progress below the diaphragm to the pelvic region from the same pup. Sections across each row correspond to
360 the same region of each pup's body. Hematoxylin and eosin-stained histology sections from *Frem2*$^{+/+}$ (*A*) and *Frem2*$^{+/-}$ (*B*)
361 pups exhibit the presence of both kidneys (KID) and a comparable arrangement of organs. *Frem2*$^{-/-}$ pups display bilateral
362 (*C*) and unilateral renal agenesis (*D*). Locations of missing kidneys are labeled with asterisks. Scale bar: (A-D); 1 mm.
363 Labels: AD, adrenal glands; KID, kidney; LV, liver; LUN, lung; I, intestines; SP, spleen; UB, urinary bladder.

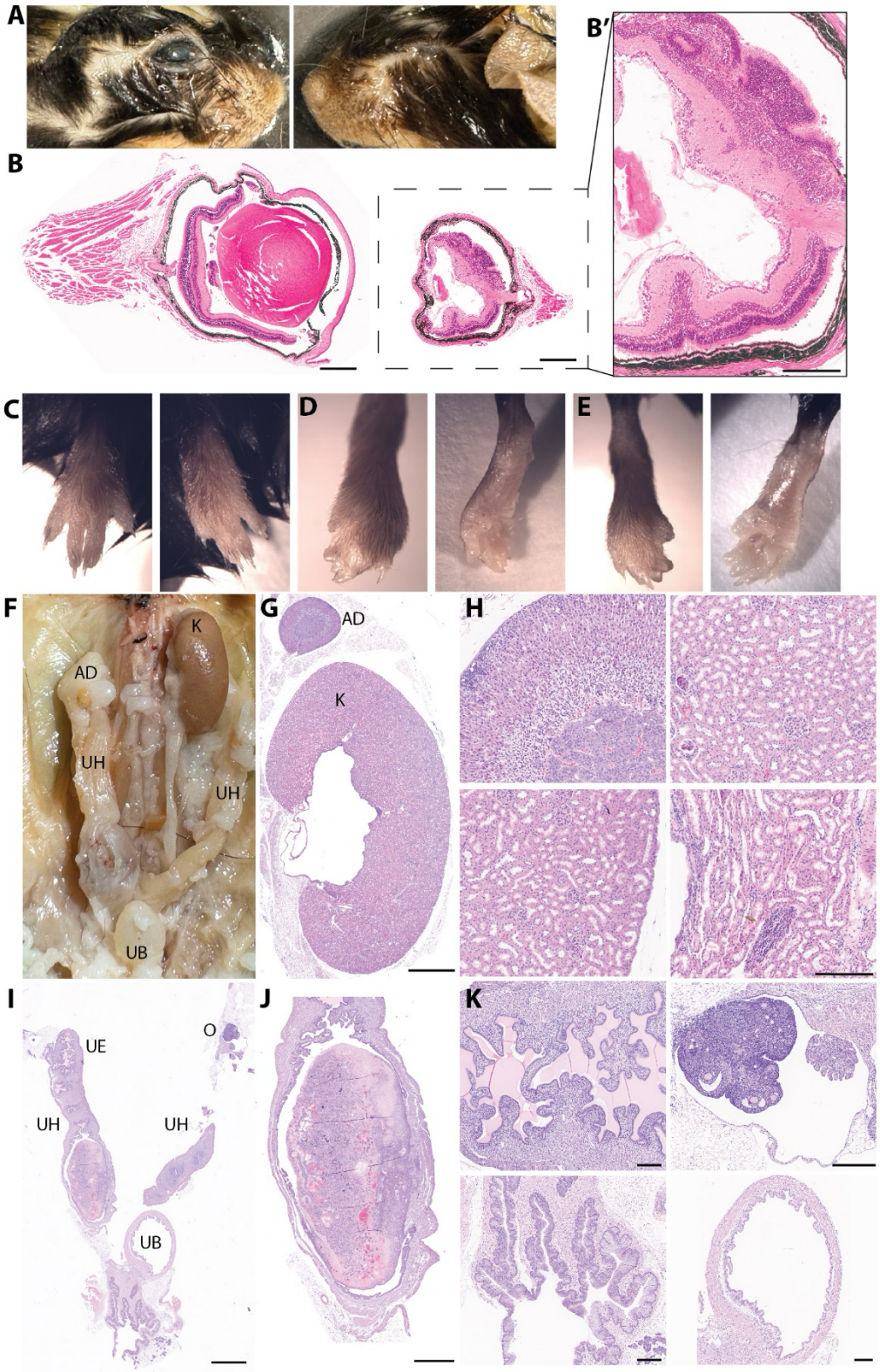

Figure 6. Characterization of the *Frem2-KO* adult mouse. (*A*) Images show the *Frem2*$^{-/-}$ adult mouse with a normal right eye and a left eye affected by cryptophthalmos. (*B*) Hematoxylin and eosin-stained histology section through the middle of the normal right eye and the defective left eye. The defective left eye reveals the lens with reduced thickness size and retinal dysplasia. (B') Higher magnification image of defective left eye showing microphthalmia. (*C*) Images of normal front paws and affected right (*D*) and left (*E*) hind paws by syndactyly. (*F*) The gross anatomy image of the adult *Frem2*$^{-/-}$ mouse shows one left kidney (K), adrenal glands (AD), uterine horns (UH), and urinary bladder (UB) present. (G) Histology section of the normal left kidney and adrenal gland. (H) High-magnification images of different regions of the kidney displaying the tubules, collecting ducts, and nephrons. Histology section displays a placental-like tissue (J) in the right uterine horn (I) of the mouse. (K) High-magnification images of the uterine epithelium (UE), ovaries (O), and urinary bladder (UB). *Scale bars:* (B) 2 mm, (B') 250 um, (G) 3 mm, (H) 500 um, (I) 4 mm, (J) 2 mm, (K) 250 um.

REFERENCES

Alazami, A. M., Shaheen, R., Alzahrani, F., Snape, K., Saggar, A., Brinkmann, B., Bavi, P., Al-Gazali, L. I., & Alkuraya, F. S. (2009). FREM1 mutations cause bifid nose, renal agenesis, and anorectal malformations syndrome. American journal of human genetics, 85(3), 414–418. https://doi.org/10.1016/j.ajhg.2009.08.010. PMID: 19732862; PMCID: PMC2771533.

Anas M. Alazami, Ranad Shaheen, Fatema Alzahrani, Katie Snape, Anand Saggar, Bernd Brinkmann, Prashant Bavi, Lihadh I. Al-Gazali, Fowzan S. Alkuraya. (2009). FREM1 Mutations Cause Bifid Nose, Renal Agenesis, and Anorectal Malformations Syndrome, *The American Journal of Human Genetics.* Volume 85, Issue 3, Pages 414-418, ISSN 0002-9297, https://doi.org/10.1016/j.ajhg.2009.08.010. PMID: 19732862; PMCID: PMC2771533.

Bladt, F., Tafuri, A., Gelkop, S., Langille, L., & Pawson, T. (2002). Epidermolysis bullosa and embryonic lethality in mice lacking the multi-PDZ domain protein GRIP1. *Proceedings of the National Academy of Sciences*, *99*(10), 6816-6821. https://doi.org/10.1073/pnas.092130099. PMID: 11983858; PMCID: PMC124486.

Bouaoud, J., Olivetto, M., Testelin, S., Dakpe, S., Bettoni, J., & Devauchelle, B. (2020). Fraser syndrome: review of the literature illustrated by a historical adult case. *International journal of oral and maxillofacial surgery*, *49*(10), 1245–1253. https://doi.org/10.1016/j.ijom.2020.01.007. PMID: 31982235.

Graw J. (2019). Mouse models for microphthalmia, anophthalmia and cataracts. *Human genetics*, *138*(8-9), 1007–1018. https://doi.org/10.1007/s00439-019-01995-w. PMID: 30919050; PMCID: PMC6710221.

Ian Smyth , Peter Scambler. (2005) The genetics of Fraser syndrome and the blebs mouse mutants, *Human Molecular Genetics*, Volume 14, Issue suppl_2, Pages R269–R274, https://doi.org/10.1093/hmg/ddi262. PMID: 16244325.

Jadeja, S., Smyth, I., Pitera, J. E., Taylor, M. S., van Haelst, M., Bentley, E., McGregor, L., Hopkins, J., Chalepakis, G., Philip, N., Perez Aytes, A., Watt, F. M., Darling, S. M., Jackson, I., Woolf, A. S., & Scambler, P. J. (2005). Identification of a new gene mutated in Fraser syndrome and mouse myelencephalic blebs. *Nature genetics*, 37(5), 520–525. https://doi.org/10.1038/ng1549. PMID: 15838507.

Kamba T, Higashi S, Kamoto T, Shisa H, Yamada Y, Ogawa O, Hiai H. (2001) Failure of ureteric bud invasion: a new model of renal agenesis in mice. Am J Pathol. 159(6):2347-53. doi: 10.1016/S0002-9440(10)63084-2. PMID: 11733383; PMCID: PMC1850611.

Kerecuk L, Long DA, Ali Z, Anders C, Kolatsi-Joannou M, Scambler PJ, Woolf AS. (2012) Expression of Fraser syndrome genes in normal and polycystic murine kidneys. *Pediatr Nephrol*. 27(6):991-8. doi: 10.1007/s00467-012-2100-5. PMID: 21993971; PMCID: PMC3337421.

Miller JL, Baschat AA, Rosner M, Blumenfeld YJ, Moldenhauer JS, Johnson A, Schenone MH, Zaretsky MV, Chmait RH, Gonzalez JM, Miller RS, Moon-Grady AJ, Bendel-Stenzel E, Keiser AM, Avadhani R, Jelin AC, Davis JM, Warren DS, Hanley DF, Watkins JA, Samuels J, Sugarman J, Atkinson MA. (2023) Neonatal Survival After Serial Amnioinfusions for Bilateral Renal Agenesis: The Renal Anhydramnios Fetal Therapy Trial. JAMA. 5;330(21):2096-2105. doi: 10.1001/jama.2023.21153. PMID: 38051327; PMCID: PMC10698620.

Pavlakis, E., Chiotaki, R., & Chalepakis, G. (2011). The role of Fras1/Frem proteins in the structure and function of basement membrane. *The international journal of biochemistry & cell biology*, 43(4), 487–495. https://doi.org/10.1016/j.biocel.2010.12.016. PMID: 21182980

Pavlakis, E., Makrygiannis, A.K., Chiotaki, R. et al. (2008) Differential localization profile of Fras1/Frem proteins in epithelial basement membranes of newborn and adult mice. *Histochem Cell Biol* 130, 785–793. https://doi.org/10.1007/s00418-008-0453-4. PMID: 18563433.

Petrou, P., Makrygiannis, A. K., & Chalepakis, G. (2008). The Fras1/Frem family of extracellular matrix proteins: structure, function, and association with Fraser syndrome and the mouse bleb phenotype. Connective tissue research, 49(3), 277–282. https://doi.org/10.1080/03008200802148025. PMID: 18661360.

Short, K., Wiradjaja, F., & Smyth, I. (2007). Let's stick together: the role of the Fras1 and Frem proteins in epidermal adhesion. IUBMB life, 59(7), 427–435. https://doi.org/10.1080/15216540701510581. PMID: 17654118.

Slavotinek, A. M., & Tifft, C. J. (2002). Fraser syndrome and cryptophthalmos: review of the diagnostic criteria and evidence for phenotypic modules in complex malformation syndromes. *Journal of medical genetics*, *39*(9), 623–633. https://doi.org/10.1136/jmg.39.9.623. PMID: 12205104; PMCID: PMC1735240.

Smyth, I., Du, X., Taylor, M. S., Justice, M. J., Beutler, B., & Jackson, I. J. (2004). The extracellular matrix gene Frem1 is essential for the normal adhesion of the embryonic epidermis. *Proceedings of the National Academy of Sciences of the United States of America*, *101*(37), 13560–13565. https://doi.org/10.1073/pnas.0402760101. PMID: 15345741; PMCID: PMC518794.

Timmer, J. R., Mak, T. W., Manova, K., Anderson, K. V., & Niswander, L. (2005). Tissue morphogenesis and vascular stability require the Frem2 protein, product of the mouse myelencephalic blebs gene. *Proceedings of the National Academy of Sciences of the United States of America*, 102(33), 11746–11750. https://doi.org/10.1073/pnas.0505404102. PMID: 16087869; PMCID: PMC1183448.

Zhang, X., Wang, R., Wang, T., Zhang, X., Dongye, M., Wang, D., Wang, J., Li, W., Wu, X., Lin, D., & Lin, H. (2021). The Metabolic Reprogramming of Frem2 Mutant Mice Embryos in Cryptophthalmos Development. *Frontiers in cell and developmental biology*, 8, 625492. https://doi.org/10.3389/fcell.2020.625492. PMID: 33490088; PMCID: PMC7820765.

SUPPLEMENTAL MATERIALS

Supplemental Movie 1. Serial sectioning of newborn *Frem2*$^{+/+}$ pup 1. Movie of images from hematoxylin and eosin-stained histology sections from a *Frem2*$^{+/+}$ newborn pup. Transverse sections through the body begin inferior to the front paws and end superior to the hind paws displaying major organs including the lungs, heart, liver, intestines, the urinary bladder, and kidneys. Scale bar: 2 mm

Supplemental Movie 2. Serial sectioning of newborn *Frem2*$^{+/+}$ pup 2. Movie of images from hematoxylin and eosin-stained histology sections from a *Frem2*$^{+/+}$ newborn pup. Transverse sections through the body begin inferior to the front paws and end superior to the hind paws displaying major organs including the lungs, heart, liver, intestines, the urinary bladder, and kidneys. Scale bar: 2 mm.

Supplemental Movie 3. Serial sectioning of newborn *Frem2*$^{+/-}$ pup 1. Movie of images from hematoxylin and eosin-stained histology sections from a *Frem2*$^{+/-}$ newborn pup. Transverse sections through the body begin inferior to the front paws and end superior to the hind paws displaying major organs including the lungs, heart, liver, intestines, the urinary bladder, and kidneys. Scale bar: 2 mm.

Supplemental Movie 4. Serial sectioning of newborn *Frem2*$^{+/-}$ pup 2. Movie of images from hematoxylin and eosin-stained histology sections from a *Frem2*$^{+/-}$ newborn pup. Transverse sections through the body begin inferior to the front paws and end superior to the hind paws displaying major organs including the lungs, heart, liver, intestines, the urinary bladder and kidneys. Scale bar: 2 mm.

Supplemental Movie 5. Serial sectioning of newborn *Frem2*$^{-/-}$ pup 1. Movie of images from hematoxylin and eosin-stained histology sections from a *Frem2*$^{-/-}$ newborn pup. Transverse sections through the body begin inferior to the front paws and end superior to the hind paws displaying major organs. No urinary bladder can be easily identified and no kidneys are present. Scale bar: 2 mm.

Supplemental Movie 6. Serial sectioning of newborn *Frem2*$^{-/-}$ pup 2. Movie of images from hematoxylin and eosin-stained histology sections from a *Frem2*$^{-/-}$ newborn pup. Transverse sections through the body begin inferior to the front paws and end superior to the hind paws, displaying all major organs. No urinary bladder can be easily identified and only the left kidney is present. Scale bar: 2 mm.