Improved detection of pre-symptomatic, non-central nervous system TDP-43 pathology in amyotrophic lateral sclerosis using RNA aptamer

Fergal M. Waldron[1], Tatiana Langerová[1], Fiona L. Read[1], Holly Spence[1], Katie Hanna[1], Kristine Roberts[1,2], Samuel B. Pattle[3], Jenna M. Gregory[1,2]*

*Correspondence to: jenna.gregory@abdn.ac.uk

Affiliations

[1]Institute of Medical Sciences, University of Aberdeen, Aberdeen, UK.

[2]NHS Grampian Tissue Biorepository, Department of Pathology, Aberdeen, UK.

[3]Department of Pathology, NHS Fife, Victoria Hospital, Kirkcaldy, UK.

Keywords:

TDP-43; RNA aptamer; Amyotrophic lateral sclerosis; Pre-symptomatic; Non-motor pathology

Abstract

A recently developed TDP-43 RNA aptamer (TDP-43^{APT}) with greater sensitivity and specificity for detecting pathological TDP-43, compared to currently available antibodies, has revealed novel pathologies in ALS, including early nuclear aggregation preceding disease symptoms. Moreover, whilst ALS has traditionally been considered a disease of the central nervous system (CNS), non-CNS manifestations of disease are gaining increasing awareness. Employing an antibody approach to detect pathologically phosphorylated TDP-43, we previously uncovered pre-symptomatic, systemic TDP-43 pathology in archived non-CNS tissue, taken during life. Here, using two recently developed tools, (i) TDP-43^{APT} to identify pathological TDP-43, and (ii) *in situ* hybridisation probes directed to a splice target of TDP-43 (*Stathmin-2*) to demonstrate concurrent loss of TDP-43 function, we re-examined non-CNS tissues from a variety of organ systems from this cohort of *ante-mortem* tissue taken from people who went on to develop ALS. Amongst non-CNS organs with evidence of pathological TDP-43 aggregation, and concurrent TDP-43 loss-of-function, occurring prior to motor symptom onset, were colon, skin, muscle, blood vessels, gallbladder, and lymph nodes. Cell types affected include sebocytes, endothelial cells, peripheral neuronal cells, dendritic cells, chondrocytes - all cells with a shared cell linage from the neural crest, implying a neurodevelopmentally-defined cell-type specific predisposition to TDP-43 pathology. This cell-type predisposition, along with TDP-43 pathology identified in tissue mobile, circulating inflammatory cells (T-cells and macrophages) may help to guide early, pre-symptomatic peripheral biopsy and biomarker development. Our findings extend the number of tissue and cell types with pathological TDP-43 aggregation outside of the CNS prior to motor symptoms, showing this is a common feature of ALS, affecting a number of organ systems that are readily accessible for biopsy. We propose that skin and gastro-intestinal tract tissues provide the most promising potential for ease of biopsy, with potential applications for ALS diagnosis and monitoring prior to motor symptom emergence amongst general and at-risk populations.

Graphical Abstract

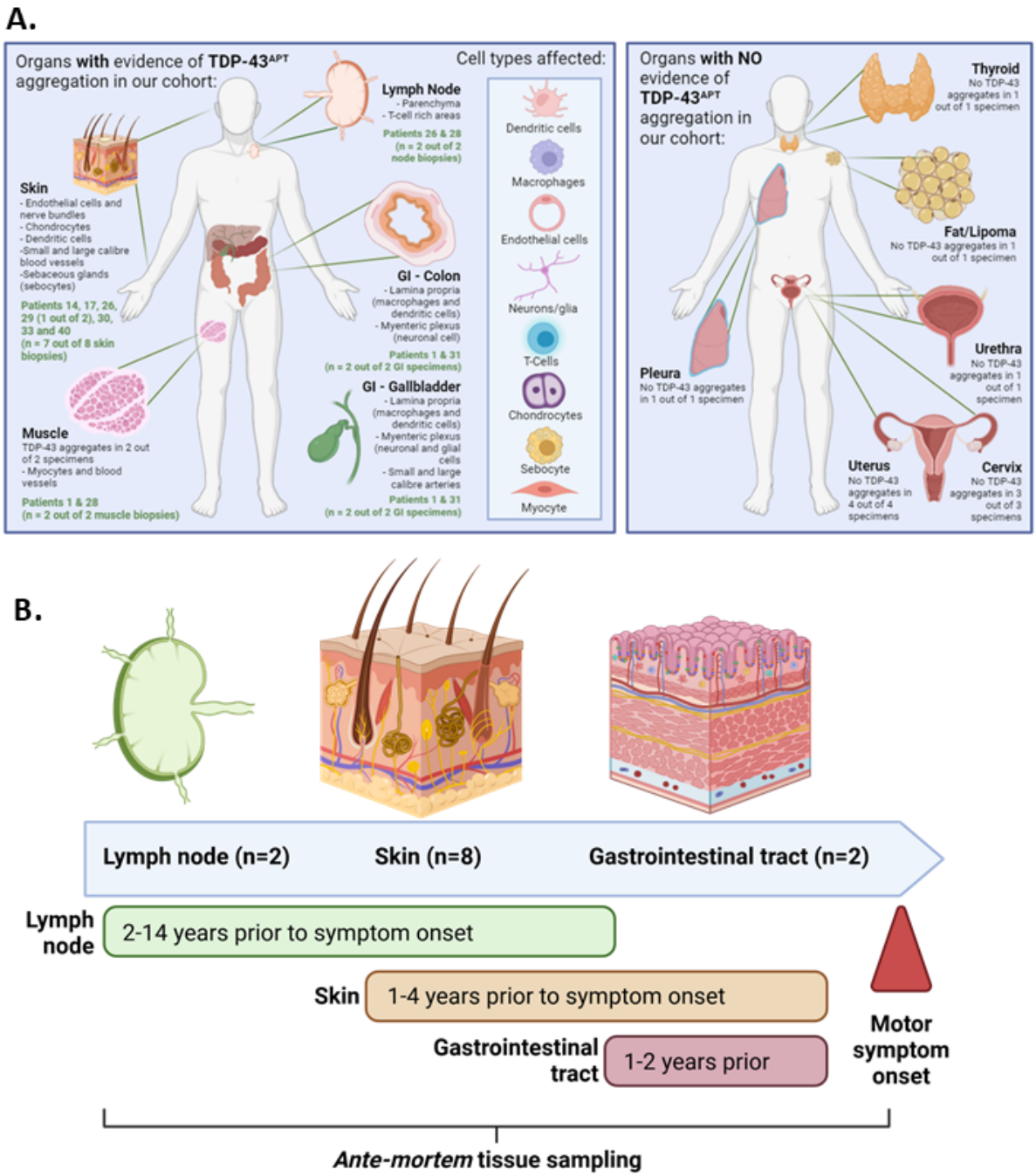

Graphical Abstract: TDP-43 RNA aptamer detects non-CNS pathological TDP-43 from ante-mortem peripheral tissues cohort taken from ALS patients prior to ALS diagnosis. A) Cartoon depicting organs with, and without, pathological TDP-43 detected by TDP-43 RNA aptamer. B) Timeline depicting the number of years prior to motor symptom onset that pathological TDP-43 could be detected by TDP-43 RNA aptamer for lymph node, skin and gastrointestinal tract ante-mortem tissues.

Introduction

Pathological protein misfolding and accumulation is a histological feature of many neurodegenerative diseases (Bossy-Wetzel *et al*., 2004). The hallmark proteinopathy seen in the majority of people with amyotrophic lateral sclerosis (ALS) is the aberrant accumulation of the TAR-DNA binding protein 43 kDa (TDP-43) in both the nucleus and cytoplasm (Huang *et al*., 2024, Neumann *et al*., 2006, Spence *et al*., 2024). Previously thought of as a disease affecting only the motor system, non-motor symptoms of ALS are now becoming better recognised (see Beswick *et al*., 2022, Fang *et al*., 2017, Nash and Sitty, 2021, Shojaie *et al*., 2023). These non-motor symptoms include cognitive symptoms of frontotemporal dementia (McHutchison *et al*., 2024), and systemic symptoms affecting a wider range of organ systems than the brain alone — extensive evidence of non-motor symptoms in non-CNS tissues in ALS is provided by pathological, patient reported, epidemiological, and clinical investigative studies, which extend to several organ systems and involvements including the gastrointestinal system (Beswick *et al*., 2023, Conroy *et al*., 2023, Günther *et al*., 2016, Marsden *et al*., 2023, Nakamura *et al*., 2012, Nicholson *et al*., 2021, Niu *et al*., 2025, Nübling *et al*., 2014, Pattle *et al*., 2023, Samara *et al*., 2021, Sonnenberg *et al*., 1994, Sun *et al*., 2021, The ALS Association, 2019, Toepfer, 1999, Toepfer *et al*., 1999, Toepfer *et al*., 1997), skin (Dalla Bella *et al*., 2016, deCarvalho *et al*., 2021, Hammad *et al*., 2007, Hayashi *et al*., 2007, Kolde *et al*., 1996, Nolano *et al*., 2024, Nolano *et al*., 2017, Ono *et al*., 1998, Ono *et al*., 1986, Paré and Gros-Louis, 2017, Pattle *et al*., 2023, Pugdahl *et al*., 2007, Truini *et al*., 2015, Wallace *et al*., 2014, Weis *et al*., 2011), bladder (Nübling *et al*., 2014), blood vessels (Kolde *et al*., 1996, Omar *et al*., 2025), lymph nodes (Pattle *et al*., 2023), skeletal muscle (Cykowski *et al*., 2018, Kurashige *et al*., 2022, Kurashige *et al*., 2025, Mori *et al*., 2019, Zhang *et al*., 2024) and myocardial muscle (Cykowski *et al*., 2018, Mori *et al*., 2019, Zhang *et al*., 2024). Crucially, non-CNS pre-symptomatic TDP-43 pathologies have been shown in ALS by identifying toxic TDP-43 gain-of-function (Kurashige *et al*., 2022, Pattle *et al*., 2023, Zhang *et al*., 2024), or TDP-43 loss-of-function through splicing repression (Irwin *et al*., 2024) prior to clinical symptoms, and sometimes over a decade before (Pattle *et al*., 2023). This indicates that early non-motor symptoms, and non-CNS tissues along with fluid biomarkers, provide potential for early diagnosis of ALS.

Cognitive and systemic symptoms correspond well with accumulation of TDP-43 aggregates detectable using classical antibody-based approaches in non-motor brain regions in the central nervous system (CNS) (Gregory *et al*., 2020b) and in different organs, such as the skin and GI tract in non-CNS tissues (Pattle *et al*., 2023). However, antibody-based detection may be limiting our ability to translate these findings into biomarker development strategies, due to impaired specificity (poor classification of negatives (Gregory *et al*., 2020b)), limiting diagnostic accuracy.

We have recently improved our ability to detect TDP-43 pathology beyond demonstration of TDP-43 aggregates alone through the combined application of, (i) a TDP-43 RNA aptamer (Zacco *et al*., 2022) optimised for use in histopathological staining of human tissue (Spence *et al*., 2024, Waldron *et al*., 2024) to detect TDP-43 pathology (TDP-43^{APT}), and (ii) *in situ* hybridisation probes for cryptic exons of *STMN-2,* thereby simultaneously demonstrating TDP-43 loss-of-function (cryptic exon detection) in tissues, and increasing the accuracy of detection of TDP-43 gain-of-function (aggregation events detected by TDP-43^{APT} (Spence *et al*., 2024)). Together, these new tools facilitate the detection of a wider range of pathological events compared to classical antibody approaches alone.

Here, we revisit a previously published cohort of ante-mortem tissue taken from people who went on to develop ALS, where the investigation of non-CNS tissues using classical antibodies to TDP-43 (pTDP-43 and C-terminal antibodies) demonstrated organs with and without systemic, non-CNS, TDP-43 pathology burden (Pattle *et al*., 2023). In the study presented here, we take advantage of the improved specificity and sensitivity of our recently published TDP-43 RNA aptamer (TDP-43^{APT}) (Spence *et al*., 2024), in combination with *STMN-2* cryptic exon *in situ* hybridisation probes (Spence *et al*., 2024), to re-examine this published *ante-mortem* tissue cohort and establish the burden of systemic, non-CNS, TDP-43 pathology with greater sensitivity and specificity, and to assess whether TDP-43 loss-of-function effects are detectable in these non-CNS tissues. Our aim was to identify, with improved tools, readily accessible organs with evidence of early TDP-43 pathology that could be used as sites for future pre-symptomatic peripheral diagnosis or for target engagement in future clinical trials, and to shed further light on possible pathomechanisms underlying the diverse non-CNS symptomatology emerging in ALS.

Methods

Tissue provision and ethics

All tissue was requested from the Lothian NRS BioResource RTB ethical approval 15/ES/0094, covering use of residual tissue surplus to diagnostic requirements taken as standard of care with approval number SR1684. All archived formalin-fixed, paraffin-embedded (FFPE) tissue material with an NHS Lothian diagnostic code (e.g. any tissue samples taken for diagnostic or surgical purposes at any time during a patient's life, under the care of NHS Lothian and NHS Fife) was requested for 48 patients with known diagnosis of sporadic ALS or ALS with a *C9orf72* hexanucleotide repeat expansion (for detailed cohort information, see Figure 1A and Table 1 of Pattle *et al*., 2023). The tissue was then assessed for sufficiency by two independent histopathologists (SBP & JMG) using a single H&E. No identifiable

clinical or demographic data were used in this study. Tissue provided by the BioResource had been fixed in 10% formalin for a minimum of 72 hours, then dehydrated in an ascending alcohol series (70–100%) followed by three 4-hour washes in xylene. Three successive 5-hour paraffin wax embedding stages were performed, with subsequent cooling and sectioning of tissue on a Leica microtome into 4 µm thick serial sections that were collected on Superfrost (ThermoFisher Scientific) microscope slides. Sections were dried overnight at 40°C before staining. Bleach treatment was performed (on skin cases where warranted) by incubating slides immediately post antigen retrieval in 10% hydrogen peroxide for 12 hours overnight. This step was followed by the normal protocol in full, including the additional 3% hydrogen peroxide step used to block endogenous peroxidases, following a previously published and optimised protocol (Lawrence Li *et al*., 1999).

Immunohistochemistry and BaseScope™ in situ hybridisation

Sections were dewaxed using successive xylene washes followed by alcohol hydration and treatment with picric acid for removal of formalin pigment. For TDP-43^{APT} staining, antigen retrieval was carried out in citric acid buffer (pH 6) in a pressure cooker for 15 min, after which immunostaining was as described previously (Spence *et al*., 2024, Waldron *et al*., 2024). *In situ* hybridisation was performed on tissue sections using BaseScope™ reagents (Advanced Cell Diagnostics) as per the manufacturer's instructions (Wang *et al*., 2012) and adapted as described previously (Gregory *et al*., 2020a). Probe hybridisation was performed using BaseScope™ probes for *STMN-2* CE mRNA transcripts (catalogue number 1048231-C1). Slides were counterstained using haematoxylin and lithium carbonate, washed in xylene, and coverslips were mounted using DPX Mountant. Slides were imaged using an EVOS M5000 microscope using brightfield settings at 40x magnification.

Results

Improved sensitivity of TDP-43^{APT} facilitates wider detection of TDP-43 pathology in peripheral tissues and cell types

Using a more sensitive and specific tool (TDP-43^{APT}) than currently available antibodies to detect TDP-43 pathology, we examined tissue from 8 organ systems of 13 people who later went on to develop ALS (sALS n=12, C9-ALS n=1; for detailed cohort information, see Figure 1A and Table 1 of Pattle *et al*., 2023). Many organs that we have shown previously to contain TDP-43 aggregates (using less sensitive antibody-based methods) such as the gastrointestinal tract (gallbladder and colon) and lymph nodes (Pattle *et al*., 2023) also exhibited TDP-43 pathology here, as defined by the presence of both TDP-43

aggregates and *STMN-2* cryptic exons (Figure 1A). In addition, now using TDP-43^{APT}, we now show (i) TDP-43 pathology in muscle biopsies, that was previously not identifiable, and (ii) more consistently detectable TDP-43 pathology in all skin (n=7/8 biopsies from a total of 7 patients; previously 2/8 biopsies from 7 patients in Pattle *et al*., 2023) and lymph node biopsies (2/2; previously 1/2 in Pattle *et al*., 2023) in the cohort. Organs for which we detected no evidence of TDP-43 pathology included the pleura, the bladder, the female reproductive tract and the thyroid (Figure 1A). Whilst we did not detect TDP-43 in these organs with the TDP-43 RNA aptamer (or previously with TDP-43 antibodies; Pattle *et al*., 2023), the numbers of individuals and samples for these organ systems were low, therefore further work to investigate involvement of these under-represented organs may be warranted.

TDP-43^{APT} consistently detects TDP-43 pathology in skin biopsies with improved accuracy compared to antibody approaches

Seven individuals had undergone a skin biopsy prior to symptom onset, ranging from 48 months prior to symptom onset through to the same year as symptom onset (median 24 months; Figure 1B). We detected TDP-43 pathology by TDP-43^{APT} staining in all seven individuals (Supplementary figure 1), most frequently observing pathology within dendritic cells of the dermis, peripheral nerve bundles and small dermal blood vessels (Figure 2A). However, one individual had two biopsies, one with pathology and one without (Figure 2B). This individual, who had a *C9orf72* mutation, had two biopsies taken from the same site (case 29; Supplementary Figure 1). The first biopsy was taken 36 months prior to symptom onset and the second was taken from the same site 12 months prior to symptom onset (Figure 2B). The first biopsy showed no evidence of TDP-43 pathology, however, the second biopsy showed florid TDP-43 pathology within the dendritic cells of the dermis, the sebocytes within the sebaceous glands and within the peripheral nerve bundles surrounding the sebaceous glands. The peripheral nerve pathology was confirmed using *STMN-2* cryptic exon *in situ* hybridisation probes detecting neuron-specific TDP-43 loss of function (Figure 2C).

Muscle biopsy reveals TDP-43 pathology in myocytes and surrounding neurovascular bundles

pTDP-43 antibody staining failed to identify TDP-43 aggregates in both muscle biopsies in this cohort (Figure 3A). However, a serial section from each biopsy stained with TDP-43^{APT} revealed TDP-43 puncta within, (i) the cytoplasm of the myocytes (sarcoplasm), and (ii) the myocyte nuclei (myonuclei) which are dispersed along the inner surface of the sarcolemma at the periphery of each fibre (Figure 3A &

3B). Furthermore, TDP-43^{APT} pathology can be visualised within the neurons of the peripheral nerve bundles running between fascicles (Figure 3C), confirmed by *in situ* hybridisation detecting a neuron-specific splice target of TDP-43 called *STMN-2* (Figure 3D). Loss of TDP-43 function (by virtue of its pathogenic aggregation state) leads to loss of cryptic exon suppression and therefore *STMN-2* cryptic exons can be detected by *in situ* hybridisation (Figure 3D; Supplementary Figure 2).

Improved sensitivity of TDP-43^{APT} facilitates detection of TDP-43 pathology in a wider range of cell types including sebocytes and myocytes

In addition to the extensive list of non-CNS cell types from which we were able to identify pathological TDP-43 using classical antibody approaches (i.e. dendritic cells, macrophages, endothelial cells, T-cells and chondrocytes; see Pattle *et al*., 2023), improved sensitivity of TDP-43^{APT} here allowed for the detection of pathological TDP-43 sebocytes (see Figure 2B), and myocytes (see Figure 3B), not previously detected.

Aggregate-laden macrophages present across non-CNS tissues

Amongst non-CNS tissues examined here, we note the presence of morphologically abnormal macrophages. Aberrant morphologies include aggregate-laden macrophages, staining positively for TDP-43 pathology, and macrophages full of large vacuoles indicative of lysosomal dysfunction. We observed such aberrant macrophage morphologies in gastrointestinal tract, skin, and lymph node specimens (Figure 5) – all of which were positive for pathological TDP-43 detected with RNA aptamer.

Blood vessel involvement by TDP-43 pathology in pre-symptomatic ALS

All of the peripheral biopsy samples in the cohort included a contingent of small blood vessels (mostly arterioles, venules and small veins as per normal anatomical composition of tissues). Within the samples with demonstrated TDP-43 pathology, we identified variable blood vessels (including veins, venules and arterioles) that were both involved and uninvolved by TDP-43 pathology (Figure 4). Smooth muscle and endothelial cells both exhibit evidence of TDP-43 pathology in different organs, with skin representing the most accessible site biopsied.

Discussion

In the past 20 years there have been over 125 clinical trials, investigating 76 drugs and recruiting more than 15 000 people with ALS. Whilst our understanding of the pathobiology underpinning ALS over this timeframe has vastly improved, translational success has been much less apparent (Wong *et al*., 2021). The reasons for this are multifactorial but there are several key missing factors in our pursuit of translational success, the first is targeting individuals sufficiently early, prior to substantial neuronal damage, and the second is having access to accurate biomarkers to do this. Targeting of the central nervous system for early diagnosis is not feasible or scalable for point of care biofluid and/or biopsy testing and may only yield diagnostic results too late in the disease process – indeed, between 50-70% of motor neurons can be lost prior to symptom onset (Rowland and Shneider, 2001).

Given the recent increase in awareness of systemic symptoms affecting people with ALS in non-CNS organs such as the skin (Hayashi *et al*., 2007, Nolano *et al*., 2024, Wallace *et al*., 2014) and the gastrointestinal tract (Beswick *et al*., 2023, Conroy *et al*., 2023, Günther *et al*., 2016, Marsden *et al*., 2023, Nakamura *et al*., 2012, Niu *et al*., 2025, Nübling *et al*., 2014, Samara *et al*., 2021, The ALS Association, 2019, Wallace *et al*., 2014), these peripheral tissues may represent a more readily accessible site for biopsy. Our previous approach, to assess peripheral tissues from people who later went on to develop ALS, employed antibodies to detect pathologically phosphorylated TDP-43 (Pattle *et al*., 2023) which whilst specific, lacks sensitivity missing early aggregation events (see Spence *et al*., 2024). Recently we have developed two new tools to improve sensitivity in detecting TDP-43 pathology. The first, a TDP-43 RNA aptamer, which binds only to pathological TDP-43, but with improved sensitivity due to its small size and ability to decorate the surface of pathological aggregates (Spence *et al*., 2024). The second is an *in situ* hybridisation tool used to detect an alternate splice form of *STMN-2* that only arises when TDP-43 splice function is lost (Spence *et al*., 2024). Using these tools, we now have unprecedented power to detect TDP-43 loss- and gain-of-function pathology, in readily accessible organs with evidence of early TDP-43 pathology, for future pre-symptomatic ALS diagnosis.

Organs with evidence of pathological TDP-43 aggregation and TDP-43 loss-of-function, were colon, skin, muscle, blood vessels, gallbladder, and lymph node; pathological TDP-43 aggregation was detectable in tissues taken long before motor symptom onset was recorded clinically. Amongst the seven people who went on to develop ALS for whom skin biopsies were taken prior to disease diagnosis, all seven were positive for pathological TDP-43. In one case of note, an individual with a *C9orf72* mutation had two temporally distinct biopsies from the same skin site. The first biopsy (a diagnostic excision biopsy of skin from the chest, containing a squamous cell carcinoma *in situ*) was taken 36 months prior to symptom onset. 24 months later, 12 months prior to diagnosis with ALS - a

second biopsy (a further diagnostic excision biopsy, containing a benign squamoproliferative lesion) was taken from the same anatomical site as the first. We observed no pathological TDP-43 in the first biopsy but found florid TDP-43 pathology in the second biopsy (taken 12 months prior to diagnosis), identifying a phenoconversion time-window within which skin TDP-43 pathology emerged. Whilst this is only one case, it demonstrates the potential of peripheral biopsy sites as readily accessible and pathologically relevant sites for future diagnosis in ALS. Furthermore, the presence of TDP-43 pathology within the sebaceous glands is reminiscent of individuals with Parkinson's disease (PD), where pre-symptomatic alpha-synuclein pathology can be detected from skin samples (Kuang *et al*., 2024), and lipidomic analysis on skin swabs can differentiate people with PD, Alzheimer's disease (AD) and healthy subjects (Briganti *et al*., 2021). This raises the further possibility of a skin-swab point of care test for neurodegenerative diseases outside of the context of PD.

Blood vessels, along with parts of peripheral nerve bundles, are contained in most peripheral tissue biopsies as per the normal anatomical composition of tissues. In this study, we identified TDP-43 pathology in both vascular and nerve structures. Indeed, vascular TDP-43 pathology has been reported previously, with recent observations demonstrating pathological TDP-43 in the cholesterol plaques of atherosclerotic lesions (Umahara *et al*., 2020) and demonstrating an association with comorbid moderate-to-severe brain arteriolosclerosis (Katsumata *et al*., 2018). Recently (Omar *et al*., 2025) endothelial cell nuclear TDP-43 was found to be reduced in ALS, frontotemporal dementia (FTD) and AD human prefrontal cortex postmortem samples. Furthermore, other groups have demonstrated that loss of TDP-43 function in endothelial cells can lead to classical neuropathological features of neurodegenerative diseases such as neuroinflammation (Arribas *et al*., 2024) and loss of blood-brain-barrier integrity (Cheemala *et al*., 2023), and blood-brain barrier associated gene pathways (Omar *et al*., 2025). Other aggregation-prone proteins, such as beta-amyloid, have also been observed to behave similarly, contributing to small vessel disease (Muir and Smith, 2024). Whether TDP-43 pathology, in this same location, could be contributing to a wider systemic vasculopathy in the same way as beta-amyloid, remains to be proven. However, the ability to detect TDP-43 in end-organ blood vessels, does hold hope for developing peripheral blood- and/or biopsy-based diagnostic tests that could act as early biomarkers of disease in those at risk.

Skeletal muscles represent another organ type with potential for readily accessible peripheral biopsy. In our cohort, we previously did not observe TDP-43 pathology in skeletal muscle biopsies using classical antibody approaches (see Figure 2A of Pattle *et al*., 2023), although other groups have demonstrated detection of TDP-43 pathology using pTDP-43 antibodies (Cykowski *et al*., 2018, Kurashige *et al*., 2022, Mori *et al*., 2019, Zhang *et al*., 2024) in muscle. However, using TDP-43^{APT} here, we do observe TDP-43 pathology in the two skeletal muscle biopsies in our cohort, in similar

pathological distributions to that demonstrated in other cohorts, i.e. within the sarcoplasm of myocytes and within their myonuclei, located on the inside surface of the sarcolemma (Zhang *et al*., 2024). We also demonstrate staining within the adjacent neurovascular bundles. Not only do we demonstrate TDP-43^{APT} pathology in skeletal muscle here, but we also found loss-of-function cryptic exon events within the nerve bundles and blood vessels between myocyte units. Whilst physiological TDP-43 misfolding has been observed in myocytes the context of excitotoxicity and hyperexcitability (Versluys *et al*., 2022, Weskamp *et al*., 2020), the presence of loss-of-function events in the intervening neurovascular bundles, out with the muscle unit, are indicative of a pathological process. This site is not only readily biopsied, but also often carried out in the diagnostic work up of a person with ALS once symptoms have started. This could therefore be an optimal site for early confirmatory diagnosis, rather than patients experiencing long diagnostic delays once their symptoms have begun.

Amongst non-CNS tissues we observed the presence of abnormal macrophage morphologies including aggregate- and vacuole-laden macrophages, consistent with histological evidence of lysosomal dysfunction. These aberrant morphologies were observed in gastrointestinal tract, skin, and lymph node specimens. Vacuole-laden macrophages are a characteristic histopathological feature of lysosomal dysfunction, which has been implicated in the onset and development of FTD and ALS (reviewed in Root *et al*., 2021). The significance of our observation of lysosomal dysfunction in some non-CNS tissues prior to ALS symptom onset is not clear at this point, and warrants further investigation, but from our limited evidence here a role for lysosomal dysfunction early in development of ALS cannot be ruled out.

Recent research has revealed an association between higher income and a younger onset of ALS, suggested to be attributable to socioeconomic factors affecting the timing of diagnosis rather than the likelihood of the condition (Shojaie *et al*., 2024). Currently, all ALS diagnoses are made in hospital settings and often some time after motor symptom onset. Skin biopsies to test for TDP-43 pathology could represent a relatively straightforward, and arguably less intimidating, earlier ALS detection methodology with potential to increase societal health equity across socioeconomic, geographical, and health education and awareness divides. Gut biopsies, although more invasive than skin biopsies, are routinely taken from people presenting with significant GI symptoms – whilst these biopsies are primarily taken to investigate for common gut pathologies, such as inflammatory bowel disease, a gut biopsy provides an opportunity for early TDP-43 pathology detection. The significance of pre-symptomatic TDP-43 pathology in peripheral tissues of people with ALS warrants further investigation and consideration. Whilst, for Parkinson's disease, the brain-first and body-first subtypes for disease ontogeny have garnered wide acceptance, two aspects of these staging systems are still debated; (i) whether pathology arises unifocally or multifocally, and (ii) whether olfactory bulb and enteric nervous

system could be the primary sites of origin. Spreading through the Vagus nerve has been suggested as a plausible means of propagation under the body-first staging system (see Braak *et al*., 2003, Hawkes *et al*., 2007) but recent findings incorporating Lewy body positive postmortem datasets with tissues from CNS and the peripheral nervous system identify two distinct body-first subtypes, one with parasympathetic vagal predominance and another with sympathetic predominance, in equal proportion (Andersen *et al*., 2025). ALS associated gene carriers, such as people with *C9orf72* hexanucleotide gene expansions, could monitor progression of TDP-43 pathology, with potential early detection and triaging for clinical trials. Clinical trials themselves could monitor the effect of their interventions on TDP-43 pathology using tissue biopsies, non-invasive or otherwise, as an alternative to, or in conjunction with CNS or blood monitoring. With early detection in mind, there is already evidence that pre-symptomatic TDP-43 loss-of-function can be detected through cryptic splicing events, with cryptic peptides (Irwin *et al*., 2024) representing an intriguing possibility for clinical sampling, as these peptides are more stable than mRNA. Tissue biopsies could supplement these approaches and/or provide direct evidence of TDP-43 pathology *in situ*. Therefore, more work needs to be carried out to assess the utility of non-CNS tissue biopsies for early detection of ALS, providing another tool in in the toolkit for the detection of pathology, and the monitoring of disease progression and target engagement in ALS clinical trials.

Taken together, we have identified several organs that have evidence of TDP-43 pathology prior to motor symptom onset in ALS. The cell types affected, at least in some instances, share a common cell linage as long-lived cells that derive from the neural crest (for example peripheral/enteric neurons, chondrocytes, dendritic cells, connective tissue, and smooth muscle of peripheral blood vessels). This could imply a cell-type specific predisposition to TDP-43 pathology that occurs in many organs, most of which are more readily accessible than the CNS. Understanding the distribution of the systemic pathological burden of TDP-43 not only allows us to identify people earlier but also allows us to target biofluid studies appropriately to organs that we know to be affected by TDP-43 pathology.

Conflicts of Interest

The authors declare no conflicts of interest.

Acknowledgements

The research leading to this manuscript has been supported by: (i) a **Target ALS** foundation grant to *JMG* and employing *FMW* (BB-2022-C4-L2); (ii) an **NIH** grant to *JMG* and employing *HS* and *FR*

(R01NS127186) ; a (iii) **MND Scotland/CSO** grant to *KR* (CAF/24/13 – 2024/MNDS/6500/780ROB); (iv) a **Motor Neurone Disease Association** grant to *JMG* and employing *KH* (Gregory/APR24/2374-791); (v) a **LifeArc** MND Primer Fund to *JMG* (A20170). Funders had no role in study design, data collection, data analyses, interpretation, or writing the manuscript. The authors would also like to thank the University of Aberdeen Microscopy and Histology Core Facility in the Institute of Medical Sciences and the NHS Lothian BioResource staff, in particular *Vishad Patel* and *Craig Marshall*.

Data sharing statement

All data are included in their entirety within the manuscript.

Figure Legends

Figure 1. Improved sensitivity of TDP-43^{APT} facilitates detection of TDP-43 pathology in peripheral tissues

A. Schematic demonstrating organs with evidence of TDP-43 pathology, detected using TDP-43^{APT} (left) and those with no evidence of TDP-43 pathology (right). Cell types affected by TDP-43 pathology are also detailed in the inset box in the left panel. **B.** Schematic demonstrating range of time from *ante-mortem* sampling to symptom onset across organs that show evidence of TDP-43 pathology.

Figure 2. TDP-43^{APT} consistently detects TDP-43 pathology in skin biopsies with improved accuracy compared to antibody approaches

A. Photomicrographs taken at 40x magnification stained with TDP-43^{APT} with DAB chromogen and counterstained with haematoxylin. Images show examples of a single case that had no evidence of TDP-43^{APT} pathology (left) and images from two other cases that showed evidence of TDP-43^{APT} pathology within the dermis (white arrowheads) of individuals who later went on to develop ALS. Scale bar = 20 µm. **B**. Images of skin biopsies from one individual who had a *C9orf72* mutation. The image on the left, taken the same year as symptom onset, shows evidence of TDP-43^{APT} pathology (white arrowheads) in the nuclei and cytoplasm of sebocytes of the sebaceous gland within the dermis (1-3). The image shows the same site biopsied 36 months prior to diagnosis, with no evidence of TDP-43^{APT} pathology (4). Scale bar = 40 µm **C**. Image taken from area highlighted in (B) showing the presence of *STMN-2* cryptic exons (indicated by red arrowheads) in the peripheral nerve bundle adjacent to the affected sebaceous gland. Scale bar = 50 µm.

Figure 3. Muscle biopsy reveals TDP-43 pathology in myocytes and surrounding neurovascular bundles

A. Photomicrographs taken at 40x magnification stained with pTDP-43 antibody (left image) and TDP-43^{APT} (right image) with DAB chromogen and counterstained with haematoxylin. Scale bar = 50 µm. Images demonstrate lack of immunoreactivity for pTDP-43 antibody, but strong immunoreactivity for TDP-43^{APT} staining. **B**. Photomicrographs taken at 20x magnification stained with TDP-43^{APT} (left image) with 4x optical zoom in right image. These images are taken from the second muscle biopsy indicating that TDP-43^{APT} pathology can be seen in both individuals sampled within this cohort. White arrowheads indicate TDP-43^{APT} pathology; scale bar = 50 µm. **C**. Photomicrographs taken at 20x

magnification stained with TDP-43^{APT} (left image) with optical zoom in right image. Scale bar = 75 µm. The image demonstrates TDP-43^{APT} pathology within the neurovascular bundle in between fascicles. White arrowheads indicate TDP-43^{APT} pathology within the peripheral nerve, and blue arrowheads indicate pathology within the endothelial cells of the adjacent blood vessels. **D**. The same region imaged in (C), except stained with *in situ* hybridisation probes directed at *STMN-2* cryptic exon, which is only seen in the context of TDP-43 loss-of-function. Here TDP-43 loss-of-function can be visualised within the peripheral nerve bundle (red arrowheads indicate individual mRNA containing the *STMN-2* cryptic exon. Scale bar = 50 µm.

Figure 4. Blood vessel involvement by TDP-43 pathology in pre-symptomatic ALS

Photomicrographs taken at 20x magnification stained with TDP-43^{APT} with DAB chromogen and counterstained with haematoxylin. Images demonstrate examples of neurovascular bundles with and without TDP-43^{APT} pathology from each of the affected organ systems. Scale bar = 50 µm. Red arrowheads indicate arteries, blue arrowheads indicate veins, orange arrowheads indicate peripheral nerves. White arrowheads indicate TDP-43^{APT} pathology.

Figure 5. Aggregate- and vacuole-laden macrophages observed across non-CNS tissues

Photomicrographs taken at 40x magnification stained with TDP-43^{APT} with DAB chromogen and counterstained with haematoxylin. Scale bar = 50 µm in the left panel and 20 µm in the right panel. Black box in left panel represents area of optical zoom in right panel. Amongst non-CNS tissues we observed the presence of abnormal macrophage morphologies (white arrowhead) including aggregate- and vacuole-laden macrophages, in gastrointestinal tract, skin, and lymph node, consistent with histological evidence of lysosomal dysfunction.

Figure 1.

A.

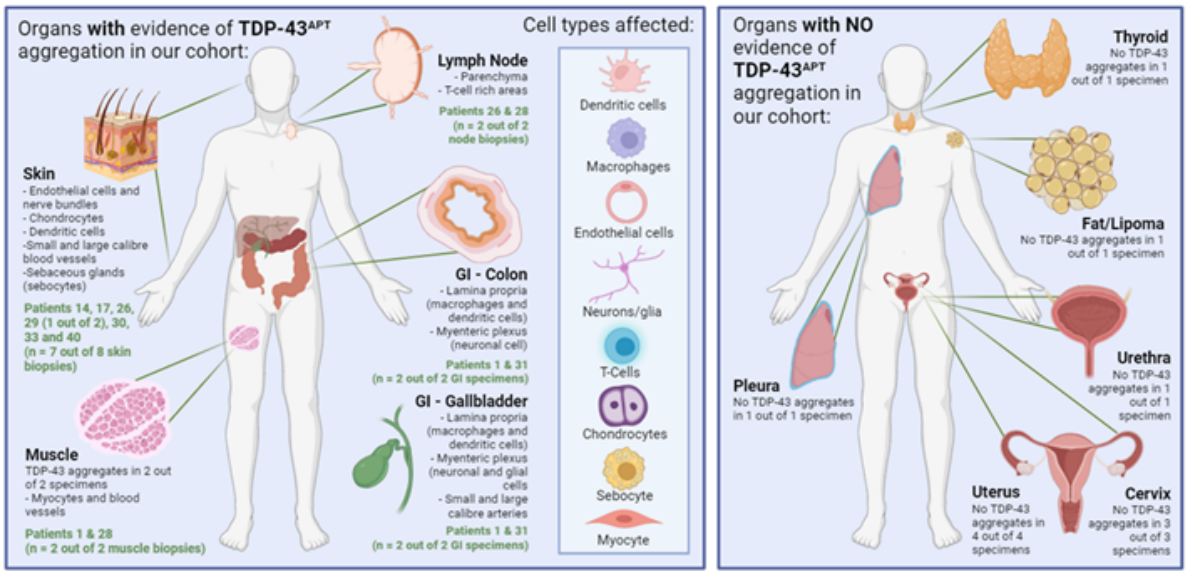
Organs with evidence of TDP-43APT aggregation in our cohort:
Cell types affected:
Lymph Node
- Parenchyma
- T-cell rich areas
Patients 26 & 28
(n = 2 out of 2 node biopsies)
Skin
- Endothelial cells and nerve bundles
- Chondrocytes
- Dendritic cells
-Small and large calibre blood vessels
-Sebaceous glands (sebocytes)
Patients 14, 17, 26, 29 (1 out of 2), 30, 33 and 40
(n = 7 out of 8 skin biopsies)
GI - Colon
- Lamina propria (macrophages and dendritic cells)
- Myenteric plexus (neuronal cell)
Patients 1 & 31
(n = 2 out of 2 GI specimens)
GI - Gallbladder
- Lamina propria (macrophages and dendritic cells)
- Myenteric plexus (neuronal and glial cells
- Small and large calibre arteries
Patients 1 & 31
(n = 2 out of 2 GI specimens)
Muscle
TDP-43 aggregates in 2 out of 2 specimens
- Myocytes and blood vessels
Patients 1 & 28
(n = 2 out of 2 muscle biopsies)
Dendritic cells
Macrophages
Endothelial cells
Neurons/glia
T-Cells
Chondrocytes
Sebocyte
Myocyte
Organs with NO evidence of TDP-43APT aggregation in our cohort:
Thyroid
No TDP-43 aggregates in 1 out of 1 specimen
Fat/Lipoma
No TDP-43 aggregates in 1 out of 1 specimen
Urethra
No TDP-43 aggregates in 1 out of 1 specimen
Pleura
No TDP-43 aggregates in 1 out of 1 specimen
Uterus
No TDP-43 aggregates in 4 out of 4 specimens
Cervix
No TDP-43 aggregates in 3 out of 3 specimens

B.

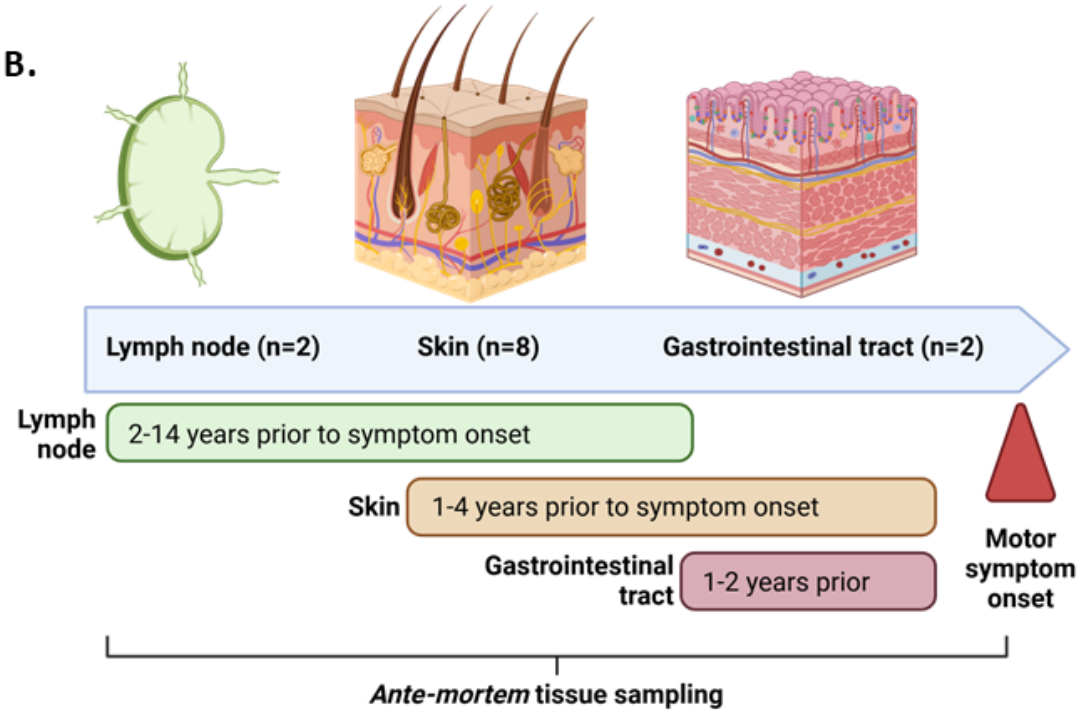
Lymph node (n=2)
Skin (n=8)
Gastrointestinal tract (n=2)
Lymph node
2-14 years prior to symptom onset
Skin
1-4 years prior to symptom onset
Gastrointestinal tract
1-2 years prior
Motor symptom onset
Ante-mortem tissue sampling

Figure 2. Skin

A.

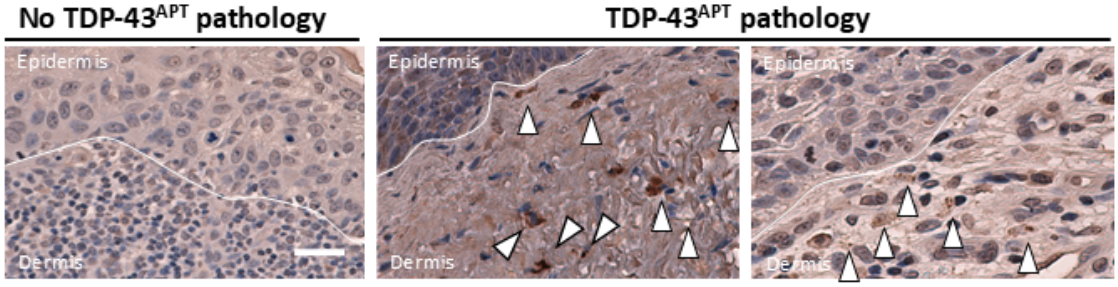

B. **Skin sampled at diagnosis** **24 months prior to diagnosis**

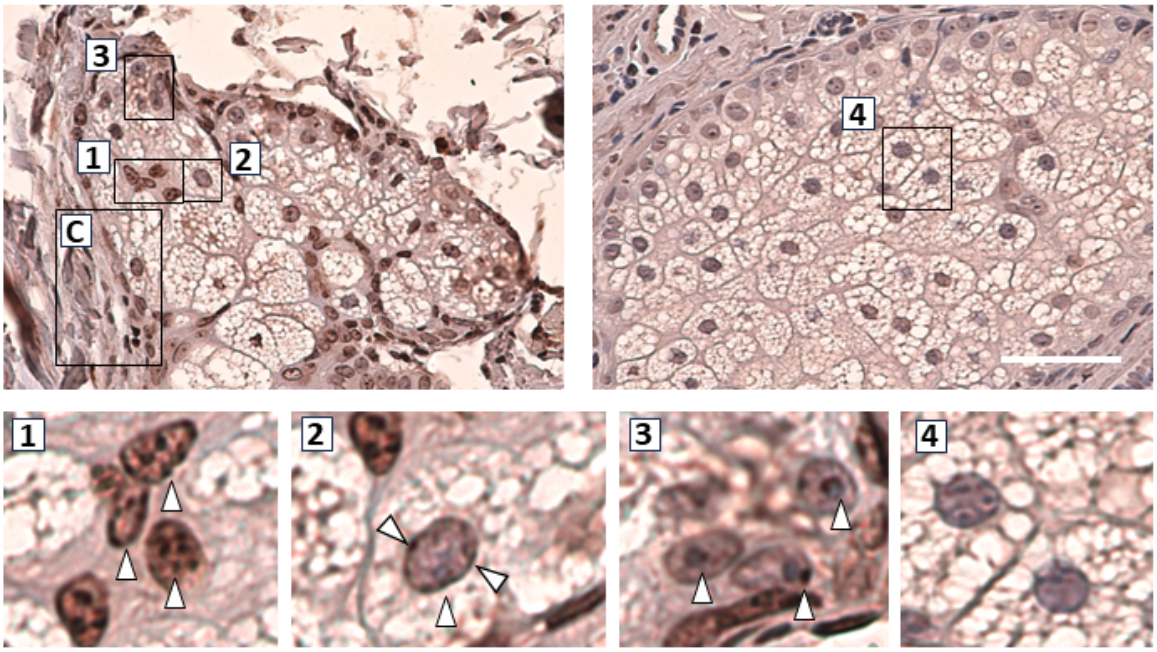

Nuclear puncta | Nuclear membrane pathology | Nucleolar decoration | No TDP-43^{APT} pathology evident

C. ***STMN-2*** **cryptic exons in corresponding region**

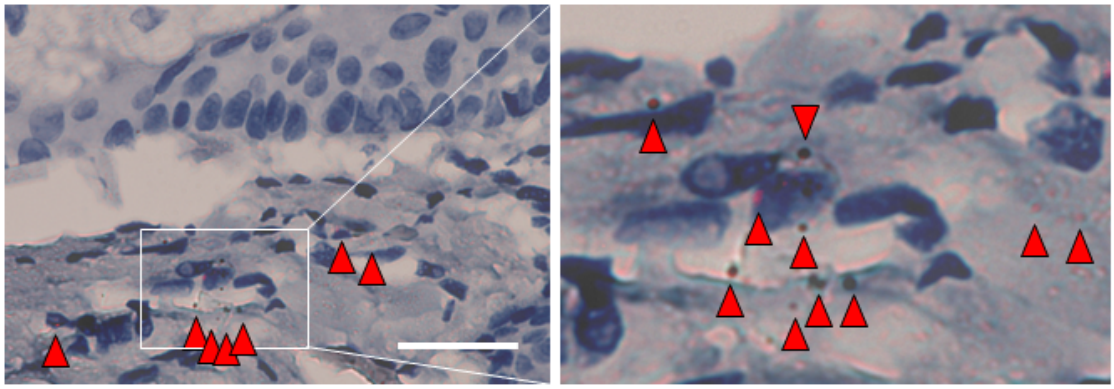

Figure 3. Muscle

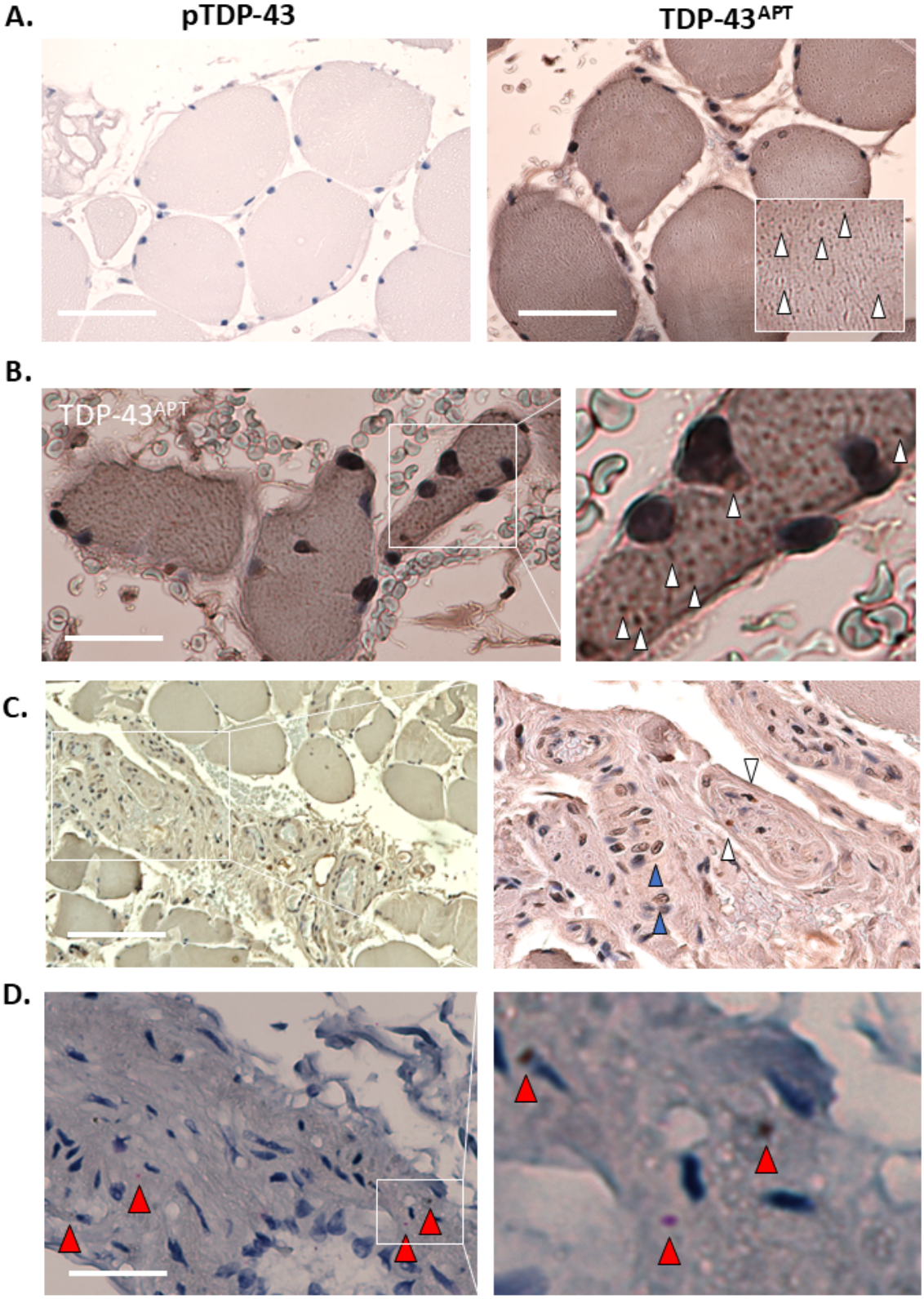

Figure 4. Blood vessels in distinct organ systems

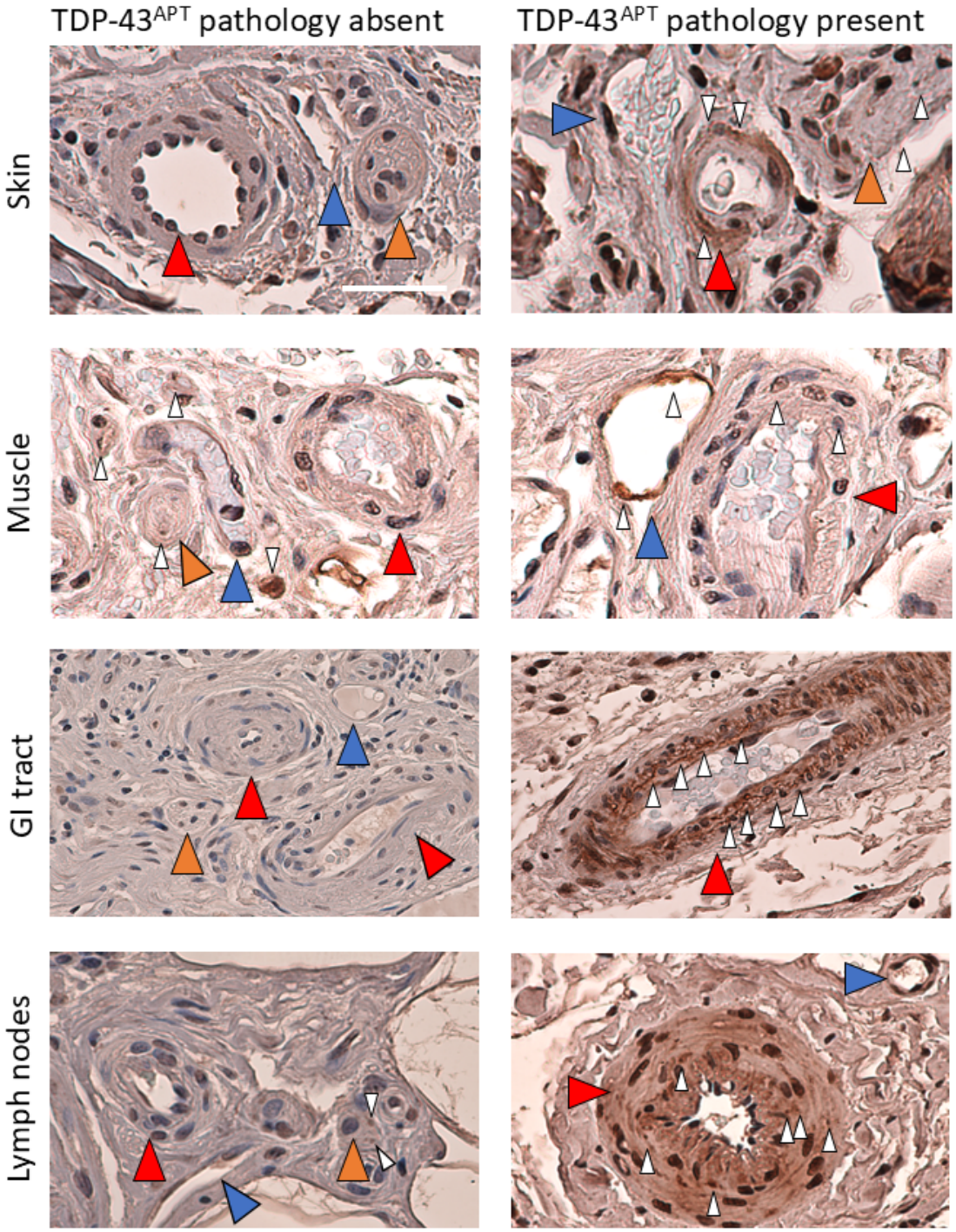

Figure 5. Aggregate- and vacuole-laden macrophages

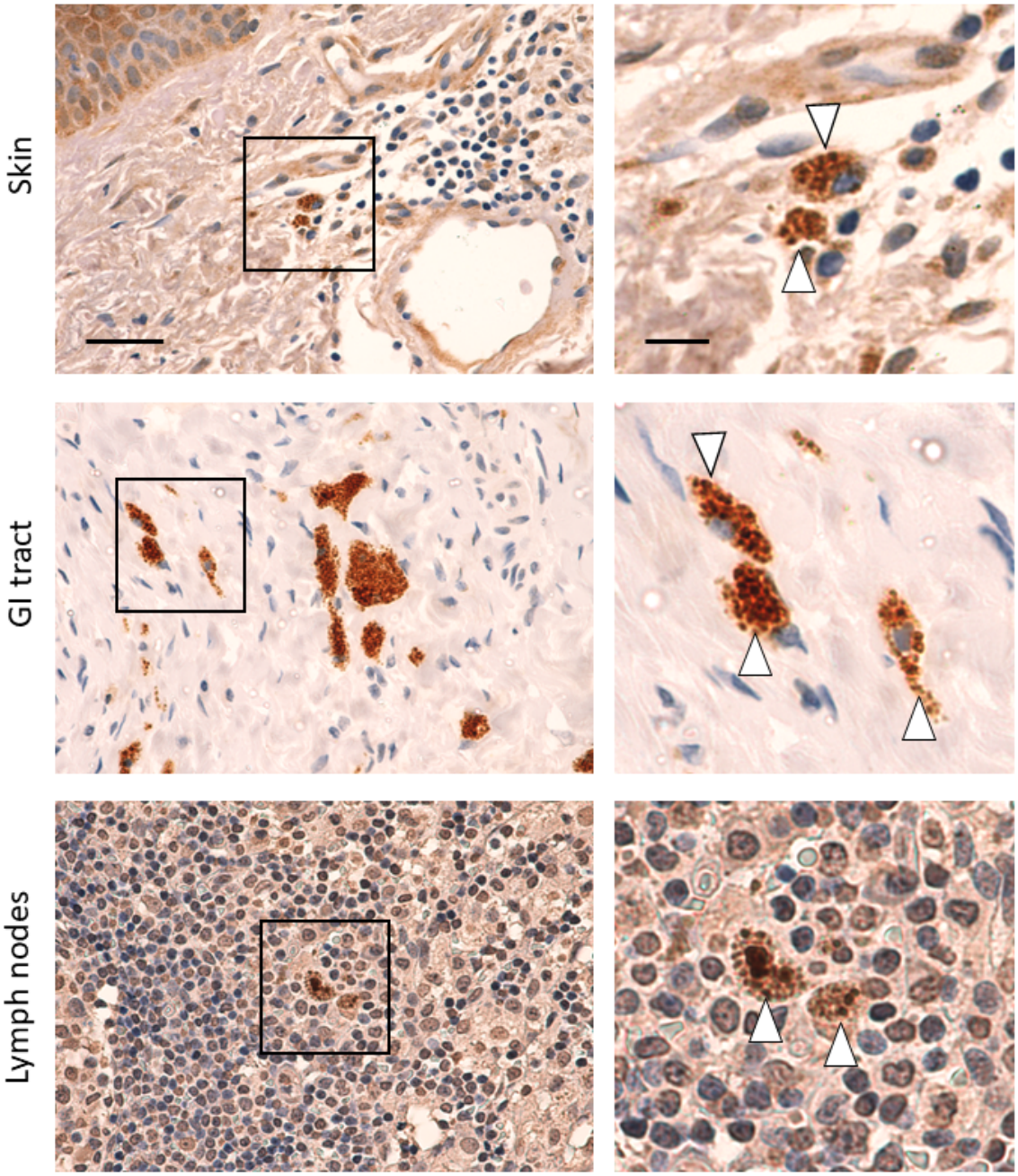

Supplementary Information

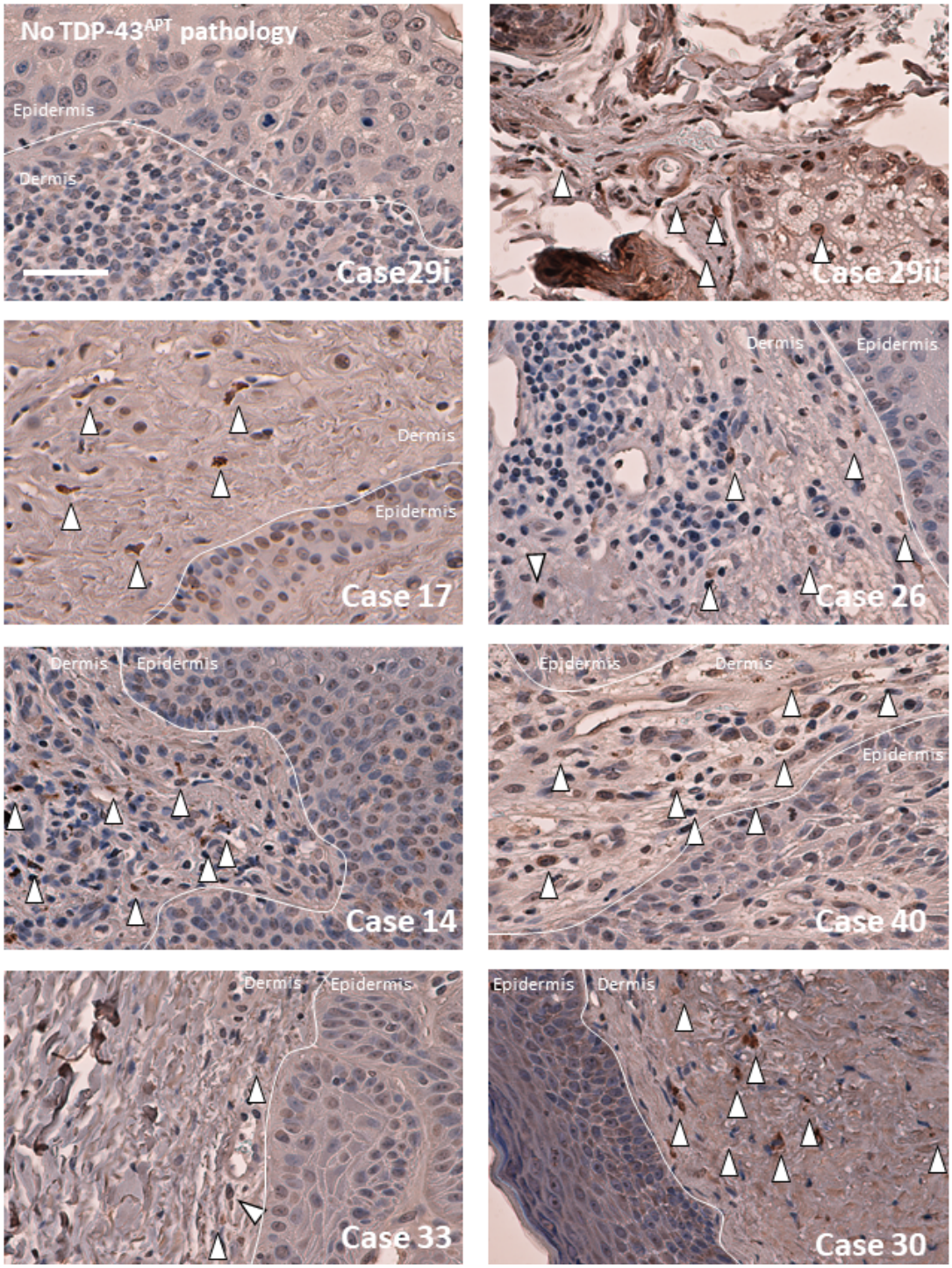

Supplementary Figure 1. ***TDP-43^{APT} pathology detected in all skin biopsies from individuals who went on to develop ALS.***

Photomicrographs taken at 40x of all skin biopsies from this cohort (n=7 individuals). One individual (case 29), who had a *C9orf72* mutation, had two biopsies taken 24 months apart (29i and 29ii). Sections are stained with TDP-43^{APT} (DAB chromogen in brown) and counterstained with haematoxylin (blue). TDP-43^{APT} pathology is indicated with white arrowheads and can be seen within the dendritic cells of the dermis, within neurovascular bundles, and sebaceous units. Delineation between dermis and epidermis is indicated by a continuous white line. Patient ID (case number) relates to clinical demographics published previously for this cohort (Pattle *et al*., 2023). Scale bar = 20 µm.

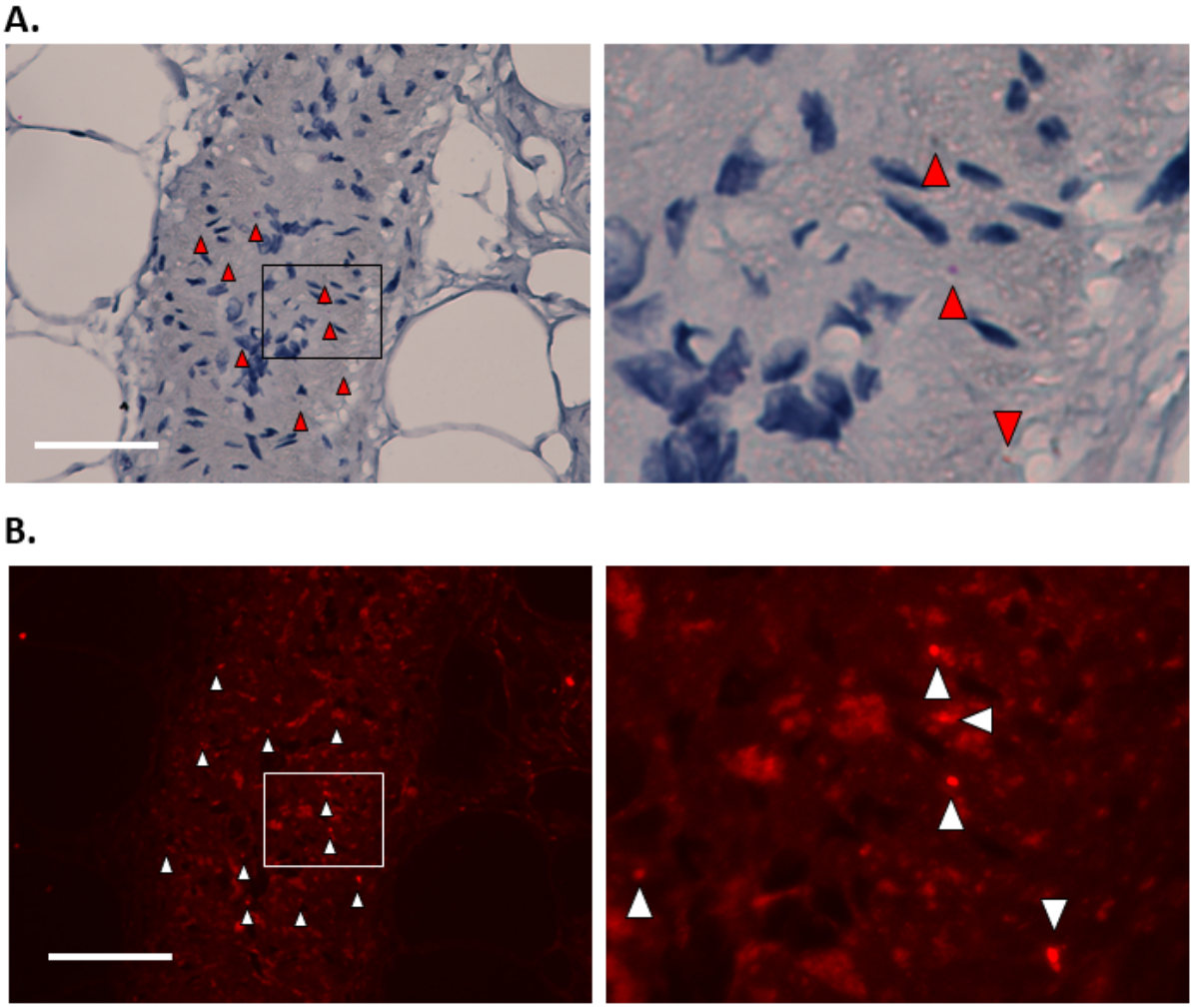

Supplementary Figure 2. ***TDP-43 pathology seen in neurovascular bundle within the fibroadipose tissue separating fascicles of muscle fibres.***

A. Photomicrographs taken at 20x magnification (left image), and 4 times optical zoom of the area highlighted with the black box (right image) stained with *in situ* hybridisation probes directed against the cryptic exon of STMN-2 and counterstained with haematoxylin. Signal can only be seen in the context of a loss of TDP-43 function, where it is no longer repressing cryptic exon inclusion. **B**. The same frame from (**A**) imaged using fluorescence microscopy (fast red chromogen is also a fluorophore), highlighting individual mRNA molecules of STMN-2 transcripts that contain cryptic exons indicating TDP-43 loss-of-function. Scale bar = 50 µm.

Bibliography

ANDERSEN, K. B., KRISHNAMURTHY, A., JUST, M. K., VAN DEN BERGE, N., SKJÆRBÆK, C., HORSAGER, J., KNUDSEN, K., VOGEL, J. W., TOLEDO, J. B., ATTEMS, J., POLVIKOSKI, T., SAITO, Y., MURAYAMA, S. & BORGHAMMER, P. 2025. Sympathetic and parasympathetic subtypes of body-first Lewy body disease observed in postmortem tissue from prediagnostic individuals. *Nature Neuroscience*.

ARRIBAS, V., ONETTI, Y., RAMIRO-PARETA, M., VILLACAMPA, P., BECK, H., ALBEROLA, M., ESTEVE-CODINA, A., MERKEL, A., SPERANDIO, M., MARTÍNEZ-ESTRADA, O. M., SCHMID, B. & MONTANEZ, E. 2024. Endothelial TDP-43 controls sprouting angiogenesis and vascular barrier integrity, and its deletion triggers neuroinflammation. *JCI Insight,* 9.

BESWICK, E., FORBES, D., HASSAN, Z., WONG, C., NEWTON, J., CARSON, A., ABRAHAMS, S., CHANDRAN, S. & PAL, S. 2022. A systematic review of non-motor symptom evaluation in clinical trials for amyotrophic lateral sclerosis. *Journal of Neurology,* 269**,** 411-426.

BESWICK, E., FORBES, D., JOHNSON, M., NEWTON, J., DAKIN, R., GLASMCHER, S., ABRAHAMS, S., CARSON, A., CHANDRAN, S. & PAL, S. 2023. Non-motor symptoms in motor neuron disease: prevalence, assessment and impact. *Brain Communications,* 6**,** fcad336.

BOSSY-WETZEL, E., SCHWARZENBACHER, R. & LIPTON, S. A. 2004. Molecular pathways to neurodegeneration. *Nature Medicine,* 10**,** S2-S9.

BRAAK, H., TREDICI, K. D., RÜB, U., DE VOS, R. A. I., JANSEN STEUR, E. N. H. & BRAAK, E. 2003. Staging of brain pathology related to sporadic Parkinson's disease. *Neurobiology of Aging,* 24**,** 197-211.

BRIGANTI, S., TRUGLIO, M., ANGIOLILLO, A., LOMBARDO, S., LECCESE, D., CAMERA, E., PICARDO, M. & DI COSTANZO, A. 2021. Application of Sebum Lipidomics to Biomarkers Discovery in Neurodegenerative Diseases. *Metabolites* [Online], 11.

CHEEMALA, A., KIMBLE, A. L., TYBURSKI, J. D., LECLAIR, N. K., ZUBERI, A. R., MURPHY, M., JELLISON, E. R., REESE, B., HU, X., LUTZ, C. M., YAN, R. & MURPHY, P. A. 2023. Loss of Endothelial TDP-43 Leads to Blood Brain Barrier Defects in Mouse Models of Amyotrophic Lateral Sclerosis and Frontotemporal Dementia. *bioRxiv***,** 2023.12.13.571184.

CONROY, E., VÉLEZ-GÓMEZ, B., O'BRIEN, D., HEVERIN, M., HARDIMAN, O., MCDERMOTT, C. & GALVIN, M. 2023. IMPACT-ALS: summary of results from a European survey of people living with ALS. *Amyotrophic Lateral Sclerosis and Frontotemporal Degeneration***,** 1-10.

CYKOWSKI, M. D., POWELL, S. Z., APPEL, J. W., ARUMANAYAGAM, A. S., RIVERA, A. L. & APPEL, S. H. 2018. Phosphorylated TDP-43 (pTDP-43) aggregates in the axial skeletal muscle of patients with sporadic and familial amyotrophic lateral sclerosis. *Acta Neuropathologica Communications,* 6**,** 28.

DALLA BELLA, E., LOMBARDI, R., PORRETTA-SERAPIGLIA, C., CIANO, C., GELLERA, C., PENSATO, V., CAZZATO, D. & LAURIA, G. 2016. Amyotrophic lateral sclerosis causes small fiber pathology. *European Journal of Neurology,* 23**,** 416-420.

DECARVALHO, M., GROMICHO, M., ANDERSEN, P., GROSSKREUTZ, J., KUZMA-KOZAKIEWICZ, M., PETRI, S., UYSAL, H. & PINTO, S. 2021. Peripheral neuropathy in ALS: phenotype association. *Journal of Neurology, Neurosurgery & Psychiatry,* 92**,** 1133.

FANG, T., JOZSA, F. & AL-CHALABI, A. 2017. Nonmotor Symptoms in Amyotrophic Lateral Sclerosis: A Systematic Review. *Int Rev Neurobiol,* 134**,** 1409-1441.

GREGORY, J. M., ELLIOTT, E., MCDADE, K., BAK, T., PAL, S., CHANDRAN, S., ABRAHAMS, S. & SMITH, C. 2020a. Neuronal clusterin expression is associated with cognitive protection in amyotrophic lateral sclerosis. *Neuropathology and Applied Neurobiology,* 46**,** 255-263.

GREGORY, J. M., MCDADE, K., BAK, T. H., PAL, S., CHANDRAN, S., SMITH, C. & ABRAHAMS, S. 2020b. Executive, language and fluency dysfunction are markers of localised TDP-43 cerebral

pathology in non-demented ALS. *Journal of Neurology, Neurosurgery & Psychiatry,* 91**,** 149.

GÜNTHER, R., RICHTER, N., SAUERBIER, A., CHAUDHURI, K. R., MARTINEZ-MARTIN, P., STORCH, A. & HERMANN, A. 2016. Non-Motor Symptoms in Patients Suffering from Motor Neuron Diseases. *Frontiers in Neurology,* 7.

HAMMAD, M., SILVA, A., GLASS, J., SLADKY, J. T. & BENATAR, M. 2007. Clinical, electrophysiologic, and pathologic evidence for sensory abnormalities in ALS. *Neurology,* 69**,** 2236-42.

HAWKES, C. H., DEL TREDICI, K. & BRAAK, H. 2007. Parkinson's disease: a dual-hit hypothesis. *Neuropathology and Applied Neurobiology,* 33**,** 599-614.

HAYASHI, T., YUGO, N., NAOKO, O., EIKO, H., MASAKO, S. & AND KUZUHARA, S. 2007. Pressure ulcers in ALS patients on admission at a university hospital in Japan. *Amyotrophic Lateral Sclerosis,* 8**,** 310-313.

HUANG, W.-P., ELLIS, B. C. S., HODGSON, R. E., SANCHEZ AVILA, A., KUMAR, V., RAYMENT, J., MOLL, T. & SHELKOVNIKOVA, T. A. 2024. Stress-induced TDP-43 nuclear condensation causes splicing loss of function and STMN2 depletion. *Cell Reports,* 43**,** 114421.

IRWIN, K. E., JASIN, P., BRAUNSTEIN, K. E., SINHA, I. R., GARRET, M. A., BOWDEN, K. D., CHANG, K., TRONCOSO, J. C., MOGHEKAR, A., OH, E. S., RAITCHEVA, D., BARTLETT, D., MILLER, T., BERRY, J. D., TRAYNOR, B. J., LING, J. P. & WONG, P. C. 2024. A fluid biomarker reveals loss of TDP-43 splicing repression in presymptomatic ALS–FTD. *Nature Medicine,* 30**,** 382-393.

KATSUMATA, Y., FARDO, D. W., KUKULL, W. A. & NELSON, P. T. 2018. Dichotomous scoring of TDP-43 proteinopathy from specific brain regions in 27 academic research centers: associations with Alzheimer's disease and cerebrovascular disease pathologies. *Acta Neuropathologica Communications,* 6**,** 142.

KOLDE, G., BACHUS, R. & LUDOLPH, A. C. 1996. Skin involvement in amyotrophic lateral sclerosis. *The Lancet,* 347**,** 1226-1227.

KUANG, Y., MAO, H., GAN, T., GUO, W., DAI, W., HUANG, W., WU, Z., LI, H., HUANG, X., YANG, X. & XU, P.-Y. 2024. A skin-specific α-Synuclein seeding amplification assay for diagnosing Parkinson's disease. *npj Parkinson's Disease,* 10**,** 129.

KURASHIGE, T., MORINO, H., MURAO, T., IZUMI, Y., SUGIURA, T., KURAOKA, K., KAWAKAMI, H., TORII, T. & MARUYAMA, H. 2022. TDP-43 Accumulation Within Intramuscular Nerve Bundles of Patients With Amyotrophic Lateral Sclerosis. *JAMA Neurology,* 79**,** 693-701.

KURASHIGE, T., MURAO, T., KANAYA, Y., DODO, Y., SUGIURA, T., KURAOKA, K. & OHSHITA, T. 2025. Intramuscular Nerve Bundles Reflect TDP-43 Pathology in the Medulla and Spinal Cord of ALS Patients. *Neuropathology and Applied Neurobiology,* 51**,** e70016.

LAWRENCE LI, L.-X., CROTTY, K. A., KRIL, J. J., PALMER, A. A. & MCCARTHY, S. W. 1999. Method of Melanin Bleaching in MIB1-Ki67 Immunostaining of Pigmented Lesions: A Quantitative Evaluation in Malignant Melanomas. *The Histochemical Journal,* 31**,** 237-240.

MARSDEN, R., JAN CLARKE, ROBIN HOWARD, KATIE SIDLE, MARTIN TURNER, KEVIN TALBOT & THOMPSON, A. 2023. BowALS: understanding changing bowel habits in people with amyotrophic lateral sclerosis. *British Journal of Neuroscience Nursing,* 19.

MCHUTCHISON, C. A., WUU, J., MCMILLAN, C. T., RADEMAKERS, R., STATLAND, J., WU, G., RAMPERSAUD, E., MYERS, J., HERNANDEZ, J. P., ABRAHAMS, S. & BENATAR, M. 2024. Temporal course of cognitive and behavioural changes in motor neuron diseases. *Journal of Neurology, Neurosurgery & Psychiatry,* 95**,** 316.

MORI, F., TADA, M., KON, T., MIKI, Y., TANJI, K., KUROTAKI, H., TOMIYAMA, M., ISHIHARA, T., ONODERA, O., KAKITA, A. & WAKABAYASHI, K. 2019. Phosphorylated TDP-43 aggregates in skeletal and cardiac muscle are a marker of myogenic degeneration in amyotrophic lateral sclerosis and various conditions. *Acta Neuropathologica Communications,* 7**,** 165.

MUIR, R. T. & SMITH, E. E. 2024. The Spectrum of Cerebral Small Vessel Disease: Emerging Pathophysiologic Constructs and Management Strategies. *Neurologic Clinics,* 42**,** 663-688.

NAKAMURA, C., BROMBERG, M., BHARGAVA, S., WICKS, P. & ZENG-TREITLER, Q. 2012. Mining Online Social Network Data for Biomedical Research: A Comparison of Clinicians' and Patients' Perceptions About Amyotrophic Lateral Sclerosis Treatments. *J Med Internet Res,* 14**,** e90.

NASH, Y. & SITTY, M. 2021. Non-Motor Symptoms of Amyotrophic Lateral Sclerosis: A Multi-Faceted Disorder. *Journal of Neuromuscular Diseases,* 8**,** 699-713.

NEUMANN, M., SAMPATHU, D. M., KWONG, L. K., TRUAX, A. C., MICSENYI, M. C., CHOU, T. T., BRUCE, J., SCHUCK, T., GROSSMAN, M., CLARK, C. M., MCCLUSKEY, L. F., MILLER, B. L., MASLIAH, E., MACKENZIE, I. R., FELDMAN, H., FEIDEN, W., KRETZSCHMAR, H. A., TROJANOWSKI, J. Q. & LEE, V. M. Y. 2006. Ubiquitinated TDP-43 in Frontotemporal Lobar Degeneration and Amyotrophic Lateral Sclerosis. *Science,* 314**,** 130-133.

NICHOLSON, K., BJORNEVIK, K., ABU-ALI, G., CHAN, J., CORTESE, M., DEDI, B., JEON, M., XAVIER, R., HUTTENHOWER, C., ASCHERIO, A. & BERRY, J. D. 2021. The human gut microbiota in people with amyotrophic lateral sclerosis. *Amyotroph Lateral Scler Frontotemporal Degener,* 22**,** 186-194.

NIU, T., WANG, P., ZHOU, X., LIU, T., LIU, Q., LI, R., YANG, H., DONG, H. & LIU, Y. 2025. An overlap-weighted analysis on the association of constipation symptoms with disease progression and survival in amyotrophic lateral sclerosis: a nested case-control study. *Therapeutic Advances in Neurological Disorders,* 18**,** 17562864241309811.

NOLANO, M., PROVITERA, V., CAPORASO, G., FASOLINO, I., BORRECA, I., STANCANELLI, A., IUZZOLINO, V. V., SENERCHIA, G., VITALE, F., TOZZA, S., RUGGIERO, L., IODICE, R., FERRARI, S., SANTORO, L., MANGANELLI, F. & DUBBIOSO, R. 2024. Skin innervation across amyotrophic lateral sclerosis clinical stages: new prognostic biomarkers. *Brain,* 147**,** 1740-1750.

NOLANO, M., PROVITERA, V., MANGANELLI, F., IODICE, R., CAPORASO, G., STANCANELLI, A., MARINOU, K., LANZILLO, B., SANTORO, L. & MORA, G. 2017. Non-motor involvement in amyotrophic lateral sclerosis: new insight from nerve and vessel analysis in skin biopsy. *Neuropathology and Applied Neurobiology,* 43**,** 119-132.

NÜBLING, G. S., MIE, E., BAUER, R. M., HENSLER, M., LORENZL, S., HAPFELMEIER, A., IRWIN, D. E., BORASIO, G. D. & WINKLER, A. S. 2014. Increased prevalence of bladder and intestinal dysfunction in amyotrophic lateral sclerosis. *Amyotrophic Lateral Sclerosis and Frontotemporal Degeneration,* 15**,** 174-179.

OMAR, O. M. F., KIMBLE, A. L., CHEEMALA, A., TYBURSKI, J. D., PANDEY, S., WU, Q., REESE, B., JELLISON, E. R., HAO, B., LI, Y., YAN, R. & MURPHY, P. A. 2025. Endothelial TDP-43 depletion disrupts core blood–brain barrier pathways in neurodegeneration. *Nature Neuroscience*.

ONO, S., IMAI, T., TAKAHASHI, K., JINNAI, K., YAMANO, T., NAGAO, K., SHIMIZU, N. & YAMAUCHI, M. 1998. Decreased type IV collagen of skin and serum in patients with amyotrophic lateral sclerosis. *Neurology,* 51**,** 114-20.

ONO, S., TOYOKURA, Y., MANNEN, T. & ISHIBASHI, Y. 1986. Amyotrophic lateral sclerosis: histologic, histochemical, and ultrastructural abnormalities of skin. *Neurology,* 36**,** 948-56.

PARÉ, B. & GROS-LOUIS, F. 2017. Potential skin involvement in ALS: revisiting Charcot's observation – a review of skin abnormalities in ALS. 28**,** 551-572.

PATTLE, S. B., O'SHAUGHNESSY, J., KANTELBERG, O., RIFAI, O. M., PATE, J., NELLANY, K., HAYS, N., ARENDS, M. J., HORROCKS, M. H., WALDRON, F. M. & GREGORY, J. M. 2023. pTDP-43 aggregates accumulate in non-central nervous system tissues prior to symptom onset in amyotrophic lateral sclerosis: a case series linking archival surgical biopsies with clinical phenotypic data. *The Journal of Pathology: Clinical Research,* 9**,** 44-55.

PUGDAHL, K., FUGLSANG-FREDERIKSEN, A., DE CARVALHO, M., JOHNSEN, B., FAWCETT, P. R. W., LABARRE-VILA, A., LIGUORI, R., NIX, W. A. & SCHOFIELD, I. S. 2007. Generalised sensory system abnormalities in amyotrophic lateral sclerosis: a European multicentre study. *Journal of Neurology, Neurosurgery & Psychiatry,* 78**,** 746.

ROOT, J., MERINO, P., NUCKOLS, A., JOHNSON, M. & KUKAR, T. 2021. Lysosome dysfunction as a cause of neurodegenerative diseases: Lessons from frontotemporal dementia and amyotrophic lateral sclerosis. *Neurobiology of Disease,* 154**,** 105360.

ROWLAND, L. P. & SHNEIDER, N. A. 2001. Amyotrophic lateral sclerosis. *N Engl J Med,* 344**,** 1688-700.

SAMARA, V. C., JERANT, P., GIBSON, S. & BROMBERG, M. 2021. Bowel, bladder, and sudomotor symptoms in ALS patients. *Journal of the Neurological Sciences,* 427**,** 117543.

SHOJAIE, A., AHMAD, A. K., SARAH, G., HANIAH, H.-B., RACHEL, T., SARAH, O.-M., SARA, J., NIGEL, L. P. & AND AL-CHALABI, A. 2024. Investigating the impact of socioeconomic status on amyotrophic lateral sclerosis. *Amyotrophic Lateral Sclerosis and Frontotemporal Degeneration,* 25**,** 702-707.

SHOJAIE, A., ROTA, S., AL KHLEIFAT, A., RAY CHAUDHURI, K. & AL-CHALABI, A. 2023. Non-motor symptoms in amyotrophic lateral sclerosis: lessons from Parkinson's disease. *Amyotrophic Lateral Sclerosis and Frontotemporal Degeneration***,** 1-10.

SONNENBERG, A., TSOU, V. T. & MÜLLER, A. D. 1994. The "institutional colon": a frequent colonic dysmotility in psychiatric and neurologic disease. *Am J Gastroenterol,* 89**,** 62-6.

SPENCE, H., WALDRON, F. M., SALEEB, R. S., BROWN, A.-L., RIFAI, O. M., GILODI, M., READ, F., ROBERTS, K., MILNE, G., WILKINSON, D., O'SHAUGHNESSY, J., PASTORE, A., FRATTA, P., SHNEIDER, N., TARTAGLIA, G. G., ZACCO, E., HORROCKS, M. H. & GREGORY, J. M. 2024. RNA aptamer reveals nuclear TDP-43 pathology is an early aggregation event that coincides with STMN-2 cryptic splicing and precedes clinical manifestation in ALS. *Acta Neuropathologica,* 147**,** 50.

SUN, J., LUDVIGSSON, J. F., ROELSTRAETE, B., PAWITAN, Y. & FANG, F. 2021. Gastrointestinal biopsies and amyotrophic lateral sclerosis - results from a cohort study of 1.1 million individuals. *Amyotroph Lateral Scler Frontotemporal Degener,* 22**,** 410-418.

THE ALS ASSOCIATION 2019. ALS Voice of the Patient Report derived from the IMPACT ALS survey.

TOEPFER, C. F. A. K. R. L. R. W. M.-F. D. P. M. 1999. Gastrointestinal dysfunction in amyotrophic lateral sclerosis. *Amyotrophic Lateral Sclerosis and Other Motor Neuron Disorders,* 1**,** 15-19.

TOEPFER, M., FOLWACZNY, C., LOCHMÜLLER, H., SCHROEDER, M., RIEPL, R. L., PONGRATZ, D. & W, M.-F. 1999. Noninvasive 13C-Octanoic Acid Breath Test Shows Delayed Gastric Emptying in Patients with Amyotrophic Lateral Sclerosis. *Digestion,* 60**,** 567–571.

TOEPFER, M., SCHROEDER, M., KLAUSER, A., LOCHMÜLLER, H., HIRSCHMANN, M., RIEPL, R. L., PONGRATZ, D. & MÜLLER-FELBER, W. 1997. Delayed colonic transit times in amyotrophic lateral sclerosis assessed with radio-opaque markers. *European Journal of Medical Research,* 2**,** 473-6.

TRUINI, A., BIASIOTTA, A., ONESTI, E., DI STEFANO, G., CECCANTI, M., LA CESA, S., PEPE, A., GIORDANO, C., CRUCCU, G. & INGHILLERI, M. 2015. Small-fibre neuropathy related to bulbar and spinal-onset in patients with ALS. *Journal of Neurology,* 262**,** 1014-1018.

UMAHARA, T., UCHIHARA, T., HIRAO, K., SHIMIZU, S., HASHIMOTO, T., AKIMOTO, J., KOHNO, M. & HANYU, H. 2020. Frontotemporal dementia-associated protein "phosphorylated TDP-43" localizes to atherosclerotic lesions of human carotid and main cerebral arteries. *Histol Histopathol,* 35**,** 159-167.

VERSLUYS, L., ERVILHA PEREIRA, P., SCHUERMANS, N., DE PAEPE, B., DE BLEECKER, J. L., BOGAERT, E. & DERMAUT, B. 2022. Expanding the TDP-43 Proteinopathy Pathway From Neurons to Muscle: Physiological and Pathophysiological Functions. *Frontiers in Neuroscience,* Volume 16 - 2022.

WALDRON, F. M., SPENCE, H. & GREGORY, J. M. 2024. TDP-43 RNA aptamer staining to detect pathological TDP-43 in FFPE human tissue, as described in Spence and Waldron *et al*., 2024 (Acta Neuropathologica): A SOP and tick-sheet. *protocols.io*.

WALLACE, V. C. J., ELLIS, C. M., BURMAN, R., KNIGHTS, C., SHAW, C. E. & AL-CHALABI, A. 2014. The evaluation of pain in amyotrophic lateral sclerosis: A case controlled observational study. *Amyotrophic Lateral Sclerosis and Frontotemporal Degeneration,* 15**,** 520-527.

WANG, F., FLANAGAN, J., SU, N., WANG, L.-C., BUI, S., NIELSON, A., WU, X., VO, H.-T., MA, X.-J. & LUO, Y. 2012. RNAscope: A Novel in Situ RNA Analysis Platform for Formalin-Fixed, Paraffin-Embedded Tissues. *The Journal of Molecular Diagnostics,* 14**,** 22-29.

WEIS, J., KATONA, I., MÜLLER-NEWEN, G., SOMMER, C., NECULA, G., HENDRICH, C., LUDOLPH, A. C. & SPERFELD, A. D. 2011. Small-fiber neuropathy in patients with ALS. *Neurology,* 76**,** 2024-9.

WESKAMP, K., TANK, E. M., MIGUEZ, R., MCBRIDE, J. P., GÓMEZ, N. B., WHITE, M., LIN, Z., GONZALEZ, C. M., SERIO, A., SREEDHARAN, J. & BARMADA, S. J. 2020. Shortened TDP43 isoforms upregulated by neuronal hyperactivity drive TDP43 pathology in ALS. *The Journal of Clinical Investigation,* 130**,** 1139-1155.

WONG, C., STAVROU, M., ELLIOTT, E., GREGORY, J. M., LEIGH, N., PINTO, A. A., WILLIAMS, T. L., CHATAWAY, J., SWINGLER, R., PARMAR, M. K. B., STALLARD, N., WEIR, C. J., PARKER, R. A., CHAOUCH, A., HAMDALLA, H., EALING, J., GORRIE, G., MORRISON, I., DUNCAN, C., CONNELLY, P., CAROD-ARTAL, F. J., DAVENPORT, R., REITBOECK, P. G., RADUNOVIC, A., SRINIVASAN, V., PRESTON, J., MEHTA, A. R., LEIGHTON, D., GLASMACHER, S., BESWICK, E., WILLIAMSON, J., STENSON, A., WEAVER, C., NEWTON, J., LYLE, D., DAKIN, R., MACLEOD, M., PAL, S. & CHANDRAN, S. 2021. Clinical trials in amyotrophic lateral sclerosis: a systematic review and perspective. *Brain Communications,* 3**,** fcab242.

ZACCO, E., KANTELBERG, O., MILANETTI, E., ARMAOS, A., PANEI, F. P., GREGORY, J., JEACOCK, K., CLARKE, D. J., CHANDRAN, S., RUOCCO, G., GUSTINCICH, S., HORROCKS, M. H., PASTORE, A. & TARTAGLIA, G. G. 2022. Probing TDP-43 condensation using an in silico designed aptamer. *Nature Communications,* 13**,** 3306.

ZHANG, Q.-J., LIN, J., WANG, Y.-L., CHEN, L., DING, Y., ZHENG, F.-Z., SONG, H.-H., LV, A.-W., LI, Y.-Y., GUO, Q.-F., LIN, M.-T., HU, W., XU, L.-Q., ZHAO, W.-L., FANG, L., CUI, M.-C., FU, Z.-F., CHEN, W.-J., ZHANG, J., WANG, Z.-Q., WANG, N. & FU, Y. 2024. Detection of pTDP-43 via routine muscle biopsy: A promising diagnostic biomarker for amyotrophic lateral sclerosis. *Brain Pathology,* 34**,** e13261.