Efficacy of Doxycycline as monotherapy or in combination with Levofloxacin in treating late-stage systemic anthrax in NHP

Amir Ben-Shmuel[*], Assa Sittner[*], Itai Glinert, Elad Bar-David, Josef Schlomovitz, Haim Levy[+] and Shay Weiss[+]

Department of Infectious Diseases, Israel Institute for Biological Research, Ness-Ziona, Israel

* Equal contribution to the manuscript

Short title: Doxycycline treatment of Anthrax in NHP

Corresponding author:

Haim Levy

Shay Weiss

Department of Infectious Diseases

Israel Institute for Biological Research

P.O.Box 19, Ness-Ziona, Israel

Tel:+972-8-9381483

E-mail: haiml@iibr.gov.il, shayw@iibr.gov.il

Abstract

Recent CDC guidelines for treating systemic anthrax recommend a combination of a Tetracycline (Minocycline or Doxycycline) with Meropenem or a Fluoroquinolone. These recommendations differ from the 2001 or 2014 updates, and in the absence of significant clinical data, rely mainly on animal studies. Herein we present high efficacy of treating late-stage systemic anthrax with Doxycycline as a monotherapy or in combination with Levofloxacin in NHP.

Introduction

Bacillus anthracis, a gram-positive spore forming bacteria, is the etiological cause of anthrax, a lethal zoonotic disease transferred to humans by contact with sick animals or contaminated animal products (1-3). In most cases the spores (the infectious form), penetrate the body through skin lesions, or the digestion or inhalation tracts (1). The route of infection determines the type of anthrax that develops: local eschar, gastro-inflammation and systemic disease. Systemic disease is almost always fatal without treatment and will always develop after inhalational and oral routes (4). The cutaneous form is the most obvious of the three and will be resolved in 80-95% of the cases (5). A relatively new form of anthrax, deep tissue infection, resulting from the injection of spore-contaminated heroin, causes extended edema and inflammation of the injected limb (6). Historically, anthrax patients were treated with injections of penicillin G, that were highly effective but of limited applicability in the case of mass exposure event (1). Following the 2001 anthrax mail attacks and the confusion in treatment of systemic patients, the CDC recommended treatment was based on Ciprofloxacin or Doxycycline in combination with up to four additional substances (7). Eventually the combination of Ciprofloxacin with Clindamycin was the treatment of choice and was successfully used in several anthrax cases since. Since 2001, the CDC updated its recommendations twice (8, 9) (in 2014 and 2023). In the last update the treatment is based on a tetracycline (Minocycline or Doxycycline) combined with Meropenem or ciprofloxacin (9). Previously we reported the high efficacy of Doxycycline in treating late stages of systemic anthrax in rabbits as a monotherapy or in combination with a fluoroquinolone or Meropenem (10-13). In this work we validate the rabbit results in NHP that were infected via intranasal spray of spores in trigger-to-treat experiments with Doxycycline alone or with Levofloxacin.

Experimental procedure

This study was carried out by trained personnel, in strict accordance with the recommendations of the Guide for the Care and Use of Laboratory Animals of the National Research Council. All protocols were approved by the IIBR committee on the Ethics of Animal Experiments (Protocol numbers, RM-01-18 and RM-03-19). Animals had free access to food and water, maintained at a controlled environment with constant fresh air supply and ambient room temperature of 24°C. Enrichment was supplied in the form of specialized toys. Before inoculation, animals were sedated using 100mg ketamine and 10mg xylazine. Animals were monitored twice a day and euthanized immediately by a 120 mg/kg sodium pentobarbitone injection when one of the following symptoms was detected: severe respiratory distress or the loss of righting reflex. Animals unable or unwilling to drink were injected with 20-100ml of saline or dextrose isotonic solution SC. Since in most cases anthrax symptoms are visible only in close proximity to death, there were cases where animals succumbed to the disease.

Animals (female Rhesus macaque) were anesthetized using 100mg ketamine and 10mg xylazine and infected by spraying *B. anthracis* Vollum spore suspension ($10xLD_{50}$) into their nasal cavity with a MicroSprayer® Aerosolizer for Rats — Model IA-1B-R (PennCentury™). Blood samples (3 ml) were drawn from a limb vein every 4h starting 24 hours post inoculation, and serum PA concentration was determined using an ELISA (12) as a correlate for bacteremia level. When bacteremia was estimated as $>10^4$ CFU/ml, blood was drawn and plated to determine the exact bacteremia (CFU/ml) and treatment was initiated.

Animals were treated SC with doxycycline (15 mg/kg) as a monotherapy or combined with Levofloxacin (20 mg/kg) twice a day for three days, followed by doxycycline alone, SC twice a day for four days. Animals were monitored for 14 days post inoculation for behavioral signs and body temperature using a subcutaneous chip in the first 7-8 days.

The use of *Bacillus anthracis* was performed according to the Israeli select agent law. The experiments were regulated and monitored by the head of the biosafety unit and by the institutional regulatory committee at the IIBR. All experiments were conducted in a BSL3 laboratory.

Results

The Doxycycline monotherapy group consisted of six animals with bacteremia between 200 to $3x10^8$ CFU/ml at treatment initiation (Fig 1A). Similar to the efficacy reported in the rabbit model, Doxycycline monotherapy was highly effective, protecting all the animals with bacteremia of up to 10^7 CFU/ml, but failing to protect the animal with bacteremia of $3x10^8$ CFU/ml. Body temperature in all surviving animals (Fig 2A) showed minimal differences throughout the treatment period. In contrast, there was a rapid decrease in temperature of the animal that succumbed to the infection. This animal died within 36h from treatment initiation, it's body temperature dropping to 32°C within 24h. Gross necropsy revealed high accumulation of plural fluids and high intracranial tension that included hemorrhage. Both blood and brain were sterile.

Since in the case of systemic disease the combination of at least two antibiotics is recommended, we tested the effect of adding Levofloxacin to the treatment. This treatment group consist of five animals with bacteremia of $5x10^4$ to $4x10^7$ CFU/ml. This combined treatment was highly effective, protecting animals with a bacteremia of $5x10^4$ to $2x10^6$ CFU/ml (Fig 1B). This treatment did not protect a single animal with $4x10^7$ CFU/ml. Body temperature monitoring (Fig 2B) showed again that in surviving animals no major changes were observed, while there was a slow decrease in temperature during the four days from treatment initiation to death in the animal that succumbed. Once this was detected, a warming infrared lamp was added and 200 ml of saline were administrated SC twice a day. This limited supportive treatment, on top of the therapeutic protocol, did not prevent the animal's death. However, intensive care level of treatment might have been be more effective in preventing animal's death. Gross necropsy did not revile any obvious damage to internal organs and there was no bacterial growth in blood or brain samples.

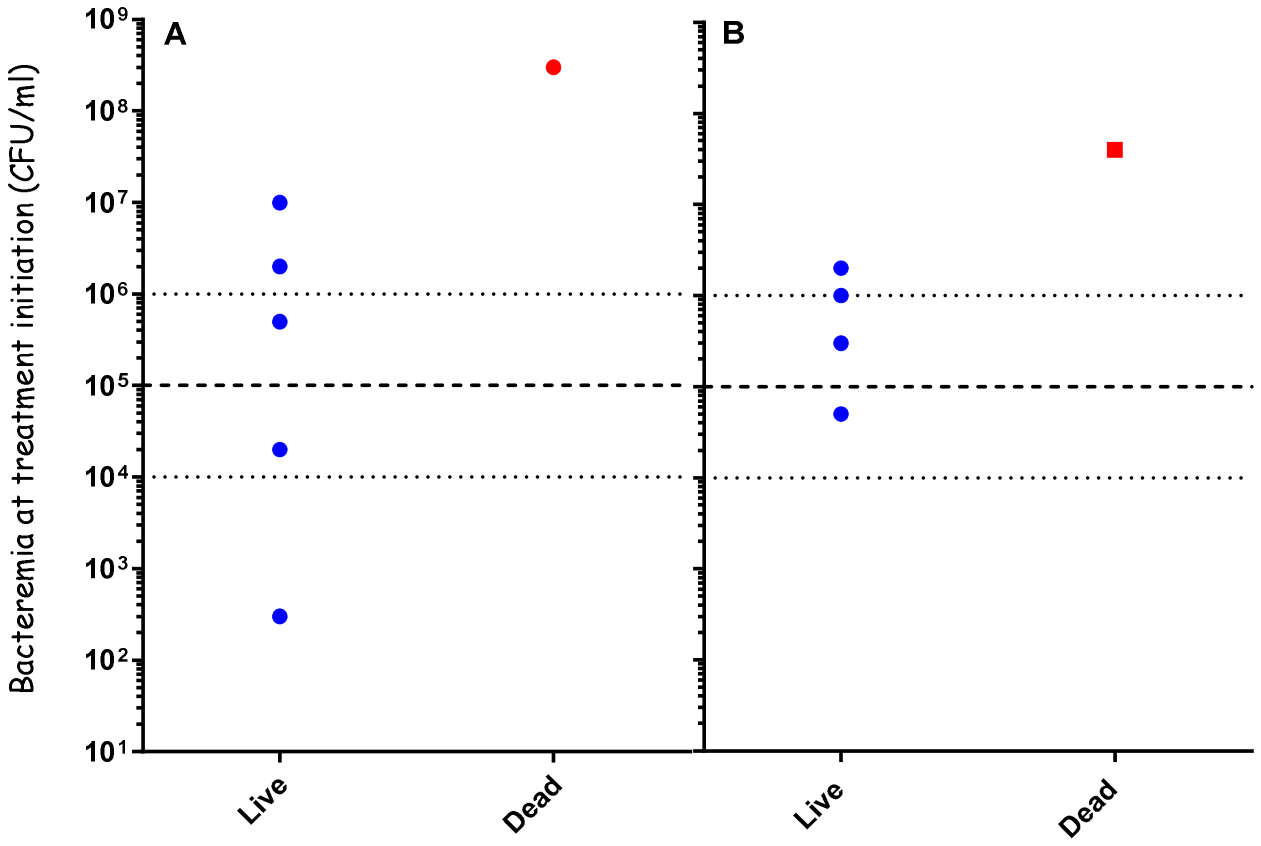

Figure 1. Outcome of inhalation anthrax treatment with Doxycycline alone or in combination with Levofloxacin. Animals were infected intranasally with Vollum spores using a PennCentury™ device. Disease progression was monitored by determining serum PA concentration which served as the trigger to treat. Bacteremia (CFU/ml) at treatment initiation and outcome the treatment (Live or Dead) is indicated for **A** – Doxycycline and **B** – Doxycycline + Levofloxacin.

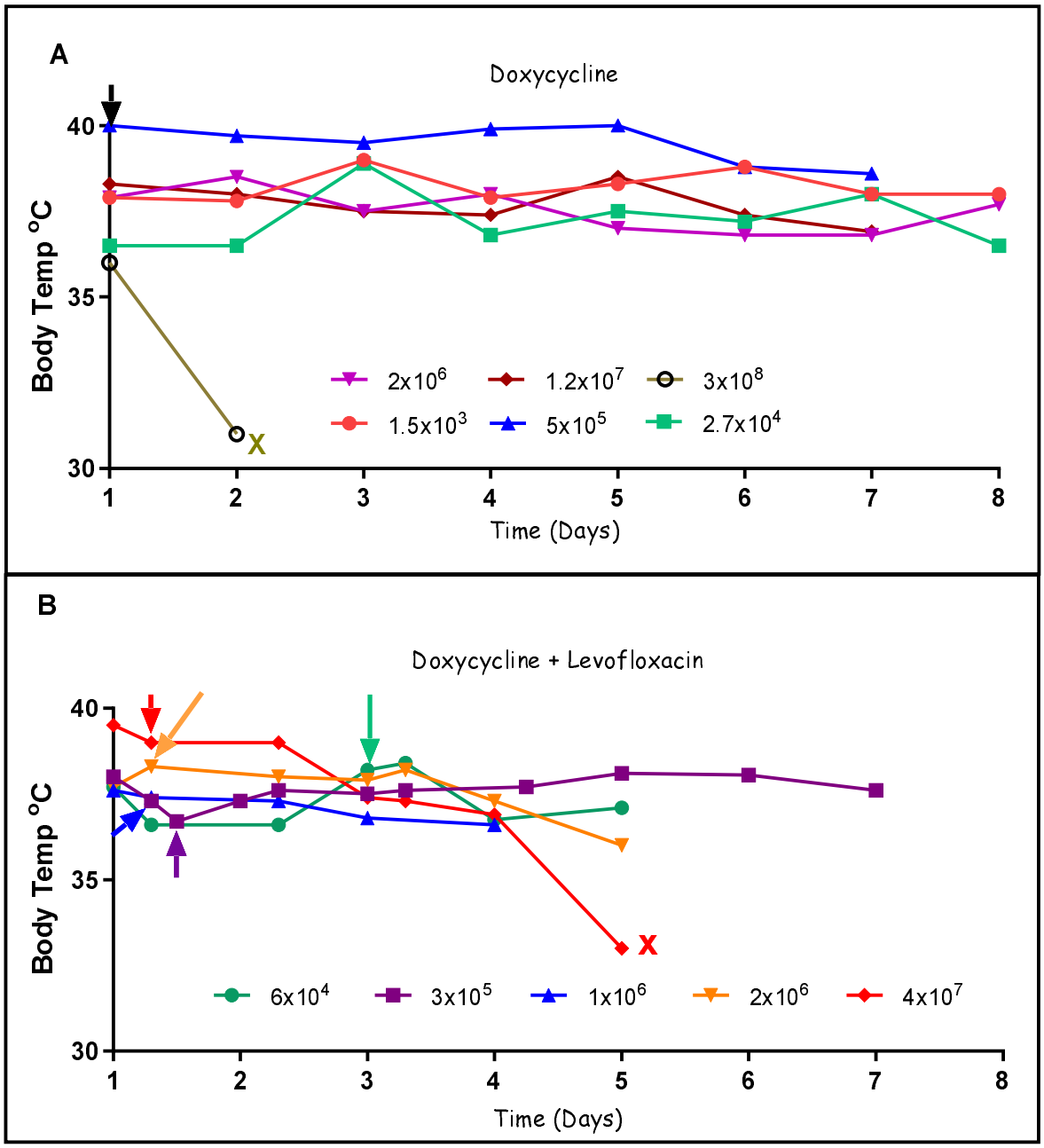

Figure 2. Body temperature of individual animals during the treatment period. A subcutaneous chip was used to record body temperature throughout the treatment period. **A** - Doxycycline and **B** - Doxycycline + Levofloxacin. Arrows indicate treatment initiation and X indicated that the specific animal succumbed to the disease. The Doxycycline treatment was initiated at 24 h (black arrow) post infection, while in the Doxycycline + Levofloxacin experiment the treatment onset variation was high and the arrows are color coded according to the specific animal treated. The Bacteremia at treatment initiation is indicated in the legend.

Discussion

Treating systemic anthrax is complicated due to the possible involvement of CNS infections. Previously we demonstrated that Doxycycline, both as monotherapy or combined with Levofloxacin, is effective in treating late-stage systemic disease or following direct CNS infection in rabbits. We also demonstrated that this treatment is effective in NHP following direct CNS infection. Herein we tested the efficacy of Doxycycline treatment of late-stage systemic disease following airway spore infection in NHP. This finding supports our previous rabbit results and the recent CDC recommendations for treating this stage of the disease.

References

1. Dixon TC, Meselson M, Guillemin J, Hanna PC. Anthrax. New England Journal of Medicine. 1999;341(11):815-26.
2. Hanna P. Anthrax pathogenesis and host response. Curr Top Microbiol Immunol. 1998;225:13-35.
3. WHO. Anthrax in humans and animals: World Health Organization; 2008. Available from: http://www.who.int/csr/resources/publications/anthrax_webs.pdf.
4. Sirisanthana T, Brown AE. Anthrax of the gastrointestinal tract. Emerging infectious diseases. 2002;8(7):649-51.
5. Doganay M, Metan G, Alp E. A review of cutaneous anthrax and its outcome. Journal of Infection and Public Health. 2010;3(3):98-105.
6. Hanczaruk M, Reischl U, Holzmann T, Frangoulidis D, Wagner DM, Keim PS, et al. Injectional anthrax in heroin users, Europe, 2000-2012. Emerging infectious diseases. 2014;20(2):322-3.
7. Centers for Disease C, Prevention. Update: Investigation of bioterrorism-related anthrax and interim guidelines for exposure management and antimicrobial therapy, October 2001. MMWR Morb Mortal Wkly Rep. 2001;50(42):909-19.
8. Bower WA, Hendricks K, Pillai S, Guarnizo J, Meaney-Delman D, Centers for Disease C, et al. Clinical Framework and Medical Countermeasure Use During an Anthrax Mass-Casualty Incident. MMWR Recomm Rep. 2015;64(4):1-22.
9. Bower WA, Yu Y, Person MK, Parker CM, Kennedy JL, Sue D, et al. CDC Guidelines for the Prevention and Treatment of Anthrax, 2023. MMWR Recomm Rep. 2023;72(6):1-47.
10. Ben-Shmuel A, Glinert I, Sittner A, Bar-David E, Schlomovitz J, Levy H, et al. Doxycycline, levofloxacin, and moxifloxacin are superior to ciprofloxacin in treating anthrax meningitis in rabbits and NHP. Antimicrob Agents Chemother. 2024:e0161023.
11. Altboum Z, Gozes Y, Barnea A, Pass A, White M, Kobiler D. Postexposure prophylaxis against anthrax: evaluation of various treatment regimens in intranasally infected guinea pigs. Infect Immun. 2002;70(11):6231-41.
12. Weiss S, Kobiler D, Levy H, Pass A, Ophir Y, Rothschild N, et al. Antibiotics cure anthrax in animal models. Antimicrob Agents Chemother. 2011;55(4):1533-42.
13. Sittner A, Bar-David E, Glinert I, Ben-Shmuel A, Schlomovitz J, Levy H, et al. Closing the Gaps: Testing the Efficacy of Carbapenem and Cephalosporin Treatments of Late-Stage Anthrax in Rabbits. Pathogens. 2024;13(11).