bioRxiv preprint doi: https://doi.org/10.1101/211763; this version posted January 7, 2018. The copyright holder for this preprint (which was not certified by peer review) is the author/funder, who has granted bioRxiv a license to display the preprint in perpetuity. It is made available under aCC-BY 4.0 International license.

Comparison of the 3D-IR - BTFE method and the conventional method in the head MRI contrast.

Daisuke Hirahara

Kagoshima Medical Professional College,Medical Radiological Technology

Email address:ffieldai@gmail.com

Abstract

Imaging MRI using gadolinium contrast media is useful to diagnosis. There is a nephrogenic systemic fibrosis as side effects of serious gadolinium contrast media. Moreover, it turns out that gadolinium deposits in a brain. The necessity for suitable use of gadolinium contrast media increased from this. I developed the new imaging method excellent in contrast. This research examined the usefulness of the new imaging method. It was suggested that the new imaging method has a high usefulness.

1)Background

Exact diagnosis of a metastatic brain tumor is important for a stage judging and a future treatment policy determination. The first choice of a metastatic brain tumor is imaging MRI which uses double the amount of gadolinium contrast media.[1-4] MRI using gadolinium contrast media plays an important role also in the differential diagnosis of other brain tumor examinations. However, the nephrogenic systemic fibrosis (NSF) which is serious side effects was reported to gadolinium contrast media. One of the causes of NSF is that contrast media chemical structure is not a macro ring contexture. Another cause is the numerousness of the amount used. In use of gadolinium contrast media, a renal function check came to be performed from this. Moreover, the amount used and the interval of contrast media were optimized. By the report of Kanda and others in 2013, with the contrast media which is not a macro ring contexture, the self-possessed risk to a brain becomes clear, and, as for any contrast media other than a macro ring contexture, recommendation of use is not carried out. By subsequent research, it turned out that I have deposited slightly in the brain also with the macro ring contexture. In order to avoid a risk, it is clear that it is necessary to use gadolinium contrast media appropriately. [5-7] As for the method of imaging after gadolinium imaging,

bioRxiv preprint doi: https://doi.org/10.1101/211763; this version posted January 7, 2018. The copyright holder for this preprint (which was not certified by peer review) is the author/funder, who has granted bioRxiv a license to display the preprint in perpetuity. It is made available under aCC-BY 4.0 International license.

T1 image of a spin echo method is used. Three-dimensional gradient echo imaging method (3D-GRE) T1 image is also used. The MPRAGE method is used in 3T by the influence of SAR and T1 extension.

2)Purpose

If there is an imaging method that emphasizes the contrast effect more than the conventional imaging method, there is a high possibility of reducing the risk of side effects due to the reduction of the gadolinium contrast agent. Further, there is a high possibility of improving the lesion detection rate due to the rise in contrast. In this study, 3D-IR (IR) with inversion recovery method (IR) added to obtain T1 emphasis based on a balanced turbo field echo (BTFE) sequence which is a coherent gradient echo method which is a high signal-to- -BTFE imaging method was prepared and the conventional imaging method and contrast were examined.[8]

3) Apparatus and method

This survey was conducted in accordance with the Declaration of Helsinki, subjects orally agreed. An object is eight examples of metastatic brain tumor search. The equipment used is a superconducting 1.5 Tesla MRI machine (Intera Achieva Nova, PHILIPS). A use coil is an 8CH SENSE head coil. The contrast media used prescribes gadolinium (HP-DO 3A) (0.4ml / kg) for the patient. EZR was used for statistical processing.[9] I picturized the slice thickness of 3 mm of T1 emphasis picture (SE-T1WI) of a two-dimensional spin echo method, and the slice thickness of 1 mm of the three-dimensional gradient echo method (3D-GRE), and 3D-IR-BTFE also imaged the slice thickness of 1 mm. I reconstructed in slice thickness of 3 mm so that it could compare with SE-T1WI about the picturizing method with a slice thickness of 1 mm. In order to eliminate the order effect, imaging order of each imaging method after gadolinium imaging was random. In consideration of the distribution to the brain of gadolinium contrast media, I started the image pick-up 5 minutes after after contrast media pouring. The main imaging conditions are shown in Table 1 and Table 2.

bioRxiv preprint doi: https://doi.org/10.1101/211763; this version posted January 7, 2018. The copyright holder for this preprint (which was not certified by peer review) is the author/funder, who has granted bioRxiv a license to display the preprint in perpetuity. It is made available under aCC-BY 4.0 International license.

FOV	230	Slice thickness	3mm
RFOV	80	Slice gap	0mm
MATRIX	256	Scan mode	MS
RECON	512	Technique	SE
Scan%	70	TR	462
SENSE	No	TE	15
Slices	48	Flip angle	90
NSA	2	Scan time	6min49sec

Table 1: shows the main imaging parameters of the SE-T1 WI.

FOV	230	Slice thickness	1mm
RFOV	80	Slice gap	0mm
MATRIX	224	Scan mode	3D(IR delay:1200)
RECON	256	Technique	FFE(TFE factor:256)
Scan%	110	TR	4.3
SENSE	YES (P:2.5,S:1.0)	TE	2.2
Slices	140	Flip angle	60
NSA	2	Scan time	3min38sec

Table 2: shows the main imaging parameters of the created 3D-IR-BTFE.

Evaluation compared contrast. Contrast comparison set the area of interest (ROI) as a pathological change and brain substance, and evaluated it.

bioRxiv preprint doi: https://doi.org/10.1101/211763; this version posted January 7, 2018. The copyright holder for this preprint (which was not certified by peer review) is the author/funder, who has granted bioRxiv a license to display the preprint in perpetuity. It is made available under aCC-BY 4.0 International license.

4) Result

A part of actually obtained image is shown in Fig. 1.

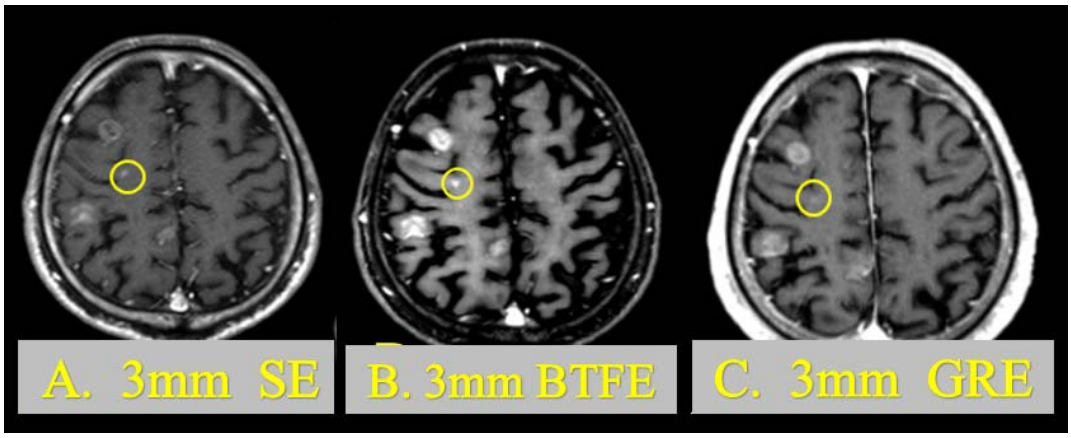

FIG. 1: shows an image actually photographed.

A is SE-T1 WI of 3 mm after imaging.

B is 3D-IR-BTFE of 3 mm after imaging.

C is 3D-IR-BTFE of 1 mm after imaging.

The example of a setting of ROI is shown in Fig. 2.

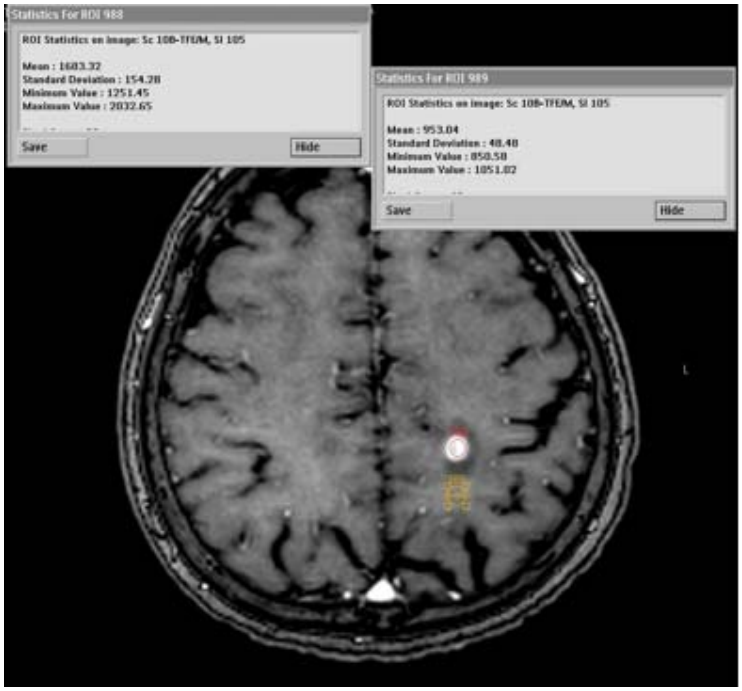

FIG. 2: shows a method of setting the actual region of interest.

bioRxiv preprint doi: https://doi.org/10.1101/211763; this version posted January 7, 2018. The copyright holder for this preprint (which was not certified by peer review) is the author/funder, who has granted bioRxiv a license to display the preprint in perpetuity. It is made available under aCC-BY 4.0 International license.

The result of the difference of the average value of SE-T1WI and 3D-IR-BTFE is shown in Fig. 3. The difference test of the average value was t (19) = - 8.252, p <.01 (p = 0.0000001), d = - 9.64.

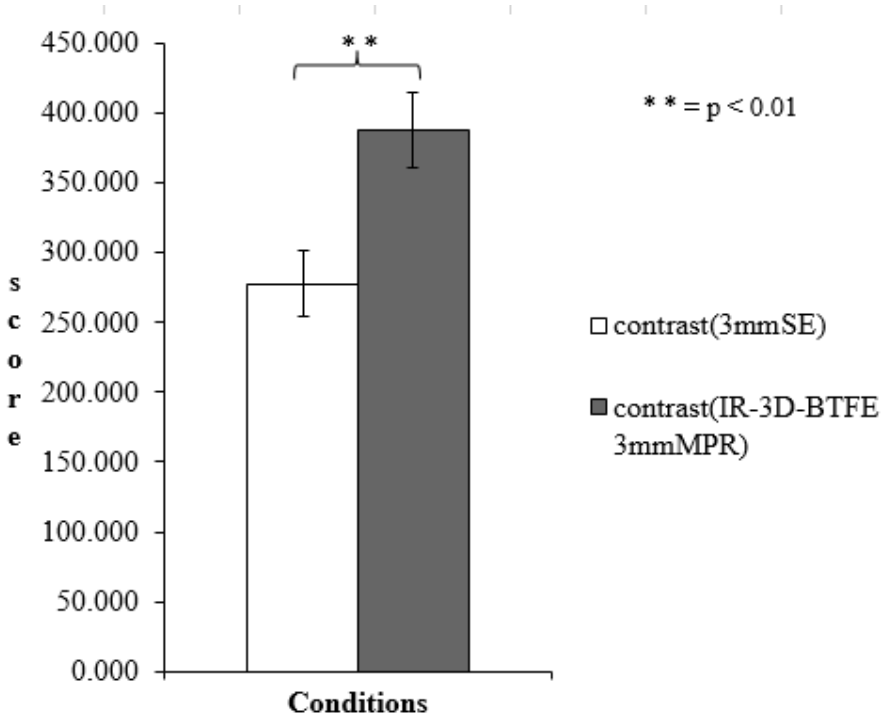

Fig. 3: shows the test results of the difference between the average value of SE-T1WI and 3D-IR-BTFE (slice thickness 3 mm).

The result of the difference of the average value of slice thickness 1 mm of SE-T1WI and 3D-IR-BTFE is shown in Fig. 4. The difference test of the mean value was t (19) = -10.828, p <.01 (p = 0.0000000014), d = -1.656.

bioRxiv preprint doi: https://doi.org/10.1101/211763; this version posted January 7, 2018. The copyright holder for this preprint (which was not certified by peer review) is the author/funder, who has granted bioRxiv a license to display the preprint in perpetuity. It is made available under aCC-BY 4.0 International license.

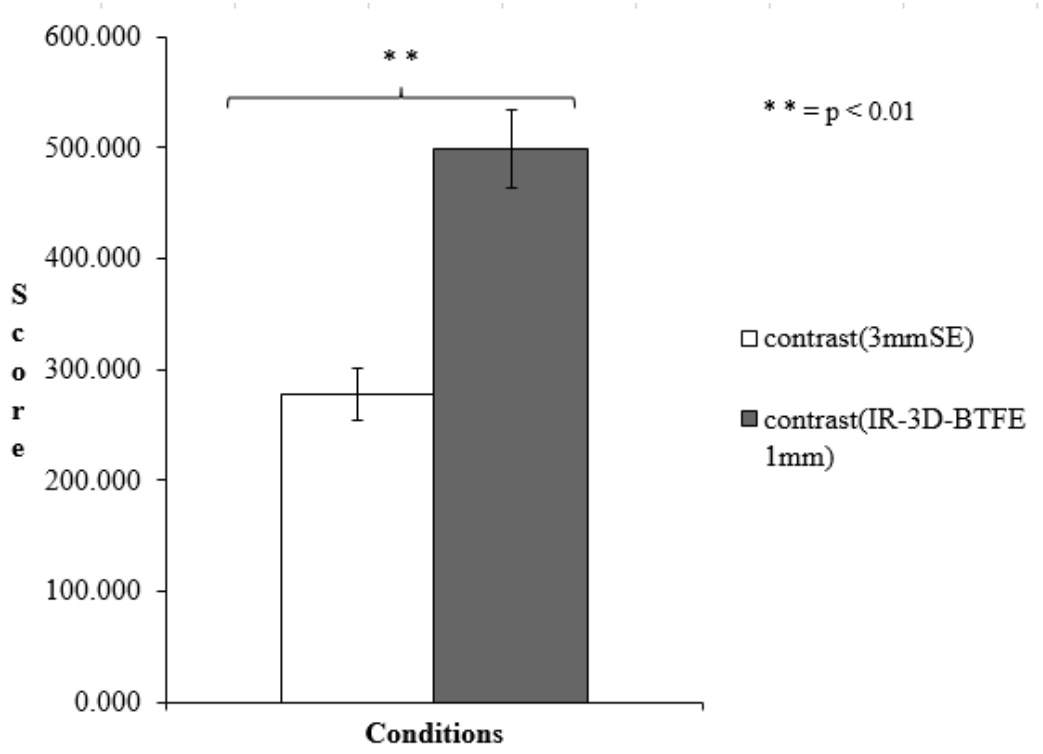

Fig. 4: shows the test results of the difference between the average value of SE-T1WI and 3D-IR-BTFE (slice thickness 1 mm).

The result of the difference of the average value of 3D-IR-BTFE 3mm and 3D-IR-BTFE 1mm is shown in Fig. 5. The difference test of the average value was t (19) = -5.637, p <.01 (p = 0.000019), d = -787.

bioRxiv preprint doi: https://doi.org/10.1101/211763; this version posted January 7, 2018. The copyright holder for this preprint (which was not certified by peer review) is the author/funder, who has granted bioRxiv a license to display the preprint in perpetuity. It is made available under aCC-BY 4.0 International license.

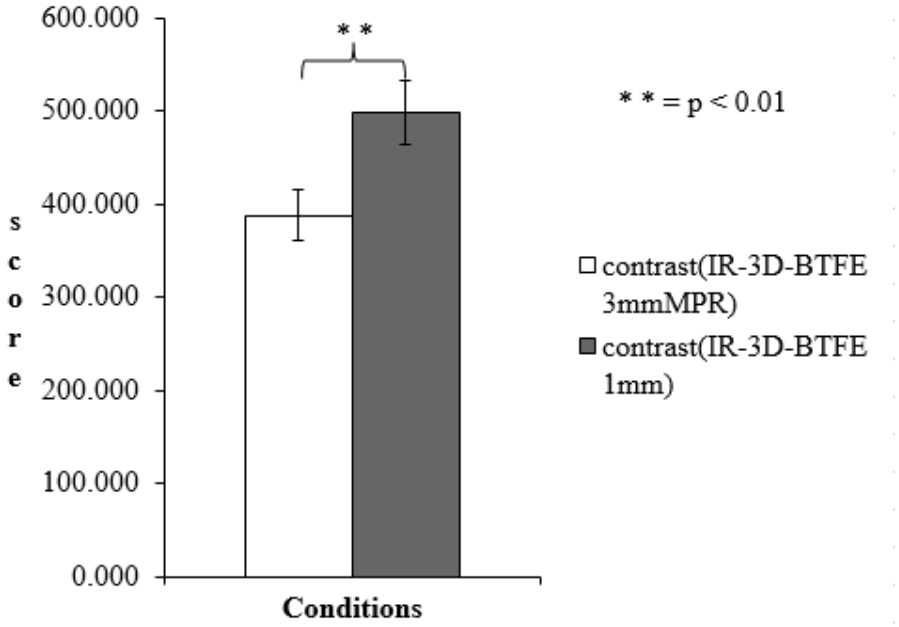

FIG. 5: shows a test result of the difference between the average value of 3D-IR-BTFE (slice thickness 3 mm) and 3D-IR-BTFE (slice thickness 1 mm).

The result of the difference between the slice thickness of 3 mm of SE-T1WI and IR-3 D-BTFE and the average of the ranks of IR-3 D-BTFE 1mm (Friedman examination) is shown in Fig. 6. The difference test was z (14) = 36.100, p <.01 (p = 0.00000001), r = .602.

bioRxiv preprint doi: https://doi.org/10.1101/211763; this version posted January 7, 2018. The copyright holder for this preprint (which was not certified by peer review) is the author/funder, who has granted bioRxiv a license to display the preprint in perpetuity. It is made available under aCC-BY 4.0 International license.

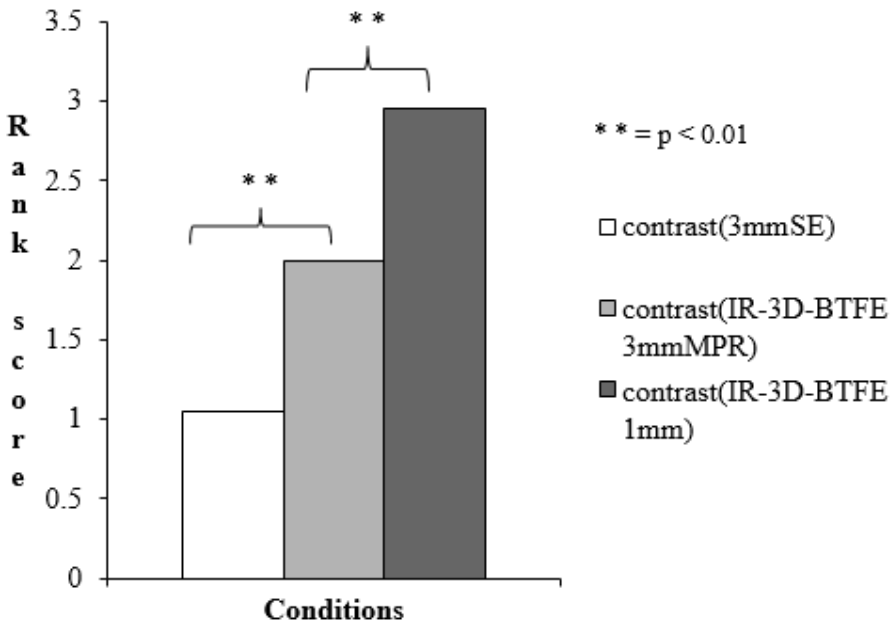

FIG. 8: shows the results of Friedman's test of the difference between SE-T1 WI and 3D-IR-BTFE (slice thickness 3 mm) and 3D-IR-BTFE (slice thickness 1 mm).

Contrast comparison of 3D-IR-BTFE and 3D-GRE is shown in Table 3. 3D-IR-BTFE has excellent contrast of 11 lesions per 12 lesions.

bioRxiv preprint doi: https://doi.org/10.1101/211763; this version posted January 7, 2018. The copyright holder for this preprint (which was not certified by peer review) is the author/funder, who has granted bioRxiv a license to display the preprint in perpetuity. It is made available under aCC-BY 4.0 International license.

	3D-IR-BTFE			3D-GRE			Contrast difference
	Lesion	White matter	contrast	Lesion	White matter	contrast	3D-IR-BTFEcontrast - 3D-GREcontrast
1	2025.5	609.6	1415.9	1726.6	515.3	1211.3	204.6
2	1232.8	631	601.8	1113.2	531.7	581.5	20.3
3	1504.1	507.1	997	892.7	406.6	486.1	510.9
4	1196.6	507.1	689.5	819.3	406.6	412.7	276.8
5	1091.1	727.5	363.6	682.4	531.9	150.5	213.1
6	1320.8	891.8	429	887.1	558	329.1	99.9
7	1183.3	906.4	276.9	855.6	576	279.6	-2.7
8	1254.1	793.3	460.8	712.5	587	125.5	335.3
9	1209.9	793.3	416.6	844.2	587	257.2	159.4
10	1919.4	770.9	1148.5	1189.6	476.9	712.7	435.8
11	1508.9	857.5	651.4	970.3	658.6	311.7	339.7
12	1329	626.1	702.9	1017.5	554.3	463.2	239.7

Table 3: shows a comparison of contrast between 3D-IR-BTFE and 3D-GRE.

The result of the difference of the average value of 3D-IR-BTFE 3mm and 3D-GRE 3mm is shown in Fig. 7. The difference test of the average value was $t(11) = 5.247$, $p < .01$ ($p = 0.00027$), $d = 0.74$. From this result, it was shown that 3D-IR-BTFE has better contrast than 3D-GRE.

bioRxiv preprint doi: https://doi.org/10.1101/211763; this version posted January 7, 2018. The copyright holder for this preprint (which was not certified by peer review) is the author/funder, who has granted bioRxiv a license to display the preprint in perpetuity. It is made available under aCC-BY 4.0 International license.

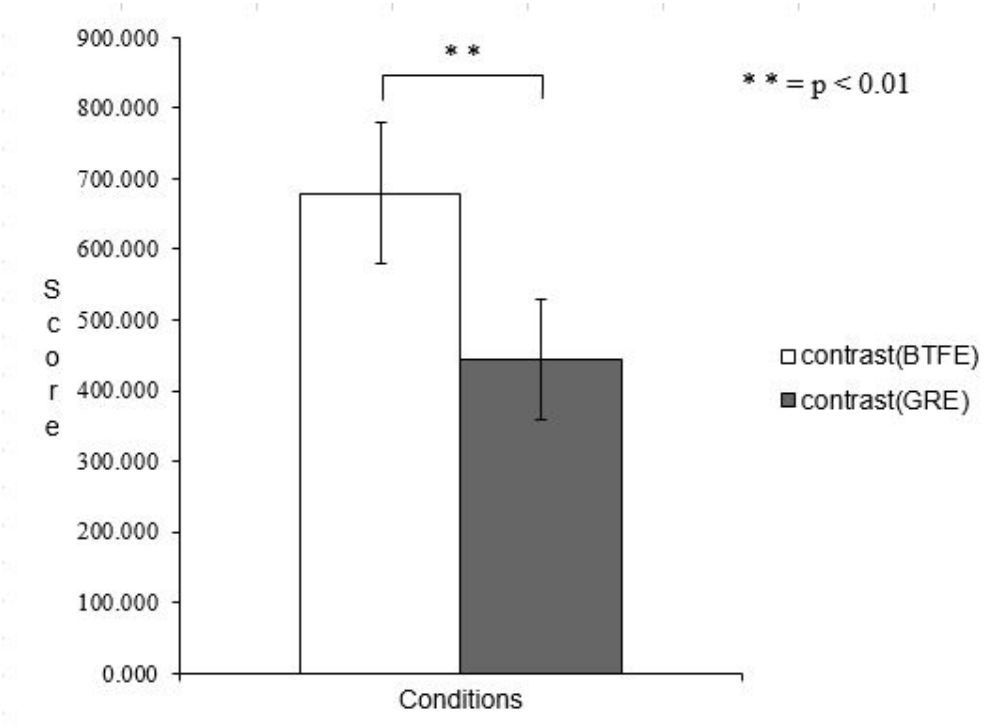

FIG. 9: shows a test result of the difference between the average value of 3D-IR-BTFE and 3D-GRE.

5) Discussion

What is required clinically in diagnostic imaging of brain metastasis is to capture the presence of metastatic lesions, then the extent and size of metastatic lesions are important. If gadolinium contrast media is prescribed for the patient, I can reinforce contrast according to the T1 shortening effect. However, gadolinium contrast media and the T1 shortening effect are not necessarily in direct proportion. Usually, it has been a standard which prescribes 0.2 ml per weight of 1 kg for the patient. For the purpose of brain metastasis lesion search, it is permitted to administer twice the amount of specific gadolinium contrast agent only. The contrast enhancing effect by gadolinium contrast media has a limit. For this reason, we only have to increase the contrast with imaging method or static magnetic field strength. The one that can raise the T1 contrast most in the imaging method is IR. 3D-IR-BTFE secured T1 contrast by adding IR. In the image pick-up by two dimensions, from the characteristic of RF pulse, MRI equipment needs to prepare an interval between slices. This may be a problem searching for metastatic lesions. A problem will be solved if it can picturize by three dimensions. However, imaging in three dimensions increases the imaging time. In order to eliminate this

bioRxiv preprint doi: https://doi.org/10.1101/211763; this version posted January 7, 2018. The copyright holder for this preprint (which was not certified by peer review) is the author/funder, who has granted bioRxiv a license to display the preprint in perpetuity. It is made available under aCC-BY 4.0 International license.

problem, a high signal-noise ratio imaging method must be selected. BTFE, in which TR is set short and imaged in steady state without eliminating residual transverse magnetization, is an imaging method that can obtain excellent SNR and contrast. For this reason BTFE was chosen. In the MRI apparatus studied this time, the signal of the transition period can also be acquired. The signal of transition period can enlarge influence of T1 contrast. The T1 contrast can be increased by restoring longitudinal magnetization. In order to realize the longitudinal magnetization recovery, the parameter's Shot interval was lengthened to 4000 ms. I considered the possibility that the recovery of the longitudinal magnetization became large by these, and excellent T1 emphasis was obtained. 3D-IR-BTFE considered SNR to be larger by BTFE than SE and Gradient echo. It was thought that good contrast was obtained by addition of IR. In order to obtain the further contrast from now on, I thought that it was necessary to optimize IR and the numerical value of Shot interval. Based on the above discussion, post-contrast 3D-IR-BTFE is superior not only to the existence diagnosis of brain metastatic lesion but also to diagnosis of spread of metastatic lesion and it is expected to be added to conventional SE-T1WI and 3D-GRE . From restriction of SAR, with three-tesla equipment, also when an image pick-up is difficult, I think. In a high magnetic field device with 3 Tesla or more, it is necessary to investigate another imaging method to which IR is added, and to find a method of reducing the contrast medium.

6) Conclusion

This research is the subject announced in the 37th Japanese Society of Magnetic Resonance in Medicine conventions in September, 2009. Since use of gadolinium contrast media had increased strictness more in recent years, I performed paper. This study found that 3D-IR-BTFE with IR added was superior in contrast. It is possible to acquire images of thin slices in a shorter time than the conventional imaging method and it was suggested that the Coherent type Gradient echo method could be used as a new routine of a possible apparatus. It was also suggested that if you aim to diagnose with the same degree of contrast as Spin Echo or Gradient echo you could reduce the contrast medium. The further examination is required for what contrast media loss in quantity is realized concretely. It was also suggested that 3D-IR-BTFE with excellent contrast contrast could be useful for every examination if it is a site with little effect of motion.

Disclosure of Conflicts of interest

bioRxiv preprint doi: https://doi.org/10.1101/211763; this version posted January 7, 2018. The copyright holder for this preprint (which was not certified by peer review) is the author/funder, who has granted bioRxiv a license to display the preprint in perpetuity. It is made available under aCC-BY 4.0 International license.

The author indicated no conflicts of interest.

References

1.Akeson F, Larssqn E, Kristoffersen D, Jonsson E, Holtas S. BRAIN METASTASES COMPARISON OF GADODIAMIDE INJECTION ENHANCED MR IMAGING AT STANDARD AND HIGH DOSE, CONTRAST- ENHANCED CT AND NON-CONTRAST-ENHANCED MR IMAGING. Acta Radiologica 1995; 36:300-306.

2.W. Schorner, M. Laniado, H. P. Niendorf, Chr. Schubert, R. Felix- Time Dependent Changes in Image Contrast in Brain Tumors After GadoliniumDTPA. AJNR 1986; 7:1013-1020.

3.E J Russell, G K Geremia, C E Johnson, et al Multiple cerebral metastases: detectability with Gd-DTPA-enhanced MR imaging. Radiology 1987; 165:609-617.

4.Suzuki K, Yamamoto M, Hasegawa Y, et al. Magnetic resonance imaging and computed tomography in the diagnoses of brain metastases of lung cancer. Lung Cancer 2004; 46:357-360.

5.Kanda T, Ishii K, Kawaguchi H, Kitajima K, Takenaka D. High signal intensity in the dentate nucleus and globus pallidus on unenhanced T1-weighted MR images: relationship with increasing cumulative dose of a gadolinium-based contrast material. Radiology 2014; 270:834-841.

6.Kanda T, Osawa M, Oba H, et al. High Signal Intensity in Dentate Nucleus on Unenhanced T1-weighted MR Images: Association with Linear versus Macrocyclic Gadolinium Chelate Administration. Radiology 2015;275: 803-809.

7. Kanda T, Oba H, Toyoda K, Kitajima K, Furui S. Brain gadolinium deposition after administration of gadolinium based contrast agents. Japanese Journal of Radiology 2016; 34: 3-9.

8. Armin Huber, Stefan O, Schoenberg, Benedikt Spannagl, et al. Single-Shot Inversion Recovery TrueFISP for Assessment of Myocardial Infarction. AJR 2006 Mar;186(3):627-633.

bioRxiv preprint doi: https://doi.org/10.1101/211763; this version posted January 7, 2018. The copyright holder for this preprint (which was not certified by peer review) is the author/funder, who has granted bioRxiv a license to display the preprint in perpetuity. It is made available under aCC-BY 4.0 International license.

9. Kanda Y. Investigation of the freely available easy-to-use software 'EZR' for medical statistics. Bone Marrow Transplantation 2013; 48:452-458.