White matter correlates of hemi-face dominance in emotional expression

Stefano Ioannucci [a-c*], Nathalie George [b], Leonardo Cerliani [a] and Michel Thiebaut de Schotten [a,b*]
[a] Brain Connectivity and Behaviour Group, Brain and Spine Institute, Paris France.

[b] Institut du Cerveau et de la Moelle épinière (ICM), UPMC UMRS 1127, Inserm U 1127, CNRS UMR 7225, Paris, France.

[c] Department of General Psychology, University of Padova, Italy

* Corresponding authors ste.ioannucci@gmail.com and michel.thiebaut@gmail.com

Keywords
Asymmetry, Emotion expression, Lateralization, White matter, Neuroanatomy.

Abstract

The neural underpinnings of human emotional expression are thought to be unevenly distributed among brain hemispheres. However, little is known on the anatomy supporting this claim, particularly in the cerebral white matter. Here we explored the relationship between hemi-face dominance in emotional expression and cerebral white matter asymmetries in 33 participants. Measures of emotional expression were derived from picture of their faces in a 'happy smiling' and a 'sad frowning' conditions. Chimeric faces were constructed by assembling right and left hemi-faces – respectively – with their mirrored version. These faces were presented in competition at the extremities of a 155 mm segment to be marked according to the emotional intensity. A jury made of 10 additional participants evaluated the set of chimeric facial stimuli. Hemispheric asymmetry of the uncinate, the cingulum and the three branches of superior longitudinal fasciculi were derived from diffusion weighted imaging tractography dissections. Group effect analyses indicated that the degree of asymmetry in emotional expression was not as prominent as reported in the literature with a large inter-individual variability. Secondly, anatomical dissections replicated previous finding in white matter anatomical lateralisation. Lastly, a strong relationship was revealed between SLF I and happy hemi-face dominance so that the greater the hemispheric lateralisation of SLF I, the more the expression of happiness in the contralateral half of the face. This result brings up interesting hypotheses on the relationship of the SLF I and emotional expression, especially its role in mood disorders.

Over a century and a half ago, scientific research started to gather proof for the asymmetrical organization of the brain. Since the acknowledgement of Broca's area (Broca 1861), the left hemisphere has been recognized as predominant in the language domain, whilst the right hemisphere has been linked to space, emotions, and their processing (Babinski 1914, Mills 1912,Sperry 1974).

Focusing on the emotion dimension, during this considerable time course a plethora of converging evidence has been gathered from cognitive, neuroanatomical, neuropsychological, and behavioural studies, with substantial methodological diversity in paradigms, measures, populations, and emotional aspect investigated (e.g. perception, recognition, production, autonomic components). (Borod 1993,Demaree et al. 2005,Silberman and Weingartner 1986).

Consequently, a variety of theoretical approaches have been developed to frame these findings, such as the Right Predominance hypothesis, the Valence & Approach/Withdrawal model (Demaree et al 2005,Silberman and Weingartner 1986) and the Homeostatic Theory of Emotion (Craig, A.D. 2005). This has resulted in a further increase in the array of experimental designs and research targets applied by the investigators. Hence, to this day, the concept of hemispheric dominance in emotion is still debated, and sometimes regarded as antiquate by many in the field of cognitive sciences.

However, evidence from animal studies, for instance, supports the hemispheric dominance in the processing of emotion (Bradshaw and Rogers 1993,Hellige 2001). Analysing chimeric facial stimuli during emotion production, separate research groups concluded that monkeys were markedly more expressive on the left side of their face, also initiating the expression earlier and ending it later than on the opposite half. (Fernández-Carriba et al. 2002,Hauser 1993) Additionally, in a study with inverted roles, in which specimen of our closest primate ancestor, chimpanzees, rated visual stimuli of composite human smiling faces, a significant preference for the left hemi-spatial field was shown (Morris and Hopkins 1993).

Human studies supporting facial asymmetries during emotional expression have also accumulated across the years. Sackheim et al (1978) employed chimeric facial stimuli expressing 6 different emotions to be evaluated by 86 subjects, finding that the composite images of left/left hemi-faces were reported to be significantly more emotionally expressive. A comprehensive review on the existing literature by Borod et al (1997) concluded that the left hemi-face is more involved than the right hemi-face in the expression of human facial emotion, implicating the right cerebral hemisphere as dominant in such process. However, left and right hemi-faces emotional expressivity were always, to our knowledge, evaluated in isolation rather than in competition, thus limiting the conclusions since it did not favour a clear comparison of each hemi-face expressing the emotion. A

new paradigm comparing directly left and right hemi-faces is required to confirm previous claims of the right hemispheric dominance for the expression of emotions and explore its relationship to brain anatomy.

The striking similarity in results regardless of species is suggestive of a common phylogenetic circuitry for the emotional processes taken into account. The anatomical substrate underlying the hemispheric lateralization of emotional processing remains however, to our best knowledge, elusive.

Both humans and non-human primates have contralateral innervation of lower facial muscles (Falk 1987,Rinn 1984), hence a dominance for the expression and recognition of emotions presented on any side of the face should be related to a contralateral hemispheric asymmetry. It is widely accepted that emotion and related behaviour emerge from the joint activities of a cluster of brain regions known as the limbic system (Catani et al. 2013). Since its earliest conceptualizations, this system has been considered as a complex network of regions that act as an intermediary between a primitive, subcortical, brain and a more evolved, cortical, one (MacLean 1952, Yakovlev 1948). Among the subcortical structures, within the inner anterior temporal lobe lies the amygdala, whose role in emotions has been largely documented (Phelphs 2006,Phelphs and LeDoux 2005). It is thought to be part of a functional subdivision of the limbic system, the temporo-amygdala-orbitofrontal network, which is involved in the integration of visceral and emotional states with cognition and behaviour (Mesulam 2000). Alterations in the aforementioned network have been linked to patients with clinical conditions involving emotional and mood disturbances, such as Fronto-Temporal Dementia (FTD) and psychopathy, among others (Catani et al. 2013). However, abnormalities in white matter pathways are found frequently not only within (i.e. uncinate fasciculus) but also outside (i.e. superior longitudinal fasciculus) the temporo-amygdala-orbitofrontal circuit in patients suffering psychopathy (Craig, M.C. 2009) or behavioural variant FTD (Agosta et al. 2011, Matsuo et al. 2008, Whitwell et al. 2010), whose deficits mainly affect emotional and social processing (Piguet et al. 2011). A second functional subdivision of the limbic system consists in the default-mode network (DMN), a group of medial and lateral regions whose activity increases during passive thought not focused on a particular task (Raichle and Snyder 2007, Raichle et al. 2001). This network is connected by the cingulum and some part of the superior longitudinal fasciculus (SLF), particularly its first branch, the SLF I. A recent meta-analysis by Jenkins et al (2016), found disruptions in the SLF as the most common white matter alteration in patients suffering from psychiatric emotional conditions such as bipolar disorder, social anxiety disorder, major depressive disorder, post-traumatic stress disorder and obsessive-compulsive disorder. Hence the superior longitudinal fasciculus, albeit frequently associated with spatial

functions (Parlatini et al. 2017, Thiebaut de Schotten et al. 2011a) may have an emotional subcomponent.

Given these premises, we hypothesised that the hemispheric lateralisation of the uncinate, cingulum and superior longitudinal fasciculi relates to the hemispheric dominance of expression of emotions in the human brain.

Therefore, the aim of the present study was to contribute to the identification of anatomical biomarkers supporting hemi-face dominance in emotional expression in the human brain. We reconstructed *in vivo* estimates of white matter fibre pathways (Basser et al. 1994) that we statistically related to behavioural measures of emotional expression on chimeric facial stimuli. Results provide a novel insight on the neuroanatomical bases of emotional processing.

Methods

Participants and Emotional expression task

The experiment was approved by the local ethics committee; all participants provided written informed consent in accordance to the Declaration of Helsinki. Participants also received an indemnity of 50 € for their participation.

A first group of 33 subjects (mean age 27.6 ±5.03, 11 male) were included in this study. To obtain a measure of their emotional expression a picture of their faces in a 'happy smiling' and a 'sad frowning' conditions was taken using a CANON PowerShot SD1790 IS 10.0 mega pixels. These photos were edited to remove hair and the border of the face in order to maintain the characteristics that determine the saliency of emotions (e.g. eyes, mouth) and uniformed by normalisation of grey levels. According to previous attempts (42) pictures were split on the midline of the full face and chimeric faces were constructed by assembling each hemi-face with its mirrored version. This resulted in two chimeric facial stimuli, one made of the left side and one made up of the right side (Figure 1a,b).

A second group of 10 participants (mean age 27.4 ±5.12, 5 male) evaluated this set of chimeric facial stimuli expressing either happiness or sadness. For this, they evaluated the Right/Right and Left/Left chimeric faces presented by pairs, at the extremities of a 155mm segment; they had to mark the segment according to the relative emotional intensity of the two stimuli, placing the mark toward the one that expressed the emotion more intensely, both in a Left/Left – Right/Right hemi-face disposal, and reversed Right/Right – Left/Left disposal, in order to control for pseudoneglect effect (28). The overall experiment included 132 trials (33 faces x 2 emotions x 2 disposals of these faces along the segment).

An asymmetry index was calculated for each face and each emotion expressed by the first group of 33 participants, based on the averages of the deviations toward the chimeric stimuli that were rated higher in terms of emotional expressivity, by the second group of 10 judges.

RR and LL Represent the marks towards the stimuli made by mirroring the right half of the face (R/R) or the left one (L/L) as measured by distance from the middle of the segment.

Therefore, a positive score indicated a tendency for left hemi-face dominance in emotional expression rated as more emotionally intense, while a negative score pointed to a right hemi-face dominance.

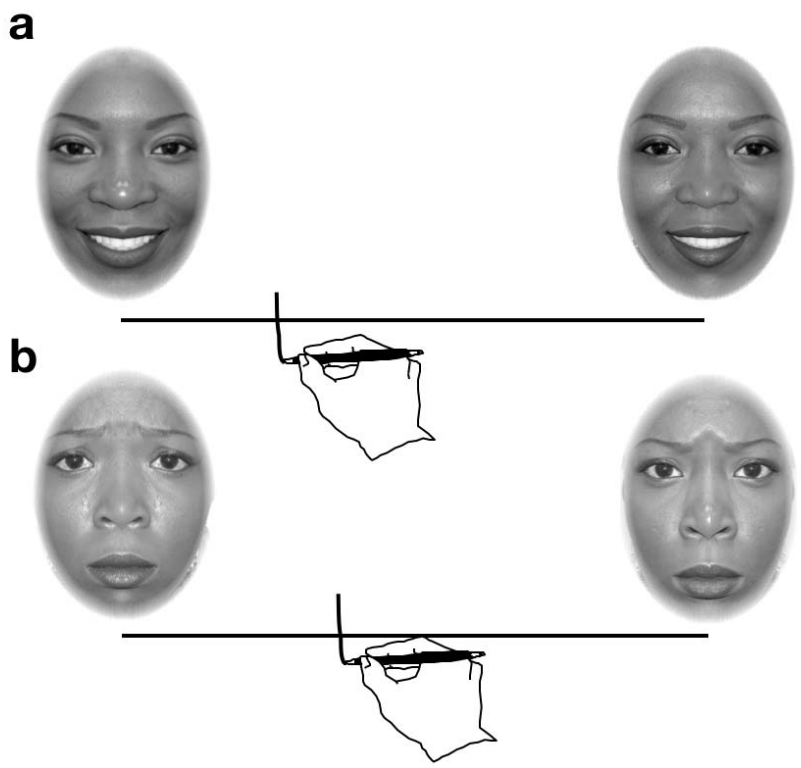

Figure 1: examples of chimeric facial stimuli asymmetry task for the happy (a) and sad (b) conditions.

Magnetic resonance imaging

Magnetic resonance imaging was acquired in the first group of 33 participants.

A total of 81 near-axial slices were acquired on a Siemens 3 Tesla Prisma system equipped with a 64-channel head coil. We used a fully optimised acquisition sequence for the tractography of diffusion-weighted imaging (DWI), which provided isotropic (1.7 × 1.7 × 1.7 mm) resolution and coverage of the whole head with a posterior-anterior phase of acquisition. with an echo time (TE) =

75 msec. We used a repetition time (TR) equivalent to 3500ms. At each slice location, 6 images were acquired with no diffusion gradient applied (b-value of 0 sec mm−2). Additionally, 60 diffusion-weighted images were acquired, in which gradient directions were uniformly distributed on the hemisphere with electrostatic repulsion. The diffusion weighting was equal to a b-value of 2000 s/mm^{-2}. This sequence was fully repeated with reversed phase-encode blips. This provides us with two datasets with distortions going in opposite directions. From these pairs the susceptibility-induced off-resonance field was estimated using a method similar to that described in (Andersson et al. 2003) and corrected on the whole diffusion weighted dataset using the tool TOPUP and EDDY as implemented in FSL (Smith et al. 2004).

Spherical deconvolution was chosen to estimate multiple orientations in voxels containing different populations of crossing fibres (Alexander 2005,Anderson 2005,Tournier et al. 2004). The damped version of the Richardson-Lucy algorithm for spherical deconvolution (Dell'Acqua et al. 2010) was calculated using Startrack (http:///www.natbrainlab.co.uk). Algorithm parameters were chosen as previously described (Dell'Acqua et al. 2012). A fixed-fibre response corresponding to a shape factor of $\alpha = 1.5 \times 10– 3$ mm^2/s was chosen (Dell'Acqua et al. 2012). Fibre orientation estimates were obtained by selecting the orientation corresponding to the peaks (local maxima) of the fibre orientation distribution (FOD) profiles. To exclude spurious local maxima, we applied both an absolute and a relative threshold on the FOD amplitude. A first "absolute" threshold was used to exclude intrinsically small local maxima due to noise or isotropic tissue. This threshold was set to 3 times the mean amplitude of a spherical FOD obtained from a grey matter isotropic voxel (and therefore also higher than an isotropic voxel in the cerebro-spinal fluid).

A second "relative" threshold of 10% of the maximum amplitude of the FOD was applied to remove maximum amplitude of the FOD was applied to remove the remaining local maxima with values greater than the absolute threshold (Dell'Acqua et al. 2010). Whole brain tractography was performed selecting every brain voxel with at least one fibre orientation as a seed voxel. From these voxels, and for each fibre orientation, streamlines were propagated using Euler integration with a step size of 1 mm (as described in (Dell'Acqua et al. 2012)). When entering a region with crossing white matter bundles, the algorithm followed the orientation vector of least curvature (Schmahmann et al. 2007). Streamlines were halted when a voxel without fibre orientation was reached or when the curvature between two steps exceeded a threshold of 60°. Spherical deconvolution, fibre orientation vector estimations and tractography were also implemented in Startrack (www.mr-startrack.com).

Tractography dissections.

Virtual dissections were made of the bilateral tracts on which we had a priori hypotheses, that is, the uncinate fasciculus, superior longitudinal fasciculi (SLF I, II and III) and the cingulum (Figure 3a,b,c).

We employed the software Trackvis (http://www.trackvis.org), which allows for visual inspection of the tracts and extracted a measure of their track count and hindrance modulated orientational anisotropy (HMOA), a new index- employed as a surrogate for tract microstructural organization (Dell'Acqua 2012).

For the isolation of the left and right uncinate fasciculi, a two ROIs approach was used. A coronal ROI was delineated around the white matter of the extreme capsule, together with an axial 'AND' ROI in the anterior temporal region.

A multiple region of interests (ROIs) approach was used to isolate the three components of the superior longitudinal fasciculus (i.e. SLF I, SLF II and SLF III).

Three coronal ROIs were delineated around the white matter of the superior, middle and inferior/precentral frontal gyri, and another three 'AND' ROIs were delineated posteriorly in the parietal region.

Streamlines of the arcuate fasciculus projecting to the temporal lobe were excluded using an axial 'NOT' ROI in the temporal white matter (the arcuate is not part of the longitudinal system as it forms an arc to reach the temporal lobe)

Finally, a two ROIs approach was used to isolate the left and the right cingulum fasciculi. A sagittal ROI was delineated around the white matter of the cingulum for the left and the right hemispheres. Streamlines of the corpus callosum projecting to the hemisphere opposite to the ROI were excluded using a sagittal 'NOT' ROI in the corpus callosum.

An asymmetry index was calculated, based on the averages volumes (i.e. number of streamlines) and HMOA of the uncinate, SLF I, II and III and the cingulum using the following formulae

$$Structural\ Asymmetry\ Index: \quad \frac{RR - LL}{RR + LL}$$

Here RR and LL represent the streamlines count and HMOA values for the tracts in the right (RR) and left (LL) hemispheres. A positive score indicated a larger tract in the right hemisphere whereas a negative score pointed to a leftward asymmetry.

Statistics

We used SPSS software (SPSS, Inc., Chicago, IL, United States of America) to perform one sample t-test against zero on the asymmetry indices of emotional expression and tract specific measurements and Pearson correlation coefficients to estimate proportional relationships between emotional expression and anatomical asymmetry indices.

Results

Behavioural measures

One sample t-test analysis did not reveal any difference between the left and the right side of the face in the happy ($t_{(32)}$= 0.74 ; p = 0.465) and sad conditions ($t_{(32)}$= 0.88 ; p = 0.39) (figure 2a). However, based on the 95% confidence intervals reported in figure 2 b& c, the 33 participants were unevenly distributed with 7 participants (21.2%) with happier right hemi-face and 8 participants (24.2%) with a happier left hemi-face (figure 3b). Similarly, 3 participants (9.1%) had a right sadder hemi-face whereas 6 (18.2%) showed a sadder left hemi-face.

Moreover, there was a significant correlation in the degree of emotional expression asymmetry between the happy and sad condition (figure 2d, Pearson correlation r = 0.47, p = 0.006).

Finally there were no gender differences in the happy ($t_{(1,31)}$= –1.67 ; p = 0.11) and in the sad ($t_{(1,31)}$= 0.26 ; p = 0.80) conditions of the experiment.

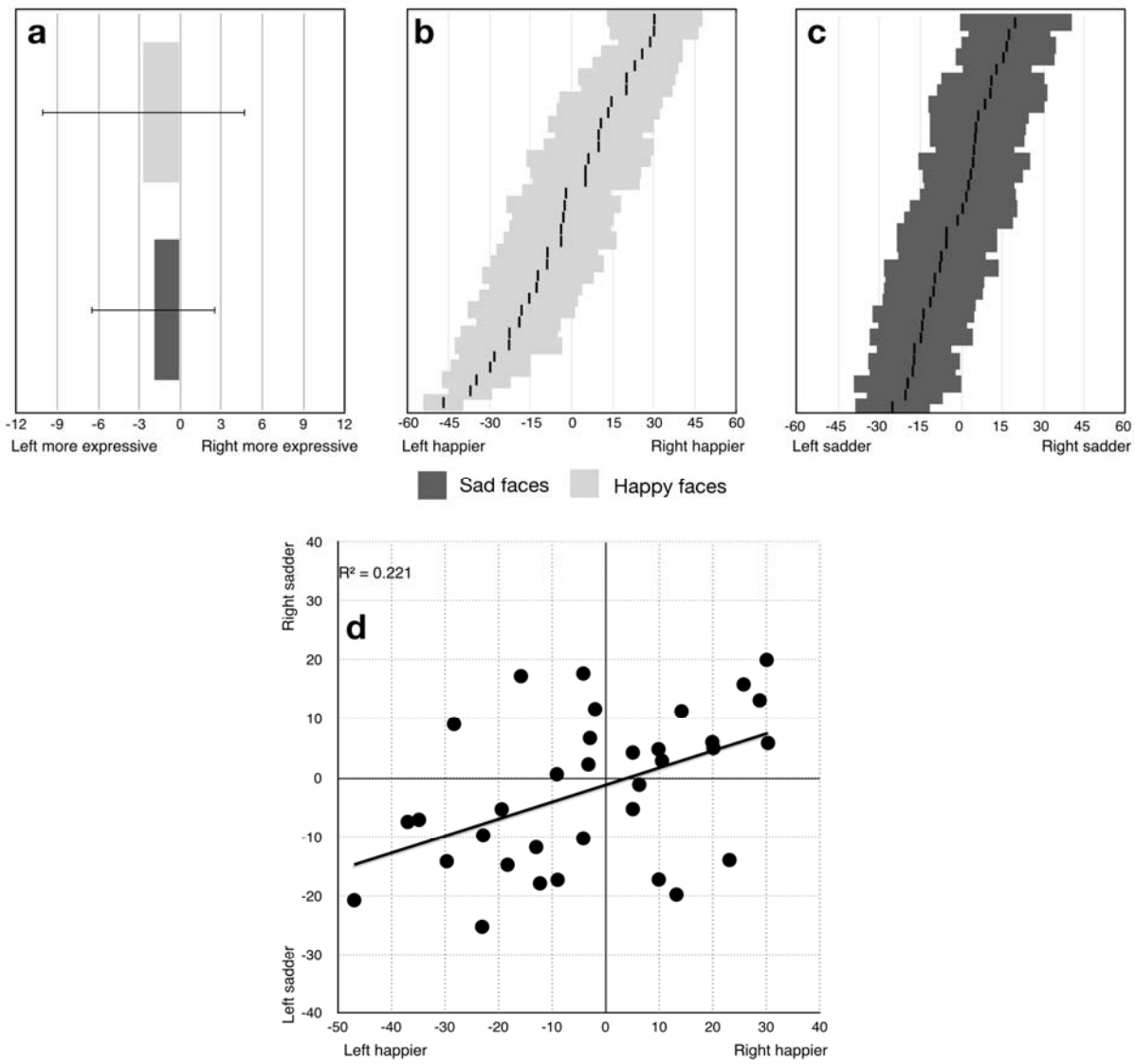

Figure 2: Behavioural measures of emotional expression asymmetries. a) Overall emotional asymmetry index for happy and sad expressions; filled bars indicate the average of the 33 participant's faces and horizontal lines correspond to 95% confidence intervals b-c) Individual emotional expression asymmetries scores for the 33 faces (in ordinate, ordered by increasing asymmetry index value), the ticks correspond to the mean score across the 10 judges for happy (in b, light grey) and sad (in c dark grey) conditions; filled bars correspond to 95% confidence intervals. * indicate faces for which 95% confidence intervals reveal significant emotional expression asymmetries d) dimensional relationship between sad and happy faces emotional expression asymmetries.

Structural measures.

First, Paired sample t-test analysis demonstrated that there was no significant difference in ROIs size between the left and the right hemispheres ($t_{(32)} < 1$).

One sample t-test analysis revealed a significant rightward hemispheric asymmetry for the number of streamlines of the uncinate fasciculus ($t_{(32)}$= 3.24 ; p = 0.003) and the SLF III ($t_{(32)}$= 7.84 ; p < 0.001), and for the HMOA of the SLF II ($t_{(32)}$= 3.34 ; p = 0.002) and the SLF III ($t_{(32)}$= 5.24 ; p < 0.001) (Figure 3d,e). A significant leftward hemispheric asymmetry was found for the cingulum both in streamline counts ($t_{(32)}$= –3.51; p = 0.001) and HMOA ($t_{(32)}$= –2.16; p = 0.039) and for the SLF I HMOA ($t_{(32)}$= –3.27 ; p = 0.003) (Figure 3d,e). P values were significant after Bonferroni correction for multiple comparisons for p < 0.01. We did not find any gender differences for these indices.

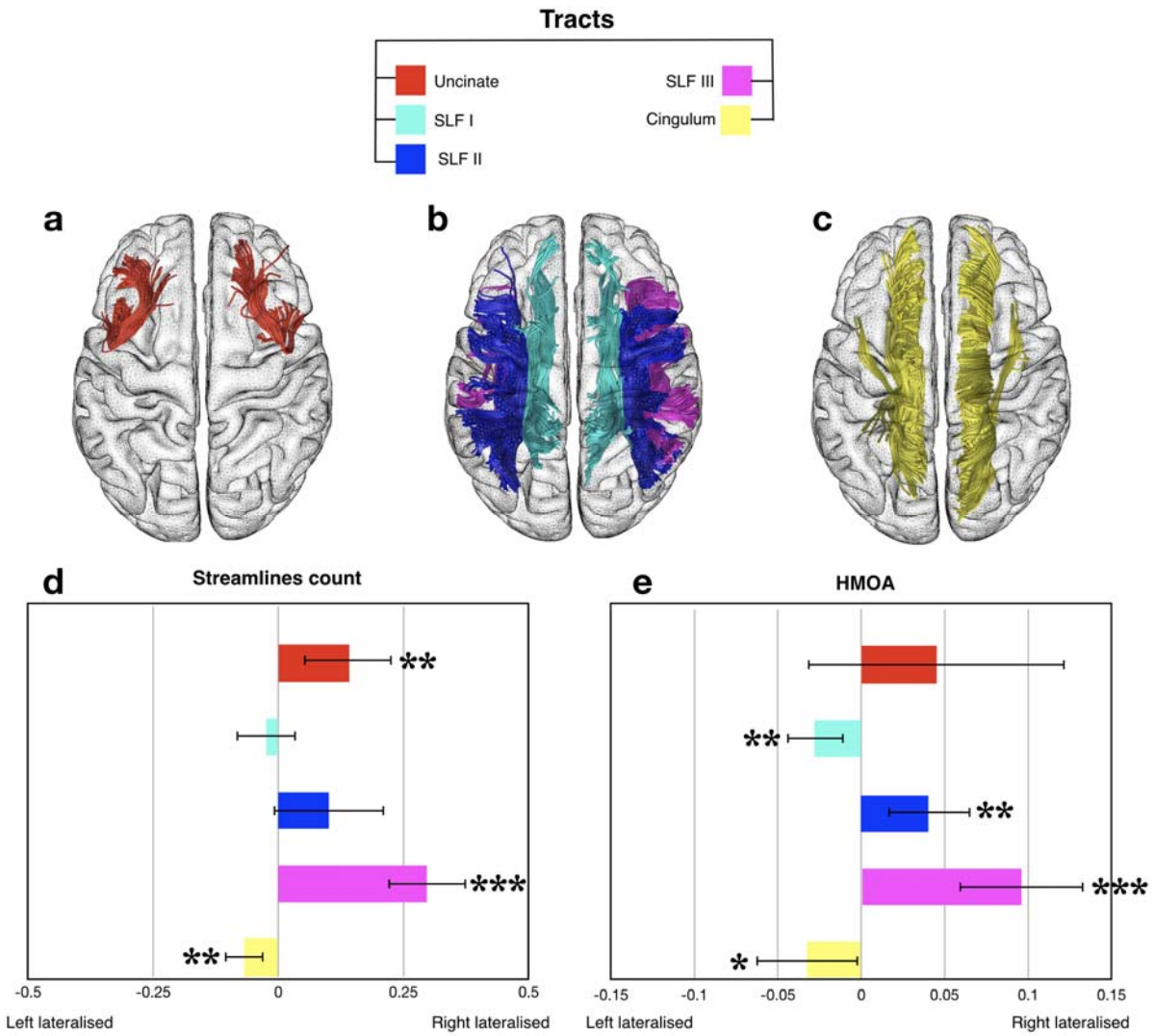

Figure 3: In vivo diffusion weighted imaging tractography dissection of a) uncinate fasciculus (red), b) superior longitudinal fasciculi, SLF I (cyan), II (blue), III (magenta) and c) cingulum fasciculus

(yellow). d-e) Overall effect across the 33 participants for tracts asymmetries in term of streamlines count (d) and HMOA (e). * $p < 0.05$, ** $p < 0.01$, *** $p < 0.001$

Behaviour-structure relationship.

Pearson correlation indicated a significant dimensional relationship between the asymmetry in emotional expression in the happy condition with the degree of lateralisation of the SLF I in term of streamlines count ($r = -0.456$; $p = 0.008$; Figure 4), significant after Bonferroni correction for multiple comparison ($p < 0.01$). No other index of asymmetry correlated significantly with the behavioural measures (all $p>.05$ after Bonferroni correction).

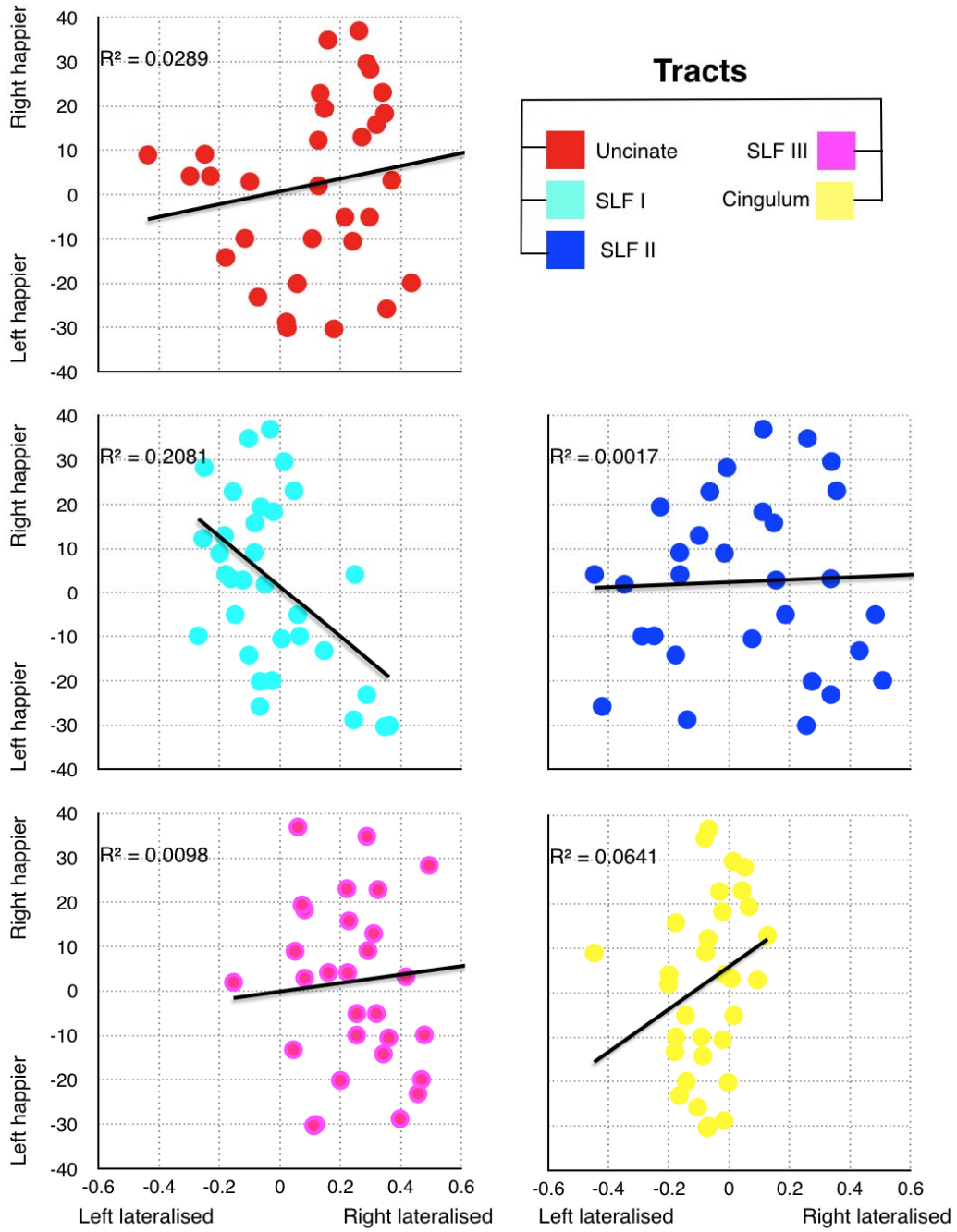

Figure 4: Dimensional relationship between measures of emotional expression asymmetries in the happy condition and tracts asymmetries in term of streamlines count. Charts of the Dimensional relationship between measures of emotional expression asymmetries in the sad condition and tracts asymmetries in term of streamlines and HMOA are available in supplementary material.

Discussion

In this study we explored a classically reported effect of asymmetry in facial emotional expression and its relationship with the degree of lateralisation of main white matter tracts. Three findings emerge from our work. First, the degree of asymmetry in emotional expression was not as prominent as reported in the literature, confirming the inter-subject variability in the hemispheric prevalence for emotion expression. Second, the anatomical investigation was consistent with and clarified previous reports on the asymmetry of the uncinate, the SLF I, II and III and the cingulum. Finally, we report for the first time that the greater the hemispheric lateralisation of SLF I, the more the expression of happiness in the contralateral half of the face.

The degree of asymmetry in emotional expression we report is not as prominent as reported in the literature on chimeric faces analyses. Compared to previous studies our analysis revealed a substantial variability among participants, who did not express emotion more intensely on one side of the face or the other at the group level. Some differences in our approach might explain this discrepancy. For instance, classical studies employing chimeric stimuli are based on a chosen subsample of a battery of already preselected emotional faces, which may have exaggerated the effect. Additionally, photographs were not emotional poses, but requested facial movements (Ekman 1980). Here, chimeric stimuli were derived from undirected emotional poses of all the participants without any exception and might be more ecological and representative of the global population, revealing a highly variable level of posed emotions asymmetry across participants. Secondly, in previous approaches the chimeric faces were scored independently whereas in the current design we purposely put chimeric faces into competition to estimate the level of asymmetry in the expression at the individual level. Hence, our current paradigm is more appropriate to estimate asymmetry in the expression of emotion at the single subject level and therefore draw its relationship with asymmetries in the brain anatomy. Furthermore, the pattern of hemi-face expressivity tended to be significantly reproducible among participants, as subjects who expressed emotion strongly in one side of the face, did so for both the happy and sad expressions.

Our results replicated preliminary evidence in the lateralisation of previously described white matters tracts, providing further evidence on the distribution of these pathways in the healthy population. In line with previous reports, the uncinate fasciculus was significantly right lateralised (Hau et al. 2017,Highley 2002), the cingulum displayed a trend to leftward asymmetry (Thiebaut de Schotten et al. 2011b), while the SLF showed a dorsal to ventral gradient of lateralisation. (Chechlacz 2015,Thiebaut de Schotten et al. 2011a)

The degree of asymmetrical expression of happiness was related to volume lateralisation of the SLF I. The happier participants appeared in the right relative to their left hemi-face, the stronger the

leftward SLF I asymmetry and *vice versa*. Although this tract has not been classically linked to the domain of emotions, it connects portions of the default-mode network, which is considered a functional subdivision of the limbic system. Abnormalities in SLF microstructure have previously been reported as the most common white matter alteration in populations affected by emotion and mood disorders (Jenkins et al. 2016). Taken together, these findings suggest a participation of the SLF I in the emotion domain, particularly in the expression of happiness.

Limitations

The degree of asymmetrical expression of sadness did not correlate with the volume lateralisation of the SLF I while the asymmetries in sadness and happiness expression were correlated. This may point at differential anatomical bases in regards to the valence of the perceived emotion. However, it may also reflect the fact that happy faces were easier to obtain from the participants as well as clearly more salient than the sad faces. Several reports indicate that happy faces are usually more distinctive from neutral faces than sad faces (smiling causes an expansion of the face), and have a perceptual advantage in detection and recognition (Becker et al. 2011, Hodsoll et al. 2011). Therefore, it is possible that the lack of correlation between the sad expression and the brain anatomy arose from a lack of power to detect such correlation due to the relatively lower intensity and coherence of expression across individuals of the sad expressions used.

Additionally, the expressed emotions were emotional poses rather than spontaneous. As this is a highly criticized issue (Ekman 1980), we would like to clarify that our participants were requested to express either happiness or sadness, without giving them indications on how to do so. We chose emotional poses in this study as there is support for the notion that voluntary control of facial movement is important for the intensity of spontaneous facial expressions (Berembaum and Rotter 1992), and because full-frontal face view photographs are crucial for the study of emotional expression.

Lastly, our research might have benefitted from a larger sample to draw additional conclusion, especially in regards to trends in the results, such as the relation of the cingulum's asymmetry and the lateralisation of emotion in participants. Future studies will allow uncovering further correlations if there are more to be found, especially in relation to the ventral and dorsal segments of the cingulum, which also connects the DMN interestingly.

Conclusion

The present work sought to explore the relationship between the hemispherical dominance in emotion processing and asymmetry of white matter tracts of the human brain. We revealed a large inter-subject variability in the asymmetrical expression of emotion, which was related to the lateralisation of white matter tracts, and brought novel speculation on the functional attributes of the SLF I. Future studies could expand the knowledge on the nature of the interaction between brain structural connectivity, emotions and the default-mode network, with keen attention to the implications for clinical populations affected by mood disorders.

Acknowledgments

We thank ERASMUS for supporting SI as well as Laurent Petit and Emmanuel Mellet for useful discussion. The research leading to these results received funding from the “Agence Nationale de la Recherche” [grants number ANR-09-RPDOC-004-01 and number ANR-13- JSV4-0001-01] and from the Fondation pour la Recherche Médicale (FRM). Additional financial support comes from the program “Investissements d’avenir” ANR-10-IAIHU-06.

References

Agosta, F., Scola, E., Canu, E., Marcone, A., Magnani, G., Sarro, L., ... & Cappa, S. F. (2012). White matter damage in frontotemporal lobar degeneration spectrum. Cerebral cortex, 22(12), 2705-2714.

Alexander, D. (2005). Multiple-Fiber Reconstruction Algorithms for Diffusion MRI. Annals of the New York Academy of Sciences, 1064(1), pp.113-133.

Anderson, A. (2005). Measurement of fiber orientation distributions using high angular resolution diffusion imaging. Magnetic Resonance in Medicine, 54(5), pp.1194-1206.

Andersson, J., Skare, S. and Ashburner, J. (2003). How to correct susceptibility distortions in spin-echo echo-planar images: application to diffusion tensor imaging. NeuroImage, 20(2), pp.870-888.

Babinski, J. (1914). Contribution of cerebral hemispheric organization in the study of mental troubles. Review Neurologique, 27, 845-848.

Basser, P.J., J. Mattiello, and D. LeBihan. "MR Diffusion Tensor Spectroscopy And Imaging". *Biophysical Journal* 66.1 (1994): 259-267.

Becker, D., Anderson, U., Mortensen, C., Neufeld, S. and Neel, R. (2011). The face in the crowd effect unconfounded: Happy faces, not angry faces, are more efficiently detected in single- and multiple-target visual search tasks. Journal of Experimental Psychology: General, 140(4), pp.637-659.

Berenbaum, H. and Rotter, A. (1992). The relationship between spontaneous facial expressions of emotion and voluntary control of facial muscles. Journal of Nonverbal Behavior, 16(3), pp.179-190.

Borod, J. C. (1993). Cerebral mechanisms underlying facial, prosodic, and lexical emotional expression: A review of neuropsychological studies and methodological issues. Neuropsychology, 7(4), 445-463

Borod, J. C., Haywood, C. S., & Koff, E. (1997). Neuropsychological aspects of facial asymmetry during emotional expression: A review of the normal adult literature. Neuropsychology Review, 7(1), 41-60.

Bradshaw, John L, and Lesley J Rogers. *The Evolution Of Lateral Asymmetries, Language, Tool Use, And Intellect*. San Diego: Academic Press, 1993. Print.

Broca, P. ”Remarques sur le siège de la faculté du langage articulé, suivies d’une observation d’aphémie (perte de la parole)”. *Bulletins de la Société d’anatomie (Paris), 2e serie*, (1861), vol.6 (pg.330-57)

Catani, Marco, Flavio Dell’Acqua, and Michel Thiebaut de Schotten. "A Revised Limbic System Model For Memory, Emotion And Behaviour". *Neuroscience & Biobehavioral Reviews* 37.8 (2013): 1724-1737.

Chechlacz, M., Gillebert, C., Vangkilde, S., Petersen, A. and Humphreys, G. (2015). Structural Variability within Frontoparietal Networks and Individual Differences in Attentional Functions: An Approach Using the Theory of Visual Attention. Journal of Neuroscience, 35(30), pp.10647-10658.

Craig, A.D. (Bud). "Forebrain Emotional Asymmetry: A Neuroanatomical Basis?". *Trends in Cognitive Sciences* 9.12 (2005): 566-571

Craig, M C et al. "Altered Connections On The Road To Psychopathy". *Molecular Psychiatry* 14.10 (2009): 946-953.

Dell'Acqua, F., Scifo, P., Rizzo, G., Catani, M., Simmons, A., Scotti, G. and Fazio, F. (2010). A modified damped Richardson–Lucy algorithm to reduce isotropic background effects in spherical deconvolution. NeuroImage, 49(2), pp.1446-1458.

Dell'Acqua, F., Simmons, A., Williams, S. and Catani, M. (2012). Can spherical deconvolution provide more information than fiber orientations? Hindrance modulated orientational anisotropy, a true-tract specific index to characterize white matter diffusion. Human Brain Mapping, 34(10), pp.2464-2483.

Demaree, H. A., Everhart, D. E., Youngstrom, E. A., & Harrison, D. W. (2005). Brain lateralization of emotional processing: historical roots and a future incorporating “dominance”. Behavioral and cognitive neuroscience reviews, 4(1), 3-20.

Ekman, P. (1980). Asymmetry in facial expression. Science, 209(4458), pp.833-834.

Falk, Dean. "Brain Lateralization In Primates And Its Evolution In Hominids". *American Journal of Physical Anthropology* 30.S8 (1987): 107-125.

Fernández-Carriba, S., Loeches, Á., Morcillo, A., & Hopkins, W. D. (2002). Asymmetry in facial expression of emotions by chimpanzees. *Neuropsychologia*, *40*(9), 1523-1533.

Hau, J., Sarubbo, S., Houde, J. C., Corsini, F., Girard, G., Deledalle, C., ... & Joliot, M. (2017). Revisiting the human uncinate fasciculus, its subcomponents and asymmetries with stem-based tractography and microdissection validation. Brain Structure and Function, 222(4), 1645-1662.

Hauser, M. "Right Hemisphere Dominance For The Production Of Facial Expression In Monkeys". *Science* 261.5120 (1993): 475-477.

Hellige, Joseph B. *Hemispheric Asymmetry*. 1st ed. Cambridge, Mass.: Harvard University Press, 2001. Print.

Highley, J. R. "Asymmetry Of The Uncinate Fasciculus: A Post-Mortem Study Of Normal Subjects And Patients With Schizophrenia". *Cerebral Cortex* 12.11 (2002): 1218-1224.

Hodsoll, S., Viding, E. and Lavie, N. (2011). Attentional capture by irrelevant emotional distractor faces. Emotion, 11(2), pp.346-353.

Jenkins, L., Barba, A., Campbell, M., Lamar, M., Shankman, S., Leow, A., Ajilore, O. and Langenecker, S. (2016). Shared white matter alterations across emotional disorders: A voxel-based meta-analysis of fractional anisotropy. NeuroImage: Clinical, 12, pp.1022-1034.

Jewell, G. and McCourt, M. (2000). Pseudoneglect: a review and meta-analysis of performance factors in line bisection tasks. Neuropsychologia, 38(1), pp.93-110.

Levy, Jerre et al. "Asymmetry Of Perception In Free Viewing Of Chimeric Faces". *Brain and Cognition* 2.4 (1983): 404-419.

MacLean, P.D., 1952. Some psychiatric implications of physiological studies on frontotemporal portion of limbic system (visceral brain). Electroencephalogr. Clin. Neurophysiol. 4, 407–418.

Matsuo, K., Mizuno, T., Yamada, K., Akazawa, K., Kasai, T., Kondo, M., ... & Nakagawa, M. (2008). Cerebral white matter damage in frontotemporal dementia assessed by diffusion tensor tractography. Neuroradiology, 50(7), 605-611.

Mesulam, M., 2000. Behavioural neuroanatomy: large-scale networks, association cortex, frontal syndromes, the limbic system, and the hemispheric specializations. In: Mesulam, M. (Ed.), Principles of Behavioural and Cognitive Neurology. , pp. 1–120.

Mills, C. K. (1912). The cerebral mechanisms of emotional expression. Transactions of the College of Physicians of Philadelphia, 34, 381-390.

Morris, R.D., and W.D. Hopkins. "Perception Of Human Chimeric Faces By Chimpanzees: Evidence For A Right Hemisphere Advantage". *Brain and Cognition* 21.1 (1993): 111-122.

Parlatini, V., Radua, J., Dell'Acqua, F., Leslie, A., Simmons, A., Murphy, D., Catani, M. and Thiebaut de Schotten, M. (2017). Functional segregation and integration within fronto-parietal networks. *NeuroImage*, 146, pp.367-375.

Phelps, Elizabeth A. "Emotion And Cognition: Insights From Studies Of The Human Amygdala". *Annual Review of Psychology* 57.1 (2006): 27-53.

Phelps, Elizabeth A., and Joseph E. LeDoux. "Contributions Of The Amygdala To Emotion Processing: From Animal Models To Human Behavior". *Neuron* 48.2 (2005): 175-187.

Piguet, O., Hornberger, M., Mioshi, E., & Hodges, J. R. (2011). Behavioural-variant frontotemporal dementia: diagnosis, clinical staging, and management. The Lancet Neurology, 10(2), 162-172.

Raichle, M. and Snyder, A. (2007). A default mode of brain function: A brief history of an evolving idea. NeuroImage, 37(4), pp.1083-1090.

Raichle, M., MacLeod, A., Snyder, A., Powers, W., Gusnard, D. and Shulman, G. (2001). A default mode of brain function. Proceedings of the National Academy of Sciences, 98(2), pp.676-682.

Rinn, W. B. The neuropsychology of facial expression: A review of the neurological and psychological mechanisms for producing facial expression. Psychol. Bull. 95:52–77; 1984

Sackeim, H., R. Gur, and M. Saucy. "Emotions Are Expressed More Intensely On The Left Side Of The Face". *Science* 202.4366 (1978): 434-436.

Schmahmann, J., Pandya, D., Wang, R., Dai, G., D'Arceuil, H., de Crespigny, A. and Wedeen, V. (2007). Association fibre pathways of the brain: parallel observations from diffusion spectrum imaging and autoradiography. Brain, 130(3), pp.630-653.

Seghier, Mohamed L. "Laterality Index In Functional MRI: Methodological Issues". *Magnetic Resonance Imaging* 26.5 (2008): 594-601.

Silberman, Edward K., and Herbert Weingartner. "Hemispheric Lateralization Of Functions Related To Emotion". *Brain and Cognition* 5.3 (1986): 322-353.

Smith, S., Jenkinson, M., Woolrich, M., Beckmann, C., Behrens, T., Johansen-Berg, H., Bannister, P., De Luca, M., Drobnjak, I., Flitney, D., Niazy, R., Saunders, J., Vickers, J., Zhang, Y., De Stefano, N., Brady, J. and Matthews, P. (2004). Advances in functional and structural MR image analysis and implementation as FSL. NeuroImage, 23, pp.S208-S219.

Sperry, R. W. (1974) Lateral specialization in the surgically separated hemispheres. In: F. Schmitt and F. Worden (Eds.), Neurosciences Third Study Program, Ch. I, Vol. 3, pp. 5- 19. Cambridge: MIT Press.

Thiebaut de Schotten, M., Dell'Acqua, F., Forkel, S., Simmons, A., Vergani, F., Murphy, D. and Catani, M. (2011). A lateralized brain network for visuospatial attention. Nature Neuroscience, 14(10), pp.1245-1246.

Thiebaut de Schotten, M., ffytche, D., Bizzi, A., Dell'Acqua, F., Allin, M., Walshe, M., Murray, R., Williams, S., Murphy, D. and Catani, M. (2011). Atlasing location, asymmetry and inter-subject variability of white matter tracts in the human brain with MR diffusion tractography. NeuroImage, 54(1), pp.49-59.

Tournier, J., Calamante, F., Gadian, D. and Connelly, A. (2004). Direct estimation of the fiber orientation density function from diffusion-weighted MRI data using spherical deconvolution. NeuroImage, 23(3), pp.1176-1185.

Whitwell, J. L., Avula, R., Senjem, M. L., Kantarci, K., Weigand, S. D., Samikoglu, A., ... & Petersen, R. C. (2010). Gray and white matter water diffusion in the syndromic variants of frontotemporal dementia. Neurology, 74(16), 1279-1287.

Yakovlev, P.J., 1948. Motility, behavior and the brain; stereodynamic organization and neural coordinates of behavior. J. Nerv. Ment. Dis. 107, 313–335.