Cerebellar grey matter volume in adolescence is associated with prodromal psychotic symptoms and norm-violating behavior

Torgeir Moberget, PhD[1*], Dag Alnæs, PhD[1], Tobias Kaufmann, PhD[1], Nhat Trung Doan, PhD[1], Aldo Córdova-Palomera, PhD[1], Linn Bonaventure Norbom, MSc[1,2], Jarek Rokicki, PhD[1,2], Dennis van der Meer[1], PhD[1], Ole A. Andreassen, MD, PhD[1], & Lars T. Westlye, PhD[1,2].

[1] NORMENT, KG Jebsen Centre for Psychosis Research, Division of Mental Health and Addiction, Oslo University Hospital & Institute of Clinical Medicine, University of Oslo, Norway
[2] Department of Psychology, University of Oslo, Oslo, Norway.

*** Corresponding author:** Torgeir Moberget, Ph.D., Email: torgeir.moberget@gmail.com Phone: 0047-23026364, Fax: 0047-23027333, Postal address: Oslo University Hospital, PO Box 4956 Nydalen, 0424 OSLO, Norway

Disclosures: The authors declare no conflict of interest

Acknowledgements:
This study has received funding from the European Commission's 7th Framework Programme (#602450, IMAGEMEND), Research Council of Norway (213837, 223273, 229129, 204966/F20, 249795, and 251134), the South-Eastern Norway Regional Health Authority (2013-123, 2014-097, 2015-073, 2016-083 and 2017112) and KG Jebsen Foundation. The Philadelphia Neurodevelopment Cohort sample is a publicly available data set. Support for the collection of the data sets was provided by grant RC2MH089983 awarded to Raquel Gur, MD, PhD, and RC2MH089924 awarded to Hakon Hakonarson, MD, PhD. All participants were recruited through the Center for Applied Genomics at The Children's Hospital in Philadelphia. No other disclosures are reported.

Key points:

Questions: Is cerebellar morphology associated with sub-clinical psychiatric symptoms in adolescence? Do such associations show symptom domain specificity or do they rather constitute a marker of general psychopathology?

Findings: Machine learning utilizing cerebellar morphology features significantly predicted the severity of prodromal psychotic symptoms, norm-violating behavior and anxiety, but not attention deficits, depressive, manic or obsessive-compulsive sub-clinical symptoms. Associations with prodromal psychotic symptoms were stronger for the cerebellum than for cerebral subcortical and cerebro-cortical regions, and remained significant when adjusting for several potentially confounding factors.

Meaning: The cerebellum appears to play a key role in the development of severe mental illness.

Abstract:

Importance: Accumulating evidence supports cerebellar involvement in mental disorders such as schizophrenia, bipolar disorder, depression, anxiety disorders and attention-deficit hyperactivity disorder. However, little is known about cerebellar involvement in the developmental stages of these disorders. In particular, whether cerebellar morphology is associated with early expression of specific symptom domains remains unclear.

Objective: To determine the robustness and specificity of associations between cerebellar morphology, general cognitive function, general psychopathology and sub-clinical psychiatric symptom domains in adolescence.

Design, setting and participants: Assessment of parametric structure-function associations between MR-based brain morphometric features and data-driven cognitive and clinical phenotypes in the Philadelphia Neurodevelopmental Cohort (N=1401, age-range: 8 - 23).

Main outcomes and measures: Robust prediction of cognitive and clinical symptom domain scores from cerebellar, subcortical and cerebro-cortical brain features using machine learning with 10-fold internal cross-validation and permutation-based statistical inference.

Results: Cerebellar morphology predicted both general cognitive function and general psychopathology (mean Pearson correlation coefficients between predicted and observed values: $r = .20$ and $r = .13$, respectively; corrected p-values $< .0009$). Analyses of specific sub-clinical symptom domains revealed significant associations with rates of norm-violating behavior ($r = .17$; $p < .0009$), prodromal psychotic symptoms ($r = .12$; $p < .0009$) and anxiety symptoms ($r = .09$; $p = .0117$). In contrast, we observed no significant associations between cerebellar features and the severity of attention deficits, depressive, manic or obsessive-compulsive symptoms (all rs =< .03, all ps => .1). Associations with norm-violating behavior and prodromal psychotic symptoms were stronger for the cerebellum than for subcortical and cerebro-cortical regions, while anxiety and general cognitive function were related to more global brain morphology patterns. The association between cerebellar volume and prodromal psychotic symptoms, and to a lesser extent norm violating behavior, remained significant when adjusting for potentially confounding factors such as general cognitive function, general psychopathology, parental education level and use of psychoactive substances.

Conclusions and relevance: The robust associations with sub-clinical psychiatric symptoms in the age range when these typically emerge highlight the cerebellum as a key brain structure in the development of severe mental disorders.

Introduction

A growing body of research reports cerebellar involvement across a wide range of mental disorders, including schizophrenia[1,2], bipolar disorder[3], depression[4-7], anxiety disorders[8], attention-deficit hyperactivity disorder[9,10] and autism[11]. However, while the majority of these conditions are conceptualized as neurodevelopmental disorders[12,13], most studies investigating the role of the cerebellum in mental health research have targeted adult populations[14-16]. Hence, it is largely unknown whether cerebellar changes can be detected already in adolescence, when initial symptoms typically first present[13,17,18], or only emerge later in the disease process. Moreover, whether cerebellar alterations in adolescence are indicative of general psychopathology[19], or are associated with specific symptom domains[9], remains unclear. Finally, it is unknown how cerebellar associations with psychiatric symptoms in adolescence compare against such associations in other brain regions. Answering these questions will be crucial for determining the relative importance of the cerebellum during this critical period for the development of mental disorders.

Here, we used machine learning with 10-fold internal cross-validation to test whether cerebellar morphometric features could predict sub-clinical psychiatric symptoms in a large and well-characterized developmental community sample centered on adolescence[20,21]. Consistent with NIMHs Research Domain Criteria framework[22], we followed a diagnostically agnostic and dimensional approach[23,24], extracting clusters of correlated symptoms from a comprehensive set of clinical assessment data using blind source separation methods[25]. A similar data-driven and anatomically agnostic approach was used to decompose cerebellar grey matter maps into spatially independent components, before testing for structure-function associations using multivariate machine learning. To confirm convergence across methodological approaches, we also tested for structure-function associations at the resolution levels of cerebellar lobules and voxels. We further evaluated the specificity of any cerebellar effects by comparing these to effects across brain-wide regions-of-interest (ROIs), and controlled for potentially confounding variables such as general level of cognitive function[26,27], general psychopathology[19], parental education level[28] and use of psychoactive substances[29].

Based on the existing literature on adults, we hypothesized that cerebellar morphology during adolescence would be associated with both cognitive function[26,30,31] and general psychopathology[19], but remained agnostic as to whether such associations would show specificity across different psychiatric symptom domains.

Methods

Participants

The main structure-function analyses were based on data from 1401 participants (52.8% female, mean age: 15.12 years, age range: 8.2 to 23.2) included in the publicly available Philadelphia Neurodevelopmental Cohort (PNC)[20,21](see Supplementary Methods for inclusion criteria and demographic information). The institutional review boards of the University of Pennsylvania and the Children's Hospital of Philadelphia approved all study procedures, and written informed consent was obtained from all participants.

Collection and processing of cognitive and clinical measures

As reported previously[25], we included performance scores from the full PNC sample (n=6,487) on 12 computerized cognitive tests[21] and 129 questionnaire items assessing symptoms of anxiety, mood, behavioral, eating and psychosis spectrum disorders, with collateral informants for individuals below 18 years of age[21]. We derived general measures of cognitive performance (gF) and psychopathology (pF) by extracting the first factor scores from principal component analyses (PCA) of all cognitive and clinical scores, respectively. Next, in order to examine specific symptom domains, all clinical item scores were submitted to independent component analysis (ICA) using ICASSO[32], decomposing them into seven independent components. Effects of gender and age on all cognitive/clinical measures were tested using generalized additive models (GAMs) as implemented in the r-package "mgcv"[33], and a set of adjusted cognitive/clinical scores were computed by regressing out main effects of age and sex (see Supplementary Methods).

Collection and processing of MRI data:

As previously described[20,34,35], all data were acquired on the same 3 Tesla scanner using the same MRI sequence (See Supplementary Methods). All images were first processed using FreeSurfer version v5.3 (http://surfer.nmr.mgh.harvard.edu), yielding estimates of total intracranial volume (eTIV)[36], volumes of eight subcortical structures[37] and mean cortical thickness of 34 cortical regions-of-interest (ROIs) per hemisphere[38]. Next, the bias-corrected images from the FreeSurfer pipeline were subjected to cerebellum-optimized voxel-based morphometry (VBM) using the SUIT-toolbox (v3.2[39,40]), running on MATLAB 2014a. In brief, SUIT isolates the cerebellum and brainstem, segments images into grey and white matter maps and normalizes these maps to a cerebellar template using Dartel[41], ensuring superior cerebellar alignment compared with whole-brain procedures[40].

Normalized cerebellar grey matter maps were modulated by the Jacobian of the transformation matrix to preserve absolute grey matter volume, and the volumes of 28 cerebellar lobules were extracted using the SUIT probabilistic atlas. Next, maps were smoothed using a 4 mm FWHM Gaussian kernel before being subjected to ICA or voxel-wise general linear models. Finally, a mask for these analyses was constructed by thresholding the mean unmodulated cerebellar grey matter map at .01 and multiplying it with the SUIT grey matter template (also thresholded at .01).

Data-driven parcellation of cerebellar grey matter

Since cerebellar parcellations based on gross anatomical features (e.g., lobules) only partially overlap with functional maps of the cerebellum[42-50], we used a data-driven approach in our primary analyses. Specifically, we subjected the modulated cerebellar grey matter maps to ICA using FSL MELODIC[51], testing model orders from 5 to 20.

In order to characterize the resulting cerebellar VBM-components, we used NeuroSynth[52] to map the full-brain functional connectivity of each components peak voxel, and decoded these full-brain connectivity maps in terms of their similarity to (i.e., spatial correlation with) meta-analytic maps generated for the 2911 terms in the NeuroSynth[52] database, reporting the top five functional terms (see Supplementary Methods).

Analysis of brain-behavior associations

Before inclusion in statistical models, all volumetric features were adjusted for effects of age, sex and eTIV, using GAMs to sensitively model and adjust for potentially non-linear effects of age[53-55] and eTIV[56,57] (see Supplementary Methods).

In our primary analyses, we tested whether subject weights on cerebellar independent components could predict cognitive and clinical scores, by using shrinkage linear regression[58] (implemented in the R-package 'care') with 10-fold internal cross-validation (i.e., based on iteratively using 90% of the sample to predict the remaining 10%), repeated 10,000 times on randomly partitioned data. Model performance was evaluated by computing the Pearson correlation coefficient between predicted and observed cognitive/clinical scores (taking the mean across iterations as our point estimate). Statistical significance was determined by comparing these point estimates to empirical null distributions of correlation coefficients under the null hypothesis (computed by running the models 10,000 times on randomly permuted clinical/cognitive scores). Results were considered significant at $p < .05$ (one-tailed), Bonferroni-adjusted for the 9 tested associations. In order to determine the relative importance of the anatomical

features included in each prediction model, we computed correlation-adjusted marginal co-relation (CAR) scores[59] for each iteration, and used the mean CAR scores as measures of relative feature importance.

To complement these multivariate prediction models, we performed a set of univariate analyses, correlating the (age- and sex-adjusted) subject weights on each cognitive/clinical component with the (eTIV- age- and sex-adjusted) anatomical subject weights (see Supplementary Methods).

In order to facilitate comparison with previously published research, we also report results from prediction models and correlation analyses using 28 cerebellar lobules as features and general linear models performed at the voxel level. The voxel-wise analyses tested for effects of cognitive/clinical scores while controlling for effects of sex, age, and eTIV using FSLs randomise[60] with 10,000 permutations per contrast.

Next, to allow for a direct comparison of cerebellar and cerebral structure-function associations, all prediction models were also performed on volumetric estimates of eight bilateral subcortical structures, and estimates of cortical thickness from 34 bilateral ROI based the Desikan-Killany atlas in FreeSurfer. We chose thickness as our cortical feature of interest, due to its generally stronger and more consistent associations with psychopathology than surface area[61,62]. All anatomical indices were adjusted for effects of age and sex (and eTIV for volumetric indices), as described above. Prediction models were also fitted using z-normalized versions of all morphometric features, in order to directly compare the relative feature importance of all anatomical measures.

Finally, on subjects with available information, we ran a set of univariate control analyses examining potentially confounding variables, such as general cognitive function, general psychopathology, parental education and use of psychoactive substances (see Supplementary Methods).

Results

Cognitive function and clinical symptoms

Results from the PCA and ICA decompositions of clinical item scores are shown in Figure 1a. As reported previously[25], the ICA yielded seven components, primarily reflecting symptoms of attention deficit hyperactivity disorder (IC01 ADHD), various anxiety disorders (IC02 Anxiety), norm violating behavior/conduct problems (IC03 Conduct), prodromal psychotic symptoms (IC04 Psychosis), depression (IC05 Depression), mania (IC06 Mania) and obsessive-compulsive disorder (IC07 OCD).

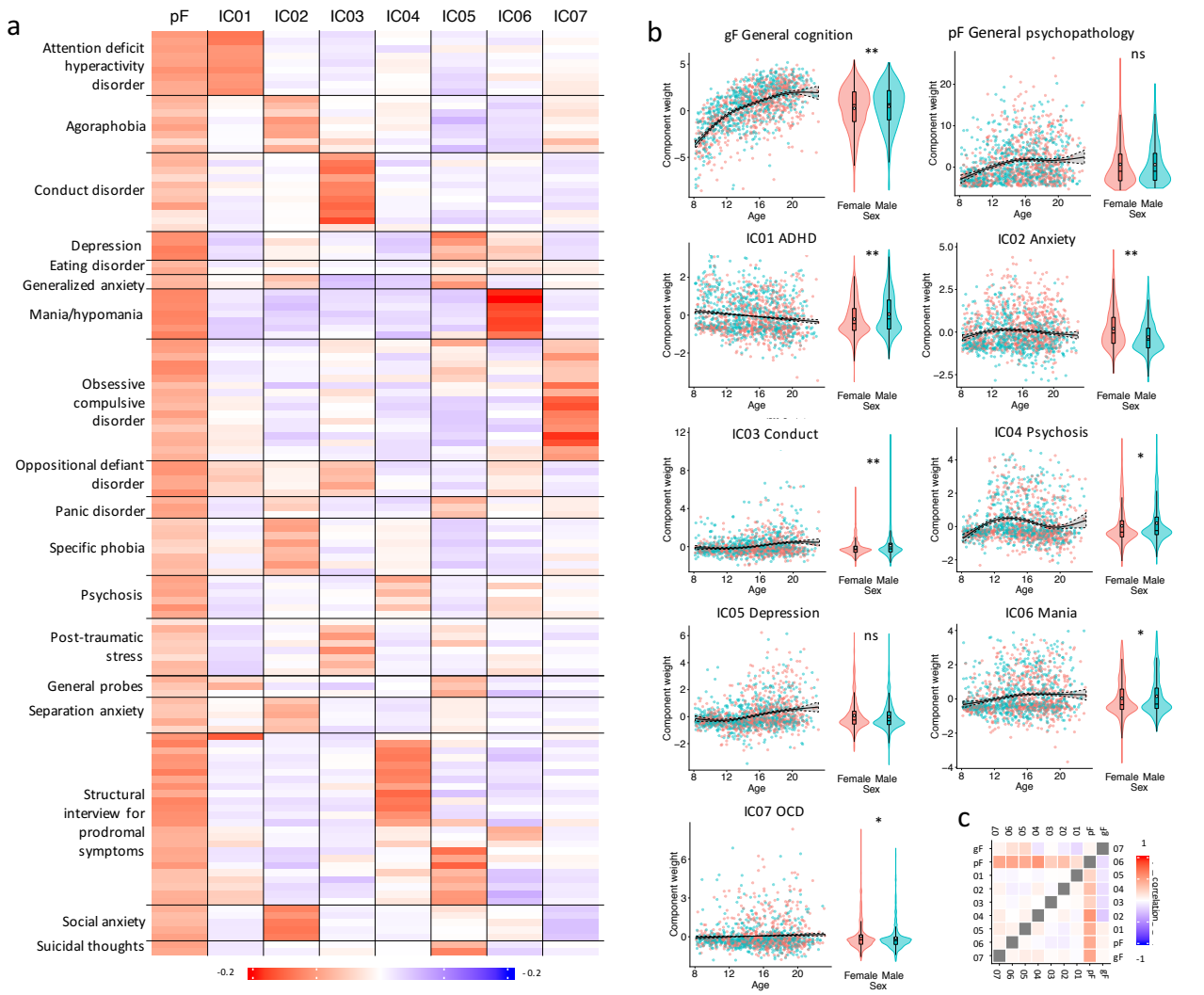

Figure 1: a: Loadings of 129 clinical items from 18 questionnaires on the general psychopathology factor (pF) and the seven clinical independent components (IC01-IC07). Clinical conditions targeted by each questionnaire are listed on the y-axis, while Supplementary Table 2 lists all 129 individual items; **b:** Effects of age and sex on cognitive/clinical scores (asterisks denote significant sex differences; * < .05, *** <.001); **c:** correlations between all cognitive/clinical scores before (upper triangle) and after (lower triangle) correcting for effects of age and sex.

Effects of age and sex on all cognitive and clinical summary scores are displayed in Figure 1b and Supplementary Results. In brief, general cognitive function (gF) showed the expected strong positive association with age, with slightly higher mean scores in males than in females. Mean levels of general psychopathology also increased over the sampled age span, but did not differ between males and females. All clinical scores varied as a function of age. Specifically, ADHD scores decreased with increasing age, whereas various increasing trends were observed for all other clinical components. Largely in line with population-based estimates[13,63,64], males scored higher on components reflecting ADHD, conduct problems, psychosis and mania, while females had higher scores on components reflecting various anxiety disorders and OCD. No significant sex differences were observed for the component reflecting depression.

MRI-based morphometry

Data-driven decomposition of cerebellar grey matter maps using a model order of 10 yielded a set of bilateral components (Figure 2a), which tended to split into unilateral components at higher model orders (see Supplementary Figures 1-3 for results using model orders of 5, 15 and 20). We consequently chose this decomposition for all further analyses. Of note, the Neurosynth analyses revealed that voxels at the peak coordinates of each cerebellar component (marked with an asterisk in Fig.2a) showed distinct patterns of whole-brain functional connectivity (Fig 3b-c), which were associated with different functional terms in the neuroimaging literature (Fig 2d). In brief, the connectivity maps of four components (IC02, IC05, IC06 and IC09) were most closely associated with motor control, while the remaining connectivity networks showed stronger associations with various cognitive functions. See Supplementary Figures and Tables 4-7 for estimated effects of age, sex and eTIV for all cerebellar and cerebral anatomical features.

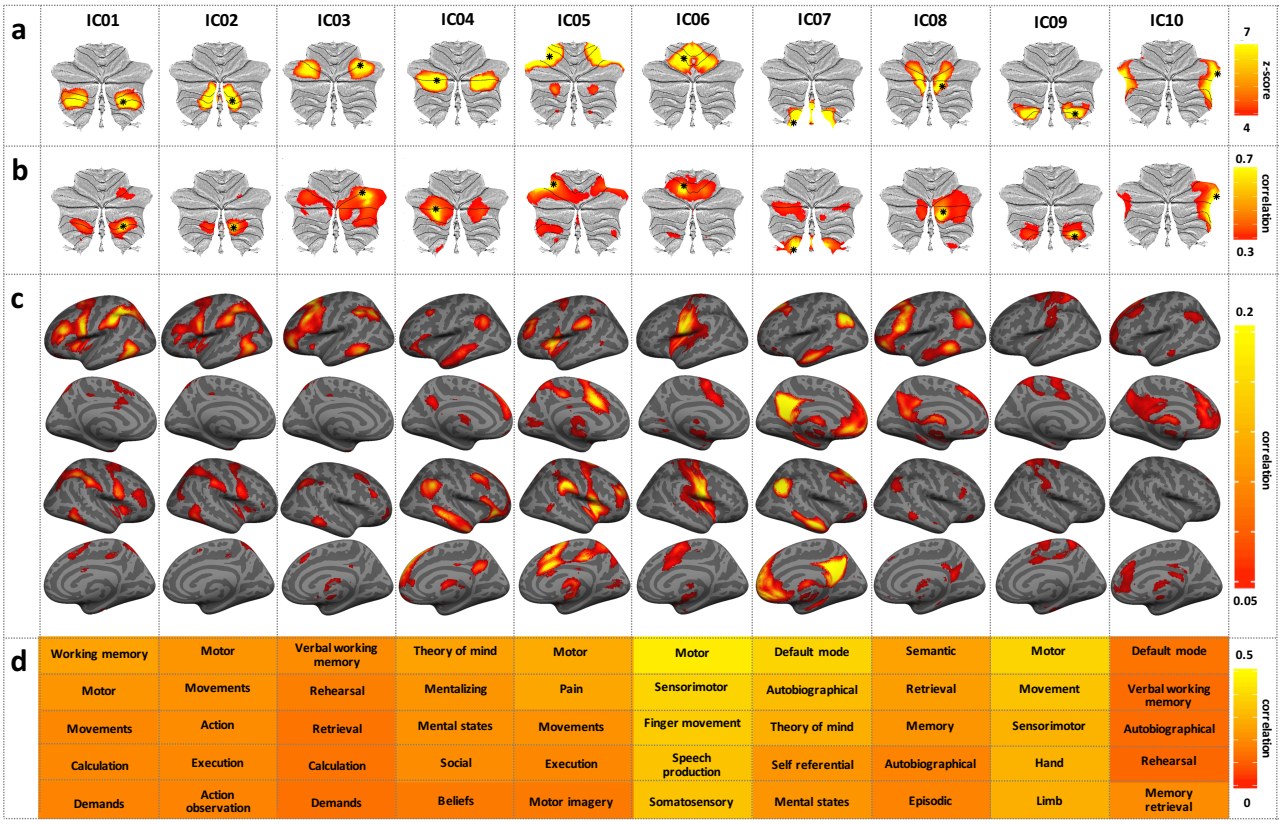

Figure 2: a: The ten independent components resulting from data-driven decomposition of cerebellar grey matter maps projected onto flat-maps of the cerebellar cortex[92]. Asterisks denote the peak voxel for each component. **b-c:** Cerebellar and cerebro-cortical functional connectivity maps (determined using NeuroSynth[44,93]) for each of the peak voxels shown in **a**. **d:** Top 5 functional terms associated with each of the full-brain cerebellar connectivity maps shown in **b** and **c**.

Structure-function associations

Results from the main structure-function analyses are presented in Figure 3.

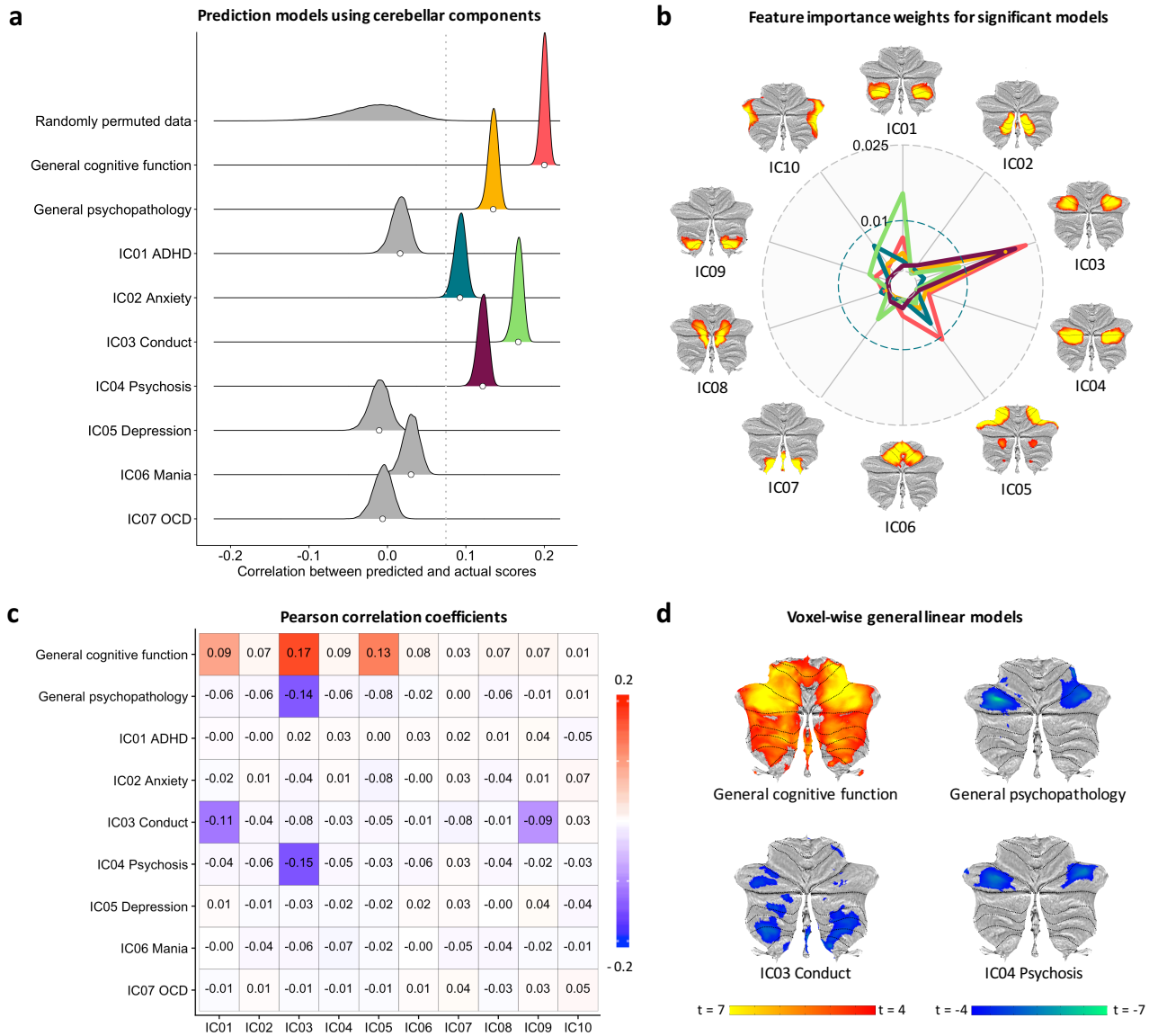

Figure 3: a: Distributions of correlations between predicted and actual cognitive/clinical scores across 10,000 iterations of the 10-fold cross-validated model. White dots denote the mean, used as point estimates for comparison with each model's empirical null distribution (computed by fitting the predictive models to randomly permuted cognitive/clinical data, across 10,000 iterations). For illustrative purposes we here plot the empirical null-distribution summed across all prediction models. The dotted grey line represents the one-tailed .05 threshold, Bonferroni-adjusted for 9 tests. **b:** Feature importance weights (CAR-scores) for the five significant models (color code as in a); **c:** Univariate correlations between cerebellar ICs and cognitive/clinical scores. Colored tiles mark significant associations (corrected for multiple comparisons across the matrix); **d:** T-statistics from the voxel-wise general linear models, thresholded at $p < .05$, two-tailed (based on 10.000 permutations).

As hypothesized, cerebellar morphological features predicted both general cognitive function (mean correlation between observed and predicted scores: $r = .20$; $p < .0009$) and general psychopathology ($r = .12$, $p < .0009$). When using cerebellar features to predict

clinical components, we observed significant results for IC03 Conduct (r = .16; p < .0009), IC04 Psychosis (r = .12; p < .0009) and IC02 Anxiety (r = .09; p = 0.0117), but not for IC01 ADHD (r = .01; ns), IC05 Depression (r = -.02; ns), IC06 Mania (r = .03; ns) or IC07 OCD (r = -.01; ns). The relative feature importance (i.e., CAR-score) for each cerebellar component used in the five significant prediction models is presented in Figure 3b. Briefly, IC03 contributed most strongly to the prediction of cognitive function (gF), general psychopathology (pF) and prodromal psychotic symptoms whereas IC01 was the most important feature when predicting conduct problems.

This pattern was confirmed in the univariate analyses (Figure 3c). Specifically, general cognitive function (gF) was positively correlated with subject weights on IC01, IC03, and IC05, while overall psychopathology (pF) was negatively correlated with subject weights on IC03. Of the seven clinical ICs, IC03 Conduct was negatively correlated with cerebellar IC01 and IC09, while IC04 Psychosis was negatively correlated with cerebellar IC03. No other associations survived correction for multiple comparisons. Prediction models and univariate analyses using cerebellar lobular volumes yielded very similar results (Supplementary Figure 8).

Results from the voxel-based analyses are given in Figure 3d and Supplementary Table 8. In line with the main findings, we observed anatomically widespread positive associations with general cognitive function, while general psychopathology scores were associated with a more restricted pattern of cerebellar grey matter volume reduction, encompassing bilateral lobule VI and Crus I. Prodromal psychotic symptoms were associated with a largely overlapping pattern, while conduct problems were associated with a partially overlapping region in left Crus I, as well as additional clusters in more inferior and midline regions. Anxiety was negatively associated with a small cluster in left lobule VI (11 voxels, not shown). No other clinical component yielded significant voxel-wise results.

Prediction models using cerebral anatomical features

Figures 4 a-c present the performance of prediction models using volumetric estimates of 8 bilateral subcortical structures, cortical thickness estimates from 34 bilateral cerebral ROIs and scaled versions of all anatomical measures, respectively (see Supplementary Figures 9-10 for CAR-scores). In brief, the subcortical model performed worse than the cerebellar model, with a notable exception for IC07 OCD (r = .08; p = .0423), where pallidum volume emerged as the most predictive feature. The cortical thickness model performed better than the cerebellar model for general cognitive function (r = .26; p <

.0009) and yielded comparable results for IC02 Anxiety (r = .09; p = .0225), but performed worse than the cerebellar model in predicting general psychopathology, IC03 Conduct and IC04 Psychosis (all *r*s < .0.08; all *p*s => .072). Models using all anatomical features significantly predicted general cognitive function (gF: *r* = .29; *p* < .0009), general psychopathology (pF: *r* = .13; *p* < .0009), IC02 Anxiety (*r* =.10; *p* = .0153), IC03 Conduct (*r* =.14; *p* < .0009) and IC04 Psychosis (*r* =.10; *p* = .0162).

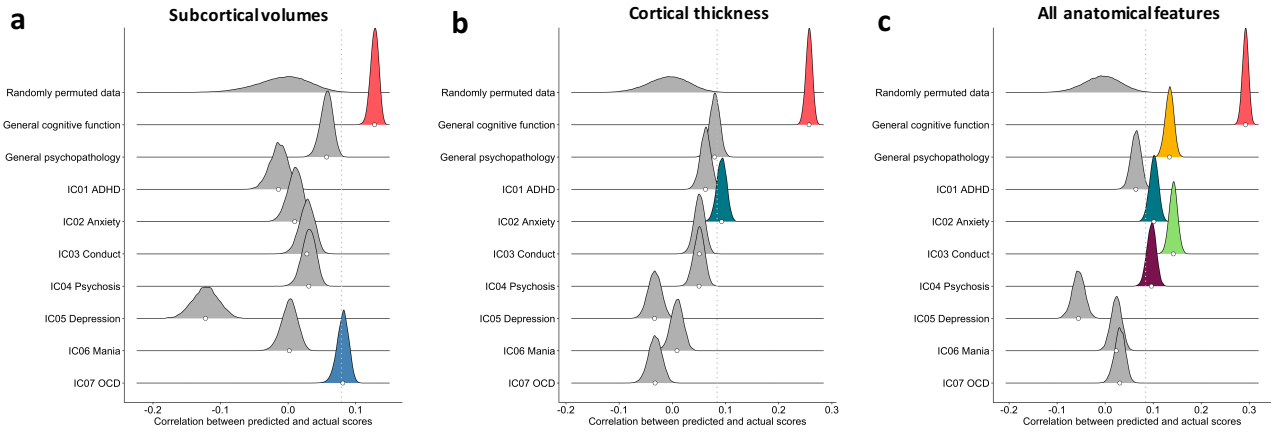

Figure 4: a: Predictive performance of machine learning models using **a:** Subcortical volumes; **b:** Mean thickness for 34 bilateral cerebrocortical ROIs; and **c:** Z-normalized versions of all anatomical features.

Figure 5 gives the feature importance weights for significant models using all anatomical features. Of note, cerebellar features emerged as the most important in several of these models (Fig 5 b-f), especially general psychopathology (pF), IC03 Conduct and IC04 Psychosis.

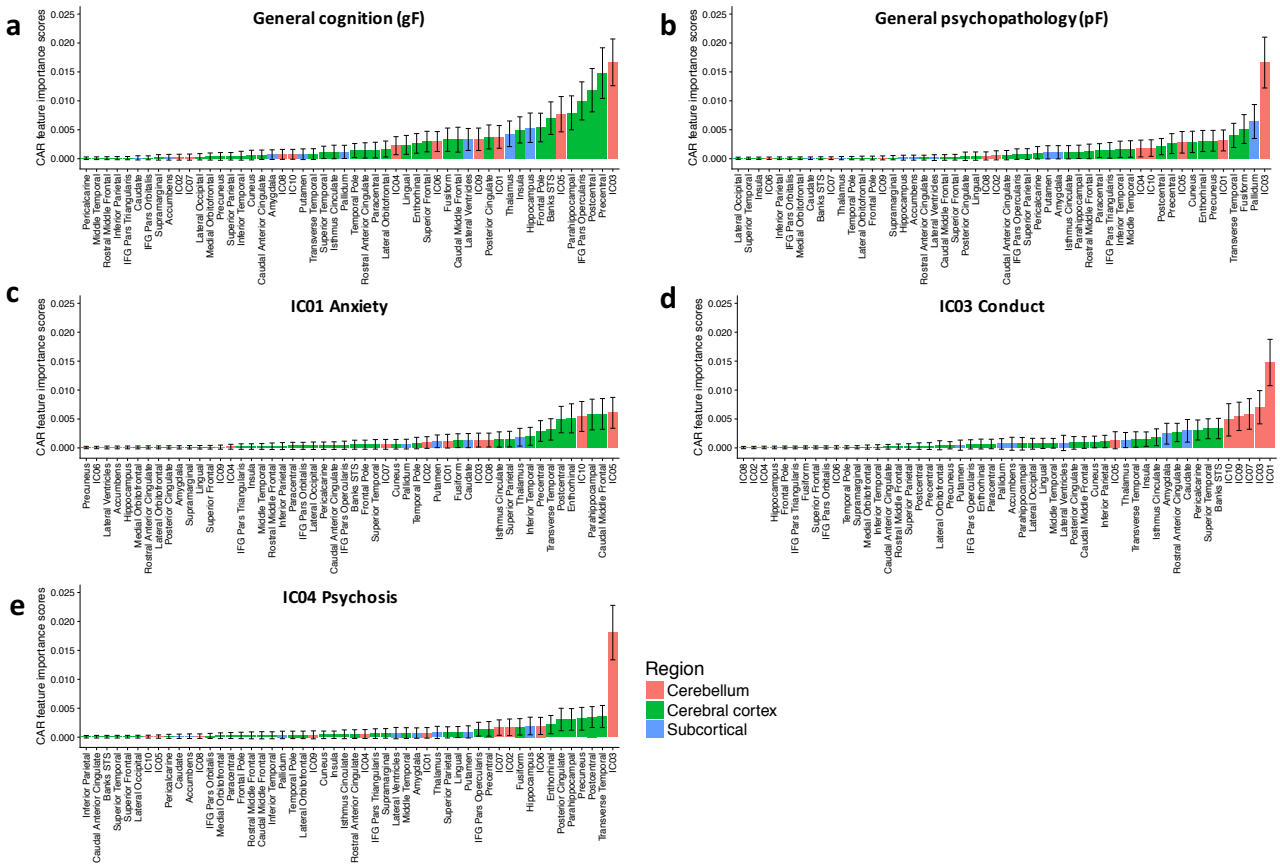

Figure 5: Feature importance weights (CAR-scores) for the five significant prediction models using all anatomical features. CAR-scores were computed for each of 10,000 iterations of the model on randomly 10-fold partitioned data, yielding 100,000 estimates for each model. Colors indicate the location of each feature, while error bars denote 2 standard deviations from the mean of these CAR-score distributions.

Control analyses

See Supplementary Results for details. In brief, the negative correlation between cerebellar IC03 and prodromal psychotic symptoms remained significant when controlling for general cognitive function, general psychopathology, parental education level, as well as in the subset of participants with no evidence of substance abuse (all corrected *p*-values < .05). The negative correlation between cerebellar IC01 and conduct problems was no longer significant when controlling for parental education level or substance abuse.

Discussion

The current machine learning approach utilizing 10-fold internal cross-validation in a large developmental MRI sample yielded three main findings. First cerebellar morphological features could significantly predict both general cognitive function and general psychopathology in adolescence. Second, structure-symptom associations showed diagnostic specificity, in that significant results were observed for sub-clinical symptoms of psychosis and rates of norm violating behavior (i.e., conduct problems) and to a lesser

extent anxiety, whereas symptoms of ADHD, depression, mania and OCD were unrelated to cerebellar morphology. We also observed a pattern of cerebellar anatomical specificity, with volume reductions in bilateral lobules VI/Crus I most strongly related to psychosis symptoms and volume reductions in more inferior cerebellar regions (lobules VIIb and VIII) most highly correlated with norm-violating behavior. Third, associations with prodromal psychotic symptoms and norm-violating behavior were stronger for the cerebellum than for subcortical volumes or regional cortical thickness. Together, these findings provide evidence for the cerebellum as a key brain structure underlying the development of core phenotypes of severe mental illness.

The associations with general cognitive function and general psychopathology were expected based on previous research in adults[26,30,31], and add to the growing database supporting a cerebellar role in cognition and affect[65]. Although the majority of structural MRI-studies on psychosis have focused on cerebral structures[66], our findings on sub-clinical psychotic symptoms are in general agreement with an emerging body of research. For instance, we have recently shown that cerebellar volume reductions is one of the strongest and most consistent morphological alterations in a large multi-site sample of schizophrenia patients (N = 983) and healthy controls (N = 1349)[1]. Of note, both in our previous patient study[1] and in the current study of premorbid symptoms, the strongest effects of the psychosis domain converged on cerebellar regions that show functional connectivity with the frontoparietal cerebral network, a cerebellar region that also emerged as one of the strongest predictors of transition to psychosis in a recent study of high-risk populations[67]. Moreover, functional neuroimaging studies consistently report reduced cerebello-cerebral connectivity in schizophrenia patients[68-71] and high-risk groups[72,73], while behavioral studies find impaired cerebellar learning in both patients with schizophrenia[74-76] and their first-degree relatives[77].

Our findings differ in some respects from a previous study of structural brain alterations in a partially overlapping sample of psychosis spectrum youth[34], which reported the strongest group effects in medial temporal, posterior cingulate and frontal regions. We highlight two possible sources of these discrepancies. First, only the current study employed analysis pipelines optimized for both the cerebellum[78] and the cerebrum[79]. Second, whereas the previous study employed an extreme group design[34], we tested parametric associations across the full phenotypic range.

The associations between cerebellar volume and rates of norm-violating behavior are consistent with some recent reports of altered cerebellar white matter microstructure[80] and functional activation[81] in conduct disorder. However, since our control analyses

suggested that these associations might be partially confounded by parental education level and substance abuse, they should be interpreted with caution.

While the current results do not allow inferences regarding underlying neurobiological processes, we observe that cerebellar volume - like hippocampal volume[82] - has previously been shown to be very sensitive to stress hormone exposure, especially during infancy[83,84] but also in adults with very high levels due to Cushing´s disease[85-87]. This may provide a potential link, to be tested in future research, between our findings and the well-documented role of stressful life events in the development of psychopathology[88].

A notable strength of the current study is the use of internal cross-validation, which should reduce the risk of overfitting, and thus ensure more generalizable effect estimates[89]. Its main limitation is the cross-sectional design, which prevents tests of causal relationships. Further, although the reported structure-function associations were robust and highly significant, cerebellar morphology explains only a limited part of the variance in clinical scores. While not surprising, given the multiple factors that influence the expression of psychiatric symptoms[88,90,91], this caveat must be kept in mind when interpreting the results.

Conclusions

In conclusion, our findings highlight the cerebellum as a key brain structure for understanding the development of mental disorders, in particular psychosis.

References

1. Moberget T, Doan NT, Alnaes D, et al. Cerebellar volume and cerebellocerebral structural covariance in schizophrenia: a multisite mega-analysis of 983 patients and 1349 healthy controls. *Mol Psychiatry.* 2017.
2. Laidi C, d'Albis M-A, Wessa M, et al. Cerebellar volume in schizophrenia and bipolar I disorder with and without psychotic features. *Acta Psychiatr Scand.* Vol 1312015:223-233.
3. Johnson CP, Follmer RL, Oguz I, et al. Quantitative T1rho mapping links the cerebellum and lithium use in bipolar disorder. *Mol Psychiatry.* 2015;20(2):149.
4. Shen Z, Cheng Y, Yang S, et al. Changes of grey matter volume in first-episode drug-naive adult major depressive disorder patients with different age-onset. *Neuroimage Clin.* 2016;12:492-498.
5. He H, Sui J, Du Y, et al. Co-altered functional networks and brain structure in unmedicated patients with bipolar and major depressive disorders. *Brain Struct Funct.* 2017.
6. Depping MS, Nolte HM, Hirjak D, et al. Cerebellar volume change in response to electroconvulsive therapy in patients with major depression. *Prog Neuropsychopharmacol Biol Psychiatry.* 2017;73:31-35.
7. Depping MS, Wolf ND, Vasic N, et al. Abnormal cerebellar volume in acute and remitted major depression. *Prog Neuropsychopharmacol Biol Psychiatry.* 2016;71:97-102.
8. Lange I, Kasanova Z, Goossens L, et al. The anatomy of fear learning in the cerebellum: A systematic meta-analysis. *Neurosci Biobehav Rev.* 2015;59:83-91.
9. Stoodley CJ. Distinct regions of the cerebellum show gray matter decreases in autism, ADHD, and developmental dyslexia. *Front Syst Neurosci.* Vol 82014:92.
10. Lantieri F, Glessner JT, Hakonarson H, Elia J, Devoto M. Analysis of GWAS top hits in ADHD suggests association to two polymorphisms located in genes expressed in the cerebellum. *Am J Med Genet B Neuropsychiatr Genet.* 2010;153B(6):1127-1133.
11. Wang SS-H, Kloth AD, Badura A. The Cerebellum, Sensitive Periods, and Autism. *Neuron.* Vol 832014:518-532.
12. Di Martino A, Fair DA, Kelly C, et al. Unraveling the miswired connectome: a developmental perspective. *Neuron.* 2014;83(6):1335-1353.
13. Kessler RC, Berglund P, Demler O, Jin R, Merikangas KR, Walters EE. Lifetime prevalence and age-of-onset distributions of DSM-IV disorders in the National Comorbidity Survey Replication. *Arch Gen Psychiatry.* 2005;62(6):593-602.
14. Phillips JR, Hewedi DH, Eissa AM, Moustafa AA. The cerebellum and psychiatric disorders. *Front Public Health.* 2015;3:66.
15. Konarski JZ, McIntyre RS, Grupp LA, Kennedy SH. Is the cerebellum relevant in the circuitry of neuropsychiatric disorders? *J Psychiatry Neurosci.* 2005;30(3):178-186.
16. Gowen E, Miall RC. The cerebellum and motor dysfunction in neuropsychiatric disorders. *The Cerebellum.* Vol 62007:268-279.
17. Merikangas KR, He JP, Burstein M, et al. Lifetime prevalence of mental disorders in U.S. adolescents: results from the National Comorbidity Survey Replication--Adolescent Supplement (NCS-A). *J Am Acad Child Adolesc Psychiatry.* 2010;49(10):980-989.
18. McGorry PD, Purcell R, Goldstone S, Amminger GP. Age of onset and timing of treatment for mental and substance use disorders: implications for preventive intervention strategies and models of care. *Curr Opin Psychiatry.* 2011;24(4):301-306.
19. Romer AL, Knodt AR, Houts R, et al. Structural alterations within cerebellar circuitry are associated with general liability for common mental disorders. *Mol Psychiatry.* 2017.
20. Satterthwaite TD, Connolly JJ, Ruparel K, et al. The Philadelphia Neurodevelopmental Cohort: A publicly available resource for the study of normal and abnormal brain development in youth. *Neuroimage.* 2016;124(Pt B):1115-1119.

21. Calkins ME, Merikangas KR, Moore TM, et al. The Philadelphia Neurodevelopmental Cohort: constructing a deep phenotyping collaborative. *J Child Psychol Psychiatry.* 2015;56(12):1356-1369.
22. Cuthbert BN, Insel TR. Toward the future of psychiatric diagnosis: the seven pillars of RDoC. *BMC Med.* Vol 112013:126.
23. Wigman JT, de Vos S, Wichers M, van Os J, Bartels-Velthuis AA. A Transdiagnostic Network Approach to Psychosis. *Schizophr Bull.* 2017;43(1):122-132.
24. van Os J, Reininghaus U. Psychosis as a transdiagnostic and extended phenotype in the general population. *World Psychiatry.* 2016;15(2):118-124.
25. Alnaes D, Kaufmann T, Doan NT, et al. Association of Heritable Cognitive Ability and Psychopathology With White Matter Properties in Children and Adolescents. *JAMA Psychiatry.* 2018.
26. Yoon YB, Shin WG, Lee TY, et al. Brain Structural Networks Associated with Intelligence and Visuomotor Ability. *Sci Rep.* 2017;7(1):2177.
27. Basten U, Hilger K, Fiebach CJ. Where smart brains are different: A quantitative meta-analysis of functional and structural brain imaging studies on intelligence. *Intelligence.* 2015;51:10-27.
28. Noble KG, Houston SM, Brito NH, et al. Family income, parental education and brain structure in children and adolescents. *Nat Neurosci.* 2015;18(5):773-778.
29. Moulton EA, Elman I, Becerra LR, Goldstein RZ, Borsook D. The cerebellum and addiction: insights gained from neuroimaging research. *Addict Biol.* 2014;19(3):317-331.
30. Barton RA, Venditti C. Rapid evolution of the cerebellum in humans and other great apes. *Curr Biol.* 2014;24(20):2440-2444.
31. Hogan MJ, Staff RT, Bunting BP, et al. Cerebellar brain volume accounts for variance in cognitive performance in older adults. *Cortex.* 2011;47(4):441-450.
32. Himberg J, Hyvarinen A, Esposito F. Validating the independent components of neuroimaging time series via clustering and visualization. *Neuroimage.* 2004;22(3):1214-1222.
33. Wood SN. Fast stable restricted maximum likelihood and marginal likelihood estimation of semiparametric generalized linear models. *J R Stat Soc B.* 2011;73:3-36.
34. Satterthwaite TD, Wolf DH, Calkins ME, et al. Structural Brain Abnormalities in Youth With Psychosis Spectrum Symptoms. *JAMA Psychiatry.* 2016;73(5):515-524.
35. Satterthwaite TD, Elliott MA, Ruparel K, et al. Neuroimaging of the Philadelphia neurodevelopmental cohort. *Neuroimage.* 2014;86:544-553.
36. Buckner RL, Head D, Parker J, et al. A unified approach for morphometric and functional data analysis in young, old, and demented adults using automated atlas-based head size normalization: reliability and validation against manual measurement of total intracranial volume. *NeuroImage.* Vol 232004:724-738.
37. Fischl B, Salat DH, Busa E, et al. Whole brain segmentation: automated labeling of neuroanatomical structures in the human brain. *Neuron.* 2002;33(3):341-355.
38. Desikan RS, Ségonne F, Fischl B, et al. An automated labeling system for subdividing the human cerebral cortex on MRI scans into gyral based regions of interest. *Neuroimage.* 2006;31(3):968-980.
39. Diedrichsen J, Zotow E. Surface-Based Display of Volume-Averaged Cerebellar Imaging Data. *PLoS One.* 2015;10(7):e0133402.
40. Diedrichsen J. A spatially unbiased atlas template of the human cerebellum. *Neuroimage.* 2006;33(1):127-138.
41. Ashburner J. A fast diffeomorphic image registration algorithm. *NeuroImage.* Vol 382007:95-113.

42. E K-H, Chen S-HA, Ho M-HR, Desmond JE. A meta-analysis of cerebellar contributions to higher cognition from PET and fMRI studies. *Hum Brain Mapp.* Vol 352014:593-615.
43. Stoodley CJ, Schmahmann JD. Functional topography in the human cerebellum: a meta-analysis of neuroimaging studies. *NeuroImage.* Vol 442009:489-501.
44. Buckner RL, Krienen FM, Castellanos A, Diaz JC, Yeo BTT. The organization of the human cerebellum estimated by intrinsic functional connectivity. *Journal of Neurophysiology.* Vol 1062011:2322-2345.
45. Sang L, Qin W, Liu Y, et al. Resting-state functional connectivity of the vermal and hemispheric subregions of the cerebellum with both the cerebral cortical networks and subcortical structures. *NeuroImage.* Vol 61: Elsevier Inc.; 2012:1213-1225.
46. Krienen FM, Buckner RL. Segregated fronto-cerebellar circuits revealed by intrinsic functional connectivity. *Cerebral Cortex.* Vol 192009:2485-2497.
47. Bernard JA, Seidler RD, Hassevoort KM, et al. Resting state cortico-cerebellar functional connectivity networks: a comparison of anatomical and self-organizing map approaches. *Front Neuroanat.* Vol 62012:31.
48. Kipping JA, Grodd W, Kumar V, Taubert M, Villringer A, Margulies DS. Overlapping and parallel cerebello-cerebral networks contributing to sensorimotor control: an intrinsic functional connectivity study. *NeuroImage.* Vol 832013:837-848.
49. Wang C, Kipping J, Bao C, Ji H, Qiu A. Cerebellar Functional Parcellation Using Sparse Dictionary Learning Clustering. *Front Neurosci.* 2016;10:188.
50. Kipping JA, Tuan TA, Fortier MV, Qiu A. Asynchronous Development of Cerebellar, Cerebello-Cortical, and Cortico-Cortical Functional Networks in Infancy, Childhood, and Adulthood. *Cereb Cortex.* 2016.
51. Beckmann CF, Smith SM. Probabilistic independent component analysis for functional magnetic resonance imaging. *IEEE Trans Med Imaging.* 2004;23(2):137-152.
52. Yarkoni T, Poldrack RA, Nichols TE, Van Essen DC, Wager TD. Large-scale automated synthesis of human functional neuroimaging data. *Nat Methods.* 2011;8(8):665-670.
53. Lenroot RK, Gogtay N, Greenstein DK, et al. Sexual dimorphism of brain developmental trajectories during childhood and adolescence. *Neuroimage.* 2007;36(4):1065-1073.
54. Giedd JN, Blumenthal J, Jeffries NO, et al. Brain development during childhood and adolescence: a longitudinal MRI study. *Nat Neurosci.* 1999;2(10):861-863.
55. Vandekar SN, Shinohara RT, Raznahan A, et al. Topologically dissociable patterns of development of the human cerebral cortex. *J Neurosci.* 2015;35(2):599-609.
56. de Jong LW, Vidal JS, Forsberg LE, et al. Allometric scaling of brain regions to intra-cranial volume: An epidemiological MRI study. *Hum Brain Mapp.* 2017;38(1):151-164.
57. Mankiw C, Park MTM, Reardon PK, et al. Allometric Analysis Detects Brain Size-Independent Effects of Sex and Sex Chromosome Complement on Human Cerebellar Organization. *J Neurosci.* 2017;37(21):5221-5231.
58. Schafer J, Strimmer K. A shrinkage approach to large-scale covariance matrix estimation and implications for functional genomics. *Stat Appl Genet Mol Biol.* 2005;4:Article32.
59. Zuber V, Strimmer K. High-Dimensional Regression and Variable Selection Using CAR Scores. *Stat Appl Genet Mol.* 2011;10(1).
60. Winkler AM, Ridgway GR, Webster MA, Smith SM, Nichols TE. Permutation inference for the general linear model. *NeuroImage.* Vol 922014:381-397.
61. Rimol LM, Nesvag R, Hagler DJ, Jr., et al. Cortical volume, surface area, and thickness in schizophrenia and bipolar disorder. *Biol Psychiatry.* 2012;71(6):552-560.
62. Hibar DP, Westlye LT, Doan NT, et al. Cortical abnormalities in bipolar disorder: an MRI analysis of 6503 individuals from the ENIGMA Bipolar Disorder Working Group. *Mol Psychiatry.* 2017.

63. Demyttenaere K, Bruffaerts R, Posada-Villa J, et al. Prevalence, severity, and unmet need for treatment of mental disorders in the World Health Organization World Mental Health Surveys. *JAMA.* 2004;291(21):2581-2590.
64. Steel Z, Marnane C, Iranpour C, et al. The global prevalence of common mental disorders: a systematic review and meta-analysis 1980-2013. *Int J Epidemiol.* 2014;43(2):476-493.
65. Schmahmann JD, Sherman JC. The cerebellar cognitive affective syndrome. *Brain.* Vol 121 (Pt 4)1998:561-579.
66. van Erp TG, Hibar DP, Rasmussen JM, et al. Subcortical brain volume abnormalities in 2028 individuals with schizophrenia and 2540 healthy controls via the ENIGMA consortium. *Mol Psychiatry.* 2016;21(4):585.
67. Koutsouleris N, Riecher-Rossler A, Meisenzahl EM, et al. Detecting the psychosis prodrome across high-risk populations using neuroanatomical biomarkers. *Schizophr Bull.* 2015;41(2):471-482.
68. Anticevic A, Cole MW, Repovs G, et al. Characterizing Thalamo-Cortical Disturbances in Schizophrenia and Bipolar Illness. *Cerebral Cortex*2013.
69. Zhuo C, Wang C, Wang L, et al. Altered resting-state functional connectivity of the cerebellum in schizophrenia. *Brain Imaging Behav.* 2017.
70. Shinn AK, Baker JT, Lewandowski KE, Ongur D, Cohen BM. Aberrant cerebellar connectivity in motor and association networks in schizophrenia. *Front Hum Neurosci.* Vol 92015:134.
71. Ferri J, Ford JM, Roach BJ, et al. Resting-state thalamic dysconnectivity in schizophrenia and relationships with symptoms. *Psychol Med.* 2018:1-8.
72. Anticevic A, Haut K, Murray JD, et al. Association of Thalamic Dysconnectivity and Conversion to Psychosis in Youth and Young Adults at Elevated Clinical Risk. *JAMA Psychiatry*2015.
73. Bernard JA, Orr JM, Mittal VA. Cerebello-thalamo-cortical networks predict positive symptom progression in individuals at ultra-high risk for psychosis. *Neuroimage Clin.* 2017;14:622-628.
74. Coesmans M, Röder CH, Smit AE, et al. Cerebellar motor learning deficits in medicated and medication-free men with recent-onset schizophrenia. *J Psychiatry Neurosci.* Vol 392014:E3-E11.
75. Parker KL, Andreasen NC, Liu D, Freeman JH, O'Leary DS. Eyeblink conditioning in unmedicated schizophrenia patients: A positron emission tomography study. *Psychiatry Res.* Vol 2142013:402-409.
76. Forsyth JK, Bolbecker AR, Mehta CS, et al. Cerebellar-dependent eyeblink conditioning deficits in schizophrenia spectrum disorders. *Schizophr Bull.* Vol 382012:751-759.
77. Bolbecker AR, Kent JS, Petersen IT, et al. Impaired Cerebellar-Dependent Eyeblink Conditioning in First-Degree Relatives of Individuals With Schizophrenia. *Schizophr Bull*2013.
78. Diedrichsen J. A spatially unbiased atlas template of the human cerebellum. *NeuroImage.* Vol 332006:127-138.
79. Fischl B. FreeSurfer. *NeuroImage.* Vol 622012:774-781.
80. Sarkar S, Dell'Acqua F, Froudist Walsh S, et al. A Whole-Brain Investigation of White Matter Microstructure in Adolescents with Conduct Disorder. *PLoS One.* 2016;11(6):e0155475.
81. Wu Q, Zhang X, Dong D, Wang X, Yao S. Altered spontaneous brain activity in adolescent boys with pure conduct disorder revealed by regional homogeneity analysis. *Eur Child Adolesc Psychiatry.* 2017;26(7):827-837.
82. Brown ES, D JW, Frol A, et al. Hippocampal volume, spectroscopy, cognition, and mood in patients receiving corticosteroid therapy. *Biol Psychiatry.* 2004;55(5):538-545.

83. Tam EW, Chau V, Ferriero DM, et al. Preterm cerebellar growth impairment after postnatal exposure to glucocorticoids. *Sci Transl Med.* 2011;3(105):105ra105.
84. Noguchi KK. Glucocorticoid Induced Cerebellar Toxicity in the Developing Neonate: Implications for Glucocorticoid Therapy during Bronchopulmonary Dysplasia. *Cells.* Vol 32014:36-52.
85. Jiang H, Ren J, He NY, et al. Volumetric magnetic resonance imaging analysis in patients with short-term remission of Cushing's disease. *Clin Endocrinol (Oxf).* 2017;87(4):367-374.
86. Burkhardt T, Ludecke D, Spies L, Wittmann L, Westphal M, Flitsch J. Hippocampal and cerebellar atrophy in patients with Cushing's disease. *Neurosurg Focus.* 2015;39(5):E5.
87. Santos A, Resmini E, Crespo I, et al. Small cerebellar cortex volume in patients with active Cushing's syndrome. *Eur J Endocrinol.* 2014;171(4):461-469.
88. Fusar-Poli P, Tantardini M, De Simone S, et al. Deconstructing vulnerability for psychosis: Meta-analysis of environmental risk factors for psychosis in subjects at ultra high-risk. *Eur Psychiatry.* 2017;40:65-75.
89. Yarkoni T, Westfall J. Choosing Prediction Over Explanation in Psychology: Lessons From Machine Learning. *Perspect Psychol Sci.* 2017;12(6):1100-1122.
90. Kendler KS, Prescott CA, Myers J, Neale MC. The structure of genetic and environmental risk factors for common psychiatric and substance use disorders in men and women. *Arch Gen Psychiatry.* 2003;60(9):929-937.
91. Matheson SL, Shepherd AM, Laurens KR, Carr VJ. A systematic meta-review grading the evidence for non-genetic risk factors and putative antecedents of schizophrenia. *Schizophr Res.* 2011;133(1-3):133-142.
92. Diedrichsen J, Zotow E. Surface-Based Display of Volume-Averaged Cerebellar Imaging Data. *PLoS ONE.* Vol 102015:e0133402.
93. Yarkoni T, Poldrack RA, Nichols TE, Van Essen DC, Wager TD. Large-scale automated synthesis of human functional neuroimaging data. *Nat Meth.* Vol 82011:665-670.