

Arginine to glutamine mutation in olfactomedin-like 3 (*OLFML3*) is a candidate for severe goniodysgenesis and glaucoma in the Border Collie dog breed.

Carys A Pugh*, Lindsay L Farrell*¹, Ailsa J Carlisle*, Stephen J Bush*†, Violeta Trejo-Reveles*, Oswald Matika*, Arne de Kloet‡, Caitlin Walsh‡, Stephen C Bishop*², James GD Prendergast*, Jeffrey J Schoenebeck*, Joe Rainger*, Kim M Summers*§

* The Roslin Institute, Easter Bush EH25 9RG, United Kingdom

† Nuffield Department of Clinical Medicine, University of Oxford, John Radcliffe Hospital, Oxford OX3 9DU, United Kingdom

‡ Animal Genetics, 1336 Timberlane Rd, Tallahassee, FL 32312, USA

§ Mater Research Institute-UQ, Translational Research Institute, Brisbane, Qld 4012, Australia

¹ Present address: British Columbia Centre on Substance Abuse, St Paul's Hospital, Vancouver, BC V6Z 1Y6, Canada

² Deceased

Running title: *OLFML3* mutation in Border Collie glaucoma

Key words: Glaucoma, goniodysgenesis, olfactomedin-like 3, Border Collie, eye development

Corresponding authors:

Dr Carys Pugh, The Roslin Institute, University of Edinburgh, Easter Bush EH25 9RG, UK

Phone: +441316519221

Email: carys.pugh@roslin.ed.ac.uk

Professor Kim M Summers, Mater Research Institute-UQ, Translational Research Institute,

37 Kent St, Woolloongabba, QLD 4102, Australia

Phone: +61734437655

Email: kim.summers@mater.uq.edu.au

Email addresses:

carys.pugh@roslin.ed.ac.uk

lfarrell@cfenet.ubc.ca

ailsa.carlisle@roslin.ed.ac.uk

stephen.bush@ndm.ox.ac.uk

s1675119@sms.ed.ac.uk

oswald.matika@roslin.ed.ac.uk

arne@animalgenetics.com

caitlin@animalgenetics.com

james.prendergast@roslin.ed.ac.uk

jeff.schoenebeck@roslin.ed.ac.uk

joe.rainger@roslin.ed.ac.uk

kim.summers@mater.uq.edu.au

Abstract

Goniodysgenesis is a developmental abnormality of the anterior chamber of the eye. It is generally considered to be congenital in dogs (*Canis lupus familiaris*), and has been associated with glaucoma and blindness. Goniodysgenesis and early-onset glaucoma initially emerged in Border Collies in Australia in the late 1990s and has subsequently been found in Europe and the USA. The objective of the present study was to determine the genetic basis of goniodysgenesis in Border Collies. Clinical diagnosis was based on results of examinations by veterinary ophthalmologists of affected and unaffected dogs from eleven different countries. Genotyping using the Illumina high density canine SNP chip and whole genome sequencing was used to identify candidate genetic regions. Expression profiles and evolutionary conservation of candidate genes were assessed using public databases. Analysis of pedigree information was consistent with an autosomal recessive mode of inheritance for severe goniodysgenesis (potentially leading to glaucoma) in this breed. There was a highly significant peak of association over chromosome 17, with a p -value of 2×10^{-13} . Whole genome sequences of three dogs with glaucoma, three with severe goniodysgenesis and three unaffected dogs identified a missense variant in the olfactomedin-like 3 (*OLFML3*) gene in all six affected animals. This was homozygous in all nine cases with glaucoma and nine of 11 other severely affected animals. None of 56 unaffected animals was homozygous for this variant. The identification of a candidate genetic region and putative causative mutation will inform breeding programs to reduce the frequency of goniodysgenesis and the risk of glaucoma in the Border Collie population.

Introduction

Companion animals including cats, dogs and horses, suffer from a range of diseases, with both genetic and environmental aetiologies. The breed barrier created by registration requirements and breeding practices seeking to maximise compliance of animals with breed specifications results in increased levels of matings between relatives [1] and means that purebred companion animals are particularly likely to suffer from recessive genetic conditions. Understanding the genetic factors underlying these diseases is important to improve welfare within breeds and the strong linkage disequilibrium in such inbred populations means that small numbers of pedigree animals can be used to identify regions of interest, making them excellent genetic models for similar diseases in humans.

In response to the identification of causal variants, breeding strategies can be put in place to reduce the prevalence of conditions that impact on animal welfare, especially when a genetic test can be developed. However, the success of these approaches depends on understanding the mode of inheritance and level of genetic contribution to the disease, and ideally on identifying a causative mutation that can be used to develop a test for genetic status.

Primary glaucoma is a condition in which increased ocular pressure damages the retinal ganglion, leading to blindness (reviewed in [2]). In domesticated dogs (*Canis lupus familiaris*) it can be preceded by goniodysgenesis (also known as mesodermal dysgenesis), a developmental abnormality of the eye characterised by narrowing or closure of the iridocorneal angle (ICA) through which the aqueous humour drains. This is associated with alterations in the structure of the pectinate ligament which transverses the drainage angle, called pectinate ligament dysplasia (PLD) [3] (more properly pectinate ligament abnormality

[4]). In the Leonberger dog breed, goniodysgenesis has been associated with an increased risk of developing primary closed angle glaucoma (PCAG) [2] and in Flat-Coated Retrievers, development of glaucoma is positively and significantly related to the severity of goniodysgenesis [5]. Goniodysgenesis is generally considered to be congenital in dogs, although its subsequent progression is different between breeds. The severity is thought to increase with age in Leonbergers [2] and Flat-Coated Retrievers [6, 7] and was shown to be strongly associated with age in Dandy Dinmont Terriers, Basset Hounds, Hungarian Vizslas and Golden Retrievers [7, 8]. However, goniodysgenesis remained stable in Samoyeds [9] and was not associated with age in a small study of Border Collies [8].

Sudden onset glaucoma leading to bilateral loss of eyes and blindness was first observed in young Border Collies in Australia about 15 years ago. A similar, sudden onset glaucoma in young animals subsequently emerged in UK Border Collie population, often in dogs that were related to the affected Australian dogs. More recently a number of dogs in the USA have been diagnosed with severe goniodysgenesis and glaucoma. Goniodysgenesis in Border Collies has been added to the Schedule B list of 'Conditions Under Investigation' in the British Veterinary Association (BVA) Eye Scheme (<http://www.bva.co.uk/Canine-Health-Schemes/Eye-scheme/>) and it is highly prevalent in some Border collie lineages (see Anadune Border collie database: <http://www.anadune.com/>; free access but registration required). In a recent study [8], 11 of 102 Border Collies (10.8%) were reported to have moderate or severe PLD (associated with goniodysgenesis). Seven (6.9%) were mildly affected. Because of the association with a small number of popular sires and the high prevalence in some family lineages, a genetic aetiology is strongly suspected in Border Collies, but the heritability and mode of inheritance of the condition is currently unknown. It is also not known why a proportion of dogs diagnosed with severe goniodysgenesis go on to

develop glaucoma while others remain glaucoma free over a life span of 15 or more years, similar to those with mild goniodysgenesis.

The aim of the current study was to perform a genome-wide analysis to find genetic loci that are associated with severe goniodysgenesis and glaucoma in the Border Collie and to identify plausible candidate mutations that might be responsible for this condition.

Materials and Methods

Full details of the Materials and Methods are available in **Supplemental File S1**.

Ethical approval

All studies were approved by the Veterinary Ethical Review Committee of the University of Edinburgh (approval number VERC 2012-8) and the Animal Ethics Committee of the University of Queensland (approval number ANFRA/MRI-UQ/565/17).

Ascertainment of clinical status and pedigree

Goniodysgenesis was diagnosed by examination of the eyes with gonioscopy when the status of the drainage angle and the pectinate ligament fibres that span it was assessed. Since we had results in multiple formats from many veterinary ophthalmologists, each report was manually assessed to assign clinical status to each subject. Only individuals who had had gonioscopy analysis were included. Breeding records and pedigree data were obtained from public databases and from the breeders' websites. Websites were accessed at various times up to February 2018. Full details including exclusion criteria are given in **Supplemental File S1**.

Genetic analysis

DNA samples were from buccal cells collected by owners and occasionally from blood. Full details of collection and extraction procedures are given in **Supplemental File S1**.

Genotyping used the Illumina 173k CanineHD Whole-Genome Genotyping Bead Chip (Illumina, San Diego, CA, USA). Results were filtered in PLINK v1.07 [10] to remove individuals that had more than 10% of missing genotypes and SNPs that had rates of genotyping < 0.95, had minor allele frequency < 0.05 in this population or deviated from the

Hardy-Weinberg equilibrium in the controls with P value of less than 0.000001. Only the autosomes were considered.

Cases for the analysis were defined as severely affected and consisted of dogs that had goniodysgenesis of grades four or five under a previous grading scheme, dogs whose goniodysgenesis was described as 'severe', those where the veterinary ophthalmologist report indicated PLD over more than 70% of the iridocorneal angle and those that developed glaucoma following a diagnosis of goniodysgenesis. Controls were dogs that were assessed as clear or clinically unaffected based on at least one gonioscopy examination. Previous work indicated that goniodysgenesis was not progressive in Border Collies [8] so the controls were categorised on the basis of a clear gonioscopy, regardless of age. The SNP analysis was performed in GEMMA v0.94.1 [11] using a linear mixed model approach, controlling for relatedness using a SNP-based relatedness matrix as a random effect. The significance threshold was based on a Bonferroni correction of 0.05. Additionally, a more conservative, regional approach was undertaken using sliding windows of 40 adjacent SNPs, overlapping by 20 SNPs in REACTA v0.9.7 [12] with the first two genomic principal components controlling for relatedness. Whole genome sequencing (30X coverage) of DNA from three dogs with glaucoma, three severely affected and three unaffected animals was performed using the Illumina HiSeq X platform. Library insert sizes were 450 bp and paired reads of 150 bp were sequenced. Reads were processed by standard procedures, detailed in **Supplemental File S1**, and mapped to the CanFam3.1 reference genome. The significance of variants was assessed using the Ensembl Variant Effect Predictor [17].

Transcriptomic analysis of candidate region genes

A time course of mouse eye development from embryonic day 12 to adult was examined using the FANTOM5 database [18-20] (<http://fantom.gsc.riken.jp/zenbu>). FANTOM5 data were also used to obtain expression levels for human eye-related samples (**Supplemental Table S1**). Transcriptomic data for the developing chicken eye were generated for another project by RNA sequencing methodology (Rainger et al, in preparation). Details are given in **Supplemental File S1**.

Analysis of canine OLFML3 gene

The region of the canine *OLFML3* gene containing the candidate causative mutation was amplified by the polymerase chain reaction and the amplicon sequenced by chain termination sequencing. Full details of primers and protocols are given in **Supplementary File S1**. Sequences for analysis of nucleotide and amino acid conservation across species were downloaded from Ensembl (<http://ensembl.org>) and alignment was performed using Clustal Omega (<http://www.ebi.ac.uk/Tools/msa/clustalo/>).

Results

Familial clustering of goniodysgenesis and glaucoma

Inspection of pedigrees revealed that there were three common ancestors in both the sire and dam lineages for all cases of glaucoma on the goniodysgenesis database (<https://bc-glaucomadatabase.synthasite.com/>) (N=12) including two pairs of full siblings both affected with glaucoma, as well as additional cases not on the database (N=4). These common ancestors dated back to the late 1970s and early 1980s and were found in multiple ancestral lineages for the glaucoma cases. All the glaucoma cases had been diagnosed with goniodysgenesis and subsequently had one or both eyes removed. However, several individuals diagnosed with severe goniodysgenesis had not gone on to develop glaucoma. This included two popular sires who reached the age of 15 years without a diagnosis of glaucoma. It also included a full sibling of two dogs with glaucoma. Three dogs with severe goniodysgenesis had produced a total of six offspring with glaucoma.

Genome wide association analysis

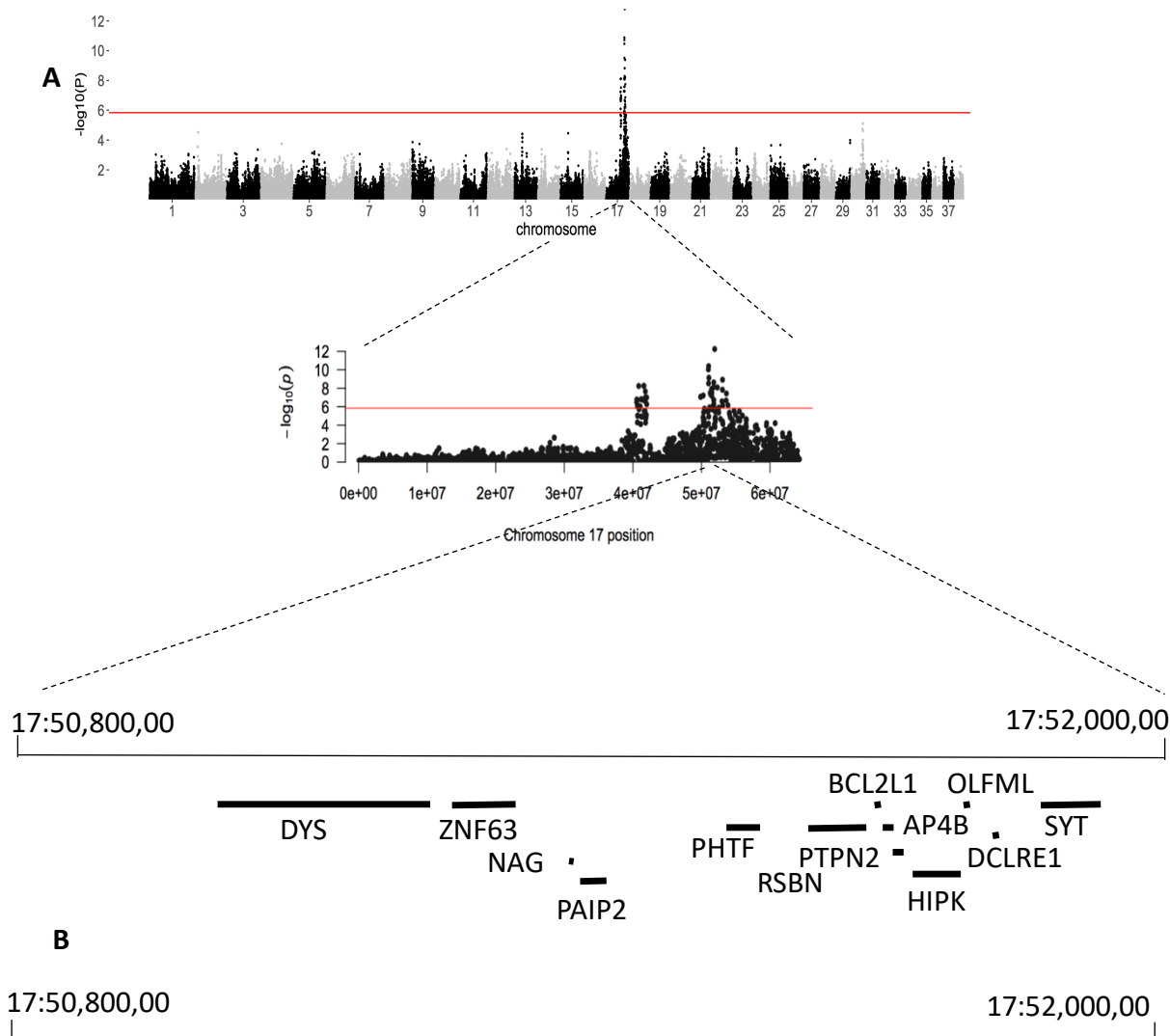
To identify genetic regions associated with goniodysgenesis in this breed, we performed SNP analysis on 17 severely affected cases (8 female, 9 male) and 42 unaffected dogs (26 female, 16 male) who had been passed as “clear” at veterinary ophthalmology testing. The cases all had goniodysgenesis described as “severe” (N=4), Grade 4 or 5 by the earlier grading scheme (N=1 and 5 respectively), or goniodysgenesis followed by glaucoma (N=7). A strong association of goniodysgenesis with a region of chromosome 17 was found (**Figure 1A**). The lowest p -value was for SNP rs22561716 at 17:51,919,221 ($P=2 \times 10^{-13}$), included in a window of 40 SNPs that had a p -value of 3×10^{-07} according to REACTA . SNPs with the lowest p -values were in a region of about 1×10^6 base pairs (**Figure 1B**). Sixteen of the severely

affected and glaucoma cases were homozygous for this haplotype and one case was heterozygous in this region. Within the genomic region identified by the association analysis there were a number of coding genes (**Figure 1A**), although none were known to be involved in eye development or glaucoma in animals or humans. Several had strong expression in the developing mouse eyeball (**Supplemental Figure F1**).

Figure 1. Genome wide association with severe goniodysgenesis and glaucoma

A. Manhattan plot for the canine genome; chromosome 17 is shown in more detail and genes in the region are shown below.

B. Homozygosity within the region of interest. Each row is a DNA sample and each column shows a SNP. Red and yellow indicate homozygosity for the major and minor allele respectively and green shows heterozygosity. The upper block shows severely affected and glaucoma animals; the lower block shows those passed as clinically unaffected at gonioscopy testing. The most significant SNP is shown as yellow (cases homozygous for the minor allele); one clinically unaffected animal was homozygous for this allele and one severely affected animal was heterozygous.



Whole genome sequencing

We then obtained the whole genome sequence of this region in three glaucoma, three severely affected and three unaffected individuals, who were members of four nuclear families (**Supplemental Figure F2**). All were distantly related through multiple lineages in the extended pedigree. Relatives were chosen to highlight variants that were different between affected and unaffected family members [21]. Within the region of the lowest P value SNP, a missense variant was found in the olfactomedin-like 3 (*OLFML3*) gene, at position 17:51,786,924. The mutation was c.590G>A with the predicted change of arginine at position 197 to glutamine (p.Arg197Gln; RNA not tested). This arginine is in the olfactomedin (OLF) domain [22, 23] (**Figure 2A**) and was found to be highly conserved throughout mammals, birds and reptiles (**Figure 2B**). The impact predicted by the Ensembl Variant Effect Predictor [17] was given as “moderate” indicating “a non-disruptive variant that might change protein effectiveness”, consistent with the non-lethal phenotype of homozygous animals. The SIFT score was 0.55, indicating a mild effect. In humans, the mutation (c.587G>A) corresponds with rs377336789 (<https://www.ncbi.nlm.nih.gov/snp/>) and was seen in four out of 121,412 chromosomes with a minor allele frequency of 3.3×10^{-5} . Genotypes are not provided for the human data, but these were presumably all heterozygous, given the minor allele frequency. SIFT score was 0.54 and PolyPhen score was 0.392, also consistent with a mild effect. The mutation was heterozygous in four of 35 Border Collies from the Dog Biomedical Variant Database Consortium (giving an allele frequency of 0.06 in this breed) but absent in 504 genotypes of other breeds. Notably, it was not present in 51 Leonbergers, 3 Basset Hounds, 8 Golden Retrievers or 1 Dandie Dinmont Terrier, all breeds reported to be associated with goniodysgenesis (see Introduction). In addition, 350 dogs of unknown clinical status recorded as Border Collies were genotyped by

Animal Genetics (Talahassie, Florida, USA) via allele-specific PCR run on an ABI 3730. There were 2 homozygotes and 29 heterozygotes among these 350 dogs, giving an allele frequency of 0.05 for the breed.

Figure 2. Conservation of *OLFML3* predicted amino acid sequence

A. Amino acid sequence of the canine *OLFML3* protein. Functional domains are highlighted: blue – signal peptide; pink – coiled coil domain; yellow – olfactomedin-like domain [22, 23]. Within the yellow region, bold lettering shows the core OLF region. Green shows the arginine at position 197.

B. Conservation of arginine 197 (green) in *OLFML3* of vertebrates. Arginine is found at the equivalent position in all mammal, bird and reptile species for which there is an annotated *OLFML3* gene, and in coelacanth but not in other fish. The region around this arginine is also highly conserved.

A

MGPYTPLLTMFLLSWWRPLQGGQHHLVEYMERRLAALAEERLAQCQDQSSRHAAELRDFK
 NKMLPLLEVAEKEREALRTEADTISGRVDRLEREVDYLETONPALPCVEVDEKVTGGPGI
 KGKGRRNEKYDMLTDCGYTISQVRSMKILKRFGGPAGLWTKDPMGPTEKIYVLDGTQNDT
 AFVFPRLRDFTLAMAAKASRVRVFPWPVGTGQLVYGGFLYARRPPGGPGGGGLENTL
 QLIKFHLANRTVVDSSVFPAGELIPPYGLTADTYIDLADEEGLWAVYATREDDRHLCIA
 KLDPQTLDTQQWDTPCPRENAEAAAFVICGTLVYVYNTRPASRARIQCSFDASGTLTPER
 AALPYFPRRYGAHASLRYNPRERQLYAWDDGYQIVYKLEMRRKKEEV

B

Opossum_OLFML3	VRSMKILKRFGSPAGMWTKDPLGPTEKIFVLDGTQNDTAYVFPRLRDFTLSTAAKASRV
Wallaby_OLFML3	VRSMKILKRFGSSAGMWTKDPLGPSEKIFVLDGTQNDTAYVFPRLRDFTLSSAAKASRV
Tasmanian_Devil_OLFML3	VRSMKILKRFGSSAGMWTKDPLGHSEKIFVLDGTQNDTAYVFPRLRDFTLSTAAKASRV
Shrew_OLFML3	VRSMKILKRFGGPTGLWTKDPLGPTEKIFVLDGTHNDTAFIFPRLRDFTLAMAAKAAARV
Kangaroo_rat_OLFML3	VRSMKILKRFGGPAGMWTKDPLGPAEKIYVFDGTQNDTALVFPRLRDFTLAMAAKASRI
Hedgehog_OLFML3	VRSMKILKRFGSPGLWTKDPLGTTEKIYVLD-PQNDTAFIFPRLRDFTLAMAAKASRV
Armadillo_OLFML3	VRSMKILKRFGGPAGLWTKDPLGPAERIVVLAGTQNDTALVFPKLRDFTLATAAKASRV
Mouse_OLFml33	VRSMKILKRFGGSVGLWTKDPLGPAEKIYVLDGTQNDTAFVFPRLRDFTLAMAAKASRI
Rat_OLFml3	VRSMKILKRFGGSAGLWTKDPLGPAEKIYVLDGTQNDTAFVFPRLRDFTLTMAAKASRI
Elephant_OLFML3	VRSMKILKRFGGPAGLWTKDPLGPTEKIVVLDGTQNDTAFVFPRLRDFSLSTATKASRV
Guinea_pig_OLFML3	VRSMKILKRFGGPAGLWTKDPLGPTEKIVVLDGTQNDTAFVFPRLRDFTLAMAAKASRV
Hyrax_OLFML3	VRSMKILKRFGGPAGLWTKDPLGPAEKIYVLDGTQNDTAFVFPRLRDFSLSMATKASRV
Microbat_OLFML3	VRSMKILKRFGSPAGLWTKDPLGPTEKIVVLDGTQNDTAFVFPRLRDFTLAMAAKASRV
Squirrel_OLFML3	VRSMKILKRFGGPAGLWTKDPLGPTEKIVVLDGTQNDTAFVFPRLRDFTLTMAAKASRV
Pig_OLFML3	VRSMKILKRFGGPAGLWTKDPLGPTEKIFVLDGTQNDTAFVFPRLRDFTLAMAAKASRI
Horse_OLFML3	VRSMKILKRFGGPAGLWTKDPMGPTEKIVVLDGTQNDTAFVFPRLRDFTLAMAAKASRV
Dog_OLFML3	VRSMKILKRFGGPAGLWTKDPMGPTEKIVVLDGTQNDTAFVFPRLRDFTLAMAAKASRV
Ferret_OLFML3	VRSMKILKRFGGPAGLWTKDPMGPTEKIVVLDGTQNDTAFVFPRLRDFTLAMAAKASRV
Panda_OLFML3	VRSMKILKRFGGPAGLWTKDPMGPTEKIVVLDGTQNDTAFIFPRLRDFTLAMAAKASRV
Cat_OLFML3	VRSMKILKRFGGPAGLWTKDPMGPAERIVVLDGTQNDTAFVFPRLRDFTLAMAAKASRV
Mouse_lemur_OLFML3	VRSMKILKRFGGPAGLWTKDPLGPTEKIVVLDGTQNDTAFVFPRLRDFTLAMAAKASRV
Human_OLFML3	VRSMKILKRFGGPAGLWTKDPLGQTEKIVVLDGTQNDTAFVFPRLRDFTLAMAAKASRV
Cow_OLFML3	VRSMKILKRFGGPAGLWTKDPLGPAEKIYVLDGTQNDTAFVFPRLRDFTLAMAAKASRV
Sheep_OLFML3	VRSMKILKRFGGPAGLWTKDPLGPAEKIYVLDGTQNDTAFVFPRLRDFTLTMAAKASRV
Dolphin_OLFML3	VRSMKILKRFGGPAGLWTKDPLGPAEKIYVLDGTQNDTAFVFPRLRDFTLAMAAKASRV
Coelacanth_OLFML3	IKSMKILKRIGSSTGMWARDPLGSDNIYVLEGTGNDTVYEYSRARDFTQSPVME-ARRI
Xenopus_OLFML3	VTAMKILKRFGSSAGLWTKDLAGNSDRIYVFDGAGNDTVYVYPRMKEFTLSSTKAAKI
Chicken_OLFML3	VRAMKILKRFGSSAGLWTKDAAGSSEKIYVFDGTANDTVYIFPRMREFTLFSATKRAARI
Flycatcher_OLFML3	VRAMKILKRFGSASGLWTKDAAGSSEKIYVFDGTANDTVYVFPRMREFTLFSATKRAARI
Lizard_OLFML3	VKAMKILKRFGSTAGLWTKDPVGNSEKIYVFDGTSNDTVYVFPRMREFTLFSATKRAARI
Turtle_OLFML3	VKAMKILKRFSSAGLWTKDPVGSSEKIYVFDGTSNDTVYVFPRMREFTLFSATKRAARI

:*****:* *:*:* * :*:*: *** : :*: *:* :

OLFML3 genotypes of severely affected and unaffected Border Collies

The results for the mutation c.590G>A in glaucoma, severe and unaffected dogs are shown in Table 1. The individual who was heterozygous for the region based on SNP chip was heterozygous for the *OLFML3* mutation. This animal had been diagnosed with severe goniodysgenesis but did not develop glaucoma over a 15 year lifespan. In general the genotype for *OLFML3* segregated with that for rs22561716, indicating strong linkage disequilibrium between them. However, an unaffected mother and son were homozygous for G at *OLFML3* but heterozygous at rs22561716 suggesting that the ancestral haplotype was G at *OLFML3* with T at rs22561716. In addition, two unaffected individuals were homozygous for several SNPs either side of *OLFML3* but heterozygous for the *OLFML3* mutation and rs22561716 and appeared to carry a different haplotype.

To validate these results we genotyped 33 additional Border Collies that had had gonioscopy investigations: two with glaucoma, five severely affected and 26 unaffected. The genotypes of these dogs are shown in Table 1 and are consistent with the results suggesting that severe goniodysgenesis/glaucoma was associated with homozygosity for the A allele of *OLFML3*.

Table 1. Genotype frequencies for *OLFML3* mutation c.590G>A in severely affected and unaffected dogs.

Genotype	AA	AG	GG	TOTAL
Clinical status				
<i>SNP-chip dogs</i>¹				
Glaucoma	7	0	0	7
Severe goniodysgenesis	8	1	0	9
Unaffected¹	1 ²	16	22	39
<i>Other dogs</i>				
Glaucoma	2	0	0	2
Severe goniodysgenesis	2	1	0	3
Unaffected	0	11	8	19
TOTALS				
Glaucoma	9	0	0	9
Severe goniodysgenesis	10	2	0	12
Unaffected	1	27	30	58

¹ Genotypes were not obtained for three unaffected SNP chip dogs due to lack of DNA.

² *OLFML3* gene not sequenced due to lack of DNA; genotype imputed from parents (both affected and AA). This was consistent with the haplotype derived from the SNP results, since this individual was also homozygous for the allele found in severely affected individuals for other SNPs in the region.

Dogs that were included in the genome wide analysis are shown separately from dogs that were only tested for *OLFML3*. Chi-squared tests were performed for the total set of dogs.

OLFML3 genotypes in mildly affected and uncategorised affected Border Collies

Our initial analysis compared severely or glaucoma affected dogs with dogs passed as unaffected at gonioscopy examination. Because of changes in the reporting scheme in the UK and differences among countries, there were a number of equivocal diagnoses. These were dogs where either the level of goniodysgenesis was given as mild (Grade 1 under the former scheme or stated as mild or marginal on the report, N = 9), moderate (Grade 2 – 3 under the old scheme, or stated as moderate or between 25 and 70% blocked on the report; N = 9), or the dogs were diagnosed as affected with no description given (N = 15). To examine whether *OLFML3* was involved in these cases we genotyped these 33 dogs. The results are shown in Table 2. All genotypes were found in these cases.

Table 2. Genotype frequencies for *OLFML3* mutation c.590G>A in mild, moderate and uncharacterised affected dogs.

Genotype	AA	AG	GG	TOTAL
Clinical status				
Mild	3	3	3	9
Moderate	5	1	4	10
Affected, no grade	6	2	4	12
TOTALS	14	6	12	31

Expression of OLFML3 in the eye

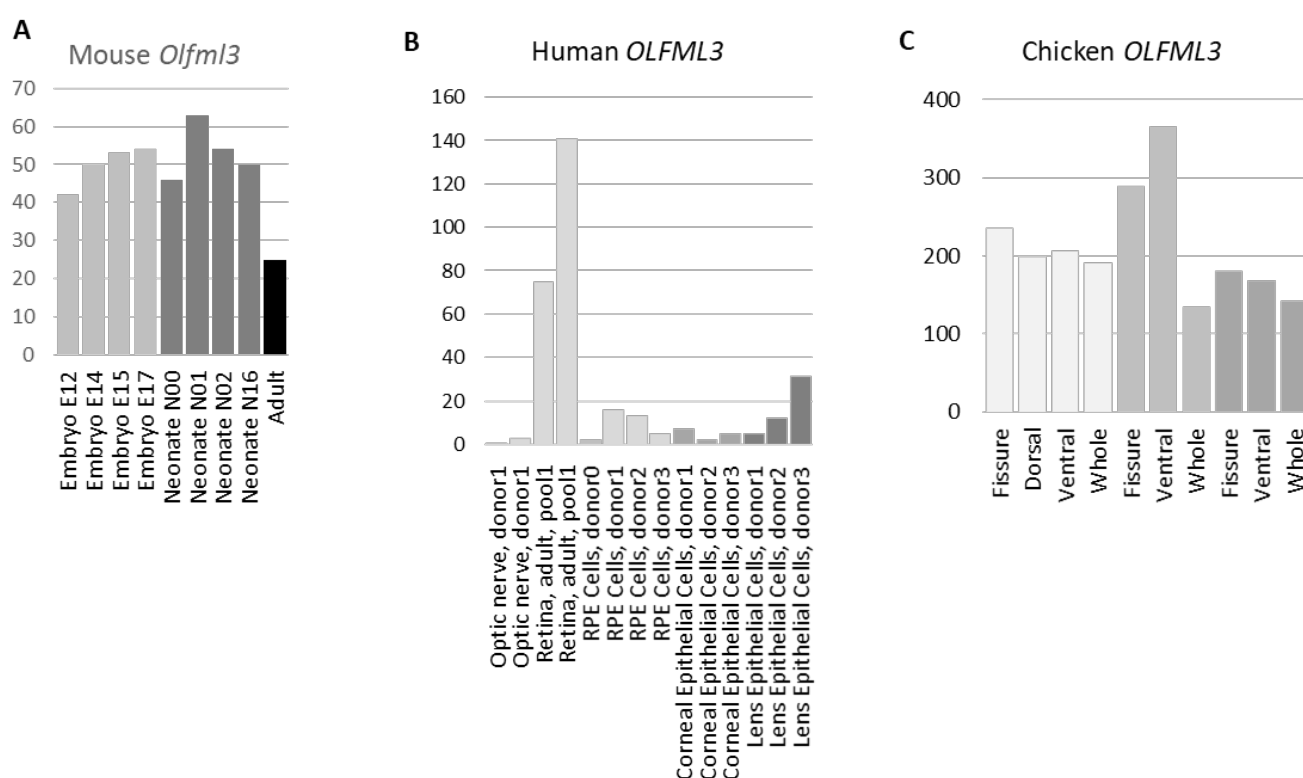
The *Olfml3* gene was strongly expressed in mouse eyeball at embryonic and neonatal stages and declined in the adult sample (**Figure 3A**). In mouse microarray data (mouse probeset 1448475_at; <http://biogps.org>) expression of *Olfml3* was highest in osteoblasts undergoing calcification, but it was also found in eyecup, iris, ciliary bodies and lens (**Supplemental Figure S3**). There was negligible expression in immune system cells, except for macrophages, osteoclasts and particularly microglia, which had expression comparable to lens and eyecup. Microarray data also available through BioGPS showed strongest expression of *OLFML3* in human adipocytes, uterus and retina, the only eye tissue represented (human probeset 218162_at; <http://biogps.org>) (**Supplemental Figure S3**). FANTOM5 data show that the gene was expressed in human lens, corneal epithelium and retina (**Figure 3B**), although the highest expression was in amniotic and placental epithelial cells and in mesenchymal stem cells (not shown). *OLFML3* was also expressed in the developing chick eye, with highest expression at embryonic day 6 (**Figure 3C**). Other OLF family members were also expressed in the developing mouse eyeball with a similar pattern to *Olfml3*, peaking in the early neonatal period and declining in the adult eye (**Supplemental Figure S4**). In contrast, the myocilin gene (encoding a related protein which is mutated in human open angle glaucoma) had negligible expression in embryo and early neonate but increased expression at neonatal day 16 and in the adult eyeball (**Supplemental Figure S4**).

Figure 3. Expression of *OLFML3* genes in eye regions

A. Expression of *Olfml3* in developing mouse eyeball. Results are based on CAGE and were downloaded from the FANTOM5 database (<http://fantom.gsc.riken.jp/5/tet>).

B. Expression of *OLFML3* in human eye tissues and cells. Results are based on CAGE and were downloaded from the FANTOM5 database.

C. Expression of *OLFML3* in the developing chick eye. Results are based on RNA sequencing (see Methods).



Discussion

In a number of dog breeds development of glaucoma has been associated with the presence of goniodysgenesis. In the Flat-Coated retriever, the likelihood of glaucoma was positively and significantly related to the severity of goniodysgenesis [5] and in the Leonberger five glaucoma-affected individuals all had a high grade of goniodysgenesis in the contralateral eye [2]. An abnormal drainage angle is considered typical of some breeds, with reports of up to 81% of individuals showing evidence of goniodysgenesis [9, 24]. However, the highest prevalence of glaucoma reported in any single breed is only 5.52% [25].

An increasing incidence of glaucoma in young animals has been reported in the Border Collie breed over the last 15 years. Consistent with results in other breeds, our survey of goniodysgenesis in the Border Collie found some individuals who lived entire lifetimes with apparently severe goniodysgenesis without developing glaucoma. This would suggest that although severe goniodysgenesis is important in the progression to glaucoma, it is not the sole cause. The aetiology may involve a genetic predisposition to goniodysgenesis combined with genetic, environmental or random factors influencing development of glaucoma.

The diagnosis of goniodysgenesis was made by veterinary ophthalmologists (such as members of the BVA Eye Panel in the UK or the equivalent certifying body in other countries) who performed gonioscopies to assess the status of the drainage angle and the pectinate ligament fibres that cross it. Since the diagnoses were made by a number of different clinicians over a period of years, there may be considerable variability in the way the phenotype was recorded. An initial eye scheme developed by the BVA in association with the Kennel Club of the United Kingdom (KCUK) involved assessing whether the dog had no eye abnormality (a pass), or some abnormality graded according to the extent of PLD and

the width of the ICA, with increasing levels of severity graded from one to five. Since there was a high degree of inter-observer variability in assigning a grade, the scheme was amended such that the dog would either pass or fail. Dogs that passed could have a drainage angle that was abnormal to some extent ('mild' goniodysgenesis; see information available at <https://www.bva.co.uk/Canine-Health-Schemes/Eye-scheme/>). The pass/fail system was expected to have a higher level of inter-observer agreement and this was observed in a study of Leonberger dogs which had a high correlation in proportion affected with goniodysgenesis between a prospective study where examinations were performed by a single specialist (2012-2014; 18% affected) and a retrospective study of BVA eye scheme certificates (2009-2014; 22% affected) [2]. In a study of PLD in Welsh Springer Spaniels, there was a good correlation between two examiners in determining unaffected eyes, although there was considerable variability between examiners in assigning the degree of PLD [4]. This variability in categorising the extent of goniodysgenesis means that the categorisation of phenotype as "affected" or "unaffected" can result in mild PLD or angle narrowing being recorded as clinically unaffected [2, 4]. For this reason we focussed our genome-wide analysis on severely affected dogs including several that had gone on to develop glaucoma.

Using severely affected cases and unaffected controls, we found a strong peak of association on chromosome 17, in the region of the *OLFML3* gene, where we detected a missense mutation p.R197Q. Although this gene has not been implicated in goniodysgenesis or glaucoma in humans, it is strongly expressed in tissues of the anterior segment of the human and baboon eye including lens, iris, sclera and trabecular meshwork [22, 26] and in the developing mouse eye [27]. The *Olfml3* gene was expressed throughout mouse and chick eye development (**Figure 3A and C**). In mouse, inactivation of the *Olfml3* gene by

insertion of a *Lac* cassette resulted in viable and fertile homozygotes [27], consistent with the relatively mild selective disadvantage of dogs with goniodysgenesis. Expression has also been observed in human tissues of mesenchymal origin such as bone and adipose (**Supplemental Figure S3**). Olfactomedin-like 3 is an extracellular matrix protein that has been implicated in the epithelial to mesenchyme transition (EMT) in cancer [28], consistent with its mesenchymal expression, and suggesting that abnormality of this protein could be associated with the formation or retention of abnormal sheets of mesenchyme in the drainage angle. Olfactomedin-like 3 is also proangiogenic [29] and interacts with BMP4. Since BMPs including BMP4 are involved in eye development (see [30] for a review), this may indicate the pathway for olfactomedin-like 3 action.

In addition, expression of *OLFML3* is also characteristic of microglia in humans [31, 32] and mice (<http://biogps.org>; <http://www.immgen.org>; **Supplemental Figure S3**), although it is not strongly expressed by other macrophage lineages. Genetic manipulation resulting in absence of microglia is associated with loss of *Olfml3* expression in mice (Rojo *et al*, in preparation). The retina contains microglia which are important for retinal health [33, 34], and they could be one source of *OLFML3* mRNA in the canine eye. Opening of the ICA involves considerable remodelling of the mesenchymal tissue within the angle, including thinning and extending of the pectinate ligament and opening the trabecular meshwork [35]. Microglia may contribute to this process as eye development progresses by phagocytosing apoptotic cells and debris from the remodelling. Abnormality of olfactomedin-like 3 in the microglia of the eye could interfere with this function and therefore disrupt the opening of the iridocorneal angle and formation of the proper drainage channels.

Olfactomedin-like 3 is a member of a large family characterised by the olfactomedin (OLF) domain [23, 36], with several members expressed in eye structures. In particular, the glucocorticoid-inducible family member myocilin (*MYOC* gene) has been implicated in dominant open angle glaucoma in humans [37] and is strongly expressed in the trabecular meshwork of the drainage angle [38, 39]. As with *Olfml3* mutants, there is no gross phenotype in *Myoc* knockout mice [40]. Increased expression of *Myoc* mRNA resulted in a reduction in *Olfml3* mRNA [41] in a mouse model, suggesting that there is an inverse association between these two OLF proteins. *In vitro* experiments indicated that myocilin interacts with olfactomedin 3 (also known as optimedlin, encoded by the *OLFM3* gene) which is coexpressed with myocilin in the eye [42]. Mutation in another OLF family member, *OLFM2*, has been associated with human open angle glaucoma in a small number of Japanese patients (rs779032127; p.Arg144Gln) [43] and identified as contributing to eye development [44]. These other OLF family members may compensate for olfactomedin-like 3 abnormalities, or may interact with olfactomedin-like 3 in the development of the eye. Hence genetic variation in these family members may modify the impact of the *OLFML3* mutation in the Border Collies, explaining the variable phenotype of homozygotes and heterozygotes carrying the mutation.

We propose that the p.Arg197Gln mutation in Border Collies is responsible for the presence of severe goniodysgenesis predisposing to glaucoma in homozygous animals. We have also seen some heterozygous animals with mild to relatively severe phenotypes (although none with glaucoma), but many heterozygotes have been passed as clinically unaffected at gonioscopy testing. This suggests that there may be variants at modifier loci that can compensate for the *OLFML3* mutation. In particular, the presence of many OLF proteins in the eye and the mild phenotype associated with relatively broadly expressed gene family

members suggests redundancy for at least some functions. It is also possible that inadequate compensation for the putative effects of the p.R197Q mutation may be responsible for the progression from severe goniodysgenesis to glaucoma.

There were too few glaucoma cases in our study to allow identification of loci involved in progression from goniodysgenesis to glaucoma in the Border Collie and ambiguous phenotyping complicates the investigation of mild goniodysgenesis. The genetic relationship between the mild forms and the more severe forms is unknown, but the *OLFML3* variant described here does not appear to be associated with mild goniodysgenesis indicating that genetic predisposition to mild goniodysgenesis may be independent of the findings of this study. Although developing a test for the *OLFML3* mutation would allow breeders to select against homozygotes and heterozygotes to decrease the prevalence of the risk genotype for severe goniodysgenesis, it is important not to reduce the breeding pool too much because of the risk of other recessive conditions resulting from homozygosity for alleles that are identical by descent. Therefore, we need to understand why some of our cases progressed to glaucoma at a young age and some did not before we can make recommendations to the breeders of Border Collies worldwide.

Acknowledgements

We are grateful to Dogs Trust (UK) for a Bateson Canine Welfare Grant for this project and to the Pastoral Breeds Health Foundation (UK) for pump priming funding. The Roslin Institute is supported by core funding from the Biotechnology and Biological Sciences Research Council (UK) [Grant numbers BB/J004235/1, BB/J004316/1, BB/P013732/1]. JR is funded by Fight for Sight (UK) [Grant number 1590/1591]. VT-R is funded by a CONACYT

(Mexico) international studentship. KS is supported by the Mater Foundation (Australia). We would like to thank all the Border Collie owners and breeders who have contributed samples and information to this investigation and the Pastoral Breeds Health Foundation for continuing support and encouragement during the course of this project. We are grateful to Dr Alan Wilton (now deceased) and Dr Barbara Zangerl for initiating and supporting the project.

Author contributions

KMS, CAP and LLF conceived the study. AJC, LLF and KMS curated and prepared the DNA samples. OM, SB and LLF performed initial genetic analysis. LLF and CAP performed the SNP analysis. CAP and SJP performed the bioinformatics analysis of the genome wide sequencing. KMS and AJC designed, performed and analysed the *OLFML3* genotyping. AdeK and CW analysed the Animal Genetics samples. JJS analysed the data from the Dog Genome Consortium. KMS analysed the public gene expression data. JR, VT-R and JGDP created and analysed the chicken data. KMS, LLF and CAP drafted the text and all authors read and approved the final manuscript.

Supplemental Material

Supplemental Table S1. FANTOM5 samples used in analysis of gene expression.

Supplemental Figure S1. Expression of genes in the candidate region in the developing mouse eye

Supplemental Figure S2. Pedigrees of animals used for whole genome sequencing

Supplemental Figure S3. Expression of olfactomedin-like 3 in cells and tissues

A. Expression in mouse tissues and cell lines (<http://biogps.org>; probe 1448475_at)

- B. Expression in human tissues and cell lines (<http://biogps.org>; probe 218162_at)
- C. Expression in mouse myeloid cells (<http://www.immgen.org>, MFs, monocytes, neutrophils; probeset 10500808)

Supplementary Figure S4. Expression of olfactomedin family genes in the developing mouse eye (data from FANTOM5; <http://fantom.gsc.riken.jp/zenbu/>)

1. Asher L, Diesel G, Summers JF, McGreevy PD, Collins LM: **Inherited defects in pedigree dogs. Part 1: disorders related to breed standards.** *Vet J* 2009, **182**(3):402-411.
2. Fricker GV, Smith K, Gould DJ: **Survey of the incidence of pectinate ligament dysplasia and glaucoma in the UK Leonberger population.** *Vet Ophthalmol* 2016, **19**(5):379-385.
3. Plummer CE, Regnier, A., Gellatt, K.N.: **The canine glaucomas.** In: *Veterinary Ophthalmology*. Edited by Gellatt KN, 5th edn. Iowa: John Wiley & Sons Inc; 2013: 1050-1145.
4. Oliver JAC, Cottrell BC, Newton JR, Mellersh CS: **Gonioscopy in the dog: inter-examiner variability and the search for a grading scheme.** *J Small Anim Pract* 2017, **58**(11):652-658.
5. Wood JL, Lakhani KH, Read RA: **Pectinate ligament dysplasia and glaucoma in Flat Coated Retrievers. II. Assessment of prevalence and heritability.** *Vet Ophthalmol* 1998, **1**(2-3):91-99.
6. Pearl R, Gould D, Spiess B: **Progression of pectinate ligament dysplasia over time in two populations of Flat-Coated Retrievers.** *Vet Ophthalmol* 2015, **18**(1):6-12.
7. Oliver JA, Ekiri A, Mellersh CS: **Prevalence of pectinate ligament dysplasia and associations with age, sex and intraocular pressure in the Basset hound, Flatcoated retriever and Dandie Dinmont terrier.** *Canine Genet Epidemiol* 2016, **3**:1.
8. Oliver JA, Ekiri AB, Mellersh CS: **Pectinate ligament dysplasia in the Border Collie, Hungarian Vizsla and Golden Retriever.** *Vet Rec* 2017, **180**(11):279.
9. Ekesten B, Narfstrom K: **Correlation of morphologic features of the iridocorneal angle to intraocular pressure in Samoyeds.** *Am J Vet Res* 1991, **52**(11):1875-1878.
10. Purcell S, Neale B, Todd-Brown K, Thomas L, Ferreira MA, Bender D, Maller J, Sklar P, de Bakker PI, Daly MJ et al: **PLINK: a tool set for whole-genome association and population-based linkage analyses.** *Am J Hum Genet* 2007, **81**(3):559-575.

11. Zhou X, Stephens M: **Genome-wide efficient mixed-model analysis for association studies.** *Nat Genet* 2012, **44**(7):821-824.
12. Cebamanos L, Gray A, Stewart I, Tenesa A: **Regional Heritability Advanced Complex Trait Analysis for GPU and Traditional Parallel Architectures.** *Bioinformatics* 2014, **30**(8):1177-1179.
13. Li H, Durbin R: **Fast and accurate short read alignment with Burrows-Wheeler transform.** *Bioinformatics* 2009, **25**(14):1754-1760.
14. Li H, Handsaker B, Wysoker A, Fennell T, Ruan J, Homer N, Marth G, Abecasis G, Durbin R, **Genome Project Data Processing S: The Sequence Alignment/Map format and SAMtools.** *Bioinformatics* 2009, **25**(16):2078-2079.
15. Van der Auwera GA, Carneiro MO, Hartl C, Poplin R, Del Angel G, Levy-Moonshine A, Jordan T, Shakir K, Roazen D, Thibault J et al: **From FastQ data to high confidence variant calls: the Genome Analysis Toolkit best practices pipeline.** *Curr Protoc Bioinformatics* 2013, **43**:11 10 11-33.
16. Robinson JT, Thorvaldsdottir H, Winckler W, Guttman M, Lander ES, Getz G, Mesirov JP: **Integrative genomics viewer.** *Nat Biotechnol* 2011, **29**(1):24-26.
17. McLaren W, Gil L, Hunt SE, Riat HS, Ritchie GR, Thormann A, Flicek P, Cunningham F: **The Ensembl Variant Effect Predictor.** *Genome Biol* 2016, **17**(1):122.
18. Arner E, Daub CO, Vitting-Seerup K, Andersson R, Lilje B, Drablos F, Lennartsson A, Ronnerblad M, Hrydziuszko O, Vitezic M et al: Gene regulation. **Transcribed enhancers lead waves of coordinated transcription in transitioning mammalian cells.** *Science* 2015, **347**(6225):1010-1014.
19. Forrest AR, Kawaji H, Rehli M, Baillie JK, de Hoon MJ, Haberle V, Lassmann T, Kulakovskiy IV, Lizio M, Itoh M et al: **A promoter-level mammalian expression atlas.** *Nature* 2014, **507**(7493):462-470.

20. Summers KM, Hume DA: **Identification of the macrophage-specific promoter signature in FANTOM5 mouse embryo developmental time course data.** *J Leukoc Biol* 2017, **102**(4):1081-1092.
21. Lander ES, Botstein D: **Homozygosity mapping: a way to map human recessive traits with the DNA of inbred children.** *Science* 1987, **236**(4808):1567-1570.
22. Rodriguez-Sanchez IP, Garza-Rodriguez ML, Mohamed-Noriega K, Voruganti VS, Tejero ME, Delgado-Enciso I, Perez-Ibave DC, Schlabritz-Loutsevitch NE, Mohamed-Noriega J, Martinez-Fierro ML et al: **Olfactomedin-like 3 (OLFML3) gene expression in baboon and human ocular tissues: cornea, lens, uvea, and retina.** *J Med Primatol* 2013, **42**(3):105-111.
23. Zeng LC, Han ZG, Ma WJ: **Elucidation of subfamily segregation and intramolecular coevolution of the olfactomedin-like proteins by comprehensive phylogenetic analysis and gene expression pattern assessment.** *FEBS Lett* 2005, **579**(25):5443-5453.
24. Kato K, Sasaki N, Matsunaga S, Mochizuki M, Nishimura R, Ogawa H: **Possible association of glaucoma with pectinate ligament dysplasia and narrowing of the iridocorneal angle in Shiba Inu dogs in Japan.** *Vet Ophthalmol* 2006, **9**(2):71-75.
25. Gelatt KN, MacKay EO: **Prevalence of the breed-related glaucomas in pure-bred dogs in North America.** *Vet Ophthalmol* 2004, **7**(2):97-111.
26. Tomarev SI, Nakaya N: **Olfactomedin domain-containing proteins: possible mechanisms of action and functions in normal development and pathology.** *Mol Neurobiol* 2009, **40**(2):122-138.
27. Ikeya M, Kawada M, Nakazawa Y, Sakuragi M, Sasai N, Ueno M, Kiyonari H, Nakao K, Sasai Y: **Gene disruption/knock-in analysis of mONT3: vector construction by employing both in vivo and in vitro recombinations.** *Int J Dev Biol* 2005, **49**(7):807-823.
28. Schmitz S, Bindea G, Albu RI, Mlecnik B, Machiels JP: **Cetuximab promotes epithelial to mesenchymal transition and cancer associated fibroblasts in patients with head and neck cancer.** *Oncotarget* 2015, **6**(33):34288-34299.

29. Miljkovic-Licina M, Hammel P, Garrido-Urbani S, Lee BP, Meguenani M, Chaabane C, Bochaton-Piallat ML, Imhof BA: **Targeting olfactomedin-like 3 inhibits tumor growth by impairing angiogenesis and pericyte coverage.** *Mol Cancer Ther* 2012, **11**(12):2588-2599.
30. Pillai-Kastoori L, Wen W, Morris AC: **Keeping an eye on SOXC proteins.** *Dev Dyn* 2015, **244**(3):367-376.
31. Butovsky O, Jedrychowski MP, Moore CS, Cialic R, Lanser AJ, Gabriely G, Koeglsperger T, Dake B, Wu PM, Doykan CE *et al*: **Identification of a unique TGF-beta-dependent molecular and functional signature in microglia.** *Nat Neurosci* 2014, **17**(1):131-143.
32. Gosselin D, Skola D, Coufal NG, Holtman IR, Schlachetzki JCM, Sajti E, Jaeger BN, O'Connor C, Fitzpatrick C, Pasillas MP *et al*: **An environment-dependent transcriptional network specifies human microglia identity.** *Science* 2017, **356**(6344).
33. Hume DA, Perry VH, Gordon S: **Immunohistochemical localization of a macrophage-specific antigen in developing mouse retina: phagocytosis of dying neurons and differentiation of microglial cells to form a regular array in the plexiform layers.** *J Cell Biol* 1983, **97**(1):253-257.
34. Karlstetter M, Ebert S, Langmann T: **Microglia in the healthy and degenerating retina: insights from novel mouse models.** *Immunobiology* 2010, **215**(9-10):685-691.
35. Trejo-Reveles V, McTeir L, Summers K, Rainger J: **An analysis of anterior segment development in the chicken eye.** *Mech Dev* 2018.
36. Anholt RR: **Olfactomedin proteins: central players in development and disease.** *Frontiers in cell and developmental biology* 2014, **2**:6.
37. Stone EM, Fingert JH, Alward WL, Nguyen TD, Polansky JR, Sunden SL, Nishimura D, Clark AF, Nystuen A, Nichols BE *et al*: **Identification of a gene that causes primary open angle glaucoma.** *Science* 1997, **275**(5300):668-670.

38. Tamm ER, Russell P, Epstein DL, Johnson DH, Piatigorsky J: **Modulation of myocilin/TIGR expression in human trabecular meshwork.** *Invest Ophthalmol Vis Sci* 1999, **40**(11):2577-2582.
39. Tomarev SI, Wistow G, Raymond V, Dubois S, Malyukova I: **Gene expression profile of the human trabecular meshwork: NEIBank sequence tag analysis.** *Invest Ophthalmol Vis Sci* 2003, **44**(6):2588-2596.
40. Kim BS, Savinova OV, Reedy MV, Martin J, Lun Y, Gan L, Smith RS, Tomarev SI, John SW, Johnson RL: **Targeted Disruption of the Myocilin Gene (Myoc) Suggests that Human Glaucoma-Causing Mutations Are Gain of Function.** *Mol Cell Biol* 2001, **21**(22):7707-7713.
41. Paper W, Kroeber M, Heersink S, Stephan DA, Fuchshofer R, Russell P, Tamm ER: **Elevated amounts of myocilin in the aqueous humor of transgenic mice cause significant changes in ocular gene expression.** *Exp Eye Res* 2008, **87**(3):257-267.
42. Torrado M, Trivedi R, Zinovieva R, Karavanova I, Tomarev SI: **Optimedin: a novel olfactomedin-related protein that interacts with myocilin.** *Hum Mol Genet* 2002, **11**(11):1291-1301.
43. Funayama T, Mashima Y, Ohtake Y, Ishikawa K, Fuse N, Yasuda N, Fukuchi T, Murakami A, Hotta Y, Shimada N *et al*: **SNPs and interaction analyses of noelin 2, myocilin, and optineurin genes in Japanese patients with open-angle glaucoma.** *Invest Ophthalmol Vis Sci* 2006, **47**(12):5368-5375.
44. Holt R, Ugur Iseri SA, Wyatt AW, Bax DA, Gold Diaz D, Santos C, Broadgate S, Dunn R, Bruty J, Wallis Y *et al*: **Identification and functional characterisation of genetic variants in OLFM2 in children with developmental eye disorders.** *Hum Genet* 2017, **136**(1):119-127.