Type of article : technical report

Title :

Assessing precocious maturation in salmon using ultrasound imaging

Authors:

Marie Nevoux[1,2], Frédéric Marchand[2,3], Jean-Pierre Destouches[2,3], Guillaume Forget[1,2], Dominique Huteau[1,2], Julien Tremblay[2,3]

Affiliations:

[1] INRA, Agrocampus-Ouest, Ecology and Ecosystem Health, 65 rue de Saint-Brieuc, Rennes, France

[2] Management of Aquatic Ecosystems in Agricultural Watersheds, INRA, Agence Française pour la Biodiversité, Rennes, France

[3] INRA, Ecologie et Ecotoxicologie Aquatique, 65 rue de Saint-Brieuc, Rennes, France

Corresponding author:

Marie Nevoux,

ESE, Ecology and Ecosystem Health, Agrocampus Ouest, INRA, 35042 Rennes, France

Email: marie.nevoux@inra.fr

Phone: +33(0)2 23 48 52 35

Abstract

Salmonids are characterized by a large diversity of life histories, but their study is often limited by the imperfect observation of the true state of an individual in the wild. Challenged by the need to reduce uncertainty of empirical data, we have taken advantage of recent development in medical imaging techniques to assess precocious maturation in Atlantic salmon. We compared traditional phenotypic (external) examination and ultrasound (internal) examination and provided recommendations on fish handling and ultrasound image interpretation. By seeing the unseen, ultrasound imaging offers great opportunities for ecological studies in the wild.

Keywords

Atlantic salmon *Salmo salar*, ecology, empirical study, fisheries, individual heterogeneity, life history trait, maturation, ultrasound scan

Introduction

Long term monitoring of animal populations in the wild is of great interest for ecology and management (Clutton-Brock and Sheldon 2010). In a context of global changes, such long term monitoring program contributed to highlight major change in population composition, dynamics and abundance over the last decades (Parmesan 2006). Indeed, global changes trigger the need to predict population structure and abundance in the future. However, predictive models are difficult to parameterize and often return high level of uncertainty, which hinder their use by managers and policy makers. This is partly because field records are imperfect observation of the true state of an individual (Genovart et al. 2012). For instance, maturation status and sex is rarely known with certainty in fish monitoring programs. Thus, field studies are challenged by the need to reduce uncertainty in individual data.

Atlantic salmon (*Salmo salar*) is an anadromous species that reproduce in freshwater and migrate at sea to grow and undergo sexual maturation. However, in this and other salmonid species, some young males (parr) would mature precociously in freshwater (Fleming 1996). It is proposed that frequency-dependent selection, as affected by intensity of mate competition and environmental variability in growth opportunities, determines a polygenic threshold (Hutchings and Myers 1994). Mature male parrs attempt to 'sneak' access to mating with large anadromous females (Fleming 1996). They can contribute substantially to the reproduction (Morán et al. 1996) but as maturation seems to be traded against survival, mature parr have a low probability to smoltify (Buoro et al. 2010). The frequency of this alternative reproduction strategy is highly variable over time, space and age classes (Bagliniere and Maisse 1985; Myers et al. 1986), but precise quantification of this phenotype remain rare in empirical studies. Furthermore, precocious maturation is virtually ignored by stock assessment models and fisheries management in Atlantic salmon (e.g. ICES (2013)). This means that mature parrs are included neither in the stock nor in the recruitment figures. This might bias stock-recruitment relationships and underestimate freshwater survival and salmon production. For instance, Myers (1984) estimated that 60% of the stock of adult male salmon was lost due to precocious maturation. Caswell et al. (1984) demonstrated that the effect of reproduction by parr on population growth rate is always greater than that of adult reproduction. We suspect that this lack of consideration for secretive mature parrs owes to the complexity of salmon life cycle. This could also be partly due to the difficulty of quantifying the proportion of precocious maturation in wild salmon populations

In the field, precocious maturity in parr is traditionally assessed by pressing the abdomen of the fish to extract milt. However, not all mature male may be producing milt at the time of capture. Moreover, based on the general look of the fish, experienced fieldworkers sometimes suspect maturity in some individuals that do not excrete milt upon abdominal pressure. However,

researchers are often reluctant to use such expert opinion data in their analysis due to unknown accuracy and potential operator effect.

Ultrasound imaging, which gave rise to significant advances in human medicine, offer reliable visualization of internal organs. Ultrasound imaging is routinely used in aquaculture as provides an accurate, non-invasive, non-lethal method that is more accurate that visual methods, e.g. to determine gender or gonadal growth in fish (Novelo and Tiersch 2012). In adult salmon, although gonads of immature males may be difficult to discern, gonads of females are always visible and hence sexing is possible by deduction (Martin et al. 1983; Mattson 1991). However the ovary and testes of the juvenile (non mature) salmon seem difficult to identify (Martin et al. 1983).

The development of portable devices offer an opportunity to bring ultrasound machines out into the wild. In this paper, we describe how ultrasound scanner can enhance the range of biological traits that can be monitored in long-term salmonids population surveys. In particular, we assessed the maturation status of young salmon in the field using traditional phenotypic examination and ultrasound examination. We compare the two approaches by testing whether biological or operator related factors would affect the uncertainty in external phenotypic assessment of maturity in parr. Finally, we provided recommendation on fish handling and the interpretation of ultrasound images.

Material and methods

Salmon monitoring

Atlantic salmon monitoring takes place every year in September or October in the River Oir, Normandy, France (Marchand et al. 2018). Young individuals (parr) are captured using a standardized electrofishing protocol, they are placed in a light anesthetic, measured, weighed, scanned and returned to the river within 0.5 hour maximum of their capture. We assessed age through scale reading. In 2015, 2016, and 2017 we examined 850 salmon (366 parrs of age 0 and 484

parrs of age 1) for maturity using traditional phenotypic (external) approach and ultrasound imaging. We caught all parrs within a period of 8 days in early October. All the animal experimentation in this study was performed according to French legislation and under licence APAFIS-201602051204637.

Traditional phenotypic examination

First, the field operator assessed the maturation state of parr by gently pressing the side of the fish. The excretion of milt (sperm) is indicative of a mature male, while the absence of milt can be encountered in a maturing male whose gonad does not yet produce milt, an immature male, or a female (females are all immature at this stage). The field operator also reported that some fish *looks like* mature parr: they display phenotypic traits similar to those of mature fish (e.g. colour pattern, body shape) but they do not excrete milt. This phenotypic assessment rely less on a fixed set of quantifiable parameters than on a general and subjective appreciation of the fish, which is specific to each operator.

Ultrasound examination

Then, the ultrasound operator screened all salmon parr for precocious maturation using a portable ultrasound scanner M-Turbo (Sonosite) with a 5-10 MHz linear transducer. We selected the default setting for muscular examination. As water perfectly transmit ultrasounds, we do not need to use ultrasound transmission gel. We placed fish on their side in a tank of freshwater, and we operated the transducer in the water keeping the transducer 1-2cm above the belly. We produced sagittal images of the abdominal cavity, i.e. the transducer was oriented parallel to the lateral line. We directly assessed the maturation state of each individual from live images on the ultrasound monitor. Parrs were classified as mature when the gonad was detected, or immature when the gonad was not detected, assuming that the gonad would be too small at this stage. Images could be stored on the ultrasound machine and then exported on a USB memory stick for post-treatment.

Comparison of the two approaches

We compared the number of parrs that were recorded as mature or non-mature by one or the other approach. Then, we conducted a multivariate analysis to investigate which biological factor drove the probability that a mature male was producing milt at the time of capture. We tested the effect of year, age, body length in a generalized linear model (GLM) with a binomial distribution of errors. We also tested whether the probability to miss a mature but parr that does not produce milt was affected by age, body length, operator identity and time of the day (testing for operator tiredness). We did not consider the date of capture because of the low variability in this variable. All models were run in R (R Development Core Team 2004).

Results and discussion

Ultrasound assessment of precocious maturity

The trained ultrasound operator conducted ultrasound examination for maturation assessment in ca. 5 seconds. In immature individuals, we can identify the liver, the stomach, caecas and the intestine (Figure 1a). Note that all internal organs appear more clearly on the live images, during ultrasound examination, than on frozen images. Nevertheless, the heterogeneous filling and uneven granularity of the abdominal cavity are diagnostic, as well as the concave shape of the cavity, which appear depressed on both sides. In mature parr (precocious males), as gonads virtually fill the whole cavity, ultrasound images depict a homogeneous and finely granulated pattern (Figure 1b, c). Digestive organs are hardly visible and the shape of the cavity is convex. In mature males that does not produce milt (Figure 1b), gonads appear less developed and fill the cavity to a lesser extent than in males producing milt (Figure 1c), which is consistent with a lower degree of maturity in the former. Interestingly, ultrasound imaging provides an objective description of maturation status in males that did not produce milt (Figure 1b) and the ones that produced milt (Figure 1c). It can also discriminate between truly mature parr from well-fed individuals, which the operator can mistakenly confuse with mature male because of their round belly.

150

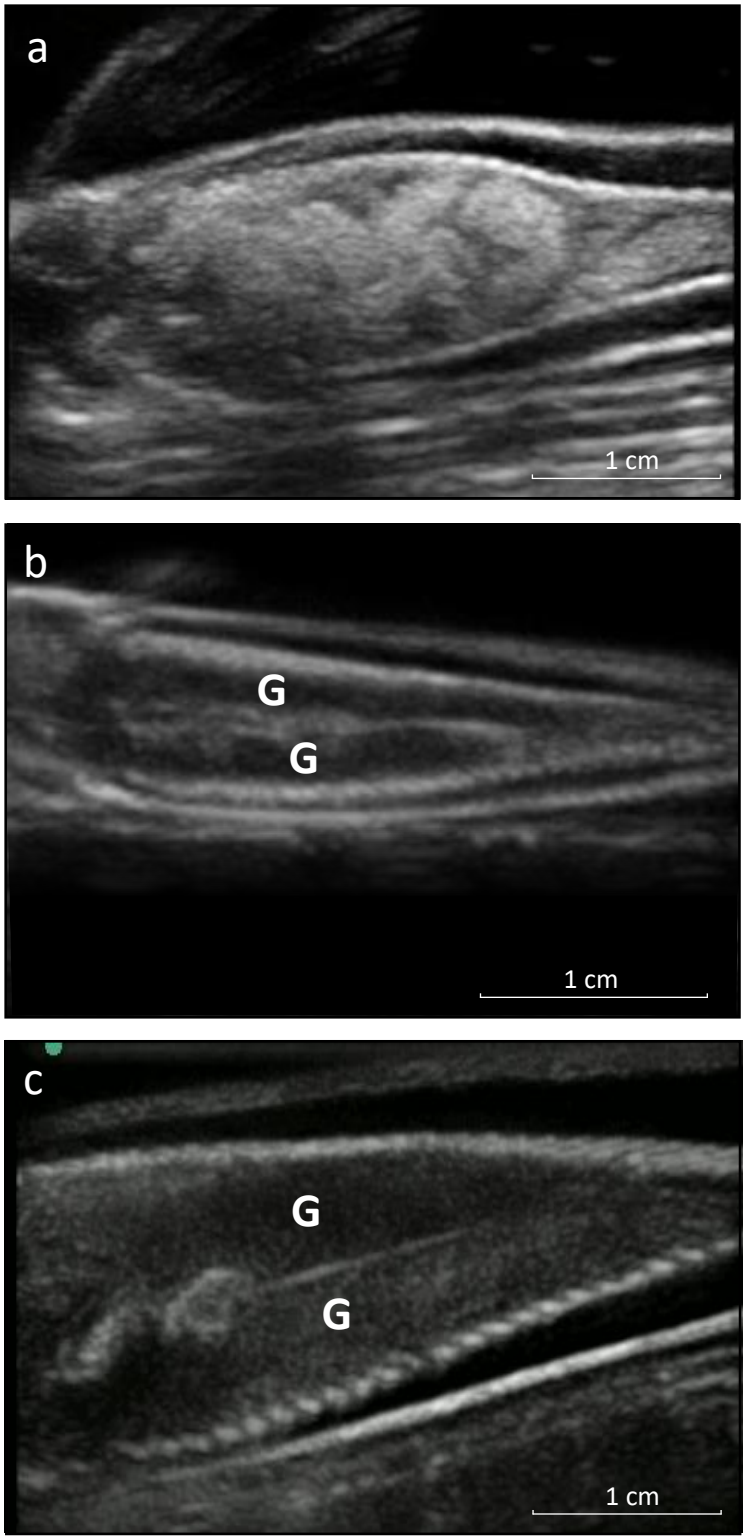

151

152 Figure 1. Assessing maturity in salmon parr using ultrasound imaging: a) immature one year old parr,

153 b) mature young of the year parr that did not produce milt (precocious male), and c) mature and

154 year old parr that produced milt (precocious male) in River Oir. On all images, the head of the fish is

155 on the left but not shown, the left and right flanks are situated on the lower and upper part of the
156 image, respectively. Gonads are identified with a “G” letter.
157
158 Comparison of phenotypic and ultrasound methods
159 On average 33.4% of the mature male were not producing milt. The probability to produce milt
160 increased with age (P = 0.025) and body length (P = 0.041), although this length effect tend to be
161 weaker in older parrs (age * length: P = 0.055). We also detected a strong year effect (P < 0.001),
162 which suggests that environmental factors influence the level of maturation of parr at the time of
163 capture.
164
165 In our study, the maturation state of 106 individuals was uncertain. However, following ultrasound
166 examination, we found that 89.6 % of those parrs that looked like mature parrs were actually
167 mature. This result acknowledged the high level of expertise of our trained operators to assess the
168 maturation state of parr from external phenotypic examination. In total, the field operator did not
169 detect 5.6 % of the mature males (i.e. the maturity was not confirmed nor suspected). This
170 probability differed between the two operators (P = 0.008), which point out to the difficulty of
171 assessing parr maturation state from external examination in the field in a fully reliable and
172 replicable manner. None of the other variable had a significant effect.
173
174 The ultrasound operator missed 2.7% of the males producing milt (the sample size is too small to
175 conduct multivariate analysis). This result pointed out that ultrasound imaging is nevertheless
176 subject to a low degree of uncertainty in maturity assessment. The interpretation of ultrasound
177 images requires a good training to improve the accuracy of the information. We also recommend
178 that all images would be examined and interpreted by two operators.
179

Table 1. Comparison of the number of records using external phenotypic observation (rows) and ultrasound imaging (columns) to assess maturation in parr.

Phenotype \ ultrasound	Gonad detected with ultrasound	Gonad not detected with ultrasound
Parr producing milt	221	6
Parr not producing milt that looks like a mature parr	95	11
Parr not producing milt that looks like a non-mature parr	19	498

Conclusion

By seeing the unseen, ultrasound imaging offer great opportunities for ecological studies in the wild. As illustrated in this paper, key phenotypic traits become accessible and help better characterize individual's true biological state. Ultrasound imaging is an accessible, easily transferable and replicable approach to investigate precocious maturity in parr as it relies on key diagnostic features. However, the accuracy and efficiency of the ultrasound examination will depend on the skill of the operator. Indeed, some training is required to operate the transducer in a fluent way and navigate between different anatomic layers. In this regard, we recommend good knowledge of the internal structure for the species of interest as a prerequisite. This will ensure a quick examination and thus minimize the impact on fish wellbeing. This will also improve the quality of the images and minimize misinterpretation issue.

References

Bagliniere, J.L., and Maisse, G. 1985. Precocious maturation and smoltification in wild Atlantic salmon in the Armorican massif, France. Aquaculture **45**(1): 249–263. doi:10.1016/0044-8486(85)90274-1.

Buoro, M., Prévost, E., and Gimenez, O. 2010. Investigating Evolutionary Trade-Offs in Wild Populations of Atlantic Salmon (*Salmo salar*): Incorporating Detection Probabilities and Individual Heterogeneity. Evolution **64**(9): 2629–2642. doi:10.1111/j.1558-5646.2010.01029.x.

Caswell, H., Naiman, R.J., and Morin, R. 1984. Evaluating the consequence of reproduction in complex salmonid life cycles. Aquaculture **43**: 123–134.

Clutton-Brock, T., and Sheldon, B.C. 2010. Individuals and populations: the role of long-term, individual-based studies of animals in ecology and evolutionary biology. Trends Ecol. Evol. **25**(10): 562–573.

Fleming, I.A. 1996. Reproductive strategies of Atlantic salmon: ecology and evolution. Rev. Fish Biol. Fish. **6**(4): 379–416. doi:10.1007/BF00164323.

Genovart, M., Pradel, R., and Oro, D. 2012. Exploiting uncertain ecological fieldwork data with multi-event capture–recapture modelling: an example with bird sex assignment. J. Anim. Ecol.: no-no. doi:10.1111/j.1365-2656.2012.01991.x.

Hutchings, J.A., and Myers, R.A. 1994. The evolution of alternative mating strategies in variable environments. Evol. Ecol. **8**(3): 256–268.

ICES. 2013. Report of the Working Group on North Atlantic Salmon (WGNAS). Copenhagen, Denmark.

Marchand, F., Azam, D., Delanoë, R., Destouches, J.-P., Tremblay, J., Baglinière, J.-L., Nevoux, M., Prévost, E., and Azam, D. 2018. Abundances and biological traits of fish sampled by electrofishing (except specific abundance indices) on the River Oir since 1988 (France). doi:10.15468/yaikgn.

Martin, R.W., Myers, J., Sower, S.A., Phillips, D.J., and Mcauley, C. 1983. Ultrasonic Imaging, a Potential Tool for Sex Determination of Live Fish. North Am. J. Fish. Manag. **3**(3): 258–264. doi:10.1577/1548-8659(1983)3<258:UIAPTF>2.0.CO;2.

Mattson, N.S. 1991. A new method to determine sex and gonad size in live fishes by using ultrasonography. J. Fish Biol. **39**(5): 673–677. doi:10.1111/j.1095-8649.1991.tb04397.x.

Morán, P., Pendás, A.M., Beall, E., and García-Vázquez, E. 1996. Genetic assessment of the reproductive success of Atlantic salmon precocious parr by means of VNTR loci. Heredity **77**(6): 655–660. doi:10.1038/hdy.1996.193.

Myers, R.A. 1984. Demographic Consequences of Precocious Maturation of Atlantic Salmon (Salmo salar). Can. J. Fish. Aquat. Sci. **41**(9): 1349–1353. doi:10.1139/f84-165.

Myers, R.A., Hutchings, J.A., and Gibson, R.J. 1986. Variation in Male Parr Maturation Within and Among Populations of Atlantic Salmon, *Salmo salar*. Can. J. Fish. Aquat. Sci. **43**(6): 1242–1248. doi:10.1139/f86-154.

Novelo, N.D., and Tiersch, T.R. 2012. A Review of the Use of Ultrasonography in Fish Reproduction. North Am. J. Aquac. **74**(2): 169–181. doi:10.1080/15222055.2012.672370.

Parmesan, C. 2006. Ecological and evolutionary responses to recent climate change. Annu. Rev. Ecol. Evol. Syst. **37**(1): 637–669.

R Development Core Team. 2004. R: A language and environment for statistical computing. R Foundation for Statistical Computing, Vienna, Austria. Available from http://www.R-project.org.