bioRxiv preprint doi: https://doi.org/10.1101/432328; this version posted October 1, 2018. The copyright holder for this preprint (which was not certified by peer review) is the author/funder, who has granted bioRxiv a license to display the preprint in perpetuity. It is made available under aCC-BY 4.0 International license.

APAP–induced organ toxicity in rats: The prophylactic role of *Acrocarpus fraxinifolius*

Eman A. Abd El-Ghffar*[1]; Alaa Barakat[2] and Ihab K. Mohamed[1]

[1]*Department of Zoology, Faculty of Science, Ain Shams University, Cairo, Egypt*

[2]*Department of Biochemistry and Biotechnology, Faculty of Pharmacy, Heliopolis University, Cairo, Egypt.*

***Correspondence**

Dr. Eman A. Abd El-Ghffar, e-mail: eman_a@sci.asu.edu.eg

APAP–induced organ toxicity in rats: The prophylactic role of *Acrocarpus fraxinifolius*

Abstract

APAP (N-acetyl-p-aminophenol) is used over-the-counter analgesic and anti–pyretic drug. APAP overdose can seriously damage several organs. *Acrocarpus fraxinifolius* Wight and Arn leaves (AFL) family Fabaceae is a medicinal tree species native to Africa and Asia. Traditionally, AFL is used in the prevention/treatment of liver and kidney damages. This study investigates the possible protective effects of AFL *n*-hexane extract (nHEAFL) against the APAP–induced organ toxicity in adult male Wistar albino rats. Rats were randomly divided into four groups. Group, I was the healthy control group that received placebo, group II (nHEAFL 500): rats received nHEAFL (500 mg/kg, p.o), group III (APAP+vehicle): rats received APAP (750 mg/kg, p.o) for 7 days. Group IV (nHEAFL 500+ APAP): rats pre-treated with nHEAFL (500 mg/kg, p.o) before inducing the organs damage in the last 7 days by APAP. Twenty-four hrs after last administration of APAP, the rats were sacrificed. APAP–induced a significant body weight loss, with the rise in serum liver markers (ASAT & ALAT), urea, uric acid, creatinine and renal/splenic/cardiac MDA, as well as with a reduction of cellular GSH, GR, GPx, SOD, and CAT activities. nHEAF showed a remarkable organs protective effect against APAP as evidenced by reduction of serum cellular toxicity and cellular lipid peroxidation, as well as enhanced cellular anti–oxidant defense system in renal/splenic/cardiac tissues. These findings suggest a potential protective role of AFL against APAP–induced organ toxicity in rats.

bioRxiv preprint doi: https://doi.org/10.1101/432328; this version posted October 1, 2018. The copyright holder for this preprint (which was not certified by peer review) is the author/funder, who has granted bioRxiv a license to display the preprint in perpetuity. It is made available under aCC-BY 4.0 International license.

Keywords: Leguminosae, anti–oxidants, heart, mundane, oxidative stress, paracetamol, pink cedar, shingle tree, spleen.

Abbreviations:

AFL, *Acrocarpus fraxinifolius leaves*; ALAT, Alanine aminotransferase; APAP, N-acetyl-p-aminophenol; ASAT, Aspartate aminotransferase; CAT, Catalase; COX, Cyclooxygenases; GR, Glutathione reductase; GSH, Reduced glutathione; GPx, Glutathione peroxidase; MDA, Malondialdehyde; NAPQI, N-acetyl-p-benzoquinoneimine; nHEAFL. AFL *n*-hexane extract; NSAIDs, Nonsteroidal anti-inflammatory drugs.

bioRxiv preprint doi: https://doi.org/10.1101/432328; this version posted October 1, 2018. The copyright holder for this preprint (which was not certified by peer review) is the author/funder, who has granted bioRxiv a license to display the preprint in perpetuity. It is made available under aCC-BY 4.0 International license.

Introduction

Nonsteroidal anti–inflammatory drugs (NSAIDs) are a heterogeneous class that non-selective/selective inhibitors for cyclooxygenase (at least two isoforms: COX1 and COX1). Commonly prescribed for their NSAIDs (such as: aspirin, paracetamol, ibuprofen, naproxen, and diclofenac) are extensively used for the relief of pain, fever and treatment of inflammatory conditions [1,2]. The common mechanism of these drugs is the ability to decrease prostaglandin synthesis by inhibiting COX (COX also known as prostaglandin-endoperoxide synthase). NSAIDs vary in their relative inhibitory effects on COX-1 and COX-2. There are worried that the COX-2 inhibitors may increase cardiovascular diseases [3]. The overdose of NSAIDs is associated with an increased toxicity. Also, this toxicity can lead to multiple complications, and may be result in death.

N-acetyl-p-aminophenol (APAP), also known as paracetamol or acetaminophen, is a non-prescription drug used as an analgesic, and anti–pyretic drug globally, considered safe and effective at therapeutic doses. APAP toxicity is one of the main causes of poisoning world-wide. Several studies reported that excessive use or overdose of APAP can damage several organs (especially the liver: represents the site of formation of the toxic metabolites, and the kidney: represents the site of its clearance) and even death [4,5]. Its toxicity is mediated by the activity of its reactive metabolite (N-acetyl-p-benzoquinoneimine, NAPQI), that generated via cytochrome P450 in liver. NAPQI is detoxified by the antioxidant effects of intracellular glutathione (GSH). Thus, an overdose of APAP cause depletion of cellular GSH. Therefore, it led to a reduced GSH capacity to detoxify NAPQI. Elevation of NAPQI mediates oxidative damage. This subsequently enhances cellular injuries and organ dysfunction [6]. Other studies reported that acute renal damage/failure can occur by overdose APAP even in the absence of liver damage/failure [6,7].

Several studies reported that APAP exerts acute and/or chronic hepato–toxic, nephro–toxic effects, gastrointestinal complications and hyperplasia of splenic tissue as well as cardio–toxicity

bioRxiv preprint doi: https://doi.org/10.1101/432328; this version posted October 1, 2018. The copyright holder for this preprint (which was not certified by peer review) is the author/funder, who has granted bioRxiv a license to display the preprint in perpetuity. It is made available under aCC-BY 4.0 International license.

[1,2,6,8-12]. 75% of blood advent to the liver arrives directly from gastro-intestinal organs, and then goes to the spleen by portal veins that bring drugs as foreign substances and xenobiotics in near-undiluted form. Following tissue injury, splenic monocytes enter the circulation migrating to inflammatory sites. These splenic monocytes differentiate into macrophages, that participate in pro/anti–inflammatory responses [11]. In dogs, the toxic effects of APAP include hepatic damage, kidney failure and serious hematologic disorders as Heinz bodies formation and hemoglobin damage (non-functioning hemoglobin) [9,13].

Medicinal plants such as Caesalpinieae may be play a significant role in both cases of disease conditions and as a possible material for maintaining health. So, Caesalpinieae (9 subtribes that have more than 47 genera) have a spectrum of biological activities including anti–oxidant, anti–inflammatory, anti–tumor, anti–diabetic, anti–fungal, anti–bacterial, hepato–protective, gastro–protective, analgesic, anti–arthritic, anti–filarial, anti–malarial, anthelmintic, amoebicidal, diuretic, anti–psoriatic, anti–estrogenic, anti–fertility, wound–healing, anxiolytic, cardio–protective, immune-modulatory, anti–HIV [2,14-18].

Acrocarpus fraxinifolius leaves (AFL), Fabaceae family and Caesalpiniaceae subfamily, is a native wide spread tree worldwide especially in Africa and Asia. Also, it is distributed in the tropical countries including Egypt. It common name pink cedar, mundani or shingle tree [2,15]. The extracts of the plant were reported to have anti–diabetic, anti–proliferative, anti–inflammatory, anti–oxidant, and hepato–protective activities *in vivo* [2,14,17,19,20] as well as antitumor activity *in vitro* [16]. Until now, there is not enough scanty information on the protective effect of nHEAFL on oxidative stress induced by APAP in some tissues like kidney, spleen and heart. So, this study was designed to investigate the possible protective activity of nHEAFL, may be for the first time, against APAP–induced organs toxicity (especially kidney, spleen and heart) in male albino rats. At the same time, it investigated any side effects caused by nHEAFL in healthy normal albino rats.

bioRxiv preprint doi: https://doi.org/10.1101/432328; this version posted October 1, 2018. The copyright holder for this preprint (which was not certified by peer review) is the author/funder, who has granted bioRxiv a license to display the preprint in perpetuity. It is made available under aCC-BY 4.0 International license.

Materials and Methods

Chemicals

APAP was purchased from Sanofi-Aventisegypts.A.E. (El Sawah, El Amiriya, Cairo, Egypt). The kits used for biochemical measurements were all purchased from Bio-diagnostic Company (Dokki, Giza, Egypt).

Preparation of nHEAFL

AFL were prepared by following the previous method [2,20]. Briefly, two kg powder of AFL was soaked in methanol (80%) for four days then filtered. The filtrate was completely evaporated (*in vacuo* at ≈ 55 °C) till complete dryness. The dried extract was further successively fractionated with *n*-hexane (nH). The nHEAFL was evaporated *in vacuo* until dryness to give fifty grams of a sticky dark greenish material. nHEAFL obtained was preserved in a sterile glass container (4°C) until further use.

Animals

Adult male Wistar albino rats weighing between 130-140gm were purchased from the Animal Breeding House of the National Research Centre (Dokki, Cairo, Egypt). The animals were housed in polypropylene cages in well-ventilated animal room (Zoology Department, Faculty of Science, Ain Shams University) and fed with pellet diet (Agricultural-Industrial Integration Company, Giza, Egypt) and tap water *ad libitum*. The animals (male rats) were acclimatized for one week before to the start of experiments. All experimental rats were humanely-treated (accordance with WHO guideline for animal care) and the design of this study was approved by the Ain Shams University Research Ethics Committee.

Experimental design & treatment schedule

bioRxiv preprint doi: https://doi.org/10.1101/432328; this version posted October 1, 2018. The copyright holder for this preprint (which was not certified by peer review) is the author/funder, who has granted bioRxiv a license to display the preprint in perpetuity. It is made available under aCC-BY 4.0 International license.

Rats were divided into four groups (n = 6), i.e., Group I (healthy control group): rats received orally distilled water only for 21 days; Group II (nHEAFL 500): rats received nHEAFL only (500 mg/kg b.wt, p.o) for 21 days. The selected dose of nHEAFL was based on Abd El-Ghffar et al. [2] and Alaa [20] who showed the hepato–protective effects of nHEAFL on the APAP–induced hepato–toxicity. Group III (APAP + vehicle): rats received orally distilled water then the animals received APAP (750 mg/kg b.wt; p.o) in the last 7 days to induced oxidative stress in organs [6]; and Group IV (nHEAFL 500 + APAP): rats received orally nHEAFL for 21 days then treated with APAP in the last 7 days.

Blood & tissues sampling

Animals were sacrificed after the last administration dose after an overnight fast (on day 22). The blood was collected into tubes with EDTA (for complete blood picture analysis) or without EDTA (for serum markers of cellular toxicity). The kidney, spleen and heart were separated out of the body, cleaned, and weighed then homogenized in 5mL cold buffer (0.5 g of Na_2HPO_4 and 0.7 g of NaH_2PO_4 per 500mL deionized water, pH 7.4) per gram tissue. Then, the homogenates were centrifuged (15 min/4000 rpm/4°C); and the obtained supernatants were divided into aliquots and preserved at –80°C until used for evaluating the oxidant/anti–oxidant parameters.

Measurements

Body weight (gain or loss) and relative organs weight were calculated. Serum amino transaminases enzymes (ASAT and ALAT), urea nitrogen, creatinine and uric acid were estimated according to Reitman & Frankel [21], Vassault et al. [22], Young et al. [23] and Fossati et al. [24], respectively. The malondialdehyde (MDA), superoxide dismutase (SOD), glutathione peroxidase (GPx), glutathione reductase (GR), and reduced glutathione (GSH) in tissue homogenates were estimated by the spectrophotometric methods described by Ohkawa et al. [25], Nishikimi et al. [26], Paglia & Valentine

bioRxiv preprint doi: https://doi.org/10.1101/432328; this version posted October 1, 2018. The copyright holder for this preprint (which was not certified by peer review) is the author/funder, who has granted bioRxiv a license to display the preprint in perpetuity. It is made available under aCC-BY 4.0 International license.

[27], Goldberg & Spooner [28], and Beutler et al. [29], respectively. Red blood cell (RBC), hemoglobin (HGB), hematocrit (HCT), blood indices, white blood cell (WBC) and differential counts were determined by automated hematology analyzer (Hemat 8 analyzer; SEAC, Freiburg, Germany).

Statistical analysis

The results were expressed as mean values with their standard errors (SE). Data was analyzed using ANOVA, and the differences between groups were determined by Tukey's multiple comparison test using Graph Pad Prism. Differences at $P<0.05$ were considered statistically significant.

Results

In Fig 1, the body weight gain and relative kidney weight were significantly decreased and increased ($p < 0.05$-0.001), respectively, in APAP- intoxicated group in contrast to the control group. This was not accompanied by significant change in spleen and heart relative weights ($p>0.05$). Oral treatment of nHEAFL completely modulated the decrease in in the body weight loss ($p>0.05$; compared to the healthy control animals), and partially alleviated the increase in relative kidney weight ($p<0.05$/$p<0.001$; compared to the healthy/APAP intoxicated control animals, respectively).

Fig 1. Body weight (a) and organs weight (b) and relative organs weight (c) of control, nHEAFL 500 alone, APAP-only and nHEAFL500 plus APAP groups. Values are means (n = 6/group), with their SEM represented by vertical bars. nHEAFL: *n*-hexane extract of *Acrocarpus fraxinifolius* leaves; APAP: N-acetyl-p-aminophenol. ** p<0.05, ***p<0.001: compared with the healthy control group; ††$P<0.01$, †††$P<0.001$: compared with the APAP intoxicated group that received vehicle.

bioRxiv preprint doi: https://doi.org/10.1101/432328; this version posted October 1, 2018. The copyright holder for this preprint (which was not certified by peer review) is the author/funder, who has granted bioRxiv a license to display the preprint in perpetuity. It is made available under aCC-BY 4.0 International license.

There was a slight but not significant decrease (p>0.05) RBCs, Hb, and HCT in APAP-intoxicated group compared with control rats (Fig 2). In addition, granulocytes and agranulocytes were a slight but not significant increase (p>0.05) in APAP- intoxicated group compared with control rats. All these hematological parameters did not significantly change (p>0.05) in APAP treated with nHEAFL compared with the healthy/ APAP- intoxicated control rats (Fig 2).

Fig 2. Hematological parameters (a) and blood indices (b), differential granulocytes (c), differential agranulocytes, (d) and total agranulo- agranulocytes counts (e) of control, nHEAFL 500 alone, APAP-only and nHEAFL500 plus APAP groups. Values are means (n = 6/group), with their SEM represented by vertical bars. nHEAFL: *n*-hexane extract of *Acrocarpus fraxinifolius* leaves; APAP: N-acetyl-p-aminophenol, Hb: hemoglobin, HCT: hematocrit, MCH: mean corpuscular Hb, MCHC: mean corpuscular, Hb concentration, MCV: mean corpuscular volume, RBCs: red blood corpuscles.

Fig 3 revealed that the serum markers for cellular toxicity (serum ALAT, ASAT activities, urea, uric acid and creatinine levels) significantly increased (p<0.05 to p<0.001) in APAP- intoxicated group compared with the healthy control animals.

Fig 3. Serum markers for cellular toxicity (a&b) of control, nHEAFL 500 alone, APAP-only and nHEAFL500 plus APAP groups. Values are means (n = 6/group), with their SEM represented by vertical bars. nHEAFL: n- hexane extract of *Acrocarpus fraxinifolius* leaves; APAP: N-acetyl-p-aminophenol, LAT: alanine aminotransferase, ASAT: aspartate aminotransferase. ** p<0.05, **p<0.001, ***p<0.001: compared with the healthy control group; †P<0.05, †††P<0.001: compared with the APAP intoxicated group that received vehicle.

As shown in Fig 4, kidney/spleen/heart MDA and non-enzymatic/enzymatic anti–oxidant (GSH, GR, GPx, SOD and CAT) were significantly increased and decreased (p<0.001), respectively, in APAP- intoxicated group compared with the healthy control group. Oral treatment of nHEAFL completely modulated the increase in heart MDA (p>0.05) compared with the healthy/APAP-intoxicated control group; But, partially alleviated the increase/decrease in MDA and non-

bioRxiv preprint doi: https://doi.org/10.1101/432328; this version posted October 1, 2018. The copyright holder for this preprint (which was not certified by peer review) is the author/funder, who has granted bioRxiv a license to display the preprint in perpetuity. It is made available under aCC-BY 4.0 International license.

enzymatic/enzymatic anti–oxidant (p<0.05-0.001 to p<0.01-0.001) compared with the healthy/APAP-intoxicated control group, respectively.

Fig 4. Cellular oxidant and anti–oxidant markers (a-f) in kidney, spleen, and heart of control, nHEAFL 500 alone, APAP-only and nHEAFL500 plus APAP groups. Values are means (n = 6/group), with their standard errors (± SEM) represented by vertical bars. nHEAFL: n- hexane extract of *Acrocarpus fraxinifolius* leaves; APAP: N-acetyl-p-aminophenol, CAT: Catalase; GPx: Glutathione peroxidase; GR: Glutathione reductase; GSH: Reduced glutathione; MDA: malondialdhyde; SOD: Superoxide dismutase. ** p<0.05, **p<0.001, ***p<0.001: compared with the healthy control group; ††P<0.01, †††P<0.001: compared with the APAP intoxicated group that received vehicle.

All the above parameters measured in the present study were not significantly altered (p>0.05) in healthy-treated rats that received nHEAFL compared with the healthy control rats (Figs 1-4). Furthermore, the mortality rates in all groups that received nHEAFL were zero during the period of the study. Subsequently, no deleterious effects were detected for the dose of nHEAFL used in this study.

Discussion

APAP is now the most common drug in self-poisoning, with a high rate of morbidity and mortality [30]. The present study showed that over dose of APAP–induced deleterious effects on some organs (kidney, spleen and heart) as indicated by decreasing cellular anti–oxidant defense system (GSH, GR, GPX, SOD and CAT and increasing serum liver/kidney biochemical markers (ALAT, ASAT, urea, uric acid and creatinine) and cellular lipid peroxidation (MDA). The elevation in serum cellular toxicity markers are indicative of cellular leakage and loss the functional integrity of cell membranes [6,13,19,31,32]. The liver, kidney, spleen and heart are thought to form a toxic metabolite only when their GSH content depleted by APAP [4,11-13]. Where, APAP is metabolized to NAPQI (highly reactive free radicals) decreases the body's natural anti-oxidant GSH and can bind covalently to proteins (selenium-binding protein and glutamine synthetase) and unsaturated fatty acids of cell membranes, resulting in lipid peroxidation, cellular membrane disruption, depressed mitochondrial

bioRxiv preprint doi: https://doi.org/10.1101/432328; this version posted October 1, 2018. The copyright holder for this preprint (which was not certified by peer review) is the author/funder, who has granted bioRxiv a license to display the preprint in perpetuity. It is made available under aCC-BY 4.0 International license.

function and elevated cellular injury markers and initiates cell death. The loss in body weight caused by APAP was also reported by Abdul Hamid et al. [6] and Manimaran et al. [33] in rats treated with 105 and 750 mg APAP/kg b.w, respectively. Relative kidney weight was significantly increased in APAP- intoxicated group. On the other hand, spleen/heart relative weights in the APAP experimental model did not significantly change, most probably due to the short treatment duration of APAP toxicity. But, we observed disturbance in anti–oxidant defense system in renal, splenic and cardiac tissues of male rats.

Several studies suggested that myocardial injury may be occurs due to a similar mechanism which causes hepatic injury by APAP through its a toxic metabolite, (NAPQI). Where NAPQI may acts as a direct toxin on the myocardium [8,10,12]. These results are in line with the research work of Hinson et al. [4] who reported that hepatic injury resulted from APAP may be suggested to toxic reactive metabolites (NAPQI) and/or their acidic moiety that bind to possibly critical cellular proteins in the liver, kidney, spleen and cardiac tissue And this damage results in the alteration of lipid/protein structure/function, loss of functional integrity of cell membrane and causes tissue injury [34]. APAP can deplete sulfydryl-groups, which interferes with nitric oxide (NO) production, and may results in coronary ischemia [8,12]. In addition, APAP may also cause organs toxicity (like liver, kidney, heart and spleen) by mechanisms leading to the formation of reactive oxygen species (ROS) and reactive nitrogen species (RNS) such as superoxide anion ($O_2^{\bullet-}$), hydrogen peroxide (H_2O_2) and hydroxyl radical, nitric oxide and peroxynitrite [6, 32,35,36]. Such assumption was confirmed in the present study by the observed significant decrease in cellular non-enzymatic/enzymatic anti–oxidant and increase cellular lipid peroxidation in kidney, spleen and heart. In addition, this may explain the observed changes in the serum urea, uric acid and creatinine [6,36].

Hematological parameters are frequently used as indicators of health status. Current data revealed that administration of APAP had no significant changes in hematological parameters (RBCs,

bioRxiv preprint doi: https://doi.org/10.1101/432328; this version posted October 1, 2018. The copyright holder for this preprint (which was not certified by peer review) is the author/funder, who has granted bioRxiv a license to display the preprint in perpetuity. It is made available under aCC-BY 4.0 International license.

Hb, HCT, blood indices, total WBC, neutrophil, eosinophil, monocyte and lymphocyte counts), which suggest that the immune system have not been compromised or due to immune modulatory effects [34,37].

Pretreatment with nHEAFL produced partial protection against APAP induced organs toxicity (such as liver, kidney, spleen and heart) represented by significant reduction of serum cellular markers (ALAT, ASAT, urea, uric acid, and creatinine), cellular MDA concentration and significant elevation renal/splenic/cardiac anti-oxidants (GSH, GR, GPX, SOD and CAT) compared with non-treated APAP group. This finding may suggest nHEAFL's ability to restore the balance between generation and clearance of ROS and lipid peroxidation, and the stability of the function during organs injury [19,20]. Also, these modulations led to alleviate the loss in body weight gain [2] and relative kidney weight. This may be attributed to the fact that phenolic acids in AFL have anti–oxidant and free radical chelators/scavengers activities as with special impact over hydroxyl/peroxyl radicals, superoxide anions, and peroxynitrites [16].

Recently, bioactive phenolics such as brevifolin carboxylic acid, ellagic acid, gallic acid and methyl gallate were identified from the extract of AFL [16,17], and may be responsible for its radical scavenging activity [38].

Our previous studies have indicated that nHEAFL (500 mg/kg,p.o, for 7 to 21 days) plays an important role in improving GSH status and total anti–oxidant capacity in intoxicated rats with APAP [2,20]. In this study, the high level of GSH in response to nHEAFL may result from increased activity of cellular anti–oxidant enzymes and decreased cellular lipid peroxidation.

Higher activity in nHEAFL may be due to presence of α–tocopherol (an isoform of vitamin E and as an anti–oxidant agent), which has a powerful anti–oxidant activity in detoxifying free radicals, stabilization of the cell membrane and structure restoration [2]. α–Tocopherol may have inhibited the chain reactions of APAP–generated free radicals or scavenged the ROS before reaching its renal,

bioRxiv preprint doi: https://doi.org/10.1101/432328; this version posted October 1, 2018. The copyright holder for this preprint (which was not certified by peer review) is the author/funder, who has granted bioRxiv a license to display the preprint in perpetuity. It is made available under aCC-BY 4.0 International license.

splenic and cardiac targets. Furthermore, α–tocopherol stimulated the upregulation of endogenous cytochrome P3 (A4 and A5) which metabolize APAP into reactive metabolite NAPQI [2,39].

The Polyphenols, flavonoids, and anthocyanins are known to possess antioxidant activities (scavenging of free radicals), due to their several phenolic hydroxyl groups [40]. Recently, El-Kashak et al. [17] reported that AFL have very strong anti–oxidant effect due to presence of flavonoids (such as: quercetin–3–O–β–D–glucopyranoside, quercetin–3–O–α–L–rhamnopyranoside, myricetin-3–O–β–D–galactopyranoside and myricetin–3–O–α–L–rhamnopyranoside). Abd El-Ghffar et al. [2] reported that the phytochemical screening of nHEAFL afforded varieties of polyphenolic components; α-tocopherol (18.23%), labda-8 (20)-13-dien-15-oic acid (13.15%), lupeol (11.93%), phytol (10.95%) and squalene (7.19%). Also, it has been reported that nHEAFL contains flavonoids, tri–terpenoids, α–tocopherol and steroids [2] which exhibited strong anti–oxidant activity. Another scientific report indicated certain flavonoids, tri-terpenoids and steroids have the protective effect on hepatic tissue due to its anti–oxidant properties [41]. The presence of these compounds in nHEAFL may be responsible for the protective effect against APAP only induced organs toxicity in rats.

Abd El-Ghffar et al. [2] and Alaa [20] proved that the anti–oxidant and hepato–protective activities exerted by nHEAFL against APAP-induced oxidative damage was attributed to its active constituents such as lupeol, squalene, and phytol. Also, another study proved that lupeol from *Ficus pseudopalma* Blanco (Moraceae) extract has the anti–oxidant and hepato–protective activities against APAP-induced oxidative damage [42]. Regarding squalene Sivakrishnan & Muthu [43] and Zuhan et al. [44] reported about the promising hepato–protective effects of squalene isolated from *Albizia procera* (Roxb.) Benth (Mimosaceae) against APAP– and CCl_4–induced toxicity. It has been reported that phytol, which is an acyclic diterpene alcohol, acts as a precursor for vitamin E and K1 and it has anti–oxidant as well as anticancer activities [2,45]. Taking this fact with gained results we could suggest that the amount of exogenous polyphenolic diets increases, endogenous anti–oxidant defense system

bioRxiv preprint doi: https://doi.org/10.1101/432328; this version posted October 1, 2018. The copyright holder for this preprint (which was not certified by peer review) is the author/funder, who has granted bioRxiv a license to display the preprint in perpetuity. It is made available under aCC-BY 4.0 International license.

increase as well. Therefore, the medicinal anti–oxidant therapeutic will offers a promising way to prevent and/or treat the diseases induced by the excessive exposure to oxidative stress (ROS/NOS).

Finally, our study demonstrated that nHEAFL has important anti–oxidant effects as ability to scavenge ROS, inhibit lipid peroxidation as well as increase of anti–oxidant defense system in kidney, spleen, and heart tissue organs; which was attributed to presence of mainly α–tocopherol, terpenoidal and steroids compounds.

Conclusion

In our observations, we have concluded that nHEAFL has great value as a source of compounds for pharmaceutical applications. nHEAFL was found to be effective in protecting the liver, kidney, spleen and heart tissue from oxidative damage in animal models of APAP -induced organs toxicity. The possible mechanism by which nHEAFL exhibited significant protection against APAP-induced organs damage may be due to its anti–oxidant effect and its constituents such as α–tocopherol, terpenoidal, and steroids compounds. Additional experiments are necessary to confirm the mechanisms of action of nHEAFL and the it's protective role that plays important role in APAP–induced oxidative damage to these organs.

Competing interests: All authors declare that there is no conflict of interest relevant to this study. *The author(s) received no specific funding for this work.*

bioRxiv preprint doi: https://doi.org/10.1101/432328; this version posted October 1, 2018. The copyright holder for this preprint (which was not certified by peer review) is the author/funder, who has granted bioRxiv a license to display the preprint in perpetuity. It is made available under aCC-BY 4.0 International license.

Acknowledgments: The authors are grateful to Dr. Omayma Abd Elkarim Eldhshan, Associate Prof. of Pharmacognosy and Phytochemistry, Department of Pharmacognosy Faculty of Pharmacy, Ain-Shams University, Cairo, Egypt. for providing and preparing nHEAFL.

References

[1] Garcia RLA, Hernandez-Diaz S. The risk of upper gastrointestinal complications associated with non-steroidal antiinflammatory drugs, glucocorticoids, acetaminophen, and combinations of these agents. Arthritis Res. 2001; 3: 98-101.

[2] Abd El-Ghffar EA, El-Nashar HAS, Eldahshan OA., Singab A-NB. GC-MS analysis and hepatoprotective activity of the *n*-hexane extract of *Acrocarpus fraxinifolius* leaves against paracetamol-induced hepatotoxicity in male albino rats. Pharm Biol. 2016; 55: 44-449.

[3] Howard PA, Delafontaine P. Nonsteroidal anti-Inflammatory drugs and cardiovascular risk. Journal of the American College of Cardiology. 2004; 43:519-525.

[4] Hinson JA, Roberts DW, James LP. Mechanisms of acetaminophen-induced liver necrosis. Handbook of Experimental Pharmacology. 2010; 196: 369-405.

[5] McGill MR, Williams CD, Xie Y, Ramachandran A, Jaeschke H. Acetaminophen-induced liver injury in rats and mice: Comparison of protein adducts, mitochondrial dysfunction, and oxidative stress in the mechanism of toxicity. Toxicol Appl Pharmacol. 2012; 264: 387-394.

[6] Abdul Hamid Z, Budin SB, Hamid A, Husain K, Mohamed J. Nephroprotective effects of *Zingiber zerumbet* Smith ethyl acetate extract against paracetamol-induced nephrotoxicity and oxidative stress in rats. J Zhejiang Univ-Sci B (Biomed & Biotechnol). 2012; 13:176-185.

[7] Boutis K, Shannon M. Nephrotoxicity after acute severe acetaminophen poisoning in adolescents. Clin. Toxicol. 2001; 39:441-445.

[8] Armour A, Slater SD. Paracetamol cardiotoxicity. Postgrad Med J. 1993; 69:52-54.

[9] Salem SI, Elgayed SSA, El-Kelany WM, Abd El-Baky AA. Diagnostic studies on acetaminophen toxicosis in dogs. Global Veterinaria. 2010; 5: 72-83.

[10] Mehrpour O, Afshari R, Delshard P, Jalazaden M, Khodashenas M. Cardiotoxicity due to paracetamol overdose-A case study and review of the literature. Indian Journal of Forensic Medicine and Toxicology. 2011; 5: 31-34.

[11] Mandal M, Gardner CR, Sun R, Choi H, Lad S, Mishin V, Laskin JD, Laskin DL. The spleen as an extramedullary source of inflammatory cells responding to acetaminophen-induced liver injury. Toxicol Appl Pharmacol. 2016; 304:110-120.

[12] Ralapanawa U, Jayawickreme KP, Ekanayake EMM, Dissanayake DM. A study on paracetamol cardiotoxicity. BMC Pharmacology and Toxicology. 2016; 17:30-38.

[13] Satirapoj BMD, Lohachit PMD, Ruamvang TMD. Therapeutic dose of acetaminophen with fatal hepatic necrosis and acute renal failure. J Med Assoc Thai. 2017; 90: 1244-1247.

[14] Abou Zeid AH, Mohammed R, Soliman FM, Sleem AA, El-Dakrory YM. Galloyle derivatives and biological activities of *Acrocarpus fraxinifolius* weight and arn leaves. Planta Med. 2012; 78: 213-219.

[15] El-Nashar HAS, Eldahshan O, Singab AN. The Tribe Caesalpinieae (Fabaceae): An Updated Review on Pharmacological Aspects. Med Aromat Plants. 2015; 4:1-4.

bioRxiv preprint doi: https://doi.org/10.1101/432328; this version posted October 1, 2018. The copyright holder for this preprint (which was not certified by peer review) is the author/funder, who has granted bioRxiv a license to display the preprint in perpetuity. It is made available under aCC-BY 4.0 International license.

[16] El-Nashar HAS, Eldahshan O; Elshawi OE, Singab AN. Phytochemical investigation, antitumor activity, and hepatoprotective effects of *Acrocarpus fraxinifolius* leaf extract. Drug Dev Res. 2017; 78: 210-226.

[17] El-Kashak WA, Hamed AR, El-Raey M, Elshamy AI, Abd-Ellatef GF. Antiproliferative, anti–oxidant and antimicrobial activities of phenolic compounds from *Acrocarpus fraxinifolius*. Journal of Chemical and Pharmaceutical Research. 2016; 8:520-528.

[18] El-Rafie HM, Abou Zeid AH, Mohammed RS, Sleem AA. Bioactivities and phytochemical studies of *Acrocarpus fraxinifolius* Bark Wight and Arn. International Journal of Pharmacological and Pharmaceutical Sciences. 2018; 12: 793. dai:10.1999/1307-6892/72471.

[19] Abd El-Ghffar EA, Shehata SM. Anti–oxidant and anti-inflammatory effects of *Acrocarpus fraxinifolius* on hyperglycemia, hyperlipidemia and liver/kidney dysfunctions against alloxan induced Type 1 diabetes in rats. Indian J Trad knowl. 2018; 17: 223-232.

[20] Alaa B. Ameliorative effects of *Acrocarpus fraxinifolius* leaves extract against liver damage induced in wistar rats by acetaminophen. RJPBCS. 2018; 9: 153-161.

[21] Reitman S, Frankel S. A colorimetric method determination of serum GOT (glutamic oxalacetic transaminase) GPT (glutamic pyruvic transaminase) activity. Amer J Clin Pathol. 1975; 28:56-63.

[22] Vassault A, Grafmeyer D, Naudin C, Dumont G, Bailly M, Henny J. Protocol for the validation of methods. Ann Biol Clin. 1986; 44: 686-45.

[23] Young DS, Pestaner LC, Gibberman V. Effects of drugs on clinical laboratory tests. Clin Chem. 1975; 21:1D-432D.

[24] Fossati P, Prencipe L, Berti G. Use of 3,5-dichloro-2-hydroxybenzenesulfonic acid/4-aminophenazone chromogenic system in direct enzymic assay of uric acid in serum and urine. Clin Chem. 1980; 26: 227-231.

[25] Ohkawa H, Ohishi N, Yagi K. Assay for lipid peroxides in animal tissues by thiobarbituric acid reaction. Anal Biochem. 1979; 95: 351-358.

[26] Nishikimi M, Appaji N, Yagi K. The occurrence of superoxide anion in the reaction of reduced phenazine methosulfate and molecular oxygen. Biochem Biophys Res Commun. 1972; 46:849-854.

[27] Paglia DE, Valentine WN. Studies on the quantitative and qualitative characterization of erythrocyte glutathione peroxidase. J Lab Clin Med. 1967; 70: 158-169.

[28] Goldberg DM, Spooner RJ. In: Methods of Enzymatic Analysis (Bergmeyen, H.V. Ed.) 3rd edn. Vol 3, pp 258-265, Verlog Chemie, Deerfield beach, FI. 1983.

[29] Beutler E, Duron O, Kelly BM. Improved method for the determination of blood glutathione. J Lab Clin Med. 1963; 61:882-888.

[30] Sheen CL, Dillon DF, Bateman DN, Simpson KJ, Macdonald TM. Paracetamol toxicity: epidemiology, prevention and costs to the health-care system. QJM. 2002; 95:609-619.

[31] Inkielewicz-Stêpniak I, Knap N. Effect of exposure to fluoride and acetaminophen on oxidative/nitrosative status of liver and kidney in male and female rats. Pharmacological Reports. 2012; 64: 902-911.

[32] Ebaed SB, Shaltoot SA, Boutros M, Mohamed AS, Shehab MM. Melatonin versus N-acetylcysteine in acetaminophen induced hepatotoxicity & nephrotoxicity and in metabolic syndrome (Experimental Study). J Am Sci. 2016; 12:88-103.

[33] Manimaran A, Sarkar SN, Sankar P. Influence of repeated preexposure to arsenic on acetaminophen-induced oxidative stress in liver of male rats. Food Chem Toxicol. 2010; 48: 605-610.

bioRxiv preprint doi: https://doi.org/10.1101/432328; this version posted October 1, 2018. The copyright holder for this preprint (which was not certified by peer review) is the author/funder, who has granted bioRxiv a license to display the preprint in perpetuity. It is made available under aCC-BY 4.0 International license.

[34] Gomaa S. Adverse effects induced by diclofenac, ibuprofen, and paracetamol toxicity on immunological and biochemical parameters in Swiss albino mice. The Journal of Basic and Applied Zoology. 2018; 79:5. doi: 10.1186/s41936-018-0025-7.

[35] Abraham P. Oxidative stress in paracetamol-induced pathogenesis: (I) renal damage. Indian J Biochem Biophys. 2005; 42:59-62.

[36] Mazer M, Perrone J. Acetaminophen induced nephrotoxicity: Pathophysiology, clinical manifestations, and management. J Med Toxicol. 2008; 4:2-6.

[37] Oyedeji KO, Bolarinwa AF, Jeniran SS. Effect of paracetamol (acetaminophen) on haematological and reproductive parameters in male albino rats. Res J Pharmacol. 2013; 7: 21-25.

[38] Rosales-Castro M, Honorato-Salazar JA, Gonz-alez-Laredo RF. Anti–oxidant phenolic compounds of ethanolic and aqueous extracts from pink cedar (*Acrocarpus fraxinifolius* Whight & Arn.) bark at two tree ages. J Wood Chem Technol. 2015; 35:270-279.

[39] Landes N, Pfluger P, Kluth D, Birringer M, R€uhl R, B€ol GF, Glatt H, Brigelius-Flohe R. Vitamin E activates gene expression via the pregnane X receptor. Biochem Pharmacol. 2003; 65:269-273.

[40] Hatano T, Kagawa H, Yasuhara T, Okuda T. Two new flavonoids and other constituents in licorice root their relative astringency and radical scavenging effects. Chem Pharm Bull. 1988; 36: 2090-2097.

[41] El-Gendy AM. The beneficial effect of *Trifolium* flower extracts on paracetamol-intoxicated male rats. The Egyptian Journal of Hospital Medicine. 2012; 49: 771-780.

[42] Arimado J, Santiago L. The anti–oxidant and hepatoprotective activities of the ethyl acetate leaf extract of *Ficus pseudopalma* Blanco. Int J Pharmacog Phytochem Res. 2015; 7:1179-1189.

[43] Sivakrishnan S, Muthu AK. Evaluation of hepatoprotective activity of squalene isolated from *Albizia procera* against paracetamol induced hepatotoxicity on Wistar rats. World J Pharm Pharmaceut Sci. 2014; 3:1351-1362.

[44] Zuhan J, Jie J, Peijiang M, Yi Y, Jingjing H. Study of the antioxidative and hepatoprotective effects of squalene on acute liver injury mice induced by CCl_4. J Zhejiang Tradit Chin Med. 2015; 9:666-670.

[45] Oyugi DA, Ayorinde FO, Gugssa A, Allen A, Izevbigie EB, Eribo B. Biological activity and mass spectrometric analysis of Vernonia amygdalina fractions. J Biosci Tech. 2011; 2:287-304.

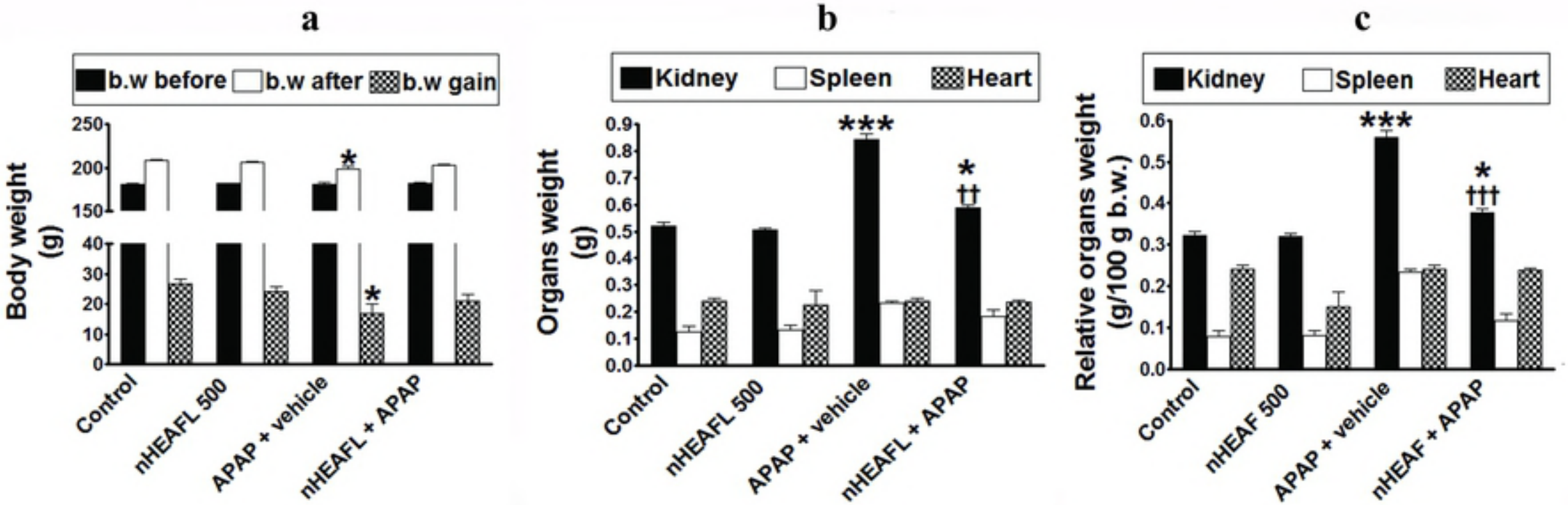
a
b.w before
b.w after
b.w gain
Body weight (g)
250
200
150
40
30
20
10
0
*
*
Control
nHEAFL 500
APAP + vehicle
nHEAFL + APAP
b
Kidney
Spleen
Heart
Organs weight (g)
0.9
0.8
0.7
0.6
0.5
0.4
0.3
0.2
0.1
0.0
***
*
††
Control
nHEAFL 500
APAP + vehicle
nHEAFL + APAP
c
Kidney
Spleen
Heart
Relative organs weight (g/100 g b.w.)
0.6
0.5
0.4
0.3
0.2
0.1
0.0
***
*
†††
Control
nHEAF 500
APAP + vehicle
nHEAF + APAP

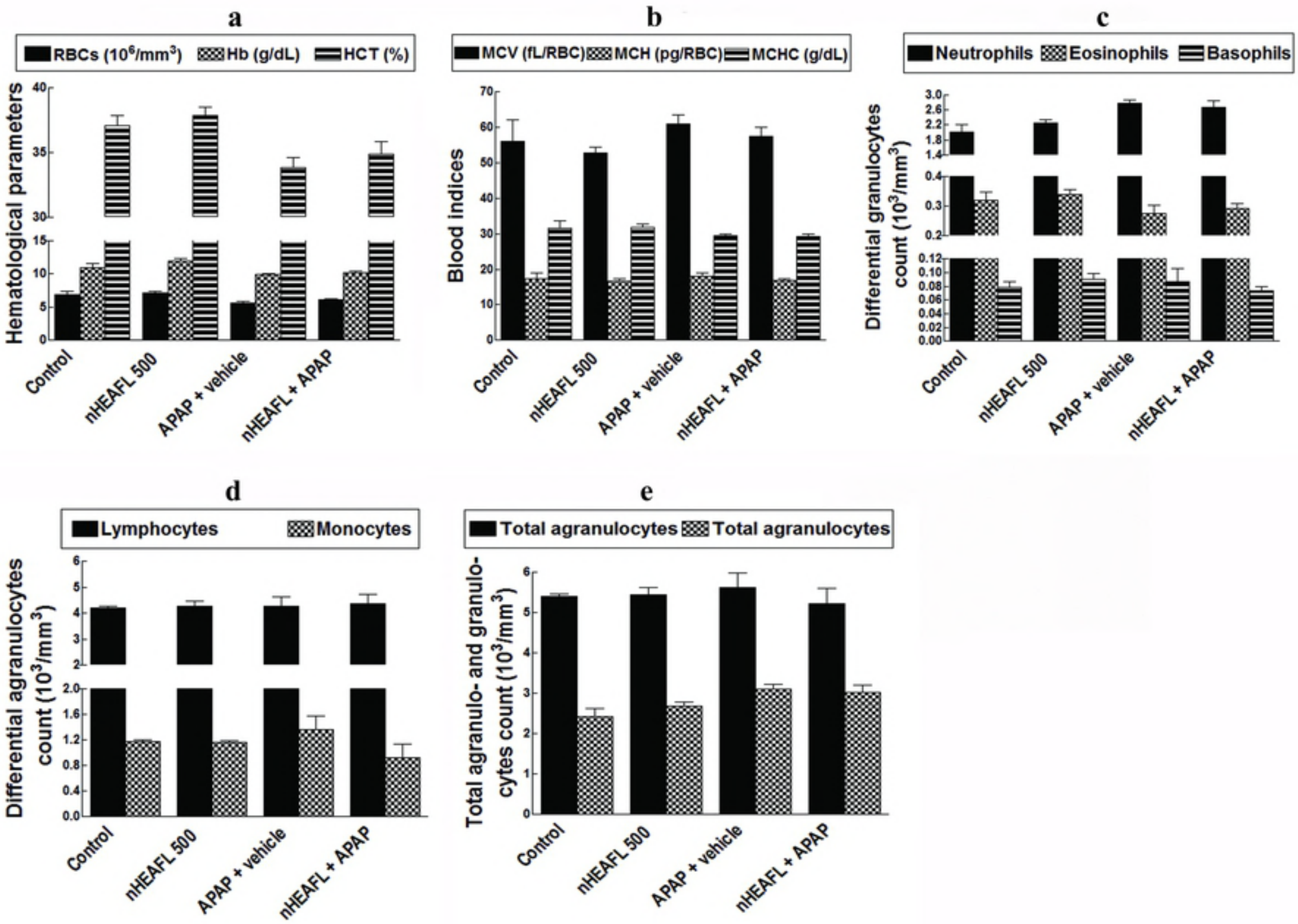
a
RBCs (10^6/mm^3)
Hb (g/dL)
HCT (%)
Hematological parameters
Control
nHEAFL 500
APAP + vehicle
nHEAFL + APAP
b
MCV (fL/RBC)
MCH (pg/RBC)
MCHC (g/dL)
Blood indices
Control
nHEAFL 500
APAP + vehicle
nHEAFL + APAP
c
Neutrophils
Eosinophils
Basophils
Differential granulocytes count (10^3/mm^3)
Control
nHEAFL 500
APAP + vehicle
nHEAFL + APAP
d
Lymphocytes
Monocytes
Differential agranulocytes count (10^3/mm^3)
Control
nHEAFL 500
APAP + vehicle
nHEAFL + APAP
e
Total agranulocytes
Total agranulocytes
Total agranulo- and granulo-cytes count (10^3/mm^3)
Control
nHEAFL 500
APAP + vehicle
nHEAFL + APAP

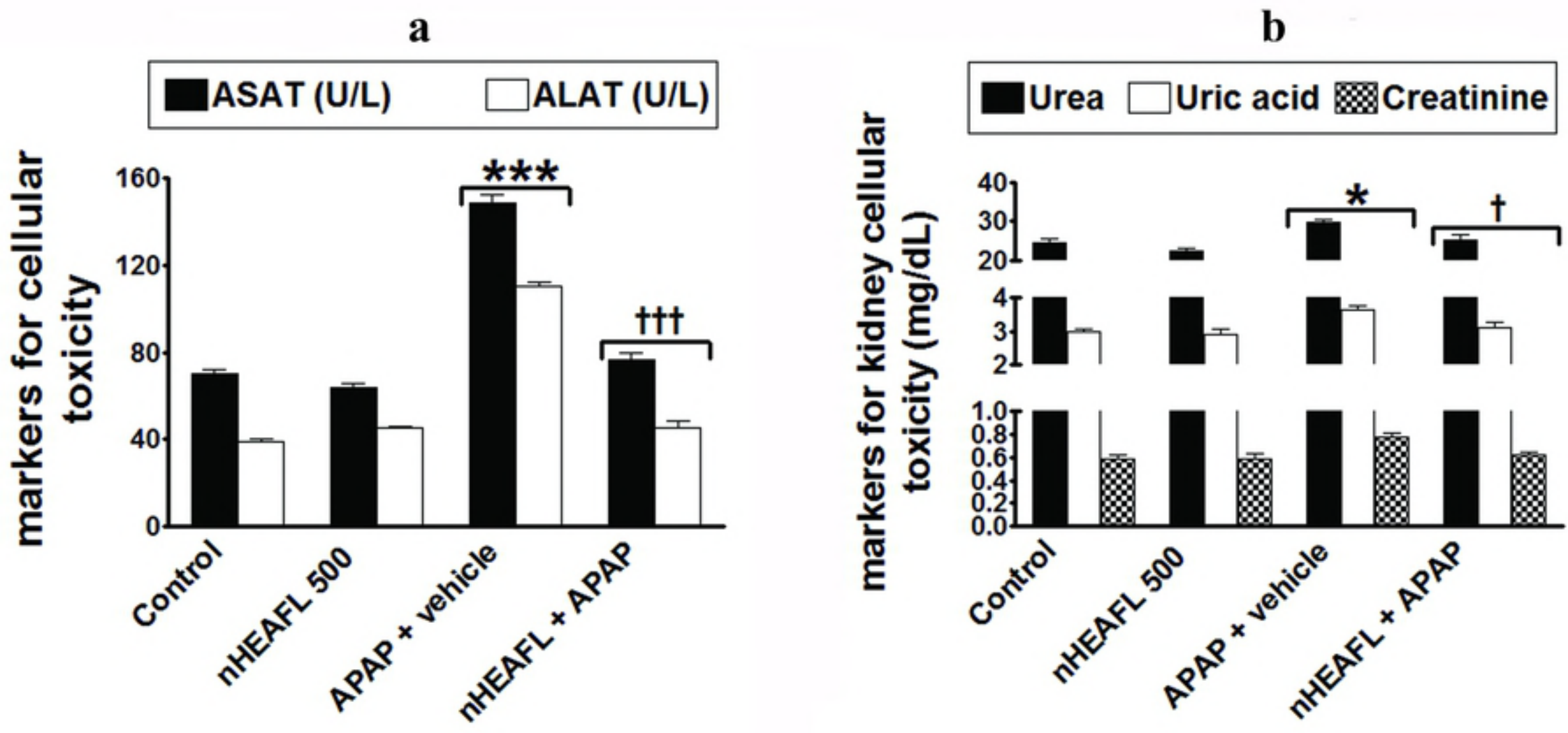
a
ASAT (U/L)
ALAT (U/L)
markers for cellular toxicity
160
120
80
40
0
***
†††
Control
nHEAFL 500
APAP + vehicle
nHEAFL + APAP
b
Urea
Uric acid
Creatinine
markers for kidney cellular toxicity (mg/dL)
40
30
20
4
3
2
1.0
0.8
0.6
0.4
0.2
0.0
*
†
Control
nHEAFL 500
APAP + vehicle
nHEAFL + APAP

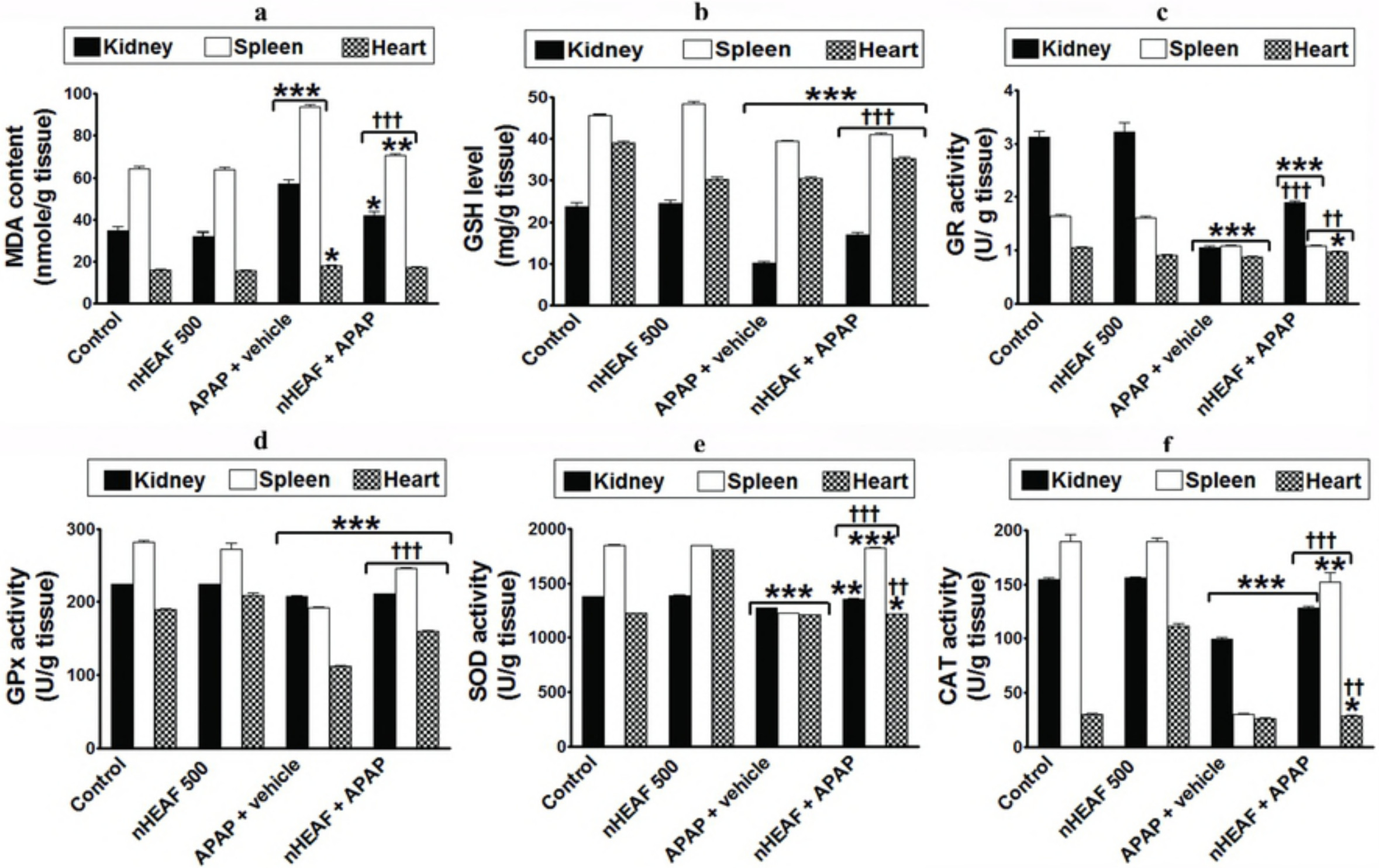
a
Kidney
Spleen
Heart
MDA content (nmole/g tissue)
0
20
40
60
80
100
***
†††
**
*
*
Control
nHEAF 500
APAP + vehicle
nHEAF + APAP
b
Kidney
Spleen
Heart
GSH level (mg/g tissue)
0
10
20
30
40
50
***
†††
Control
nHEAF 500
APAP + vehicle
nHEAF + APAP
c
Kidney
Spleen
Heart
GR activity (U/ g tissue)
0
1
2
3
4
***
***
†††
††
*
Control
nHEAF 500
APAP + vehicle
nHEAF + APAP
d
Kidney
Spleen
Heart
GPx activity (U/g tissue)
0
100
200
300
***
†††
Control
nHEAF 500
APAP + vehicle
nHEAF + APAP
e
Kidney
Spleen
Heart
SOD activity (U/g tissue)
0
500
1000
1500
2000
†††
***
***
**
††
*
Control
nHEAF 500
APAP + vehicle
nHEAF + APAP
f
Kidney
Spleen
Heart
CAT activity (U/g tissue)
0
50
100
150
200
†††
**
***
††
*
Control
nHEAF 500
APAP + vehicle
nHEAF + APAP