Title: **Gastrocnemius fascicles are shorter and more pennate immediately following acute Achilles tendon rupture**

Authors**:** Todd J. Hullfish, BSME, Kathryn M O'Connor, MD, MSPT, Josh R. Baxter, PhD

Department of Orthopaedic Surgery, University of Pennsylvania, Philadelphia, PA USA

Mailing address: 3737 Market Street, Suite 702, Philadelphia, PA, USA 19104

Corresponding author: Josh R. Baxter, PhD; josh.baxter@uphs.upenn.edu

Authors' Contributions KO and JB designed the experiment; TH collected and analyzed the data; TH and JB analyzed and interpreted the data; TH and JB drafted the manuscript; TH, KO, and JB revised the intellectual content of the manuscript; TH, KO, and JB approved the final version of the manuscript; and TH, KO, and JB agreed to be accountable for all aspects of the study.

Acknowledgements this work was supported by The Thomas B. McCabe and Jeannette E. Laws McCabe Fund

Word Count 2,403

Conflict of interest the Authors have no conflicts of interest that are relevant to this work

Running title Muscle remodels following tendon rupture

ABSTRACT

The purpose of this study was to characterize the short-term effects of Achilles tendon ruptures on medial gastrocnemius. We hypothesized that the medial gastrocnemius muscle of the injured Achilles tendon would have shorter and more pennate fascicles immediately following the injury and would persist throughout 4 weeks post-injury. Longitudinal ultrasound images of the medial gastrocnemius were acquired in 10 adults who suffered acute Achilles tendon ruptures and were treated non-operatively. B-mode ultrasound images were acquired within 10 days of the initial injury as well as two and four weeks following the initial clinical treatment. Resting muscle structure was characterized by measuring fascicle length, pennation angle, muscle thickness, and muscle echo intensity in both the injured and contralateral (control) limbs. Fascicle length and pennation was 15% shorter and 21% greater at the presentation of injury (week 0), respectively ($P < 0.001$). These differences in fascicle length and pennation angle persisted throughout the 4 weeks after the injury ($P < 0.008$). Muscle thickness changes were not detected at any of the post-injury visits (difference < 4%, $P > 0.04$). Echo intensity of the injured limb was 8 and 11% lower ($P < 0.008$) than the contralateral muscle at presentation of injury and 2 weeks following injury, respectively, but returned to within 1% by 4 weeks ($P = 0.393$). Achilles tendon ruptures elicit rapid changes in the configuration and quality of the medial gastrocnemius, which may explain long-term functional deficits.

Key Terms: muscle remodeling, architecture, ultrasound, imaging

Introduction

The incidence of Achilles tendon ruptures has increased 10-fold over the last three decades, disproportionally affecting athletic adults who participate in sports requiring sudden acceleration and jumping (19). This well-documented increase in the prevalence of acute Achilles tendon ruptures (15, 19, 25) is mostly likely explained by the recent rise in sports participation amongst aging adults (15). While advances in rehabilitation protocols have improved outcomes in patients treated either operatively or non-operatively (34), approximately one out of five patients without other complications are unable to return to their previous levels of athletic participation (36).

Deficits in plantarflexion function of the affected limb play a large role in preventing return to pre-injury levels of activity (26) and have been shown to persist as far out as 14-years following injury (5, 11). Clinically, these deficits present as decreased resting ankle angle (37), reduced calf-raise function (6, 30), and 10-20% reductions in plantarflexion strength (11, 21, 27). Tendon elongation and plantarflexor muscle atrophy have both been associated with these reductions in function (10, 23, 30). Decreased resting tension in the muscle-tendon unit stimulates sarcomere subtraction (32, 33), effectively restoring the resting tension in the muscle. Both increased tendon length and decreased muscle fascicle length have been shown to negatively affect single-leg heel raise performance in computational simulations (1).

Plantarflexor function is governed by muscle-tendon structure and mechanical properties. Although isometric strength is a commonly measured metric of patient function and correlates with muscle size and leverage (3), athletics require active plantarflexor shortening to generate ankle power (20). Longer muscle fascicles generate greater power at high speeds, which is beneficial for activities like sprinting (20). Targeted training can increase muscle fascicle length (28), effectively increasing power potential. Although muscle structure has been linked to function in many populations, shorter muscle fascicles have only been reported in a single case report of a patient with poor outcomes following an Achilles tendon rupture (2). Sudden changes in muscle-tendon tension, either induced through joint immobilization (32, 33) or changes in muscle leverage (7, 17), stimulate changes in muscle fascicle length within weeks. However, this muscle modeling response to an immediate loss of muscle-tendon tension caused by Achilles tendon ruptures have not been prospectively studied in a patient cohort.

Therefore, the purpose of this study was to quantify the immediate structural changes to the medial gastrocnemius in patients who suffered acute Achilles tendon ruptures and were treated non-operatively. We hypothesized that the medial gastrocnemius muscle would have shorter and more pennate fascicles immediately following an acute Achilles tendon rupture and would persist throughout 4 weeks post-injury.

Methods

Study Design

Ten adults (9 males, Age: 43.9 ± 11.6; BMI: 28.58 ± 6.5) who suffered acute Achilles tendon ruptures (**Table 1**) and were treated non-operatively were enrolled in this IRB approved study. All subjects met several inclusion criteria: patient was between 18 and 60 years old, elected to be treated non-operatively for acute Achilles tendon rupture within 2 weeks of injury, were not of an excessive weight (BMI < 50), and had no concomitant lower extremity injuries. We acquired ultrasound images of the medial gastrocnemius during three clinical visits (**Figure 1**): time of injury when subjects were placed in a cast (week 0); time of cast removal when subjects were transitioned into partial weight bearing in a walking boot (week 2); and 2 weeks after transitioning into boot use (week 4). Patients were enrolled in this study within 10 days of suffering the injury (4.5 ± 3.5 days), at which the week 0 images were acquired. We imaged the contralateral limb at week 0, which served as a control for all subjects. We imaged the affected limb at each time point and compared to the control muscle to determine

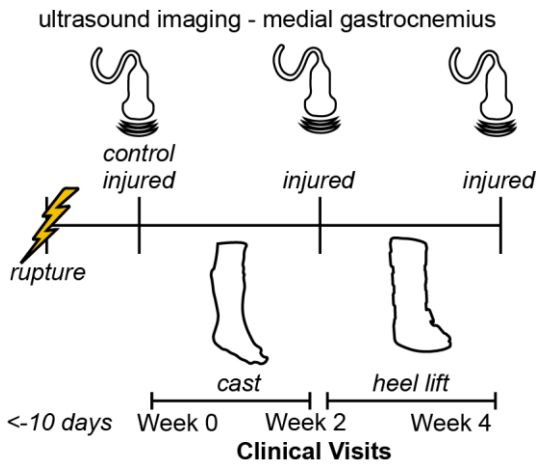

Figure 1. Patients who suffered acute Achilles tendon ruptures were enrolled in this prospective study at their initial clinical visit (week 0). We measured the architecture of the medial gastrocnemius muscle on the injured side using ultrasound at each clinical visit (week 0, 2, and 4) and the contralateral-healthy side (week 0) to serve as a control.

changes in resting muscle structure. Resting structure of the muscle was characterized by the length and pennation of the constituent fascicles as well as the thickness of the muscle belly. We also determined muscle quality by quantifying the average echo intensity of the muscle belly.

Image Acquisition

Longitudinal images of the medial gastrocnemius were acquired while subjects lay prone on a treatment table with their feet and ankles supported by the edge of the table in plantarflexion and kept in the same position for all imaging sessions. Continuous B-mode ultrasound images of the medial gastrocnemius

Table 1. Patient Demographics

	Sex	Age (yrs)	Injury Mechanism	Days to treatment	Ht (m)	Wt (kg)	BMI)
Subject Data	F	49	Tennis	1	1.68	72.6	25.8
	M	46	Basketball	3	1.85	83.9	24.4
	M	63	Ladder fall	10	1.80	80.7	24.8
	M	32	Basketball	1	1.75	86.2	28.1
	M	51	Basketball	7	1.75	104.3	34.0
	M	32	Basketball	4	1.78	124.3	39.3
	M	31	Skateboarding	1	1.75	77.1	25.1
	M	59	Jump rope	9	1.85	83.0	24.1
	M	40	Slip	2	1.85	72.6	21.1
	M	36	Stair descent	7	1.80	127.0	39.1
Avg ± SD	9M/1F	43.9 ± 11.6	7sports/3other	4.5 ±3.5	1.79±0.06	91.2±20.3	28.6±6.5

were acquired by a single investigator using an 8 MHz ultrasound transducer with a 6 cm scanning width (LV7.5/60/128Z-2, SmartUs, TELEMED). The probe was positioned in the middle of the muscle belly aligned with the fascicles to ensure that the muscle fascicles lie in the image plane (**Figure 2**, (4)). During pilot testing, we identified canning parameters (scan parameters: Dynamic Range: 72 dB; Frequency: 8 MHz; Gain: 47 dB) that produced high-contrast images and held them constant for all subjects and scanning sessions. All images were acquired by the same investigator and saved as digital videos to be processed later by the same investigator. Individual frames from the continuous imaging were exported as still images to be processed for muscle structure.

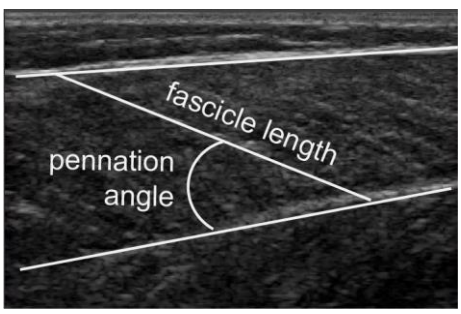

Figure 2. Ultrasound images of the medial gastrocnemius were acquired and analyzed by the same investigator to quantify resting fascicle length, pennation angle, thickness, and muscle belly echogenicity.

Image Analysis

Resting fascicle length, pennation angle, muscle thickness, and muscle quality were quantified using custom written software (MATLAB 2017b, The MathWorks, Inc, Natick, MA) (2). We anonymized and randomized each image to ensure that the investigator analyzing the images could not be biased. For each image, the investigator identified the deep and superficial aponeuroses as well as a single fascicle (**Figure 2**). We quantified fascicle length as the distance between the fascicle's insertions into the aponeuroses. Pennation angle was determined to the be the angle between the fascicle and the deep aponeuroses. Muscle thickness was calculated based on fascicle length and pennation angle (**Eq. 1**, **Figure 2**)**.** During this analysis, we observed that many of the ultrasound images showed the muscle to be of 'poor quality'. Therefore, we calculated the mean echo intensity between deep and superficial aponeuroses to quantify muscle quality. A previous study correlated muscle strength with mean echogenicity and attributed this link between muscle form and function to increased fibrous and adipose tissues within the muscle belly (8).

Eq. 1. $thickness = l_{fascicle} \times \sin\theta_{pennation}$

Statistical Analysis

To test our hypothesis that resting muscle architecture would change following injury, resting fascicle length, pennation angle, and muscle thickness at week 0, 2, and 4 were each compared to against the control values using paired one-way t-tests. Bonferroni corrections for multiple comparisons were applied, which set the threshold for statistical significance to p = 0.0167 (0.05 / 3, where 3 is the number of comparisons for each variable of interest. We performed an *a priori* sample size calculation based on the variation of medial gastrocnemius fascicle length in young adults (3) and determined that 10 subjects would be able to detect a 10% decrease with desired statistical power of 0.8.

Results

Gastrocnemius muscle structure following an acute Achilles tendon rupture differed with the healthy-contralateral muscle throughout the first four weeks following injury (**Figure 3**). Fascicle length and pennation was 12% shorter and 21% greater at the presentation of injury (week 0), respectively ($P < 0.001$). These differences in fascicle length and pennation angle persisted throughout the 4 weeks after the injury ($P < 0.008$). Muscle thickness changes were not detected at any of the post-injury visits; however, a 3% decrease in muscle thickness at week 4 approached our threshold for significance when controlling for multiple comparisons ($P = 0.41$). Muscle quality measured, as mean echogenicity of the muscle belly, was 8 and 11% lower in the injured limb immediately and 2 weeks following

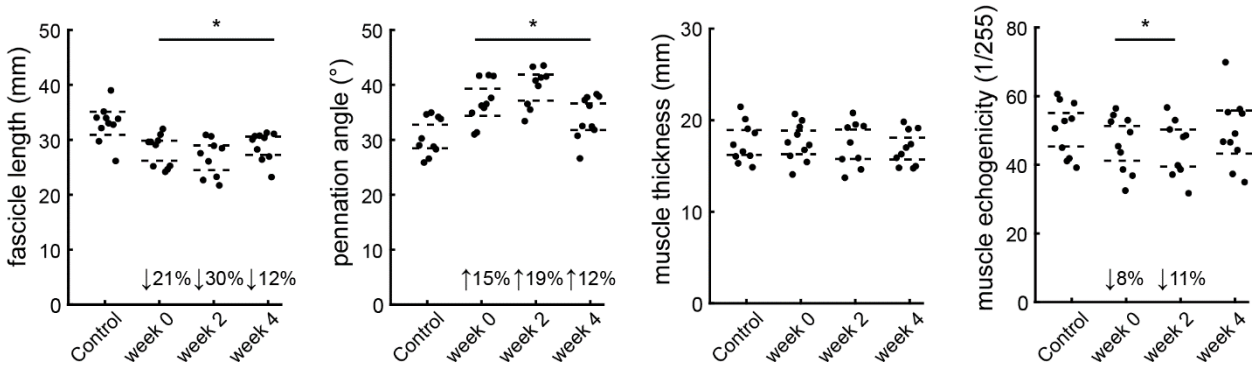

Figure 3. Medial gastrocnemius structure was altered following an acute Achilles tendon rupture. Resting fascicle length decreased while pennation angle increased in similar proportions, which explained the stable muscle belly thickness following 4 weeks of injury. Muscle echogenicity was 8-11% reduced at week 0 and 2 before returning to non-injured values at week 4.

injury, respectively ($P < 0.008$). At week 4 muscle quality had returned to within 1% of the contralateral limb ($P = 0.393$).

Discussion

Acute Achilles tendon ruptures are increasingly common sports injuries in physically active adults (15, 19). Long-term functional deficits have been linked to tendon elongation (30), which occurs within the first month following the initial injury (16). Preliminary reports suggest that plantarflexor muscle structure is the primary determinant of function following Achilles tendon ruptures (1, 2). Sudden changes in muscle-tendon tension, whether imposed by immobilization (32) or tendon repairs (18), elicit rapid remodeling of skeletal muscle. Therefore, the purpose of this study was to quantify medial gastrocnemius structure following the first month of acute Achilles tendon ruptures. Our findings support our hypothesis that the gastrocnemius muscle fascicles of the affected side would demonstrate shorter length and greater pennation than the contralateral control muscle. These changes appear to be a biologic response to a sudden loss of intra-muscular tension, which is typically present with an intact tendon (14). When this tension is released by an acute rupture, the muscle retracts resulting in a shorter and more pennate fascicle. Our report is the first to our knowledge to document gastrocnemius remodeling immediately following an Achilles tendon rupture, which is an important advancement in the study and treatment of tendon injuries.

Our measurements of medial gastrocnemius structure compared favorably with prior reports. Due to the clinical constraints of these patients, we were required to image the muscle with the foot supported in maximal plantarflexion by a table. As expected, our measurements of gastrocnemius structure were shorter and more pennate than compared to other studies that have measured gastrocnemius structure at neutral ankle angle (3, 20). However, our measurements of fascicle length and pennation were similar to a previous report of gastrocnemius structure in peak plantarflexion (9), which demonstrated a linear relationship between ankle angle and both fascicle length and pennation angle. We calculated muscle thickness using a single longitudinal scan of the muscle belly rather than a transverse scan or multiple longitudinal scans at different locations. Using this imaging approach, we detected a small (3%) decrease in muscle thickness at week 4 that approached statistical significance ($P = 0.041$). This small decrease in muscle thickness was less than previous reports of muscle atrophy at least 1 year following injury (10, 12). Decreases in muscle quality have been associated with age-related muscle deterioration such as sarcopenia (8), but these changes have not been observed in muscle following tendon rupture. The changes in muscle quality we observed suggest that the biologic response dictating structural remodeling may also lead to fluid or fatty infiltration into the muscle belly.

Functional deficits are associated with elongated tendon and shorter muscle fascicles following Achilles tendon rupture (**Figure 4**, (1, 2, 6, 12, 30)). When considered in this context, our

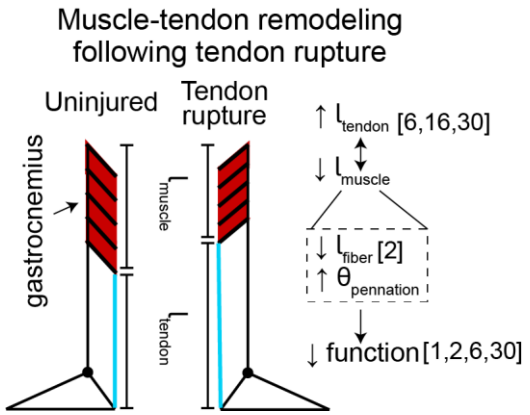

Figure 4. Achilles tendon length and plantarflexor structure appear to be closely related and sensitive to tendon injuries. We hypothesize that the injury-induced tendon elongation elicits muscle remodeling, which increases tendon tension and continues tendon elongation.

current findings of shorter and more pennate gastrocnemius fascicles immediately following Achilles tendon rupture indicate a coupled remodeling response with the healing tendon.(31) Imaging studies of the healing Achilles tendon show continued tendon elongation (16, 22, 24), which suggests that muscle-tendon adaptations continue for several months following the injury. We hypothesize that the initial tendon injury stimulates a rapid change in muscle structure in an attempt to restore the optimal resting tension in the muscle-tendon unit, which triggers a positive feedback loop. Prospective research is needed to directly link the interaction between tendon elongation and muscle remodeling. Understanding the progression of this remodeling process is crucial for the treatment of tendon injuries and can be used to inform clinical decisions as well as the prescription of rehabilitation protocols.

In addition to our current findings that skeletal muscle architecture is sensitive to tendon rupture (**Figure 3**), muscle fascicle length can also be affected by loading, pathology, surgical procedures, and immobilization in both humans and animal models. High-acceleration training during maturation in guinea fowl stimulates longer muscle fascicles that contain greater amounts of sarcomeres in series (28). Children with cerebral palsy have shorter gastrocnemius fascicles that can be increased with surgical correction of the plantarflexor contracture (35). Increasing the muscle shortening demands by surgically releasing the ankle retinaculum elicits rapid sarcomere subtraction in both mice (7) and rabbits (17). Immobilizing the ankle joint in plantarflexion elicits muscle fiber remodeling, highlighted by a shorter optimal length and reduced sarcomeres in series (32, 33). Seminal work by Williams (32) demonstrates the importance of muscle tension on muscle length and joint range of motion in the context of immobilization.

These findings are a preliminary set of data from a larger clinical cohort of patients that have been enrolled in a 1-year long prospective study. We are closely monitoring muscle and tendon structure at each clinical visit. Once cleared for activity, we will test plantarflexor strength and power in these patients using dynamometry and single-leg heel raises (2, 3). Prior research also suggests that these structural changes in muscle are permanent(2) and the magnitude of these changes may be predictive of long-term functional deficits (1, 30).

This study had several limitations. Due to the loading restrictions in the weeks following the injury, we imaged the muscle fascicles with the foot in maximal plantarflexion to ensure an unloaded tendon. We are prospectively following this cohort for 1 year to link changes in gastrocnemius structure with tendon elongation and functional deficits. Once cleared by their treating physician, we will acquire muscle and tendon measurements throughout the ankle range of motion. Continued monitoring of this cohort will yield further insight into the link between tendon injury, muscle remodeling, and patient function. We did not perform muscle biopsy or intramuscular sarcomere measurement (29); as such, this study was not designed to establish whether optimal sarcomere length was preserved via sarcomere subtraction or not. However, animal studies that imposed sudden changes in joint mechanics demonstrates that rapid change in sarcomere number to preserve optimal sarcomere length (7, 17, 32). We decided to image the medial gastrocnemius, which has longer and less pennate fascicles than the soleus and generates tension in greater amounts of plantarflexion (13),

which is critical for functional tasks such as heel raises. This study highlights the rapid change in muscle structure following acute Achilles tendon ruptures.

In summary, our findings demonstrate that the medial gastrocnemius muscle undergoes rapid changes in configuration in response to an acute Achilles tendon rupture. While the mechanisms governing these changes remain unclear, prior work suggests that perturbations in muscle-tendon tension stimulate these changes. Future research should be focused on the effects of muscle-tendon tension on muscle remodeling pathways. Immobilizing joints has been shown to stimulate sarcomere addition or subtraction to preserve optimal sarcomere lengths. Therefore, careful immobilization paradigms may prove to be efficacious for preserving muscle structure and quality in patients following tendon injuries.

References

1. **Baxter JR**, **Farber DC**, **Hast MW**. Plantarflexor fiber length and tendon slack length are the strongest determinates of simulated single-leg heel raise function. *BioRxiv Prepr.* (September 12, 2018). doi: 10.1101/415679.

2. **Baxter JR**, **Hullfish TJ**, **Chao W**. Functional deficits may be explained by plantarflexor remodeling following Achilles tendon rupture repair: Preliminary findings. *J Biomech* 0, 2018.

3. **Baxter JR**, **Piazza SJ**. Plantar flexor moment arm and muscle volume predict torque-generating capacity in young men. *J Appl Physiol* 116: 538–44, 2014.

4. **Bolsterlee B**, **Gandevia SC**, **Herbert RD**. Ultrasound imaging of the human medial gastrocnemius muscle: how to orient the transducer so that muscle fascicles lie in the image plane. *J Biomech* 49: 1002–1008, 2016.

5. **Brorsson A**, **Grävare Silbernagel K**, **Olsson N**, **Nilsson Helander K**. Calf Muscle Performance Deficits Remain 7 Years After an Achilles Tendon Rupture. *Am J Sports Med* 46: 470–477, 2018.

6. **Brorsson A**, **Willy RW**, **Tranberg R**, **Silbernagel KG**. Heel-Rise Height Deficit 1 Year After Achilles Tendon Rupture Relates to Changes in Ankle Biomechanics 6 Years After Injury. *Am J Sports Med* 45: 3060–3068, 2017.

7. **Burkholder TJ**, **Lieber RL**. Sarcomere number adaptation after retinaculum transection in adult mice. *J Exp Biol* 201: 309–316, 1998.

8. **Fukumoto Y**, **Ikezoe T**, **Yamada Y**, **Tsukagoshi R**, **Nakamura M**, **Mori N**, **Kimura M**, **Ichihashi N**. Skeletal muscle quality assessed from echo intensity is associated with muscle strength of middle-aged and elderly persons. *Eur J Appl Physiol* 112: 1519–1525, 2012.

9. **Gao F**, **Grant TH**, **Roth EJ**, **Zhang LQ**. Changes in Passive Mechanical Properties of the Gastrocnemius Muscle at the Muscle Fascicle and Joint Levels in Stroke Survivors. *Arch Phys Med Rehabil* 90: 819–826, 2009.

10. **Heikkinen J**, **Lantto I**, **Flinkkila T**, **Ohtonen P**, **Niinimaki J**, **Siira P**, **Laine V**, **Leppilahti J**. Soleus Atrophy Is Common After the Nonsurgical Treatment of Acute Achilles Tendon Ruptures. *Am. J. Sports Med.* (2017). doi: 10.1177/0363546517694610.

11. **Heikkinen J**, **Lantto I**, **Flinkkilä T**, **Ohtonen P**, **Pajala A**, **Siira P**, **Leppilahti J**. Augmented Compared with Nonaugmented Surgical Repair After Total Achilles Rupture: Results of a Prospective Randomized Trial with Thirteen or More Years of Follow-up. *J Bone Jt Surg* 98: 85–92, 2016.

12. **Heikkinen J**, **Lantto I**, **Piilonen J**, **Flinkkilä T**, **Ohtonen P**, **Siira P**, **Laine V**, **Niinimäki J**, **Pajala A**, **Leppilahti J**. Tendon Length, Calf Muscle Atrophy, and Strength Deficit After Acute Achilles Tendon Rupture: Long-Term Follow-up of Patients in a Previous Study. *J Bone Jt Surg* 99: 1509–1515, 2017.

13. **Hirata K**, **Kanehisa H**, **Miyamoto-Mikami E**, **Miyamoto N**. Evidence for intermuscle difference in slack angle in human triceps surae. *J Biomech* 48: 1210–1213, 2015.

14. **Hug F**, **Lacourpaille L**, **Maïsetti O**, **Nordez A**. Slack length of gastrocnemius medialis and Achilles tendon occurs at different ankle angles. *J Biomech* 46: 2534–2538, 2013.

15. **Huttunen TT**, **Kannus P**, **Rolf C**, **Felländer-Tsai L**, **Mattila VM**. Acute Achilles Tendon Ruptures: Incidence of Injury and Surgery in Sweden Between 2001 and 2012. *Am J Sports Med* 42: 2419–2423, 2014.

16. **Kangas J**, **Pajala A**, **Ohtonen P**, **Leppilahti J**. Achilles Tendon Elongation after Rupture Repair: A Randomized Comparison of 2 Postoperative Regimens. *Am J Sports Med* 35: 59–64, 2007.

17. **Koh TJ**, **Herzog W**. Excursion is important in regulating sarcomere number in the growing rabbit tibialis anterior. *J Physiol* 508: 267–280, 1998.

18. **Krochmal DJ**, **Kuzon WM**, **Urbanchek MG**. Muscle Force and Power Following Tendon Repair at Altered Tendon Length. *J Surg Res* 146: 81–89, 2008.

19. **Lantto I**, **Heikkinen J**, **Flinkkilä T**, **Ohtonen P**, **Leppilahti J**. Epidemiology of Achilles tendon ruptures: increasing incidence over a 33-year period. *Scand J Med Sci Sports* 25: e133-138, 2015.

20. **Lee SSM**, **Piazza SJ**. Built for speed: musculoskeletal structure and sprinting ability. *J Exp Biol* 212: 3700–3707, 2009.

21. **Leppilahti J**, **Lahde S**, **Forsman K**, **Kangas J**, **Kauranen K**, **Orava S**. Relationship Between Calf Muscle Size and Strength after Achilles Rupture Repair. *Am. Orthop. Foot Ankle Soc.* .

22. **Mortensen HM**, **Skov O**, **Jensen PE**. Early motion of the ankle after operative treatment of a rupture of the Achilles tendon. A prospective, randomized clinical and radiographic study. *J Bone Joint Surg Am* 81: 983–990, 1999.

23. **Mullaney M**, **McHugh M**, **Tyler T**, **Nicholas S**, **Lee S**. Weakness in End-Range Plantar Flexion After Achilles Tendon Repair. *Am Coll Sports Med* 34, 2006.

24. **Nyström B**, **Holmlund D**. Separation of tendon ends after suture of achilles tendon. *Acta Orthop Scand* 54: 620–621, 1983.

25. **Nyyssönen T**, **Lüthje P**, **Kröger H**. The increasing incidence and difference in sex distribution of Achilles tendon rupture in Finland in 1987-1999. *Scand J Surg* 97: 272–275, 2008.

26. **Olsson N**, **Nilsson-Helander K**, **Karlsson J**, **Eriksson BI**, **Thomée R**, **Faxén E**, **Silbernagel KG**. Major functional deficits persist 2 years after acute Achilles tendon rupture. *Knee Surg Sports Traumatol Arthrosc* 19: 1385–1393, 2011.

27. **Pajala A**, **Kangas J**, **Siira P**, **Othonen P**, **Leppilahti J**. Augmented compared with nonaugmented surgical repair of a fresh total Achilles tendon rupture. A prospective randomized study. *J Bone Joint Surg Am* 91: 1092–100, 2009.

28. **Salzano MQ**, **Cox SM**, **Piazza SJ**, **Rubenson J**. High-acceleration training during growth increases optimal muscle fascicle lengths in an avian bipedal model. *J Biomech* 0, 2018.

29. **Sanchez GN**, **Sinha S**, **Liske H**, **Chen X**, **Nguyen V**, **Delp SL**, **Schnitzer MJ**. In Vivo Imaging of Human Sarcomere Twitch Dynamics in Individual Motor Units. *Neuron* 88: 1109–1120, 2015.

30. **Silbernagel KG**, **Steele R**, **Manal K**. Deficits in Heel-Rise Height and Achilles Tendon Elongation Occur in Patients Recovering From an Achilles Tendon Rupture. *Am J Sports Med* 40: 1564–1571, 2012.

31. **Suydam SM**, **Buchanan TS**, **Manal K**, **Silbernagel KG**. Compensatory muscle activation caused by tendon lengthening post-Achilles tendon rupture. *Knee Surg Sports Traumatol Arthrosc* 23: 868–874, 2015.

32. **Williams PE**. Use of intermittent stretch in the prevention of serial sarcomere loss in immobilised muscle. *Ann Rheum Dis* 49: 316–317, 1990.

33. **Williams PE**, **Goldspink G**. Changes in sarcomere length and physiological properties in immobilized muscle. *J Anat* 127: 459–468, 1978.

34. **Willits K**, **Amendola A**, **Bryant D**, **Mohtadi NG**, **Giffin JR**, **Fowler P**, **Kean CO**, **Kirkley A**. Operative versus Nonoperative Treatment of Acute Achilles Tendon Ruptures: A Multicenter Randomized Trial Using Accelerated Functional Rehabilitation. *J Bone Jt Surg* 92: 2767–2775, 2010.

35. **Wren TAL**, **Cheatwood AP**, **Rethlefsen SA**, **Hara R**, **Perez FJ**, **Kay RM**. Achilles Tendon Length and Medial Gastrocnemius Architecture in Children With Cerebral Palsy and Equinus Gait. *J Pediatr Orthop* 30: 479–484, 2010.

36. **Zellers JA**, **Carmont MR**, **Silbernagel KG**. Return to play post-Achilles tendon rupture: a systematic review and meta-analysis of rate and measures of return to play. *Br J Sports Med* 50: 1325–1332, 2016.

37. **Zellers JA**, **Carmont MR**, **Silbernagel KG**. Achilles Tendon Resting Angle Relates to Tendon Length and Function. *Foot Ankle Int* 39: 343–348, 2018.