Title: Reorganization of thalamocortical connections in congenitally blind humans

Running title: Thalamic plasticity in congenital blindness

Authors: Theo F. Marins[a,b], Maite Russo[c], Erika C. Rodrigues[a,d], Marina Monteiro[a], Jorge Moll[a], Daniel Felix[a], Julia Bouzas[a], Helena Arcanjo[e]; Claudia D. Vargas[c], Fernanda Tovar-Moll[a,b,1]

[a] D'Or Institute for Research and Education (IDOR), Rio de Janeiro, Brazil
[b]Institute of Biomedical Sciences (ICB), Federal University of Rio de Janeiro (UFRJ), Rio de Janeiro, Brazil; [c]Institute of Biophysics Carlos Chagas Filho (IBCCF), Federal University of Rio de Janeiro (UFRJ); [d]Post-Graduation Program in Rehabilitation Sciences, Augusto Motta University Center (UNISUAM), Rio de Janeiro, RJ, Brazil; [e]Centro de Oftalmologia Especializada

[1]Corresponding Author: fernanda.tovarmoll@idor.org

ABSTRACT

Evidence of cross-modal plasticity in blind individuals has been reported over the past decades showing that non-visual information is carried and processed by 'visual' brain structures. This feature of the blind brain makes it a pivotal model to explore the limits and mechanisms of brain plasticity. However, despite multiple efforts, the structural underpinnings of cross-modal plasticity in congenitally blind individuals remain unclear. Using advanced neuroimaging techniques, we mapped thalamocortical connectivity and assessed cortical thickness and integrity of white matter of ten congenitally blind individuals and ten sighted controls. We hypothesized an aberrant thalamocortical pattern of connectivity taking place in the absence of visual stimuli from birth as a potential mechanism of cross-modal plasticity. In addition to the increased cortical thickness of the primary visual cortex and reduced integrity of visual white matter bundles, we observed structural connectivity changes between the thalamus and both occipital and temporal cortices. Specifically, the thalamic territory dedicated to connections with the occipital cortex was found to be smaller and displayed weaker connectivity in congenitally blind individuals, whereas the one that connects with the temporal cortex showed greater volume and stronger connectivity when compared to sighted controls. The abnormal pattern of thalamocortical connectivity included the lateral and medial geniculate nuclei and the pulvinar nucleus. For the first time in humans, a remapping of structural thalamocortical connections involving both unimodal and multimodal thalamic nuclei has been demonstrated, shedding light on the possible mechanisms of cross-modal plasticity in humans. Future studies should employ neurophysiologic approaches to explore the functional relevance of present findings.

Keywords: cross-modal plasticity, congenital blindness, diffusion tensor imaging, thalamus, cortical thickness

Abbreviations: WM = White Matter; DTI = Diffusion Tensor Imaging; LGN = Lateral Geniculate Nucleus; MGN = Medial Geniculate Nucleus; Congenitally blinds = CB; Sighted controls = SC.

INTRODUCTION

Blindness and vision impairment affects at least 2.2 billion people around the world[1]. A significant part of these patients suffers from congenital blindness, which can be caused by congenital anomalies, infantile glaucoma, among other causes[2]. Congenital blindness represents an intriguing model to understand how the brain builds and maintains its fundamental principles of organization and hierarchy of processing in the absence of one of the major sources of inputs. The impact of congenital blindness over spared sensory systems has also been a focus of study over the past years. A better characterization of the basis of blindness-related brain alterations, including the well-described phenomenon of cross-modal plasticity, can pave the way for developing and optimizing new inclusive devices and rehabilitation brain-machine interfaces.

Numerous brain alterations can take place in response to the lack of visual input, including in the white matter (WM) and gray matter (GM) of both cortical and subcortical brain structures. Congenitally/early blind individuals often exhibit atrophy of optic chiasm and reduced microstructural integrity of optic radiations and geniculocalcarine tract[3–7], as investigated by Diffusion Tensor Imaging (DTI). Also, splenium of the corpus callosum, inferior longitudinal fasciculus, and inferior fronto-occipital fasciculus, which are major WM bundles connecting different cortical areas involved in visual processing and perception, are impacted by the absence of visual input[7–12]. Alterations of cortical morphometry in congenitally and early blind individuals have been observed as an increased cortical thickness in the calcarine sulcus, middle temporal gyrus, and primary visual cortex[5,10,13].

Functional neuroimaging studies have shown that visual cortical structures often participate in the processing of non-visual information, which is called cross-modal plasticity. In blind individuals, this reorganization is commonly observed as a visual takeover by the auditory and tactile systems[14–19], but it has also been reported involving language[20,21], olfaction and gustation[22,23] very often leading to increased abilities and behavioral improvement in the remaining senses. In addition, recruitment of 'visual' brain areas in blindness has been reported during auditory[24–28], tactile[15], and linguistic [21] tasks, and correlation with behavioral gains has also been shown[13,25,29–31]. Moreover, virtual lesions targeted to the 'visual' cortex induced by Transcranial Magnetic Stimulation

(TMS) can temporarily impair performance on both auditory [8] and tactile[32,33] tasks in blind individuals. Altogether, these findings suggest that the brain goes under critical changes in the absence of visual input, which pave the way for cross-modal plasticity.

Despite accumulating evidence corroborating cross-modal plasticity in blinds, neuroanatomical correlates underlying this phenomenon are controversial and may involve a wide range of brain structural changes, including the development of new connections and/or unmasking and/or rewiring of the existing ones[34]. Indeed, there is no consensus about how and which pathways convey non-visual information to the visual cortex in blinds. Most findings on the possible anatomical underpinnings of cross-modal plasticity and its mechanisms come from studies in animal models of blindness. They point to the emergence of direct connections between deprived visual, auditory, and somatosensory cortices, indicating that non-visual information would reach the visual cortex by direct corticocortical connectivity, a transient connection that becomes stabilized during development by the lack of appropriate visual stimuli[35–41]. On the other hand, it is also well documented the preservation of geniculocalcarine pathways in blind individuals[5,42,43], which supports the idea that adaptive plasticity may rely upon the conservation of thalamocortical pathways. In the naturally blind mole rat, the remnant visual pathways carry auditory information to the visual cortex as their visual nuclei of the thalamus receive input from the inferior colliculus, an important auditory center[44,45] Moreover, in addition to the preserved thalamocortical connections, visual cortical areas receive input from auditory and somatosensory nuclei of the thalamus in blind mice and opossu[39,46]. These findings suggest that robust changes in the thalamocortical connectivity may occur in response to the lack of visual input and could also explain the cross-modal plasticity observed in congenitally blind individuals.

While brain structural underpinnings of cross-modal plasticity are still uncertain, well-established findings support the idea that the blind brain consists of a great model to explore the limits of brain plasticity and investigate its mechanisms. In the present study, we used advanced neuroimaging techniques, based on diffusion-weighted imaging, probabilistic tractography, and brain morphometry, to interrogate the thalamic (re)mapping of cortical connections, the microstructure of WM, and the cortical thickness of congenitally blind individuals. Specifically, we tested the hypothesis that structural changes of thalamocortical projections involved in visual and multimodal sensory processing would occur in response to the absence of appropriate visual input from birth. Our results point to a wide range of brain changes observed in congenitally blind

individuals, including increased cortical thickness in V1, poorer WM microstructure of visual-related bundles, and remapping of thalamic connections with both temporal and occipital cortices in these subjects when compared to a matched sample of sighted controls.

METHODS

Subjects

This study was conducted in accordance with the ethical standards compliant with the Declaration of Helsinki and has been approved by the IDOR / Copa D'Or Ethics and Scientific Committee. Ten congenitally blind (CB; mean age: 31.8, standard deviation: 8.7, 6 males) and ten sex- and age-matched sighted controls (SC; mean age: 32.2, standard deviation: 6.66, 6 males) were included in the study. All participants were right-handed, had no history of neurologic or psychiatric diseases, and were not taking brain-active medication. All congenitally blind participants were braille readers. The cohort characteristics are summarized in Table 1.

Table 1. Cohort characteristics

Patient ID	Age	Gender	Cause of congenital blindness	Handedness	Braille
CB01	35	F	Anophthalmia	Right	Yes
CB02	36	M	Macular dystrophy	Right	Yes
CB03	32	F	Glaucoma	Right	Yes
CB04	18	M	Glaucoma	Right	Yes
CB05	40	M	Glaucoma	Right	Yes
CB06	27	M	Glaucoma	Right	Yes
CB07	22	M	Retinal detachment	Right	Yes
CB08	44	M	Unknown	Right	Yes
CB09	24	F	Retinopathy of prematurity	Right	Yes
CB10	40	F	Unknown	Right	Yes

M: male. F: female

Data Acquisition

Brain imaging was performed at D'Or Institute for Research and Education (IDOR) in a 3T Achieva scanner (Philips Medical Systems, the Netherlands) using an eight-channel SENSE head coil. Imaging consisted in a high-resolution 3D T1-weighted image ($1mm^3$ isotropic, TR/TE (ms) = 7,2 / 3,4, FOV= 240 x 240, matrix = 240, slice thickness = 1mm) and diffusion-weighted ($2 \times 2 \times 2mm^3$ isotropic, no gap, TR/TE (ms)= 10150/60, FOV = 224 x 224, matrix = 112 x 112) with diffusion sensitization gradients applied in 64 noncollinear directions, with a b factor of 1000 s/mm2.

Data Analysis

Before data preprocessing, images were visually inspected for excessive movements or artifacts. Diffusion-weighted images were preprocessed and analyzed using FSL toolboxes. In each subject, original data was corrected for the effects of head movement and eddy currents using eddy correct, and a brain mask was created by running bet on one of the B=0 (no diffusion weighting) images. We created FA images using FDT, and then non-brain tissue was removed using BET. All subjects' data were aligned into a standard space (Montreal Neurological Institute, MNI) using the nonlinear registration tool FNIRT, and the mean FA image was created and thinned to create a mean FA skeleton. The FA map of each subject was projected onto skeletonized FA and the resulting data was fed into voxel-wise cross-subject statistics using TBSS[47]. Nonparametric analysis of the whole brain was conducted to find differences in WM integrity among groups in major bundles. Also, analysis restricted to the thalamus was separately conducted.

Connectivity-based segmentation of the thalamus was also performed using FDT, as described previously[48], in each hemisphere separately. Six cortical masks were predefined using the Harvard-Oxford atlas: Prefrontal, Precentral, Postcentral, Posterior Parietal (parietal cortex, except for the postcentral cortex), Occipital, and Temporal. Since the Oxford Thalamic Connectivity Probability Atlas does not include the lateral and medial geniculate nuclei (LGN and MGN, respectively), both right and left thalamic masks were obtained from an atlas based on the Colin-27 Average Brain[49]. All masks were registered into the subjects' space using nonlinear registration. After BEDPOSTX, probabilistic tracking was conducted with the PROBTRACKX tool, in which the unilateral thalamus was defined as the seed region and the six ipsilateral cortical masks as classification targets. Following, we calculated the number of samples reaching each

target mask as a proportion of the total number of samples reaching any target mask. Then, the hard segmentation of each thalamus based on its connectivity to each of the six ipsilateral cortical areas was performed. The volume of each resultant segment of the thalamus was normalized by the volume of the ipsilateral thalamus in the subject level. Group analysis of the normalized volume was performed with SPSS 20.0 (IBM Corporation, New York) using two repeated measures analysis of variance (ANOVA; within-subjects' factor: 'segment'; between-subjects factor: 'group') for each side.

To perform a voxel-wise analysis of the thalamocortical connectivity and compare them between groups, the resultant six segments at subject-level were transformed back to the MNI space. Each segment was overlapped to create a single mask and a nonparametric analysis of the connectivity maps for each segment was performed by running 5000 permutations of each segment in each thalamus.

Cortical thickness analysis

Cortical thickness analysis was performed based on high-resolution 3D T1-weighted gradient-echo images using Freesurfer software (http://surfer.nmr.mgh.harvard.edu/). Preprocessing steps included removal of non-brain tissue, segmentation of the subcortical white matter and deep gray matter volumetric structures, intensity normalization, tessellation of the gray matter/white matter boundary, automated topology correction, and surface deformation following intensity gradients.

To investigate group differences, we applied the command-line Freesurfer group analysis stream, including correction for multiple comparisons. First, the data from every subject was assembled, by resampling each subject's data onto a common space, spatially smoothing it, and concatenating all the subject's resampled and smoothed data into a single file. We defined the design matrix and design contrast comparing both groups, resulting in a t-test analysis of the whole brain. The statistical results were then submitted to a cluster-wise correction for multiple comparisons ($p<0.05$).

For the sake of simplicity, group differences are referred to as "increase" and "decrease" throughout the manuscript taking the SC group as reference. The coordinates in the figures are given according to MNI space, and results are plotted on the MNI standard brain.

Data availability

Data that support the present findings are available from the corresponding author upon reasonable request.

RESULTS

White Matter Microstructure Changes in Blind Subjects

We investigated differences in WM microstructure using TBSS for fractional anisotropy (FA). Whole-brain (threshold-free cluster enhancement (TFCE), corrected $p<0.05$) analysis showed decreased FA in the major WM structures connecting the occipital cortex, such as the splenium of the corpus callosum, bilateral inferior longitudinal fasciculi, bilateral inferior fronto-occipital fasciculi, and right superior longitudinal fasciculi (Fig. 1) in the CB group. Additional analysis restricted to the thalamus revealed a diffuse decrease in FA in the CB group, including both left and right pulvinar, medial dorsal nucleus, right ventral lateral nucleus, right lateral posterior, and left lateral nucleus (Fig. 1).

Figure 1 around here.

Increased Cortical Thickness in Blind Subjects

Whole-brain comparison of cortical thickness (whole-brain analysis, cluster-corrected for multiple comparisons, $p < 0.05$; Fig. 2A) revealed greater thickness of the left primary visual cortex (V1, Brodmann area 17 (BA17), Size= 268.24 mm^2, X=-5.2, Y=-86.4, Z=10.3, MNI) in the CB group (CB group > SC group). This single cluster was then masked to allow further investigation of thickness in each participant (Fig. 2B). No other cortical region showed group differences in thickness.

Figure 2 around here.

The segmentation of the thalamus based on the structural connectivity patterns to six predefined cortical areas (Prefrontal, Precentral, Postcentral, Posterior Parietal, Temporal, and Occipital) successfully resulted in six thalamic segments in each side (Fig. 3) in all participants.

We extracted the volume (normalized by the volume of each thalamus) of the resultant segments and compared them between groups using a mixed effect ANOVA (within-subjects' factor: 'segment'; between-subjects factor: 'group'). As a result, both

ANOVAs revealed an interaction effect between 'segment' and 'group' (left side: $F(3.51, 63.15)=4.44$, $p= 0.005$; right side $F(1.8, 32.4)=5.64$, $p= 0.01$). In addition, there was a main effect of 'segment' (left side: $F(3.51, 63.15)= 413.04$, $p< 0.001$; right side: $F(1.8, 32.4)=392$, $p< 0.001$). Simple-effect analysis with Sidak correction for multiple comparisons on the interaction 'segment' and 'group' indicated that the SC and CB groups significantly differed on the volume of the Occipital segments bilaterally, being reduced in the CB group; and bilateral Temporal segments being increased in the CB group (Fig. 3; Table 2). Analysis of the effect of 'segment' in the right thalamus revealed ($p<0.05$) that the Prefrontal segment showed greater volume when compared to all other five segments; the Precentral segment showed smaller volume when compared to the Temporal and Occipital segments, and greater volume than the Somatosensory segment; the Occipital segment showed greater volume than the Somatosensory segment and smaller volume than the Temporal segment; the Posterior Parietal segment revealed smaller volume than the Temporal segment; the Somatosensory segment showed smaller volume than the Temporal segment. On the left side, similar findings were observed. The Prefrontal segment showed greater volume when compared to all other five segments; the Precentral segment showed smaller volume when compared to the Temporal and Occipital segments; the Occipital segment showed greater volume than the Postcentral segment and smaller volume than the Temporal segment; the Posterior parietal segment revealed smaller volume than the Temporal segment; the Postcentral segment showed smaller volume than the Temporal segment. Due to the non-spherical nature of the data, results were corrected using Greenhouse-Geisser correction.

Figure 3 around here.

Table 2. Normalized volume comparisons of thalamic segments

Segment	Side	Sighted		Blind	
		Mean Volume	SD	Mean Volume	SD
Prefrontal	R	0.561224	0.0372437	0.515953	0.0578148

	L	0.537903	0.0424005	0.505637	0.0457513
Precentral	R	0.055635	0.0125891	0.060761	0.0150288
	L	0.067851	0.0290276	0.078154	0.0259177
Occipital*	R	0.11052	0.0286398	0.071793	0.0451293
	L	0.138718	0.0443775	0.088397	0.0174996
Posterior Parietal	R	0.065566	0.0267344	0.064867	0.0174419
	L	0.049694	0.026557	0.05505	0.0229696
Postcentral	R	0.044252	0.0156764	0.040539	0.0148974
	L	0.060081	0.0209732	0.071497	0.0407492
Temporal*	R	0.162803	0.0458977	0.246086	0.0842971
	L	0.145753	0.0363323	0.201264	0.0570562

*Segments that showed significant ($p<0.05$) between-group differences after simple-effect analysis of the interaction 'segment' and 'group'.
Sidak correction for multiple comparisons was applied. L= left thalamus; R= right thalamus. Mean volume refers to the normalized mean volume, in arbitrary units.

To investigate whether congenital blindness alters the anatomical connectivity pattern between the thalamus and the cortex, we conducted a nonparametric group comparison using threshold-free cluster enhancement (TFCE, FWE-corrected, $p<0.05$) of the probability maps of connectivity of each thalamic segment. This analysis revealed that the connectivity of the thalamic segment connecting to the occipital and the temporal cortices significantly differed between groups, with the thalamo-temporal connectivity being increased and the thalamo-occipital connectivity being reduced in the CB group. Specific regions showing increased thalamo-temporal connectivity in the CB group were observed in both thalami, specifically on the bilateral lateral geniculate nuclei (LGN), bilateral pulvinar, bilateral medial geniculate nuclei (MGN), left medial dorsal nuclei and anterior nuclei, and right ventral anterior nuclei (Fig. 4). On the other hand, reduced

thalamo-occipital anatomical connectivity in the CB group was restricted to the territory of the pulvinar and lateral posterior nucleus on the left thalamus (Fig. 4). Further analysis revealed that both group-differences in thalamocortical connectivity (increased thalamo-temporal connectivity and decreased thalamo-occipital connectivity) partially shared a common neural territory on the left pulvinar (Fig. 4). Thalamic projections to the Prefrontal, Precentral, Postcentral, and Posterior Parietal segments did not differ between groups.

Figure 4 around here.

DISCUSSION

The present findings indicate that the absence of appropriate visual input from birth in humans leads to a wide range of structural brain changes, including remapping of thalamocortical connectivity, which can help to understand some of the functional adaptation commonly observed in congenitally blind individuals.

The analysis of a sample of congenitally blind (CB) individuals, braille readers, right-handed, brought new evidence of reduced thalamic territories projecting to/from the occipital cortex, compared to sighted controls (SC). On the other hand, a greater volume of thalamic territory dedicated to connections with the temporal cortex was observed in CB compared to SC. Additionally, the voxel-wise analysis revealed that thalamic nuclei such as bilateral LGN, MGN, and pulvinar were more connected to the temporal cortex in CB. In contrast, left pulvinar and lateral posterior nuclei displayed weaker projections to the left occipital cortex in this group. Interestingly, we found strengthened connectivity of the left pulvinar to the temporal cortex over the occipital cortex, suggesting a possible reallocation of pulvinar connections in CB due to brain plasticity induced by congenital blindness. Moreover, we confirmed previous findings by showing that visual cortical areas can exhibit greater thickness, besides a diffuse impairment in the microstructure of visual WM bundles.

Our findings are in line with previous studies showing visual-related impairment of thalamic nuclei, such as LGN and pulvinar. Using voxel-based morphometry (VBM) previous studies have shown volume reductions in thalamic visual centers, including

dorsal LGN and pulvinar[9,51], identified with the aid of brain atlases, in congenitally blind individuals. A similar approach was used to describe volume reduction in WM close to the LGN in six bilaterally anophthalmic subjects compared with sighted subjects[5]. It is worth noting, however, that the present study did not intend to simply compare the volume of thalamic structures between groups. Rather, we went beyond by mapping the thalamocortical projections and exploring possible remapping of thalamic territories and their connectivity pattern to/from the cortex. Thus, one major difference between our and previous studies is that visual-related thalamic nuclei investigated here were identified using subject-level tractography. Interestingly, thalamic territory occupied by projections to/from the temporal cortex showed greater volume, whereas the on to/from the occipital cortex showed reduced volume in CB individuals when compared to the SC group, which brings new insights into the thalamic remodeling in congenital blindness.

Even though interesting, volume comparisons of thalamic structures have low intrinsic sensitivity, as differences in connectivity may not be reflected as volume changes. This would be even more tricky since thalamocortical remapping may be presented as both shrinkage and expansions of nuclei territories in a non-homogeneous and distributed pattern. We disentangled this by comparing the voxel-wise differences in thalamocortical connectivity between groups, which revealed the central role of pulvinar in the remapping of thalamocortical connectivity. WM connections between pulvinar/lateral posterior nuclei and occipital cortex were revealed to be decreased in the CB group. On the other hand, increased connectivity to/from the temporal cortex was also observed in the pulvinar. These findings suggest a thalamic shift of cortical connections in blind individuals, prioritizing the temporal projections over the occipital ones.

Interpreting the functional impact of these findings is not straightforward. The pulvinar is well known as the largest, higher-order multimodal thalamic nucleus, involved mainly in visual attention[52]. It displays a wide range of cortical connectivity that goes beyond the visual cortex, roughly to the gray matter of all lobes and subcortical structures such as the amygdala and superior colliculus[52–54]. Evidence suggests that cortico-cortical integration via pulvinar is an important pathway for the transfer of visual information between cortical areas[54,55]. Thus, it is reasonable to hypothesize that the pulvinar may become a central player in the dynamics of brain plasticity, possibly by integrating different sensory modalities at associative levels and paving multimodal plasticity in blind individuals. However, the pulvinar typically displays connections to higher-order

areas of the temporal cortex such as inferior, ventral, and lateral temporal areas; as well as temporoparietal junction and mesial temporal cortex[53,56,57]. As a consequence, it is not possible to conclude whether the aberrant pattern of connectivity of the pulvinar observed here relies on new thalamocortical projections to the temporal cortex or a mechanism of remodeling preexisting ones. Hence, the role of pulvinar in cross-modal plasticity needs to be considered and further explored in future studies.

It is worth noting that our findings add new insights to the still incipient literature on thalamocortical connectivity changes in blind humans. Even though Reislev and colleagues[58] have investigated possible differences of thalamocortical connectivity between CB and SC groups, evidence for thalamic remapping has not been found. In contrast, here we reported converging evidence that thalamic projections to/from the temporal cortex are increased as opposed to those to/from the occipital cortex. First, comparisons of the thalamic territory connecting to the temporal and the occipital (and prefrontal) cortices showed increased and decreased volume in the CB group, respectively. Second, the voxel-wise analysis pointed to an aberrant pattern of thalamocortical connectivity involving pulvinar/lateral posterior nucleus, LGN, MGN, among others.

Our findings are in accordance with previous studies that described an expansion of different sensory territories on the thalamus, including the auditory, over deprived visual nuclei. Interestingly, studies have shown impairment of pulvinar microstructure and volume in blind humans[4,9]. LGN is the main thalamic relay of the visual system, often associated with cross-modal plasticity. Animal studies suggest that neurons on the LGN territory convey auditory information to the visual cortex since they receive inputs from the inferior colliculus, a mesencephalic auditory nucleus[39,45,46,59]However, ectopic projections of the inferior colliculus to the LGN and then to V1 are diffuse and disorganized[60], which makes it very unlikely to explain all the phenomena of cross-modal plasticity in blinds. Instead, thalamocortical and cortico-cortical plasticity have been hypothesized as additional pathways by which non-visual information reaches the visual cortex[34].

Over the past years, several authors have described increased cortical thickness in the blind brain[5,13,28,61,62], which can be explained by the lack of correct pruning during ontogenesis due to insufficient input[61,63,64]. In the present study, congenitally blind

individuals displayed greater thickness of the left but not the right V1 (BA 17), when compared with sighted controls. Despite the increase of cortical thickness in blinds has been reported bilaterally in previous studies, most prominent results are often reported in the left occipital cortex in right-handers[28,62], indicating lateralization effects of plasticity in blinds. Indeed, the visual cortex is highly lateralized for a wide range of stimuli[65–68] Non-visual tasks, such as spatial and pitch discrimination of sounds[26], voice perception[69] and recognition[27], sound localization[29], syntactic[21] and semantic[20] processing of sentences seem to elicit lateralized activation of visual cortex in blinds, either at right or left hemisphere. In addition, the lateralization of functional connectivity to associative brain areas has also been reported[26,70]. Due to the nature of hemispheric dominance of the visual cortex that differently affects both hemispheres depending on the task, it is hard to precise what aspects of brain plasticity underpin the left lateralization of increased cortical thickness in congenitally blinds. One possible mechanism affecting specifically the left V1 is that input to V1 seems to be a critical part of cortical maturation and pruning[61,63,64]. Indeed, we found evidence of left-lateralized impairment effects on thalamo-occipital connections in CB. Thus, the involvement of thalamocortical connectivity in this phenomenon should be addressed in future studies.

We did not find evidence of thalamic remapping of connections to the somatosensory and motor cortices, for example, in CB. However, careful interpretation of the results must consider two key points. First, the connectivity-based segmentation of the thalamus used in the present study is a 'winner-takes-all' approach in which most probable connections are considered while the least probable ones are discarded. Hence, plasticity involving somatosensory and motor remodeling of thalamic connections may not have been strong enough to be detected by our methods. As a result, the 'normal' pattern of thalamic segmentation, due to subtle and unnoticed thalamic remapping, would mask meaningful but less structured connections. Second, although we did not intend to assess corticocortical connections between visual and the remaining sensory modalities, this kind of direct connectivity has been reported in animal models of blindness and must be considered as a possible mechanism of cross-modal plasticity in humans. In fact, the intermodal connections during ontogenesis seem to be altered by the lack of visual input in animals[41,46,71–73]. In humans, the indirect measurement based on functional connectivity pointed to direct connections between the occipital and auditory cortex [74] and primary somatosensory cortex[75,76]. Moreover, the visual cortex of enucleated animals also displays

both abnormal corticocortical and thalamocortical connections with somatosensory, auditory, and motor areas[39], suggesting that both mechanisms may coexist to support cross-modal plasticity in blinds.

In accordance with previous studies that showed decreased FA of WM in CB[7,9–11], we observed focal impairment of WM integrity in CB individuals impacting most of the occipital connections to the associative cortical areas. Structures showing decreased FA were splenium of the corpus callosum, bilateral inferior longitudinal fasciculi, bilateral inferior fronto-occipital fasciculi, and right superior longitudinal fasciculus, which are known for their role in processing and integration of visual information. Lower FA values refer to WM integrity and myelination impairments and are commonly pointed to as a biomarker of developmental changes, axonal degeneration, and plasticity. Indeed, visual input is crucial for maturation and refinement of initial crude connectivity of the visual system[63,73,77] suggesting that decreased myelination of visual WM tracts in CB individuals might reflect the lack of maturation of the system rather than axonal degeneration per se. Moreover, the thalamus also displayed reduced integrity in the CB group, indicating that microstructural impairment is not restricted to corticocortical bundles. These findings are in line with the previous study of Reislev and colleagues [58] that, using a similar approach of connectivity-based segmentation of the thalamus, reported lower FA in the thalamo-occipital and thalamo-temporal connections in both congenitally and late blind individuals. In addition to the reduced FA, previous studies suggest that the lack of visual input also impacts WM volume, compared with sighted controls[4,5,12].

In summary, the present study corroborates previous findings pointing to the blind brain as a model of a wide range of plastic phenomena. Furthermore, for the first time in humans, the remapping of thalamocortical connections, involving both unimodal and multimodal thalamic nuclei, has been described as a potential mechanism that could explain how non-visual stimuli are relayed to the 'visual' cortex, as previously described. Future studies should employ neurophysiologic approaches in order to explore the functional relevance of present findings.

ACKNOWLEDGEMENTS

We thank Ivanei Bramati for the technical support during data analysis.

FUNDING

This work was funded by the Foundation for Research Support in the State of Rio de Janeiro (FAPERJ), the National Council of Scientific and Technological Development (CNPq), the Capes Foundation, and intramural grants of the D'Or Institute for Research and Education (IDOR).

COMPETING INTERESTS

The authors report no competing interests.

REFERENCES

1. WHO. *World Report on Vision*. Vol 214.; 2019.
2. Gogate P, Gilbert C, Zin A. Severe visual Impairment and blindness in infants: Causes and opportunities for control. *Middle East African Journal of Ophthalmology*. 2011;18(2):109-114. doi:10.4103/0974-9233.80698
3. Noppeney U, Friston KJ, Ashburner J, Frackowiak R, Price CJ. Early visual deprivation induces structural plasticity in gray and white matter [1]. *Current Biology*. 2005;15(13):488-490. doi:10.1016/j.cub.2005.06.053
4. Park HJ, Jeong SO, Kim EY, et al. Reorganization of neural circuits in the blind on diffusion direction analysis. *NeuroReport*. 2007;18(17):1757-1760. doi:10.1097/WNR.0b013e3282f13e66
5. Bridge H, Cowey A, Ragge N, Watkins K. Imaging studies in congenital anophthalmia reveal preservation of brain architecture in "visual" cortex. *Brain*. 2009;132(12):3467-3480. doi:10.1093/brain/awp279
6. Shu N, Liu Y, Li J, Li Y, Yu C, Jiang T. Altered anatomical network in early blindness revealed by diffusion tensor tractography. *PLoS ONE*. 2009;4(9):1-13. doi:10.1371/journal.pone.0007228
7. Reislev NL, Dyrby TB, Siebner HR, Kupers R, Ptito M. Simultaneous Assessment of White Matter Changes in Microstructure and Connectedness in the Blind Brain. *Neural Plasticity*. 2016;2016. doi:10.1155/2016/6029241
8. Collignon O, Lassonde M, Lepore F, Bastien D, Veraart C. Functional cerebral reorganization for auditory spatial processing and auditory substitution of vision in early blind subjects. *Cerebral Cortex*. 2007;17(2):457-465. doi:10.1093/cercor/bhj162
9. Ptito M, Schneider FCG, Paulson OB, Kupers R. Alterations of the visual pathways in congenital blindness. *Experimental Brain Research*. 2008;187(1):41-49. doi:10.1007/s00221-008-1273-4
10. Shu N, Li J, Li K, Yu C, Jiang T. Abnormal diffusion of cerebral white matter in early blindness. *Human Brain Mapping*. 2009;30(1):220-227. doi:10.1002/hbm.20507
11. Leporé N, Voss P, Lepore F, et al. Brain structure changes visualized in early- and late-onset blind subjects. *NeuroImage*. 2010;49(1):134-140. doi:10.1016/j.neuroimage.2009.07.048
12. Dietrich S, Hertrich I, Kumar V, Ackermann H. Experience-related structural changes of degenerated occipital white matter in late-blind Humans-A diffusion tensor imaging study. *PLoS ONE*. 2015;10(4):1-19. doi:10.1371/journal.pone.0122863

13. Voss P, Zatorre RJ. Occipital cortical thickness predicts performance on pitch and musical tasks in blind individuals. *Cerebral Cortex*. 2012;22(11):2455-2465. doi:10.1093/cercor/bhr311
14. Sadato N, Pascual-Leone A, Grafman J, et al. Activation of the primary visual cortex by Braille reading in blind subjects. *Nature*. 1996;380(6574):526-528. doi:10.1038/380526a0
15. Büchel C, Price C, Frackowiak RSJ, Friston K. Different activation patterns in the visual cortex of late and congenitally blind subjects. *Brain*. 1998;121(3):409-419. doi:10.1093/brain/121.3.409
16. Röder B, Teder-Sälejärvi W, Sterr A, Rösler F, Hillyard SA, Neville HJ. Improved auditory spatial tuning in blind humans. *Nature*. 1999;400(6740):162-166. doi:10.1038/22106
17. Weeks R, Horwitz B, Aziz-Sultan A, et al. A positron emission tomographic study of auditory localization in the congenitally blind. *Journal of Neuroscience*. 2000;20(7):2664-2672. doi:10.1523/jneurosci.20-07-02664.2000
18. Burton H, Snyder AZ, Diamond JB, Raichle ME. Adaptive changes in early and late blind: A fMRI study of verb generation to heard nouns. *Journal of Neurophysiology*. 2002;88(6):3359-3371. doi:10.1152/jn.00129.2002
19. Wan CY, Wood AG, Reutens DC, Wilson SJ. Early but not late-blindness leads to enhanced auditory perception. *Neuropsychologia*. 2010;48(1):344-348. doi:10.1016/j.neuropsychologia.2009.08.016
20. Röder B, Stock O, Bien S, Neville H, Rösler F. Speech processing activates visual cortex in congenitally blind humans. *European Journal of Neuroscience*. 2002;16(5):930-936. doi:10.1046/j.1460-9568.2002.02147.x
21. Lane C, Kanjlia S, Omaki A, Bedny M. "Visual" cortex of congenitally blind adults responds to syntactic movement. *Journal of Neuroscience*. 2015;35(37):12859-12868. doi:10.1523/JNEUROSCI.1256-15.2015
22. Rosenbluth R, Grossman ES, Kaitz M. Performance of early-blind and sighted children on olfactory tasks. *Perception*. 2000;29(1):101-110. doi:10.1068/p3001
23. Cuevas I, Plaza P, Rombaux P, de Volder AG, Renier L. Odour discrimination and identification are improved in early blindness. *Neuropsychologia*. 2009;47(14):3079-3083. doi:10.1016/j.neuropsychologia.2009.07.004
24. de Volder AG, Catalan-Ahumada M, Robert A, et al. Changes in occipital cortex activity in early blind humans using a sensory substitution device. *Brain Research*. 1999;826(1):128-134. doi:10.1016/S0006-8993(99)01275-5
25. Gizewski ER, Gasser T, de Greiff A, Boehm A, Forsting M. Cross-modal plasticity for sensory and motor activation patterns in blind subjects. *NeuroImage*. 2003;19(3):968-975. doi:10.1016/S1053-8119(03)00114-9
26. Collignon O, Vandewalle G, Voss P, et al. Functional specialization for auditory-spatial processing in the occipital cortex of congenitally blind humans. *Proceedings of the National Academy of Sciences of the United States of America*. 2011;108(11):4435-4440. doi:10.1073/pnas.1013928108
27. Hölig C, Föcker J, Best A, Röder B, Büchel C. Crossmodal plasticity in the fusiform gyrus of late blind individuals during voice recognition. *NeuroImage*. 2014;103:374-382. doi:10.1016/j.neuroimage.2014.09.050
28. Anurova I, Renier LA, de Volder AG, Carlson S, Rauschecker JP. Relationship between Cortical Thickness and Functional Activation in the Early Blind. *Cerebral Cortex*. 2015;25(8):2035-2048. doi:10.1093/cercor/bhu009
29. Gougoux F, Zatorre RJ, Lassonde M, Voss P, Lepore F. A functional neuroimaging study of sound localization: Visual cortex activity predicts

performance in early-blind individuals. *PLoS Biology*. 2005;3(2):0324-0333. doi:10.1371/journal.pbio.0030027
30. Stevens AA, Snodgrass M, Schwartz D, Weaver K. Preparatory activity in occipital cortex in early blind humans predicts auditory perceptual performance. *Journal of Neuroscience*. 2007;27(40):10734-10741. doi:10.1523/JNEUROSCI.1669-07.2007
31. Voss P, Gougoux F, Zatorre RJ, Lassonde M, Lepore F. Differential occipital responses in early- and late-blind individuals during a sound-source discrimination task. *NeuroImage*. 2008;40(2):746-758. doi:10.1016/j.neuroimage.2007.12.020
32. Cohen LG, Celnik P, Pascual-Leone A, et al. Functional relevance of cross-modal plasticity in blind humans. *Nature*. 1997;389(6647):180-183. doi:10.1038/38278
33. Zangaladze A, Epstein CM, Grafton ST, Sathian K. Involvement of visual cortex in tactile discrimination orientation. *Nature*. 1999;401(6753):587-590. doi:10.1038/44139
34. Bavelier D, Neville HJ. Cross-modal plasticity: Where and how? *Nature Reviews Neuroscience*. 2002;3(6):443-452. doi:10.1038/nrn848
35. Falchier A, Clavagnier S, Barone P, Kennedy H. Anatomical evidence of multimodal integration in primate striate cortex. *Journal of Neuroscience*. 2002;22(13):5749-5759. doi:10.1523/jneurosci.22-13-05749.2002
36. Kingsbury MA, Lettman NA, Finlay BL. Reduction of early thalamic input alters adult corticocortical connectivity. *Developmental Brain Research*. 2002;138(1):35-43. doi:10.1016/S0165-3806(02)00456-X
37. Rockland KS, Ojima H. Multisensory convergence in calcarine visual areas in macaque monkey. *International Journal of Psychophysiology*. 2003;50(1-2):19-26. doi:10.1016/S0167-8760(03)00121-1
38. Clavagnier S, Falchier A, Kennedy H. Long-distance feedback projections to area V1: Implications for multisensory integration, spatial awareness, and visual consciousness. *Cognitive, Affective and Behavioral Neuroscience*. 2004;4(2):117-126. doi:10.3758/CABN.4.2.117
39. Karlen SJ, Kahn DM, Krubitzer L. Early blindness results in abnormal corticocortical and thalamocortical connections. *Neuroscience*. 2006;142(3):843-858. doi:10.1016/j.neuroscience.2006.06.055
40. Hall AJ, Lomber SG. Auditory cortex projections target the peripheral field representation of primary visual cortex. *Experimental Brain Research*. 2008;190(4):413-430. doi:10.1007/s00221-008-1485-7
41. Charbonneau V, Laramée ME, Boucher V, Bronchti G, Boire D. Cortical and subcortical projections to primary visual cortex in anophthalmic, enucleated and sighted mice. *European Journal of Neuroscience*. 2012;36(7):2949-2963. doi:10.1111/j.1460-9568.2012.08215.x
42. Pallas SL, Littman T, Moore DR. Cross-modal reorganization of callosal connectivity without altering thalamocortical projections. *Proceedings of the National Academy of Sciences of the United States of America*. 1999;96(15):8751-8756. doi:10.1073/pnas.96.15.8751
43. Zhang Y, Wan S, Ge J, Zhang X. Diffusion tensor imaging reveals normal geniculocalcarine-tract integrity in acquired blindness. *Brain Research*. 2012;1458:34-39. doi:10.1016/j.brainres.2012.04.012
44. Bronchti G, Heil P, Scheich H, Wollberg Z. Auditory pathway and auditory activation of primary visual targets in the blind mole rat (Spalax ehrenbergi): I. 2-

deoxyglucose study of subcortical centers. *Journal of Comparative Neurology*. 1989;284(2):253-274. doi:10.1002/cne.902840209
45. Doron N, Wollberg Z. Cross-modal neuroplasticity in the blind mole rat spalax ehrenbergi: A WGA-HRP tracing study. *NeuroReport*. 1994;5(18):2697-2701. doi:10.1097/00001756-199412000-00072
46. Laemle LK, Strominger NL, Carpenter DO. Cross-modal innervation of primary visual cortex by auditory fibers in congenitally anophthalmic mice. *Neuroscience Letters*. 2006;396(2):108-112. doi:10.1016/j.neulet.2005.11.020
47. Smith SM, Jenkinson M, Johansen-Berg H, et al. Tract-based spatial statistics: Voxelwise analysis of multi-subject diffusion data. *NeuroImage*. 2006;31(4):1487-1505. doi:10.1016/j.neuroimage.2006.02.024
48. Behrens TEJ, Woolrich MW, Jenkinson M, et al. Characterization and Propagation of Uncertainty in Diffusion-Weighted MR Imaging. *Magnetic Resonance in Medicine*. 2003;50(5):1077-1088. doi:10.1002/mrm.10609
49. Chakravarty MM, Bertrand G, Hodge CP, Sadikot AF, Collins DL. The creation of a brain atlas for image guided neurosurgery using serial histological data. *NeuroImage*. 2006;30(2):359-376. doi:10.1016/j.neuroimage.2005.09.041
50. Chakravarty MM, Bertrand G, Hodge CP, Sadikot AF, Collins DL. The creation of a brain atlas for image guided neurosurgery using serial histological data. *NeuroImage*. 2006;30(2):359-376. doi:10.1016/j.neuroimage.2005.09.041
51. Cecchetti L, Ricciardi E, Handjaras G, Kupers R, Ptito M, Pietrini P. Congenital blindness affects diencephalic but not mesencephalic structures in the human brain. *Brain Structure and Function*. 2016;221(3):1465-1480. doi:10.1007/s00429-014-0984-5
52. Benarroch EE. Pulvinar: Associative role in cortical function and clinical correlations. *Neurology*. 2015;84(7):738-747. doi:10.1212/WNL.0000000000001276
53. Leh SE, Chakravarty MM, Ptito A. The connectivity of the human pulvinar: A diffusion tensor imaging tractography study. *International Journal of Biomedical Imaging*. 2008;2008(1). doi:10.1155/2008/789539
54. Saalmann YB, Pinsk MA, Wang L, Li X, Kastner S. Pulvinar regulates information transmission between cortical areas based on attention demands. *Science*. 2012;337(6095):753-756. doi:10.1016/S0140-6736(02)11602-3.Association
55. Theyel BB, Llano DA, Sherman SM. The corticothalamocortical circuit drives higher-order cortex in the mouse. *Nature Neuroscience*. 2010;13(1):84-88. doi:10.1038/nn.2449
56. Arcaro MJ, Pinsk MA, Kastner S. The anatomical and functional organization of the human visual pulvinar. *Journal of Neuroscience*. 2015;35(27):9848-9871. doi:10.1523/JNEUROSCI.1575-14.2015
57. Rosenberg DS, Mauguière F, Catenoix H, Faillenot I, Magnin M. Reciprocal thalamocortical connectivity of the medial pulvinar: A depth stimulation and evoked potential study in human brain. *Cerebral Cortex*. 2009;19(6):1462-1473. doi:10.1093/cercor/bhn185
58. Reislev NH, Dyrby TB, Siebner HR, Lundell H, Ptito M, Kupers R. Thalamocortical Connectivity and Microstructural Changes in Congenital and Late Blindness. *Neural Plasticity*. 2017;2017(November). doi:10.1155/2017/9807512

59. Chabot N, Charbonneau V, Laramée ME, Tremblay R, Boire D, Bronchti G. Subcortical auditory input to the primary visual cortex in anophthalmic mice. *Neuroscience Letters*. 2008;433(2):129-134. doi:10.1016/j.neulet.2008.01.003
60. Kaiserman-Abramof IR, Graybiel AM, Nauta WJH. The thalamic projection to cortical area 17 in a congenitally anophthalmic mouse strain. *Neuroscience*. 1980;5(1):41-52. doi:10.1016/0306-4522(80)90069-X
61. Jiang J, Zhu W, Shi F, et al. Thick visual cortex in the early blind. *Journal of Neuroscience*. 2009;29(7):2205-2211. doi:10.1523/JNEUROSCI.5451-08.2009
62. Park HJ, Lee JD, Kim EY, et al. Morphological alterations in the congenital blind based on the analysis of cortical thickness and surface area. *NeuroImage*. 2009;47(1):98-106. doi:10.1016/j.neuroimage.2009.03.076
63. Bourgeois JP, Jastreboff PJ, Rakic P. Synaptogenesis in visual cortex of normal and preterm monkeys: Evidence for intrinsic regulation of synaptic overproduction. *Proceedings of the National Academy of Sciences of the United States of America*. 1989;86(11):4297-4301. doi:10.1073/pnas.86.11.4297
64. Luo L, O'Leary DDM. Axon retraction and degeneration in development and disease. *Annual Review of Neuroscience*. 2005;28:127-156. doi:10.1146/annurev.neuro.28.061604.135632
65. Corballis PM, Funnell MG, Gazzaniga MS. Hemispheric asymmetries for simple visual judgments in the split brain. *Neuropsychologia*. 2002;40(4):401-410. doi:10.1016/S0028-3932(01)00100-2
66. Rossion B, Joyce CA, Cottrell GW, Tarr MJ. Early lateralization and orientation tuning for face, word, and object processing in the visual cortex. *NeuroImage*. 2003;20(3):1609-1624. doi:10.1016/j.neuroimage.2003.07.010
67. Hougaard A, Jensen BH, Amin FM, Rostrup E, Hoffmann MB, Ashina M. Cerebral asymmetry of fMRI-BOLD responses to visual stimulation. *PLoS ONE*. 2015;10(5):1-16. doi:10.1371/journal.pone.0126477
68. Davies-Thompson J, Johnston S, Tashakkor Y, Pancaroglu R, Barton JJS. The relationship between visual word and face processing lateralization in the fusiform gyri: A cross-sectional study. *Brain Research*. 2016;1644:88-97. doi:10.1016/j.brainres.2016.05.009
69. Gougoux F, Belin P, Voss P, Lepore F, Lassonde M, Zatorre RJ. Voice perception in blind persons: A functional magnetic resonance imaging study. *Neuropsychologia*. 2009;47(13):2967-2974. doi:10.1016/j.neuropsychologia.2009.06.027
70. Sabbah N, Authié CN, Sanda N, et al. Increased functional connectivity between language and visually deprived areas in late and partial blindness. *NeuroImage*. 2016;136:162-173. doi:10.1016/j.neuroimage.2016.04.056
71. Berman NEJ. Alterations of visual cortical connections in cats following early removal of retinal input. *Developmental Brain Research*. 1991;63(1-2):163-180. doi:10.1016/0165-3806(91)90076-U
72. Bock AS, Kroenke CD, Taber EN, Olavarria JF. Retinal input influences the size and corticocortical connectivity of visual cortex during postnatal development in the ferret. *Journal of Comparative Neurology*. 2012;520(5):914-932. doi:10.1002/cne.22738
73. Laramée ME, Bronchti G, Boire D. Primary visual cortex projections to extrastriate cortices in enucleated and anophthalmic mice. *Brain Structure and Function*. 2014;219(6):2051-2070. doi:10.1007/s00429-013-0623-6
74. Klinge C, Eippert F, Röder B, Büchel C. Corticocortical connections mediate primary visual cortex responses to auditory stimulation in the blind. *Journal of*

Neuroscience. 2010;30(38):12798-12805. doi:10.1523/JNEUROSCI.2384-10.2010
75. Wittenberg GF, Werhahn KJ, Wassermann EM, Herscovitch P, Cohen LG. Functional connectivity between somatosensory and visual cortex in early blind humans. *European Journal of Neuroscience*. 2004;20(7):1923-1927. doi:10.1111/j.1460-9568.2004.03630.x
76. Ioannides AA, Liu L, Poghosyan V, et al. MEG reveals a fast pathway from somatosensory cortex to occipital areas via posterior parietal cortex in a blind subject. *Frontiers in Human Neuroscience*. 2013;7(JUL):1-12. doi:10.3389/fnhum.2013.00429
77. Sengpiel F, Kind PC. The role of activity in development of the visual system. *Current Biology*. 2002;12(23):818-826. doi:10.1016/S0960-9822(02)01318-0

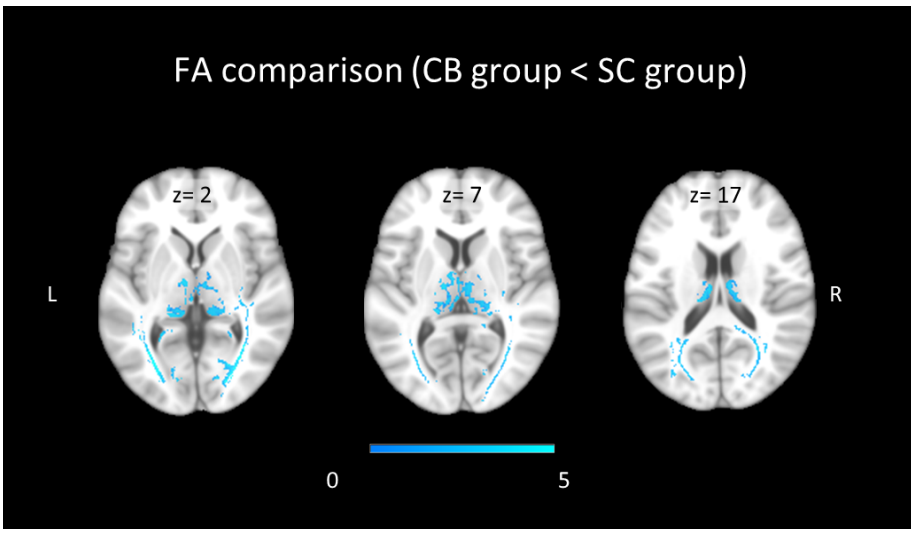

Fig.1 FA comparison (CB group < SC group). White matter tracts (whole brain) showed reduced FA (fractional anisotropy) in the CB (congenitally blinds) group, as compared to SC (sighted controls) group (family-wise error (FWE)-corrected, $p < 0.05$). FA difference in the thalamus, resulting from a separate analysis, is also displayed. Color bar represents t value corrected for multiple comparisons.

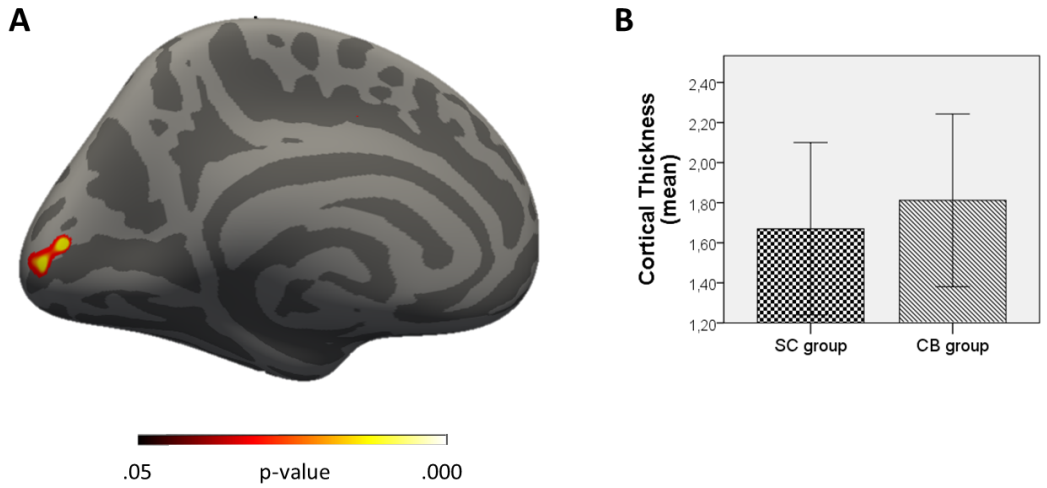

Figure 2. Increased Cortical Thickness in Blinds. (A) Increased cortical thickness in the left V1 (BA17) in the CB (congenitally blind) group compared to the SC (sighted controls) group, whole-brain analysis. (B) The mean cortical thickness (in mm) of each group is displayed for visualization of the clustered values and not for inference (error bar represents standard deviation).

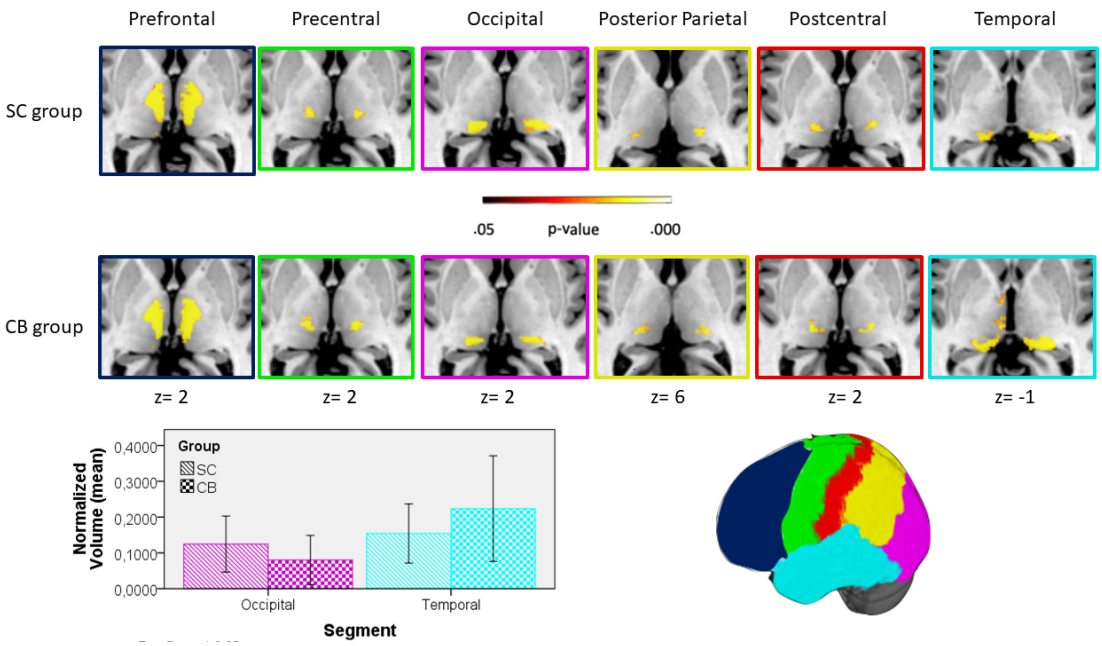

Fig. 3 Thalamocortical connectivity. Resultant thalamic segments showing statistically significant connectivity to each cortical area in the SC (sighted controls, top) and CB (congenitally blinds, middle) groups. The color of each frame denotes the according cortical area showed in the scheme (bottom right). Color bar represents p-value after FWE

correction. The normalized volume of the Occipital and Temporal segments showed group differences (p<0.001, Sidak correction for multiple comparisons). The graph bars (bottom left) are shown to illustrate the direction of the differences and not for inference (error bars represent standard deviation).

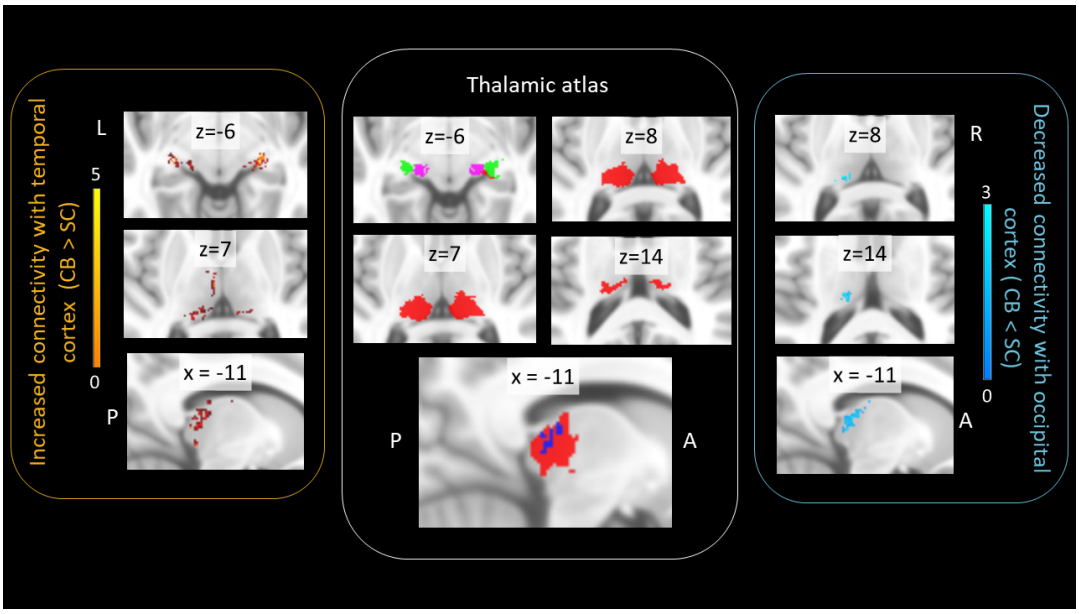

Figure 4. Thalamocortical connectivity changes in congenitally blind individuals. The yellow box (left) depicts thalamic areas that exhibited increased connectivity with the temporal cortex, including MGN, LGN and pulvinar bilaterally. The blue box (right) depicts thalamic territory that exhibited decreased connectivity with the occipital cortex in congenitally blind individuals on the left pulvinar. The white box (middle) shows thalamic territories obtained from an atlas based on the Colin-27 Average Brain[50] and depicts the location of LGN (green), MGN (pink), and pulvinar (red). A graphical overlay (dark blue) of thalamic areas that exhibited both increased connectivity to the temporal cortex and decreased connectivity to the occipital cortex (p<0.05, FWE-corrected) in congenitally blind individuals is shown (white box, bottom). L = left; R = right; A = anterior; P = posterior. The coordinates are given according to MNI space and results are plotted on the MNI standard brain. Color bars represent the t-value.