Sonodynamic therapy as an adjunctive treatment on *porphyromonas gingivalis* induced periodontitis in rats with diabetes

Yi Zhang[1], Hongbo Zhang[1,3],Deshu Zhuang[1,2,#], Liangjia Bi[1], Zheng Hu[4] and Wenwu Cao[4,5]

[1]Department of Stomatology, The Fourth Affiliated Hospital, Harbin Medical University, Harbin 150001, China

[2]Faculty of Dentistry, Department of Oral Biological and Medical Sciences, University of British Columbia, Vancouver, BC V6T 1Z3, Canada

[3]Department of Restorative Dentistry, Faculty of Dental Medicine and Graduate School of Dental Medicine, Hokkaido University, Sapporo 0600808, Japan

[4]Condensed Matter Science and Technology Institute, Harbin Institute of Technology, Harbin 150080, China

[5]Department of Mathematics and Materials Research Institute, The Pennsylvania State University, University Park, Pennsylvania 16802, USA

[*]**Corresponding Author:** Deshu Zhuang

Address: Department of Stomatology, The Fourth Affiliated Hospital, Harbin Medical University, Harbin, 150001, China

Email: stevenchuang88@126.com

Tel and fax:86-451-82576565

Abstract

Objectives: The aim of this study was to evaluate the efficacy of hematoporphyrin monomethyl ether (HMME)-mediated sonodynamic therapy (SDT) on *porphyromonas gingivalis* (Pg) and experimental periodontal disease in rats with diabetes.

Methods: Pg (ATCC 33277) was used in this study. Colony forming unit assay was performed to evaluate the bactericidal effect with different ultrasonic time and HMME concentration parameters. The intracellular content of reactive oxygen species (ROS) was detected. 36 female Wistar rats weighing 200 to 250 g were randomly divided into two groups: non-diabetic (ND; n=18) and diabetic (D; n=18). Periodontal disease was induced by orally administering Pg and placing ligatures around the cervix of the first maxillary molar. Streptozotocin (STZ) was injected intraperitoneally (60 mg/kg) to establish the diabetic rat model. After 4 weeks, the rats in each group (ND and D groups) were received one of three treatments (6 rats per treatment): irrigation with sterile saline solution (control group); scaling and root planing (SRP) (SRP group); hypodermic injection of 40 μg/mL HMME with 3 W/cm^2 low-intensity ultrasound irradiation every other day (1 MHz, 600 s) (SRP+SDT group). All rats were euthanized at 10 days postoperatively. The maxilla was taken for histological examination. The distance between the cementoenamel junction (CEJ) and the alveolar bone crest (ABC) was measured to access the level of alveolar bone.

Results: In SDT treatment, higher HMME concentration and longer ultrasound irradiation time induced more CFU reduction. 4.7 lg reduction in CFU, When Pg was

treated with ultrasound (3 W/cm^2 for 10 min) at 40 μg/mL HMME concentration (P<0.01). The intracellular ROS in SDT group had a significant difference in comparison with the control group (P<0.01). In the D group, the intragroup analysis revealed less bone loss in the SRP+SDT treatment than in the control and SRP treatment (P<0.05). Intergroup analysis (ND and D groups) showed a greater bone loss in the ND group treated with SRP compared to the D group treated with SRP+SDT.

Conclusions: SDT was an effective adjuvant therapy to SRP on induced periodontal disease and diabetes mellitus in rats.

Keywords: *porphyromonas gingivalis;* periodontitis; diabetes; sonodynamic therapy; alveolar bone loss.

Introduction

About one-half of the adult population suffers from moderate to severe periodontal diseases that are also potentially associated with diabetes mellitus [1]. The hyperglycemic environment promotes the expression of toll-like receptors in periodontal tissues, making diabetic patients more susceptible to periodontitis [2]. Diabetes mellitus also causes differentiation dysfunction of osteoblasts, and decreased the density of alveolar bone [3]. Additionally, periodontitis can affect glycemic control in diabetic patients and induce various diabetic complications [4].

Porphyromonas gingivalis (Pg), a Gram-negative and obligate anaerobe bacterium, is associated with many chronic systemic diseases, such as rheumatoid arthritis, cardiovascular diseases, diabetes mellitus and even cancers [5, 6].

Researchers have found that Pg infection induced the expressions of TNF-α and IL-6 and might be an important risk factor for diabetes mellitus [7]. Pg, as a periodontal pathogen, utilizes multiple virulence factors, such as LPS, gingipains, and cytotoxic. These virulence factors are helpful to breakdown the host-defense mechanisms, damage the connective tissue and cause the alveolar bone loss around the teeth [8]. According to the systematic and retrospective reviews, scaling and root planing (SRP) is the main treatment for periodontal disease. It can effectively eliminate the dental plaque and calculus in 85% of instrumented root surfaces when the periodontal depth of pockets was 4-6 mm. However, SRP fails to remove the bacterial toxins which hide in the connective tissue and furcation area [9, 10]. The most common adjunctive therapy of periodontitis is applying the local or systemic antibiotics. However, considering the large usage of antibiotics during the therapeutic process, many bacteria may gain resistance, particularly to the tetracyclines by limiting the drug access to the cell or generating antibiotic enzymes. Moreover, antibiotics may cause some side effects, such as nausea, xerostomia and stomachache [11].

Sonodynamic therapy (SDT) is a promising treatment for killing cancer cells using low-intensity ultrasound with sonosensitizers. When the low-intensity ultrasound reaches the target, it can activate sonosensitizers and generate reactive oxygen species (ROS) [12]. Hematoporphyrin monomethyl ether (HMME) is an effective sonosensitizer in SDT with a stable structure, lower dark toxicity, higher singlet oxygen yield to induce cell apoptosis via the mitochondrial apoptotic pathway [13]. The major advantages of SDT are its strong penetrating power, noninvasive, no

drug resistance and initiation of activity only when irradiated to ultrasound [14]. Recently, many studies have indicated satisfactory results with SDT in inhibiting bacteria such as methicillin-resistant *staphylococcus aureus* (MRSA) [15], *bacillus cereus* and *escherichia coli* [16]. Our previous study showed that HMME-mediated SDT could effectively inhibit the growth of *staphylococcus aureus* [14]. In addition, HMME combined with low-intensity ultrasound could effectively alleviate the alveolar bone loss in experimental periodontal disease in rats [17, 18].

Although SDT has been shown effective on various bacteria, sonosensitizer-mediated SDT on Pg has not been reported up to date. The purpose of this study is to evaluate the effect of HMME-mediated SDT on Pg and the role of SDT as a repeated adjunctive treatment on experimentally induced periodontal disease in rats with diabetes. SDT may be an alternative adjunctive treatment for suppressing the alveolar bone resorption in diabetics who suffer from periodontal disease.

Materials and methods

Bacterial strain and culture

Porphyromonas gingivalis (Pg) strain (ATCC 33277) was cultured in brain-heart infusion (BHI, Difco, Detroit, MI) broth which supplied with 10 μg/mL hemin (Sigma-Aldrich, USA) and 0.2 μg/mL vitamin K (Sigma-Aldrich, USA). The bacteria were cultured in a 37 □ anaerobic chamber (5% H_2, 10%CO_2, and 85% N_2). After 5 days, the Pg suspensions were diluted with a sterile saline solution and set to an optical density (OD_{630nm}) of approx 1×10^7 cells/mL.

Animals

36 adult female Wistar rats, weighing 200-250 g, from the Animal Facility of the Second Affiliated Hospital of Harbin Medical University, were used. Before the study, all rats were allowed to acclimatize to the laboratory environment for 7 days. This study was approved by the Use Committee of Harbin Medical University (Harbin, People's Republic of China), in accordance with the National Institutes of Health guide for the care and use of Laboratory animals (NIH Publications No. 8023, revised 1978).

Induction of diabetic rats

After 12 h fasting period, diabetes was induced in half of the animals by an intraperitoneal injection of 60 mg/kg of streptozotocin (STZ) (Sigma, St. Louis, MO, USA). Other rats were injected with 0.1 mol/L citrate buffer as control. Diabetes mellitus was confirmed via the caudal vein 48 h after the STZ administration by the measurement of a blood glucose levels above 300 mg/dL. Blood glucose levels were recorded before the diabetic induction and at the end of the periodontal treatment.

Experimental periodontal disease induction

Intraperitoneal anaesthesia was induced by administering ketamine (80 mg/kg) and dexedetomidine (0.6 mg/kg). The maxillary first molars of each rat received a 3-0 silk ligature around the cervix to induce experimental periodontal disease. Animals were given sulfamethoxazole (1 mg/mL) and trimethoprim (200 μg/mL) in their drinking water for 3 days to inhibit the commensal bacteria. After a 3-day resting period without antibiotics, a 500 μL mixture of 5% carboxymethyl cellulose sodium and Pg (1×10^7 cells/mL) was orally administered for 3 times, each interval 48 h. After

4 weeks, ligatures were removed from all animals. The process above was operated by the same experienced operator (Deshu Zhuang). Then the rats in each group (ND and D groups) were randomly received one of three treatments (6 rats/treatment): irrigation with sterile saline solution (control group); scaling and root planing (SRP) with a manual curette (13–14 mini-five Gracey curette, Hu-Friedy, USA) through distal-mesial traction movements in buccal and lingual areas and cervical–occlusal traction movements in furcation and interproximal areas, then irrigated with l00 μL sterile saline solution. (SRP group); SRP and hypodermic injection of 40 μg/mL HMME with 3 W/cm^2 low-intensity ultrasound irradiation every other day (1 MHz, 600 s) (SRP+SDT group).

SDT treatment *in vivo and in vitro*

The HMME sterile solution was purchased from Xianhui Pharmaceutical co., Shanghai, People's Republic of China. The HMME solution was injected into the periodontal tissue between the first and second maxillary molars using an insulin syringe (1 mL) in dark. The low-intensity ultrasound used in this study was provided by Harbin Institute of Technology (Harbin, People's Republic of China), with a frequency of 1.0 MHz, a pulse repetition frequency of 100 Hz and a duty factor of 10%. After 90 min HMME application, ultrasound was applied to the alveolar bone area between the first and second maxillary molars with a connection of medical ultrasonic coupling agent. The ultrasound was released with a diameter of 6 mm and a low intensity of 3 W/cm^2 for 600s every other day, which calibrated with a hydrophone (Onda Corp., Sunnyvale, CA, USA) in degassed distilled water. All

animals were euthanized after 10 days of periodontal treatment.

In vitro, the bacteria suspension was cultured in the 96-well plate, and positioned in a water bath and 5 cm directly away from the ultrasound transducer (diameter 3 cm, resonance frequency 1 MHz, duty factor 30%, repetition rate 100 Hz). The ultrasound intensity was 3 W/cm^2 as measured by a needle hydrophone (HNC-1000, Onda Corp., Sunnyvale, CA) inside the well. The Pg suspension was divided into five groups: SDT in different HMME concentration (10-40 μg/mL) under 10 min ultrasonic time, SDT in different ultrasonic time (2-10 min) with 40 μg/mL HMME, different HMME concentration (10-40 μg/mL) treatment alone with no ultrasound, ultrasound treatment alone in different ultrasonic time (2-10 min) with no HMME, and the control (no treatment).

Colony forming units (CFU) assay

After the SDT treatment *in vitro*, all the suspensions were diluted serially (10^{-1}-10^{-5}) using the sterile saline solution. Then cultured in Columbia blood ager (Beijing Land Bridge Technology co., LTD, China) in a 37 □ anaerobic chamber (5% H_2, 10%CO_2, and 85% N_2). After 5 days of incubation, the Pg viability was counted by CFU.

Intracellular ROS detection

The intracellular ROS was detected by using ROS assay kit (Beyotime Reagent Co., China). 10 μM DCFH-DA was added to the bacteria suspensions for 20 min incubation. The suspensions were washed three times with sterile saline solution, and the fluorescence intensity of DCFH-DA was observed under a laser scanning confocal

microscope (LSCM) at 488 nm excitation and 525 nm emission wavelengths. The level of ROS was analyzed using an Image-Pro Plus 6.0 software (Media cybernetics, USA).

Histologic and histometric analysis

The maxillas were collected and fixed in paraformaldehyde (10%) for 48h, and then placed in ethylenediaminetetraacetic acid (EDTA) demineralizing solution for 4 weeks. Paraffin serial sections of 6μm in mesio-distal direction were obtained and stained with hematoxylin and eosin (H&E), and photographed using a digital camera attached to a light microscope (Carl Zeiss, Germany). The linear distance from the CEJ to ABC in the alveolar bone area between the first and second maxillary molars was measured by an image analysis software (ImageJ, Version 1.51r, National Institute of Health, USA).

Statistical analysis

The histometric data were statistically analyzed using SPSS 22.0 software, and expressed as the mean ± standard deviation. In vitro, the differences of interblock were performed with a one-way analysis of variance (ANOVA). After the in vivo experiment, the intragroup and interblock were analyzed with a two-way ANOVA followed by Tukey's test. The statistical significance was set at $P<0.05$.

Results

CFU counting

The antibacterial efficiency of HMME-mediated SDT on Pg was showed by the CFU/mL counts. As shown in Fig. 1, after the SDT treatment, the growth of Pg

decreased when the HMME concentration increased from 10 to 40 μg/mL with 3 W/cm^2 ultrasonic intensity for 10 min. And 4.7 lg reduction in CFU When HMME concentration reached 40 μg/mL ($P<0.01$). But there was no significant effect when treated HMME alone in different concentration ($P>0.05$). As the ultrasound irradiation time increased after SDT treatment, the growth of Pg decreased rapidly (Fig. 2). There was also no significant effect when treated ultrasound alone in 2 and 4 min ultrasonic time. However, when the ultrasound irradiation time increased at 6 min, the growth of Pg reduced to 6.1 lg ($P<0.01$). And 1.5 lg reduction in CFU when the ultrasonic time was 10 min ($P<0.01$). In Fig. 3, when Pg was treated with ultrasound (3 W/cm^2 for 10 min) at 40 μg/mL HMME concentration, the number of CFU decreased 4.7 lg compared to the control group ($P<0.01$).

Production of intracellular ROS

The intracellular ROS was observed using a ROS fluorescence probe DCFH-DA by LSCM. As shown in Fig. 4, the fluorescence was present a large number of cells in the SDT group, and a part of cells in the ultrasound alone group, but a few cells in the control and HMME alone group. Furthermore, the intensity of fluorescence in SDT and ultrasound alone group had a significant difference in comparison with the control group in Fig. 5 ($P<0.01$).

Blood glucose

As shown in Table 1, there was no significant difference in blood glucose level among the animal in ND group at all experimental periods. After the STZ administration, the blood glucose level in D group presented a significant difference

compared to the initial of diabetic induction.

Histological analysis

Most specimens in ND and D control groups showed disordered connective tissue with intense inflammatory infiltrate and areas of bone resorption. In ND SRP group, there was organized bone with thin bone trabeculae in Fig 6. And specimens in D SRP group demonstrated connective tissue with scattered mild inflammatory infiltrate and bone resorption. At 10 days post-treatment, there was no inflammatory infiltrate in the well-developed connective tissue in the ND and D SRP+SDT groups. The bone trabeculae were thick and the cementum areas presented normally without resorption.

Alveolar bone loss

In the D group, Intragroup analysis revealed less bone loss in the SRP treatment compared to control treatment in Table 1 ($P<0.05$). However, there was no significant bone loss between SRP treatment and control treatment in the ND group ($P>0.05$). Both ND and D groups assessment demonstrated less bone loss in the SRP+SDT treatment than in the control and SRP treatment ($P<0.05$). Intergroup analysis (ND and D groups) showed greater bone loss in the ND group treated with SRP compared to the D group treated with SRP+SDT.

Discussion

Pg, as the major pathogenic microorganism, plays an important role in promoting the development and progression of periodontal disease [8]. Previous studies have reported that HMME combined with laser or ultrasound has an antimicrobial effect on whether Gram-positive or Gram-negative bacteria, such as MRSA, *Escherichia coli*

and even supragingival plaque [15, 16, 11]. In our previous study, HMME-mediated SDT could effectively kill more than 95% of *Staphylococcus aureus* [14]. In the present study *in vitro*, the number of Pg CFU decreased 4.7 lg compared to the control group, when treated by HMME (40 μg/mL)-mediated SDT in Fig. 3. Sun et al. [11] demonstrated that higher HMME concentration led to a stronger antimicrobial effect. Our results showed that the CFU of Pg decreased when increased the HMME concentration from 10 to 40 μg/mL in SDT. Furthermore, for same HMME concentration, the antimicrobial effect of SDT depends on the ultrasonic time. When the ultrasonic time increased from 2 to 10 min, the growth of Pg reduced 4.3 lg ($P<0.01$). The Pg suspension that received ultrasound alone treatment showed CFU reduction when the ultrasonic time rises to 6 min. Such observation is probably due to the effective antimicrobial action of ultrasound, as the previous study mentioned [14].

ROS, a general term of oxygen-containing free radicals and peroxides, is related to oxygen metabolism in bacteria [19]. In normal conditions, the production and elimination of ROS in cells are balanced. ROS can activate cellular transcription factors and promote the cell proliferation and differentiation, when it is at a low concentration. However, overproduction of ROS is more reactive than non-free radicals and easily reacts with other molecules, resulting in cell membrane lipid peroxidation, protein and DNA damage [20]. Previous studies have reported that the mechanism of SDT in cancer cells apoptosis was thought to be induced by acoustic cavitation [12, 21]. Sonosensitizers are highly sensitive and selective to metabolically active cells. When ultrasound irradiates the cells, microbubbles in the liquid are

formed and catastrophically implode, then excite the sonosensitizer to produced the excessive ROS, which irreversibly damages the cell cytoplasmic membrane, mitochondrial proteins, and eventually eradicate cells [22]. In the present study, the changes of intracellular ROS fluorescence level in four groups were observed by LSCM. Compare to the control group, the ROS fluorescence is significantly enhanced in the SDT group. These findings demonstrated that ROS was excessively generated during the HMME-mediated SDT treatment, and might be necessary to induce the antibacterial effect.

Our present in vivo study evaluated the efficacy of HMME-mediated SDT on Pg induced experimental periodontal disease in rats with diabetes. STZ was used to damage the pancreas β cells to change the pancreatic function in secretion. After the STZ administration 48 h, the blood glucose level in D group presented a significant difference compare to the initial of diabetic induction. The diabetes may increased the severity of periodontitis, and the bone loss in D group was higher than the ND group ($P<0.05$), which is in agreement with Aral et al. who evaluated bone loss both in induced-periodontitis and periodontitis with diabetes [23]. Furthermore, diabetes could increase oxidative stress, change the accumulation of advanced glycation end products, and activate inflammatory cytokine release [24]. It also enhanced alveolar bone resorption and decreased the number of osteoblasts and periodontal ligament fibroblasts [25].

Our previous studies demonstrated that HMME mediated SDT could effectively suppress the alveolar bone resorption [17]. This study compared the influence of SDT

as an adjunctive treatment on Pg induced periodontitis in rats with diabetes. The histometric analysis showed that whether in ND or in D group, less bone loss was presented in the SRP+SDT treatment than in the control and SRP treatment ($P<0.05$). In addition, intergroup analysis (ND and D groups) showed less bone loss in the D group treated with SRP+SDT compared to the ND group treated with SRP. This could be explained by the ability of ultrasound to promote angiogenesis and collagen synthesis in damaged areas [26, 27]. Gu XQ et al. found that low-intensity pulsed ultrasound could facilitate the calcium salt deposition as well as new bone maturation [28]. Another explanation might be the antibacterial activity of SDT. Studies have indicated that SDT could generate ROS, which effectively damages the bacterial membrane, protein and DNA [29]. Thus, it might restrain the bacterial colonization, alleviate the periodontium inflammation and enhance the tissue healing.

Conclusions

In summary, our present study demonstrates HMME-mediated SDT has a remarkable antibacterial effect on Pg *in vivo* and *in vitro*. The excessive generation of ROS might be a crucial part of the antimicrobial mechanism of SDT. In addition, the results indicated that HMME-mediated SDT might be a promising complementary method for treating periodontal diseases.

Acknowledgements

This work was supported by the Natural Science Foundation, Heilongjiang Province of China [grant number H2017022]; National Key Technology Support Program of China [grant number 2013BAI03B06].

Data availability Statement:

All relevant data are within the paper and its supporting information files by the link: https://www.dropbox.com/sh/yx7m5scuunoxokx/AAAUmtOza9mFBC33A2L5yLJaa?dl=0

References

[1] Oberoi SS, Harish Y, Hiremath S, Puranik M. A cross-sectional survey to study the relationship of periodontal disease with cardiovascular disease, respiratory disease, and diabetes mellitus. J Indian Soc Periodontol 2016; 20(4):446-452. doi: 10.4103/0972-124X.186946.

[2] Promsudthi A, Poomsawat S, Limsricharoen W. The role of Toll-like receptor 2 and 4 in gingival tissues of chronic periodontitis subjects with type 2 diabetes. J Periodontal Res 2014;49(3):346-54. doi: 10.1111/jre.12112.

[3] Kim JH, Lee DE, Woo GH, Cha JH, Bak EJ, Yoo YJ. Osteocytic sclerostin expression in alveolar bone in rats with diabetes mellitus and ligature-induced periodontitis. J Periodontol 2015;86(8):1005-11. doi: 10.1902/jop.2015.150083.

[4] Miranda TS, Feres M, Retamal-Valdés B, Perez-Chaparro PJ, Maciel SS, Duarte PM. Influence of glycemic control on the levels of subgingival periodontal pathogens in patients with generalized chronic periodontitis and type 2 diabetes. J Appl Oral Sci 2017;25(1):82-89. doi: 10.1590/1678-77572016-0302.

[5] Jeong E, Lee JY, Kim SJ, Choi J. Predominant immunoreactivity of *Porphyromonas gingivalis* heat shock protein in autoimmune diseases. J Periodontal Res 2012;47(6):811-6. doi: 10.1111/j.1600-0765.2012.01501.x.

[6] Peters BA, Wu J, Pei Z, Yang L, Purdue MP, Freedman ND, Jacobs EJ, Gapstur SM, Hayes RB, Ahn J. Oral Microbiome Composition Reflects Prospective Risk for Esophageal Cancers. Cancer Res 2017;77(23):6777-6787. doi: 10.1158/0008-5472.

[7] Kang W, Wang T, Hu Z, Liu F, Sun Y, Ge S. Metformin inhibits *Porphyromonas gingivalis* lipopolysaccharide-influenced inflammatory response in human gingival fibroblasts via regulating activating transcription factor-3 expression. J Periodontol 2017;88(10):e169-e178. doi: 10.1902/jop.2017.170168.

[8] Zhou W, Zhang X, Zhu CL, He ZY, Liang JP, Song ZC. Melatonin receptor agonists as the "Perioceutics" agents for periodontal disease through modulation of *Porphyromonas gingivalis* virulence and inflammatory response. PLoS One 2016;11(11):e0166442. doi: 10.1371/journal.pone.0166442.

[9] Assem NZ, Alves MLF, Lopes AB, Gualberto EC Junior, Garcia VG, Theodoro LH. Antibiotic therapy as an adjunct to scaling and root planing in smokers: a systematic review and meta-analysis. Braz Oral Res 2017;31:e67. doi: 10.1590/1807-3107BOR-2017.vol31.0067.

[10] Monje A, Kramp AR, Criado E, Suárez-López Del Amo F, Garaicoa-Pazmiño C, Gargallo-Albiol J, Wang HL. Effect of periodontal dressing on non-surgical periodontal treatment outcomes: a systematic review. Int J Dent Hyg 2016;14(3):161-7. doi: 10.1111/idh.12130.

[11] Sun Y, Xing D, Shen L, Sun M, Fang M, Bi L, Sui Y, Zhang Z, Cao W. Bactericidal effects of hematoporphyrin monomethyl ether-mediated photosensitization against pathogenic communities from supragingival plaque. Appl

Microbiol Biotechnol 2013;97(11):5079-87. doi: 10.1007/s00253-013-4903-0.

[12] Bilmin K, Kujawska T, Secomski W, Nowicki A, Grieb P. 5-Aminolevulinic acid-mediated sonosensitization of rat RG2 glioma cells in vitro. Folia Neuropathol 2016;54(3):234-240.

[13] Su X, Wang P, Wang X, Cao B, Li L, Liu Q. Apoptosis of U937 cells induced by hematoporphyrin monomethyl ether-mediated sonodynamic action. Cancer Biother Radiopharm 2013;28(3):207-17. doi: 10.1089/cbr.2012.1190.

[14] Zhuang D, Hou C, Bi L, Han J, Hao Y, Cao W, Zhou Q. Sonodynamic effects of hematoporphyrin monomethyl ether on *Staphylococcus aureus* in vitro. FEMS Microbiol Lett 2014;361(2):174-80. doi: 10.1111/1574-6968.12628.

[15] Wang X, Ip M, Leung AW, Wang P, Zhang H, Hua H, Xu C. Sonodynamic action of hypocrellin B on methicillin-resistant *Staphylococcus aureus*. Ultrasonics 2016;65:137-44. doi: 10.1016/j.ultras.2015.10.008.

[16] Wang X, Ip M, Leung AW, Yang Z, Wang P, Zhang B, Ip S, Xu C. Sonodynamic action of curcumin on foodborne bacteria *Bacillus cereus* and *Escherichia coli*. Ultrasonics 2015;62:75-9. doi: 10.1016/j.ultras.2015.05.003.

[17] Zhuang D, Han J, Bi L, Wang Y, Hao Y, Zhou Q, Cao W. Sonodynamic effect of hematoporphyrin monomethyl ether on ligature-induced periodontitis in rats. Drug Des Devel Ther 2015;9:2545-51. doi: 10.2147/DDDT.S82347.

[18] Zhuang D, Ji Z, Bi L, Wang X, Zhou Q, Cao W. Low-intensity ultrasound combined with hematoporphyrin monomethyl ether in the treatment of experimental periodontitis in rats. Biomed Res Int 2016;2016:7156716.

[19] Becerra MC, Albesa I. Oxidative stress induced by ciprofloxacin in *Staphylococcus aureus*. Biochem Biophys Res Commun 2002;297(4):1003-7.

[20] Trachootham D, Lu W, Ogasawara MA, Nilsa RD, Huang P. Redox regulation of cell survival. Antioxid Redox Signal 2008;10(8):1343-74. doi: 10.1089/ars.2007.1957.

[21] Shanei A, Sazgarnia A, Tayyebi Meibodi N, Eshghi H, Hassanzadeh-Khayyat M, Esmaily H, Attaran Kakhki N. Sonodynamic therapy using protoporphyrin IX conjugated to gold nanoparticles: an in vivo study on a colon tumor model. Iran J Basic Med Sci 2012;15(2):759-67.

[22] Shibaguchi H, Tsuru H, Kuroki M, Kuroki M. Sonodynamic cancer therapy: a non-invasive and repeatable approach using low-intensity ultrasound with a sonosensitizer. Anticancer Res 2011;31(7):2425-9.

[23] Aral CA, Kesim S, Greenwell H, Kara M, Cetin A, Yakan B. Alveolar bone protective and hypoglycemic effects of systemic propolis treatment in experimental periodontitis and diabetes mellitus. J Med Food 2015;18(2):195-201.

[24] Liu R, Bal HS, Desta T, Krothapalli N, Alyassi M, Luan Q, Graves DT. Diabetes enhances periodontal bone loss through enhanced resorption and diminished bone formation. J Dent Res 2006;85(6):510-4.

[25] Grauballe MB, Belstrom D, Ostergaard JA, Paster BJ, Schou S, Flyvbjerg A, Holmstrup P. Ligature-associated bacterial profiles are linked to type 2 diabetes mellitus in a rat model and influenced by antibody treatment against TNF-α or RAGE. Clin Exp Dent Res 2017;3(1):25-31.

[26] Mu HM, Wang LY. Effect of therapeutic ultrasound on brain angiogenesis following intracerebral hemorrhage in rats. Microvasc Res 2015;102:11-8. doi: 10.1016/j.mvr.2015.08.001.

[27] Fantinati MS, Mendonça DE, Fantinati AM, Santos BF, Reis JC, Afonso CL, Vinaud MC, Lino Rde S Júnior. Low intensity ultrasound therapy induces angiogenesis and persistent inflammation in the chronic phase of the healing process of third degree burn wounds experimentally induced in diabetic and non-diabetic rats. Acta Cir Bras 2016;31(7):463-71. doi: 10.1590/S0102-865020160070000006.

[28] Gu XQ, Li YM, Guo J, Zhang LH, Li D, Gai XD. Effect of low intensity pulsed ultrasound on repairing the periodontal bone of Beagle canines. Asian Pac J Trop Med 2014;7(4):325-8. doi: 10.1016/S1995-7645(14)60049-3.

[29] Costley D, Nesbitt H, Ternan N, Dooley J, Huang YY, Hamblin MR, McHale AP, Callan JF. Sonodynamic inactivation of Gram-positive and Gram-negative bacteria using a Rose Bengal-antimicrobial peptide conjugate. Int J Antimicrob Agents 2017;49(1):31-36. doi: 10.1016/j.ijantimicag.2016.09.034.

Figures and illustrations

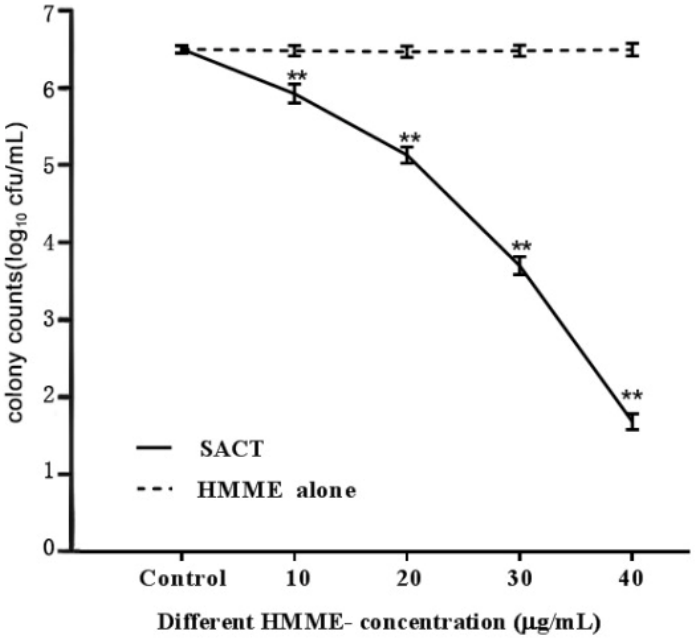

Fig.1 Reduction in CFU after SDT with variation of HMME concentration on Pg. HMME concentration ranged from 10 to 40 μg/ml were used in combination with a ultrasound intensity of 3 W/cm^2. Data represent mean values (n=10), and error bars represent standard deviations. **P <0.01 compared with the control group.

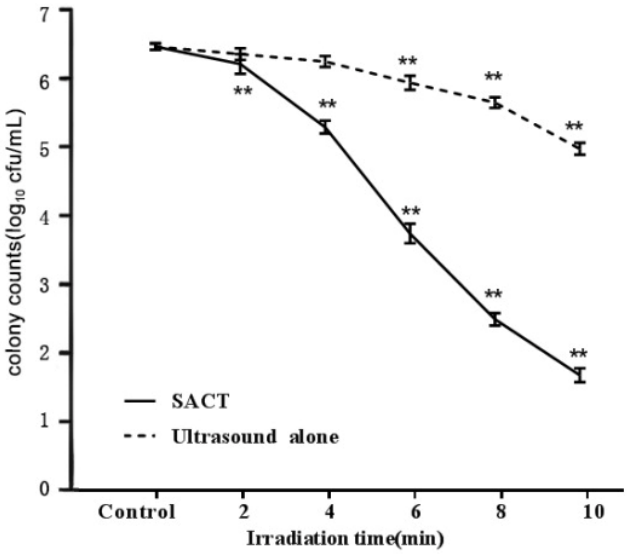

Fig.2 Reduction in CFU after SDT with variation of ultrasonic irradiation time on Pg. Ultrasonic irradiation time ranged from 2 to 10 min were used in combination with

40 μg/ml HMME concentration and 3 W/cm^2 ultrasound intensity. Data represent mean values (n=10), and error bars represent standard deviations. **P <0.01 compared with the control group.

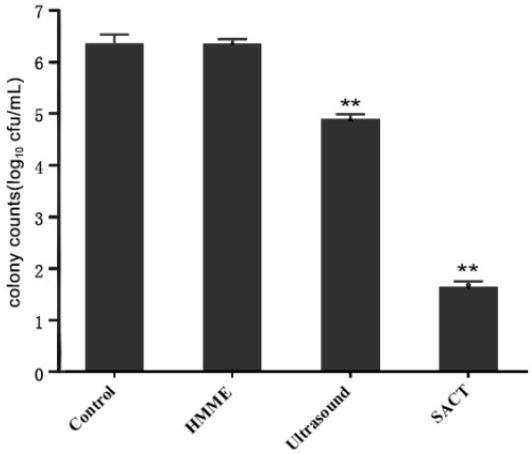

Fig.3 Influence of HMME-mediated SDT on Pg growth. Groups consisted of samples incubated with 40 μg/ml HMME in the absence of ultrasound (HMME), irradiated with 3 W/cm^2 ultrasound intensity in the absence of HMME (Ultrasound), and without ultrasound and HMME treatment (Control), respectively. Data represent mean values (n=10), and error bars represent standard deviations. **P <0.01 compared with the control group.

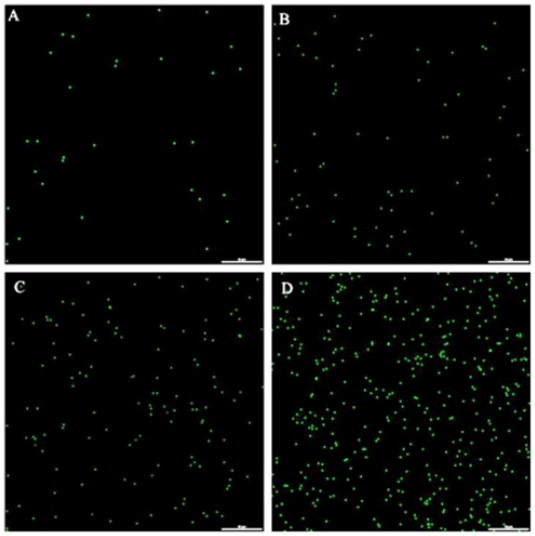

Fig.4 Intracellular ROS production induced by SDT under a LSCM by DCFH-DA.

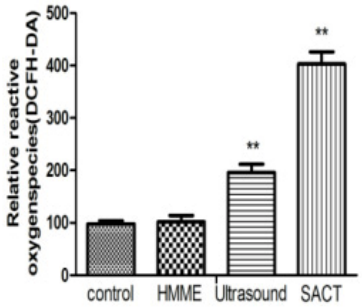

Fig.5 Fluorescence intensity of ROS induced by SDT. Data represent mean values (n=3), and error bars represent standard deviations. **P <0.01 compared with the control group.

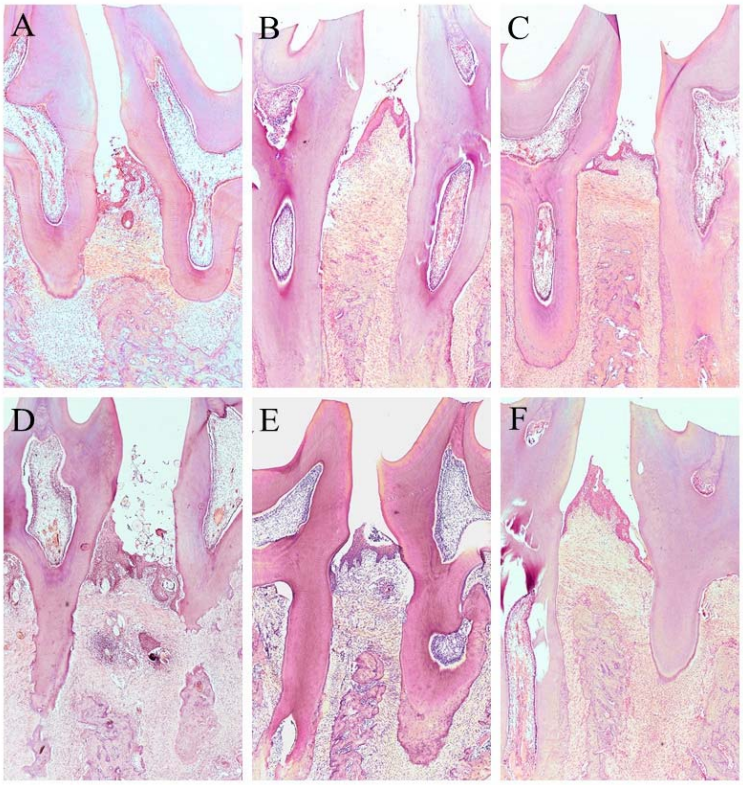

Fig.6 Photomicrographs of bone tissue in the alveolar bone region between the first and second maxillary molars with induced periodontitis.

Notes: (A) ND group: no treatment as control at 10 days. (B) ND group: SRP treatment at 10 days. (C) ND group: SRP+SDT treatment at 10 days. (D) D group: no treatment as control at 10 days. (E) D group: SRP treatment at 10 days. (F) D group: SRP+SDT treatment at 10 days. (H&E; original magnification ×4.)

Table

Table 1 Glycemic level (mg/dL; mean ± standard deviation) in different treatment and the distance between the CEJ and ABC (mm; mean ± standard deviation) in the alveolar bone region between the first and second maxillary molars.

	ND group	D group

Treatment	control	SRP	SRP+SDT	control	SRP	SRP+SDT
n	6	6	6	6	6	6
Initial blood glucose (mg/dL)	84.6±15.2	79.3±8.3	82.5±2.6	76.4±7.9	81.2±9.2	87.4±14.3
48 h blood glucose (mg/dL)	88.3±10.1	78.5±13.7	85.2±11.4	378.2±11.5*	388.3±7.7*	391.4±10.4*
Final blood glucose (mg/dL)	84.8±7.4	79.2±6.3	83.3±8.4	372.7±13.1*	390.8±10.5*	397.6±11.0*
CEJ-ABC (mm)	1.19±0.02*&	0.94±0.05&	0.56±0.01*†	1.31±0.03*&†	1.01±0.07&	0.67±0.02*†

Notes: &Significant difference compared to SRP+SDT treatment (P<0.05; ANOVA and Tukey's tests).*Significant difference between groups in the same treatment (P<0.05; ANOVA and Tukey's tests).†Significant difference compared to SRP treatment (P<0.05; ANOVA and Tukey's tests). The data is shown as means ± standard deviation, unless otherwise specified.

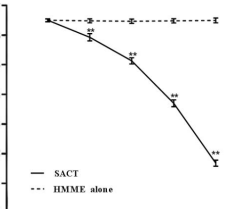
7
6
5
4
3
2
1
0
colony counts(log10 cfu/mL)
**
**
**
**
SACT
HMME alone
Control
10
20
30
40
Different HMME- concentration (µg/mL)

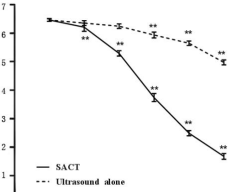
colony counts(log10 cfu/mL)
7
6
5
4
3
2
1
0
Control
2
4
6
8
10
Irradiation time(min)
SACT
Ultrasound alone
**

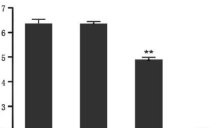
colony counts(log10 cfu/mL)
7
6
5
4
3
2
1
0
**
**
Control
HHME
Ultrasound
SACT

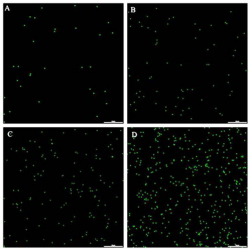
A
B
C
D

Relative reactive oxygenspecies(DCFH-DA)
500
400
300
200
100
0
**
**
control
HMME
Ultrasound
SACT

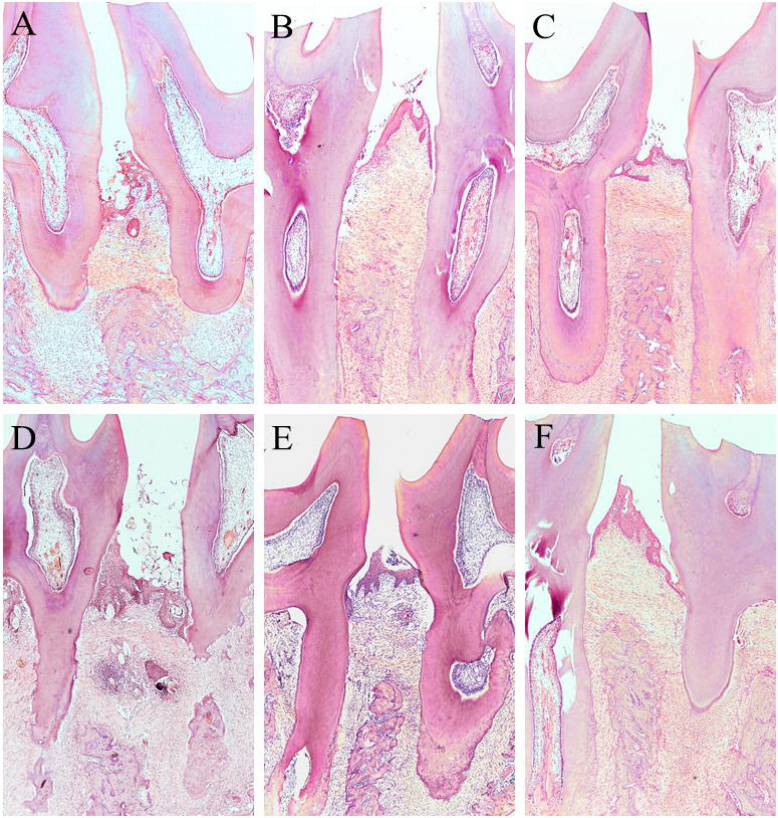
A
B
C
D
E
F