Renal Localization of *Plasmodium vivax* and Zoonotic Monkey Parasite *Plasmodium knowlesi* in Malaria Associated Acute Kidney Injury

Pragyan Acharya[1#], Atreyi Pramanik[1]*, Charandeep Kaur[1]*, Kalpana Sinha[2]*, Amit Kumar Dinda[2], Jhuma Sankar[3], Arvind Bagga[3], Sanjay Kumar Agarwal[4], Aditi Sinha[3], Geetika Singh[2]

*These authors have contributed equally

[#] Corresponding Author: pragyan.acharya@aiims.edu

Author Affiliations:

[1] Department of Biochemistry, All India Institute of Medical Sciences, New Delhi, India

[2] Department of Pathology, All India Institute of Medical Sciences, New Delhi, India

[3]Department of Pediatrics, All India Institute of Medical Sciences, New Delhi, India

[4]Department of Nephrology, All India Institute of Medical Sciences, New Delhi, India

ABSTRACT:

Acute kidney injury (AKI) is a frequent presentation in *Plasmodium vivax* (*P. vivax*) associated severe malaria. However, tissue presence of *P. vivax* parasites in the kidney has never been demonstrated. In the present study, we show that renal biopsies from malaria associated AKI patients harbor the human malaria parasite *P. vivax* and, in several cases, the zoonotic monkey malaria parasite *P. knowlesi* in addition to *P. vivax*. Presence of microvascular injury in a majority of the malaria associated AKI cases suggests vascular involvement of *P. vivax* and *P. knowlesi*. This study implicates Plasmodium species as a possible pathogenic mechanism for AKI, and suggests host renal tissue interaction of *P. vivax* and *P. knowlesi*.

INTRODUCTION:

Acute kidney injury (AKI) is a frequent presentation in severe malaria due to both *Plasmodium falciparum* and *Plasmodium vivax*- the two most common causes of malaria in the world[1–3]. AKI has been shown to have a global prevalence in about 20-50% in hospitalized malaria cases[4].The mechanism of tissue specific pathogenesis in *P. falciparum* malaria is attributed to its

cytoadherence to endothelial cells of tissue capillaries resulting in localized inflammation and tissue damage[5,6]. On the other hand, cytoadherence of *P. vivax* is still under investigation and has not been linked to pathogenesis in humans[7]. This is important to investigate since *P. vivax* in general, is expected to be more benign than *P. falciparum*. However, AKI has been well documented in hospitalized cases of *P. vivax* infection[2,3,8,9]. Therefore, it is possible that *P. vivax* has host tissue specific interaction, and may be responsible for renal injury in malaria associated AKI. Therefore, we investigated the presence of all the five *Plasmodium* species known to infect humans (*P. falciparum*, *P. vivax*, *P. knowlesi*, *P. the malariae*, and *P. ovale*) in renal biopsies of malaria cases that presented with AKI at our center. This study is a proof of concept that *Plasmodium vivax* may be directly present in host tissue. We report our observations here.

SHORT METHODS:

This study was carried out at All India Institute of Medical Sciences (AIIMS), New Delhi, as collaboration between the Departments of Biochemistry, Pathology, Pediatrics and Nephrology.

Collection of renal tissue samples: Archival formalin-fixed paraffin-embedded (FFPE) renal tissue blocks from 2011-2018 were retrieved from the Department of Pathology, AIIMS, New Delhi. The diagnosis of AKI was made using standard criteria, as defined in the Supplementary file.

Extraction of DNA from FFPE and fresh Kidney Biopsies:DNA extraction was carried out using the Qiagen QiAmp DNA FFPE tissue kit as per the manufacturer's protocol (Supplementary file).

Detection of Plasmodium species: PCR for all the five *Plasmodium* species (*P. falciparum*, *P. vivax*, *P. knowlesi*, *P. malariae* and *P. ovale*) were carried out as described in the Supplementary file. The PCR products obtained from the *P. knowlesi* positive reactions were subjected to Sanger Sequencing (Bencos Research Solutions Pvt. Ltd.) in order to confirm the species identity (The sequencing results are listed in the Supplementary File).

RESULTS:

In the present study, 16 FFPE samples with AKI and 5 controls samples (AKI without clinical, laboratory, or histopathologic evidence of malaria) collected from 2011 to 2018 were included (Table1, Supplementary file). Of the 16 cases, 12 presented with fever and associated oliguria, 1 presented with fever and associated hematuria; 1 as hematuria alone; 1 presented as AKI about one and half month after diagnosis as complicated *P. vivax* malaria; and 1 had presented with placental abruption associated with AKI (Table 1; column 2).The various histological diagnosis in these cases were – acute cortical necrosis (ACN), acute tubular injury / necrosis (ATI/ ATN), thrombotic microangiopathy (TMA), and interstitial fibrosis and tubular atrophy (IFTA). Of the 16 cases, 14 had evidences of cortical necrosis, TMA, or mesangiolysis, indicating vascular involvement (Table 1). The representative histopathology of cortical and tubular damage has been depicted in Figure 1.

The peripheral blood smears of 8 cases were found to have infection of *P. vivax* alone, and 1 showed the presence of both *P. vivax* and *P. falciparum* trophozoites; 7 cases had no evidence ofmalaria from peripheral blood smears (Table 1). Of the 7 samples with no blood smear evidence of malaria parasites, 5 were clinically diagnosed as cerebral malaria (CM), and 2 cases were not labeled as malaria infections (Table 1). Of the latter 2 cases, one presented with hematuria and one with placental abruption (Table 1).

All the 16 samples were subjected to PCR analysis of all the 5 *Plasmodium* spp. (*P. falciparum*, *P. vivax*, *P. knowlesi*, *P. malariae* and *P. ovale*). Eight cases had *P. vivax*, 1 had *P. knowlesi*, 1 had mixed infection of *P. vivax* and *P. falciparum*, 2 had mixed infections of *P. vivax* and *P. knowlesi*, 1 had mixed infection of *P. falciparum* and *P. knowlesi*, and 3 had mixed infections consisting of three parasites *P. vivax*, *P. falciparum*, and *P. knowlesi* (Table 1). Overall, of 16 cases with malaria associated AKI, the renal tissue of 14 had *P. vivax*, 7 had *P. knowlesi* and, 5 had *P. falciparum* infection. Interestingly, of the 7 cases of malarial AKI having *P. knowlesi* by PCR, 1 had been misdiagnosed as *P. vivax* from peripheral smear, and 6 had no peripheral smear detection of the parasite (Table 1). Of these latter 6 cases, 4 presented as CM with no peripheral

smear detection of the parasite, 1 had placental abruption with AKI and 1 presented with TMA and required plasmapheresis (Table 1).

DISCUSSION:

We showed evidence of direct renal presence of the human malaria parasite *Plasmodium vivax*, and the zoonotic monkey malaria parasite *Plasmodium knowlesi* in human renal biopsies of patients with AKI. We showed that of the 16 malaria cases presenting with AKI, 14 (~88%) have *P. vivax* infection. Although several studies show association of AKI with peripheral blood *P. vivax* infection[2,3,8,9] this is the first study to demonstrate direct tissue presence of the parasite. We also found that the renal tissue from 7 out of the 16 (~38%) malaria cases with AKI are infected with the zoonotic monkey parasite *P. knowlesi* (6 along with *P. vivax*, and 1 with *P. knowlesi* alone). Interestingly, of the 7 cases harboring *P. knowlesi*, 1 had been misdiagnosed as *P. vivax* and 6 had no evidence of the parasite from microscopic examination of peripheral blood smear suggesting that microscopic examination alone may not be sufficient for detection and diagnosis of *P. knowlesi*. This is the first study to demonstrate tissue infection of *P. knowlesi*. This is an important observation since the response of *P. knowlesi* to current anti-malarial therapy is not well understood [10, 11] and may affect treatment outcomes in AKI cases that have co-infections of *P. vivax* and *P. knowlesi* within the renal tissue. In addition, this also suggests that *P. knowlesi* might have tissue sequestration characteristics similar to *P. falciparum*.

We find that of the 16 cases of malaria AKI, 14 have evidence of cortical necrosis, thrombotic microangipathy, and/ or mesangiolysis indicating the involvement of the renal microvasculature. This suggests that *P. vivax*, as well as *P. knowlesi*, might have the ability to bind vasculature indicating the presence of specific receptor-ligand interactions in the renal tissue capillaries. Indeed, association studies that have been carried out with malaria associated AKI, show the association of *P. knowlesi* malaria with AKI [11]. Although the present study does not provide evidence of molecular interaction between these parasites and renal endothelial cells, this evidence suggests that specific host pathogen interactions exist, which require further investigation.

In summary, we present evidence for the presence of *P. vivax* and *P. knowlesi* in renal tissue of patients presenting with malaria associated AKI. We find that most of the histopathological

features suggest microvascular injury, and propose the presence of specific interactions between *P. vivax* and endothelial cells of tissue capillaries or *P. knowlesi* and tissue capillaries, that may be similar to *P. falciparum* infections.

Acknowledgements:

P.A. thanks SERB [Grant no. ECR/2016/000833] for funding. AP thanks DBT, CK thanks CSIR and SERB. All authors thank study participants.

The authors declare no conflict of interest.

REFERENCES:

1. Plewes, K. *et al.* Cell-free hemoglobin mediated oxidative stress is associated with acute kidney injury and renal replacement therapy in severe falciparum malaria: An observational study. *BMC Infect. Dis.***17**, 313–325 (2017).

2. Kochar, D. K. *et al.* Clinical features of children hospitalized with malaria - A study from Bikaner, Northwest India. *Am. J. Trop. Med. Hyg.***83**, 981–989 (2010).

3. Siqueira, A. M. *et al.* Characterization of Plasmodium vivax-associated admissions to reference hospitals in Brazil and India. *BMC Med.***13**, 57–71 (2015).

4. Sitprija V. Nephropathy in falciparum malaria. *Kidney Int.* 3**4**(6):867-77. (1988)

5. Storm, J. & Craig, A. G. Pathogenesis of cerebral malaria - inflammation and cytoadherence. *Front. Cell. Infect. Microbiol.***4**, 1–8 (2014).

6. Autino, B., Corbett, Y., Castelli, F. & Taramelli, D. Pathogenesis of malaria in tissues and blood. *Mediterr. J. Hematol. Infect. Dis.***4**, e2012061 (2012).

7. Totino, P. R. & Lopes, S. C. Insights into the cytoadherence phenomenon of Plasmodium vivax: The putative role of phosphatidylserine. *Front. Immunol.***8**, 1–6 (2017).

8. Kimmatkar, P. *et al.* Acute kidney injury in patients with Plasmodium vivax malaria: Clinicohistopathological profile. *Saudi J. Heal. Sci.***5**, 138–141 (2016).

9. Dr Ashwini Kumar Nigam, Dr Akhilesh Kumar Singh, D. A. & Gautam, D. B. K. G. Profile of Acute Kidney Injury in Plasmodium Vivax Malaria. *J. Med. Sci. Clin. Reasearch***05**, 27043–27049 (2017).

10. Amir, A., Cheong, F. W., de Silva, J. R., Liew, J. W. K. & Lau, Y. L. Plasmodium knowlesi malaria: current research perspectives. *Infect. Drug Resist.***11**, 1145–1155 (2018).

11. Barber, B. E. *et al.* Intravascular haemolysis in severe Plasmodium knowlesi malaria: Association with endothelial activation, microvascular dysfunction, and acute kidney injury. *Emerg. Microbes Infect.***7**, 106–116 (2018).

Table 1. Summary of clinical presentation of AKI in patients with malaria infection, with PCR diagnosis of the five *Plasmodium* species infecting humans.

Lab Id	Age (Years) / Sex	Clinical presentation	Laboratory investigations	Blood Smear evidence	Histology	PCR diagnosis
AIIMSK7167	6/F	Fever, oliguria	Thrombocytopenia, anemia, hyperkalemia, deranged RFT, LDH elevated urine: proteinuria (2+), 10-15 RBC/hpf	*Pv* trophozoites	ACN (45-50%), viable area-ATI, Arteries and arterioles unremarkable	*Pk*
AIIMSK8299	23/F	Sudden onset placental abruption	Sudden rise of creatinine (4.2 mg/dl)	Nil	Patchy ACN	*Pv* + *Pk*
AIIMSK6691	22/M	Fever &edema 1month, hematuria, hypertensive retinopathy,CM	Low C3 level, LDH elevated, urine: RBCs full field	Nil	ATI and subacute TMA	*Pf* + *Pk*
AIIMSK1056	8/M	Fever, oliguria,CM	Creatinine-3.6 mg/dl, thrombocytopenia	Nil	ACN (70-75%), viable single artery- fibrin thrombus (TMA)	*Pk* + *Pv*
AIIMSK3873	30/M	Fever, oliguria-3 months,CM	Creatinine-5.9mg/dl, proteinuria (2+), HD dependent	Nil	Patchy cortical necrosis (scarring phase), acute interstitial nephritis, vessels -UR	*Pv*+*Pk*+*Pf*
AIIMSK0447	37/F	hematuria	Case of TMA on PLEX, on rituximab	Nil	Chronic TMA	*Pv* + *Pk* + *Pf*
AIIMSK4424	17/M	Fever, right-sided hemiplegia, oliguria-15 days,CM	Deranged RFT, LDH elevated	Nil	ATN, interstitial inflammation, IFTA (20%)	*Pv* + *Pk* + *Pf*
AIIMSK0014	18/F	Fever, jaundice, oliguria	Creatinine-7.2 mg/dl, thrombocytopenia, proteinuria (2+), raised LDH, HD-dependent,	*Pv* and *Pf* trophozoites	Multifocal cortical necrosis with scarring, ATI, chronic TMA	*Pv* + *Pf*
AIIMSK7559	20/F	Complicated malaria (one and half months back), Sepsis, anuria, myocarditis	Creatinine-4.1, thrombocytopenia, proteinuria (2+), HD dependent	*Pv* trophozoites	ACN (60%)	*Pv*
AIIMSK2788	22/F	Fever, oliguria, melena, jaundice, cardiac dysfunction	Creatinine-9.4, thrombocytopenia, proteinuria (1+)	*Pv* trophozoites	Patchy ACN	*Pv*
AIIMSK6701	11/F	Fever-10 days, oliguria-3 days, epistaxis, splenomegaly,	Creatinine-7.9 mg/dl, thrombocytopenia, urine: proteinuria (2+), 15-20 RBC/hpf, raised LDH	*Pv* trophozoites	Resolving ACN, AIN, mesangiolysis, arterioles-vacuolization & endothelial swelling	*Pv*
AIIMSK6683	12/M	Fever & oliguria-3 days, epistaxis, melena, splenomegaly	Creatinine-10.3 mg/dl, thrombocytopenia, urine: proteinuria (1+), 8-10RBC/hpf, raised LDH	*Pv* trophozoites	Resolving ATN	*Pv*
AIIMSK9006	10/F	Fever & oliguria-6 days, epistaxis, melena, splenomegaly	Creatinine-6.2 mg/dl, thrombocytopenia, urine: proteinuria (4+), 8-10 RBC/hpf, raised LDH	*Pv* trophozoites	ATN, TMA	*Pv*
AIIMSK7384	19/M	Fever & oliguria-3 days, epistaxis, melena, splenomegaly, CM	Creatinine-4 mg/dl, thrombocytopenia, urine: proteinuria (2+), 8-10 RBC/hpf, raised LDH	Nil	Focal ACN, TMA, blackish-brown pigments glomerulus, tubules &interstitium	*Pv*
AIIMSK3326	18/F	Fever-7 days, epistaxis, hypertension, coma, anemia, oliguria-15 days	Creatinine-9.8 mg/dl, thrombocytopenia, urine: proteinuria (4+), 15-20 RBC/hpf, raised LDH	*Pv* trophozoites	Resolving ATN with focal mesangiolysis	*Pv*

AIIMSK6641	9/F	Fever-10 days, oliguria-2 days, splenomegaly	Creatinine-6.5 mg/dl, thrombocytopenia, proteinuria (1+), raised LDH	*Pv* trophozoites	Resolving ATN with AIN. Arteries and arterioles-endothelial swelling	*Pv*

Abbreviations: ACN; Acute Cortical Necrosis, ATI; Acute Tubular Injury, TMA; Thrombotic Microangiopathy, AIN: Acute Interstitial Nephrosis, IFTA; Interstitial Fibrosis Tubular Atrophy, RFT; Renal Function Test, HD; Hemodialysis; CM: Complicated Malaria, LDH: Lactate Dehydrogenase Pf: Plasmodium falciparum; Pv: Plasmodium vivax; Pk: Plasmodium knowlesi. Plasmodium ovale and Plasmodium malariae were not detected in these samples.

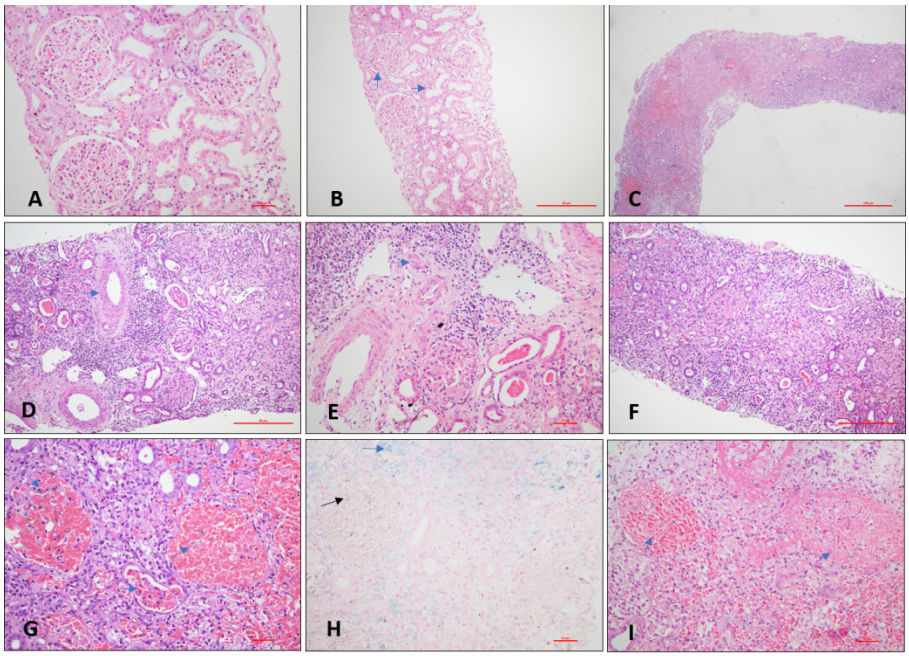

Figure 1: Photomicrograph depicting single linear core of renal parenchyma showing normal kidney cortex **(A)** comprising of normal glomerulusand tubules (**blue arrow**) and interstitium **(B)**. Single core of renal cortex and medulla displaying diffuse cortical necrosis containingnecrosed glomeruli, tubules and blood vessels with interstitial haemorrhage involving 70%of the biopsied cortex and viable inflamed area (30%) **(C)**.Moderate mixed interstitial inflammation in the juxtamedullary area. Juxtamedullary arteries appear unremarkable**(blue arrow, D)**. Arterioles show mild medial hypertrophy with no evidence of thrombotic microangiopathy**(blue arrow, E)**.Viable cortex shows interstitial fibrosis tubular atrophy**(F)**. Glomeruli display severe mesangiolysis and congestion along with deposition ofdark brown to black pigment**(blue arrow)**. Surrounding tubules shows evidence of acute tubular injury with presence of RBCs cast along with deposition of hemosiderin and blackish brown pigment in the tubular lumen and interstitium**(blue arrow, G)**. Prussian blue stain highlights presence of iron as bright blue pigment in the tubules and interstitium**(blue arrow)** while other pigment does not take the stain in the glomerulus**(black arrow, H)**. H&E slide was kept overnight in the coplin jar immersed in saturated alcoholic picric acid solution (malarial bleach), showed absence of brownish-black pigment confirming hemozoin (**black arrow**, **I)**.