Validation study of a diffusion MRI derived vessel density biomarker for detecting viral hepatitis-b induced liver fibrosis

Yì Xiáng J. Wáng[1*] , Ben-Heng Xiao [2], Li-Fei Wang[3], Shi-Wen Qiu[1], Yong-Xing Yun[3], Hua Huang[3*]

1. Department of Imaging and Interventional Radiology, Faculty of Medicine, The Chinese University of Hong Kong, Shatin, New Territories, Hong Kong SAR, China

2. Department of Biomedical Engineering, South China University of Technology, Guangzhou, Guangdong Province, China.

3. Department of Radiology, The Third People's Hospital of Shenzhen, The Second Affiliated Hospital of Southern University of Science and Technology, Shenzhen, Guangdong Province, China.

Acknowledgement: This work was partially supported by a grant from the Research Grants Council of Hong Kong SAR (Project No. 2141061) and the Sanming Project of Medicine in Shenzhen (SZSM201612053).

*Correspondence to:

Dr. Yì Xiáng Wáng. Department of Imaging and Interventional Radiology, Faculty of Medicine, The Chinese University of Hong Kong, Shatin, New Territories, Hong Kong SAR, China. Email: yixiang_wang@cuhk.edu.hk

Dr Hua Huang. Department of Radiology, The Third People's Hospital of Shenzhen, The Second Affiliated Hospital of Southern University of Science and Technology, Shenzhen, Guangdong Province, China. Email: hncz05hh@163.com

Abstract

Aim: Liver vessel density may be evaluated by a diffusion MRI surrogate biomarker DDVD (diffusion derived vessel density): DDVD/area=(Sb0-Sb1)/ROIarea; where Sb0 and Sb1 refer to the liver signal when *b* is 0 or 1 s/mm^2, and Sb1 can be replaced by Sb2 (*b*=2 s/mm^2). This concept was validated in this study.

Materials and Methods: Liver diffusion images were acquired at 1.5T, and *b*-values of 2, 0 s/mm^2 were applied. There were 26 healthy volunteers and 19 consecutive chronic viral hepatitis-b patients. Four patients did not have liver fibrosis. The liver fibrosis patients had 5, 3, 5, 2 subjects for stage-1, -2, -3 and -4 livers respectively.

Results: Mean DDVD/area [=(Sb0-Sb2)/ROIarea] was 23.28±2.07 (range: 20.18-27.21) for healthy volunteers, 23.91±0.688 (range:23.0-24.48) for chronic VHB patients without fibrosis, 19.51±0.497 (range: 18.96- 20.01) for stage-1 fibrotic livers, 18.19± 2.32 (range: 15.54- 19.92) for stage-2 fibrotic livers, and 16.00± 1.678 (range: 13.65- 17.60) for stage 3-4 fibrotic livers.

Conclusion: DDVD/area separated fibrotic and non-fibrotic livers among the cohorts in this study.

Introduction

Currently there is no established non-invasive diagnostic method to detect and grade early stage liver fibrosis. The reference standard for detection and staging of liver fibrosis remains being biopsy; however it is invasive and frequently causes pain and discomfort, with risk of bleeding and hospitalization and not suitable for longitudinal monitoring. It is well accepted that liver fibrosis is associated with reduced liver perfusion and progressive loss of endothelial fenestration and deposition of collagen in the space of Disse. These processes reduce the rate of blood flow and prolong its transit time. It is known that blood vessels show high signal when there is no diffusion gradient (b=0 s/mm^2), while show low signal even when very low b-values (such as 1 s/mm^2) is applied. Recently Wang [1] proposed the concept that liver vessel density can be measured by a diffusion weighted imaging derived surrogate biomarker (DDVD: diffusion derived vessel density):

DDVD/area = (Sb0-Sb1)/ROIarea

where Sb0 refers to the measured liver signal intensity when b=0 s/mm^2, and Sb1 refers to the measured liver signal intensity when b=1 s/mm^2. This Sb1 can also be approximated by Sb2 which is the measured liver signal intensity when b=2 s/mm^2. Sb2 may be preferable in cases when Sb1 image contains residual high vessel signal. This study aims to develop a method to calculate DDVD/area and validate its application in an image database composed of healthy livers and fibrotic livers.

Material and Methods

The MRI data were acquired during July 27, 2017 to Nov 2, 2018. This study was approved by the institutional ethical committee of The Third People's Hospital of Shenzhen, Shenzhen, China, and the informed consent was obtained for all the subjects. There were 26 healthy volunteers (14 males, 12 females, mean age: 24 yrs old; range: 20–41yrs old) and 19 consecutive patients suspected of liver fibrosis with liver biopsy results. Three patients had chronic viral hepatitis-b infection, but biopsy did not show liver fibrosis, and one patient's biopsy result showed only

mild simple steatosis. These four patients were all males, aged 19-57 yrs. The liver fibrosis patients (mean age: 46.1 yrs, range: 22-67 yrs; 11 males and 4 females) had 5, 3, 5, 2 subjects for stage-1, -2, -3 and -4 livers respectively, all with chronic viral hepatitis-b. One patient additionally had hepatocellular carcinoma.

The IVIM type of diffusion scan was based on a single-shot spin-echo type echo-planar sequence using a 1.5-T magnet (Achieva, Philips Healthcare, Best, Netherlands), with 15 *b*-value images of 2, 0, 1, 15, 20, 30, 45, 50, 60, 80, 100, 200, 300, 600, 800 s/mm^2 acquired. SPIR technique (Spectral Pre-saturation with Inversion-Recovery) was used for fat suppression. Respiratory-gating was applied in all scan participants and resulted in an average TR of 1600 ms, and the TE was 63 ms. Other parameters included slice thickness =7 mm and inter-slice gap 1mm, matrix= 124×97, FOV =375 mm×302 mm, NEX=2, number of slices =6.

Images with *b*=values of 0, 2 s/mm^2 were used in the current study, while the images of *b*-values of 15 ~ 800 s/mm^2 have been analyzed and reported using IVIM analysis approach with all volunteers and 16 patients [2]. Data analysis was implemented in a custom program developed on MATLAB (Mathworks, Natick, MA, USA). Only the liver tissue right to the right border of the vertebral body was included for analysis. Based on the *b*=0 s/mm^2 image, regions-of-interests (ROIs) were placed to cover the right liver parenchyma. ROIs were then copied and pasted on *b*=2 s/mm^2 images. Since liver fibrosis mainly affect small/micro- vessels, while in severe fibrosis big vessels may even be dilated [3,4], this study removed big vessels from analysis. For this purpose, on the *b*=0 s/mm^2 image we evaluated and selected a threshold to remove all visible vessel pixels which were of bright signal; on the *b*=2 s/mm^2 image, we evaluated and selected a threshold to remove all visible vessel pixels which were of 'signal void'. Then, for both *b*=0 s/mm^2 image and *b*=2 s/mm^2 image, only the pixels within the range of these two threshold were kept. If we assume that the liver motion was minimal between the acquisition of *b*=0 s/mm^2 image and *b*=2 s/mm^2 image, then theoretically the vessels removed on *b*=0 s/mm^2 image and *b*=2 s/mm^2 image (or *b*=1 s/mm^2 image) would be the same.

In practice, based on visual assessment, the threshold to remove bright signal vessels was determined to be 35% higher than the mean signal of all pixels in the ROI; the threshold to

remove signal void vessels was determined to be 25% lower than the mean signal of all pixels in the ROI. This criteria was applied to all images, and all results of 'vessel pixel removal process' were additionally inspected visually. It was noted that these two thresholds might have led to an 'over-kill' of some pixels, but would have ensured all pixels of pure vessel signal to be removed. The DDVD from each slice was the weighted by the number of pixels included in the ROI, then the average of the weighted mean of DDVDs of individual slice's ROIs was calculated to obtain the value of the liver.

Results

DDVD/area and DDVD/relative were acquired from all study participants. The image data of three patients (patient study ID: 06, 06, 09), who were judged to be unusable for IVIM analysis [2], could also be evaluated in this study. Mean DDVD/area was 23.28±2.07 (range: 20.18-27.21) for healthy volunteers, with a CoV of 8.9% suggesting a small variation among the volunteer participants. Mean DDVD/area was 23.91±0.688 (range: 23.0-24.48) for chronic VHB patients without fibrosis, 19.51 ±0.497 (range: 18.96- 20.01) for stage-1 fibrotic livers, 18.19± 2.32 (range: 15.54- 19.92) for stage-2 fibrotic livers, and 16.00± 1.678(range: 13.65- 17.60) for stage 3-4 fibrotic livers [Fig-1]. DDVD/area separated non-fibrotic and fibrotic livers, livers with severe fibrosis tended to have even lower measurement than those with milder liver fibrosis. On the other hand, patients without liver fibrosis showed measured value similar to healthy livers.

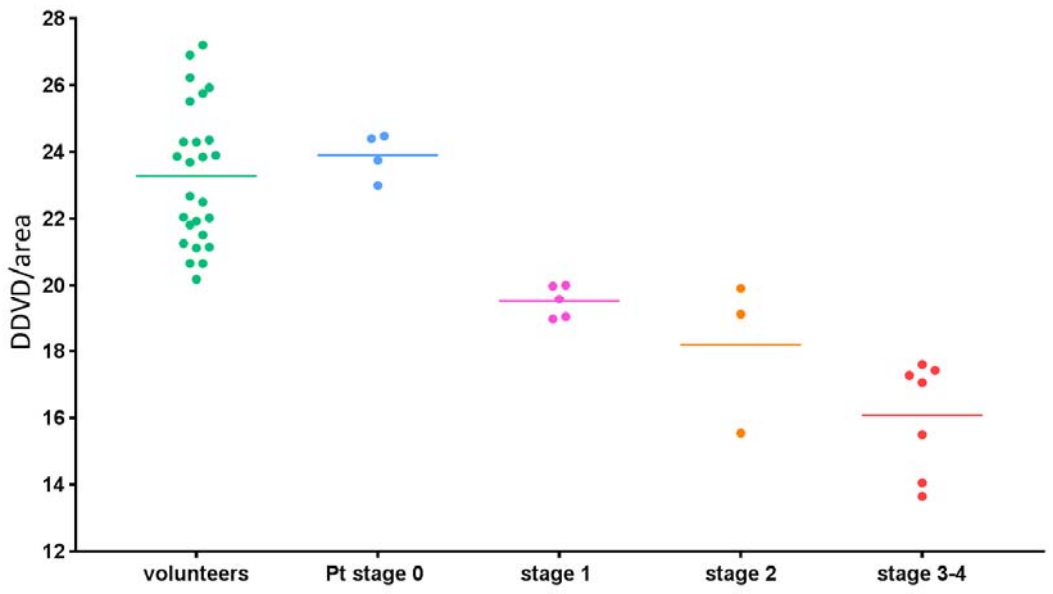

Fig-1, Liver DDVD/area of healthy volunteers, chronic viral hepatitis-b VHB without fibrosis, and stage-1, stage-3 and stage-3 and 4 fibrosis. Y-axis in relative unit.

Discussion

Wang *et al* [1, 5], Huang *et al* [2], and Li *et al* [6] recently demonstrated that Diffusion MRI derived IVIM measurements can offer high performance in detecting liver fibrosis. However, the disadvantages of IVIM measurement include long scan time to acquire multiple *b*-value imaging data, and this itself is often associated with respiration induced motion artefacts. Dfast (D*) is known to be difficult to be fitted precisely [7]. The signal difference between b=0 s/mm^2 image and b=1 or b=2 s/mm^2 images can be dramatic, particularly the vessels show high signal without diffusion gradient while show 'signal-void' when the diffusion gradient is on even at b=1 s/mm^2 [1]. This provides the basis for the analysis described in this study. Fibrosis, regenerative nodule formation, and intrahepatic vasoconstriction are classical mechanisms that account for increased intrahepatic vascular resistance in cirrhosis. Mechanisms responsible for the increase in sinusoid resistance include a mechanic factor which is a direct consequence of fibrosis deposition and a dynamic component related to endothelial dysfunction, deficient intrahepatic nitric oxide production, increased vasoconstrictor production, and other factors that promote the increased contraction of hepatic stellate cells.

The DDVD approach offered a separation of livers with and without fibrosis in the cohorts of this study, and livers with severe fibrosis tended to have even lower measurement than those with milder liver fibrosis. The same as IVIM analysis, the measures of the three patients of chronic viral hepatitis-b without fibrosis and one patient with simple steatosis resembled those of the healthy volunteers [2]. The IVIM results of yet another four patients presented by Li *et al* [6] further suggested that while pathological process of fibrosis can drive down the liver blood perfusion (as shown with decreased Dfast and PF), mere chronic viral hepatitis-b without fibrosis could have normal liver blood perfusion as well as diffusion.

Compared with IVIM approach, DDVD offers a simpler sand faster method to evaluate liver perfusion. The image data of three patients (patient study ID: 06, 06, 09, supplementary Fig-2 of reference-2) who were judged to be unusable for IVIM analysis could also be evaluated in this study [2], and provided reasonable data. As the b=2 s/mm^2 images were acquired immediately before the acquisition of b=0 s/mm^2 image, thus the respiration induced liver position displacement was not substantial for all cases. This study's image data were acquired with respiration gating as the intention of the datasets were for IVIM analysis, for studies only require DDVD analysis, then breathhold would be sufficient to acquire b=0 and b=2 b=0 s/mm^2 images.

Though for the 19 patients of the current study, DDVD alone provided a sufficient separation between non-fibrotic livers and fibrotic livers. It is also likely that a multi-parametric approach will have even better accuracy for evaluating the spectrum of chronic liver disease. As noted, it is likely that inflammation might promote perfusion [6]. For example, recently Li *et al* [6] described a HCC patient with fibrosis stage-2 and inflammation stage-2, who had diffusion MRI derived parameters suggesting rich perfusion for the parenchyma [6]. Thus, due to its relative simplicity, while DDVD may provide a first line testing, incorporating other techniques such as IVIM, liver T1/T1rho/T2 relaxivity and elastography may offer a full analysis of liver tissue characteristics.

There are a few limitations this study. As noted, the image data were acquired with respiratory gating, the b=0 s/mm^2 image and b=2 s/mm^2 image would not have been perfectly matched in anatomical location. However, the results obtained in this study is satisfactory. Our volunteers

were on average younger than the patients, so that patients groups and control group were not matched in age. All our patients had liver fibrosis due to viral hepatitis-b, whether results of our study can be generalized to liver fibrosis of other causes, such as NASH, remains to be validated. We did not control the meal status for this study, as post-meal and fasted status may influence blood flow to the liver, for future studies it can be recommended that scan subjects fast for 6 hours before liver imaging [8].

In conclusion, the DDVD approach, i.e. (Sb0-Sb2)/ROIarea, offered separation of livers with and without fibrosis in cohorts described in this study; livers with severe fibrosis tended to have even lower measurement than those with milder liver fibrosis. In combination of recent IVIM reports by Wang *et al* [1], Huang *et al* [2], and Li *et al* [6], we believe there are now strong evidences that diffusion MRI derived surrogate biomarkers can play important role in liver fibrosis management, both for detection as well as longitudinal monitoring. It can be expected that the experience learned for liver fibrosis evaluation can also be useful for DDVD analysis of other organs and other pathologies, particularly for perfusion-rich tissues.

References

1. Wang YX. Living tissue intravoxel incoherent motion (IVIM) diffusion MR analysis without b=0 image: an example for liver fibrosis evaluation. ***Quant Imaging Med Surg*** 2019;9:127-33

2. Huang H, Che-Nordin N, Wang LF, Xiao BH, Chevallier O, Yun YX, Guo SW, Wáng YX. High performance of intravoxel incoherent motion diffusion MRI in detecting viral hepatitis-b induced liver fibrosis. *Ann Transl Med* 2019;7:39

3. Blendis L, Wong F. The hyperdynamic circulation in cirrhosis: an overview. ***Pharmacol Ther.*** 2001;89:221-31

4. Lonjedo E, Ripollés T. Vascular imaging and interventional procedures in hepatic cirrhosis. ***Semin Ultrasound CT MR***. 2002;23:130-40

5. Wáng YX, Deng M, Li YT, Huang H, Leung JCS, Chen W, Lu PX. A Combined Use of Intravoxel Incoherent Motion MRI Parameters Can Differentiate Early-Stage Hepatitis-b Fibrotic Livers from Healthy Livers. ***SLAS Technol.*** 2018;23:259-268

6. Li T, Che-Nordin N, Wáng YX, Rong PF, Qiu SW, Zhang SW, Zhang P, Jiang YF, Chevallier O, Zhao F, Xiao XY, Wang W. Intravoxel incoherent motion derived liver perfusion/diffusion readouts can be reliable biomarker for the detection of viral hepatitis B induced liver fibrosis. ***Quant Imaging Med Surg*** 2019;9(3):371-385

7. Zhang Q, Wang YX, Ma HT, Yuan J. Cramér-Rao bound for Intravoxel Incoherent Motion Diffusion Weighted Imaging Fitting. ***Conf Proc IEEE Eng Med Biol Soc*** 2013;2013:511-4

8. Regini F, Colagrande S, Mazzoni LN, Busoni S, Matteuzzi B, Santini P, Wyttenbach R. Assessment of Liver Perfusion by IntraVoxel Incoherent Motion (IVIM) Magnetic Resonance-Diffusion-Weighted Imaging: Correlation With Phase-Contrast Portal Venous Flow Measurements. ***J Comput Assist Tomogr*** 2015;39:365-72