Lop-eared rabbits have more aural and dental problems than erect-eared rabbits: a rescue population study

Jade C. Johnson and Charlotte C. Burn

The Royal Veterinary College, Hawkshead Lane, North Mymms, AL9 7TA, UK

Corresponding author: Charlotte Burn, The Royal Veterinary College, Hawkshead Lane, North Mymms, AL9 7TA, UK, Tel: 01707 666333; email: cburn@rvc.ac.uk

Abstract

This research aimed to assess whether rabbits having lop-ears is a welfare issue by investigating the occurrence of aural and dental pathology in lop-eared compared with erect-eared rabbits.

Thirty rabbits (15 lop-eared and 15 erect-eared) from a rabbit-only rescue shelter were examined. An otoscope was used to visualise the ear canals and mouth. Samples were taken from each ear to examine for mites, bacteria and yeast. Medical records were also examined.

Lop-eared rabbits showed statistically significantly more frequent ear canal stenosis, higher scores of cerumen and erythema, and more frequent potential pain response during ear examination, compared with erect-eared rabbits. We also found statistically significantly more frequent incisor pathology, molar overgrowth, molar sharpness, molar spurs and history of veterinary dental treatment in lop-eared compared with erect-eared rabbits. The effect sizes were often large. Age was not statistically significant between the lop- and erect-eared rabbit groups.

Thus, lop-eared rabbits are at an increased risk of aural and dental pathology. This brings into debate the ethics of breeding and buying lop-eared rabbits, as they are more likely to suffer conditions that negatively impact welfare, such as pain, and potentially deafness and difficulty eating.

Key words: Animal welfare, Conformation; Dental pathology; Otitis; Rabbits; Veterinary Research

Introduction

Breeding animals for extreme traits is coming under scrutiny, and has thus far mostly focused on dogs[1-3]. However, the ethics of breeding extreme rabbit conformations, such as pendulous ears and brachycephaly, is also starting to be debated[4, 5]. Lops are among the most common pet rabbit breed groups, representing 57% (n=58/102) and 36% (n=449/1254) of pet rabbits in England according to two surveys by Mullan and Main (2006) and Rooney et al. (2014), respectively. They also recently comprised 58.1% of known rabbit breeds advertised via Pets4Homes, a popular free pet advertisement and information website in the UK[6]. Thus, if the lop-eared phenotype is associated with suffering, it would constitute a prevalent rabbit welfare issue. However, clear evidence of whether this is the case is lacking.

Domestication of the wild rabbit has created at least nine breeds with a lop-eared phenotype, as it is a heritable trait[7, 8]. The wild type has erect and mobile pinna due to three interdigitating auricular cartilages that provide a scaffold for the vertical ear canal[9, 10]. In contrast, lop-eared breeds have 3-5mm of soft tissue between the proximal acoustic meatus cartilage ring and the tragal cartilage of the distal ear canal, causing the pinna to fold and become pendulous[10, 11].

Charles Darwin first noted how artificial selection for pendulous pinnae in rabbits was associated with altered skull morphology[12]. Cordero and Berns (2016) found supportive evidence of this in natural woodrat populations that have likely undergone selection for long ears, finding substantial covariance of ear length and shape of the neighbouring auditory meatus[13]. This means that the lop-eared phenotype could not just affect aural function directly, but also other aspects of cranial health, such as dental function.

Potential consequences for aural health

Lop-eared rabbits have increased stenosis (narrowing) of their ear canals[9, 14, 15]. This, along with ear canal occlusion by the pinna, is believed by some veterinary professionals to reduce airflow and hinder expulsion of cerumen (or 'earwax')[10, 11, 14]. Cerumen accumulation at the base of the ear in lop-eared rabbits has been suggested as a predisposing factor for otitis externa, caused by bacterial or yeast overgrowths[11, 14, 16, 17]. Mite infestation with *Psoroptes cuniculi* can also cause otitis externa, usually with extensive crusting of the pinna[10]. Veterinary professionals have observed that otitis externa can cause head shaking, ear scratching, pain, depression and inappetance in rabbits[18, 19], and if it progresses to otitis media and interna then head tilts and neurological deficits can occur[19]. Veterinary opinion suggests that deafness can result from excess cerumen accumulation, otitis interna, or chronic otitis externa or media, at least in cats and dogs[20], so it is possible that this could occur in rabbits also. Additionally, if the length of the lop ear is great, such as in English lops, then there could be increased risk of trauma to the pinnae[5].

Despite the above veterinary and animal welfare expertise suggesting impacts of the lop-eared morphology on aural health, there has been limited empirical research into the issue; we found just one empirical study specifically comparing lop-eared and erect-eared rabbits, which solely investigated aural Malassezia yeast variation, and found no significant difference[21]. Thus, there is currently little evidence to argue the ethics of breeding and buying lop-eared rabbits. Veterinary opinion is mostly formed on the basis of experience with populations requiring veterinary attention, so it is unknown whether the same associations exist in otherwise healthy rabbits. However, it is possible that they do, because canine research has found that dogs with pendulous ears have a higher risk of otitis externa

86 and an increased risk of *Malassezia species* infection, compared with dogs with erect-ears[22-
87 24]. Thus, we hypothesise that these findings may also extend to rabbits with lop-ears.

88 Potential consequences for dental health

89 Veterinary professionals have suggested that the altered skull morphology of lop-eared
90 rabbits can cause congenital malocclusion of the dental arcades, such as maxillary
91 brachygnathism (relative shortening of the lower jaw)[25]. This is also believed to occur in
92 brachycephalic and dwarf breeds including the Netherland dwarf[25, 26]. Rabbit teeth grow
93 continuously, so reduced attrition caused by malocclusion (i.e. if the upper and lower teeth
94 are mis-aligned) can cause the teeth to overgrow[10, 27]. This has animal welfare implications
95 because, if the teeth are not worn down appropriately then incisor overgrowth, elongated
96 molar tooth roots and molar spurs can occur[27]. Rabbit incisors can grow at 2-2.4mm per
97 week so problems can rapidly occur and reoccur after treatment, especially if the problem is
98 due to malocclusion and thus cannot be rectified by husbandry changes[28]. Maxillary root
99 overgrowth can penetrate the nasolacrimal duct and present as epiphora (watering of the
100 eye) and secondary dacrocystitis (infection of the lacrimal sac)[28-30]. Root elongation can put
101 pressure on sensory nerves innervating the teeth causing pain[28]. Further pain can occur if
102 overgrown incisors penetrate the soft tissue of the lips, and mandibular and maxillary molar
103 spurs can lacerate the lingual and buccal mucosa respectively[28].

104 Dental disease is a chronic condition and the resulting oral pain and physical restrictions of
105 overgrown teeth can lead to inappetance, poor body condition, and if severe can cause
106 mortality through gut stasis[29, 31]. Other presentations of dental disease due to oral discomfort
107 are hypersalivation, and a lack of grooming or caecotrophy that can lead to flystrike[27, 29, 31].

Aims and hypotheses

This research evaluated the number and type of aural and dental abnormalities in lop-eared versus erect-eared rabbit groups in a non-veterinary context: a rabbit-only rescue centre. We used two complementary sources of information: standardised direct observations of the rabbits, and medical records for the same rabbits; the latter were more heterogeneous and clinically driven than the observations, but could indicate past issues in the rabbits.

We hypothesised that, if the lop-eared phenotype leads to functional impairment, there would be significantly more aural pathology, such as ear canal stenosis, cerumen accumulation and inflammation, and dental pathology, such as incisor overgrowth and molar spurs, in lop-eared rabbits than in erect-eared rabbits.

Materials and Methods

Animals and husbandry

A convenience sample of fifteen lop-eared and fifteen erect-eared rabbits were selected for examination at a rabbit rescue centre. The sample size of 30 was chosen on the basis of feasibility, because the observations required completion within a relatively short time period, and without disrupting the husbandry routines of the rabbits at the shelter. The rabbits were selected by the rescue manager, who attempted to include a wide range of breeds and ages (where ages were known), and only included rabbits amenable to handling (for animal welfare, and health and safety reasons). She was not aware of the hypothesis, but she was aware that we would examine the ears and teeth of the rabbits as well as general health, and we did specify an equal number of lop- and erect-eared rabbits.

The rescue centre was capable of holding approximately 100 rabbits. All rabbits observed were housed in outdoor enclosures measuring at least 8ft x 6ft, which varied but typically comprised a large aviary with a hutch or shelter. Most rabbits (22/30) were housed in

133 opposite sex neutered pairs, whilst eight were singly housed, and environmental enrichment
134 included tunnels and chew toys. Water was provided *ad libitum* from bottles, and the diet
135 consisted of a twice daily supply of hay, pellets (Burgess™, Pickering), and fresh leaves and
136 vegetables.
137 Data were collected about each rabbit, including ear type (lop or erect), breed, face shape,
138 sex, age, weight, and body condition score[32]. Face shape was assessed by subjectively
139 observing the approximate length and breadth of the skull, and subsequently categorised into
140 brachycephalic (broad, short skull, particularly seen in breeds such as the Netharland Dwarf
141 and Lionhead), mesocephalic (moderately short and broad skull) and doliocephalic (narrow
142 and long skull, as seen in the wild type) based on the independent opinion of two observers.
143 Data were collected on standardised recording sheets (Supplementary material). The study
144 received ethical approval from the Royal Veterinary College's Clinical Research Ethical
145 Review Board (URN 2015 1372).
146

147 ## Aural health examination

148 Firstly, an observer (JCJ) stood quietly, approximately 1m from the enclosure, for 5 min to
149 record presence or absence of head shaking and ear scratching, and the number of bouts of
150 these. Then, the rabbit was gently restrained by an assistant whilst the observer performed a
151 subjective clinical examination as summarised in Table 1 (details can be seen in
152 supplementary information). Unfortunately, it was not possible to test inter-observer
153 reliability during the examinations, as the available assistants were not medically trained so
154 could not assess the ears or teeth. During direct observations, the observer could also not be
155 blind to ear shape, so to minimise bias, this was explicitly discussed before observations
156 started; we examined the possibility that lop-eared rabbits having conformational problems

157 could be erroneous, especially since the only scientific comparison to date had found no
158 cytological issues[21], and that science was important for debunking incorrect perceptions. We
159 were also aware of methods for interpreting and publishing studies where no statistical
160 significance was founde.g. [33, 34], which minimised any incentive to find differences where
161 none may exist.

162 The bases of the ears were palpated for swelling and the skin checked for evidence of
163 scratching. The external pinnae were observed for crusting and inflammation (erythema,
164 heat and swelling). An otoscope was used to visualise the ear canal to look for erythema,
165 stenosis, increased cerumen, abnormal masses and potential pain responses such as flinching
166 or struggling during only this part of the exam: the examination was shortened and not
167 forced if this occurred, for animal welfare reasons (if the rabbit showed this response
168 generally upon initiation of the exam then it was deemed to be due to fear, rather than pain,
169 and the rabbit was excluded from the study due to it being unable to be examined). The
170 otoscope heads were sterilised in a chlorhexidine solution between subjects.

171 Table 1. The descriptive criteria for each variable investigated statistically. The criteria are arranged
172 such that aural pathology is first described, followed by dental pathology. Full details of the data
173 collected are provided in the Supplementary information.

Examination area	**Variable for analysis**	**Criteria required for each variable to be identified as 'present'**
Aural	Stenotic ear canals	On examination the internal ear canal was deemed to be narrow, the otoscope specula was unable to be passed down the canal, or being unable to visualise down the canal due to limited space between the ear canal walls
	Potential aural pain response	• On examination the rabbit appeared painful when palpating the base of the ear, inserting the otoscope specula into the ear canal, or swabbing the ear canal 'Appeared painful' was defined as: flinching or struggling during only this part of the exam

	Cerumen of the ear canal	• On aural examination there was subjectively deemed to be increased cerumen in the ear canal. • Categories were defined as: • 0= normal low level of cerumen • 1= mild amount of cerumen • 2= moderate amount of cerumen • 3= large amount of cerumen Each ear was categorised separately, then a combined total of both ears was used for the analysis
	Erythema of the ear canal	• On aural examination there was subjectively deemed to be increased reddening of the ear canal • Categories were defined as: • 0= pale pink, normal • 1= pink • 2= dark pink • 3= red Each ear was categorised separately, then a combined total of both ears was used for the analysis
	Scratching the ears	• A bout of head shaking or ear scratching was seen during the 5 min pre-examination observation; Or there was fur loss, skin scaling or scabs around the ears on examination
	Malassezia-like yeast species	This was categorised in multiple formats: Categorisation 1: • 5 yeasts or more identified on average per 10 high power fields Categorisation 2 (presence of yeast species): • 1 yeast or more identified on average per 10 high power fields Categorisation 3 (average number of yeasts per high power field): Total number of yeasts for combined left and right ears analysed
	Aural veterinary treatment	The veterinary medical history reported a treatment for aural disease whilst the rabbit was in the rescue's care, including ear flush, ear canal surgery, and ear drop prescription
Dental	Incisor pathology	Incisor malocclusion (underbite or overbite), overgrown incisors or fractured incisors were identified on oral examination; • Or veterinary treatment for incisor pathology was recorded in the veterinary record
	Molar overgrowth	• Abnormally long molars or molars of different height to the other molars were identified on oral examination

Sharp molars	• On oral examination there was subjectively deemed to be an increased sharpness of the molars at the buccal and lingual points, but that were not severe enough to be classified as spurs
Molar spurs	• Buccal or lingual spurs were identified on oral examination; Or veterinary history of treatment for molar spurs (burring)
Oral mucosal sores	Current or scarred sores were visible on the oral mucosa on oral examination
Potential oral pain response	• The rabbit appeared painful when palpating the jaw region • The rabbit appeared painful when using the otoscope to examine the oral cavity • 'Appeared painful' was defined as: flinching or struggling during only this part of the exam •
Epiphora	• Excess discharge from the eye, a crusting or damp area below the eye, seen on gross visual examination; • Or excess discharge from the eye reported in the rescue's or veterinary history; • Or a treatment for epiphora reported, such as a tear duct flush
Dental veterinary treatment	• The veterinary medical history reported a treatment for dental disease whilst the rabbit was in the rescues care, such as incisor trimming or removal, or molar spur burring
Poor coat condition	• The coat looked unkempt on examination, such as matting of the fur
Hypersalivation	• There was deemed to be a large amount of saliva at oral examination; • Or if there was wet or crusty fur around the mouth, dewlap or front paws on examination
Lack of caecotrophy	• Caecotrophs were present in the perineal region on examination

Two samples were taken from each ear by gently inserting a sterile cotton swab into the external part of the ear canal and rotating fully three times. The samples were labelled with codes so that the observer could examine them blind to whether they originated from a rabbit with lop or erect ears. One sample from each ear was put onto a glass microscope

179 slide with liquid paraffin and then covered with a cover slip. These slides were evaluated
180 microscopically the same day using low magnification (10X) and high contrast to assess for
181 mites. The other sample was rolled onto a microscope slide, allowed to dry for 10 min and
182 then stained using Diff-quik (Rapi-Diff II stain, Atom Scientific, Cheshire) as per the
183 manufacturer guidelines. Cytological assessment began with 40X magnification to find a
184 representative area of interest, which was then evaluated using oil immersion and 100X
185 magnification, to count the average number of bacteria (cocci and rods), and yeasts across
186 10 microscopic high-power fields. Cocci were identified as well-defined, circular and blue
187 stained, and rods were identified as well-defined, rod shaped and blue stained.

188 ## Dental health examination

189 After conducting the aural examination, the rabbit's face was palpated externally for facial
190 swellings, bony protrusions along the mandible and maxilla, ability to close the mouth and
191 symmetry of the face. The examiner gently separated the lips manually using fingers and the
192 eight incisors were evaluated for pathology including malocclusion, overgrowth, fractures or
193 abnormal appearance such as horizontal ridging of the tooth surface. Then an otoscope was
194 used in the mouth to assess the molars for overgrowth, sharpness, spurs, fractures and
195 variation in tooth height. The lingual and buccal soft tissues were examined using the
196 otoscope for sores and scars indicating healed sores. Evidence of potential pain was
197 monitored for, such as flinching or struggling during only this part of the exam, and the
198 examination was again shortened if this occurred. Secondary signs of dental disease were
199 looked for including epiphora, poor coat condition, hypersalivation (also seen as wet or
200 crusty fur around the mouth and throat), and caecotrophs around the perineum.

201 ## Medical history records

202 The medical history of the rabbits whilst at the shelter was checked using hard copies of
203 veterinary records and the rescue centre's weekly health check record, especially focusing
204 on dental and aural disease and any treatments for these. This was carried out after all rabbit
205 examinations were completed, so that the examinations were not biased by knowledge of
206 existing medical conditions.

207 ## Statistical analysis

208 Where necessary, rare categories of data were collapsed together with similar categories to
209 enable statistical analysis, with the final categories as described in Table 1. IBM SPSS
210 statistics version 24 was used to carry out binary logistic regression on binary dependent
211 variables. The predictors used in the model were ear type, sex, weight and face shape. Five
212 rabbits had unknown ages (three with erect ears and two with lop ears), so, because age was
213 not a statistically significant predictor in any of the initial models, and because mean age
214 showed no significant difference between both groups (as analysed using binary logistic
215 regression: P=0.492), it was removed from the final models, allowing data from all 30
216 rabbits to be included. The following outcomes were compared in lop- and erect-eared rabbit
217 groups using binary logistic regression: incisor pathology, molar overgrowth, sharp molars,
218 epiphora, lack of caecotrophy, stenosis of the ear canal, potential aural pain, and the
219 presence of yeast.

220 However, no rabbits from the erect-eared group at all were affected for the following
221 variables: molar spurs, potential oral pain response, oral mucosal sores, poor coat condition,
222 hypersalivation, veterinary dental treatment, aural veterinary treatment, and scratching the

ears. This meant there were fewer than five values in one group, so a Fisher's exact statistical test was carried out using GraphPad Prism Version 7.

For outcomes that were recorded as continuous scores, Mann-Whitney U statistical tests were carried out using GraphPad Prism Version 7. This was the case for the average number of yeasts per high power field, cerumen in the ear canal and erythema in the ear canal.

Results

Demographics

Rabbit signalment is shown in Table 2. The known ages of the erect-eared rabbit group ranged from 5 months to 9 years, whilst those of the lop-eared rabbit group ranged from 8 months to 7 years 9 months. The mean age was not statistically different between the lop- and erect-eared groups (P=0.492). The rabbits' body weights ranged from 1.4kg to 3.5kg in both groups. The erect-eared breeds mainly consisted of cross breeds (n=10), followed by Lionheads (n=3), whilst Dwarf lops (n=3) and Mini Lops (n=3) were the most common lop-eared rabbits.

Table 2. Demographic details of the lop-eared and erect-eared rabbit groups.

Signalment	**Lop-eared**	**Erect-eared**
Mean known age +/- standard deviation (years)	4.1 +/- 2.2	3.6 +/- 2.7
Sex (Females; Males)	5; 10	7; 8
Mean body weight +/- standard deviation (kg)	2.2 +/- 0.5	2.3 +/- 0.6
Mean body condition score +/- standard deviation	3.00 +/- 0.27 Range = 2.5-3.5	3.03 +/- 0.35 Range = 2.5-3.5
Face shape	3 brachycephalic	2 brachycephalic

	6 mesaticephalic	2 mesaticephalic
	6 doliocephalic	11 doliocephalic
Breeds	Dwarf lops (x3); Mini lops (x3); Crossbreeds (x3); Cashmere lops (x2); English lop (x1); Butterfly lop (x1); Harlequin lop (x1); Frost point lop (x1)	Crossbreeds (x10); Lionheads (x3); Astrex Rex (x1); Angora (x1)

Aural health results

Statistical results are summarised in Table 3. Lop-eared rabbits had approximately forty-three times higher odds of having stenotic ear canals (OR=42.7; 95% CI: 4.2-434; P=0.002) and a statistically significantly higher erythema score of the ear canal (U=50.5; N=15; P=0.004; Figure 1), compared with erect-eared rabbits. They also had a statistically significantly higher cerumen score in the ear canal compared with erect-eared rabbits (U=24; N=30; P<0.001; Figure 2).

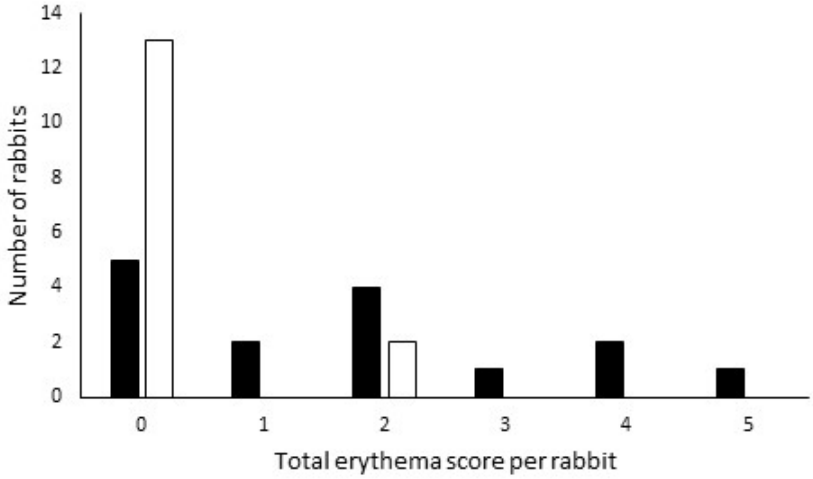

Figure 1. Frequency distribution of erythema scores in the ear canals of lop-eared and erect-eared rabbits. Black bars indicate lop-eared rabbits; white bars indicate erect-eared rabbits. Each ear was scored as follows: 0= pale pink, 1= pink, 2= dark pink, 3= red, and the added total for both ears per rabbit is shown.

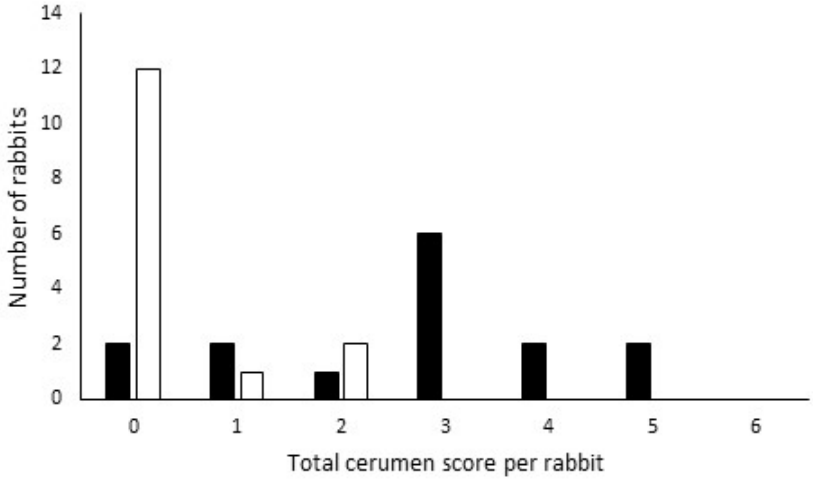

Figure 2. Frequency distribution of cerumen scores lop-eared and erect-eared rabbits. Black bars indicate lop-eared rabbits; white bars indicate erect-eared rabbits. Each ear was scored as follows: 0= normal low amount of cerumen, 1= mild amount of cerumen, 2= moderate amount of cerumen, 3= large amount of cerumen, and the added total for both ears per rabbit is shown.

Lop-eared rabbits had approximately fifteen times higher odds of demonstrating a potential pain response during ear examination than erect-eared rabbits (OR=14.8; 95% CI: 1.1-200.9; P=0.043).

The health records revealed that 14/15 of the lop-eared rabbits had at least one recording of excess wax during health checks by the rescue staff, compared with 3/15 of the erect-eared rabbits (Fisher's Exact X^2= 13.575; DF = 1; P < 0.001). The rescue carried out repeated ear cleaning in 9/15 of the lop-eared rabbits, compared with none of the erect-eared rabbits (Fisher's Exact X^2= 10.159; DF = 1; P = 0.001).

271 Table 3. Prevalence of binary variables investigated in both lop and erect-eared rabbit groups and the

272 significance of the difference between both groups.

Examination area	**Pathology investigated**	**Cases in lop-eared rabbits (n=15)**	**Cases in erect-eared rabbits (n=15)**	**Significance between lop- and erect-eared groups (P=)**
Aural	Ear canal stenosis	13	2	0.002
	Potential aural pain response	6	1	0.043
	Scratching the ears	2	0	0.483
	Mallasezia-like yeast species	12	8	0.174
	Record of aural veterinary treatment	4	0	0.100
	Record of excess cerumen	14	3	<0.001
	Record of repeated ear cleaning	9	0	0.001
Dental	Incisor pathology	7	1	0.015
	Molar overgrowth	13	6	0.015
	Sharp molars	13	6	0.015
	Molar spurs	11	0	0.006
	Oral mucosal sores/scars	2	0	0.483
	Potential oral pain response	2	0	0.483
	Epiphora	4	1	0.095
	Poor coat condition	3	0	0.224
	Hypersalivation	2	0	0.483
	Lack of caecotrophy	5	2	0.274
	Record of dental veterinary treatment	6	0	0.017

273

No statistically significant difference was found between lop-eared and erect-eared rabbits for evidence of scratching (fur loss or scaling) around the ears (2/15 versus 0/15, respectively), or ear pathology requiring treatment whilst at the rescue centre (4/15 versus 0/15, respectively). None of the rabbits had crusting of the external pinna, masses in the ear, head shaking or scratching in pre-examination observation or a head tilt. No statistical significance was found for any of the other predictors used in the binary logistic regression (face shape, sex or weight) for any of the aural pathology outcomes.

Microscopy revealed the presence of yeast species in some rabbits (12/15 lop-eared rabbits versus 8/15 erect-eared rabbits), which were identified as *Malassezia cuniculi* based on morphology described in other research[21, 24, 35]. The presence/absence, and also number of, malassezia-like yeasts found on microscopy were not statistically significantly different between lop- and erect-eared rabbits.

Only one mite was found, identified as Psoroptes cuniculi, in the ear of an erect-eared rabbit. This rabbit had no associated clinical signs or previous history of aural problems. No rod bacteria were identified, but cocci were found in three lop-eared rabbits and two erect-eared rabbits.

Dental health results

Lop-eared rabbits had approximately twenty-three times higher odds of incisor pathology compared with erect-eared rabbits (OR=23.3; 95% CI: 1.9–293.2; P=0.015). They also had approximately twelve times higher odds of having molar overgrowth (OR=12; 95% CI: 1.6-88.9; P=0.015), thirteen times higher odds of molar sharpness (OR=13.4; 95% CI: 1.7-

298 107.2; P=0.015) and were statistically significantly more likely to have molar spurs
299 (attributable risk=0.4667; P=0.006), compared with erect-eared rabbits (Table 3).
300 Veterinary records showed that 8/15 of the lop-eared rabbits had tooth abnormalities,
301 compared with none of the erect-eared rabbits (attributable risk= 0.53, 95% CI: 0.17-0.78;
302 P=0.002). Additionally, 6/15 of the lop ears had been for a dental whilst at the rescue,
303 whereas none of the erect-eared rabbits had, which was again statistically significant
304 (attributable risk=0.4; 95% CI: 0.06-0.67; P=0.017).
305 On the other hand, statistically significant differences between lop and erect-eared rabbits
306 were not found for oral mucosal sores, potential oral pain response, epiphora, poor coat
307 condition, hypersalivation, or lack of caecotrophy, although the trends were for all of these
308 to be slightly more likely in lop-eared rabbits (Table 3). No rabbits had an inability to close
309 the mouth or fractured teeth.
310
311 No statistical significance was found for any of the other predictors used in the binary
312 logistic regression (face shape, sex or weight) for any of the dental pathology outcomes.

313 Discussion

314 The results confirmed that lop-eared rabbits did indeed have a statistically significantly
315 higher level of aural pathology, including stenotic ear canals, potential pain response during
316 aural examination, increased levels of cerumen and erythema of the ear canal. Similarly,
317 there was also a statistically significantly higher level of dental pathology, including incisor
318 pathology, molar overgrowth, molar sharpness, molar spurs and veterinary dental treatment,
319 in lop-eared compared with erect-eared rabbits. Both the direct observations and the medical
320 records showed that the lop-eared rabbits had statistically significantly more aural and dental
321 pathologies than did erect-eared rabbits.

322 The use of a rescue population may of course not represent the general population of pet
323 rabbits. It is difficult to know if rescue rabbits would be affected more than pet rabbits by the
324 issues investigated here, or less. On one hand, rabbits in the rescue centre may be more
325 prone to health problems if they were given to the rescue because their owners could not
326 afford veterinary bills, or due to neglect and being fed an inappropriate diet. On the other
327 hand, the rescue staff were highly knowledgeable about rabbit health and carried out weekly
328 health checks, so current severe dental or aural disease was not found during the clinical
329 examination of this study. In either case, lop- and erect-eared rabbits would have been
330 affected by these factors to a similar extent. Thus, the finding that lop-eared rabbits were
331 prone to the aural and dental pathology investigated here constitutes a welfare concern
332 associated with breeding and buying lop-eared rabbits, for reasons described below in more
333 detail.

334 ## Aural pathology

335 The increased erythema, ceruminous discharge and stenosis of the ear canal found in the
336 lop-eared rabbits here, could indicate a higher frequency of otitis externa. This would concur
337 with two canine studies that found higher prevalences of otitis externa in dogs with
338 pendulous ears[22, 23]. In many of the rabbits, this appeared to be a chronic condition as the
339 medical records showed that 9/15 of the lop-eared rabbits required repeated ear cleaning
340 whilst at the rescue.

341 Thus, the welfare consequences of a rabbit having lop-ears include pain, as indicated by
342 statistically significantly increased pain responses during examination of lop-ears.
343 Additionally the higher frequency of signs consistent with otitis externa found in the lop-
344 eared compared with the erect-eared rabbits, suggest potential for pain, auditory deficit or
345 even deafness[18, 19], which in turn increases the vulnerability of the animal to threats and

346 could cause anxiety[20]. Deafness itself could not be tested in the current study, but this could
347 be assessed in future studies using Transient Evoked Otoacoustic Emissions testing, which
348 has been successfully used as a less invasive and relatively inexpensive alternative to
349 brainstem auditory evoked responses in puppies[36]. The rescue centre staff anecdotally
350 believed that more of the lop-eared rabbits had auditory impairment than the erect-eared
351 ones had, and unpublished research from our laboratory suggested that lop-eared rabbits
352 showed more signs of anxiety in a novel object test than erect-eared rabbits[37].

353 The results here suggest that the aetiology of any potentially associated auditory deficits
354 would be multifactorial as it is in dogs and cats[20, 38], with the over-hanging immobile pinnae,
355 the stenotic ear canals, and the accumulation of cerumen all comprising physical barriers to
356 sound perception. The middle and inner structures themselves may also be more prone to
357 issues, such as tympanic membrane rupture and sensorineural damage, if repeated infection
358 occurs.

359 The lack of a statistically significant difference in the presence of *Malassezia cuniculi*
360 between lop and erect-eared rabbits could of course be due to the fairly small sample size
361 here, but it agrees with the findings of Quinton et al. (2014), who reported no statistically
362 significant difference due to ear type in 146 clinically healthy domestic pet rabbits. This
363 could be explained by *Malassezia* being a normal coloniser of the rabbit ear canal, as in
364 other species such as dogs and cats[17, 21]. In future, culture could offer a more sensitive
365 method for quantifying *Malassezia* colonisation than cytology[39]. Campbell et al.[17] found a
366 positive correlation between the amount of ceruminous discharge and the culture of
367 *Malassezia*. However, although the present study found higher levels of cerumen in lop-
368 eared rabbits, the lack of difference in *Malassezia* colonisation suggests that this increased

369 cerumen was due to difficulties in expulsion, potentially due to the anatomy of the lop-ear,
370 rather than a *Malassezia* overgrowth[10].

371 ## Dental pathology

372 The increased presence of dental pathology found in lop-eared rabbits in this study partially
373 supports results from Mullan and Main[40], who found that dwarf lops were reported by their
374 owners to have statistically significantly more dental abnormalities compared with other
375 breeds (including some other lops), but only when diet and age were excluded from the
376 model. However, the present results disagree with a Finnish study[41] of 167 pet rabbits,
377 which found no associations between lop-eared breeds and dental disease, although they did
378 find statistically significantly more dental pathology in Lionhead rabbits, which are erect-
379 eared, but brachycephalic. A possible explanation for the disagreement is that the study by
380 Mäkitaipale et al.[41] was carried out on healthy pet rabbits whose owners voluntarily signed
381 up for the study, so those with known current dental problems may have been excluded from
382 that study.

383 The rabbits in our study represent a convenience sample of a rescue population, but if our
384 results can be replicated more widely, the increased risk of dental pathology for lop-eared
385 rabbit welfare is concerning for several reasons. Rabbit dental pathology can lead to lesions
386 of the mouth, pain, difficulty chewing food e.g. avoidance of, or prolonged chewing of, hard
387 foods as seen in bears with dental pathology[42], and possibly gastrointestinal problems
388 following inadequately chewed food as found in humans[43, 44], among other issues described
389 earlier. The rescue staff caring for rabbits in the current study were more knowledgeable of
390 and attentive to rabbit health issues than many owners, and health records indicated that they
391 had already identified more dental issues requiring veterinary attention in lop-eared than

392 erect-eared rabbits, before our study started. Indeed, the rabbits at the rescue centre
393 underwent weekly health checks by experienced rescue staff with the use of an otoscope.
394 Despite this enhanced care and monitoring of dental pathology, we observed statistically
395 significantly more abnormalities in both incisors and molars in the lop-eared rabbits. The
396 potentially associated secondary issues, such as trauma to the mouth and lips,
397 hypersalivation, and pain responses, were too rare to reach statistical significance, but all
398 showed trends towards being slightly more common in lop-eared rabbits.

399 The dental abnormalities here are unlikely to be due to diet, because there is currently no a
400 priori reason to believe that lop-eared rabbits would have been fed poorer diets than erect-
401 eared rabbits. Thus, they are likely to be caused at least partly by the skull and jaw
402 conformations associated with the lop-eared phenotype. Future studies could help confirm
403 this by observing random sample populations, and by utilising radiology to look at oral
404 conformations, alongside oral examination if possible[29, 31, 41].

405 ## Conclusions
406

407 The results from this research support the hypothesis that lop-eared rabbits have more dental
408 and aural pathology than erect-eared rabbits, which is concerning given the popularity of the
409 lop-eared phenotype. This brings into debate the ethics of breeding and buying lop-eared
410 rabbits, as they appear more likely to suffer from these conditions, which can be painful and
411 often chronic or recurrent.

412

Acknowledgements

The authors wish to thank the staff at The Rabbit Residence Rescue, Royston for allowing the inclusion of their rabbits in the project, Dr Anette Loeffler for her guidance on making and interpreting ear smears, Dr Anke Hendricks for her help with equipment and advice, Katie Lovell for supplying laboratory equipment, Katie Franklin for her assistance at the rescue and providing the list of rabbits, and Natalie Chancellor and Tomaso Carucci for their help handling the rabbits for examination. This research was carried out in part fulfilment of JCJ's Bachelor of Veterinary Medicine with Intercalated BSc Bioveterinary Sciences degree, in year 5 of this course at the Royal Veterinary College. The Royal Veterinary College assigned the following ID number to this study: PPS_01851.

References

1. BSAVA. Inherited diseases and exaggerated characteristics position statement 2012 https://www.bsava.com/Resources/Veterinary-resources/Position-statements/Inherited-diseases-and-exaggerated-characteristics (accessed 30th March 2018).

2. Gaines SA, Rooney NJ, Bradshaw JWS. The effect of feeding enrichment upon reported working ability and behavior of kenneled working dogs. Journal of Forensic Sciences. 2008;53:1400-1404.

3. British Veterinary Association. Health and welfare of brachycephalic dogs 2014 https://www.bva.co.uk/news-campaigns-and-policy/policy/companion-animals/brachycephalic-dogs/ (accessed 30th March 2018).

4. Rabbit Welfare Association and Fund. Brachycephaly not just a dog issue. Veterinary Record. 2017;180:316.

5. UFAW. Genetic Welfare Problems of Companion Animals 2011 https://www.ufaw.org.uk/rabbits/english-lop-overlong-ears (accessed 30th March 2018).

6. Gosling EM, Vázquez-Diosdado JA, Harvey ND. The Status of Pet Rabbit Breeding and Online Sales in the UK: A Glimpse into an Otherwise Elusive Industry. Animals. 2018;8:199.

440 7. Castle WE, Reed SC. Studies of Inheritance in Lop-Eared Rabbits. Genetics.
441 1936;21:297-309.

442 8. British rabbit council. British Rabbit Council breed standards 2016-2020 2016
443 https://thebritishrabbitcouncil.org/Mono%20Breed%20Standards%20Book%20APRIL%202
444 017%20small.pdf (accessed 29th April 2018).

445 9. Eatwell K, Mancinelli E, Hedley J, Keeble E, Kovalik M, Yool DA. Partial ear canal
446 ablation and lateral bulla osteotomy in rabbits. Journal of Small Animal Practice.
447 2013;54:325-330.

448 10. Harcourt-Brown F, Chitty J. BSAVA Manual of Rabbit Surgery, Dentistry and Imaging.
449 Quedgeley, Gloucester: BSAVA [British Small Animal Veterinary Association]; 2013.

450 11. Csomos R, Bosscher G, Mans C, Hardie R. Surgical Management of Ear Diseases in
451 Rabbits. Veterinary Clinics of North America: Exotic Animal Practice. 2016;19:189-204.

452 12. Darwin C. The variation of animals and plants under domestication: O. Judd; 1868.

453 13. Cordero GA, Berns CM. A test of Darwin's 'lop-eared' rabbit hypothesis. Journal of
454 Evolutionary Biology. 2016;29:2102-2110.

455 14. Lennox AM, Kelleher S. Bacterial and Parasitic Diseases of Rabbits. Veterinary Clinics:
456 Exotic Animal Practice. 2009;12:519-530.

457 15. Vella D, Donnelly TM. Chapter 12 - Basic Anatomy, Physiology, and Husbandry. In:
458 Quesenberry KE, Carpenter JW, editors. Ferrets, Rabbits, and Rodents: Clinical Medicine
459 and Surgery (Third Edition). Saint Louis: W.B. Saunders; 2012. p. 157-173.

460 16. Mayer Jr. Otology of the Rabbit: Anatomy, Physiology, and Surgery Association of
461 exotic mammal veterinarians lectures and practical workshop 2011
462 http://www.aemv.org/documents/2011-rAEMV%20-%2030709%20Guts.pdf#page=58
463 (accessed 4th March 2018).

464 17. Campbell J, Coyner KS, Rankin SC, Lewis TP, Schick AE, Shumaker AK. Evaluation of
465 fungal flora in normal and diseased canine ears. Veterinary Dermatology. 2010;21:619-625.

466 18. Mancinelli E, Lennox AM. Management of Otitis in Rabbits. Journal of Exotic Pet
467 Medicine. 2017;26:63-73.

468 19. Chow EP. Surgical Management of Rabbit Ear Disease. Journal of Exotic Pet Medicine.
469 2011;20:182-187.

470 20. Strain GM. Aetiology, prevalence and diagnosis of deafness in dogs and cats. British
471 Veterinary Journal. 1996;152:17-36.

472 21. Quinton J-F, Francois M, Laprais A, Prelaud P. Cytology of the external auditory meatus
473 in healthy domestic pet rabbits (*Oryctolagus cuniculus*). Revue Medecine Veterinaire.
474 2014;165:263-266.

475 22. Hayes HJ, Pickle L, Wilson G. Effects of ear type and weather on the hospital prevalence
476 of canine otitis externa. Research in Veterinary Science. 1987;42:294-298.

477 23. Perry LR, MacLennan B, Korven R, Rawlings TA. Epidemiological study of dogs with
478 otitis externa in Cape Breton, Nova Scotia. The Canadian Veterinary Journal. 2017;58:168-
479 174.

480 24. Cafarchia C, Gallo S, Capelli G, Otranto D. Occurrence and Population Size of
481 Malassezia spp. in the External Ear Canal of Dogs and Cats Both Healthy and with Otitis.
482 Mycopathologia. 2005;160:143-149.

483 25. Lord B. Dental disease in the rabbit Part 2: Dental disease causes, clinical signs and
484 diagnosis. Companion Animal. 2011;16:39-42.

485 26. Meredith A. The Importance of Diet in Rabbits: The British Rabbit council; 2010
486 https://thebritishrabbitcouncil.org/diet.htm (accessed 29th April 2018).

487 27. Varga M. Chapter 5 - Dental Disease. Textbook of Rabbit Medicine (Second Edition):
488 Butterworth-Heinemann; 2014. p. 203-248.

489 28. Harcourt-Brown F. Dental disease in pet rabbits 1. Normal dentition, pathogenesis and
490 aetiology. In Practice. 2009;31:370.

491 29. Harcourt-Brown F. Diagnosis, treatment and prognosis of dental disease in pet rabbits. In
492 Practice. 1997;19:407.

493 30. Florin M, Rusanen E, Haessig M, Richter M, Spiess Bernhard M. Clinical presentation,
494 treatment, and outcome of dacryocystitis in rabbits: a retrospective study of 28 cases (2003–
495 2007). Veterinary Ophthalmology. 2009;12:350-356.

31. Mosallanejad B, Moarrabi A, Avizeh R, Ghadiri A. Prevalence of Dental Malocclusion and Root Elongation in Pet Rabbits of Ahvaz, Iran. Iranian Journal of Veterinary Science and Technology. 2011;2:109–116.

32. Pet Food Manufacturer's Association. Rabbit Size-O-Meter 2013 https://www.pfma.org.uk/_assets/docs/pet-size-o-meter/pet-size-o-meter-rabbit.pdf (accessed 1st February 2018).

33. Colegrave N, Ruxton GD. Confidence intervals are a more useful complement to nonsignificant tests than are power calculations. Behavioral Ecology. 2003;14:446-447.

34. Levine TR. A defense of publishing nonsignificant (ns) results. Communication Research Reports. 2013;30:270-274.

35. Cabañes FJ, Vega S, Castellá G. Malassezia cuniculi sp. nov., a novel yeast species isolated from rabbit skin. Medical Mycology. 2011;49:40-48.

36. McBrearty A, Penderis J. Transient evoked otoacoustic emissions testing for screening of sensorineural deafness in puppies. Journal of Veterinary Internal Medicine. 2011;25:1366-1371.

37. Franklin KA. The Extent to Which Ear Morphology Affects Rabbit Health and Behaviour [BSc (Hons) dissertation]: The Royal Veterinary College; Unpublished 2018.

38. Mactaggart D. Assessment and management of chronic ear disease. In Practice. 2008;30:450.

39. Bensignor E, Jankowski F, Seewald W, Touati F, Deville M, Guillot J. Comparison of two sampling techniques to assess quantity and distribution of Malassezia yeasts on the skin of Basset Hounds. Veterinary Dermatology. 2002;13:237-241.

40. Mullan SM, Main DCJ. Survey of the husbandry, health and welfare of 102 pet rabbits. Veterinary Record. 2006;159:103-109.

41. Mäkitaipale J, Harcourt-Brown FM, Laitinen-Vapaavuori O. Health survey of 167 pet rabbits (*Oryctolagus cuniculus*) in Finland. Veterinary Record. 2015;177:418.

42. Fleming M, Burn CC. Behavioural assessment of dental pain in captive Malayan Sun Bears (*Helarctos malayanus*). Animal Welfare. 2014;23:131-140.

43. Buschang PH. Masticatory Ability and Performance: The Effects of Mutilated and Maloccluded Dentitions. Seminars in Orthodontics. 2006;12:92-101.

44. Koike S, Sujino T, Ohmori H, Shimazaki K, Fukuyama E, Kanai T, et al. Gastric emptying rate in subjects with malocclusion examined by [13C] breath test. Journal of Oral Rehabilitation. 2013;40:574-581.