bioRxiv preprint doi: https://doi.org/10.1101/721134; this version posted August 1, 2019. The copyright holder for this preprint (which was not certified by peer review) is the author/funder. All rights reserved. No reuse allowed without permission.

Neuroanatomical Risk Factors for Post Traumatic Stress Disorder (PTSD) in Recent Trauma Survivors

Short/Running Title: Neuroanatomical Risk Factors for PTSD

Ziv Ben-Zion[1,2]*, Moran Artzi[1,2,3], Dana Niry[3,4], Nimrod Jackob Keynan[1,5], Roee Admon[6], Haggai Sharon[1,3,7,8], Pinchas Halpern[3,9], Israel Liberzon[10], Arieh Y. Shalev[11] & Talma Hendler[1,2,3,5*]

[1]Sagol Brain Institute Tel-Aviv, Wohl Institute for Advanced Imaging, Tel Aviv Sourasky Medical Center, Tel-Aviv, Israel

[2]Sagol School of Neuroscience, Tel-Aviv University, Tel-Aviv, Israel

[3]Sackler Faculty of Medicine, Tel-Aviv University, Tel-Aviv, Israel

[4]Department of Radiology, Tel Aviv Sourasky Medical Center, Tel-Aviv, Israel

[5]School of Psychological Sciences, Faculty of Social Sciences, Tel-Aviv University, Tel-Aviv, Israel

[6]Department of Psychology, University of Haifa, Haifa, Israel

[7]Institute of Pain Medicine, Department of Anesthesiology and Critical Care Medicine, Tel Aviv Sourasky Medical Center, Tel-Aviv, Israel

[8]Pain Management & Neuromodulation Centre, Guy's & St Thomas' NHS Foundation Trust, London, UK

[9]Department of Emergency Medicine, Tel Aviv Sourasky Medical Center, Tel-Aviv, Israel

[10]Department of Psychiatry, Texas A&M Health Science Center, TX, USA

[11]Department of Psychiatry, NYU Langone Medical Center, New York, NY, USA

bioRxiv preprint doi: https://doi.org/10.1101/721134; this version posted August 1, 2019. The copyright holder for this preprint (which was not certified by peer review) is the author/funder. All rights reserved. No reuse allowed without permission.

***Corresponding Authors:**

Prof. Talma Hendler, M.D. Ph.D.

Professor of Psychiatry and Psychology, Sagol School of Neuroscience, Sackler Faculty of Medicine, and School of Psychological Sciences, Tel Aviv University, P.O. Box 39040, Tel Aviv, Israel; Director, Sagol Brain Institute, Wohl Institute for Advanced Imaging, Tel Aviv Sourasky Medical Center, Weizmann 6, Tel Aviv, 64239, Israel;

Phone: +972 (0)3 697 3549. Email: hendlert@gmail.com.

Ziv Ben-Zion, PhD candidate

Sagol Brain Institute, Wohl Institute for Advanced Imaging, Tel Aviv Sourasky Medical Center, Weizmann 6, Tel Aviv, 64239, Israel; Sagol School of Neuroscience, Tel-Aviv University, P.O. Box 39040, Tel Aviv 69978, Israel;

Phone: +972 (0)3 697 3549. Email: zivbenzion@mail.tau.ac.il

bioRxiv preprint doi: https://doi.org/10.1101/721134; this version posted August 1, 2019. The copyright holder for this preprint (which was not certified by peer review) is the author/funder. All rights reserved. No reuse allowed without permission.

Abstract

Background: A distinct neuroanatomical indicator for Post-traumatic Stress Disorder (PTSD) soon after exposure is still lacking. Contradictory findings regarding the hippocampus as a potential early risk factor could be related to the overlooked contribution of developmental brain anomaly. One such anomaly could be a persistently enlarged cavum septum pellucidum (CSP), which has been associated with PTSD. To test this assertion, we performed a longitudinal volumetric MRI study on trauma survivors, within one-, six- and fourteen-months after trauma. We hypothesized that at one-month post-trauma, the relation between hippocampal volume and PTSD severity would be moderated by CSP volume, and that this early interaction would account for persistent PTSD symptoms at subsequent time points.

Methods: 171 adults which were admitted to emergency room following a traumatic incident, underwent clinical assessment and structural MRI within one-month after trauma. Follow-up clinical evaluations were conducted six (n=97) and fourteen (n=78) months after trauma. Hippocampus and CSP volumes were extracted automatically by FreeSurfer and verified manually, and correlated with PTSD severity at each time point.

Results: At one-month following trauma, CSP volume significantly moderated the relation between hippocampal volume and PTSD severity, and this interaction predicted symptom severity at fourteen months post-trauma. Specifically, individuals with smaller hippocampus and larger CSP at one-month after trauma, showed more severe symptoms at one- and fourteen months following trauma exposure.

Conclusions: Our study provides evidence for an early neuroanatomical cause of PTSD that could also predict the progression of the disorder. Such a simple-to-acquire neuroanatomical signature for PTSD could guide early management as well as long-term monitoring.

bioRxiv preprint doi: https://doi.org/10.1101/721134; this version posted August 1, 2019. The copyright holder for this preprint (which was not certified by peer review) is the author/funder. All rights reserved. No reuse allowed without permission.

Trial Registration: Neurobehavioral Moderators of Post-traumatic Disease Trajectories.

ClinicalTrials.gov registration number: NCT03756545.

https://clinicaltrials.gov/ct2/show/NCT03756545

Keywords: Post Traumatic Stress Disorder; Hippocampus; Cavum Septum Pellucidum; Resilience; Vulnerability; Risk Factors;

bioRxiv preprint doi: https://doi.org/10.1101/721134; this version posted August 1, 2019. The copyright holder for this preprint (which was not certified by peer review) is the author/funder. All rights reserved. No reuse allowed without permission.

Introduction

More than 70% of adults worldwide experience a traumatic event at some time in their lives[1], yet only a subset of these individuals (1.3% to 12.2%) will develop post-traumatic stress disorder (PTSD)[2], a highly debilitating mental health disorder, often resistant to existing therapeutics[3–6]. Although accumulating findings point to a neural origin of this post-exposure personal outcome, reliable risk factors of vulnerability to develop traumatic stress psychopathology have yet to be discovered[7–9]. Such vulnerability factors could allow accurate diagnosis and therapeutic intervention in the early aftermath of the traumatic event, which has been shown to reduce the likelihood of developing chronic PTSD[10–12].

The most replicated structural abnormality found in PTSD is lower hippocampal volume[13–18], with substantial evidence that this could represent a risk factor for PTSD, including studies on twins with different life experience[19,20]. It seems that the hippocampus may have a multifaceted role in PTSD pathogenesis, including the formation and recall of memory traces for contextual information of traumatic events, and providing a representation of safety or danger of the situation[21]. Intriguingly, the hippocampus seems to play a dynamic role in both post-traumatic psychopathology and recovery from trauma. While hippocampal volume reduction was observed after trauma exposure[22] and in chronic PTSD[23], increased hippocampal volume was associated with clinical improvement of PTSD symptoms[24]. Nevertheless, trauma exposure even in the absence of PTSD was shown to be associated with hippocampal volume deficits[22], and further hippocampal volume reduction was seen in chronic PTSD[23]. Taken together, controversy exists as to whether reduced hippocampal size in PTSD is the result of trauma exposure, represents a risk factor for PTSD, or a combination of both[23,25,26]. It might be that the hippocampus is not the only structural change in PTSD, and its impact depends on related brain development anomaly.

One such commonly seen anomaly is persistent enlarged Cavum Septum Pellucidum (CSP), known to be related to disturbed brain development[27,28]. The CSP, sometimes inaccurately referred to as “fifth ventricle”, is a small cleft filled with cerebrospinal fluid (CSF), located between two thin

bioRxiv preprint doi: https://doi.org/10.1101/721134; this version posted August 1, 2019. The copyright holder for this preprint (which was not certified by peer review) is the author/funder. All rights reserved. No reuse allowed without permission.

translucent leaflet membranes, that extends from the anterior part of the corpus callosum to the superior surface of the fornix. In normal development, the fusion of the septi pellucidi occurs within three to six months of age, due to rapid growth of the hippocampal alvei and the corpus callosum[29]. However, in some cases the two leaves of the septum pellucidum do not completely fuse, resulting in persistent CSP, which above a certain size, may reflect neurodevelopmental anomaly in midline structures of the brain[27,30] *(see Fig. 1).* Therefore, persistent enlarged CSP in adults may reflect developmental abnormalities of brain structures bordering the septum pellucidum, such as the hippocampus[29,31].

A wide variance in the prevalence of CSP in healthy adults has been reported, depending on the method of detection, definition criteria, and homogeneity of the population[28,32–37]. In clinical population, abnormally large CSP was associated with schizophrenia[28,32,42,33–36,38–41], bipolar disorders[35,43,44], and others psychopathologies[45,46]. However, other studies did not find higher rates of enlarged CSP in schizophrenia[47–49] or other psychiatric disorders[50–53], making it difficult to determine its connection to psychopathology in a systematic and reliable manner. Interestingly, in patients with schizophrenia and an enlarged CSP, smaller amygdala and posterior parahippocampal gyrus volumes were also found (compared to schizophrenia patients without CSP)[54].

To date, only two studies have addressed the relationship between the presence of enlarged CSP and PTSD symptomatology. A pioneer study by Myslobodsky et al (1995)[55] has reported increased incidence of CSP (50%) in combat veterans with PTSD, compared with matched normal volunteers (14%), suggesting the CSP might be an antecedent marker for psychopathological vulnerability to stress. More recently, May et al. (2004)[56] found there was a greater proportion of abnormal CSP in combat-exposed twins with PTSD and their noncombat-exposed co-twins, suggesting that the presence of an abnormal CSP may serve as a familial vulnerability factor for PTSD. However, the authors also suggested that PTSD vulnerability is not contributed directly by abnormal CSP itself, but rather indirectly by some neurodevelopmental third factor.

bioRxiv preprint doi: https://doi.org/10.1101/721134; this version posted August 1, 2019. The copyright holder for this preprint (which was not certified by peer review) is the author/funder. All rights reserved. No reuse allowed without permission.

Here, we tested the relationship between CSP volume and hippocampus volume in a large population of recent trauma survivors using a longitudinal approach. Specifically, we examined hippocampus and CSP volumes within on one-month after trauma, and PTSD symptoms at one-, six-, and fourteen-month following trauma exposure. CSP and hippocampal three-dimensional volumes were assessed using automated tools to provide a continuous measure of size of a reliably demarcated region. While for the hippocampus this automated approach has been validated in multiple studies[57–59], for the CSP, as far as we know, no such studies were reported. Therefore, we employed an additional validation procedure by a blinded neuroradiologist for the automated CSP assessment.

Given the consistent finding of low hippocampal volume in PTSD, and the potential of enlarged CSP to serve as vulnerability factor for stress psychopathology, we hypothesized that the relationship between hippocampal volume and post-traumatic stress symptoms will be moderated by CSP volume. More specifically, we hypothesized that individuals with lower hippocampal volume and higher CSP volume would exhibit more severe PTSD symptoms at one-month post-trauma. To test this assumption, we employed a regression model in which we examined the ability of the interaction effect between hippocampal and CSP volumes to predict post-traumatic stress symptoms. Using the same regression model, we further examined the predictive power of this relation between hippocampus and CSP volumes at one-month post-trauma, with respect to subsequent PTSD symptom severity at six- and fourteen-month post-trauma.

bioRxiv preprint doi: https://doi.org/10.1101/721134; this version posted August 1, 2019. The copyright holder for this preprint (which was not certified by peer review) is the author/funder. All rights reserved. No reuse allowed without permission.

Methods and Materials

The present study is part of a larger scale on-going project. Here we present results obtained from all the participants which completed clinical and neural assessments within one-month following the traumatic incidents (n=171). Out of these 171 individuals, we also present results of n=97 and n=78 which currently completed clinical assessments at six- and fourteen-month post-trauma (respectively).

Participants

Participants were adult survivors of potentially traumatic events, admitted to a Medical Center's Emergency Room (ER). Individuals were considered for a telephone screening interview if they met the following inclusion criteria: (i) Age 18 – 65 years (ii) Able to read and comprehend native language (iii) Arrived in the ER due to motor-vehicle accidents, bicycle accidents, physical assaults, terrorist attacks, work accidents, large-scale disaster or other trauma types. To reduce confounds related to concurrent disorders, the exclusion criteria included: (i) survivors with head trauma with coma exceeding a 30 minutes upon ER arrival; (ii) survivors with known medical condition that will interfere with their ability to give informed consent, cooperate with screening and/or treatment; (iii) survivors with claustrophobia, incompatibility for MRI scan, history of substance abuse, current or past psychotic disorder, chronic PTSD; (iv) individuals using psychotropic medication or recreational drugs in the week that precedes the assessment.

Procedure

A member of the research team identified potentially trauma-exposed individuals using the ER medical records. Within 10–14 days after potential trauma exposure, the identified individuals were contacted by telephone. After verbal consent, risk of PTSD development was assessed using a modified dichotomous version of the PTSD Checklist (PCL) questionnaire[61]. Participants which

bioRxiv preprint doi: https://doi.org/10.1101/721134; this version posted August 1, 2019. The copyright holder for this preprint (which was not certified by peer review) is the author/funder. All rights reserved. No reuse allowed without permission.

met PTSD symptom criteria or at least part of it, and did not meet any of the exclusion criteria, received verbal information about the study. They were subsequently invited to participate in both comprehensive clinical assessment and a high-resolution MRI scan, within one-month post-trauma (TP1). Two identical follow-up meetings (including both clinical and neural assessments) were conducted at six- and fourteen-month after trauma (TP2 and TP3, respectively). The study met all ethical regulations as required by ethics committee in the local Medical Center (Reference number 0207/14). All participants gave written informed consent in accordance with the Declaration of Helsinki. The study ClinicalTrials.gov registration number is NCT03756545.

Clinical Assessment

The clinical status of participants was determined by the Clinician-Administered PTSD Scale (CAPS)[62,63], structured clinical interview corresponding to DSM-based PTSD criteria as determined by dimensions of frequency, intensity, and severity of symptoms. An instrument combining both CAPS-4 and CAPS-5 was used, based on DSM-IV and DSM-5 criteria, accordingly. The CAPS contain explicit, behaviorally anchored questions and rating scale descriptors to enhance reliability. It yields a continuous symptom severity score, obtained by summing individual items' scores (each item ranges from 0-4, with 0 being absent to 4 being extreme/incapacitating).

Magnetic Resonance Imaging (MRI)

Acquisition. MRI scans were conducted using a Siemens 3T MAGNETOM scanner, located at the Tel Aviv Sourasky Medical Center. In order to assess subcortical and cortical volumes, as well cortical thickness, we used a high resolution sagittal T_1-weighted magnetization prepared rapid gradient echo (MPRAGE) sequence (TE=2.29 msec, TR=2400 msec, flip angle=8°, FOV =224 mm, Slice Thickness 0.70 mm, voxel size 0.7x0.7x0.7 mm).

bioRxiv preprint doi: https://doi.org/10.1101/721134; this version posted August 1, 2019. The copyright holder for this preprint (which was not certified by peer review) is the author/funder. All rights reserved. No reuse allowed without permission.

Analysis. Cortical reconstruction and volumetric segmentation was performed with the FreeSurfer (FS) image analysis suite [64], which is documented and freely available for download online (http://surfer.nmr.mgh.harvard.edu/). Right and left hippocampal and CSP volumes were derived from this process for each subject. The automated hippocampal volumetric measurement by FS was previously shown to have a good agreement with manual hippocampal volumetric assessment, as well as with other automatic methods[58,65,66]; however, this was not done for CSP volumetric measurement. In order to validate the automated measurement of the CSP, individuals' CSP sizes were manually verified by a senior neuroradiologist (D.N.) who was blinded to participants' clinical symptoms. For each subject, the FS mask of the CSP was evaluated independently according to its correct location and intensity. Based on this blind assessment, participants were divided into two groups: those in which there was agreement between the FS marking and the manual neuroradiologist evaluation, and those in which there was disagreement between the two (hence were excluded from the final analysis).

Statistical Analysis

In order to test whether CSP volume moderated the relationship between bilateral hippocampal volume and PTSD symptoms, moderation analysis including hierarchical multiple regression analysis was conducted using PROCESS macro for SPSS[67,68]. In the first step, two independent variables (bilateral hippocampus and CSP volumes at TP1), alongside four covariates (participants' age, gender, trauma type and intracranial volume (ICV)), were used to predict the dependent variable (PTSD symptom severity as measured by CAPS-4 or CAPS-5 total scores). In the second step of the regression, the centered interaction term between hippocampal volume and CSP volume was added to the regression model to test its contribution. Significant interactions were probed by testing the conditional effects of CSP volume at the different quartiles of hippocampal volume (Q1=25th percentile, Q2=50th percentile=Median, Q3=75th percentile).

bioRxiv preprint doi: https://doi.org/10.1101/721134; this version posted August 1, 2019. The copyright holder for this preprint (which was not certified by peer review) is the author/funder. All rights reserved. No reuse allowed without permission.

In accordance with common norms, the skewed distribution of CSP volume was treated by adding a constant (b=1.25) to the original values of CSP volume, and then a log transformation was performed on these modified values[69]. Bilateral hippocampal volume, and total scores of both CAPS-4 and CAPS-5 followed a normal distribution, therefore did not require transformations. Furthermore, to reduce the threat of multi-collinearity, both hippocampal and CSP volumes were centered prior to analyses, and an interaction term between these two was created[70].

Results

A total of 171 participants completed clinical and neural assessments within one-month following their traumatic incident (TP1). Out of which, 10 individuals were excluded from the analysis due to a missing MPRAGE sequence (n=3), missing clinical data (n=3), or poor quality structural scan (n=4). The CSP sizes of the remaining 161 participants were manually verified by a senior neuroradiologist *(see MRI Analysis under Methods and Materials)*. Based on this blind assessment, for 28 participants (17%) there was a disagreement between the FS marking and the manual neuroradiologist evaluation, hence they were excluded from the analysis. For the remaining 133 participants, there was an agreement between the FS marking and the manual neuroradiologist evaluation, hence they were included in the final analyses described below.

The majority of the traumatic events which the participants exhibited were motor-vehicle accidents (n=108, 81%). The other most common types of trauma included bicycle accidents (n=13, 10%) and physical assaults (n=11, 8%). For the follow-up assessments, n=97 and n=78 participants which completed clinical assessments at six- and fourteen-month post-trauma (TP2 and TP3; respectively), were included in the final analyses. No significant differences were found between the 97 individuals which completed TP2 assessments and the 36 which did not, in bilateral hippocampal volume (p=0.747), CSP volume (p=0.491), or ICV (p=0.813). Furthermore, no

bioRxiv preprint doi: https://doi.org/10.1101/721134; this version posted August 1, 2019. The copyright holder for this preprint (which was not certified by peer review) is the author/funder. All rights reserved. No reuse allowed without permission.

significant differences were found between the 78 individuals which completed TP3 assessments and the 19 which did not, in bilateral hippocampal volume (p=0.220), CSP volume (p=0.990), or ICV (p=0.650). *For further demographic, clinical, and neuroanatomical characteristics of all participants along the three time-points, refer to Table 1.*

Volumetric markers of PTSD symptom severity at one-month after trauma exposure (TP1)

To test the hypothesis that PTSD symptoms one-month after trauma are a function of multiple volumetric abnormalities, and more specifically whether CSP volume moderates the relationship between hippocampal volume and PTSD severity, a hierarchical multiple regression analysis was conducted *(see details under Statistical Analysis).* Results showed that bilateral hippocampus volume and CSP volume, alongside four covariates (participants' age, gender, trauma type and ICV), accounted for a significant amount of variance of total scores of both CAPS-4 *(R^2 = 0.323, F(6, 126) = 2.439, p = 0.029)*. After the interaction term between hippocampal volume and CSP volume was added, the regression model accounted for a significant change in proportion of CAPS-4 total scores *(ΔR^2 = 0.035, ΔF(1,125) = 5.057 ,p = 0.026).* Consistent with our hypothesis, a significant interaction (moderation) effect was found between bilateral hippocampus volume and CSP volume in predicting CAPS-4 total scores at one-month post-trauma *(b = -0.0134, t(125) = -2.249, p = 0.026) (See Table 2).* Importantly, neither hippocampal volume nor CSP volume by themselves predicted CAPS-4 total scores *(p = 0.109; p = 0.183, respectively).*

The above-mentioned interaction was probed by testing the conditional effects of CSP volume at the different quartiles of hippocampal volume (Q1=25th percentile, Q2=50th percentile=Median, Q3=75th percentile) *(see Fig. 2).* At low hippocampal volume (Q1), CSP volume was significantly related to PTSD severity *(CAPS-4: p=0.008; CAPS-5: p=0.028).* However, at median and high hippocampal volumes (Q2 and Q3 respectively), the relationship between CSP and hippocampus was not significant *(p>0.15 for both CAPS-4 and CAPS-5) (see Fig. 2).*

bioRxiv preprint doi: https://doi.org/10.1101/721134; this version posted August 1, 2019. The copyright holder for this preprint (which was not certified by peer review) is the author/funder. All rights reserved. No reuse allowed without permission.

When using CAPS-5 total scores (instead of CAPS-4) to assess PTSD symptom severity with identical statistical approach, the regression model accounted for a significant amount of variance of CAPS-5 total scores *(R^2 = 0.332, F(6, 126) = 2.603, p = 0.021)*. After the interaction term was added, the regression model accounted for a marginally significant change in proportion of CAPS-5 total scores *(ΔR^2 = 0.024, ΔF(1,125) = 3.539 ,p = 0.062)*. Consistent with our hypothesis, a marginally significant interaction (moderation) effect was found between bilateral hippocampus volume and CSP volume in predicting CAPS-5 total scores at one-month post-trauma *(b = -0.0059, t(125) = -1.881, p = 0.062)*. Examination of this interaction showed a similar pattern to the one mention-above using CAPS-4 total scores: individuals with large CSP had a negative relationship between hippocampal volume and CAPS-5 scores; however, this relationship did not exist in individuals with small or without CSP *(see above)*.

Volumetric predictors of PTSD symptom severity at follow-up assessments (TP2 and TP3)

To further examine the relation between hippocampal and CSP volumes at TP1 and subsequent PTSD symptoms at TP2 and TP3, two additional hierarchical multiple regression analyses were conducted (one for TP2 and one for TP3). The outcome measure for PTSD symptom severity was CAPS-4 total scores (and not CAPS-5), since it presented the more robust findings for TP1.

Focusing on PTSD symptom assessment at six months after trauma (TP2), the hierarchical regression model accounted for a non-significant proportion of the variance in PTSD symptom severity, both without the interaction *(R^2 = 0.080, F(6,90) = 1.304 ,p = 0.264)*, and when it was added *(ΔR^2 = 0.012, ΔF(1,89) = 1.187 ,p = 0.279)*. Hence, there was no significant moderation (interaction) effect between hippocampal and CSP volumes in predicting CAPS-4 total scores at TP2.

bioRxiv preprint doi: https://doi.org/10.1101/721134; this version posted August 1, 2019. The copyright holder for this preprint (which was not certified by peer review) is the author/funder. All rights reserved. No reuse allowed without permission.

Focusing on PTSD symptom assessment at fourteen months after trauma (TP3), the hierarchical regression model without the interaction accounted for a non-significant proportion of the variance in PTSD symptom severity *($R^2 = 0.034$, $F(6,71) = 0.442$,$p = 0.862$).* After adding the interaction term between hippocampal volume and CSP volume to the regression model, it accounted for a significant proportion of the variance in PTSD symptom severity *($\Delta R^2 = 0.075$, $\Delta F(1,70) = 5.913$,$p = 0.018$).* A significant interaction (moderation) effect was found between bilateral hippocampus and CSP volumes at TP1 in predicting CAPS-4 total scores at TP3 *($b = -0.014$, $t(70) = -2.432$, $p = 0.018$) (See Table 4).* Importantly, neither hippocampal volume nor CSP volume by themselves predicted CAPS-4 total scores *($p = 0.970$; $p = 0.996$, respectively).*

The above-mentioned interaction was probed by testing the conditional effects of CSP volume at the different quartiles of hippocampal volume (Q1=25th percentile, Q2=50th percentile=Median, Q3=75th percentile) *(see Fig. 3).* At low hippocampal volume (Q1), CSP volume was marginally significantly related to PTSD severity *($p=0.057$).* However, at median and high hippocampal volumes (Q2 and Q3 respectively), the relationship between CSP and hippocampus was not significant *($p=0.952$ and $p=0.276$ respectively) (see Fig. 3).*

Discussion

The current study revealed a moderation effect of CSP volume on the relationship between hippocampal volume and PTSD symptom severity in a population of recent trauma survivors. Specifically, we found that smaller hippocampus volume, together with larger CSP volume, was associated with more severe PTSD symptoms within one-month post-trauma. More so, such relationship at the early aftermath of trauma predicted greater persistence of PTSD at fourteen-month following trauma exposure. Altogether these findings point to an objective and easy to acquire neuroanatomical signature of PTSD severity among recent trauma survivors, as well as provide a predictive risk factors for persistent chronicity for the disorder. While a great amount of

bioRxiv preprint doi: https://doi.org/10.1101/721134; this version posted August 1, 2019. The copyright holder for this preprint (which was not certified by peer review) is the author/funder. All rights reserved. No reuse allowed without permission.

literature suggests the role of hippocampal volume in PTSD[25], fewer studies have linked abnormal CSP with post-traumatic psychopathology[55,56]. Our results provide novel insights regarding the relationship between these two brain structures in marking contemporary symptoms and predicting chronic course of PTSD. Importantly, their combined effect supports a brain development origin for PTSD vulnerability following exposure to potentially traumatic event.

Reduced hippocampal volume is the most consistent finding in structural MRI studies of patients diagnosed chronic PTSD[71–74]. Controversy exists, however, over the nature and source of smaller hippocampal volumes in PTSD; whether volumetric differences represent the consequence of traumatic exposure, or a pre-existing trait that predisposes people to pathological stress reactions to a traumatic event[75–78]. Our results suggest that in the presence of a smaller hippocampus, an abnormally enlarged CSP might serve as a risk factor for developing PTSD following trauma.

Because an enlarged CSP is considered a neurodevelopmental anomaly, it has been postulated as a potential marker for psychiatric disorders that have neurodevelopmental origins[79]. As the postnatal closure of the CSP is dependent on adjacent growing brain structures, a risk for developing different psychopathologies might be associated with a combination of both enlarged CSP and smaller limbic system structures (e.g. hippocampus and amygdala)[80]. Here we provide evidence that a combination of enlarged CSP and smaller hippocampal volume might be associated with PTSD symptomatology.

Our study combined early structural brain indices with longitudinal PTSD clinical measures, enabling to examine the relationship between potential neuroanatomical measures and PTSD symptom severity in the first critical year following trauma. Indeed, we demonstrated that enlarged CSP together with smaller hippocampus measured at one-month following exposure, marked PTSD development and predicted their persistence over 14 months. Nevertheless, the combination of enlarged CSP and smaller hippocampus at one-month post-trauma did not significantly predicted symptom severity at six-month post-trauma. This might be explained by the dynamic clinical manifestations during the first critical year following trauma, in which there is a progressive

bioRxiv preprint doi: https://doi.org/10.1101/721134; this version posted August 1, 2019. The copyright holder for this preprint (which was not certified by peer review) is the author/funder. All rights reserved. No reuse allowed without permission.

reduction in the severity of PTSD symptoms[81–84]. An intermediary point of six-month might be too early to capture the tangible chronic PTSD subtype, whereas 14-months may portray a more stable representation of the chronic disorder as it was shown to predict over 90% of expected PTSD recovery[3,85].

The methodological strengths of the current study derive from the standardized structural MRI measurements obtained in a large population-based sample of 171 trauma-exposed individuals with different demographic characteristics (e.g. age, gender). In specific, we applied an automated approach for the volume assessment of CSP, yet included only cases that have been also validated by a neurologist *(see MRI Analysis).* This approach, although commonly applied with the hippocampus, goes beyond the current practice with regard to CSP measurements. Indeed methodological drawbacks, mainly the great variation in the way that the studies detected and quantified CSP, have yet limited a tangible conclusion regarding the contribution of CSP to psychopathology. The most commonly applied method has been a subjective classification by a radiologist of small or large CSP[28,32,36,86], dependent on different definitions and criteria, resulting in large variability and inconsistencies among raters. Moreover, this manual classification requires both time and expertise. Some researchers adopted more quantitative methods of classification, such as counting the number of slices in which the cavity clearly appears (especially on coronal MRI views), and multiplying it by the slice thickness in order to calculate the anterior-to-posterior length of the cavum[31,33,41,47,54,87]. Even with this more quantitate method, there are still conflicting results among the studies that employed such technique[48]. Moreover, such linear measurements only permit a unidimensional representation of the CSP, which can have a complex three-dimensional shape. Volumetric CSP measurement, as employed in this study, may be more meaningful than linear methodologies, since that they provide detailed information about the true size of the structure[88]. Our comprehensive approach of combining automated and manual assessments allowed greater confidence in the results and strengthen findings' generalizability. Having a large sample

bioRxiv preprint doi: https://doi.org/10.1101/721134; this version posted August 1, 2019. The copyright holder for this preprint (which was not certified by peer review) is the author/funder. All rights reserved. No reuse allowed without permission.

size allowed to find a sufficient group of individuals with enlarged CSP presence (n=38), thus increasing the statistical power and conclusions.

Although our findings are promising, this work has several limitations. First, as in most PTSD studies, there is a lack of baseline measurement before trauma exposure. However, as structural brain changes typically occur at time frames of months and years, and considering that MRI scans were conducted in here within one-month form exposure, it is plausible to assume that structural abnormalities would reflect pre-disposition factors rather than consequence of trauma exposure. Second, majority of participants suffered from a single trauma, which was mostly related to car accidents. Future work may explore the relationship between these structural brain abnormalities and PTSD symptom severity among varying traumatic events (e.g. terror attacks, sexual or interpersonal violence, continuous traumatic experiences). Lastly, future studies should further examine the relation between hippocampus, CSP and PTSD symptomatology in trauma-exposed individuals in order to increase the validity and replicability of out findings.

This study suggests a promising opportunity of an easy-to-detect individual neuroanatomical abnormalities, large CSP and small hippocampus, that together could serve as distinct neuroanatomical signature for the likelihood to develop psychopathology following exposure to traumatic events. Such risk factors can be used meaningfully to improve early diagnostic assessment and since it further predicted long term prognosis of the PTSD, it could also serve as a monitoring marker for treatment outcome. As structural MRI is becoming more available, we could readily identify individuals who could benefit from early intervention following trauma and follow up their clinical course in an objective manner.

bioRxiv preprint doi: https://doi.org/10.1101/721134; this version posted August 1, 2019. The copyright holder for this preprint (which was not certified by peer review) is the author/funder. All rights reserved. No reuse allowed without permission.

Acknowledgments: This work was supported by award number R01MH-103287 from the National Institute of Mental Health (NIMH) to AS, and had undergone critical review by the NIMH Adult Psychopathology and Disorders of Aging (ADPA) study section. Nevertheless, the NIMH had no role in the design, execution, data management and data analysis of the current study. The content is solely the responsibility of the authors, and does not necessarily represent the official views of the NIMH. The authors would like to thank the research team at Tel-Aviv Sourasky Medical Center for their major contribution in carrying out this research, including subjects' recruitment and screening, and performing clinical and neural assessments. The authors also wish to thank Yoav Zeevi for his assistance in statistical consultation.

Disclosures: The authors declare that they have no financial disclosures and no conflict of interests.

bioRxiv preprint doi: https://doi.org/10.1101/721134; this version posted August 1, 2019. The copyright holder for this preprint (which was not certified by peer review) is the author/funder. All rights reserved. No reuse allowed without permission.

References

1. Benjet C, Bromet E, Karam EG, et al. The epidemiology of traumatic event exposure worldwide: results from the World Mental Health Survey Consortium. *Psychol Med*. 2016;46(2):327-343. doi:10.1017/S0033291715001981

2. Shalev A, Liberzon I, Marmar C. Post-Traumatic Stress Disorder. *N Engl J Med*. 2017;376(25):2459-2469. doi:10.1056/NEJMra1612499

3. Kessler RC, Sonnega A, Bromet E, Hughes M, Nelson CB. Posttraumatic Stress Disorder in the National Comorbidity Survey. *Arch Gen Psychiatry*. 1995;52(12):1048. doi:10.1001/archpsyc.1995.03950240066012

4. Kessler RC. Posttraumatic stress disorder: the burden to the individual and to society. *J Clin Psychiatry*. 2000;61:4-12.

5. Kessler RC, Berglund P, Demler O, Jin R, Merikangas KR, Walters EE. Lifetime Prevalence and Age-of-Onset Distributions of DSM-IV Disorders in the National Comorbidity Survey Replication. *Arch Gen Psychiatry*. 2005;62(6):593. doi:10.1001/archpsyc.62.6.593

6. Shalev AY, Ankri YLE, Peleg T, Israeli-Shalev Y, Freedman S. Barriers to receiving early care for PTSD: results from the Jerusalem trauma outreach and prevention study. *Psychiatr Serv*. 2011;62(7):765-773. doi:10.1176/appi.ps.62.7.765

7. Swartz JR, Knodt AR, Radtke SR, Hariri AR. A Neural Biomarker of Psychological Vulnerability to Future Life Stress. *Neuron*. 2015;85(3):505-511. doi:10.1016/J.NEURON.2014.12.055

8. Swartz JR, Knodt AR, Radtke SR, Hariri AR. A neural biomarker of psychological vulnerability to future life stress. *Neuron*. 2015;85(3):505-511. doi:10.1016/j.neuron.2014.12.055

bioRxiv preprint doi: https://doi.org/10.1101/721134; this version posted August 1, 2019. The copyright holder for this preprint (which was not certified by peer review) is the author/funder. All rights reserved. No reuse allowed without permission.

9. Admon R, Milad MR, Hendler T. A causal model of post-traumatic stress disorder: disentangling predisposed from acquired neural abnormalities. *Trends Cogn Sci*. 2013;17(7):337-347. doi:10.1016/J.TICS.2013.05.005

10. Galatzer-Levy IR, Ankri Y, Freedman S, et al. Early PTSD symptom trajectories: persistence, recovery, and response to treatment: results from the Jerusalem Trauma Outreach and Prevention Study (J-TOPS). *PLoS One*. 2013;8(8):e70084. doi:10.1371/journal.pone.0070084

11. Shalev AY, Ankri Y, Israeli-Shalev Y, Peleg T, Adessky R, Freedman S. Prevention of Posttraumatic Stress Disorder by Early Treatment. *Arch Gen Psychiatry*. 2012;69(2):166. doi:10.1001/archgenpsychiatry.2011.127

12. Shalev AY, Ankri YLE, Peleg T, Israeli-Shalev Y, Freedman S. Barriers to Receiving Early Care for PTSD: Results From the Jerusalem Trauma Outreach and Prevention Study. *Psychiatr Serv*. 2011;62(7):765-773. doi:10.1176/ps.62.7.pss6207_0765

13. Pitman RK, Rasmusson AM, Koenen KC, et al. Biological studies of post-traumatic stress disorder. *Nat Rev Neurosci*. 2012;13(11):769-787. doi:10.1038/nrn3339

14. Kitayama N, Vaccarino V, Kutner M, Weiss P, Bremner JD. Magnetic resonance imaging (MRI) measurement of hippocampal volume in posttraumatic stress disorder: A meta-analysis. *J Affect Disord*. 2005;88(1):79-86. doi:10.1016/j.jad.2005.05.014

15. Z. W, T.C. N, S.G. M, et al. Magnetic resonance imaging of hippocampal subfields in posttraumatic stress disorder. *Arch Gen Psychiatry*. 2010;67(3):296-303. http://archpsyc.ama-assn.org/cgi/reprint/67/3/296%5Cnhttp://ovidsp.ovid.com/ovidweb.cgi?T=JS&PAGE=reference&D=emed9&NEWS=N&AN=2010147464. Accessed January 16, 2019.

16. E. SM. Bilateral hippocampal volume reduction in adults with post□traumatic stress

bioRxiv preprint doi: https://doi.org/10.1101/721134; this version posted August 1, 2019. The copyright holder for this preprint (which was not certified by peer review) is the author/funder. All rights reserved. No reuse allowed without permission.

disorder: A meta analysis of structural MRI studies. *Hippocampus*. 2005;15(6):798-807. doi:10.1002/hipo.20102

17. Karl A, Schaefer M, Malta LS, et al. A meta-analysis of structural brain abnormalities in PTSD. *Neurosci Biobehav Rev*. 2006;30(7):1004-1031. doi:10.1016/j.amp.2006.02.006

18. Sapolsky RM, Uno H, Rebert CS, Finch CE. Hippocampal damage associated with prolonged glucocorticoid exposure in primates. *J Neurosci*. 1990;10(9):2897-2902. http://www.ncbi.nlm.nih.gov/pubmed/2398367. Accessed March 9, 2018.

19. Gilbertson MW, Shenton ME, Ciszewski A, et al. Smaller hippocampal volume predicts pathologic vulnerability to psychological trauma. *Nat Neurosci*. 2002;5(11):1242-1247. doi:10.1038/nn958

20. Gurvits T V., Metzger LJ, Lasko NB, et al. Subtle Neurologic Compromise as a Vulnerability Factor for Combat-Related Posttraumatic Stress Disorder. *Arch Gen Psychiatry*. 2006;63(5):571. doi:10.1001/archpsyc.63.5.571

21. Acheson DT, Gresack JE. Hippocampal dysfunction effects on context memory: Possible etiology for posttraumatic stress disorder. *Neuropharmacology*. 2012;62(2):674-685. doi:10.1016/J.NEUROPHARM.2011.04.029

22. Admon R, Leykin D, Lubin G, et al. Stress-induced reduction in hippocampal volume and connectivity with the ventromedial prefrontal cortex are related to maladaptive responses to stressful military service. *Hum Brain Mapp*. 2013;34(11):2808-2816. doi:10.1002/hbm.22100

23. Woon FL, Sood S, Hedges DW. Hippocampal volume deficits associated with exposure to psychological trauma and posttraumatic stress disorder in adults: A meta-analysis. *Prog Neuro-Psychopharmacology Biol Psychiatry*. 2010;34(7):1181-1188. doi:10.1016/j.pnpbp.2010.06.016

bioRxiv preprint doi: https://doi.org/10.1101/721134; this version posted August 1, 2019. The copyright holder for this preprint (which was not certified by peer review) is the author/funder. All rights reserved. No reuse allowed without permission.

24. Levy-Gigi E, Szabó C, Kelemen O, Kéri S. Association among clinical response, hippocampal volume, and FKBP5 gene expression in individuals with posttraumatic stress disorder receiving cognitive behavioral therapy. *Biol Psychiatry*. 2013;74(11):793-800. doi:10.1016/j.biopsych.2013.05.017

25. Pitman RK, Rasmusson AM, Koenen KC, et al. Biological studies of post-traumatic stress disorder. *Nat Rev Neurosci*. 2012;13(11):769-787. doi:10.1038/nrn3339

26. Bolsinger J, Seifritz E, Kleim B, Manoliu A. Neuroimaging Correlates of Resilience to Traumatic Events—A Comprehensive Review. *Front Psychiatry*. 2018;9:693. doi:10.3389/fpsyt.2018.00693

27. Bodensteiner JB, Schaefer GB. Wide cavum septum pellucidum: a marker of disturbed brain development. *Pediatr Neurol*. 1990;6(6):391-394. doi:10.1016/0887-8994(90)90007-N

28. Jurjus GJ, Nasrallah HA, Olson SC, Schwarzkopf SB. Cavum septum pellucidum in schizophrenia, affective disorder and healthy controls: a magnetic resonance imaging study. *Psychol Med*. 1993;23(02):319. doi:10.1017/S0033291700028403

29. Rakic P, Yakovlev PI. Development of the corpus callosum and cavum septi in man. *J Comp Neurol*. 1968;132(1):45-72. doi:10.1002/cne.901320103

30. Sarwar M. The septum pellucidum: normal and abnormal. *Am J Neuroradiol*. 1989;10(5):989-1005. http://www.ncbi.nlm.nih.gov/pubmed/2505543.

31. de Souza Crippa JA, Zuardi AW, Busatto GF, et al. Cavum septum pellucidum and adhesio interthalamica in schizophrenia: an MRI study. *Eur Psychiatry*. 2006;21(5):291-299. doi:10.1016/j.eurpsy.2005.09.010

32. Degreef G, Lantos G, Bogerts B, Ashtari M, Lieberman J. Abnormalities of the septum pellucidum on MR scans in first-episode schizophrenic patients. *Am J Neuroradiol*.

bioRxiv preprint doi: https://doi.org/10.1101/721134; this version posted August 1, 2019. The copyright holder for this preprint (which was not certified by peer review) is the author/funder. All rights reserved. No reuse allowed without permission.

1992;13(3):835-840. http://www.ajnr.org/content/ajnr/13/3/835.full.pdf. Accessed January 24, 2018.

33. Nopoulos P, Swayze V, Flaum M, Ehrhardt JC, Yuh WTC, Andreasen NC. Cavum septi pellucidi in normals and patients with schizophrenia as detected by magnetic resonance imaging. *Biol Psychiatry*. 1997;41(11):1102-1108. doi:10.1016/S0006-3223(96)00209-0

34. Scott TF, Price TR, George MS, Brillman J, Rothfus W. Midline cerebral malformations and schizophrenia. *J Neuropsychiatry Clin Neurosci*. 1993;5(3):287-293. doi:10.1176/jnp.5.3.287

35. Shioiri T, Oshitani Y, Kato T, et al. Prevalence of cavum septum pellucidum detected by MRI in patients with bipolar disorder, major depression and schizophrenia. *Psychol Med*. 1996;26(02):431. doi:10.1017/S0033291700034838

36. DeLisi LE, Hoff AL, Kushner M, Degreef G. Increased prevalence of cavum septum pellucidum in schizophrenia. *Psychiatry Res Neuroimaging*. 1993;50(3):193-199. doi:10.1016/0925-4927(93)90030-L

37. Hagino H, Suzuki M, Kurokawa K, et al. Magnetic Resonance Imaging Study of the Cavum Septi Pellucidi in Patients With Schizophrenia. *Am J Psychiatry*. 2001;158(10):1717-1719. doi:10.1176/appi.ajp.158.10.1717

38. FUKUZAKO Tsuyosh, FUKUZAKO H, KOUAMA S, HASHIGUCHI T, TAKIGAWA M. Cavum septum pellucidum in schizophrenia: A magnetic resonance imaging study. *Psychiatry Clin Neurosci*. 1996;50(3):125-128. doi:10.1111/j.1440-1819.1996.tb01675.x

39. Kwon JS, Shenton ME, Hirayasu Y, et al. MRI Study of Cavum Septi Pellucidi in Schizophrenia, Affective Disorder, and Schizotypal Personality Disorder. *Am J Psychiatry*. 1998;155(4):509-515. doi:10.1176/ajp.155.4.509

40. Nopoulos PC, Giedd JN, Andreasen NC, Rapoport JL. Frequency and Severity of Enlarged

bioRxiv preprint doi: https://doi.org/10.1101/721134; this version posted August 1, 2019. The copyright holder for this preprint (which was not certified by peer review) is the author/funder. All rights reserved. No reuse allowed without permission.

Cavum Septi Pellucidi in Childhood-Onset Schizophrenia. *Am J Psychiatry*. 1998;155(8):1074-1079. doi:10.1176/ajp.155.8.1074

41. Rajarethinam R, Miedler J, DeQuardo J, et al. Prevalence of cavum septum pellucidum in schizophrenia studied with MRI. *Schizophr Res*. 2001;48(2-3):201-205. doi:10.1016/S0920-9964(00)00110-9

42. Ferrari MCF, Busatto GF, McGuire PK, Crippa JAS. Structural magnetic ressonance imaging in anxiety disorders: an update of research findings. *Rev Bras Psiquiatr*. 2008;30(3):251-264. doi:10.1590/S1516-44462008000300013

43. Kim MJ, Lyoo IK, Dager SR, et al. The occurrence of cavum septi pellucidi enlargement is increased in bipolar disorder patients. *Bipolar Disord*. 2007;9(3):274-280. doi:10.1111/j.1399-5618.2007.00442.x

44. Beraldi GH, Prado KS, Amann BL, Radua J, Friedman L, Elkis H. Meta-analyses of cavum septum pellucidum in mood disorders in comparison with healthy controls or schizophrenia. *Eur Neuropsychopharmacol*. 2018;28(12):1325-1338. doi:10.1016/J.EURONEURO.2018.10.001

45. Chun T, Filippi CG, Zimmerman RD, et al. Diffusion changes in the aging human brain. *AJNR Am J Neuroradiol*. 2003;21(6):1078-1083. http://www.ncbi.nlm.nih.gov/pubmed/10871018. Accessed January 26, 2018.

46. Nopoulos P, Krie A, Andreasen NC. Enlarged Cavum Septi Pellucidi in Patients With Schizophrenia. *J Neuropsychiatry Clin Neurosci*. 2000;12(3):344-349. doi:10.1176/jnp.12.3.344

47. Flashman LA, Roth RM, Pixley HS, et al. Cavum septum pellucidum in schizophrenia: Clinical and neuropsychological correlates. *Psychiatry Res Neuroimaging*. 2007;154(2):147-155. doi:10.1016/J.PSCYCHRESNS.2006.09.001

bioRxiv preprint doi: https://doi.org/10.1101/721134; this version posted August 1, 2019. The copyright holder for this preprint (which was not certified by peer review) is the author/funder. All rights reserved. No reuse allowed without permission.

48. Trzesniak C, Oliveira IR, Kempton MJ, et al. Are cavum septum pellucidum abnormalities more common in schizophrenia spectrum disorders? A systematic review and meta-analysis. *Schizophr Res*. 2011;125(1):1-12. doi:10.1016/j.schres.2010.09.016

49. Rajarethinam R, Sohi J, Arfken C, Keshavan MS. No difference in the prevalence of cavum septum pellucidum (CSP) between first-episode schizophrenia patients, offspring of schizophrenia patients and healthy controls. *Schizophr Res*. 2008;103(1-3):22-25. doi:10.1016/j.schres.2007.11.031

50. Takahashi T, Malhi GS, Wood SJ, et al. Midline brain abnormalities in established bipolar affective disorder. *J Affect Disord*. 2010;122(3):301-305. doi:10.1016/J.JAD.2009.09.003

51. Chon M-W, Choi J-S, Kang D-H, Jung MH, Kwon JS. MRI study of the cavum septum pellucidum in obsessive–compulsive disorder. *Eur Arch Psychiatry Clin Neurosci*. 2010;260(4):337-343. doi:10.1007/s00406-009-0081-6

52. T. T, M. Y, V. L, et al. Midline brain structures in patients with current and remitted major depression. *Prog Neuro-Psychopharmacology Biol Psychiatry*. 2009;33(6):1058-1063. http://ovidsp.ovid.com/ovidweb.cgi?T=JS&PAGE=reference&D=emed9&NEWS=N&AN=2009374102. Accessed April 10, 2019.

53. Nopoulos P, Berg S, Castellenos FX, Delgado A, Andreasen NC, Rapoport JL. Developmental Brain Anomalies in Children With Attention-Deficit Hyperactivity Disorder. *J Child Neurol*. 2000;15(2):102-108. doi:10.1177/088307380001500208

54. Takahashi T, Suzuki M, Hagino H, et al. Prevalence of large cavum septi pellucidi and its relation to the medial temporal lobe structures in schizophrenia spectrum. *Prog Neuro-Psychopharmacology Biol Psychiatry*. 2007;31(6):1235-1241. doi:10.1016/J.PNPBP.2007.04.019

55. Myslobodsky MS, Glicksohn J, Singer J, et al. Changes of brain anatomy in patients with

bioRxiv preprint doi: https://doi.org/10.1101/721134; this version posted August 1, 2019. The copyright holder for this preprint (which was not certified by peer review) is the author/funder. All rights reserved. No reuse allowed without permission.

posttraumatic stress disorder: a pilot magnetic resonance imaging study. *Psychiatry Res*. 1995;58(3):259-264. http://www.ncbi.nlm.nih.gov/sites/entrez?Db=pubmed&DbFrom=pubmed&Cmd=Link&LinkName=pubmed_pubmed&LinkReadableName=Related Articles&IdsFromResult=8570781&ordinalpos=3&itool=EntrezSystem2.PEntrez.Pubmed.Pubmed_ResultsPanel.Pubmed_RVDocSum.

56. May FS, Chen QC, Gilbertson MW, Shenton ME, Pitman RK. Cavum septum pellucidum in monozygotic twins discordant for combat exposure: Relationship to posttraumatic stress disorder. *Biol Psychiatry*. 2004;55(6):656-658. doi:10.1016/j.biopsych.2003.09.018

57. Morey RA, Petty CM, Xu Y, et al. A comparison of automated segmentation and manual tracing for quantifying hippocampal and amygdala volumes. *Neuroimage*. 2009;45(3):855-866. doi:10.1016/J.NEUROIMAGE.2008.12.033

58. Tae WS, Kim SS, Lee KU, Nam E-C, Kim KW. Validation of hippocampal volumes measured using a manual method and two automated methods (FreeSurfer and IBASPM) in chronic major depressive disorder. *Neuroradiology*. 2008;50(7):569-581. doi:10.1007/s00234-008-0383-9

59. Mulder ER, de Jong RA, Knol DL, et al. Hippocampal volume change measurement: Quantitative assessment of the reproducibility of expert manual outlining and the automated methods FreeSurfer and FIRST. *Neuroimage*. 2014;92:169-181. doi:10.1016/J.NEUROIMAGE.2014.01.058

61. Weathers FW, Huska JA, Keane TM. The PTSD Checklist-Civilian Version (PCL-C). *Boston, MA Natl Cent for, 1994*1991 ..

62. Blake DD, Weathers FW, Nagy LM, et al. The development of a clinician-administered PTSD scale. *J Trauma Stress*. 1995;8(1):75-90. doi:10.1002/jts.2490080106

bioRxiv preprint doi: https://doi.org/10.1101/721134; this version posted August 1, 2019. The copyright holder for this preprint (which was not certified by peer review) is the author/funder. All rights reserved. No reuse allowed without permission.

63. Weathers FW, Bovin MJ, Lee DJ, et al. The Clinician-Administered PTSD Scale for DSM–5 (CAPS-5): Development and initial psychometric evaluation in military veterans. *Psychol Assess*. 2018;30(3):383-395. doi:10.1037/pas0000486

64. Fischl B. FreeSurfer. *Neuroimage*. 2012;62(2):774-781. doi:10.1016/j.neuroimage.2012.01.021

65. Sánchez-Benavides G, … BG-A-PR, 2010 undefined. Manual validation of FreeSurfer's automated hippocampal segmentation in normal aging, mild cognitive impairment, and Alzheimer Disease subjects. *Elsevier*. https://www.sciencedirect.com/science/article/pii/S0925492709002443. Accessed April 10, 2019.

66. Wenger E, Mårtensson J, … HN-H brain, 2014 undefined. Comparing manual and automatic segmentation of hippocampal volumes: reliability and validity issues in younger and older brains. *Wiley Online Libr*. https://onlinelibrary.wiley.com/doi/abs/10.1002/hbm.22473. Accessed April 10, 2019.

67. Preacher KJ, Hayes AF. Asymptotic and resampling strategies for assessing and comparing indirect effects in multiple mediator models. *Behav Res Methods*. 2008;40(3):879-891. doi:10.3758/BRM.40.3.879

68. Hayes AF. *Introduction to Mediation, Moderation and Conditional Process Analysis*. Vol 53.; 2013. doi:10.5539/ass.v11n9p207

69. Feng C, Wang H, Lu N, et al. Log-transformation and its implications for data analysis. *Shanghai Arch psychiatry*. 2014;26(2):105-109. doi:10.3969/j.issn.1002-0829.2014.02.009

70. Aiken LS, West SG, Reno RR. *Multiple Regression: Testing and Interpreting Interactions*. Vol 45.; 1991. doi:10.2307/2583960

bioRxiv preprint doi: https://doi.org/10.1101/721134; this version posted August 1, 2019. The copyright holder for this preprint (which was not certified by peer review) is the author/funder. All rights reserved. No reuse allowed without permission.

71. Douglas J, Tammy M, Richard A. MRI-based measurement of hippocampal volume in patients with combat-related p ... *ncbi.nlm.nih.gov*1995 .;i. https://www.ncbi.nlm.nih.gov/pmc/articles/PMC3233767/. Accessed April 25, 2018.

72. J.D. B, P. R, E. V, et al. Magnetic resonance imaging-based measurement of hippocampal volume in posttraumatic stress disorder related to childhood physical and sexual abuse: a preliminary report. *Biol Psychiatry*. 1997;41(1):23-32. doi:http://dx.doi.org/10.1016/S0006-3223(96)00162-X

73. Gurvits T, Shenton M, Hokama H, Ohta H, Lasko N, Pitman R. Magnetic resonance imagine study of hippocampal volume in chronic, combat-related PTSD. *Biol Psychiatry*. 1996;40:1091-1099. http://www.sciencedirect.com/science/article/pii/S0006322396002296. Accessed August 27, 2017.

74. Stein MB, Koverola C, Hanna C, Torchia MG, McClarty B. Hippocampal volume in women victimized by childhood sexual abuse. Psychological Medicine, 27, 951-959. *Psychol Med*. 1997;27:951-959. https://www.cambridge.org/core/journals/psychological-medicine/article/hippocampal-volume-in-women-victimized-by-childhood-sexual-abuse/F4CB63A9A69EEAB4377CC2C4F43E115D. Accessed April 25, 2018.

75. Yehuda R. Are glucocortoids responsible for putative hippocampal damage in PTSD? How and when to decide. *Hippocampus*. 2001;11(2):85-89. doi:10.1002/hipo.1025

76. McEwen BS. Commentary on PTSD discussion. *Hippocampus*. 2001;11(2):82-84. doi:10.1002/hipo.1024

77. Bremner JD. Hypotheses and controversies related to effects of stress on the hippocampus: An argument for stress-induced damage to the hippocampus in patients with posttraumatic stress disorder. *Hippocampus*. 2001;11(2):75-81. doi:10.1002/hipo.1023

78. Pitman RK. Hippocampal diminution in PTSD: More (or less?) than meets the eye.

bioRxiv preprint doi: https://doi.org/10.1101/721134; this version posted August 1, 2019. The copyright holder for this preprint (which was not certified by peer review) is the author/funder. All rights reserved. No reuse allowed without permission.

Hippocampus. 2001;11(2):73-74. doi:10.1002/hipo.1022

79. Trzesniak C, Oliveira IR, Kempton MJ, et al. Are cavum septum pellucidum abnormalities more common in schizophrenia spectrum disorders? A systematic review and meta-analysis. *Schizophr Res*. 2011;125(1):1-12. doi:10.1016/j.schres.2010.09.016

80. White T, Vernooij MW, Verhulst FC, et al. Cavum Septum Pellucidum in the General Pediatric Population and Its Relation to Surrounding Brain Structure Volumes, Cognitive Function, and Emotional or Behavioral Problems. *Am J Neuroradiol*. 2019:340-346. doi:10.3174/ajnr.a5939

81. Yehuda R, McFarlane AC, Shalev AY. Predicting the development of posttraumatic stress disorder from the acute response to a traumatic event. *Biol Psychiatry*. 1998;44(12):1305-1313.

82. Koren D, Arnon I, Klein E. Long term course of chronic posttraumatic stress disorder in traffic accident victims: A three-year prospective follow-up study. *Behav Res Ther*. 2001;39(12):1449-1458. doi:10.1016/S0005-7967(01)00025-0

83. Hepp U, Moergeli H, Buchi S, et al. Post-traumatic stress disorder in serious accidental injury: 3-Year follow-up study. *Br J Psychiatry*. 2008;192(5):376-383. doi:10.1192/bjp.bp.106.030569

84. Perkonigg A, Pfister H, Stein MB, et al. Longitudinal Course of Posttraumatic Stress Disorder and Posttraumatic Stress Disorder Symptoms in a Community Sample of Adolescents and Young Adults. *Am J Psychiatry*. 2005;162(7):1320-1327. doi:10.1176/appi.ajp.162.7.1320

85. Shalev AY, Freedman S. PTSD Following Terrorist Attacks: A Prospective Evaluation. *Am J Psychiatry*. 2005;162(6):1188-1191. doi:10.1176/appi.ajp.162.6.1188

bioRxiv preprint doi: https://doi.org/10.1101/721134; this version posted August 1, 2019. The copyright holder for this preprint (which was not certified by peer review) is the author/funder. All rights reserved. No reuse allowed without permission.

86. Shioiri T, Oshitani Y, Kato T, et al. Prevalence of cavum septum pellucidum detected by MRI in patients with bipolar disorder, major depression and schizophrenia. *Psychol Med*. 1996;26(02):431. doi:10.1017/S0033291700034838

87. Takahashi T, Yung AR, Yücel M, et al. Prevalence of large cavum septi pellucidi in ultra high-risk individuals and patients with psychotic disorders. *Schizophr Res*. 2008;105(1-3):236-244. doi:10.1016/j.schres.2008.06.021

88. Crippa JA de S, Zuardi AW, Busatto GF, et al. Cavum septum pellucidum and adhesio interthalamica in schizophrenia: an MRI study. *Eur Psychiatry*. 2006;21(5):291-299. doi:10.1016/J.EURPSY.2005.09.010

bioRxiv preprint doi: https://doi.org/10.1101/721134; this version posted August 1, 2019. The copyright holder for this preprint (which was not certified by peer review) is the author/funder. All rights reserved. No reuse allowed without permission.

Tables Titles and Legends

Table 1. Demographic, clinical and neuroanatomical characteristics of the participants along the three time-points. Means (M) and standard deviations (SD) of participants' age, gender (Women:Men), CAPS-5 and CAPS-4 total scores, bilateral hippocampal volume and CSP volume, at one-, six- and fourteen-month following trauma (TP1, TP2 and TP3, respectively).

	TP1 (n=133)		TP2 (n=97)		TP3 (n=78)	
Measure	*M*	*SD*	*M*	*SD*	*M*	*SD*
Age	34.38	12.01	35.82	12.46	35.40	12.87
Gender (W:M)	67:66	-	48:49	-	37:41	-
CAPS-5 Total	24.30	11.85	14.74	11.40	8.65	8.58
CAPS-4 Total	50.29	22.72	30.19	22.98	18.05	17.53
Hippocampus Vol	8464	928	8448	936	8475	875
CSP Vol	1.51	3.19	1.62	3.24	1.57	3.25

Table 2. Hippocampus volume at TP1 moderates relationship between CSP volume at TP1 and PTSD symptoms at TP1. Regression model of CAPS-4 total scores at TP1 predicted from CSP and hippocampal volumes of 133 participants, with age, gender, trauma type and ICV as covariates.

Predictor	**Coefficient**	**SE**	**t**	***p***
Bilateral Hippocampus Volume	.0040	.0025	1.6131	.1092
CSP Volume	7.9672	5.9510	1.3388	.1831
CSP x Hippocampus*	-.0134	.0060	-2.2487	.0263
Age*	-.3374	.1617	-2.0867	.0389
Gender	2.9068	4.8019	.6054	.5460
Trauma Type	-.3097	.9858	-.3142	.7539
ICV*	.0000	.0000	-2.1171	.0362

*p <.05

bioRxiv preprint doi: https://doi.org/10.1101/721134; this version posted August 1, 2019. The copyright holder for this preprint (which was not certified by peer review) is the author/funder. All rights reserved. No reuse allowed without permission.

Table 3. Hippocampus volume at TP1 moderates relationship between CSP volume at TP1 and PTSD symptoms at TP3. Regression model of CAPS-4 total scores at TP3 predicted from CSP and hippocampal volumes of 78 participants, with age, gender, trauma type and ICV as covariates.

Predictor	**Coefficient**	**SE**	**t**	***p***
Bilateral Hippocampus Volume	-.0001	.0027	-.0382	.9696
CSP Volume	.0297	6.1805	.0048	.9962
CSP x Hippocampus*	-.0144	.0059	-2.4316	.0176
Age	.0087	.1583	.0550	.9563
Gender	-.2879	4.9999	-.0576	.9543
Trauma Type	-.2979	1.0966	-.2717	.7867
ICV	.0000	.0000	-1.0894	.2797

*$p < .05$

bioRxiv preprint doi: https://doi.org/10.1101/721134; this version posted August 1, 2019. The copyright holder for this preprint (which was not certified by peer review) is the author/funder. All rights reserved. No reuse allowed without permission.

Figures Titles and Legends

Figure 1: Cavum Septum Pellucidum (CSP). Coronal view of the T_1-weighted (MPRAGE) image of an example subject. A red line marks the CSP as identified by Freesurfer automatic volumetric segmentation.

Figure 2: Interaction between hippocampus and CSP volumes at TP1 in predicting TP1 PTSD symptoms. Conditional effects of TP1 CSP volume on TP1 CAPS-4 total scores at different TP1 hippocampal volumes of 133 individuals (Q1=Low Hippocampal Volume in red, Q2=Median Hippocampal Volume in green, Q3=High Hippocampal Volume in blue). Both hippocampal and CSP volumes are centered. *significant at $p<0.05$

Figure 3: Interaction between hippocampus and CSP volumes at TP1 in predicting TP PTSD symptoms. Conditional effects of TP1 CSP volume on TP3 CAPS-4 total scores at different TP1 hippocampal volumes of 78 individuals (Q1=Low Hippocampal Volume in red, Q2=Median Hippocampal Volume in green, Q3=High Hippocampal Volume in blue). Both hippocampal and CSP volumes are centered. *significant at $p<0.1$

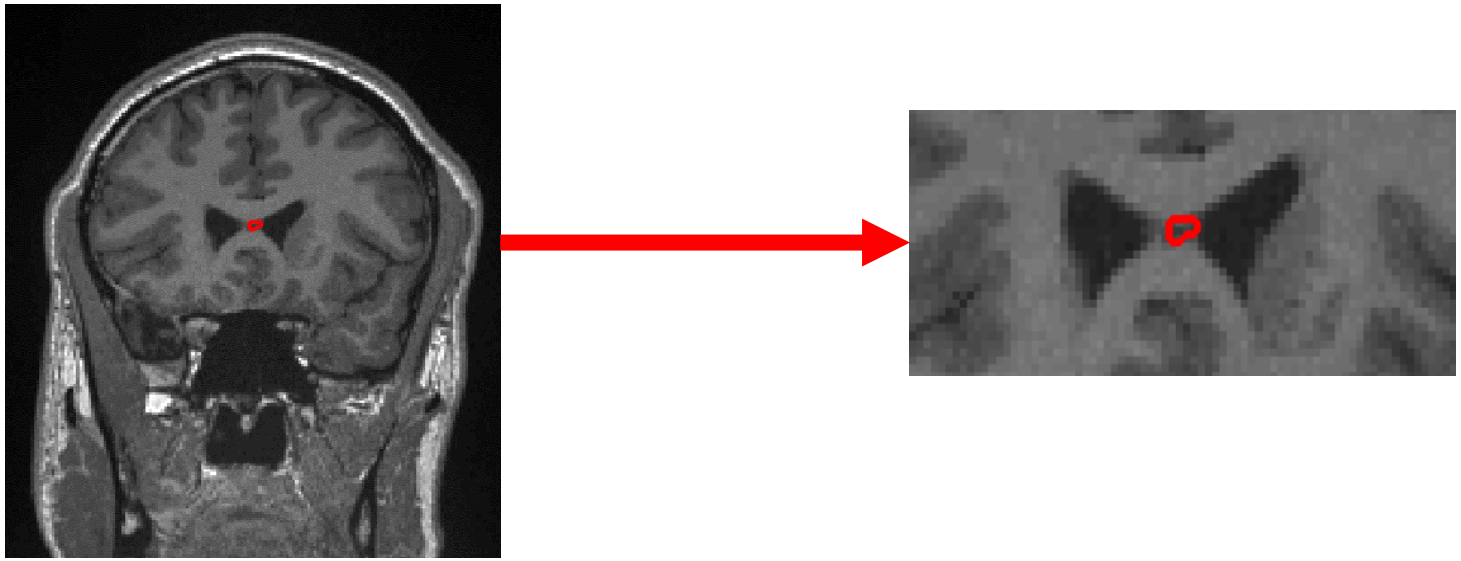

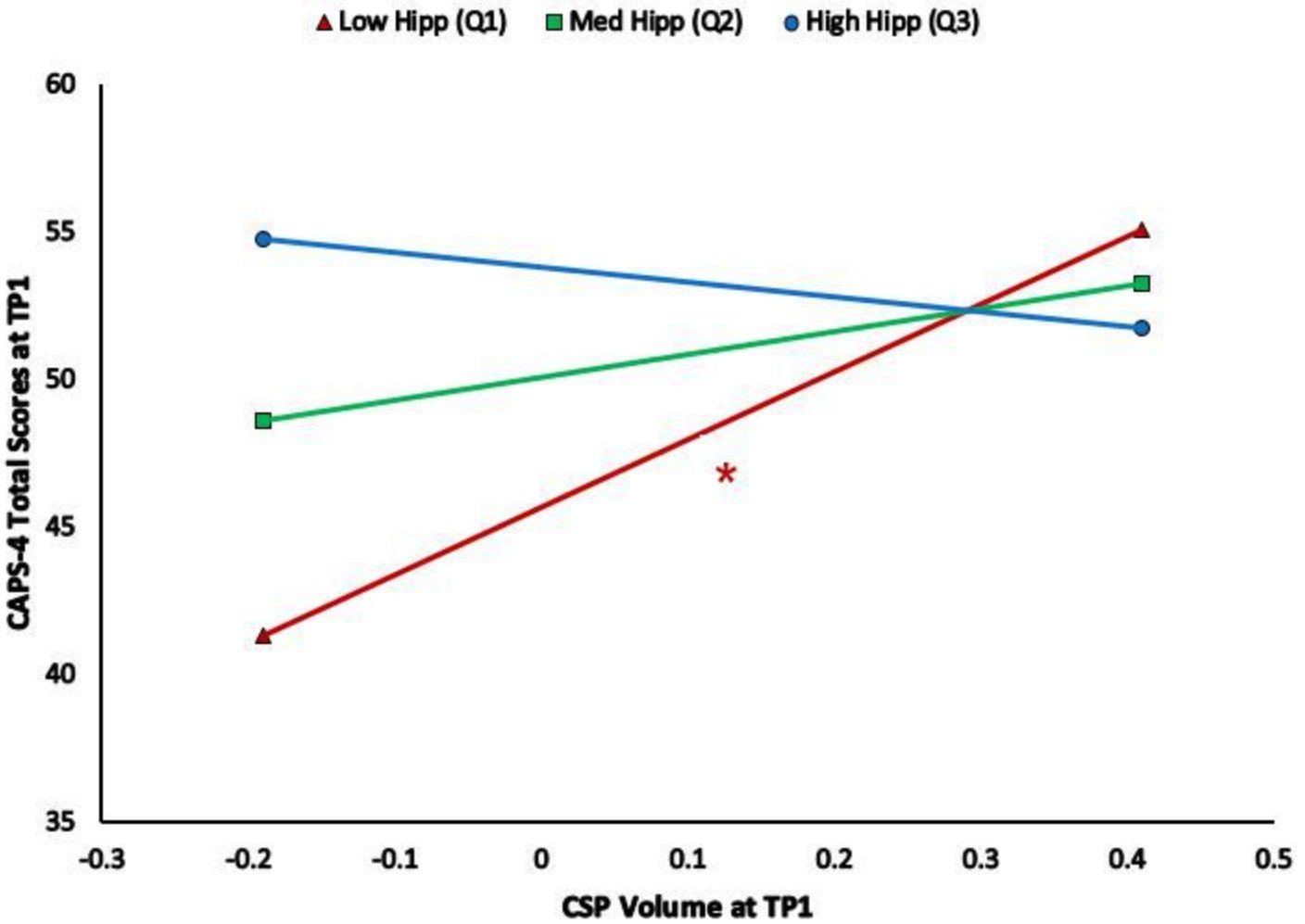
Low Hipp (Q1)
Med Hipp (Q2)
High Hipp (Q3)
60
55
50
45
40
35
CAPS-4 Total Scores at TP1
*
-0.3
-0.2
-0.1
0
0.1
0.2
0.3
0.4
0.5
CSP Volume at TP1

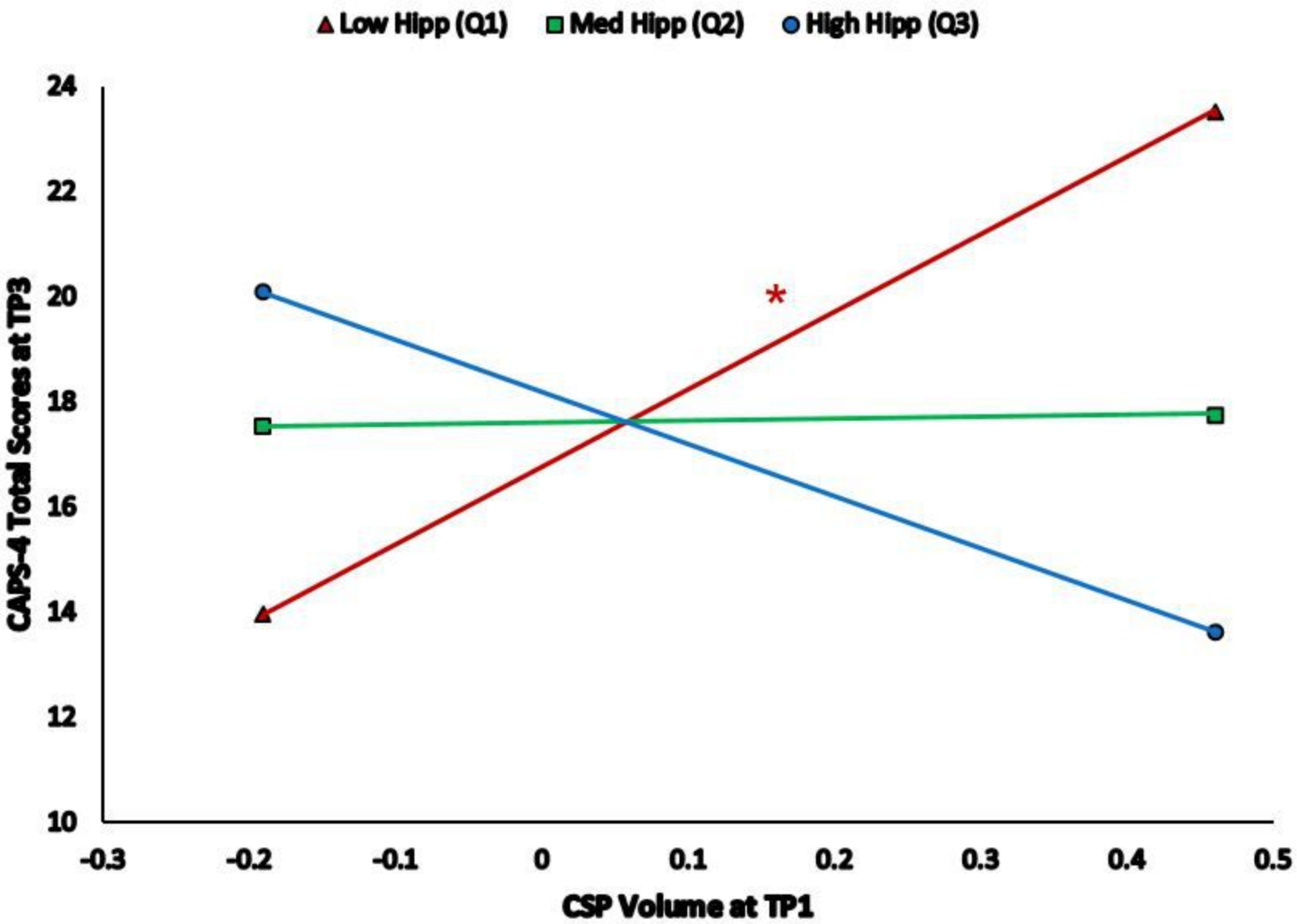
Low Hipp (Q1)
Med Hipp (Q2)
High Hipp (Q3)
CAPS-4 Total Scores at TP3
24
22
20
18
16
14
12
10
*
-0.3
-0.2
-0.1
0
0.1
0.2
0.3
0.4
0.5
CSP Volume at TP1