ASSESSMENT OF ANESTHESIA ON PHYSIOLOGICAL STABILITY AND BOLD SIGNAL RELIABILITY DURING VISUAL OR ACOUSTIC STIMULATION IN THE CAT

Alexandra Levine[2,3†], Benson Li[1†], Paisley Barnes[2‡], Stephen G. Lomber[1-4‡], and Blake E. Butler[*1,3,4]

[1]Department of Psychology
[2]Department of Physiology & Pharmacology
[3]Brain and Mind Institute
[4]National Centre for Audiology
†Authors made equal contributions

University of Western Ontario
London, Ontario, Canada N6A 5B7

‡Present address:
Department of Physiology
McGill University
Montréal, Québec, Canada H3G 1Y6

[*]Correspondence should be addressed to:
Dr. Blake Butler
Email: bbutler9@uwo.ca
Phone: 519-661-2111 x85831

Abstract:

Background: Neuroimaging methods including fMRI provide powerful tools to observe whole-brain functional networks. This is particularly powerful in animal models, allowing these networks to be probed using complementary methods. However, most animals must be anesthetized for neuroimaging, giving rise to complications resulting from anesthetic effects on the animal's physiological and neurological functions. For example, an established protocol for feline neuroimaging involves co-administration of ketamine and isoflurane – the latter of which is known to suppress cortical function.

New Method: Here, we compare this established protocol to alfaxalone, a single-agent anesthetic for functional neuroimaging. We first compare the two in a controlled environment to assess relative safety and to measure physiological stability over an extended time window. We then compare patterns of auditory and visually-evoked activity measured at 7T to assess mean signal strength and between-subjects signal variability.

Results in Comparison with Existing Methods: We show that alfaxalone results in more stable heart and respiratory rates over the 120 minutes testing period, with evidence of smaller between measurements variability in respiratory rates within this time window, when compared to ketamine plus isoflurane. Moreover, we demonstrate that both agents evoke similar mean BOLD signals across animals, but that alfaxalone elicits more consistent BOLD activity in response to sound stimuli across all ROIs observed.

Conclusions: Alfaxalone is observed to be more physiologically stable, evoking a more consistent BOLD signal across animals than the co-administration of ketamine and isoflurane. Thus, an alfaxalone-based protocol may represent a better approach for neuroimaging in animal models requiring anesthesia.

Keywords: anesthesia, fMRI, physiological stability, animal models, stimulus-evoked, BOLD

1. Introduction

Experiments in animal models continue to be critical for understanding the structure and function of the brain. For decades, cats have been successfully used as an animal model to study sensory systems, largely due to the remarkable similarities that they share with human cell types, neural pathways, and cytoarchitecture (Blake, 1979). Electrophysiological (Hubel and Wiesel, 1962; Liu et al., 2010), neuroanatomical (Lomber et al., 1995; Wong et al., 2015; Butler et al., 2016), behavioral (Heffner and Heffner, 1988; Wong et al., 2018), and imaging studies (Brown et al., 2014; Butler et al., 2015; Stolzberg et al., 2018) undertaken in the cat have played a critical role in advancing our knowledge of neural processing within visual and auditory systems, and the interactions between the two.

Recently, there has been increased interest in non-invasive neuroimaging methods like functional magnetic resonance imaging (fMRI) for the study of sensory system function in animal models. This approach offers several advantages, including the ability to examine perception at the whole-brain level, and the ability to undertake longitudinal, within-animal studies of sensory system development (which in turn aids in reducing the number of animals required to power meaningful comparisons). This offers a distinct advantage over other methods such as electrophysiological studies, which are highly invasive and are limited in their capacity to evaluate processes occurring over spatially disparate neural networks. fMRI measures changes in the ratio of oxygenated to deoxygenated blood, or blood-oxygen-level-dependent (BOLD) signals (Ogawa et al., 1990). An increase in this BOLD signal is thought to reflect increased neuronal activity compared to a baseline measurement (Buxton and Frank, 1997; Logothetis et al., 2001; Ferris et al., 2006). Moreover, by measuring the temporal coherence of the BOLD signal across spatially disparate areas of the brain, it is possible to estimate the degree to which these areas are functionally connected into networks that support perception and associated behaviors.

Modern fMRI scanners can provide spatial resolution with 1 mm precision, but the accuracy of these measures depends critically on minimizing subject movement within the scanner. While most human participants can be instructed to remain still during imaging sessions, this is not possible in most other animals, and meaningful measurements must thus

be taken under anesthesia. Anesthetic agents help minimize potential stress and fluctuations in behavior that can affect the quality of data retrieved. However, the use of anesthetics during fMRI necessitates due consideration be given to the effects of the drugs themselves (Ueki et al., 1992; Biermann et al., 2012), as these agents can influence neurovasculature by changing cerebral blood flow, blood volume, and rate of oxygen metabolism (Gao et al., 2017), and can suppress neuronal activity by reducing excitatory synaptic transmission or increasing inhibitory transmission (Richards, 1983). Further complications may include physiological variability based on the drug type, concentration, and route of administration (Peng et al., 2010; Nagore et al., 2013; Aksenov et al., 2015; Ros et al., 2017). Therefore, there is a need to establish a robust and reliable anesthetic protocol that will facilitate bridging the gap between animal and human neuronal organization and function.

Fortunately, decades of electrophysiological work in the cat has revealed a great deal about the effects of different anesthetic agents on recorded neural function. A common protocol involves the continuous infusion of ketamine alongside other agents such as sodium pentobarbital, xylazine, or diazepam to induce and maintain anesthesia (e.g. Heil and Irvine, 1998; Miller et al., 2002; Pienkowski and Eggermont, 2009). This protocol has evolved over time; for example, early studies found that ketamine infusion reduces spontaneous and peak firing rates in auditory cortex (Zurita et al., 1994), possibly due to altered sensory perception and reduced cortical glucose metabolism (Crosby et al., 1982; Oye et al., 1992). To reduce the amount of ketamine required for anesthesia (and reduce these suppressive effects, accordingly), Jezzard et al. (1997) proposed to pre-medicate with ketamine but maintain sedation with isoflurane (1-2%, gas). However, other studies showed that isoflurane redirected cerebral blood flow, and reduced neural activity recorded in various visual brain regions by up to 50% (Harel et al., 2002; Olman et al., 2003; White & Alkire, 2002). Isoflurane has recently been shown to suppress resting-state connectivity in the primary somatosensory cortex of non-human primates as well (Wu et al., 2016). Therefore, when establishing the protocol for initial fMRI experiments in the cat, Brown et al. (2013) reduced isoflurane concentrations to the minimum level required to maintain sedation (0.4-0.5%) and supplemented with a continuous rate infusion of ketamine (0.6-0.75 mg/kg/hr). Under this protocol, the authors were able to

record BOLD signal changes up to 6% in some but not all auditory regions. The protocol was used in subsequent auditory-evoked studies (Hall et al., 2014; Butler et al., 2015) and in an examination of resting-state connectivity using fMRI (Stolzberg et al., 2018).

In spite of successive revisions, the combination of isoflurane and ketamine is known to result in widespread cortical deactivation in other animals (e.g. Hodkinson et al., 2012). Moreover, these effects appear to differ by brain region/sensory modality such that the co-administration of ketamine and isoflurane may limit the ability to study sensory processes beyond audition (Oye et al., 1992; Ries & Puil, 1999; Höflich et al., 2017). Thus, there remains a need to develop an anesthetic protocol that can induce and maintain a light anesthetic plane sufficient to suppress movement, without drastic reductions in cortical activity across multiple brain regions.

Several potential agents were considered in the current study, but many were excluded because their mechanism of action was deemed not conducive for measuring BOLD signals (Table 1). Others were eliminated in consultation with veterinary care staff due to concerns with respect to physiological effects. As a result, alfaxalone was considered to be the strongest candidate protocol to serve as an alternative to the coadministration of ketamine and isoflurane as a primary anesthetic agent for fMRI. Alfaxalone: i) has dose-dependent effects on cardiovasculature, respiration, neuronal activity, and neuromusculature (Warne et al., 2015; Whittem et al., 2008; Muir et al., 2009; Taboada and Murison, 2010; Baldy-Moulinier et al., 1975) which may allow for more predictable changes in BOLD response; ii) has been found to sufficiently maintain a stable level of anesthesia for up to 2-hours as a stand-alone agent (Tamura et al., 2015; Deutsch et al., 2017) which in our experience is the typical amount of time required for neuroimaging in cats; and iii) has been successfully administered intravenously to maintain anesthesia in cats during surgical procedures in our own laboratory, and by others (Beths et al., 2014; Nagakubo et al., 2017) with minimal physiological side effects.

141 **Table 1.** Studies examining cardiovascular, respiratory, and neural effects of anesthetic agents.

Anesthetic	Primary Mechanism	First Author and Year	Reason for Exclusion
Pentobarbital	$GABA_A$ Agonist	Kaitin (1985)	Suppressed cortical activity
		Morin-Surun et al. (1984)	Inhibition of respiratory neurons
Propofol	$GABA_A$ Agonist	Lahti et al. (1999)	Decreased BOLD signal intensity
		Bonhomme et al. (2000)	Reduced cerebral blood flow
		Dueck et al. (2005)	Decreased BOLD signal intensity
Butorphanol	Opioid (κ-type)	Paddleford (1999)	Long-acting (up to 4-hours)
Fentanyl	Opioid (μ-type)	Peng et al. (2010)	Suppressed cortical activity
		Freeman et al. (1967)	Reduced cortical blood flow
Dexmedetomidine	Adrenergic (α_2) Agonist	Fukuda et al., 2013	Reduced cerebral blood flow

142

143 Here, we compare an alfaxalone (Alf) protocol with a previously established protocol
144 consisting of a combination of isoflurane and ketamine (Iso+Ket), providing detailed measures
145 of physiological stability as well as evoked activity in cats during fMRI. The investigation is
146 separated into two parts; in the first study, we evaluate the physiological stability of each
147 protocol in an operating suite. A light anesthetic plane was maintained for a minimum of 2-
148 hours while cats were exposed to mock scanner noises at 90 dB and vital signs (heart rate,
149 respiratory rate, end-tidal CO_2, blood pressure, etc.) were recorded. In the second study, both
150 protocols were employed in the scanner while BOLD signal changes were recorded in response
151 to visual and auditory stimuli. This study is the first to evaluate different anesthetic protocols in
152 cats by directly comparing BOLD signal responses. Quantification of these signals will provide
153 insight into the contribution of different anesthetics on neural activity, and potentially offer an
154 alternative option to the combination of isoflurane and ketamine.

155 **2. Methods**

156 *2.1 Animals*

157 Two healthy adult domestic short-hair cats were used in study one, and a total of 12
158 cats were compared in the second study. Animals were born to pregnant queens obtained from
159 a commercial laboratory animal breeding facility (Liberty Labs, Waverly, NY), and were housed
160 as a clowder. Normal hearing status was confirmed at approximately 3 months of age using
161 auditory brainstem responses. All procedures were conducted in accordance with the Canadian
162 Council on Animal Care's Guide to the Care and Use of Experimental Animals and were
163 approved by the University of Western Ontario Animal Use Subcommittee of the University
164 Council on Animal Care.

165 *2.2 Study 1: Physiological Stability during Anesthesia*

166 *2.2.1 Anesthesia*

167 The first study was conducted in a surgical suite in order to evaluate the safety and
168 stability of the selected protocols. In the alfaxalone protocol, the animal was first pre-
169 medicated with dexdomitor (0.04 mg/kg, i.m.) prior to catheter placement. Sedation was
170 confirmed after 10 minutes by the absence of a paw-pinch reflex. Ophthalmic ointment was
171 applied to prevent drying of the eyes, body temperature was maintained at 37°C using a
172 circulating warm water pad, and an indwelling 22g catheter was placed in the cephalic vein to
173 facilitate maintenance of anesthesia. A bolus dose of alfaxalone (0.3-0.5 ml, i.v.) was
174 administered to achieve deeper anesthesia and the animal's larynx was sprayed with xylocaine
175 prior to intubation. The animal was placed in a sternal position on the surgical table, and
176 anesthesia was maintained through continuous infusion of alfaxalone (7 mg/kg/hr, i.v.), while
177 100% oxygen was provided at a rate of 1.0L/min. Finally, a bolus dose of atipamezole (0.27 ml,
178 i.m.) was administered to reverse any residual effects of the dexdomitor.

179 For the ketamine plus isoflurane protocol, animals were pre-medicated with a
180 combination of dexdomitor (0.022 mg/kg, i.m.), ketamine (4 mg/kg, i.m.), and acepromazine
181 (0.05 mg/kg, i.m.). Sedation was confirmed, the animal's core temperature was maintained,
182 ophthalmic ointment was applied, and a catheter was placed for anesthetic maintenance as

183 above. The animal was placed in a sternal position on the surgical table, and a continuous
184 infusion of ketamine (5 ml/kg/hr, i.v.), combined with gaseous isoflurane (0.5% in oxygen
185 provided at a rate of 1.0L/min) was used to maintain anesthesia. The reversal of dexdomitor
186 was not necessary in this protocol as premedication volume was lower and consequently would
187 not be expected to have effects lasting into the experimental period. Approximately 60 minutes
188 into the session, the rate of ketamine infusion was increased to 6.25 ml/kg/hr (i.v.) and
189 isoflurane was reduced to 0.25% in order to mimic the protocol developed previously for
190 imaging, in which these changes are required prior to functional image acquisition to optimize
191 BOLD signal.

192 At the end of each session, anesthesia was discontinued, and animals were monitored
193 until they recovered fully from anesthetic effects. Animals anesthetized with alfaxalone
194 received a bolus dose of butorphanol (0.2 mg/kg, s.c.; opioid analgesic) to counteract
195 hyperkinesia, a side-effect commonly observed during post-anesthetic recovery from prolonged
196 IV administration of alfaxalone in cats (Whittem et al., 2008). The intubation tube was removed
197 when the animal exhibited a gag reflex and increased jaw tone, and following recovery, the
198 indwelling catheter was removed and the animal was returned to their clowder. Each agent was
199 tested twice in each animal for a total of 4 sessions per agent.

200 *2.2.2 Data Recording*

201 To mimic conditions in the scanner, the animal was presented with previously recorded
202 scanner noise through foam insert earbuds (Sensimetric S14) at 90 dB SPL for the duration of
203 experimental sessions. Each agent's ability to induce anesthesia, maintain a lightly sedated
204 state for 2-hours, and to allow for uneventful recovery was noted. Anesthetic and physiological
205 stability was evaluated by monitoring and recording parameters including autonomic reflexes
206 (e.g. paw-pinch, gag, palpebral) and vital signs (e.g. heart rate, end-tidal CO_2, respiratory rate,
207 peripheral capillary oxygen saturation, blood pressure, and mean arterial pressure) in 5-minute
208 intervals.

209

210 *2.3 Study 2: fMRI*

211 The second study sought to compare the auditory- and visually- evoked BOLD signals
212 recorded while animals were anesthetized with each candidate agent. A group of 6 cats were
213 scanned while anesthetized with alfaxalone, and results were compared to a group of 6 sex-
214 and age-matched animals scanned previously using the exact same equipment and
215 experimental procedure.

216 *2.3.1 Animal Preparation and Anesthesia*

217 For both the ketamine plus isoflurane and alfaxalone protocols, anesthesia was induced
218 and maintained as described for Study 1 above. Once anesthetized, the animal was placed in a
219 sternal position within a custom-built Plexiglass sled. Phenylephrine hydrochloride and atropine
220 sulfate ophthalmic solutions were applied to both eyes to dilate the pupils and retract the
221 nictitating membranes. Lubricated contact lenses were placed in both eyes (a blackout lens in
222 the left eye, and a clear lens in the right eye). This permitted visual stimuli to be brought into
223 focus on the retina and have visual signals preferentially sent to the left hemisphere. MRI-
224 compatible foam insert earphones (Sensitmetrics S14) were inserted in each ear to allow for
225 the presentation of auditory stimuli, and the animal's head was stabilized within a custom 8-
226 channel radio-frequency (RF) coil. Vital signs (heart rate, respiratory rate, end-tidal CO_2,
227 inspiratory CO_2, percent oxygen saturation, systolic/diastolic and mean blood pressure, and
228 rectal body temperature) were monitored throughout the scanning session. At the conclusion
229 of the imaging session, anesthesia was discontinued and animals were recovered as outlined in
230 Study 1 above.

231 *2.3.2 Stimuli*

232 Visual stimuli were generated with PsychoPy (Peirce, 2007; 2009) and presented
233 through a Dell laptop to an Avotec SV-6011 Rear Projector. From their sternal position within
234 the bore of the magnet, the animals eyes were located approximately 75 cm from an acrylic
235 screen (H = 14.5 cm, W = 19cm), which was viewed through a custom-built mirrored periscope.
236 The stimulus extended 14.5 visual degrees horizontally and 11 degrees vertically and consisted
237 of a black and white flickering checkerboard (8 ring-segments of 16 wedges) on a grey

background (100% luminance contrast, 50% luminance background), counter-phase flickering at 5Hz. The stimulus was arranged in a simple ON/OFF block design, where the OFF block consisted of a blank grey screen, each block lasting 30s. The animal's gaze was assessed visually through the scanner bore before the acrylic screen was placed at the end of the bore.

Auditory stimuli were generated using Audacity® recording and editing software (Audacity Team, 2019), and consisted of a 30s stimulus consisting of 400ms broadband noises separated by 100ms silent gaps. This stimulus was arranged in an ON/OFF block design, where the OFF block consisted of a 30s period of silence. Sounds were presented diotically from a Dell laptop through an external Roland Corporation soundcard (24-bit/96 kHz; Model UA- 25EX), a PylePro power amplifier (Model PCAU11), and Sensimetrics MRI-compatible ear inserts (Model S14). All stimuli were calibrated to 80-90 dB SPL using an ear simulator (Bruel & Kjaer, Model #4157).

2.3.3 Scanning Parameters

Data were collected using an ultra-high-field 7T Siemens MRI human head-only scanner located at the Centre for Functional and Metabolic Mapping at the Robarts Research Institute operating at a 350 mT/m/s slew rate. An automated 3D mapping procedure (Klassen & Menon, 2004) was used to optimize the magnetic field (B_0 shimming) over the specific volume of interest.

High-resolution structural T1-weighted MP2RAGE images were acquired prior to functional scanning with the following parameters: isotropic voxel size of 0.5mm^3, 80 slices, FoV=96mm, TE=3.95ms, TR= 6000ms, TI =800ms, and a flip angle of 4. Functional images were acquired over the whole brain in axial orientation with a single shot echo-planar imaging (EPI) acquisition with grappa acceleration and the following parameters: isotropic voxels 1mm^3, 38 slices (interleaved), FoV=72mm, TE=22.0ms, TR= 2000ms and a flip angle of 60 degrees. Each functional scan (visual- and auditory-evoked) lasted six minutes, and consisted of alternating 30 second blocks of stimulus and baseline conditions.

265 *2.3.4 Image Analysis*

266 T1-weighted structural images were processed with a combined approach of automated
267 and manual processing. The structural images were skull-stripped with use of MRIcron (NITRC;
268 Rorden & Brett, 2000) and FSLmath functions (FMRIB's toolbox, Oxford, UK; Smith et al., 2004,
269 http://fsl.fmrib.ox.ac.uk/fsl/fslwiki/).

270 First-level statistical analysis of each animal's functional data was carried out using FEAT
271 processing in FSL (Woolrich et al., 2001). The functional images were skull stripped using FSL's
272 Brain Extraction Tool (BET). Preprocessing began with the removal of the first 2 volumes (4s) of
273 the scan to allow for the scanner magnetic field to stabilize and reach magnetic saturation.

274 The following were also applied: motion correction (MCFLIRT; though the movement is
275 nearly non-existent during these procedures), spatial smoothing (Gaussian, FWHM, 2mm) and a
276 temporal high-pass filter cut off (0.01Hz/60s). First-level general linear model analysis (FILM)
277 was then carried out, where regressors for each condition-block were convolved with a gamma
278 hemodynamic response function (phase = 0, standard deviation = 3s, mean lag = 6s; the BOLD
279 signal time course in cats has been shown to closely resemble that observed in humans and
280 non-human primates [Brown et al., 2013]).

281 Each individual EPI sequence underwent time series pre-whitening (Smith et al., 2004),
282 allowing us to carry through contrasts for higher-level analysis to test for group effects;
283 individual animal GLM results were co-registered to the coordinate space of the high-resolution
284 structural image for each participant using FMRIBs Linear Image Registration Tool (FLIRT;
285 Jenkinson et al., 2002). Further analysis compared differences in average BOLD signal change
286 under each anesthetic agent across all voxels within a given region of interest. Visual ROIs
287 included primary visual cortical areas 17, 18 and 19, as well as the lateral geniculate nuclei
288 (LGN) of the thalamus. Auditory ROIs included primary (A1) and second (A2) auditory cortex
289 and the medial geniculate nuclei (MGN) of the thalamus.

290 Mean BOLD signal changes (relative to baseline) evoked by visual and auditory stimuli
291 were extracted for each ROI of each animal, using FEATquery (FMRIB toolbox in FSL). To carry
292 this out, FEATquery takes each participant's high-resolution structural scan and co-registers it

to the feline template space (CATLAS, Stolzberg et al., 2017) using FLIRT multi-registration, in which all the predefined functional ROIs are defined (Fig. 1).

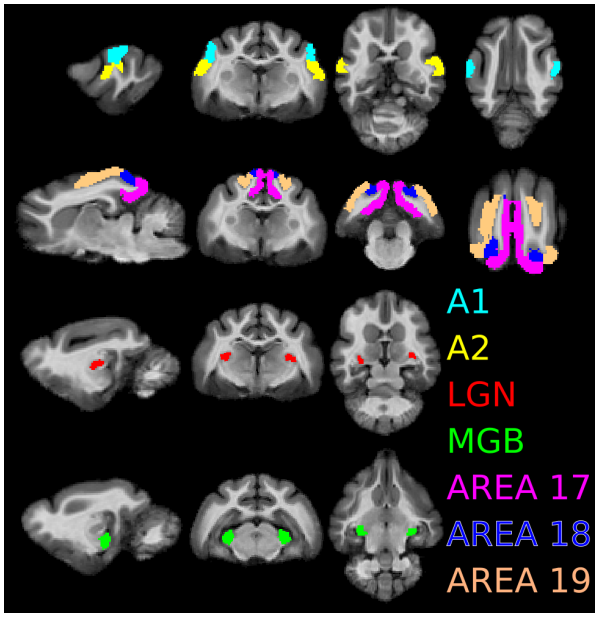

Figure 1. Visual and auditory regions of interest (ROIs) used in analysis displayed in feline template space (CATLAS; Stolzberg et al., 2017). Visual ROIs (LGN, 17/18/19) contralateral to the open eye were isolated for analysis.

3. Results

3.1 Study 1 - Physiology

Two animals were observed two times under each anesthetic protocol in the operating suite to evaluate the stability of heart and respiratory rates across anesthetics. These physiological measures are commonly yoked; in practice, respiratory rate is used as an indicator of anesthetic depth where high rates are more representative of an awake state (Myles, 2007). The data from the present evaluation, averaged across animals and runs for each anesthetic agent tested, are presented in Figure 2A. It is apparent that both measures exhibit more stability across the duration of testing under alfaxalone than under ketamine plus isoflurane. To examine the variability within a test session, the change in each measure between successive timepoints (i.e. the change in heart/respiratory rate across each 5-minute interval) was calculated; these values are presented in Figure 2B. On this time scale, changes in heart rate were very similar across anesthetics; however, the changes in respiratory rate under alfaxalone

313 appear smaller, suggesting more within-session stability under this anesthetic when compared
314 to coadministration of ketamine and isoflurane.

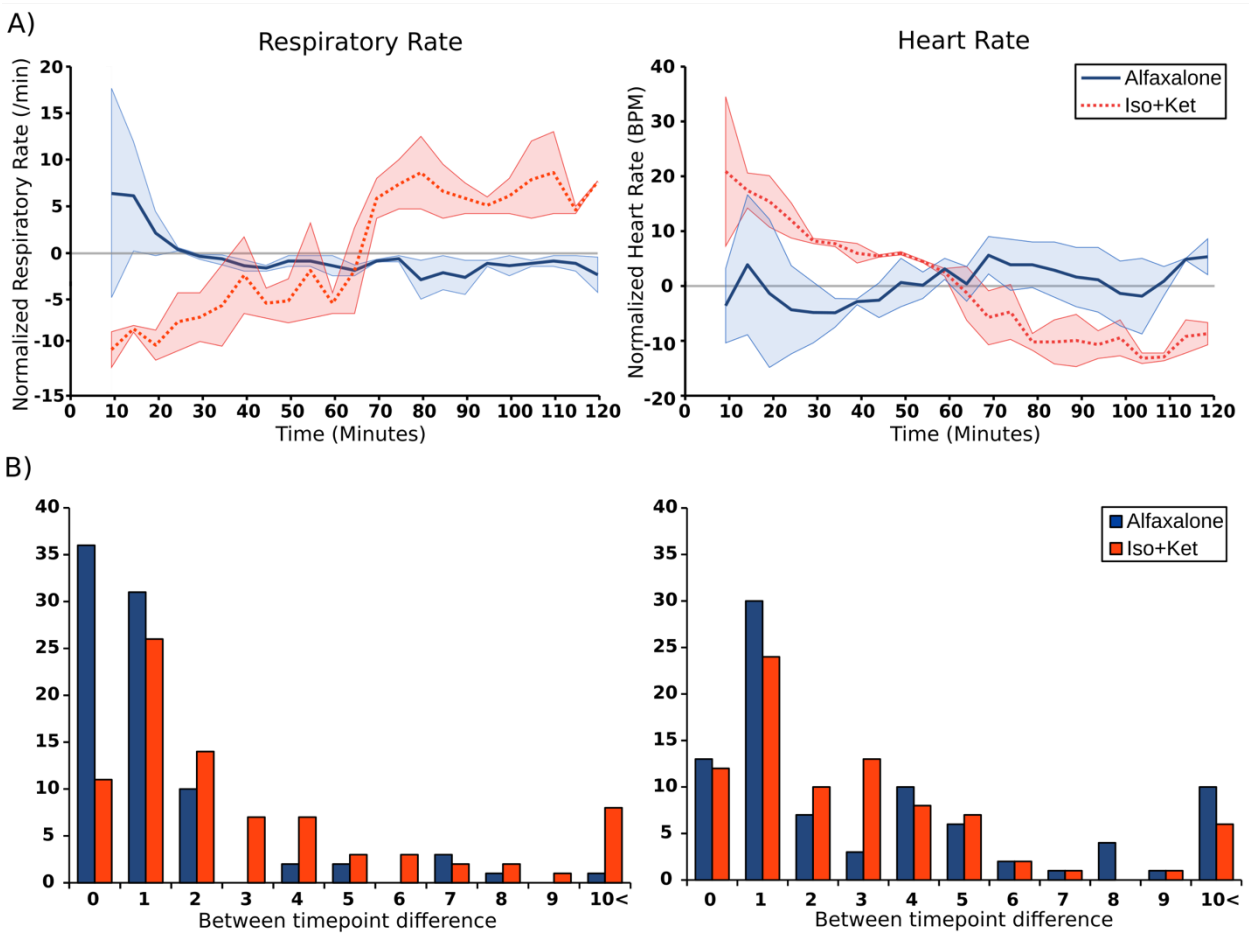

315

316 **Figure 2.** A) Normalized respiratory rates (breaths per min) and heart rates (beats
317 per min) under alfaxalone and co-administered ketamine and isoflurane. Data were
318 normalized to the mean rate for an individual run, and then normalized values were
319 averaged across animals and runs. Shaded regions represent the standard error of
320 the mean. The first 10 minutes of each measurement period were omitted from
321 analysis to account for setup of monitoring/recording devices. B) A histogram
322 representing change magnitude in successive measurements of respiratory and
323 heart rate under each anesthetic tested. Lower values indicate relative stability in
324 the variable measured, while larger values indicate increased variability over time.

325

326 It is important to note that increased variability under ketamine plus isoflurane is not
327 entirely due to the drugs per se; imaging under this protocol requires that the rate of ketamine

328 infusion be increased and the concentration of isoflurane reduced approximately 60 minutes
329 into a testing session in order to acquire functional images with measurable BOLD signal (Brown
330 et al., 2013; Stolzberg et al., 2018). As a result, physiological measures such as heart rate and
331 respiratory rate often change dramatically at this point in time (observable in Figure 2A). As
332 described above, these shifts indicate drift towards a lighter anesthetic plane, as is necessary to
333 provide increased BOLD signal in the presence of isoflurane. However, this also increases the
334 risk of the animal becoming alert, which should be avoided. In contrast, the rate of alfaxalone
335 infusion can remain unchanged for the duration of the session, resulting in more stable vital
336 signs throughout.

337 *3.2 Study 2 - fMRI*

338 *3.2.1 BOLD signal strength*

339 To examine whether a global difference in BOLD signal amplitude exists between
340 anesthetics, normalized percent BOLD signal changes (hereafter referred to as BOLD signals)
341 were extracted from all selected ROIs, in each animal.

342 As an initial test, a mixed ANOVA was performed on these BOLD signals, where
343 anesthetic protocol (ketamine plus isolflurane/alfaxalone) was treated as a between-subjects
344 factor, and within-subject factors included two stimulus types (auditory/visual) and seven ROIs
345 (auditory cortical areas A1 and A2, the MGB, visual cortical areas 17, 18, and 19, and the LGN).
346 A significant interaction was observed between stimulus type and ROI ($F[11, 110] = 13.505$, $p <$
347 0.001) demonstrating that across anesthetic protocols, the BOLD signal observed in a given ROI
348 depended on the nature of the stimulus presented. The comparison of between-subjects
349 effects across all regions and conditions revealed no significant effect of anesthetic protocol
350 ($F[1, 10] = 1.108$, $p = 0.337$). Overall, these results indicate that, as expected, auditory and
351 visual stimuli evoke different patterns of activity across sensory brain regions. Moreover, the
352 patterns of evoked activity are similar across the anesthetics tested. While this suggests that
353 both alfaxalone and co-administered ketamine and isoflurane may be appropriate for imaging
354 experiments, this analysis provides little insight into the consistency and stability of the BOLD

signal measured under each. We thus conducted planned post-hoc tests investigating the variability of these signals.

3.2.2 BOLD signal variability

Figure 3 shows the BOLD signals recorded in each ROI broken down by stimulus type (auditory, visual) and anesthetic protocol for each animal tested. Doing so allows BOLD signal variability to be observed across all ROIs (bilateral MGN, A1, & A2; LGN, 17, 18, & 19 contralateral to the opened eye) and individual subjects. Across regions of interest, between-subjects variability in the BOLD signal evoked by stimuli to which a region is typically responsive (i.e. the signal recorded in A1/A2 in response to sound) was greater under ketamine plus isoflurane than under alfaxalone. Further, signals recorded in response to stimuli to which an ROI is *not* typically responsive (i.e. the signal recorded in areas 17/18/19 in response to sound), were also far more variable under ketamine plus isoflurane. This latter analysis provides a measure of signal variability in the absence of evoked activity (i.e. a measure of background activity under a given anesthetic agent).

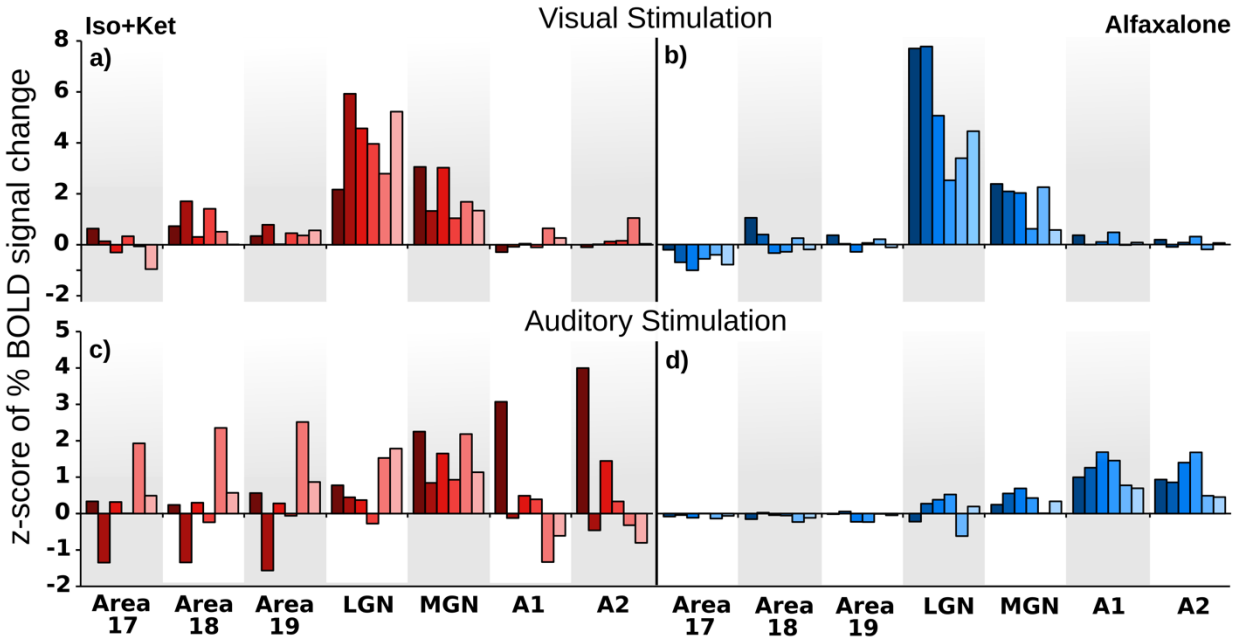

Figure 3 Individual z-scores of BOLD signal changes within all regions of interest in response to visual (a & b) and auditory (c & d) stimulation under coadministration of ketamine and isoflurane (a & c) or alfaxalone (b & d). Data are thresholded using

clusters determined by Z>2.3 and a corrected cluster significance threshold of p=0.05 (Worsley, 2001).

To quantify variability in more detail, the range of the normalized BOLD signal across animals for each region of interest and anesthetic protocol is presented in Figure 4. With respect to visually-evoked activity, the between-subjects variability in BOLD activity was highly similar across all ROIs. In response to sound, the signal recorded was less variable under alfaxalone than under co-administered ketamine and isoflurane across all ROIs. Thus, while both anesthetics evoke similar mean BOLD signal amplitudes (as evidenced by the absence of a statistically significant effect of anesthetic protocol, as described above), between-subjects variability is decreased under alfaxalone, notably in response to sounds.

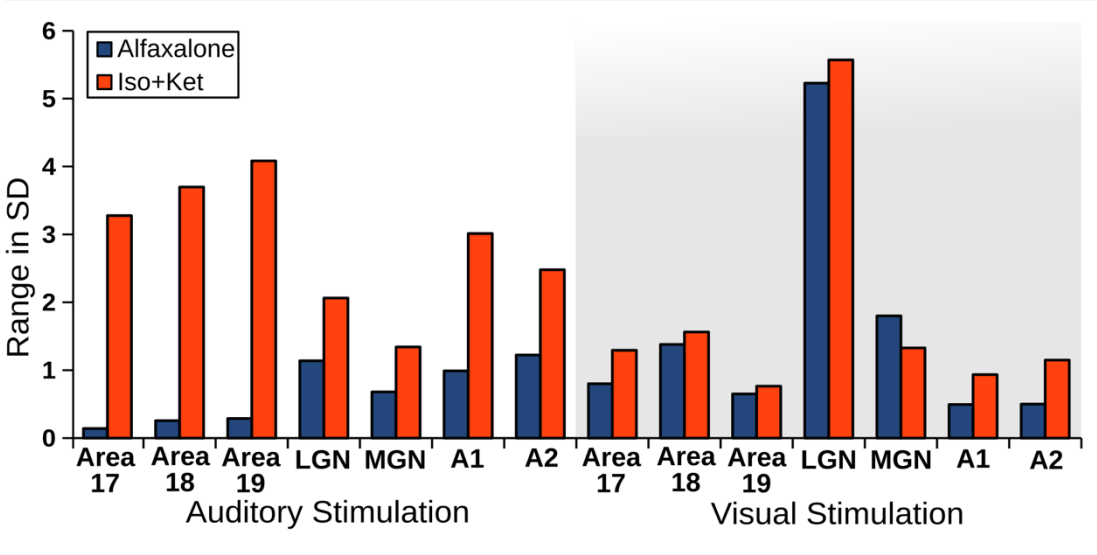

Figure 4 Range (max-min) of z-scored percent BOLD signal change across animals for each region of interest studied, in response to auditory and visual stimuli under alfaxalone (blue) and co-administered ketamine and isoflurane (red).

4. Discussion

This study was undertaken to compare and contrast potential anesthetic protocols for functional neuroimaging with a focus on 1) physiological stability and 2) optimizing BOLD signal across stimulus modalities. While all anesthetics affect neural function, their use remains necessary in most animal models to minimize movement and stress, and to ensure animal

394 safety within the magnet. Thus, it is important to establish a regime that strikes a balance
395 between achieving and maintaining safe and stable anesthesia, while optimizing cortical
396 activity. Previous studies have used a variety of anesthetic agents in an attempt to optimize
397 responses; one common protocol involves the co-administration of ketamine and isoflurane–
398 an approach that has been shown to allow for the observation of sound-evoked BOLD activity
399 (Brown et al., 2013; Hall et al., 2014; Butler et al., 2015; Stolzberg et al., 2018). However, this
400 combination can produce physiological instability and has suppressive effects on cortical
401 activity (Zurita et al., 1994; Harel et al., 2002; Olman et al., 2003; Hodkinson et al., 2012). It
402 therefore remains important to explore alternative and perhaps more reliable protocols. Here,
403 we provide physiological and neuroimaging evidence that supports the use of alfaxalone as a
404 stable and consistent anesthetic agent for neuroimaging.

405 *4.1 Anesthesia and Physiology*

406 The primary goal of the physiological pilot described above, was to determine the safety
407 and stability of candidate protocols using heart and respiratory rates as indicators. Importantly,
408 these measures have been shown to reflect anesthetic depth (Musizza & Ribaric, 2010; Thomas
409 & Lerche, 2011). Moreover, fluctuations in either heart or respiratory rate have been shown to
410 interfere with neural signals measured by fMRI (Gao et al., 2017; Birn et al., 2003; Abbott et al.,
411 2005; Kastrup et al., 1999). In the present study, both heart and respiratory rates appear more
412 stable across a 120-minute testing duration under alfaxalone than under co-administered
413 ketamine and isoflurane. In part, this reflects a simultaneous increase in ketamine infusion rate
414 and decrease in isoflurane concentration approximately 60 minutes into an imaging session
415 that is necessary to allow for BOLD signal visualization (Brown et al., 2013; Hall et al., 2014;
416 Butler et al., 2015; Stolzberg et al., 2018). Thus, this previously established protocol includes a
417 trade-off between measurable BOLD responses and increased risk of the animal becoming alert
418 in the scanner. Conversely, the alfaxalone protocol described here maintains a constant
419 infusion rate for the duration of the experimental session, and thus results in only small-scale
420 changes in heart and respiratory rate over time, consistent with previous examinations of the
421 anesthetic properties of alfaxalone for other applications (Beths et al., 2014; Muir et al., 2009).
422 In addition to long-term stability, respiratory rate under alfaxalone was also shown to be more

423 stable across shorter duration measurement intervals (5 min; Figure 2B). Both protocols
424 examined attained safe levels of anesthetic depth for functional imaging; however, alfaxalone
425 resulted in more physiological stability across individuals and sessions when compared to the
426 co-administration of isoflurane and ketamine.

427 *4.2 Anesthesia and BOLD*

428 Having demonstrated the safety of both candidate protocols, the imaging experiment
429 (Study 2) sought to compare and contrast BOLD signal changes evoked in auditory and visual
430 thalamic and cortical regions of interest under each anesthetic. To the best of our knowledge,
431 this is the first study to provide such a comparison. Here, we demonstrate that both protocols
432 facilitate comparable mean levels of overall evoked BOLD activity across ROIs. These results are
433 in accordance with similar mechanisms of action between alfaxalone and isoflurane (Lambert et
434 al., 2003; Nakahiro et al., 1999). Examining these patterns of evoked activity in more detail,
435 more reliable and consistent neural responses were observed under alfaxalone, evidenced by
436 decreased BOLD signal variability across animals (Figures 3 & 4). This is highly important, as
437 fMRI analyses often involve averaging or subtractive computations across blocks of data
438 acquired over the duration of an imaging session. That the activity recorded under co-
439 administered ketamine and isoflurane is highly variable within a given ROI means these
440 between-block contrasts may be particularly susceptible to anesthetic effects. Interestingly,
441 signals measured in brain regions not traditionally associated with a particular stimulus
442 modality (e.g. BOLD signal estimates from primary visual cortex in response to auditory
443 stimulation) were more variable under co-administered ketamine and isoflurane than under
444 alfaxalone, suggesting signal variability associated with the former extends well beyond effects
445 on stimulus-evoked activity. This activity may reflect between-subjects differences in non-
446 selective suppression observed under isoflurane (Wu et al., 2016) or the potentially dissociative
447 effects of ketamine (Abel et al., 2003) – either of which presents a challenge to the
448 interpretation of stimulus-evoked signals. Increased consistency between individual animals
449 and ROIs under alfaxalone suggests that it may be better suited for fMRI studies than the co-
450 administration of isoflurane and ketamine.

5. Conclusion

Anesthetics are important to many experimental approaches in animal research. However, without good, consistently applied protocols for neuroimaging, findings from these studies remain difficult to consolidate, and the degree to which they can be generalized to understand the brain in its natural neural state remains unclear. The present study sought to compare alfaxalone as a novel imaging anesthetic, to the previously established protocol for feline functional imaging studies that relied upon the co-administration of ketamine and isoflurane (Brown et al., 2013; Hall et al., 2014; Butler et al., 2015; Stolzberg et al., 2018). We provide evidence that alfaxalone is more physiologically stable and allows for the observation of more consistent patterns of BOLD activity. Additionally, there are some practical implications that favor the use of alfaxalone: 1) a single-agent protocol is easier to maintain over extended testing, is preferred by veterinary staff, and reduces concerns related to drug interactions; 2) unlike ketamine, alfaxalone in not a controlled substance, and is thus easier to obtain and store; and 3) because anesthetic depth is more consistent across the testing session under alfaxalone, the duration of testing is more predictable and concerns related to the animal waking up within the magnet are reduced. For all of these reasons, we therefore propose that alfaxalone may be a superior anesthetic agent for the safe and reliable collection of fMRI data.

6. Acknowledgments

We would like to thank Stephen Gordon and Alessandra Sacco for their assistance with animal care and data collection, and Trevor Szekeres for technical assistance. This research was undertaken thanks to funding from the Canada First Research Excellence Fund awarded to BrainsCAN at Western University, the Natural Sciences and Engineering Research Council of Canada, Canadian Institutes of Health Research, and the Canada Foundation for Innovation.

7. References

Abbott, D.F., Opdam, H.I., Briellmann, R.S., & Jackson, G.D. (2005). Brief breath holding may confound functional magnetic resonance imaging studies. *Human Brain Mapping*, *24*(4), 284-290.

Abel, K. M., Allin, M. P., Kucharska-Pietura, K., Andrew, C., Williams, S., David, A. S., & Phillips, M. L. (2003). Ketamine and fMRI BOLD signal: distinguishing between effects mediated by change in blood flow versus change in cognitive state. Human brain mapping, 18(2), 135-145.

Aksenov, D.P., Limin, L., Miller, M.J., Iordanescu, G., & Wyrwicz, A.M. (2015). Effects of anesthesia on BOLD signal and neuronal activity in the somatosensory cortex. *Journal of Cerebral Blood Flow and Metabolism*, *35*(11), 1819-1826.

Audacity Team (2019). Audacity®: Free audio editor and recorder [computer application]. Version 2.3.1 retrieved May 6, 2019 from https://audacityteam.org/.

Baldy-Moulinier, M., Basset-Lehmann, J., & Passonaut, P. (1975). Effects of combination alfaxalone and alfadolone, anesthetic derivatives of pregnenedione, on cerebral hemodynamics in cats. *Comptes Rendus Des Seances de la Societe de Biologie et de Ses Filiales*, *169*(1), 126-131.

Beths, T., Touzot-Jourde, G., Musk, G., & Pasloske, K. (2014). Clinical evaluation of alfaxalone to induce and maintain anesthesia in cats undergoing neutering procedures. *Journal of Feline Medicine and Surgery*, *16*(8), 609-615.

Biermann, K., Hungerbühler, S., Mischke, R., & Kästner, S.B.R. (2012). Sedative, cardiovascular, haematologic and biochemical effects of four different drug combinations administered intramuscularly in cats. *Veterinary Anaesthesia and Analgesia*, *39*(2), 137-150.

Birn, R.M., Smith, M.A., Jones, T.B., & Bandettini, P.A. (2008). The respiration response function: the temporal dynamics of fMRI signal fluctuations related to changes in respiration. *NeuroImage*, *40*(2), 644-654.

Blake, R. (1979). The visual system of the cat. *Perception and Psychophysics*, *26*(6), 423-448.

Bonhomme, V., Fiset, P., Meuret, P., Backman, S., Plourde, G., Paus, T., Bushnell, M.C., & Evans, A.C. (2000). Propofol anesthesia and cerebral blood flow changes elicited by vibrotactile

stimulation: a positron emission tomography study. *Journal of Neurophysiology*, *85*(3), 1299-1308.

Brown, T.A., Joanisse, M.F., Gati, J.S., Hughes, S.M., Nixon, P.L., Menon, R.S., & Lomber, S.G. (2013). Characterization of the blood-oxygen level-dependent (BOLD) response in cat auditory cortex using high-field fMRI. *NeuroImage*, *64*, 458-465.

Brown, T.A., Gati, J.S., Hughes, S.M., Nixon, P.L., Menon, R.S., & Lomber S.G. (2014). Functional imaging of auditory cortex in adult cats using high-field fMRI. *Journal of Visualized Experiments*, (84), e50872, doi:10.3791/50872.

Butler, B.E., Chabot, N., & Lomber, S.G. (2016). Quantifying and comparing the pattern of thalamic and cortical projections to the posterior auditory field in hearing and deaf cats. *Journal of Comparative Neurology*, *524*(15), 3042-3063.

Butler, B.E., Hall, A.J., & Lomber, S.G. (2015). High-field functional imaging of pitch processing in auditory cortex of the cat. *PLoS One*, *10*(7), e0134362. https://doi.org/10.1371/journal.pone.0134362.

Buxton, R.B. & Frank, L.R. (1997). A model for the coupling between cerebral blood flow and oxygen metabolism during neural stimulation. *Journal of Cerebral Blood Flow and Metabolism*, *17*(1), 64-72.

Crosby, G., Crane, A.M., & Sokoloff, L. (1982). Local changes in cerebral glucose utilization during ketamine anesthesia. *Anesthesiology*, *56*(6), 437-443.

Deutsch, J., Jolliffe, C., Archer, E., & Leece, E.A. (2017). Intramuscular injection of alfaxalone in combination with butorphanol for sedation in cats. *Veterinary Anaesthesia and Analgesia*, *44*(4), 794-802.

Dueck, M.H., Petzke, F., Gerbershagen, H.J., Paul, M., Hebelmann, V., Girnus, R., … Boerner, U. (2005). Propofol attenuates responses of the auditory cortex to acoustic stimulation in a dose-dependent manner: a fMRI study. *Acta Anaesthesiologica Scandinavica*, *49*(6), 784-791.

Ferris, C.F., Febo, M., Luo, F., Schmidt, K., Brevard, M., Harder, J.A., … King, J.A. (2006). Functional magnetic resonance imaging in conscious animals: a new tool in behavioral neuroscience research. *Journal of Neuroendocrinology*, *18*(5), 307-318.

533 Freeman, J., & Ingvar, H. (1967). Effects of fentanyl on cerebral cortical blood flow and EEG in
534 the cat. *Acta Anaesthesiology Scandinavica*, *11*(4), 381-391.
535 Fukuda, M., Vazquez, A.L., Zong, X., & Kim, S.G. (2013). Effects of the alpha 2-adrenergic
536 receptor agonist dexmedetomidine on neural, vascular and BOLD fMRI responses in the
537 somatosensory cortex. *European Journal of Neuroscience*, *37*(1), 80-95.
538 Gao, Y.R., Ma, D., Zhang, Q., Winder, A.T., Liang, Z., Antinori, L., Drew, P.J., & Zhang, N. (2017).
539 Time to wake up: Studying neurovascular coupling and brain-wide circuit function in the
540 un-anesthetized animal. *NeuroImage*, *153*, 382-398.
541 Hall, A.J., Brown, T.A., Grahn, J.A., Gati, J.S., Nixon, P.L., Hughes, S.M., Menon, R.S., & Lomber,
542 S.G. (2014). There's more than one way to scan a cat: Imaging cat auditory cortex with
543 high-field fMRI using continuous or sparse sampling. *Journal of Neuroscience Methods*,
544 *224*, 96-106.
545 Harel, N., Lee, S.P., Nagaoka, T., Kim, D.S., & Kim, S.G. (2002). Origin of negative blood
546 oxygenation level-dependent MRI signals. *Journal of Cerebral Blood Flow and*
547 *Metabolism*, *22*(8), 908-917.
548 Heffner, R.S., & Heffner, H.E. (1988). Sound localization acuity in cat: Effect of azimuth, signal
549 duration, and test procedure. *Hearing Research*, *36*(2-3), 221-232.
550 Heil, P., & Irvine, D.R. (1998). Functional specialization in auditory cortex: responses to
551 frequency-modulated stimuli in cat's posterior auditory field. *Journal of*
552 *Neurophysiology*, *79*(6), 3041-3059.
553 Hodkinson, D.J., de Groote, C., McKie, S., William Deakin, J.F., & Williams, S.R. (2012).
554 Differential effects on anaesthesia on the phMRI response to acute ketamine challenge.
555 British Journal of Medicine and Medical Research, 2(3), 373-385.
556 Höflich, A., Hahn, A., Küblböck, M., Kranz, G.S., Vanicek, T., Ganger, S., Spies, M.,
557 Windischberger, C., Kasper, S., Winkler, D. & Lanzenberger, R (2017). Ketamine-
558 dependent neuronal activation in healthy volunteers. Brain Structure and Function,
559 222(3), 1533-1542.
560 Hubel, D.H., & Wiesel, T.N. (1962). Receptive fields, binocular interaction and functional
561 architecture in the cat's visual cortex. *Journal of Physiology*, *160*(1), 106-154.

562 Jenkinson, M., Bannister, P., Brady, M., & Smith, S. (2002). Improved optimization for the robust
563 and accurate linear registration and motion correction of brain images. *NeuroImage*,
564 *17*(2), 825-841.
565 Jezzard, P., Rauschecker, J.P., & Malonek, D. (1997). An in vivo model for functional MRI in cat
566 visual cortex. *Magnetic Resonance in Medicine*, *38*(5), 699-705.
567 Kaitin, K.I. (1985). Effects of thalidomide and pentobarbital on neuronal activity in the preoptic
568 area during sleep and wakefulness in the cat. *Psychopharmacology*, *85*(1), 47-50.
569 Kastrup, A., Liu, T.Q., Glover, G.H., & Moseley, M.E. (1999). Cerebral blood flow-related signal
570 changes during breath-holding. *American Journal of Neuroradiology*, *20*(7), 1233-1238.
571 Klassen, L.M., & Menon, R.S. (2004). Robust automated shimming technique using arbitrary
572 mapping acquisition parameters (RASTAMAP). *Magnetic Resonance in Medicine*, *51*(5),
573 881-887.
574 Lahti, K.M., Ferris, C.F., Li, F., Sotak, C.H., & King, J.A. (1999). Comparison of evoked cortical
575 activity in conscious and propofol-anesthetized rats using functional MRI. *Magnetic*
576 *Resonance in Medicine*, *41*(2), 412-416.
577 Lambert, J.J., Belelli, D., Peden, D.R., Vardy, A.W., & Peters, J.A. (2003). Neurosteroid
578 modulation of $GABA_A$ receptors. *Progress in Neurobiology*, *71*(1), 67-80.
579 Liu, Y., Qin, L., Zhang, X., Dong, C., & Sato, Y. (2010). Neural correlates of auditory temporal-
580 interval discrimination in cats. *Behavioural Brain Research*, *215*(1), 28-38.
581 Logothetis, N.K., Pauls, J., Augath, M., Trinath, T., & Oeltermann, A. (2001). Neurophysiological
582 investigation of the basis of the fMRI signal. *Nature*, *412*(6843), 150-157.
583 Lomber, S.G., MacNeil M.A., & Payne, B.R. (1995). Amplification of thalamic projections to
584 middle suprasylvian cortex following ablation of immature primary visual cortex in the
585 cat. *Cerebral Cortex*, *5*(2),166-191.
586 Miller, L.M., Escabi, M.A., Read, H.L., & Schreiner, C.E. (2002). Spectrotemporal receptive fields
587 in the lemniscal auditory thalamus and cortex. *Journal of Neurophysiology*, *87*(1), 516-
588 527.

589 Morin-Surun, M.P., Champagnat, J., Denavit-Saubie, M., & Moyanova, S. (1984). The effects of
590 acetylcholine on bulbar respiratory related neurons: Consequences of anaesthesia by
591 pentobarbital. *Archives of Pharmacology*, *325*(3), 205-208.
592 Muir, W., Lerche, P., Wiese, A., Nelson, L., Pasloske, K., & Whittem, T. (2009). The
593 cardiorespiratory and anesthetic effect of clinical and supraclinical doses of alfaxalone in
594 cats. *Veterinary Anaesthesia and Analgesia*, *36*(1), 42-54.
595 Musizza, B., & Ribaric, S. (2010). Monitoring the depth of anaesthesia. *Sensors (Basel,*
596 *Switzerland)*, *10*(12), 10896-10935.
597 Myles, P.S. (2007). Prevention of awareness during anaesthesia. *Best Practice and Research:*
598 *Clinical Anaesthesiology*, *21*(3), 345-355.
599 Nagakubo, D., Hamamoto, Y., Hasegawa, D., Kamata, M., Iizuka, T., Muta, K., Fujita, N.,
600 Nakagawa, T. & Nishimura, R. (2017). Functional MRI-based identification of brain
601 regions activated by mechanical noxious stimulation and modulatory effect of
602 remifentanil in cats. Research in Veterinary Science, 114, 444-449.
603 Nagore, L., Soler, C., Gil, L., Serra, I., Soler, G., & Redondo, J.I. (2013). Sedative effects of
604 dexmedetomidine, dexmedetomidine-pethidine and dexmedetomidine-butorphanol in
605 cats. *Journal of Veterinary Pharmacology and Therapeutics*, *36*(3), 222-228.
606 Nakahiro, M., Yeh, J.Z., Brunner, E. & Narahashi, T. (1999). General anesthetics modulate GABA
607 receptor channel complex in rat dorsal root ganglion neurons. *Federation of American*
608 *Societies for Experimental Biology*, *3*(7), 1850-1854.
609 Ogawa, S., Lee, T.M., Kay, A.R., & Tank, D.W. (1990). Brain magnetic resonance imaging with
610 contrast dependent on blood oxygenation. Proceedings of the National Academy of
611 Sciences (USA), *87*(24), 9868-9872.
612 Olman, C., Ronen, I., Ugurbil, K., Kim, D.S. (2003). Retinotopic mapping in cat visual cortex using
613 high-field functional magnetic resonance imaging. *Journal of Neuroscience Methods*,
614 *131*(1-2), 161-170.
615 Oye, I., Paulsen, O., & Maurset, A. (1992). Effects of ketamine on sensory perception: evidence
616 for a role of N-methyl D-aspartate. *Journal of Pharmacological and Experimental*
617 *Therapeutics*, *260*(3), 1209-1213.

Paddleford, R.R. (1999). Manual of small animal anesthesia. Philadelphia, Pennsylvania: W.B. Saunders Company.

Peirce, J.W. (2007). Psychophysics software in Python. *Journal of Neuroscience Methods*, *162*(1-2), 8-13. doi:10.1016/j.jneumeth.2006.11.017.

Peirce J.W. (2009). Generating stimuli for neuroscience using PsychoPy. *Frontiers in Neuroinformatics*, *2*(10), 1-8. doi:10.3389/neuro.11.010.2008.

Peng, Y.Z., Li, X.X., & Wang, Y.W. (2010). Effects of parecoxib and fentanyl on nociception-induced cortical activity. *Molecular Pain*, *6*(3), doi: 10.1186/1744-8069-6-3.

Pienkowski, M., & Eggermont, J.J. (2009). Long-term, partially-reversible reorganization of frequency tuning in mature cat primary auditory cortex can be induced by passive exposure to moderate-level sounds. *Hearing Research*, *257*(1-2), 24-40.

Richards, C.D. (1983). Actions of general anaesthetics on synaptic transmission in the CNS. *British Journal of Anaesthesia*, *55*(3), 201-207.

Ries, C.R., & Puil, E. (1999). Mechanism of anesthesia revealed by shunting actions of isoflurane on thalamocortical neurons. *Journal of Neurophysiology*, *81*(4), 1795-1801.

Rorden, C., & Brett, M. (2000). Stereotaxic display of brain lesions. *Behavioral Neurology*, *12*(4), 191-200.

Ros, C., Soler, C., & Mateo, A.G.G.C. (2017). Comparison of brainstem auditory evoked responses during sevoflurane or alfaxalone anaesthesia in adult cats. *Veterinary Anaesthesia and Analgesia*, *44*(5), 1085-1090.

Smith, S.M., Jenkinson, M., Woolrich, M.W., Beckmann, C.F., Behrens, T.E.J., Johansen-Berg, H., … Matthews, P.M. (2004). Advances in functional and structural MR image analysis and implementation as FSL. *NeuroImage*, *23*(S1), 208-219.

Stolzberg, D., Wong, C., Blake, B.E., & Lomber, S.G. (2017). Catlas: A magnetic resonance imaging-based three-dimensional cortical atlas and tissue probability maps for the domestic cat (Felis Catus). *Journal of Comparative Neurology*, *525*(15), 3190-3206.

Stolzberg, D., Blake, B.E., & Lomber, S.G. (2018). Effects of neonatal deafness on resting-state functional network connectivity. *NeuroImage*, *165*, 69-82.

646 Taboada, F.M., & Murison, P.J. (2010). Induction of anesthesia with alfaxalone or propofol
647 before isoflurane maintenance in cats. *Veterinary Records*, *167*(3), 85-89.
648 Tamura, J., Ishizuka, T., Fukui, S., Oyama, N., Kawase, K., Itami, T., … Yamashita, K. (2015).
649 Sedative effects of intramuscular alfaxalone administered to cats. *Journal of Veterinary*
650 *Medical Science*, *77*(8), 874-904.
651 Thomas, J.A., & Lerche, P. (2011). *Anesthesia and analgesia for veterinary technicians*. St. Louis:
652 Elsevier.
653 Ueki, M., Mies, G., & Hossmann, K.A. (1992). Effects of alpha-chloralose, halothane,
654 pentobarbital and nitrous oxide anesthesia on metabolic coupling in somatosensory
655 cortex of rat. *Anaesthesiologica Scandinavica*, *36*(4), 318-322.
656 Warne, L.N., Beths, T., Whittem, T., Carter, J.E., & Bauquier, S.H. (2015). A review of the
657 pharmacology and clinical application of alfaxalone in cats. *The Veterinary Journal*, *203*,
658 141-148.
659 White, N.S., & Alkire, M.T. (2003). Impaired thalamocortical connectivity in humans during
660 general-anesthesia-induced unconsciousness. *NeuroImage*, *19*(2), 402-411.
661 Whittem, T., Pasloske, K.S., Heit, M.C., & Ransinghe, M.G. (2008). The pharmacokinetics and
662 pharmacodynamics of alfaxalone in cats after single and multiple intravenous
663 administration of Alfaxan at clinical and supraclinical doses. *Journal of Veterinary*
664 *Pharmacology*, *31*(6), 571-579.
665 Woolrich, M.W., Ripley, B.D., Brady, M., & Smith, S.M. (2001). Temporal autocorrelation in
666 univariate linear modeling of fMRI data. *NeuroImage, 14*(6) , 1370-1386.
667 Wong, C., Chabot, N., Kok, M.A., & Lomber, S.G. (2015). Amplified somatosensory and visual
668 cortical projections to a core auditory area, the anterior auditory field, following early-
669 and late-onset deafness: Modified projections to AAF following deafness. *Journal of*
670 *Comparative Neurology*, *523*(13), 1925-1947.
671 Wong, C., Pearson, K.G., & Lomber, S.G. (2018). Contributions of parietal cortex to the working
672 memory of an obstacle acquired visually or tactilely in the locomoting cat. *Cerebral*
673 *Cortex*, *28*(9), 3143-3158.

Worsley, K.J. Statistical analysis of activation images. (2001) In: Jezzard, P., Matthews, P.M., & Smith, S.M. (2002*). Functional MRI: an introduction to methods*. Oxford: Oxford University Press.

Wu, T.L., Mishra, A., Wang, F., Yang, P.F., Gore, J.C., & Chen, L.M. (2016). Effects of isoflurane anesthesia on resting-state fMRI signals and functional connectivity within primary somatosensory cortex of monkeys. *Brain and Behavior*, *6*(12), 2016.

Zurita, P., Villa, A.E.P., de Ribaupierre, Y., de Ribaupierre, F., Rouiller, E.M. (1994). Changes of single unit activity in the cat auditory thalamus and cortex associated with different anesthetic conditions. *Neuroscience Research*, *19*(3), 303-316.