Free water: a sensitive metric for age-related modifications of the cingulum white matter and its association with cognition

Manon Edde[1,2*], Guillaume Theaud[6*], François Rheault[6], Bixente Dilharreguy[2], Catherine Helmer[4], Jean-François Dartigues [4,5], Hélène Amieva[4], Michèle Allard[1,2,5], Maxime Descoteaux[6], Gwénaëlle Catheline[1,2,3]

[1] EPHE, PSL, F-33000, Bordeaux, France

[2] CNRS, INCIA, UMR 5287, F-33000 Bordeaux, France

[3] Université de Bordeaux, INCIA, UMR 5287, F-33000 Bordeaux, France

[4] Université de Bordeaux, Inserm, Bordeaux Population Health Research Center, UMR 1219, F-33000 Bordeaux, France

[5] CHU de Bordeaux, Bordeaux, France

[6] Sherbrooke Connectivity Imaging Lab (SCIL), Université de Sherbrooke, Sherbrooke, QC, Canada

* both authors contributed equally

Running title: Free Water: marker of age-related white matter changes

Corresponding author:

Manon Edde

Bât. 2A - 2ème étage - Case 22,
146 rue Léo Saignat,
33076 Bordeaux cedex
eddemanon@gmail.com

Abstract

Diffusion MRI is used extensively to investigate changes in white matter microstructure during aging. However, diffusion metrics within white-matter tissue can be affected by partial volume effects due to cerebrospinal fluid, and white matter hyperintensities, especially in aging brain. The aim of this study was to evaluate the effect of free water elimination and WMHs burden on the cingulum diffusion metrics during aging. Using a group of 45 older individuals divided in two groups presenting a high or low WMH burden, we examined the effect of the free water elimination on conventional DTI measures of white matter within the cingulum tract. Moreover, free water elimination effect on the association between cingulum diffusion metrics and cognitive evolution over 12 years is studied. The cingulum bundle was reconstructed with a tractography pipeline that includes a manually curated WMH mask applied in the native space of subjects to limit their negative effect on fiber tracking algorithms. We showed that free water correction not only improved the sensitivity of conventional DTI metrics to age-related tissue changes, but also allow the detection of associations between tissue specific diffusion metrics and changes in verbal fluency in older individuals. Moreover, free water value itself, measured along the cingulum was associated to verbal fluency performance. Therefore, these observations suggest the importance of using the free water compartment to scrutinize aging brain with DTI metrics and that free water itself could be a relevant metric for age-related white matter modifications.

Keywords: aging, tractography, free water, white matter hyperintensity, cingulum

1. Introduction

Aging is associated with widespread brain structural modifications including atrophy and neurodegeneration of white and grey matter (Damoiseaux, 2017; Ikram et al., 2008; Yang et al., 2016). In the last few years, diffusion tensor imaging (DTI) has been widely used to indirectly explore microstructural properties of white matter within brain tissues and constitutes a sensitive technique to describe age-related white matter microstructural changes (Sexton et al., 2014; Meike W. Vernooij et al., 2009). Parameters quantified by DTI such as Fractional Anisotropy (FA), Mean Diffusivity (MD) and Radial Diffusivity (RD) can be used to indirectly infer changes in axonal integrity and myelination (Madden et al., 2012). In aging population, DTI studies described a decrease in FA and an increase in MD and RD in major white matter tracts (de Groot et al., 2015; Madden et al., 2012; Vinke et al., 2018), and these changes are associated with cognitive impairment (Arvanitakis et al., 2016; Bendlin et al., 2010; Borghesani et al., 2013; Wiseman et al., 2018).

However, diffusion metrics within brain tissue can be affected by partial volume effects due to cerebrospinal fluid (Pasternak, Sochen, Gur, Intrator, & Assaf, 2009), especially in the aging brain already affected by atrophy and presenting ventricles enlargement (Jbabdi & Johansen-Berg, 2011; Kurki & Heiskanen, 2018; Salminen et al., 2016; Vos, Jones, Viergever, & Leemans, 2011). Indeed, diffusion metrics derived from DTI are indicators of tissue microstructural state as far as voxels contain only one type of tissue. When voxels contain cerebrospinal fluid (e.g. partial volume), diffusion metrics can be biased and lead to high diffusivity measures (MD, Axial Diffusivity (AD), RD) and reduced FA (Metzler-Baddeley et al., 2012; Pfefferbaum & Sullivan, 2003). This effect has been particularly shown for fornix and corpus callosum because of their proximity to the periventricular regions (Concha, Gross, & Beaulieu, 2005, p. 20; Derek K. Jones & Cercignani, 2010; Metzler-Baddeley et al., 2012).

To overcome this problem, Free Water Elimination (FWE) method was used to differentiate the diffusion properties of brain tissue, such as white matter bundles, and surrounding free water, such as cerebrospinal fluid (Pasternak et al., 2009; Sepehrband et al., 2019). It has been shown that elimination of extracellular free water contamination improves the sensitivity and specificity of most measures derived from conventional DTI (Albi et al., 2017; Pasternak, Westin, et al., 2012; Salminen et al., 2016; Sepehrband et al., 2019). Although this correction techniques exist and have been used in pathological conditions (Bergamino, Kuplicki, Victor, Cha, & Paulus, 2017; Dumont et al., 2019; Ji et al., 2017; Ofori et al., 2017; Tanner et al., 2019) to date the majority of diffusion MRI studies do not consider free water effects on heathy aging brain (Albi et al., 2017; Chad, Pasternak, Salat, & Chen, 2018). Moreover, while FWE was initially developed to correct DTI derived metrics, it has recently been shown that the extracellular free water fraction may be a sensitive marker of age-related microstructural changes (Chad et al., 2018). Indeed, aging is associated with grey

and white matter tissue loss, and the resulting enlargement of interstitial space can lead to increase in free water (unhindered) (Aboitiz, Rodriguez, Olivares, & Zaidel, 1996; Barkhof, Fox, Bastos-Leite, & Scheltens, 2011; Meier-Ruge, Ulrich, Brühlmann, & Meier, 1992; Tang, Nyengaard, Pakkenberg, & Gundersen, 1997).

In addition, many aging studies have not taken white matter hyperintensities (WMH) burden into account. The prevalence and severity of these white matter signal abnormalities as observed on a T2-weighted MRI scan, increase with age and more than 90% of older adults (>60 years old) exhibit WMH (Habes et al., 2016; Leeuw et al., 2001). In older adults, WMH have been associated with a diverse set of inter-related metabolic, inflammatory and vascular factors that affect brain integrity in healthy adults (Arvanitakis et al., 2016; Habes et al., 2018; Jagust, 2013; Wiseman et al., 2018) and related to cognitive impairments, especially in memory and executive functions (Maillard et al., 2019; Svärd et al., 2017; Meike W. Vernooij et al., 2009). Recently, WMHs were associated with changes in white matter composition, indicative of altered water content in white matter fibers (Alber et al., 2019; Ji et al., 2017). Moreover, several recent studies investigating the relationship between WMH and DTI parameters estimate that WMH constitute the ending stage of an histopathological continuum (Maillard et al., 2011; William Reginold et al., 2018), with modifications of DTI parameters in normal appearing white matter may represent the early stage (Maillard et al., 2014; Maniega et al., 2015; Pelletier et al., 2015). Furthermore, tractography studies in aging (Jiang et al., 2018; William Reginold et al., 2018) and in patients with gliomas (Leote, Nunes, Cerqueira, Loução, & Ferreira, 2018) showed a detrimental effect of WMH on fiber tracking algorithms. Despite a decreased FA in WMH, we showed that principal direction under the lesion mask seems to be preserved and coherent, and hence, the tractography algorithm should be able to explore WMHs (Theaud, Dilharreguy, Catheline, & Descoteaux, 2016; and see Figure 1). However, this FA decrease has an impact on the stopping criteria of fiber tracking algorithms and therefore lead to broken streamlines in regions of hyperintensities.

Cingulum bundle runs from the anterior to the postero-temporal part of the brain and is one of the most studied tracts (Jones, Christiansen, Chapman, & Aggleton, 2013). However, literature about cingulum bundle changes occurring in aging is controversial with some studies reporting no difference along the cingulum (Gunbey et al., 2014; Stadlbauer, Salomonowitz, Strunk, Hammen, & Ganslandt, 2008) and others presenting alterations (Catheline et al., 2010; Ezzati, Katz, Lipton, Zimmerman, & Lipton, 2016; Jang, Kwon, Lee, Kim, & Seo, 2016), which ones are or not associated with cognition including executive functions (Kantarci et al., 2011; Metzler-Baddeley et al., 2012; Seiler et al., 2018) and memory (Ezzati et al., 2016; Kantarci et al., 2011; Metzler-Baddeley et al., 2012; Sexton et al., 2010). The different subdivisions of the cingulum investigated in those studies may explain the discrepancies of the literature. More importantly, most of these studies did not consider neither CSF partial effect due to atrophy nor WMH burden whereas recent tractography studies

consistently showed that the atrophy-related partial volume effects (Metzler-Baddeley et al., 2012; Salminen et al., 2016), age-related ventricle enlargement (Kurki & Heiskanen, 2018) or WMH burden (Reginold et al., 2016), affected diffusion metrics of cingulum in healthy older adults. In particular, Reginold and colleagues reported higher RD of cingulum tracts that crossed WMH compared with tracts not passing through WMH (Reginold et al., 2016; see also Kurki & Heiskanen, 2018). Thereby, these studies suggest that atrophy as well as WMH burden might affect cingulum diffusion metrics and these latters could constitute source of significant bias in white matter analyzes of cingulum and its distinctive roles with cognitive functions in aging.

In this study, we tested the prediction that WMHs accounting and free water elimination would provide more accurate white matter diffusion metrics and better characterize the microstructural changes of cingulum during aging. For this, the cingulum bundle was reconstructed with a tractography pipeline that includes a manually curated WMH mask applied in the native space of subjects to limit their negative effect on fiber tracking algorithms. In two groups of older individuals presenting a high or a low WMH burden, we firstly described the commonly used DTI metrics of the cingulum bundle when they either derived from the conventional tensor DTI model or the bi-tensor FWE diffusion model. Secondly, we explored the association of these parameters with cognitive changes evaluated over 12 years. Because cingulum is usually associated with executive functions and memory (Bathelt, Johnson, Zhang, & Astle, 2019; Bubb, Metzler-Baddeley, & Aggleton, 2018), we used the Isaacs Set Test, a widely used test of verbal fluency, involving semantic memory and executive functioning to assess the impact of free water elimination on association between cingulum diffusion metrics and cognitive functions.

2. Methods

2.1. Dataset

Participants have been selected from the Bordeaux sample of the Three-City study (3C Study Group, 2003), an ongoing longitudinal multicenter population-based elderly cohort designed to evaluate risk factors of dementia. The study protocol was approved by the ethics committee of Kremlin-Bicêtre University Hospital (Paris, France), and all participants provided written informed consent. At baseline, subjects were non-institutionalized, randomly recruited from electoral lists, and were at least 65-years old. Since the 1999-2000 baseline inclusion, an extended neuropsychological assessment was administered by trained psychologists at each follow-up occurring at 2, 4, 7, 10 and 12 years. MRI scans have been performed at the 10-year follow-up. Based on the terciles of the WMH volumes, we identified 27 subjects with a high level of WMH (upper tercile) and 27 subjects with a low level of WMH (lower tercile). Because of cerebral atrophy, cingulum reconstruction failed for 5 subjects in the low WMH group and 4 subjects in the high WMH group. Finally, a total of 45 subjects were

included in the present study. All participants were right-handed, had a Mini Mental State Examination (MMSE) score > 24 and were free of dementia and brain pathologies such as stroke and meningioma.

2.2. Cognitive and clinical variables

For this study, we used the MMSE to control for global cognitive function and the Isaacs Set Test (IST, Isaacs & Kennie, 1973) to assess verbal fluency. To evaluate cognitive changes over 12 years, participant's specific slope for IST score was estimated using a linear mixed model with time as a continuous variable, random intercept and slope. For the IST, one score was used corresponding to the number of words named at 15-second. In addition, several clinical variables were also collected: depressive symptoms evaluated with the Center for Epidemiologic Studies-Depression scale (CESD, Radloff, 1977), vascular risk factors including hypertension defined as blood pressure > 140/90 mm Hg or anti-hypertensive medication, diabetes defined as glycemia > 7 mmol/l or anti-diabetics medication, and body mass index (BMI).

2.3. MRI acquisition

MRI examinations were performed using a 3T Achieva system (Philips Medical Systems, The Netherlands) equipped with a 8-channel SENSE head coil. Head motions were minimized by using a tightly padded clamps attached to the head coil. For each subject, anatomical and diffusion images were obtained. All acquisitions were aligned on the anterior commissure-posterior commissure plan. Anatomical MRI volumes were acquired using a 3D magnetization-prepared rapid gradient-echo (MPRAGE) T1-weighted sequence with the following parameters: repetition time (TR)/ echo time (TE) = 8.2 ms/3.5 ms, flip angle 7°, field of view (FOV) 256x256 mm^2, 180 slices of 1 mm of thickness, voxel size 1x1x1 mm^3. Fluid-attenuated inversion recovery (FLAIR) images were also obtained with the following parameters: TR=11000 ms; TE=140 ms, inversion time = 2800 ms, 90-degree flip angle, FOV 230x172 mm^2, 24 slices of 5 mm of thickness, voxel size 0.72x1.20x5 mm^3. Diffusion weighted images were acquired using a spin echo single shot EPI sequence composed of one b0 map (b-value=0 s/mm^2) follow by 21 diffusion gradients maps (b-value=1000s/mm^2) homogenously spread over a half sphere and the 21 opposite directions spread over the opposite half sphere. To increase signal-to-noise ratio, a second series of two b0 and 42 DWI volumes was acquired. Sixty axial slices were acquired with the following parameters: TR= 9700 ms, TE= 60 ms, flip angle 90°, FOV 224×224 mm^2, 60 slices, no gap and voxel size 2x2x2 mm^3.

2.4. MRI preprocessing

2.4.1. Diffusion MRI preprocessing

Diffusion MRI images were pre-processed using FMRIB's Diffusion toolbox (Behrens, Berg, Jbabdi, Rushworth, & Woolrich, 2007; Behrens et al., 2003) in order to produce individual FA, MD, AD and RD maps in native space. For the diffusion MRI preprocessing, the processing steps are similar than the steps in TractoFlow pipeline described in Theaud et al., 2019. For each subject, dMRI images were co-registered to the b0 reference image with an affine transformation and were corrected for motion and eddy current distortions. Brain Extraction Tool (BET, Smith, 2002) was applied to eliminate non-brain voxels. Diffusion MRI images was denoised using the non-local mean denoising method (Descoteaux, Wiest-Daesslé, Prima, Barillot, & Deriche, 2008). Successive dMRI runs were then averaged for each participant to increase signal-to-noise ratio. The fiber Orientation Distribution Functions (fODF) was computed using the spherical constrained deconvolution (Descoteaux, Angelino, Fitzgibbons, & Deriche, 2007; Tournier, Calamante, & Connelly, 2007). Finally, Free Water Elimination (FWE, Pasternak et al., 2009) was used to estimate and remove the free water components from diffusion images. Briefly, FWE is a method which fits a bi-tensor model within each voxel to separate changes affecting the extracellular space, defining as an isotropic diffusion, from those reflecting intracellular processes (Pasternak, Westin, et al., 2012). The FW-corrected DTI maps were called FA tissue (FAt), RDt, ADt and MDt.

2.4.2. White Matter Hyperintensity segmentation

White matter hyperintensity volumes were automatically segmented by the lesion growth algorithm implemented in the Lesion Segmentation Tool (LST, v2.0; Schmidt et al., 2012) for SPM12. For each participant, T1-weighted image was used to generate partial volume estimation and three tissue probability maps (grey matter, white matter and cerebrospinal fluid). Then, each FLAIR image was co-registered on the corresponding T1 image to compute lesion belief maps for the three tissue classes. These maps were finally summed up and a lesion growth model with a pre-chosen initial threshold ($\kappa = 0.3$) was applied to create lesion maps in native space. Visual inspection of the lesion probability maps was performed and WMH volumes were extracted, normalized by white matter volume and log transformed.

2.4.3. Cingulum tractography

For each participant, a local tracking with twenty seeds per voxels was performed using fODF map. The seeding and tracking mask were modified to include the WMH mask as previously described (Theaud et al., 2016) (Figure 2). Next, the left and right cingulum bundles were extracted using the RecoBundles approach (Garyfallidis et al., 2018) (Figure 3), and visually inspected using MI-Brain (http://www.imeka.ca/mi-brain, (Rheault, Houde, & Descoteaux, 2017).

2.5. Cingulum metrics

Cingulum diffusion metrics including FA, MD, RD and AD were extracted before and after FW-correction. After FW-correction, the free water value was also extracted. Metrics of the left and right cingulum were then averaged. The volume of WMH burden within the cingulum was estimated by crossing the WMH mask with the cingulum bundle.

To evaluate changes in diffusion metrics after FW-correction, we determined a percentage of metrics change (% change) for each participant by computing the difference between the metric value before and after FW-correction divided by the value before FW-correction [*i.e*. % change = ((FW-corrected metric – DTI metric)/DTI metric) × 100].

2.6. Statistical analysis

First, demographic, cognitive and structural variables were compared between low and high WMH subjects with Mann–Whitney U-tests for continuous variables and Pearson's Chi-squared test for categorical variables. Next, Spearman's correlation or Mann–Whitney U-tests was used to evaluate the association or differences between cingulum diffusion metrics and confounding variables usually affecting white matter parameters such as depressive symptoms, or cardiovascular factors (diabetes, hypertension and BMI, see supplementary material) (Wassenaar, Yaffe, van der Werf, & Sexton, 2019).

To evaluate the effects of FW-correction on cingulum diffusion metrics relative to those estimated by the conventional DTI, we first performed a within group effect using a paired sample Wilcoxon's test. Then, we evaluated how these corrections affect the between group differences using a Mann–Whitney U-test for independent samples. To ensure that between group difference was not led by age, linear regression model was performed with diffusion metrics (DTI or FW-corrected metrics) as dependent variables and group and age as independent variables. For free water value, the differences in cingulum free water value between the two groups was assessed using a Mann–Whitney U-test for independent samples.

Partial Spearman's correlations controlling for age, cingulum white matter and WMH volume within cingulum were also performed within each group before and after FW-correction to describe to what extent the FW-correction affect the associations between metrics of the cingulum bundle and changes in verbal fluency. This model of partial Spearman's correlation was also used to examine the relationship between free water content and changes in verbal fluency within each group. As diabetes and hypertension were significantly associated with cingulum diffusion metrics (see Table 1 supplementary material), we also performed partial Spearman's correlations controlling for diabetes and hypertension.

A false discovery rate (FDR) multiple-comparison correction method was systematically applied for each analysis. Results were considered significant for $p<0.05$, FDR corrected (Benjamini & Hochberg, 1995). All statistical analyses were performed using IBM SPSS Statistics v.23 software (IBM Corporation, Armonk, NY, USA).

3. Results

3.1. Sample characteristics

Characteristics of participants are presented in Table 1. Compared to the low WMH group, high WMH subjects were older (median [IQR]: 78.75 [77-89] *vs* 84.3 [76-91], $p < 0.05$). Both groups did not differ for sex, cognition (MMSE and IST decline), education level, BMI, depressive symptoms, diabetes and hypertension (Table 1). No difference between the two groups was observed for the whole white matter volume (low WMH: 403.1 cm^3, [77.0] and high WMH: 378.9 cm^3, [68.1], $p > 0.05$) and for the cingulum tract volume (low WMH:5.2 cm^3, [3.2] and high WMH: 4.9 cm^3, [1.9], $p > 0.05$). Diabetes and hypertension were significantly associated with cingulum diffusion metrics but not the depressive symptoms nor the BMI (see Table 1 supplementary material).

3.2. Effect of FW-correction on conventional DTI parameters and free water content

3.2.1. Within-group differences for the cingulum diffusion metrics

Cingulum diffusion metrics for the low and high WMH groups are presented in Table 2. After FW-correction, the low WMH group presented a median increase of 7.79 % of FAt ($z=-3.15$, $p=0.029$, effect of size $r = -0.46$) and a median decrease of 1.80 % of MDt ($z =-2.86$, $p=0.023$, $r=-0.42$), 1.33% of ADt ($z =-1.46$, $p=0.030$; $r=-0.21$) and 3.24% of RDt ($z =-3.32$, $p=0.014$, $r=-0.48$). Similar results were observed for the high WMH group for FAt (median increase of 7.15%, $z =-3.27$, $p=0.021$, $r=-0.47$) and MDt (median decrease of 1.75%, $z =-2.95$, $p=0.020$, $r=-0.43$), ADt (median decrease of 1.51%, $z = -1.41$, $p=0.032$, $r=-0.20$) and RDt (median decrease of 3.48%, $z =-3.38$, $p=0.012$, $r=-0.49$) after FW-correction.

3.2.2. Between-group differences for the cingulum diffusion metrics

Before FW-correction, only RD values were significantly different between the two groups ($U=196$, $p=0.04$, Table 2). In contrast after FW-correction, high WMH subjects presented lower FAt ($U=246$, $p = 0.031$, Table 2, Figure 4c), higher MDt ($U = 242$, $p = 0.023$, Table 2, Figure 4d) and RDt ($U = 201$, $p = 0.01$, Table 2, Figure 4e) compared to the low WMH group. No significant difference was observed for ADt ($U=306$; $p=0.28$, Table 2, Figure 4f). In linear regression model adjusted for age, a significant group effect was still found for FAt ($\beta = -0.305$, $p=0.039$, $R^2=0.1$), MDt ($\beta = 0.322$, $p=0.037$, $R^2=0.09$) and RDt ($\beta = 0.408$, $p=0.015$, $R^2=0.128$).

3.2.3. Between-group differences for the cingulum free water content

A non-zero value of free water fraction within the cingulum bundle was observed in both groups (0.136 *versus* 0.142 for low and high group respectively, Table 2) that showed no significant group difference (U=300; p=0.25, Table 2, Figure 4g).

3.3. Relationships between cingulum diffusion metrics and verbal fluency

3.3.1. Associations with DTI conventional metrics

Only one significant association was observed between DTI conventional metric and cognitive changes. In high WMH group, lower FA value was associated with IST decline at 15 seconds in a model adjusted for age, cingulum WMH and white matter volumes ($p < 0.05$, Table 3). When the models were adjusted for cardiovascular confounding variables (i.e. diabetes and hypertension), conventional DTI cingulum diffusion metrics remained significantly associated with IST changes at 15 seconds (Partial spearman rho coefficient, for FA ρ = -0.245; p=0.044, FDR corrected)

3.3.2. Associations with FW-corrected metrics

After FW-correction, cingulum diffusion metrics were more strongly associated with changes in IST score than before FW-correction. For low WMH group, high values of ADt was associated with IST decline at 15 seconds in a model adjusted for age, cingulum WMH and white matter volumes ($p < 0.05$, Table 3). For high WMH group, high values of RDt and low values of FAt were both strongly associated with IST decline at 15 seconds in a model adjusted for age, cingulum WMH and white matter volumes ($p < 0.05$, Table 3).

When the models were adjusted for cardiovascular confounding variables, FW-corrected cingulum diffusion metrics remained significantly associated with IST changes at 15 seconds in both the low WMH group (Partial spearman rho coefficient, for ADt ρ = -0.251; p=0.039) and high WMH group (Partial spearman rho coefficient, for FAt: ρ = 0.310, p=0.036; for RDt: ρ = -0.302, p=0.037).

3.3.3. Association with cingulum free water content

Whatever the WMH burden, high value of free water was associated with changes in IST score at 15 seconds in a model adjusted for age, cingulum WMH and white matter volumes ($p < 0.05$, Table 3). When the models were adjusted for cardiovascular confounding variables, (i.e. Diabetes and hypertension), free water associations remained significant both in low WMH group (Partial spearman coefficient, ρ = -0.278; p=0.035) and high WMH group (Partial spearman coefficient, ρ -0.315; p = 0.031, p FDR-corrected).

4. Discussion

In this study, we examined the effect of the free water elimination on conventional DTI measures of white matter within the cingulum tract in subjects presenting unequal WMH burden. We first investigated whether applying a FW-correction improved the sensitivity of conventional DTI metrics to detect white matter alterations within the cingulum tract. The effect of this correction on the association between cingulum diffusion metrics and cognitive evolution over 12 years was then determined. In our group of 45 older individuals, FW-correction significantly impacted all conventional DTI metrics. Compared to the low WMH group, in addition to RDt difference, FW-correction revealed additional differences for FAt and MDt within the cingulum bundle in subjects with high WMH burden. We observed significant associations between these FW-corrected cingulum diffusion metrics and longitudinal changes in verbal fluency performance at 15 seconds. Finally, we showed a non-null free water fraction in the cingulum bundle, which was associated to the verbal fluency performance at 15 seconds, whatever the WMH burden.

4.1. Free water elimination effect

In accordance with recent findings in young (Sepehrband et al., 2019), older adults (Chad et al., 2018) and clinical samples (Bergamino, Pasternak, Farmer, Shenton, & Paul Hamilton, 2016; Ji et al., 2017), FW-correction was associated with an increase in FA, and a decrease in diffusion metrics (MD, RD and AD) in both groups. These changes of DTI metrics after elimination of the free water compartment suggested not only a non-zero volume of the extracellular water (Hoy, Kecskemeti, & Alexander, 2015; Ji et al., 2017; Madden et al., 2012; Pasternak et al., 2009), but also indicate that white matter microstructural changes were less pronounced than previously suggested by conventional DTI metrics (Bennett & Madden, 2014; Bennett et al., 2017; Lockhart & DeCarli, 2014; Pelletier et al., 2015).

In our results based on conventional DTI, between-group difference showed that subjects with high WMH burden exhibited higher RD values in the cingulum bundle compared to the low WMH group. The elimination of the free water content revealed additional differences between the two groups including higher MDt and lower FAt values in subjects with a high WMH burden, independently of age. In line with this, FW-correction also revealed significant associations in both groups between the FW-corrected cingulum metrics (FAt, MDt and RDt) and cognitive decline that could not be fully observed without considering free water. This

suggests that free water affect group differences as well as associations between conventional DTI measures and changes in verbal fluency in older subjects. We assumed that this free water effect could partly explain the controversial results of the literature regarding the role of cingulum in cognition. Therefore, our results support previous studies reporting that the elimination of the free water enabled better estimation of tissue-specific indices which were more sensitive to microstructural changes than the measures derived from conventional DTI (Albi et al., 2017; Dumont et al., 2019; Hoy et al., 2015; Lyall et al., 2018; Madden et al., 2012).

4.2. Free water content

In our group of elderly participants, we observed a non-zero value of free water fraction in the cingulum bundle that showed no difference according to the WMH groups. This suggests that free water fraction was unaffected by the WMH burden, supporting previous studies (Dumont et al., 2019; Ji et al., 2017) but in contrast to others (Maillard et al., 2019; Pasternak, Westin, et al., 2012; Promjunyakul et al., 2016) emphasizing the need for additional studies. Moreover, this non-zero value of free water suggests that despite its distance from the ventricles there is an accumulation of free water in the extracellular space within the cingulum bundle. This is consistent with recent studies reporting a fraction of free water on whole white matter in the elderly (Albi et al., 2017; Chad et al., 2018; Papadaki et al., 2019). In addition, in our subjects no association between free water fraction within cingulum and CSF volumes was found (data not shown), while a negative association between free water fraction and cingulum volume was observed (i.e. higher free water with low cingulum volume). This suggest that non-zero free water value could be due to atrophy-related process and not to the CSF contamination in our subjects (Oestreich et al., 2016; Wang et al., 2011).

Furthermore, higher free water fraction within cingulum bundle was strongly associated with changes in verbal fluency performance, regardless of WMH burden and other confounding factors. The Isaacs set test is a multi-composite test involving executive processing strategy allowing efficient search within the semantic stores (Amieva et al., 2008; Catheline et al., 2015). The observed association is consistent with previous studies that evidenced the involvement of the cingulum bundle in executive functioning (Bettcher et al., 2016; Gyebnár et al., 2018; Metzler-Baddeley et al., 2012; Seiler et al., 2018) and with studies showing that higher free water fraction was associated with poorer cognitive performance in older adults (Maillard et al., 2019) and in clinical populations (Bergamino et al., 2017; Ji et al., 2017, 2019; Maillard et al., 2017). Indeed, in a recent longitudinal study on 224 elderly subjects, Maillard and colleagues showed that free water increased was not only associated with reduced performance in executive function but was also the most robust predictor of cognitive decline (Maillard et al., 2019). Ji and colleagues showed in sample of 85 subjects with Alzheimer's Disease or vascular dementia that high free water fraction was associated with the symptom severity (Clinical Dementia Rating) and poor cognitive performance (Ji et al., 2017). Together, these results and ours support the idea that beyond the

elimination of CSF contamination, free water would provide additional structural information as an index of physiological tissue changes within the white matter (Chad et al., 2018; Hoy et al., 2015, 2017). However, the underlying microcellular events associated to this index is far from being fully understood; its increase could be related to different pathophysiological processes such as microvascular degeneration (Ji et al., 2017; Maillard et al., 2017; Rydhög et al., 2017), reduction in myelin content (Oestreich et al., 2016; Papadaki et al., 2019) or modulation of the permeability of the blood-brain barrier (Maillard et al., 2017).

4.3. White matter hyperintensities burden effect

In agreement with previous studies (Reginold et al., 2016; Svärd et al., 2017; M. W. Vernooij et al., 2008), WMH burden was associated with a lower FA and higher diffusion metrics of the cingulum bundle, even though we considered the whole WMH burden and not their location. Interestingly, in high WMH group we showed that only 4% of the cingulum crossed areas with WMH lesions (Leeuw et al., 2001; Yoshita et al., 2006). This suggests that despite this weak direct impact, WMH burden may contribute at least in part to the modifications observed in the high WMH group. In accordance, recent tractography studies have shown that cingulum tract crossing WMH compared to tract not crossing showed changes in the diffusion measures, in particular increase of RD (Reginold et al., 2016), and suggested that these modifications could extend beyond the lesion to the unaffected portion by the WMHs (Maillard et al., 2014; Promjunyakul et al., 2016; Reginold et al., 2018). Moreover, previous DTI studies reported that WMH were associated with white matter microstructure modifications occurring in the normal-appearing white matter (Leritz et al., 2014; Maillard et al., 2014; Pelletier et al., 2015; Promjunyakul et al., 2016), indicating that individuals with higher WMH burden were more susceptible to present lower FA (Birdsill et al., 2014; Sala et al., 2012; Svärd et al., 2017) and higher diffusion metrics (Iverson et al., 2011; Lange et al., 2014; Pelletier et al., 2015; Svärd et al., 2017). Taken together these results suggest that small focal WMH burden have local and distal effects large enough to affect the white matter diffusion properties on the whole cingulum tract and as a result can impact cognition.

Moreover, depending on the WMH burden, changes in verbal fluency were associated with different diffusion metrics. These results suggest that two types of physiological process could account for decline in verbal fluency in elderly according to the presence or not of WMH. In low WMH group ADt values are associated to verbal fluency decline, whereas in high WMH group lower FAt was associated with higher changes in verbal fluency at 15 seconds, in conjunction with higher RDt, without changes in ADt (see supplementary material). This latter diffusion pattern has been described in animal studies as predominantly reflecting myelin-specific effect (Song et al., 2003; Sun et al., 2005). Moreover, in human post-mortem studies, RD increase in multiple sclerosis patients

was correlated with demyelination severity (Klawiter et al., 2011; Schmierer et al., 2008). This suggest a myelin-specific change within cingulum bundle, rather than axonal damage (Madden et al., 2012; M. W. Vernooij et al., 2008), which would be related to change in verbal fluency (Peters, 2002). Yet, it is difficult to interpret the microstructural properties based on DTI indices alone and the link to neurobiology support stills incomplete (Madden et al., 2012; Maier-Hein et al., 2017).

Some methodological limitations have to be considered in interpreting our data. First, this study was based on a moderate sample size of healthy elderly participants. However, our population exhibited sufficient inter-individual variability in structural parameters and cognitive performances to detect associations between theses parameters. Second, the cingulum bundle was considered here as a single entity despite that this complex network structure, contains not only long fibers that potentially extend to the frontal and temporal lobes, but also short association fibers connecting adjacent cortices (Bubb et al., 2018; Catani & Thiebaut de Schotten, 2008; Lawes et al., 2008). Finally, the current study was based on diffusion MRI data that was acquired with a single b-value. Thus, the algorithm used to fit the free water imaging model involved spatial regularization of the data which decreases intra-group variability (Pasternak et al., 2009), and may hide subtle spatial features. Although comparable results using single- and multi-shell acquisitions have been reported (Pasternak, Shenton, & Westin, 2012), more advanced acquisitions that include multi b-values could further increase the accuracy of the free water model (Hoy et al., 2015; Pasternak, Shenton, et al., 2012).

5. Conclusion

To conclude, in the present study we showed that FW-correction improved the sensitivity of conventional DTI metrics to age-related tissue changes. We also emphasized the importance to consider WMH burden in aging study. The FW-correction improve the sensitivity to detect associations between tissue specific diffusion metrics and changes in verbal fluency in older individuals. Moreover, free water value *per se* seems to be a relevant metric for age-related modifications within the white matter tissue. Therefore, these observations suggest the importance of using the free water compartment for DTI metrics in aging.

6. Funding

This research was funded by the FONDATION VAINCRE ALZHEIMER (#14733). This study was also funded as an emerging project within the context of the laboratory of Excellence TRAIL ANR-10-LABX-57. The Three-City study is conducted under a partnership agreement between the Institut National de la Santé et de la Recherche Médicale (INSERM), the University Bordeaux 2 Victor Segalen and Sanofi-Aventis. The Fondation pour la Recherche Médicale funded the preparation and initiation of the study. The Three-City study is also supported by the Caisse Nationale Maladie des Travailleurs Salariés, Direction Générale de la Santé, MGEN, Institut de la Longévité, Conseils Régionaux d'Aquitaine et Bourgogne, Fondation de France, Ministry of Research-INSERM Programme "Cohortes et collections de données biologiques", Agence Nationale de la Recherche ANR PNRA 2006 and LongVie 2007, the "Fondation Plan Alzheimer" (FCS 2009-2012) and the Caisse Nationale de Solidarité pour l'Autonomie (CNSA). Part of this research was also supported by the Fonds de recherche du Québec – Nature et technologies (FRQNT), the NSERC Discovery grant, the Université de Sherbrooke institutional chair in neuroinformatics from Pr Descoteaux and the Mitacs Accelerate program.

7. Compliance with ethical standards

Conflict of interest The authors declare that they have no conflict of interest.

Studies involving human participants All procedures were conducted with approval from the ethics committee of Kremlin Bicêtre Hospital (Paris, France)

Informed consent All participants provided written informed consent for participation in this study.

8. Data availability

The data that support the findings of this study are available from the corresponding author upon reasonable request.

9. References

3C Study Group. (2003). Vascular factors and risk of dementia□: Design of the Three-City Study and baseline characteristics of the study population. *Neuroepidemiology*, *22*(6), 316□325. https://doi.org/10.1159/000072920

Aboitiz, F., Rodriguez, E., Olivares, R., & Zaidel, E. (1996). Age-related changes in fibre composition of the human corpus callosum. *Neuroreport*, *7*(11), 1761□1764.

Alber, J., Alladi, S., Bae, H.-J., Barton, D. A., Beckett, L. A., Bell, J. M., … Hainsworth, A. H. (2019). White matter hyperintensities in vascular contributions to cognitive impairment and dementia (VCID)□: Knowledge gaps and opportunities. *Alzheimer's & Dementia (New York, N. Y.)*, *5*, 107□117. https://doi.org/10.1016/j.trci.2019.02.001

Albi, A., Pasternak, O., Minati, L., Marizzoni, M., Bartrés-Faz, D., Bargalló, N., … PharmaCog Consortium. (2017). Free water elimination improves test-retest reproducibility of diffusion tensor imaging indices in the brain□: A longitudinal multisite study of healthy elderly subjects. *Human Brain Mapping*, *38*(1), 12□26. https://doi.org/10.1002/hbm.23350

Amieva, H., Le Goff, M., Millet, X., Orgogozo, J. M., Pérès, K., Barberger-Gateau, P., … Dartigues, J. F. (2008). Prodromal Alzheimer's disease□: Successive emergence of the clinical symptoms. *Annals of Neurology*, *64*(5), 492□498. https://doi.org/10.1002/ana.21509

Arvanitakis, Z., Fleischman, D. A., Arfanakis, K., Leurgans, S. E., Barnes, L. L., & Bennett, D. A. (2016). Association of white matter hyperintensities and gray matter volume with cognition in older individuals without cognitive impairment. *Brain Structure & Function*, *221*(4), 2135□2146. https://doi.org/10.1007/s00429-015-1034-7

Barkhof, F., Fox, N. C., Bastos-Leite, A. J., & Scheltens, P. (2011). Normal Ageing. In F. Barkhof, N. C. Fox, A. J. Bastos-Leite, & P. Scheltens (Éd.), *Neuroimaging in Dementia* (p. 43□57). https://doi.org/10.1007/978-3-642-00818-4_4

Bathelt, J., Johnson, A., Zhang, M., & Astle, D. E. (2019). The cingulum as a marker of individual differences in neurocognitive development. *Scientific Reports*, *9*(1), 2281. https://doi.org/10.1038/s41598-019-38894-z

Behrens, T. E. J., Berg, H. J., Jbabdi, S., Rushworth, M. F. S., & Woolrich, M. W. (2007). Probabilistic diffusion tractography with multiple fibre orientations□: What can we gain? *NeuroImage*, *34*(1), 144□155. https://doi.org/10.1016/j.neuroimage.2006.09.018

Behrens, T. E. J., Woolrich, M. W., Jenkinson, M., Johansen-Berg, H., Nunes, R. G., Clare, S., … Smith, S. M. (2003). Characterization and propagation of uncertainty in diffusion-weighted MR imaging. *Magnetic Resonance in Medicine*, *50*(5), 1077□1088. https://doi.org/10.1002/mrm.10609

Bendlin, B. B., Fitzgerald, M. E., Ries, M. L., Xu, G., Kastman, E. K., Thiel, B. W., … Johnson, S. C. (2010). White matter in aging and cognition□: A cross-sectional study of microstructure in adults aged eighteen to eighty-three. *Developmental Neuropsychology*, *35*(3), 257□277. https://doi.org/10.1080/87565641003696775

Benjamini, Y., & Hochberg, Y. (1995). Controlling the False Discovery Rate□: A Practical and Powerful Approach to Multiple Testing. *Journal of the Royal Statistical Society: Series B (Methodological)*, *57*(1), 289□300. https://doi.org/10.1111/j.2517-6161.1995.tb02031.x

Bennett, I. J., & Madden, D. J. (2014). Disconnected aging□: Cerebral white matter integrity and age-related differences in cognition. *Neuroscience*, *276*, 187□205. https://doi.org/10.1016/j.neuroscience.2013.11.026

Bennett, Ilana J., Greenia, D. E., Maillard, P., Sajjadi, S. A., DeCarli, C., Corrada, M. M., & Kawas, C. H. (2017). Age-related white matter integrity differences in oldest-old without dementia. *Neurobiology of Aging*, *56*, 108□114. https://doi.org/10.1016/j.neurobiolaging.2017.04.013

Bergamino, M., Kuplicki, R., Victor, T. A., Cha, Y.-H., & Paulus, M. P. (2017). Comparison of two different analysis approaches for DTI free-water corrected and uncorrected maps in the study of white matter microstructural integrity in individuals with depression. *Human Brain Mapping*, *38*(9), 4690□4702. https://doi.org/10.1002/hbm.23694

Bergamino, M., Pasternak, O., Farmer, M., Shenton, M. E., & Paul Hamilton, J. (2016). Applying a free-water correction to diffusion imaging data uncovers stress-related neural pathology in depression. *NeuroImage: Clinical*, *10*, 336□342. https://doi.org/10.1016/j.nicl.2015.11.020

Bettcher, B. M., Mungas, D., Patel, N., Elofson, J., Dutt, S., Wynn, M., … Kramer, J. H. (2016). Neuroanatomical substrates of executive functions□: Beyond prefrontal structures. *Neuropsychologia*, *85*, 100□109. https://doi.org/10.1016/j.neuropsychologia.2016.03.001

Birdsill, A. C., Koscik, R. L., Jonaitis, E. M., Johnson, S. C., Okonkwo, O. C., Hermann, B. P., … Bendlin, B. B. (2014). Regional white matter hyperintensities□: Aging, AD risk, and cognitive function. *Neurobiology of aging*, *35*(4). https://doi.org/10.1016/j.neurobiolaging.2013.10.072

Borghesani, P. R., Madhyastha, T. M., Aylward, E. H., Reiter, M. A., Swarny, B. R., Schaie, K. W., & Willis, S. L. (2013). The association between higher order abilities, processing speed, and age are variably mediated by white matter integrity during typical aging. *Neuropsychologia*, *51*(8), 1435□1444. https://doi.org/10.1016/j.neuropsychologia.2013.03.005

Bubb, E. J., Metzler-Baddeley, C., & Aggleton, J. P. (2018). The cingulum bundle□: Anatomy, function, and dysfunction. *Neuroscience and Biobehavioral Reviews*. https://doi.org/10.1016/j.neubiorev.2018.05.008

Catani, M., & Thiebaut de Schotten, M. (2008). A diffusion tensor imaging tractography atlas for virtual in vivo dissections. *Cortex; a Journal Devoted to the Study of the Nervous System and Behavior*, *44*(8), 1105□1132. https://doi.org/10.1016/j.cortex.2008.05.004

Catheline, G., Amieva, H., Dilharreguy, B., Bernard, C., Duperron, M.-G., Helmer, C., … Allard, M. (2015). Semantic retrieval over time in the aging brain□: Structural evidence of hippocampal contribution. *Hippocampus*, *25*(9), 1008□1016. https://doi.org/10.1002/hipo.22423

Catheline, G., Periot, O., Amirault, M., Braun, M., Dartigues, J.-F., Auriacombe, S., & Allard, M. (2010). Distinctive alterations of the cingulum bundle during aging and Alzheimer's disease. *Neurobiology of Aging*, *31*(9), 1582□1592. https://doi.org/10.1016/j.neurobiolaging.2008.08.012

Chad, J. A., Pasternak, O., Salat, D. H., & Chen, J. J. (2018). Re-examining age-related differences in white matter microstructure with free-water corrected diffusion tensor imaging. *Neurobiology of Aging*, *71*, 161–170. https://doi.org/10.1016/j.neurobiolaging.2018.07.018

Concha, L., Gross, D. W., & Beaulieu, C. (2005). Diffusion Tensor Tractography of the Limbic System. *American Journal of Neuroradiology*, *26*(9), 2267–2274.

Damoiseaux, J. S. (2017). Effects of aging on functional and structural brain connectivity. *NeuroImage*, *160*, 32–40. https://doi.org/10.1016/j.neuroimage.2017.01.077

de Groot, M., Ikram, M. A., Akoudad, S., Krestin, G. P., Hofman, A., van der Lugt, A., … Vernooij, M. W. (2015). Tract-specific white matter degeneration in aging: The Rotterdam Study. *Alzheimer's & Dementia: The Journal of the Alzheimer's Association*, *11*(3), 321–330. https://doi.org/10.1016/j.jalz.2014.06.011

Descoteaux, M., Angelino, E., Fitzgibbons, S., & Deriche, R. (2007). Regularized, fast, and robust analytical Q-ball imaging. *Magnetic Resonance in Medicine*, *58*(3), 497–510. https://doi.org/10.1002/mrm.21277

Descoteaux, M., Wiest-Daesslé, N., Prima, S., Barillot, C., & Deriche, R. (2008). Impact of Rician adapted Non-Local Means filtering on HARDI. *Medical Image Computing and Computer-Assisted Intervention: MICCAI ... International Conference on Medical Image Computing and Computer-Assisted Intervention*, *11*(Pt 2), 122–130.

Dumont, M., Roy, M., Jodoin, P.-M., Morency, F. C., Houde, J.-C., Xie, Z., … Descoteaux, M. (2019). Free water in white matter differentiates MCI and AD from control subjects. *BioRxiv*, 537092. https://doi.org/10.1101/537092

Ezzati, A., Katz, M. J., Lipton, M. L., Zimmerman, M. E., & Lipton, R. B. (2016). Hippocampal volume and cingulum bundle fractional anisotropy are independently associated with verbal memory in older adults. *Brain imaging and behavior*, *10*(3), 652–659. https://doi.org/10.1007/s11682-015-9452-y

Garyfallidis, E., Côté, M.-A., Rheault, F., Sidhu, J., Hau, J., Petit, L., … Descoteaux, M. (2018). Recognition of white matter bundles using local and global streamline-based registration and clustering. *NeuroImage*, *170*, 283–295. https://doi.org/10.1016/j.neuroimage.2017.07.015

Gunbey, H. P., Ercan, K., Fındıkoglu, A. S., Bulut, H. T., Karaoglanoglu, M., & Arslan, H. (2014). The Limbic Degradation of Aging Brain: A Quantitative Analysis with Diffusion Tensor Imaging [Research article]. https://doi.org/10.1155/2014/196513

Gyebnár, G., Szabó, Á., Sirály, E., Fodor, Z., Sákovics, A., Salacz, P., … Csukly, G. (2018). What can DTI tell about early cognitive impairment? – Differentiation between MCI subtypes and healthy controls by diffusion tensor imaging. *Psychiatry Research: Neuroimaging*, *272*, 46–57. https://doi.org/10.1016/j.pscychresns.2017.10.007

Habes, M., Erus, G., Toledo, J. B., Bryan, N., Janowitz, D., Doshi, J., … Davatzikos, C. (2018). Regional tract-specific white matter hyperintensities are associated with patterns of aging-related brain atrophy via vascular risk factors, but also independently. *Alzheimer's & Dementia: Diagnosis, Assessment & Disease Monitoring*, *10*, 278–284. https://doi.org/10.1016/j.dadm.2018.02.002

Habes, M., Erus, G., Toledo, J. B., Zhang, T., Bryan, N., Launer, L. J., … Davatzikos, C. (2016). White matter hyperintensities and imaging patterns of brain ageing in the general population. *Brain*, *139*(4), 1164–1179. https://doi.org/10.1093/brain/aww008

Hoy, A. R., Kecskemeti, S. R., & Alexander, A. L. (2015). Free water elimination diffusion tractography: A comparison with conventional and fluid-attenuated inversion recovery, diffusion tensor imaging acquisitions. *Journal of Magnetic Resonance Imaging*, *42*(6), 1572–1581. https://doi.org/10.1002/jmri.24925

Hoy, A. R., Ly, M., Carlsson, C. M., Okonkwo, O. C., Zetterberg, H., Blennow, K., … Bendlin, B. B. (2017). Microstructural white matter alterations in preclinical Alzheimer's disease detected using free water elimination diffusion tensor imaging. *PloS One*, *12*(3), e0173982. https://doi.org/10.1371/journal.pone.0173982

Ikram, M. A., Vrooman, H. A., Vernooij, M. W., van der Lijn, F., Hofman, A., van der Lugt, A., … Breteler, M. M. B. (2008). Brain tissue volumes in the general elderly population: The Rotterdam Scan Study. *Neurobiology of Aging*, *29*(6), 882–890. https://doi.org/10.1016/j.neurobiolaging.2006.12.012

Isaacs, B., & Kennie, A. T. (1973). The Set test as an aid to the detection of dementia in old people. *The British Journal of Psychiatry: The Journal of Mental Science*, *123*(575), 467–470.

Iverson, G. L., Hakulinen, U., Wäljas, M., Dastidar, P., Lange, R. T., Soimakallio, S., & Öhman, J. (2011). To exclude or not to exclude: White matter hyperintensities in diffusion tensor imaging research. *Brain Injury*, *25*(13–14), 1325–1332. https://doi.org/10.3109/02699052.2011.608409

Jagust, W. (2013). Vulnerable neural systems and the borderland of brain aging and neurodegeneration. *Neuron*, *77*(2), 219–234. https://doi.org/10.1016/j.neuron.2013.01.002

Jang, S. H., Kwon, Y. H., Lee, M. Y., Kim, J.-R., & Seo, J. P. (2016). Aging of the cingulum in the human brain: Preliminary study of a diffusion tensor imaging study. *Neuroscience Letters*, *610*, 213–217. https://doi.org/10.1016/j.neulet.2015.11.018

Jbabdi, S., & Johansen-Berg, H. (2011). Tractography: Where do we go from here? *Brain Connectivity*, *1*(3), 169–183. https://doi.org/10.1089/brain.2011.0033

Ji, F., Pasternak, O., Liu, S., Loke, Y. M., Choo, B. L., Hilal, S., … Zhou, J. (2017). Distinct white matter microstructural abnormalities and extracellular water increases relate to cognitive impairment in Alzheimer's disease with and without cerebrovascular disease. *Alzheimer's Research & Therapy*, *9*(1), 63. https://doi.org/10.1186/s13195-017-0292-4

Ji, F., Pasternak, O., Ng, K. K., Chong, J. S. X., Liu, S., Zhang, L., … Zhou, J. H. (2019). White matter microstructural abnormalities and default network degeneration are associated with early memory deficit in Alzheimer's disease continuum. *Scientific Reports*, *9*(1), 4749. https://doi.org/10.1038/s41598-019-41363-2

Jiang, J., Paradise, M., Liu, T., Armstrong, N. J., Zhu, W., Kochan, N. A., … Wen, W. (2018). The association of regional white matter lesions with cognition in a community-based cohort of older individuals. *NeuroImage: Clinical*, *19*, 14–21. https://doi.org/10.1016/j.nicl.2018.03.035

Jones, D. K., Christiansen, K. F., Chapman, R. J., & Aggleton, J. P. (2013). Distinct subdivisions of the cingulum bundle revealed by diffusion MRI fibre tracking: Implications for neuropsychological investigations. *Neuropsychologia*, *51*(1), 67. https://doi.org/10.1016/j.neuropsychologia.2012.11.018

Jones, Derek K., & Cercignani, M. (2010). Twenty-five pitfalls in the analysis of diffusion MRI data. *NMR in Biomedicine*, *23*(7), 803–820. https://doi.org/10.1002/nbm.1543

Kantarci, K., Senjem, M. L., Avula, R., Zhang, B., Samikoglu, A. R., Weigand, S. D., … Jack, C. R. (2011). Diffusion tensor imaging and cognitive function in older adults with no dementia. *Neurology*, *77*(1), 26–34. https://doi.org/10.1212/WNL.0b013e31822313dc

Klawiter, E. C., Schmidt, R. E., Trinkaus, K., Liang, H.-F., Budde, M. D., Naismith, R. T., … Benzinger, T. L. (2011). Radial diffusivity predicts demyelination in ex vivo multiple sclerosis spinal cords. *NeuroImage*, *55*(4), 1454–1460. https://doi.org/10.1016/j.neuroimage.2011.01.007

Kurki, T. J. I., & Heiskanen, L. A. A. (2018). Diffusion parameters of the core of cingulum are associated with age-related ventricular enlargement: A diffusion tensor tractography study. *Neuroradiology*, *60*(10), 1013–1018. https://doi.org/10.1007/s00234-018-2068-3

Lange, R. T., Shewchuk, J. R., Heran, M. K. S., Rauscher, A., Jarrett, M., Brubacher, J. R., & Iverson, G. L. (2014). To exclude or not to exclude: Further examination of the influence of white matter hyperintensities in diffusion tensor imaging research. *Journal of Neurotrauma*, *31*(2), 198–205. https://doi.org/10.1089/neu.2013.2866

Lawes, I. N. C., Barrick, T. R., Murugam, V., Spierings, N., Evans, D. R., Song, M., & Clark, C. A. (2008). Atlas-based segmentation of white matter tracts of the human brain using diffusion tensor tractography and comparison with classical dissection. *NeuroImage*, *39*(1), 62–79. https://doi.org/10.1016/j.neuroimage.2007.06.041

Leeuw, F.-E. de, Groot, J. C. de, Achten, E., Oudkerk, M., Ramos, L. M. P., Heijboer, R., … Breteler, M. M. B. (2001). Prevalence of cerebral white matter lesions in elderly people: A population based magnetic resonance imaging study. The Rotterdam Scan Study. *Journal of Neurology, Neurosurgery & Psychiatry*, *70*(1), 9–14. https://doi.org/10.1136/jnnp.70.1.9

Leote, J., Nunes, R. G., Cerqueira, L., Loução, R., & Ferreira, H. A. (2018). Reconstruction of white matter fibre tracts using diffusion kurtosis tensor imaging at 1.5T: Pre-surgical planning in patients with gliomas. *European Journal of Radiology Open*, *5*, 20–23. https://doi.org/10.1016/j.ejro.2018.01.002

Leritz, E. C., Shepel, J., Williams, V. J., Lipsitz, L. A., McGlinchey, R. E., Milberg, W. P., & Salat, D. H. (2014). Associations between T1 white matter lesion volume and regional white matter microstructure in aging. *Human Brain Mapping*, *35*(3), 1085–1100. https://doi.org/10.1002/hbm.22236

Lockhart, S. N., & DeCarli, C. (2014). Structural imaging measures of brain aging. *Neuropsychology Review*, *24*(3), 271–289. https://doi.org/10.1007/s11065-014-9268-3

Lyall, A. E., Pasternak, O., Robinson, D. G., Newell, D., Trampush, J. W., Gallego, J. A., … Szeszko, P. R. (2018). Greater Extracellular Free Water in First-Episode Psychosis Predicts Better Neurocognitive Functioning. *Molecular psychiatry*, *23*(3), 701–707. https://doi.org/10.1038/mp.2017.43

Madden, D. J., Bennett, I. J., Burzynska, A., Potter, G. G., Chen, N., & Song, A. W. (2012). Diffusion tensor imaging of cerebral white matter integrity in cognitive aging. *Biochimica et Biophysica Acta (BBA) - Molecular Basis of Disease*, *1822*(3), 386–400. https://doi.org/10.1016/j.bbadis.2011.08.003

Maier-Hein, K. H., Neher, P. F., Houde, J.-C., Côté, M.-A., Garyfallidis, E., Zhong, J., … Descoteaux, M. (2017). The challenge of mapping the human connectome based on diffusion tractography. *Nature Communications*, *8*(1), 1349. https://doi.org/10.1038/s41467-017-01285-x

Maillard, P., Fletcher, E., Harvey, D., Carmichael, O., Reed, B., Mungas, D., & DeCarli, C. (2011). White matter hyperintensity penumbra. *Stroke*, *42*(7), 1917–1922. https://doi.org/10.1161/STROKEAHA.110.609768

Maillard, P., Fletcher, E., Lockhart, S. N., Roach, A. E., Reed, B., Mungas, D., … Carmichael, O. (2014). White Matter Hyperintensities and their Penumbra Lie Along a Continuum of Injury In The Aging Brain. *Stroke; a journal of cerebral circulation*, *45*(6), 1721–1726. https://doi.org/10.1161/STROKEAHA.113.004084

Maillard, P., Fletcher, E., Singh, B., Martinez, O., Johnson, D. K., Olichney, J. M., … DeCarli, C. (2019). Cerebral white matter free water: A sensitive biomarker of cognition and function. *Neurology*, *92*(19), e2221–e2231. https://doi.org/10.1212/WNL.0000000000007449

Maillard, P., Mitchell, G. F., Himali, J. J., Beiser, A., Fletcher, E., Tsao, C. W., … DeCarli, C. (2017). Aortic Stiffness, Increased White Matter Free Water, and Altered Microstructural Integrity: A Continuum of Injury. *Stroke*, *48*(6), 1567–1573. https://doi.org/10.1161/STROKEAHA.116.016321

Maniega, S. M., Valdés Hernández, M. C., Clayden, J. D., Royle, N. A., Murray, C., Morris, Z., … Wardlaw, J. M. (2015). White matter hyperintensities and normal-appearing white matter integrity in the aging brain. *Neurobiology of Aging*, *36*(2), 909–918. https://doi.org/10.1016/j.neurobiolaging.2014.07.048

Meier-Ruge, W., Ulrich, J., Brühlmann, M., & Meier, E. (1992). Age-related white matter atrophy in the human brain. *Annals of the New York Academy of Sciences*, *673*, 260–269.

Metzler-Baddeley, C., Jones, D. K., Steventon, J., Westacott, L., Aggleton, J. P., & O'Sullivan, M. J. (2012). Cingulum Microstructure Predicts Cognitive Control in Older Age and Mild Cognitive Impairment. *Journal of Neuroscience*, *32*(49), 17612–17619. https://doi.org/10.1523/JNEUROSCI.3299-12.2012

Oestreich, L. K. L., Pasternak, O., Shenton, M. E., Kubicki, M., Gong, X., McCarthy-Jones, S., & Whitford, T. J. (2016). Abnormal white matter microstructure and increased extracellular free-water in the cingulum bundle associated with delusions in chronic schizophrenia. *NeuroImage: Clinical*, *12*, 405–414. https://doi.org/10.1016/j.nicl.2016.08.004

Ofori, E., Krismer, F., Burciu, R. G., Pasternak, O., McCracken, J. L., Lewis, M. M., … Vaillancourt, D. E. (2017). Free water improves detection of changes in the substantia nigra in parkinsonism: A multisite study. *Movement Disorders: Official Journal of the Movement Disorder Society*, *32*(10), 1457–1464. https://doi.org/10.1002/mds.27100

Papadaki, E., Kavroulakis, E., Kalaitzakis, G., Karageorgou, D., Makrakis, D., Maris, T. G., & Simos, P. G. (2019). Age-related deep white matter changes in myelin and water content: A T2 relaxometry study. *Journal of Magnetic Resonance Imaging: JMRI*. https://doi.org/10.1002/jmri.26707

Pasternak, O., Shenton, M. E., & Westin, C.-F. (2012). Estimation of extracellular volume from regularized multi-shell diffusion MRI. *Medical Image Computing and Computer-Assisted Intervention: MICCAI ... International Conference on Medical Image Computing and Computer-Assisted Intervention*, *15*(Pt 2), 305–312.

Pasternak, O., Sochen, N., Gur, Y., Intrator, N., & Assaf, Y. (2009). Free water elimination and mapping from diffusion MRI. *Magnetic Resonance in Medicine*, *62*(3), 717–730. https://doi.org/10.1002/mrm.22055

Pasternak, O., Westin, C.-F., Bouix, S., Seidman, L. J., Goldstein, J. M., Woo, T.-U. W., … Kubicki, M. (2012). Excessive extracellular volume reveals a neurodegenerative pattern in schizophrenia onset. *The Journal of Neuroscience: The Official Journal of the Society for Neuroscience*, *32*(48), 17365–17372. https://doi.org/10.1523/JNEUROSCI.2904-12.2012

Pelletier, A., Periot, O., Dilharreguy, B., Hiba, B., Bordessoules, M., Chanraud, S., … Catheline, G. (2015). Age-Related Modifications of Diffusion Tensor Imaging Parameters and White Matter Hyperintensities as Inter-Dependent Processes. *Frontiers in Aging Neuroscience*, *7*, 255. https://doi.org/10.3389/fnagi.2015.00255

Peters, A. (2002). Structural changes in the normally aging cerebral cortex of primates. *Progress in Brain Research*, *136*, 455–465.

Pfefferbaum, A., & Sullivan, E. V. (2003). Increased brain white matter diffusivity in normal adult aging: Relationship to anisotropy and partial voluming. *Magnetic Resonance in Medicine*, *49*(5), 953–961. https://doi.org/10.1002/mrm.10452

Promjunyakul, N.-O., Lahna, D. L., Kaye, J. A., Dodge, H. H., Erten-Lyons, D., Rooney, W. D., & Silbert, L. C. (2016). Comparison of cerebral blood flow and structural penumbras in relation to white matter hyperintensities: A multi-modal magnetic resonance imaging study. *Journal of Cerebral Blood Flow and Metabolism: Official Journal of the International Society of Cerebral Blood Flow and Metabolism*, *36*(9), 1528–1536. https://doi.org/10.1177/0271678X16651268

Radloff, L. S. (1977). The CES-D Scale: A Self-Report Depression Scale for Research in the General Population. *Applied Psychological Measurement*, *1*(3), 385–401. https://doi.org/10.1177/014662167700100306

Reginold, W., Itorralba, J., Luedke, A. C., Fernandez-Ruiz, J., Reginold, J., Islam, O., & Garcia, A. (2016). Tractography at 3T MRI of Corpus Callosum Tracts Crossing White Matter Hyperintensities. *American Journal of Neuroradiology*, *37*(9), 1617–1622. https://doi.org/10.3174/ajnr.A4788

Reginold, William, Sam, K., Poublanc, J., Fisher, J., Crawley, A., & Mikulis, D. J. (2018). Impact of white matter hyperintensities on surrounding white matter tracts. *Neuroradiology*, *60*(9), 933–944. https://doi.org/10.1007/s00234-018-2053-x

Rheault, F., Houde, J.-C., & Descoteaux, M. (2017). Visualization, Interaction and Tractometry: Dealing with Millions of Streamlines from Diffusion MRI Tractography. *Frontiers in Neuroinformatics*, *11*, 42. https://doi.org/10.3389/fninf.2017.00042

Rydhög, A. S., Szczepankiewicz, F., Wirestam, R., Ahlgren, A., Westin, C.-F., Knutsson, L., & Pasternak, O. (2017). Separating blood and water: Perfusion and free water elimination from diffusion MRI in the human brain. *NeuroImage*, *156*, 423–434. https://doi.org/10.1016/j.neuroimage.2017.04.023

Sala, S., Agosta, F., Pagani, E., Copetti, M., Comi, G., & Filippi, M. (2012). Microstructural changes and atrophy in brain white matter tracts with aging. *Neurobiology of Aging*, *33*(3), 488-498.e2. https://doi.org/10.1016/j.neurobiolaging.2010.04.027

Salminen, L. E., Conturo, T. E., Bolzenius, J. D., Cabeen, R. P., Akbudak, E., & Paul, R. H. (2016). REDUCING CSF PARTIAL VOLUME EFFECTS TO ENHANCE DIFFUSION TENSOR IMAGING METRICS OF BRAIN MICROSTRUCTURE. *Technology and innovation*, *18*(1), 5–20. https://doi.org/10.21300/18.1.2016.5

Schmidt, P., Gaser, C., Arsic, M., Buck, D., Förschler, A., Berthele, A., … Mühlau, M. (2012). An automated tool for detection of FLAIR-hyperintense white-matter lesions in Multiple Sclerosis. *NeuroImage*, *59*(4), 3774–3783. https://doi.org/10.1016/j.neuroimage.2011.11.032

Schmierer, K., Wheeler-Kingshott, C. A. M., Tozer, D. J., Boulby, P. A., Parkes, H. G., Yousry, T. A., … Miller, D. H. (2008). Quantitative magnetic resonance of postmortem multiple sclerosis brain before and after fixation. *Magnetic Resonance in Medicine*, *59*(2), 268–277. https://doi.org/10.1002/mrm.21487

Seiler, S., Fletcher, E., Hassan-Ali, K., Weinstein, M., Beiser, A., Himali, J. J., … Maillard, P. (2018). Cerebral tract integrity relates to white matter hyperintensities, cortex volume, and cognition. *Neurobiology of Aging*, *72*, 14–22. https://doi.org/10.1016/j.neurobiolaging.2018.08.005

Sepehrband, F., Cabeen, R. P., Choupan, J., Barisano, G., Law, M., Toga, A. W., & Alzheimer's Disease Neuroimaging Initiative. (2019). Perivascular space fluid contributes to diffusion tensor imaging changes in white matter. *NeuroImage*, *197*, 243–254. https://doi.org/10.1016/j.neuroimage.2019.04.070

Sexton, C. E., Mackay, C. E., Lonie, J. A., Bastin, M. E., Terrière, E., O'Carroll, R. E., & Ebmeier, K. P. (2010). MRI correlates of episodic memory in Alzheimer's disease, mild cognitive impairment, and healthy aging. *Psychiatry Research*, *184*(1), 57–62. https://doi.org/10.1016/j.pscychresns.2010.07.005

Sexton, C. E., Walhovd, K. B., Storsve, A. B., Tamnes, C. K., Westlye, L. T., Johansen-Berg, H., & Fjell, A. M. (2014). Accelerated changes in white matter microstructure during aging: A longitudinal diffusion tensor imaging study. *The Journal of Neuroscience: The Official Journal of the Society for Neuroscience*, *34*(46), 15425–15436. https://doi.org/10.1523/JNEUROSCI.0203-14.2014

Smith, S. M. (2002). Fast robust automated brain extraction. *Human Brain Mapping*, *17*(3), 143–155. https://doi.org/10.1002/hbm.10062

Song, S.-K., Sun, S.-W., Ju, W.-K., Lin, S.-J., Cross, A. H., & Neufeld, A. H. (2003). Diffusion tensor imaging detects and differentiates axon and myelin degeneration in mouse optic nerve after retinal ischemia. *NeuroImage*, *20*(3), 1714–1722. https://doi.org/10.1016/j.neuroimage.2003.07.005

Stadlbauer, A., Salomonowitz, E., Strunk, G., Hammen, T., & Ganslandt, O. (2008). Age-related degradation in the central nervous system: Assessment with diffusion-tensor imaging and quantitative fiber tracking. *Radiology*, *247*(1), 179–188. https://doi.org/10.1148/radiol.2471070707

Sun, S.-W., Neil, J. J., Liang, H.-F., He, Y. Y., Schmidt, R. E., Hsu, C. Y., & Song, S.-K. (2005). Formalin fixation alters water diffusion coefficient magnitude but not anisotropy in infarcted brain. *Magnetic Resonance in Medicine*, *53*(6), 1447–1451. https://doi.org/10.1002/mrm.20488

Svärd, D., Nilsson, M., Lampinen, B., Lätt, J., Sundgren, P. C., Stomrud, E., … Westen, D. van. (2017). The effect of white matter hyperintensities on statistical analysis of diffusion tensor imaging in cognitively healthy elderly and prodromal Alzheimer's disease. *PLOS ONE*, *12*(9), e0185239. https://doi.org/10.1371/journal.pone.0185239

Tang, Y., Nyengaard, J. R., Pakkenberg, B., & Gundersen, H. J. G. (1997). Age-Induced White Matter Changes in the Human Brain: A Stereological Investigation. *Neurobiology of Aging*, *18*(6), 609–615. https://doi.org/10.1016/S0197-4580(97)00155-3

Tanner, J. J., Amin, M., Hardcastle, C., Parvataneni, H., Vaillancourt, D. E., Mareci, T. H., & Price, C. C. (2019). Better Brain and Cognition Prior to Surgery Is Associated With Elevated Postoperative Brain Extracellular Free-Water in Older Adults. *Frontiers in Aging Neuroscience*, *11*. https://doi.org/10.3389/fnagi.2019.00117

Theaud, G., Dilharreguy, B., Catheline, G., & Descoteaux, M. (2016). *Impact of white matter hyperintensities on tractography*. Présenté à ISMRM.

Theaud, G., Houde, J.-C., Boré, A., Rheault, F., Morency, F., & Descoteaux, M. (2019). TractoFlow: A robust, efficient and reproducible diffusion MRI pipeline leveraging Nextflow & Singularity. *BioRxiv*, 631952. https://doi.org/10.1101/631952

Tournier, J.-D., Calamante, F., & Connelly, A. (2007). Robust determination of the fibre orientation distribution in diffusion MRI: Non-negativity constrained super-resolved spherical deconvolution. *NeuroImage*, *35*(4), 1459–1472. https://doi.org/10.1016/j.neuroimage.2007.02.016

Vernooij, M. W., de Groot, M., van der Lugt, A., Ikram, M. A., Krestin, G. P., Hofman, A., … Breteler, M. M. B. (2008). White matter atrophy and lesion formation explain the loss of structural integrity of white matter in aging. *NeuroImage*, *43*(3), 470–477. https://doi.org/10.1016/j.neuroimage.2008.07.052

Vernooij, Meike W., Ikram, M. A., Vrooman, H. A., Wielopolski, P. A., Krestin, G. P., Hofman, A., … Breteler, M. M. B. (2009). White matter microstructural integrity and cognitive function in a general elderly population. *Archives of General Psychiatry*, *66*(5), 545–553. https://doi.org/10.1001/archgenpsychiatry.2009.5

Vinke, E. J., de Groot, M., Venkatraghavan, V., Klein, S., Niessen, W. J., Ikram, M. A., & Vernooij, M. W. (2018). Trajectories of imaging markers in brain aging: The Rotterdam Study. *Neurobiology of Aging*, *71*, 32–40. https://doi.org/10.1016/j.neurobiolaging.2018.07.001

Vos, S. B., Jones, D. K., Viergever, M. A., & Leemans, A. (2011). Partial volume effect as a hidden covariate in DTI analyses. *NeuroImage*, *55*(4), 1566–1576. https://doi.org/10.1016/j.neuroimage.2011.01.048

Wang, Y., Wang, Q., Haldar, J. P., Yeh, F.-C., Xie, M., Sun, P., … Song, S.-K. (2011). Quantification of increased cellularity during inflammatory demyelination. *Brain: A Journal of Neurology*, *134*(Pt 12), 3590–3601. https://doi.org/10.1093/brain/awr307

Wiseman, S. J., Booth, T., Ritchie, S. J., Cox, S. R., Muñoz Maniega, S., Valdés Hernández, M. D. C., … Bastin, M. E. (2018). Cognitive abilities, brain white matter hyperintensity volume, and structural network connectivity in older age. *Human Brain Mapping*, *39*(2), 622–632. https://doi.org/10.1002/hbm.23857

Yang, Z., Wen, W., Jiang, J., Crawford, J. D., Reppermund, S., Levitan, C., … Sachdev, P. S. (2016). Age-associated differences on structural brain MRI in nondemented individuals from 71 to 103 years. *Neurobiology of Aging*, *40*, 86–97. https://doi.org/10.1016/j.neurobiolaging.2016.01.006

Yoshita, M., Fletcher, E., Harvey, D., Ortega, M., Martinez, O., Mungas, D. M., … DeCarli, C. S. (2006). Extent and distribution of white matter hyperintensities in normal aging, MCI, and AD. *Neurology*, *67*(12), 2192–2198. https://doi.org/10.1212/01.wnl.0000249119.95747.1f

10. Tables

Table 1. Characteristics of the participants,12-year cognitive decline and volumetric variables

	Low WMH		High WMH		
N = 45	**22**		**23**		*U or* χ^2
Sociodemographic variables	median [IQR]		median [IQR]		
Age [a]	78.8	[3.5]	84.3	[8.6]	**129***
Gender (male/female) [b]	6 / 17		11 / 13		1.948
High level of education % [b c]	30.4		41.7		0.731
Behavioral variables					
MMSE [a]	27.5	[2.3]	27.4	[1.9]	318
CES-D [a]	7.0	[2.1]	8.5	[7]	295.5
Vascular risk factors					
BMI (kg/m^2) [a]	25.8	[5.3]	25.1	[5.4]	254
Diabetes % [b]	4.5		16.7		1.622
Hypertension % [b]	36.0		43.0		1.329
Verbal fluency decline					
IST at 15 seconds [a]	-0.434	[0.05]	-0.430	[0.07]	205
Volumetric variables					
WMH volume ml [a]	0.98	[0.81]	23.93	[14.2]	**552***
White matter volume (% TIV) [a]	29.8	[3.0]	27.3	[2.8]	110
Cingulum bundle volume (% TIV) [a]	0.45	[0.59]	0.39	[0.51]	325
WMH volume within Cingulum (%) [a d]	0.01	[0.02]	4.8	[4.3]	**106***

MMSE, Mini Mental State Examination; BMI, Body Mass Index; CES-D, Center for Epidemiologic Studies-Depression scale; IST, Isaacs Set Test; WMH, White Matter Hyperintensity.

* $p < 0.05$

[a] Mann-Whitney U-test, U value

[b] Pearson Chi-squares test, χ^2 value

[c] Long secondary school and university level

[d] Express in % of cingulum white matter volume

Table 2. Cingulum diffusion metrics before (conventional DTI) and after FW-correction and % of change between both metrics for each group

Low WMH group				
Cingulum diffusion measures	**DTI** median [IQR]	**FW-correction** median [IQR]	**Z**	**% Change** median [IQR]
FA	0.535 [0.060]	0.581 [0.054]	-3.15*	7.79 [4.8]
MD (10^{-3} mm^2/s)	0.779 [0.036]	0.750 [0.030]	-2.86*	-1.80 [1.1]
AD (10^{-3} mm^2/s)	1.300 [0.120	1.280 [0.11]	-1.46*	-1.33 [0.8]
RD (10^{-3} mm^2/s)	0.503 [0.052]	0.496 [0.046]	-3.32*	-3.24 [2.1]
FW	-	0.136 [0.013]		

High WMH group				
Cingulum diffusion measures	**DTI** median [IQR]	**FW-correction** median [IQR]	**Z**	**% Change** median [IQR]
FA	0.504 [0.057]	0.541 [0.056]	-3.27*	7.15 [4.1]
MD (10^{-3} mm^2/s)	0.784 [0.045]	0.770 [0.036]	-2.95*	-1.75 [1.2]
AD (10^{-3} mm^2/s)	1.290 [0.095]	1.270 [0.08]	-1.41*	-1.51 [1.0]
RD (10^{-3} mm^2/s)	0.536 [0.039]	0.517 [0.040]	-3.38*	-3.48 [2.1]
FW	-	0.147 [0.012]		

* $p<0.05$ FDR corrected,

Wilcoxon Paired sample tests, Z

Table 3. Relationship between cingulum diffusion metrics before (conventional DTI) and after FW-correction and verbal fluency score (IST)

	DTI				FW-correction				
Low WMH group	FA	MD	AD	RD	FAt	MDt	ADt	RDt	Free Water
	ρ	ρ	ρ	ρ	ρ	ρ	ρ	ρ	ρ
IST 15s	0.213	0.029	-0.245	-0.162	0.224	-0.030	**-0.295***	-0.156	**-0.431***
High WMH group	FA	MD	AD	RD	FAt	MDt	ADt	RDt	Free water
	ρ	ρ	ρ	ρ	ρ	ρ	ρ	ρ	ρ
IST 15s	**0.299***	-0.065	0.079	-0.203	**0.358***	-0.089	0.130	**-0.337***	**-0.393***

ρ, Rho coefficient of partial spearman correlations adjusted for age, cingulum WM and WMH volumes

* $p < 0.05$ FDR corrected

11. Figures Legends

Figure 1. In yellow the white matter hyperintensity (WMH) lesion. In A, the peak directions extracted from the fODF are not impacted by the WMH. In B, the lesion doesn't impact the reconstruction of the Corpus Callusum tracts.

Figure 2. Tracts that stop in WMH represented in blue (A) without WMH mask correction and (B) with WMH mask correction. With mask correction, less erroneous tracts were observed.

Figure 3. Left and right cingulum template used to extract the cingulum tract for each participant (A); Example of the cingulum bundle obtained for one subject displayed on the corresponding T1-weighted image (B). Along the fibers, color represents the RGB scale.

Figure 4. Cingulum diffusion metrics after FW-correction for the (a) low and the (b) high WMH groups (FLAIR axial view). Boxplot charts of the difference in FW-corrected cingulum diffusion metrics between the low (light grey) and the high WMH groups (dark grey) for (c) fractional anisotropy (FAt), (d) mean diffusivity (MDt), (e) radial diffusivity (RDt), (f) axial diffusivity (ADt) and (g) fraction of free-water (FW) values.

Figures

Figure 1

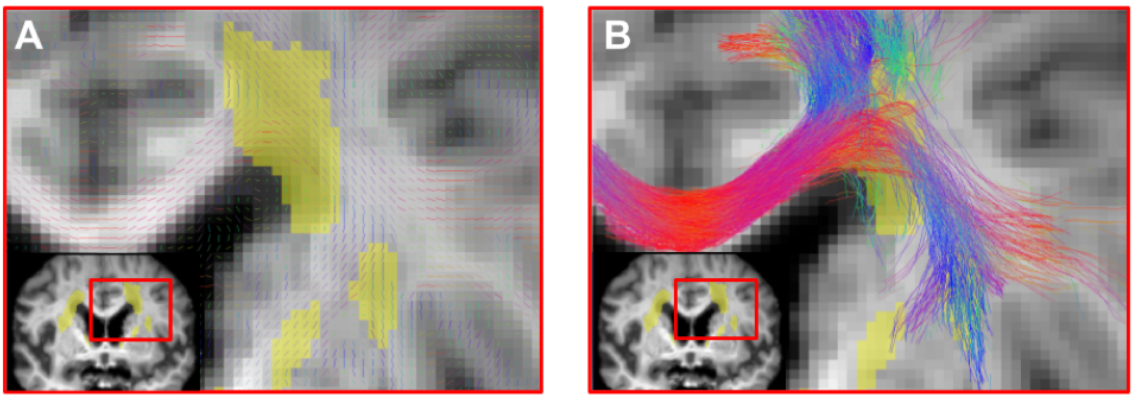

Figure 2

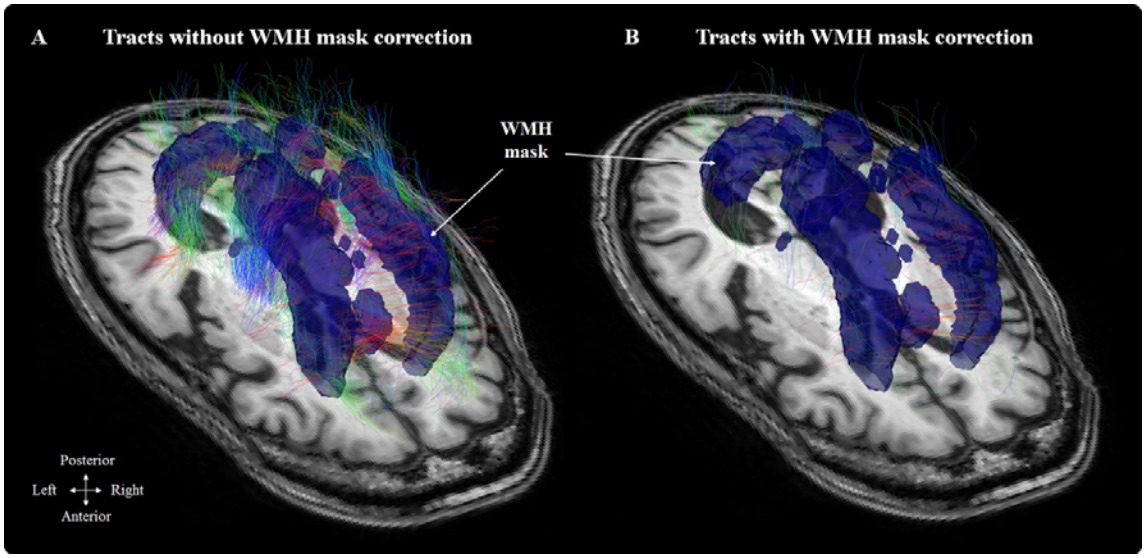
A
Tracts without WMH mask correction
B
Tracts with WMH mask correction
WMH
mask
Posterior
Left
Right
Anterior

Figure 3

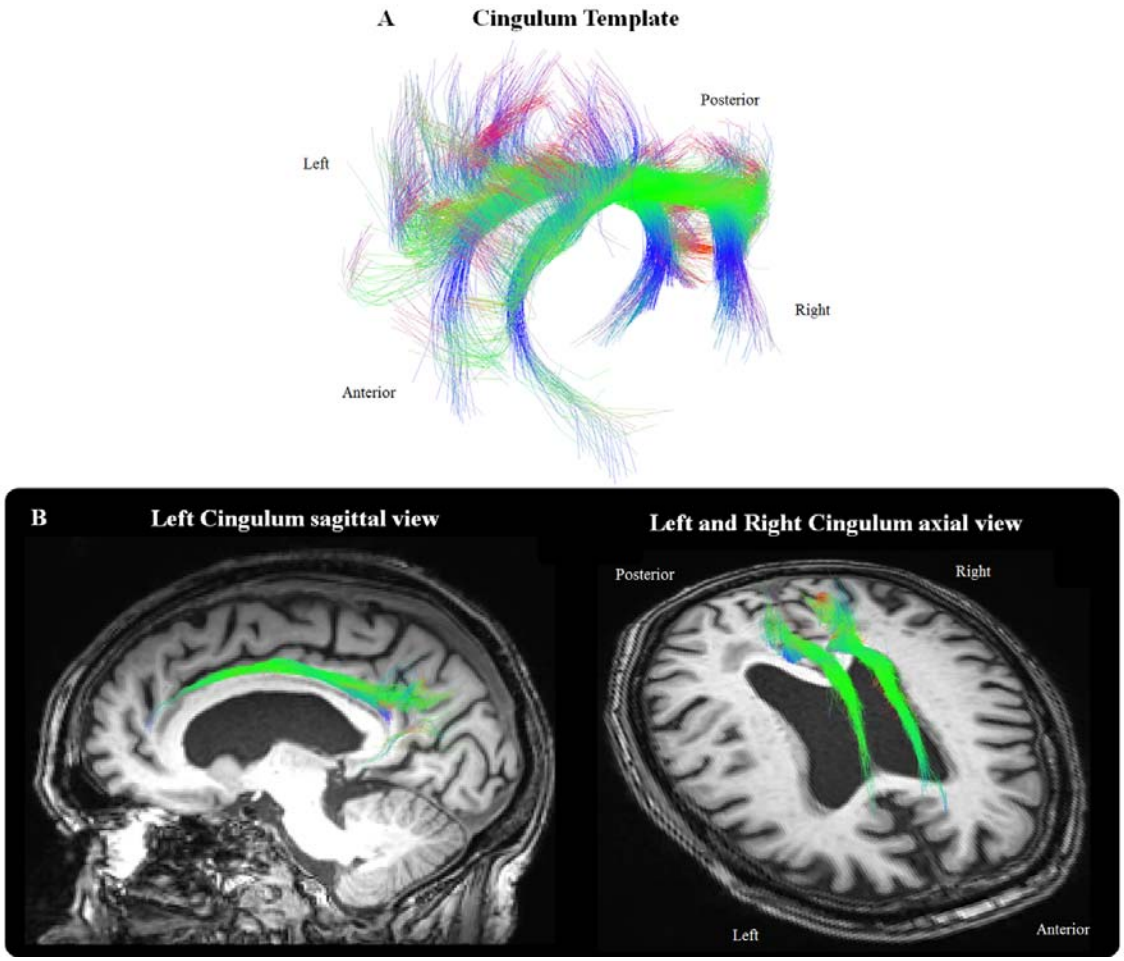
A
Cingulum Template
Posterior
Left
Right
Anterior
B
Left Cingulum sagittal view
Left and Right Cingulum axial view
Posterior
Right
Left
Anterior

Figure 4

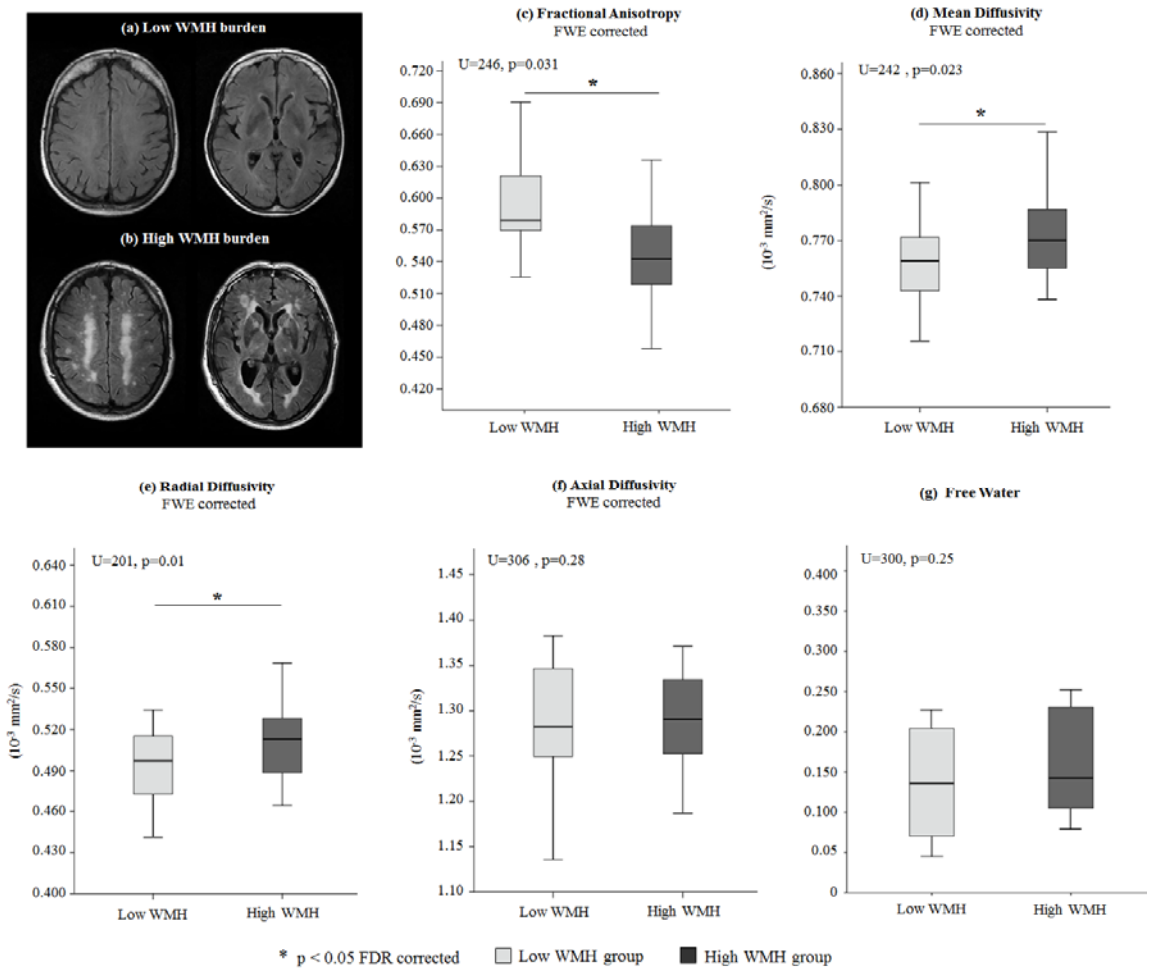
(a) Low WMH burden
(b) High WMH burden
(c) Fractional Anisotropy
FWE corrected
U=246, p=0.031
*
0.720
0.690
0.660
0.630
0.600
0.570
0. 540
0.510
0.480
0.450
0.420
Low WMH
High WMH
(d) Mean Diffusivity
FWE corrected
U=242 , p=0.023
*
0.860
0.830
0.800
0.770
0.740
0.710
0.680
(10-3 mm2/s)
Low WMH
High WMH
(e) Radial Diffusivity
FWE corrected
U=201, p=0.01
*
0.640
0.610
0.580
0.550
0.520
0.490
0.460
0.430
0.400
(10-3 mm2/s)
Low WMH
High WMH
(f) Axial Diffusivity
FWE corrected
U=306 , p=0.28
1.45
1.40
1.35
1.30
1.25
1.20
1.15
1.10
(10-3 mm2/s)
Low WMH
High WMH
(g) Free Water
U=300, p=0.25
0.400
0.350
0.300
0.250
0.200
0.150
0.100
0.05
0
Low WMH
High WMH
* p < 0.05 FDR corrected
Low WMH group
High WMH group