TITLE: The hierarchical organization of human praxis: A lesion-connectome mapping study of limb and oral apraxias

RUNNING TITLE: Neuroanatomy of limb and oral apraxias

AUTHORS: Yoshiyuki Nishio [1)], Ryo Itabashi [2)], Yuka Kataoka [3)], Yukako Yazawa [4)], Etsuro Mori [1)]

AFFILIATIONS: 1) Department of Behavioral Neurology and Neuropsychiatry, The University of Osaka, Suita, Japan; 2) Division of Neurology and Gerontology, Department of Internal Medicine, Iwate Medical University, Yahaba, Japan; 3) Department of Rehabilitation Medicine, Kohnan Hospital, Sendai, Japan; 4) Department of Stroke Neurology, Kohnan Hospital, Sendai, Japan

KEYWORDS: Apraxia, Limb apraxia, Buccofacial apraxia, Connectome, Lesion-symptom mapping, Motor control

CORRESPONDENCE TO: Yoshiyuki Nishio (nishiokov@gmail.com)

ABSTRACT

The neural architecture underlying apraxias remains a complex puzzle. While primary motor cortices exhibit clear somatotopic organization, it is unclear whether this segregation extends to the higher-order networks governing skilled actions. Furthermore, the dissociation between verbal (apraxia of speech, AOS) and non-verbal (buccofacial apraxia, BFA) oral motor control remains debated. We investigated the neuroanatomical substrates of limb apraxia (LA), BFA, and AOS in 136 patients with

acute left-hemisphere ischemic stroke using voxel-based, region-of-interest-based, and connectome-based lesion-symptom mapping. Our results revealed a fundamental anatomical dissociation extending beyond simple effector specificity. LA was associated with damage to the inferior parietal lobule and widespread white matter disconnections, specifically involving intra-hemispheric temporo-parietal pathways and massive inter-hemispheric transcallosal fibers. In contrast, BFA was attributable to focal cortical lesions centered on the ventral precentral and postcentral gyri, without significant involvement of long-range white matter tracts. AOS showed no significant lesion overlap at the population level, suggesting a heterogenous etiology distinct from the premotor patterns of BFA. These findings indicate that LA and BFA differ not only in their effectors but in their network dependency: LA relies on a distributed, bilaterally integrated temporo-parietal network for multimodal action control, whereas BFA depends on localized proprioceptive-motor loops in the ventral sensorimotor cortex. This study provides a structural framework for the hierarchical organization of human praxis, distinguishing between distributed network disconnections and focal cortical dysfunctions.

INTRODUCTION

Clinical neurology has long recognized apraxias as a distinct class of motor disorders. These impairments of skilled action cannot be attributed to elementary motor deficits such as paresis or ataxia, and typically result from damage to the dominant fronto-parietal lobes[1,2]. Clinically, apraxias are categorized by the specific effectors involved: limb apraxia (LA) affects skilled movements of the upper extremities, while oral apraxias are subdivided into buccofacial apraxia (BFA) for non-verbal actions and apraxia of speech (AOS) for motor speech production. While the clinical phenomenology is well-documented, the underlying neural architecture remains elusive. Primate studies have established that fronto-parietal networks supporting complex motor control are organized into parallel pathways[3,4]. Crucially, while frontal motor cortices exhibit clear effector-specific somatotopic organization, it is unclear whether this segregation extends

to the higher-order parietal networks governing praxis. Lesion studies often contradict simple somatotopic principles[5,6]; for instance, LA typically affects bilateral limbs despite unilateral damage, leading to classical hypotheses of white matter disconnection rather than focal cortical dysfunction[7,8]. Furthermore, in the oral domain, the anatomical relationship between verbal (AOS) and non-verbal (BFA) control remains elusive, with debate persisting over whether they share common substrates or dissociate within the fronto-parietal network[9,10].

These discrepancies raise fundamental questions about the hierarchical organization of human action. Does the brain organize skilled movements strictly by effector (somatotopy), or does it rely on a hierarchy where some actions depend on distributed networks while others rely on focal modular loops? To resolve these uncertainties, we conducted a comprehensive lesion-symptom mapping analysis in 136 acute stroke patients, utilizing voxel-based, region-of-interest-based, and connectome-based approaches. We addressed three primary questions: (1) Is there a distinct somatotopic organization distinguishing limb from oral apraxias?; (2) To what extent do white matter disconnection mechanisms contribute to these phenotypes? ; and (3) Are the neural substrates for verbal and non-verbal oral motor control dissociated? By integrating lesion topography with structural disconnectivity, this study aims to provide a structural framework for the hierarchical organization of human praxis.

METHODS

Study population

Participants were retrospectively selected from a cohort of 2,146 consecutive patients with acute ischemic stroke admitted to Kohnan Hospital between April 2007 and March 2012. This cohort is identical to that described in our previous study[11]. Clinical and investigative data were prospectively collected and registered in a standardized

database. Diagnosis of ischemic stroke was confirmed by board-certified stroke neurologists based on clinical and neuroimaging findings.

Inclusion criteria were as follows: (1) first-ever stroke onset; (2) hospital admission within 7 days of onset; (3) isolated non-lacunar infarction restricted to the left middle cerebral artery territory, verified by MRI; (4) right-handedness; (5) native Japanese speaker; (6) no history of dementia; and (7) completion of a comprehensive neuropsychological evaluation by speech-language pathologists during hospitalization. Neuropsychological evaluations were indicated for patients exhibiting behavioral or language impairments interfering with daily activities. A total of 136 patients met these criteria (**Table 1**).

The study protocol was approved by the Kohnan Hospital Ethics Committee (2015-0107-04). According to the institutional review board policy, individual informed consent was waived due to the retrospective nature of the study. Instead, an opt-out approach was employed, and information regarding the study was publicly disclosed on the hospital website to provide patients with the opportunity to refuse participation. All participant data were anonymized before analysis to ensure patient confidentiality.

Behavioural assessments

All assessments were conducted by trained speech-language pathologists. The median interval between stroke onset and neuropsychological evaluation was 7 days [IQR: 5–10]. Patients were instructed to execute motor actions in response to verbal commands and imitation. For the purpose of lesion-symptom mapping, the diagnosis of each apraxia subtype was operationalized as a binary variable (present vs. absent) based on the criteria described below.

Limb Apraxia

LA was assessed using symbolic actions of the left upper limb (to avoid confounds from right hemiparesis). Tasks included communicative gestures (military salute, beckoning, waving goodbye) and pantomime of tool use (brushing teeth, combing hair, shaving). LA

was diagnosed based on the presence of distinct errors, including incorrect movement direction, abnormal hand configuration, or action substitution.

Buccofacial Apraxia

BFA was assessed through the execution of non-verbal oropharyngeal and facial movements (coughing, clicking the tongue, whistling). A diagnosis was made when patients failed to perform these actions or produced substitution errors on verbal command or imitation.

Apraxia of Speech

AOS was diagnosed based on specific speech characteristics observed during free conversation, cartoon description, repetition, and reading-aloud subtests of the Standard Language Test of Aphasia (SLTA)[12]. Diagnostic features included slow speech rate, distorted sound substitutions or additions, articulatory groping, lengthened intersegment durations, or syllable segmentation. Aphasia subtypes were also classified according to the SLTA.

Imaging procedures

Structural brain imaging was acquired using a 1.5-T scanner (Signa Excite, GE Medical Systems, Milwaukee, WI, USA). Lesions were identified on axial T2-weighted images (TR=3,000 ms; TE=80 ms; matrix=320×256; FOV=22×22 mm; thickness=6 mm; gap=2.0 mm) or FLAIR images (TR=8,002 ms; TE=126 ms; TI=2,000 ms; matrix=256×224; FOV=22×22 mm; thickness=6 mm; gap=2.0 mm). The median intervals between stroke onset and MRI, and between neuropsychological evaluation and MRI, were 9 days [IQR: 7–12] and 3 days [IQR: 1–6], respectively.

Native images and lesion masks were normalized to a standard T2-weighted or FLAIR template using a nonlinear transformation with enantiomorphic lesion-cost function masking[13]. The resulting images were resampled to 1-mm isotropic voxels.

Voxel- and Region-of-interest-based Lesion-Symptom Mapping

To delineate the neuroanatomical correlates of LA, BFA, and AOS, we performed both voxel-based lesion-symptom mapping (VLSM) and region-of-interest (ROI)-based lesion-symptom mapping (ROI-LSM) using the General Linear Model framework in the NiiStat toolbox (https://github.com/neurolabusc/NiiStat)[14].

For ROI-LSM, we calculated the percentage of lesioned tissue within each of the 65 left-hemisphere regions defined by the Johns Hopkins University grey and white matter atlas[15]. For VLSM, analysis was restricted to voxels damaged in at least 10 patients to ensure statistical power. We modeled the relationship between lesion location and behavioral deficits (presence/absence of apraxia) while controlling for total lesion volume as a nuisance regressor. Statistical significance was determined using the non-parametric Freedman-Lane permutation method (5,000 permutations)[16], with a family-wise error (FWE) corrected threshold of $p < 0.05$.

Connectome-based Lesion-Symptom Mapping

To quantify white matter network disruption, we employed connectome-based lesion-symptom mapping (CLSM) based on the "indirect structural disconnection" framework[17]. This method estimates structural disconnection by projecting individual lesion masks onto a normative healthy connectome, avoiding artifacts associated with tracking through pathological tissue.

Voxel-wise disconnection probability maps were generated using the Network Modification (NeMo) tool[18]. The reference tractography was derived from healthy individuals using advanced parameters (deterministic and probabilistic algorithms with SIFT2 re-weighting) to capture comprehensive white matter architecture. Statistical analysis of the disconnection maps followed the same procedure as VLSM: we assessed the association between disconnection severity at each voxel and behavioral

variables using NiiStat, with significance established at $p < 0.05$ (FWE-corrected, 5,000 permutations).

RESULTS

Clinical characteristics

Demographic and clinical characteristics are summarized in **Table 1** and **Supplementary Table 1**. Age did not significantly differ between patients with and without apraxias. Male prevalence was significantly higher in the BFA group compared to patients without apraxia ($p = 0.004$). Patients with apraxias presented with greater stroke severity, as indicated by significantly higher National Institutes of Health Stroke Scale (NIHSS) scores across all apraxia subtypes compared to the non-apraxia group ($p < 0.05$ for all comparisons). Given the high comorbidity among apraxia subtypes, over half of patients with one type also exhibited the others, we performed subgroup analyses on mutually exclusive groups (e.g., LA+/BFA- vs. LA-/BFA+ vs. LA+/BFA+) to disentangle their specific characteristics. NIHSS scores did not differ significantly among these mutually exclusive subgroups.

Regarding lesion volume, patients with LA and BFA had significantly larger lesions than those without apraxia ($p = 0.010$ and $p = 0.005$, respectively), whereas patients with AOS did not show a significant difference ($p = 0.12$). When comparing mutually exclusive oral apraxia groups, patients with BFA-/AOS+ had significantly smaller lesion volumes than those with BFA+/AOS- ($p = 0.009$).

Aphasia subtypes differed significantly between groups; notably, AOS was exclusively associated with Broca’s aphasia or pure AOS (AOS without aphasia). Stroke etiology (subtype) did not differ significantly across groups.

Voxel- and Region-of-interest-based Lesion-Symptom Mapping

Lesion distributions are illustrated in **Figure 1** and **Supplementary Figure 1**. The results of VLSM and ROI-LSM analyses are presented in **Figure 2** and **Table 2**.

Limb Apraxia

VLSM revealed that LA was associated with damage to both deep white matter and cortical structures in the posterior temporo-parietal region. Significant clusters were identified in the centrum semiovale, corresponding to the superior longitudinal fasciculus/arcuate fasciculus (SLF/AF), and in the white matter adjacent to the trigone of the lateral ventricle, corresponding to the forceps major and tapetum of the corpus callosum. Cortical involvement included the supramarginal gyrus, angular gyrus, and postcentral gyrus. ROI-LSM confirmed these findings, showing significant associations with the SLF/AF, posterior thalamic radiation, tapetum, supramarginal gyrus, angular gyrus, precuneus, and posterior temporal and occipital regions.

Buccofacial Apraxia

In contrast to the posterior pattern of LA, BFA was associated with anterior lesions centered on the ventral sensorimotor cortex. VLSM identified clusters in the mid-portion of the left precentral gyrus, extending to the inferior and middle frontal gyri and postcentral gyrus. ROI-LSM similarly implicated the precentral and postcentral gyri, middle and inferior frontal gyri, and the insula. ROI-LSM indicated involvement of the anterior corona radiata, sagittal stratum (corresponding to the inferior longitudinal and inferior fronto-occipital fasciculi), and the SLF/AF.

Apraxia of Speech

Neither VLSM nor ROI-LSM analyses revealed any suprathreshold voxels or regions significantly associated with AOS at the population level.

Connectome-based Lesion-Symptom Mapping

To clarify the structural disconnection mechanisms, we performed deterministic (**Figure 3**) and probabilistic (**Supplementary Figure 2**) CLSM analyses for LA and BFA. AOS was excluded from this analysis due to the absence of significant findings in the lesion-symptom mapping. Both tractography methods yielded anatomically consistent results.

Limb Apraxia

LA was characterized by extensive white matter disruption. In addition to localized disconnection in the left parieto-occipital regions (supramarginal, angular, and superior parietal gyri), we observed massive inter-hemispheric transcallosal disconnection. These disrupted callosal fibers traversed the splenium, connecting the left parieto-occipital cortex with the contralateral (right) posterior temporal, parietal, and occipital cortices.

Buccofacial Apraxia

Disconnection in BFA was highly localized, centered on the middle portion of the left (ipsilateral) postcentral gyrus. Unlike LA, BFA showed no significant involvement of long-range inter-hemispheric or widespread intra-hemispheric white matter pathways.

DISCUSSION

The Anterior-Posterior Dissociation in Praxis

This study demonstrates a fundamental neuroanatomical dissociation: LA is linked to posterior temporo-parietal networks, whereas BFA arises from anterior frontal lesions. This dichotomy resonates with classical behavioral neurology, where LA was frequently observed with Wernicke's aphasia and BFA with Broca's aphasia[6,7]. This neuroanatomical dissociation suggests that the difference between the two apraxias lies

more in functional levels than in motor effectors. While the parietal and frontal cortices cooperate for action execution, their roles differ fundamentally. The parietal cortex, extensively connected with occipital and temporal areas[19], subserves the online and predictive modulation of motor actions[20]. Consequently, LA affects upper limb actions that depend on multimodal, both visual and proprioceptive, sensory feedback supported by this posterior network. In contrast, the frontal cortex, specifically the premotor cortex, projects subcortically to the reticulospinal tracts[21,22] and stores complex motor repertoires[23,24]. Non-verbal orofacial actions rely heavily on intrinsic proprioceptive feedback rather than visual guidance [25,26]. Thus, BFA depends on a localized network of ventral motor and somatosensory cortices. Accordingly, the core functional impairment of BFA may correspond to limb-kinetic apraxia, an elusive disorder linked to premotor dysfunction in Geschwind's disconnection framework, often characterized by the loss of dexterity or kinetic melody[6,7].

Regarding LA, recent evidence supports the critical role of an extended network. A meta-analysis of lesion-symptom mapping studies demonstrated that critical cortical sites are centered at the supramarginal gyrus but extend into the intraparietal sulcus and posterior temporal cortex[27]. Furthermore, the etiology of LA highlights the importance of white matter disconnection. Pure ideomotor-type LA is rarely observed in neurodegenerative disorders, where cortical atrophy is diffuse but connections often remain intact; instead, limb-kinetic or conceptual apraxia typically dominates in these conditions[28,29]. This suggests that axonal disconnections in the temporo-parietal lobe, alongside inferior parietal cortical lesions, play a significant role in the development of stroke-induced LA, rather than diffuse cortical damage alone[5].

While previous studies have noted the frequent coexistence of LA and BFA[6,7,30], a closer inspection of lesion distributions offers a structural explanation for this comorbidity. We observed that the superior longitudinal fasciculus (SLF/AF) was frequently damaged in patients exhibiting both LA and BFA, but was spared in most patients with isolated LA (**Supplementary Figure 1**; **Supplementary Figure 3**). This suggests that the concurrence of LA and BFA may be driven by parieto-frontal disconnection via SLF/AF damage in large strokes. Taken together, these findings imply

distinct mechanisms for BFA depending on the context: one type associated with extensive disconnection (when co-occurring with LA), and another attributable to circumscribed frontal cortical lesions (isolated BFA).

Revisiting Disconnection Mechanisms in Limb Apraxia

Liepmann's seminal model conceptualized LA as a disconnection syndrome. He postulated that "movement formulas" generated in the posterior cortex must be transmitted to anterior motor regions for execution[2,8]. Following this tradition, the classical disconnection framework has largely focused on the disruption of intra-hemispheric fronto-parietal pathways (i.e., the SLF/AF)[2,7]. Our findings partly challenge and refine this view. While our VLSM analysis implicated the SLF/AF, the CLSM revealed that the core structural disruption lies not only in fronto-parietal connections but in intra-parietal and inter-hemispheric networks. Functionally, the left supramarginal gyrus (SMG) is thought to store the spatio-temporal kinematic patterns of skilled actions, serving as a forward prediction model[2,31]. This region operates in concert with the superior parietal lobule (online visuomotor control) and the posterior temporal cortex (visual templates of posture)[20,32]. The deep white matter lesions observed in our study likely sever the short association fibers linking these posterior modules, disrupting the integration of multimodal sensory feedback required for limb praxis.

In addition to intra-hemispheric disconnections within the temporo-parietal cortices, the present CLSM analysis revealed significant inter-hemispheric disconnections between bilateral temporo-parietal cortices in LA. This disruption is presumably caused by lesions in the white matter regions surrounding the trigone of the lateral ventricle, corresponding to the tapetum of the corpus callosum and the forceps major of the splenium (**Supplementary Figure 3**). Functionally, these anatomical findings have important implications for the lateralization of praxis. The left inferior parietal cortex subserves the "cognitive side of motor control", which is specifically the spatio-temporal kinematic patterns of learned actions. This dominance is the primary reason why unilateral left inferior parietal lesions affect both the ipsilateral and contralateral sides of the body[31,33]. This view is supported by the fact that unilateral ideomotor LA of the left

limb occurs after callosal lesions, where the cognitive motor control represented in the left inferior parietal cortex fails to be transferred to the contralateral hemisphere. On the other hand, there is evidence indicating that the hemispheric asymmetry of the inferior parietal cortex is not absolute. Gazzaniga and colleagues demonstrated that apraxia of the left limb was not persistent and resolved within a week after complete surgical sections of the corpus callosum[34]. This suggests that the right homologue also houses spatial-temporal kinetic patterns similar to those represented in the left hemisphere[35,36]. In the present study, the combined damage to the left parietal lobe and posterior callosal fibers might be functionally interpreted as compromising these bilateral representations of praxis-related functions, potentially leading to the severe deficits observed in LA.

Hierarchical Organization of the Oral Domain: BFA vs. AOS

The present study revealed that BFA was associated with localized frontal lesions centered on the precentral gyrus at the vertical level of the inferior frontal sulcus, extending to the postcentral, inferior, and middle frontal gyri. In contrast, neither VLSM nor ROI-LSM analyses revealed any neuroanatomical correlates of AOS. The primary reason for these negative results may be the presence of aphasia concomitant with AOS. Previous studies have demonstrated variable neuroanatomical regions associated with AOS when accompanied by aphasia, including the anterior insula, inferior frontal cortex, and subcortical structures[11,37,38]. AOS accompanied by aphasia presumably reflects heterogeneous functional abnormalities. Conversely, pure AOS (without aphasia) has been consistently associated with lesions in the precentral gyrus at the level of the middle frontal gyrus, which lies just dorsal to the regions associated with BFA in our study[11,39–41]. Consistent with the proximity of these neuroanatomical substrates, BFA frequently co-occurs with AOS (**Table 1**), a pattern observed in up to half of cases[42].

The ventral part of the human central gyrus is largely occupied by the premotor cortex, except for its posterior rim, whereas its dorsal part corresponds to the primary motor cortex[43,44]. The mid-portion, where the neural correlates of BFA and pure AOS are

situated, represents a transitional zone. This anatomical arrangement maps onto the dual organization of the laryngeal motor cortex: a dorsal laryngeal motor cortex (primary motor cortex) located at the level of the middle frontal gyrus, and a ventral laryngeal motor cortex (premotor cortex) located in the precentral operculum[45,46]. Our findings localize the center of BFA lesions to the ventral laryngeal cortex extending to the adjacent prefrontal cortex, whereas pure AOS has been associated with lesions confined to the dorsal laryngeal cortex. This suggests that BFA represents a premotor symptom, whereas pure AOS represents a largely primary motor symptom, which can be termed “cortical dysarthria”[47]. This speculation is supported by direct cortical stimulation studies. Stimulation of the mid-level precentral gyrus primarily elicits positive motor responses of the face and articulators, a primary motor phenomenon, whereas stimulation of the ventral precentral gyrus produces negative motor responses, characterized by the complete inhibition of ongoing movement without loss of muscle tone[48,49]. The observed difference in lesion volumes (**Table 1**), significantly larger in BFA than in AOS, further supports these distinct mechanisms: generally, the more primary a cortical function is, the smaller the lesion required to impair it.

Limitations

The first limitation of the present study concerns the use of indirect CLSM. While this approach avoids artifacts inherent to tractography in pathological brains, it relies on a normative atlas, thereby failing to account for individual premorbid anatomical variability. In addition, the validity of disconnection estimates depends on the quality of the reference tractography, which carries a risk of overestimating disconnection due to false positives, distance biases, or the assumption of complete disruption within the lesion mask[17,18]. Furthermore, recent simulations suggest that joint analyses of left and right hemisphere lesions may introduce a statistical bias that disproportionately favors the detection of inter-hemispheric transcallosal disconnections over intra-hemispheric ones[50].

Second, the assessment of apraxias had methodological limitations. The evaluations were not performed in a fully systematic manner, specifically for patients without

apparent language or cognitive symptoms. In addition, because our assessments were based on a binary (present/absent) classification, the severity of apraxias or potential dissociations between imitation and verbal commands were not considered.

Conclusions

This study provides a structural framework for the hierarchical organization of human praxis. We demonstrate that limb praxis relies on a distributed, bilaterally integrated temporo-parietal network, where disconnection leads to multimodal integration failure. Conversely, oral praxis is hierarchically segregated: non-verbal actions (BFA) depend on a ventral premotor loop, while verbal articulation (AOS) engages a dorsal primary motor circuit. These findings move beyond simple somatotopy, highlighting how the brain utilizes distinct network architectures, distributed versus focal, to control different classes of skilled action.

========

Abbreviations: AF = arcuate fasciculus; AOS = apraxia of speech; BFA = buccofacial apraxia; CLSM = connectome-based lesion-symptom mapping; LA = limb apraxia; NIHSS = National Institutes of Health Stroke Scale; ROI = region of interest; SLF = superior longitudinal fasciculus; SLTA = Standard Language Test of Aphasia; VLSM = voxel-based lesion-symptom mapping.

Contributors: Y.N., R.I., and E.M. contributed to the conception and design of the study. R.I., Y.K., and Y.Y. contributed to data collection. Y.N. performed all the analyses and wrote the manuscript.

Funding: This work was supported by JSPS KAKENHI Grant Number 25K15842.

Competing interests: The authors report no competing interests.

Data availability: The data that support the findings of this study are available from the corresponding author, upon reasonable request. The data are not publicly available due to privacy or ethical restrictions.

REFERENCES

1. Kertesz A. Apraxia and aphasia. Anatomical and clinical relationship. In: *Advances in Psychology*. Vol 23. Advances in psychology. Elsevier; 1985:163-178.
2. Goldenberg G. Apraxia and the parietal lobes. *Neuropsychologia*. 2009;47(6):1449-1459.
3. Vingerhoets G. Contribution of the posterior parietal cortex in reaching, grasping, and using objects and tools. *Front Psychol*. 2014;5:151.
4. Battaglia-Mayer A, Caminiti R. Corticocortical Systems Underlying High-Order Motor Control. *J Neurosci*. 2019;39(23):4404-4421.
5. Kertesz A, Ferro JM. Lesion size and location in ideomotor apraxia. *Brain*. 1984;107 (Pt 3)(3):921-933.
6. Raade AS, Rothi LJ, Heilman KM. The relationship between buccofacial and limb apraxia. *Brain Cogn*. 1991;16(2):130-146.
7. Geschwind N. Disconnexion syndromes in animals and man. II. *Brain*. 1965;88(3):585-644.
8. Pearce JMS. Hugo Karl Liepmann and apraxia. *Clin Med*. 2009;9(5):466-470.
9. Conterno M, Kümmerer D, Dressing A, et al. Speech apraxia and oral apraxia: association or dissociation? A multivariate lesion-symptom mapping study in acute stroke patients. *Exp Brain Res*. 2022;240(1):39-51.
10. Morihara K, Ota S, Kakinuma K, et al. Buccofacial apraxia in primary progressive aphasia. *Cortex*. 2023;158:61-70.
11. Itabashi R, Nishio Y, Kataoka Y, et al. Damage to the Left Precentral Gyrus Is Associated With Apraxia of Speech in Acute Stroke. *Stroke*. 2016;47(1):31-36.
12. Japan Society for Higher Brain Dysfunction. *The Standard Language Test of Aphasia (SLTA): Manual of Directions*. Shinko Medical Press.; 1997.
13. Brett M, Leff AP, Rorden C, Ashburner J. Spatial Normalization of Brain Images with Focal Lesions Using Cost Function Masking. *NeuroImage*. 2001;14(2):486-500.
14. Karnath HO, Sperber C, Rorden C. Mapping human brain lesions and their functional consequences. *NeuroImage*. 2018;165:180-189.

15. Faria AV, Joel SE, Zhang Y, et al. Atlas-based analysis of resting-state functional connectivity: evaluation for reproducibility and multi-modal anatomy-function correlation studies. *Neuroimage*. 2012;61(3):613-621.
16. Winkler AM, Ridgway GR, Webster MA, Smith SM, Nichols TE. Permutation inference for the general linear model. *Neuroimage*. 2014;92:381-397.
17. Sperber C, Griffis J, Kasties V. Indirect structural disconnection-symptom mapping. *Brain Struct Funct*. 2022;227(9):3129-3144.
18. Kuceyeski A, Maruta J, Relkin N, Raj A. The Network Modification (NeMo) Tool: Elucidating the Effect of White Matter Integrity Changes on Cortical and Subcortical Structural Connectivity. *Brain Connectivity*. 2013;3(5):451-463.
19. Rozzi S, Calzavara R, Belmalih A, et al. Cortical connections of the inferior parietal cortical convexity of the macaque monkey. *Cereb Cortex*. 2006;16(10):1389-1417.
20. Binkofski F, Buxbaum LJ. Two action systems in the human brain. *Brain Lang*. 2013;127(2):222-229.
21. Fregosi M, Contestabile A, Hamadjida A, Rouiller EM. Corticobulbar projections from distinct motor cortical areas to the reticular formation in macaque monkeys. *Eur J Neurosci*. 2017;45(11):1379-1395.
22. Fisher KM, Zaaimi B, Edgley SA, Baker SN. Extensive cortical convergence to primate reticulospinal pathways. *J Neurosci*. 2021;41(5):1005-1018.
23. Graziano M. The organization of behavioral repertoire in motor cortex. *Annu Rev Neurosci*. 2006;29(1):105-134.
24. Rizzolatti G, Cattaneo L, Fabbri-Destro M, Rozzi S. Cortical mechanisms underlying the organization of goal-directed actions and mirror neuron-based action understanding. *Physiol Rev*. 2014;94(2):655-706.
25. Haggard P, de Boer L. Oral somatosensory awareness. *Neurosci Biobehav Rev*. 2014;47:469-484.
26. Lutz OJ, Bensmaia SJ. Proprioceptive representations of the hand in somatosensory cortex. *Curr Opin Physiol*. 2021;21:9-16.
27. Osiurak F, Reynaud E, Baumard J, Rossetti Y, Bartolo A, Lesourd M. Pantomime of tool use: looking beyond apraxia. *Brain Commun*. 2021;3(4):fcab263.
28. Ochipa C, Rothi LJ, Heilman KM. Conceptual apraxia in Alzheimer's disease. *Brain*. 1992;115 (Pt 4):1061-1071.
29. Zadikoff C, Lang AE. Apraxia in movement disorders. *Brain*. 2005;128(Pt 7):1480-1497.
30. Luria AR. *Higher Cortical Functions in Man*. Basic Books, Inc.; 1980.

31. Buxbaum LJ. Learning, remembering, and predicting how to use tools: Distributed neurocognitive mechanisms: Comment on Osiurak and Badets (2016). *Psychol Rev*. 2017;124(3):346-360.
32. Buxbaum LJ, Shapiro AD, Coslett HB. Critical brain regions for tool-related and imitative actions: a componential analysis. *Brain*. 2014;137(Pt 7):1971-1985.
33. Goldenberg G. Apraxia - the cognitive side of motor control. *Cortex*. 2014;57:270-274.
34. Gazzaniga MS, Bogen JE, Sperry RW. Dyspraxia following division of the cerebral commissures. *Arch Neurol*. 1967;16(6):606-612.
35. Watson R, Heilman KM. Callosal apraxia. *Brain : a journal of neurology*. 1983;106 (Pt 2):391-403.
36. Heilman KM, Watson RT. The disconnection apraxias. *Cortex*. 2008;44(8):975-982.
37. Dronkers NF. A new brain region for coordinating speech articulation. *Nature*. 1996;384(6605):159-161.
38. Hillis AE, Work M, Barker PB, Jacobs MA, Breese EL, Maurer K. Re-examining the brain regions crucial for orchestrating speech articulation. *Brain*. 2004;127(Pt 7):1479-1487.
39. Lecours AR. The “Pure Form” of the phonetic disintegration syndrome (pure anarthria); anatomo-clinical report of a historical case. *Brain Lang*. 1976;3(1):88-113.
40. Graff-Radford J, Jones DT, Strand EA, Rabinstein AA, Duffy JR, Josephs KA. The neuroanatomy of pure apraxia of speech in stroke. *Brain Lang*. 2014;129:43-46.
41. Chang EF, Kurteff G, Andrews JP, et al. Pure apraxia of speech after resection based in the posterior middle frontal gyrus. *Neurosurgery*. 2020;87(3):E383-E389.
42. Whiteside SP, Dyson L, Cowell PE, Varley RA. The relationship between apraxia of speech and oral apraxia: Association or dissociation? *Arch Clin Neuropsychol*. 2015;30(7):670-682.
43. Geyer S, Ledberg A, Schleicher A, et al. Two different areas within the primary motor cortex of man. *Nature*. 1996;382(6594):805-807.
44. Glasser MF, Coalson TS, Robinson EC, et al. A multi-modal parcellation of human cerebral cortex. *Nature*. 2016;536(7615):171-178.
45. Eichert N, Papp D, Mars RB, Watkins KE. Mapping human laryngeal motor cortex during vocalization. *Cereb Cortex*. 2020;30(12):6254-6269.
46. Ammanuel SG, Kondapavulur S, Lu AY, et al. Intraoperative cortical stimulation mapping with laryngeal electromyography for the localization of human laryngeal motor cortex. *J Neurosurg*. 2024;141(1):268-277.
47. Johns DF, Darley FL. Phonemic variability in apraxia of speech. *J Speech Hear Res*.

1970;13(3):556-583.
48. Rech F, Herbet G, Gaudeau Y, et al. A probabilistic map of negative motor areas of the upper limb and face: a brain stimulation study. *Brain*. 2019;142(4):952-965.
49. Zhou Y, Zhao Z, Zhang J, et al. Electrical stimulation-induced speech-related negative motor responses in the lateral frontal cortex. *J Neurosurg*. 2022;137(2):496-504.
50. Röhrig L, Rosenzopf H, Wöhrstein S, Karnath HO. The need for hemispheric separation in pairwise structural disconnection studies. *Hum Brain Mapp*. 2023;44(16):5212-5220.

TABLES.

Table 1. Demographic and clinical characteristics of participants

	LA	**BFA**	**AOS**	**No apraxias**	**Total**
n	17	20	22	93	136
Age (Mean ± SD)	76.5 ± 11.6	69.5 ± 11.0	67.0 ± 13.9	70.4 ± 12.9	70.5 ± 12.9
Sex (Female)	5	2[a]	9	42	55
NIHSS (Mean ± SD)	13.6 ± 9.6[b]	10.9 ± 7.8[b]	9.5 ± 8.6[b]	5.7 ± 5.8	7.3 ± 7.2
Stroke subtype					
Cardioembolic	11	7	7	35	53
Large artery atherosclerotic	4	10	9	34	49
Others	2	3	6	24	34
Lesion volume (mm^3, Mean ± SD)	86685.6 ± 94942.7[c]	82512.8 ± 89171.0[c]	50228.4 ± 89567.6	19170.6 ± 26114.0	31223.1 ± 49110.7
Aphasia type					
Broca	5	8	15	0	15
Pure AOS	0	1	7	0	7
Wernicke	9	6	0	19	32
Conduction	0	0	0	1	1
Transcortical sensory	1	1	0	14	16

Anomic	1	2	0	16	19
Others	0	2	0	4	6
No aphasia or AOS	1	0	0	39	40
Comorbid apraxia					
BFA	5	-	9	-	20
AOS	5	9	-	-	22
LA	-	5	5	-	17

AOS, apraxia of speech; BFA, buccofacial apraxia; LA, limb apraxia; NIHSS, National Institutes of Health Stroke Scale

a, Male prevalence was significantly higher in the BFA group compared to patients without apraxia (Fisher's exact test, $p = 0.004$); b, Patients with apraxias had higher NIHSS scores across all apraxia subtypes compared to the non-apraxia group (t-test, $p < 0.05$ for all comparisons); c, Patients with LA and BFA had significantly larger lesions than those without apraxia (t-test, $p = 0.010$ and $p = 0.005$, respectively), whereas patients with AOS did not show a significant difference ($p = 0.12$).

Table 2. Results of ROI-LSM

ROIs	z-score
LA	(p<0.05 is z>3.64)
Superior longitudinal fasciculus	5.26
Posterior thalamic radiation	5.17
Fusiform gyrus	4.57
Inferior occipital gyrus	4.54
Angular gyrus	4.53
Supramarginal gyrus	4.28
Middle occipital gyrus	4.19
Precuneus	4.05
Posterior superior temporal gyrus	4.03
Tapetum of corpus callosum	3.96

Posterior middle temporal gyrus	3.92
Postcentral gyrus	3.66
BFA	(p<0.05 is z>3.65)
Precentral gyrus	5.22
Inferior frontal gyrus, pars opercularis	4.76
Inferior frontal gyrus, pars triangularis	4.53
Superior longitudinal fasciculus	4.35
Middle frontal gyrus	4.25
Meynert nucleus	4.24
Sagittal stratum	4.20
Anterior corona radiata	4.17
Insula	3.94
Postcentral gyrus	3.84
Inferior frontal gyrus, pars orbitalis	3.81
AOS	(p<0.05 is z>3.54)
No suprathreshold regions	

FIGURES.

Figure 1. Lesion distribution of participants

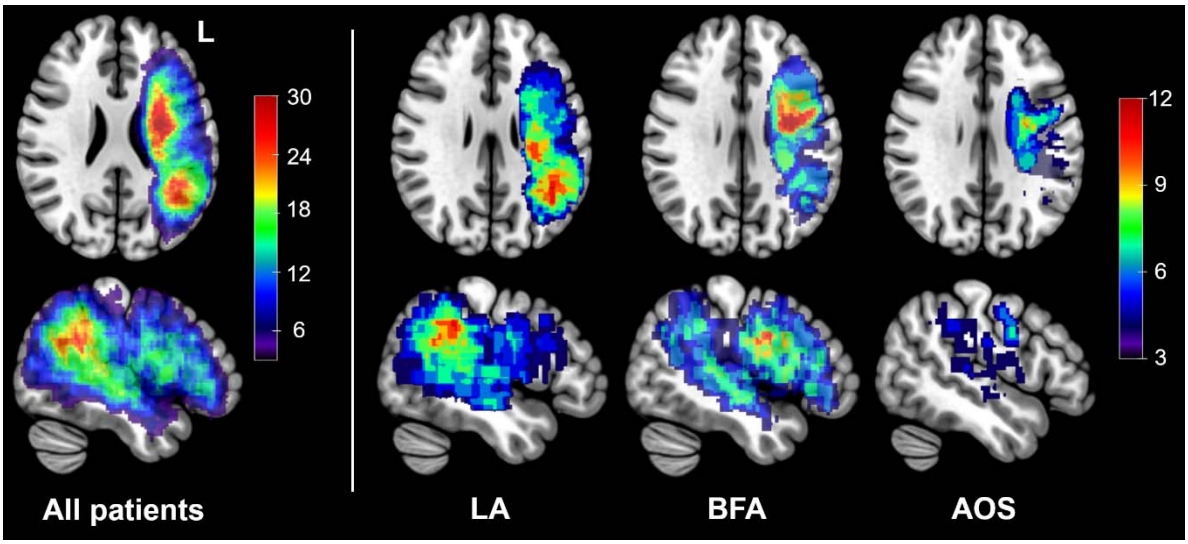

Figure 2. Results of VLSM and ROI-LSM analyses

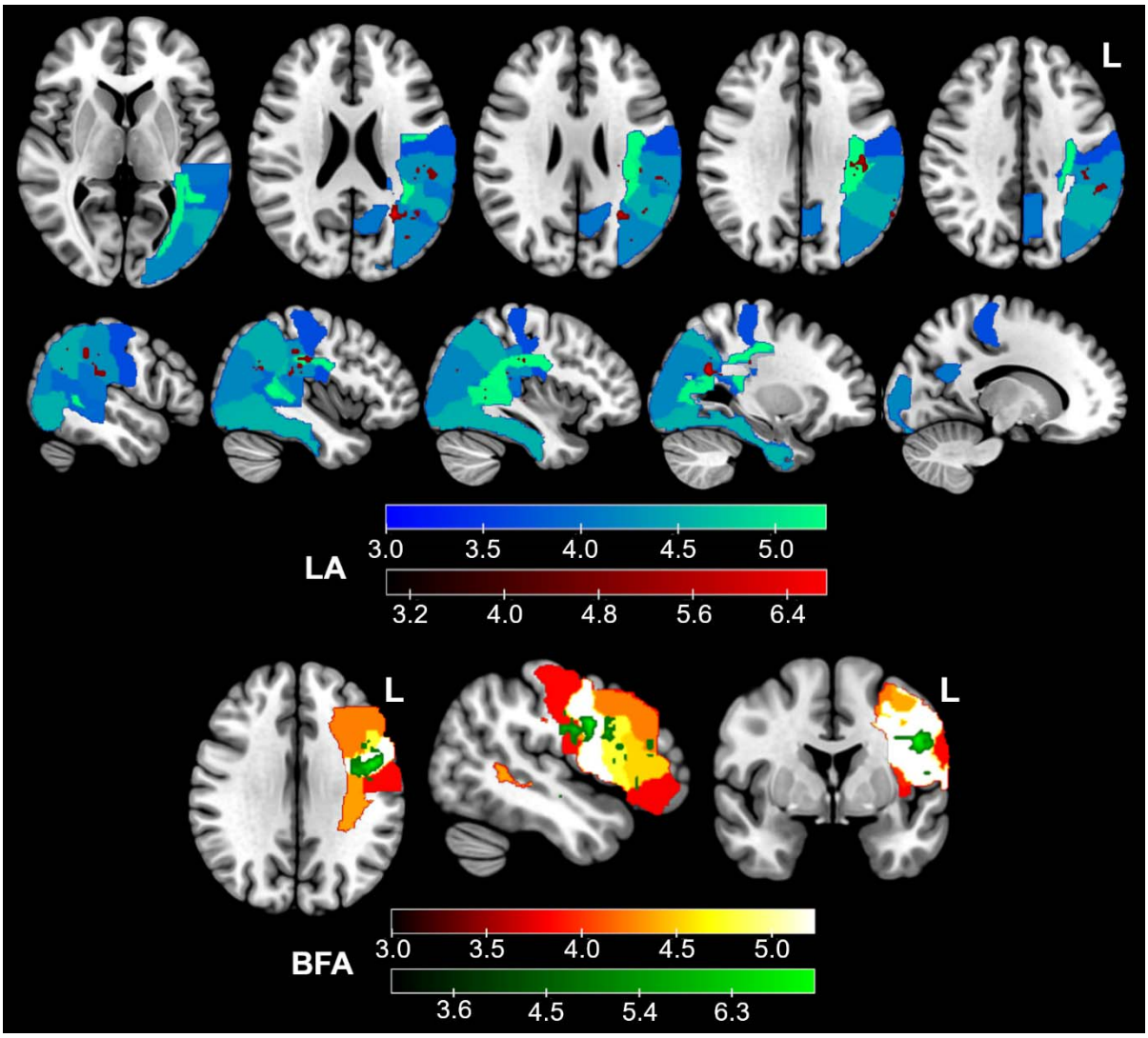

The upper row displays regions associated with limb apraxia; VLSM results are shown in red, and ROI-LSM results in blue-green. The lower row displays regions associated with buccofacial apraxia; VLSM results are shown in green, and ROI-LSM results in red-orange-white. Color bars indicate z-scores.

Figure 3. Results of CLSM with deterministic tractography

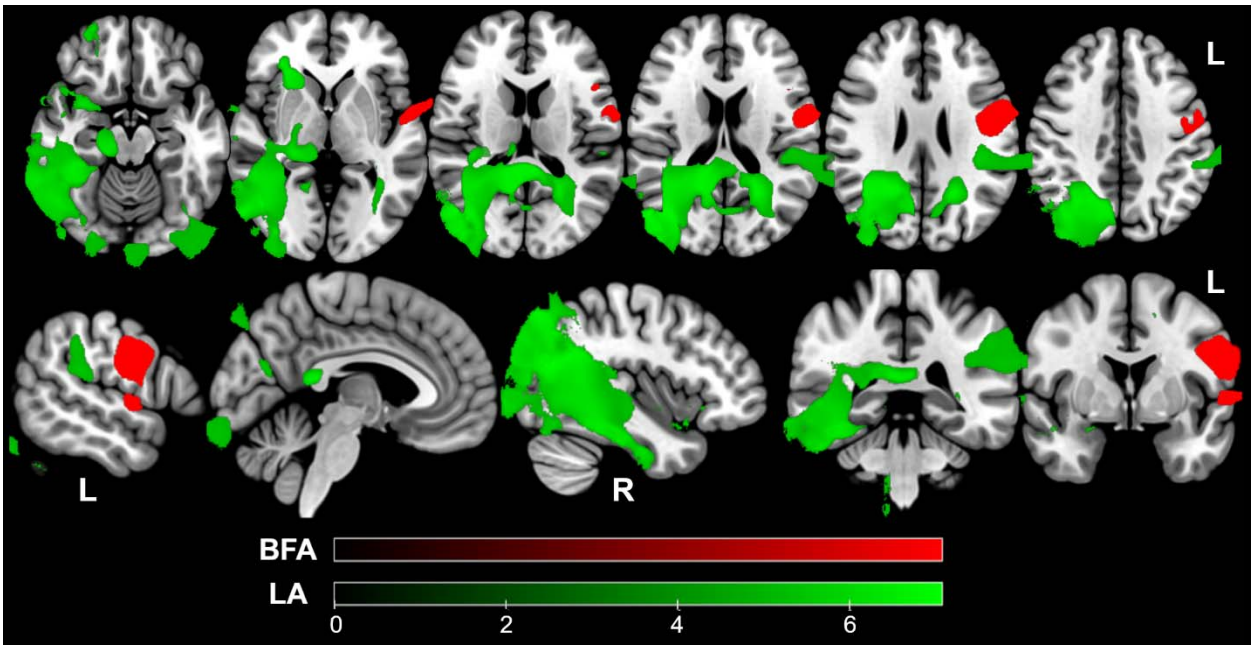

Disconnection maps associated with LA are shown in green, and those associated with BFA are shown in red.

SUPPLEMENTARY MATERIALS.

Supplementary Table 1. Demographic and clinical characteristics of participants (Mutually exclusive groups)

	LA without BFA	**BFA without LA**	**BFA+LA**	**BFA without AOS**	**AOS without BFA**	**BFA+AOS**
n	12	15	5	11	13	9
NIHSS (Mean ± SD)	12.7 ± 10.3	9.3 ± 7.1	16.0 ± 8.3	10.0 ± 6.7	7.7 ± 8.0	12.1 ± 9.2
Lesion volume (mm^3, Mean ± SD)	56389.3 ± 54117.6	56884.8 ± 51484.5	159396.8 ± 136529.5	67977.5 ± 44210.3[a]	15578.5 ± 18140.0[a]	100278.2 ± 125682.1
Aphasia type						
Broca	2	5	3	0	7	8
Pure AOS	0	1	0	0	6	1
Wernicke	7	4	2	6	0	0
Conduction	0	0	0	0	0	0
Transcortical sensory	1	1	0	1	0	0
Anomic	1	2	0	2	0	0
Others	0	2	0	2	0	0
No aphasia or AOS	1	0	0	0	0	0
Comorbid apraxia						
BFA	-	-	-	-	-	-
AOS	2	6	3	-	-	-
LA	-	-	-	2	2	3

a, Patients with BFA-/AOS+ had significantly smaller lesion volumes than those with BFA+/AOS- (t-test, $p = 0.009$).

Supplementary Figure 1. Lesion distribution of participants

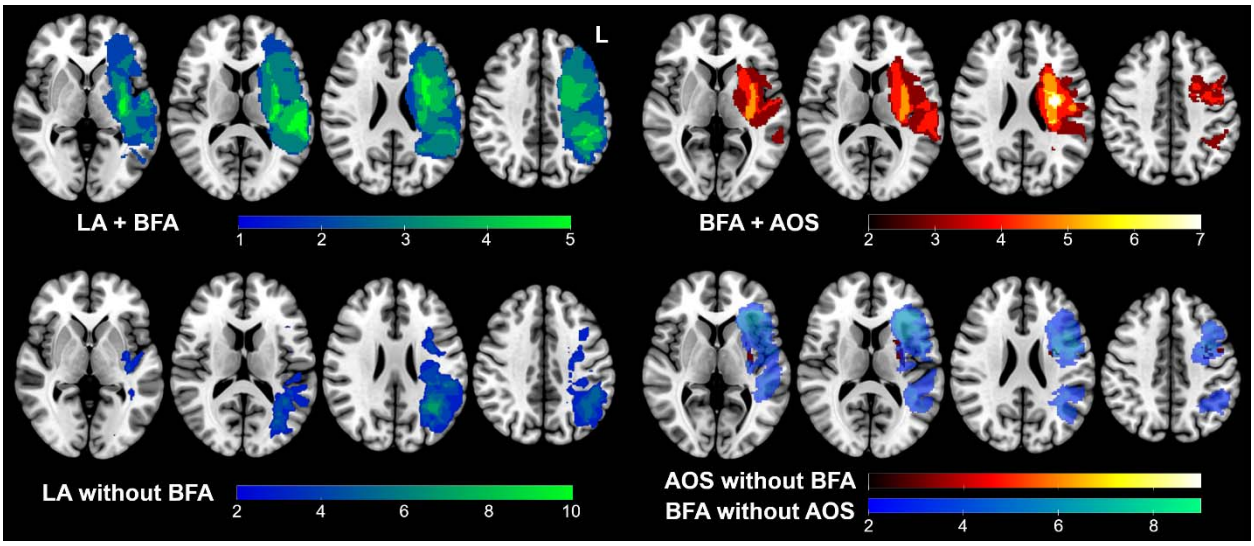

Supplementary Figure 2. Results of CLSM with probabilistic tractography

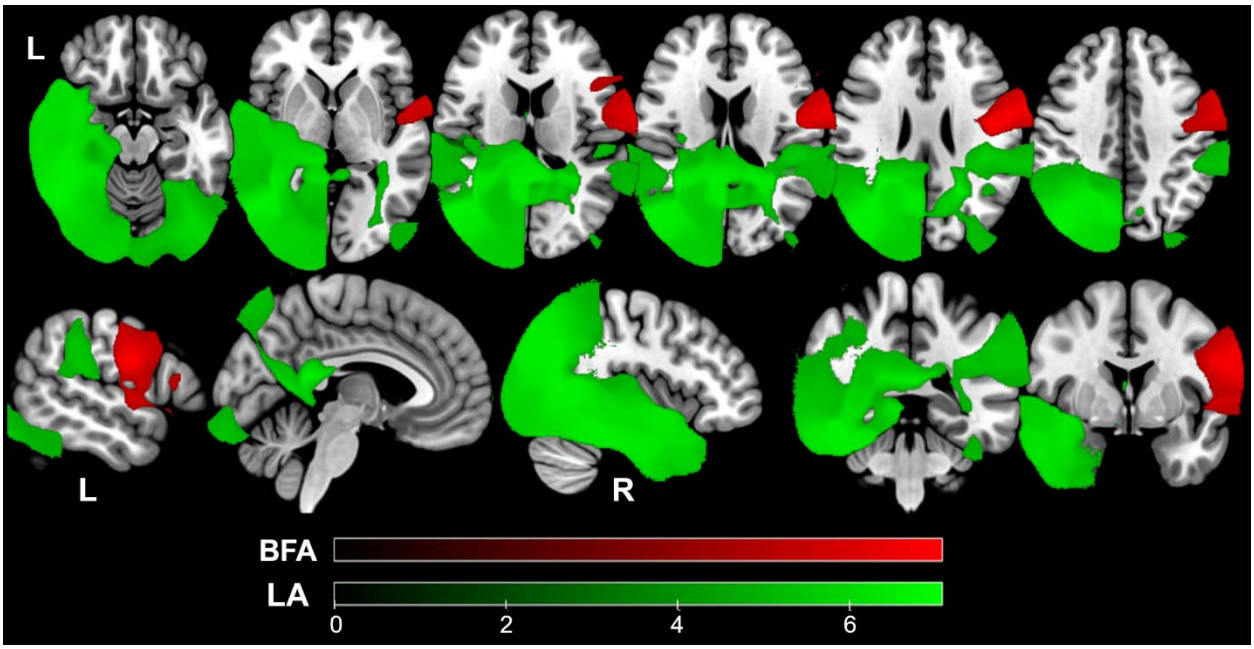

The Disconnection map associated with LA is shown in green, and that with BFA is shown in red.

Supplementary Figure 3. Locations of white matter fiber tracts on the JHU atlas

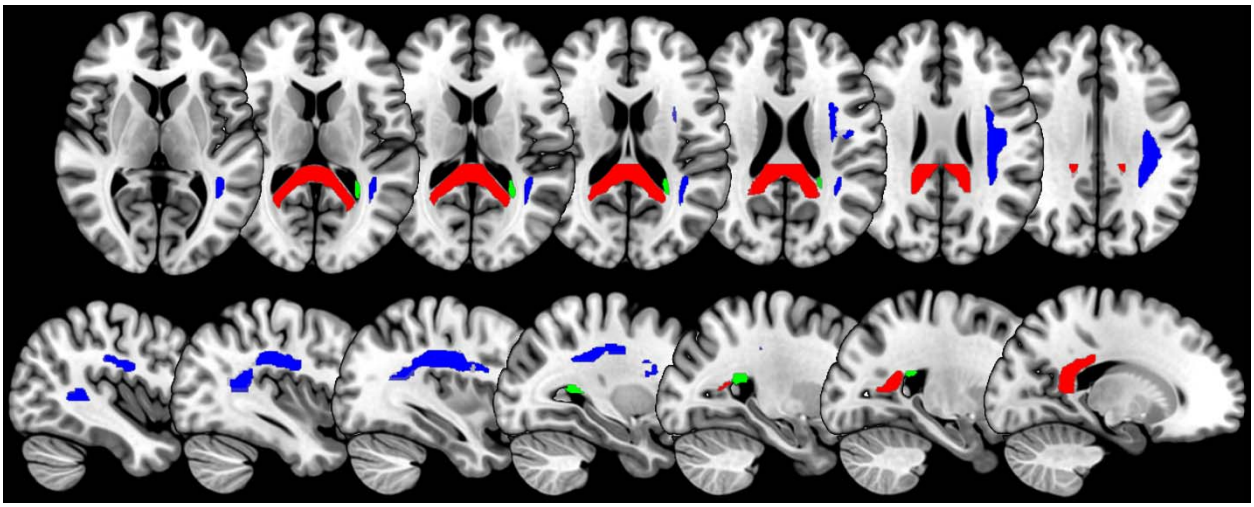

The superior longitudinal fasciculus/arcuate fasciculus, tapetum of the corpus callosum, and splenium are shown in blue, green, and red, respectively.