Minimally Invasive In-Situ Perfusion Method for Targeted AAV Delivery in Native Kidney: Proof of Concept in Pigs

Enrique Montagud-Marrahi[1,2,3*], Elisenda Bañon-Maneus[1,2*], Ander Zugazaga[4*], Diana Gutierrez[2], Luigi Zattera[5], Rubén Rabadan-Ros[6], Marta Lazo[2], Marc Bohils[7], Arantza Gelabert[4], Yosu Luque Rincon[1,8].

1. Kidney Transplantation and Nephrology Department. Hospital Clinic de Barcelona, Spain.

2. Nephrology and Kidney Transplantation Laboratory. Fundació per a la Recerca Biomèdica - Institut d'Investigacions Biomèdiques August Pi i Sunyer, Barcelona, Spain.

3. Red de Investigación Cooperativa Orientada a Resultados en Salud (RICORS 2040), Madrid, Spain.

4. Radiology Department. Hospital Clinic de Barcelona, Spain.

5. Anesthesiology Department, Hospital Clinic de Barcelona, Spain.

6. Group of Metabolism and Genetic Regulation of Disease, UCAM HiTech Sport & Health Innovation Hub, Universidad Católica de Murcia, Murcia, Spain

7. Transplant Coordination Department. Hospital Clinic de Barcelona, Spain.

8. Sorbonne Université and Assistance Publique des Hôpitaux de Paris, Paris, France

*Contributed equally

Corresponding author: Dr. Yosu LUQUE RINCON

Kidney Transplantation and Nephrology Department. Hospital Clinic of Barcelona, Barcelona, Spain.

Sorbonne Université – Assistance Publique Hôpitaux de Paris, Paris, France

yluque@clinic.cat and yosu.luque@gmail.com and yosu.luque@aphp.fr

ORCID:0000-0002-3172-6571

Co-corresponding author: Dr. Arantza GELABERT

Radiology Department. Hospital Clinic of Barcelona, Barcelona, Spain.

magelabert@clinic.cat

ORCID:0000-0003-1817-3500

ABSTRACT

Currently, there is not any method for efficient and targeted delivery of gene therapies using viral vectors to the native kidneys. Adeno-associated viruses (AAV) are limited by hepatotoxicity and poor kidney tropism. This study aimed to develop a minimally invasive approach that overcomes both challenges.

We evaluated in pigs a technique leveraging external perfusion systems to transiently isolate native kidney vascularization. Using a percutaneous femoral approach, fluoroscopy-guided catheterization of the kidney artery and vein enabled the establishment of a temporary isolated kidney perfusion circuit permitting native kidney in-situ perfusion. AAV delivery was then assessed by detecting construct encoding Td-Tomato protein, its mRNA and fluorescence 6 days after the perfusion.

The method was achieved with two different external perfusion systems and was not associated with procedure related mortality or any major complication. Td-Tomato was detected in the perfused kidney without a significant detection in the liver which showed no inflammatory infiltrates.

We developed, in pigs, a minimally invasive method permitting in-situ native kidney perfusion that enables kidney-targeted AAV delivery. Besides, it limits liver off-target transduction, potentially reducing its main side effect, hepatotoxicity, when AAV is systemically injected. It offers fast-track translational possibilities for developing kidney-targeted gene therapies. Finally, it may permit additional non-AAV therapeutics for patients with kidney diseases.

MAIN TEXT

Chronic Kidney Disease (CKD) represents a growing health burden that affects about 10% of the general world population and is associated with high cost[1,2]. The current possibilities for those patients with end stage kidney disease are replacement therapies such as dialysis or transplantation. Nevertheless, neither of them completely substitutes for the complex physiological functions of a native kidney. Besides these therapies have cardiovascular or infectious side effects, and are associated with an impaired patient quality of life[1]. To avoid or delay the need for kidney replacement therapies, the recent advances in gene therapy and regenerative medicine as the published animal studies on partial reprogramming sound promising[3–6]. However, for translating these results to humans, the development and optimization of delivery vectors as viruses or also lipidic nanoparticles is crucial for specifically targeting deep organs as the kidneys[7]. A key challenge for therapeutical innovation in kidney targeted therapies remains the limited delivery of the currently only clinically approved gene therapy vectors, the adeno-associated viruses (AAV)[8,9]. The key goal would be a method that maximizes its kidney delivery while minimizing off-target transduction, particularly in the liver. Indeed, the liver retains and metabolizes a wide spectrum of molecules as the AAV when systemically injected. The AAV hepatotoxicity, mostly dose dependent, represents a main current concern for its use in gene therapies[10].

For maximizing virus delivery in kidney cells, we thought about first isolating the kidney vascular system from the systemic circulation. It was already performed on kidney grafts with ex-vivo perfusion devices, a promising platform for kidney graft editing[11]. Thanks to normothermic ex-vivo perfusion a broad range of interventions is allowed as the organ is maintained close to physiological conditions, oxygenated and with a maintained cell metabolism[12].

For patients with a chronic kidney disease, the isolated perfusion treatment of a native kidney using the previous method would require a surgical technique. A feasible procedure associating a nephrectomy, the ex-situ kidney perfusion and treatment followed by an auto-transplantation. However, patients with a chronic kidney disease are often fragile and have several comorbidities including vascular alterations[2] that increase the risk of side effects. A less invasive procedure avoiding the general anesthesia needed for an open surgery and avoiding the need for vessel and urinary tract sectioning could be more suitable for them.

In the present study, we offer an innovative method combining a minimally invasive interventional radiology technique with organ ex-situ perfusion systems. It permits delivering an AAV based therapy

to a native kidney after its vascular isolation and perfusion. It also limits the liver AAV delivery and potentially its hepatotoxicity.

Experiments were conducted in 3 female pigs (*Sus scrofa domesticus*) under general anesthesia.

We first tested the feasibility of the method, achieving selective *in-situ* kidney perfusion with the interventional radiology technique using two external perfusion devices. A scheme showing the system using Aferetica SL® Perlife device is shown in **Figure 1A**. One perfusion system was used for each kidney sequentially on a single pig in a non-recovery procedure. A percutaneous approach combining femoral vascular access with fluoroscopy-guided catheterization and balloon occlusion of the kidney artery and vein (**Figure 1B**) permitted to establish a temporary isolated kidney perfusion circuit. Each perfusion lasted for 1 h in each native kidney with a perfusate including leucocyte-depleted red blood cells, a balanced crystalloid solution, antibiotics and a vasodilator. One of these two external perfusion systems included, as previously cited, Aferetica SL® Perlife kidney perfusion device that recorded the parameters available in **Supplementary Figure 1-4**. The arterial flow was not exceeding 130 mL/min, and the target arterial pressure of 70 mmHg was achieved. The second device included the Ex-Stream (Transbiotech®) ECMO pump and an oxygenator without the possibility of recording any of the previous parameters. Post-perfusion kidney viability and vascularization were validated by fluoroscopy and ultrasound. The necropsy found a mild subcapsular hematoma in the first perfused kidney (**Supplemental Figure 5-6**).

After the feasibility experiment describing the new in-situ native kidney perfusion method, we tested its efficiency for kidney targeted AAV delivery. In the next pig the left kidney was perfused as the right kidney had unfavorable vascular anatomy including 3 kidney veins. A serotype DJ AAV[13] carrying a construct expressing the Td-Tomato fluorescent protein in the infected cells was used. It was administered in the arterial line 1h before the end of the in-situ kidney perfusion. The kidney was flushed with Ringer lactate at the end of the perfusion to avoid a systemic AAV leakage. Post-perfusion kidney viability was as previously validated by fluoroscopy and ultrasound. The immediate post-procedure skin aspect is shown in **Supplemental Figure 7** to illustrate the minimally invasive characteristic. After the procedure, the animal was followed up for 5 days and treated with daily ceftriaxone and 300 mg of acetylsalicylic acid. Veterinarians did not detect pain or behavioral issues either after the procedure (**Supplemental Movie 1**) or in the following days. Kidney ultrasound was performed before euthanasia and demonstrated a preserved echogenicity and a maintained global perfusion as assessed with color and power Doppler (**Figure 1C**). The necropsy did not show any kidney abnormality. Histological analysis showed slight tubular dilation and inflammatory infiltrates in the perfused kidney compared to the non-perfused kidney and a preserved liver parenchyma

(**Supplemental Figure 8**). The efficacy of the method for targeted kidney AAV delivery was validated in a third pig.

The AAV delivery was analyzed by different techniques. The In Vivo Imaging System (IVIS), detecting the red fluorescence, showed a signal in the perfused kidney that was not identified in the non-perfused kidney (**Figure 2A**). However, the heterogenous aspect observed in the perfused kidney shown in that Figure could suggest a partial infarction. Anti-Td-Tomato immunofluorescence detected a transduction in kidney tubular and glomerular epithelial cells including glomerular parietal epithelial cells **(Figure 2B**). Digital PCR analysis was performed, and the results were pooled across the two animals to provide organ-level summaries. Perfused Kidney Medulla and Cortex compartments (PKM and PKC) exhibited the highest mean copy numbers per µL (**Figure 2C**). Interestingly, we detected a signal in the bladder (Bl) suggesting a urinary elimination of the AAV. That could also explain the observed glomerular parietal cell transduction. We finally used in fresh frozen sections the direct excitation of Td-Tomato with a fluorescence microscope in the kidneys and the liver of the treated pigs and controls. It showed a slight signal in the perfused kidney, not present in the non-perfused kidney or the control kidney of a pig not receiving any AAV. The liver of the perfused pig showed a signal that was comparable to the signal of the non-treated pig control liver (**Supplemental Figure 9 and 9bis**).

Our study provides a new minimally invasive and innovative method that achieved specific native kidney AAV delivery with no leakage to non-target organs such as the contralateral kidney and liver. These results were achieved despite a short perfusion length. The procedures were not associated with major vascular issues or liver alteration. However, kidney inflammatory infiltrates observed could be due to the AAV dose or to an immune reaction of the host to the Td-Tomato protein expression in pig cells[14]. In its human potential use, local anesthesia or sedation could only be required. Importantly, the procedure could be repeated in the treated kidney or in the contralateral one due to its minimally invasive characteristics.

Some limitations should be acknowledged, such as the sample size, using a pig model that represents a high cost. It is compensated by great advantages: similar organ size compared to humans and so a method using clinically close settings and devices. However, pigs have a significantly increased risk of vascular thrombosis compared to humans, likely attributable to the pig inherent hypercoagulability[15] and vascular fragility. It is to note as it could be a challenge associated to vascular complications as the infarction observed in one perfused kidney.

The procedure has been achieved using two settings using two different organ perfusion devices. One is Aferetica Perlife, that is already commercially available in Europe for graft preservation[16] and the other included Ex-Stream (Transbiotech) pump used for ECMO systems in many countries[17]. Finally, we employed a fluorescent reporter construct as a proof of principle for AAV delivery validation but further studies using other AAV serotypes and/or therapeutic constructs can confirm the translational value of the method for the patients with kidney diseases.

For future human application or future experiments in pigs, pre-procedural imaging with computed tomography or magnetic resonance imaging would be recommended. It would allow a previous assessment of vascular anatomy and provide an estimation of the kidney weight. That estimation would be helpful for accurate calculation of the AAV dosing.

Kidney isolated ex-situ and the current in-situ perfusion method represent valuable platforms for translational research and therapeutical advances. Compared to ex-situ kidney perfusion, our novel method is minimally invasive and can be used for native kidneys opening a broad avenue of innovative therapeutics for kidney diseases. It was feasible thanks to the previous advances in organ perfusion techniques and in interventional radiology.

We think it will constitute a significant step forward in the development of kidney gene therapies and potentially in many other kidney diseases.

ANIMALS AND METHODS

The procedures were performed at SPECIPIG SL / VERSA Biomedical facilities (Barcelona, Spain). Three female pigs (*Sus scrofa domesticus*) of 60-80 kilograms were used for the procedures. Animals were kept at an appropriate and constant temperature and humidity, and with light-controlled cages on a 12–12 h light-dark cycle, with free access to water and food. Food is withheld 12 hours prior to the experiment. The study was approved by and conducted according to the guidelines of SPECIPIG SL animal ethics committee. The current experimental study was sent to the competent authorities (Generalitat de Catalunya) by SPECIPIG SL.

The post-procedure care for the two recovery studies consisted of daily administration of ceftriaxone (2 mg/kg) and acetylsalicylic acid (300 mg). The welfare scores were recorded daily. The urine color was observed to non-invasively exclude hematuria suggesting kidney vessel thrombosis. On day 6, before euthanasia and organ collection, a final kidney ultrasound was performed to assess treated kidney appearance and vascularization.

Adeno-Associated Virus (AAV)

The DJ serotype AAV produced by Vector Biolabs (USA) carried an encoding plasmid for a td-Tomato fluorescent protein (AAV/DJ-EF1A>NLS-tdTomato:WPRE). The aimed dose was 10^14 genome copies (gc) per kg. To note the kidney weight must be estimated as it cannot be weighed before the in-situ procedure. Clinically approved AAV based gene therapies use lower doses expressed per total body weight. Here we acknowledge that the dose was higher when the organ is supposed to be isolated from the systemic circulation. However, the set up was innovative and the targeted organ is classically reluctant to AAV transduction. Besides, previous nonpublished data from our team suggested that AAV could be filtered into the urine decreasing its concentration over time. AAV/DJ refers to an adeno-associated virus vector using the DJ capsid, which is a hybrid designed for broad tropism and high transduction efficiency across many mammalian cell types. EF1A promoter (elongation factor 1 alpha) is a strong, ubiquitous promoter commonly used in gene therapy and research because it drives robust expression in a wide range of species and cell types, including human, mouse, and other mammalian cells. The EF1A promoter is considered species-independent and works well in most mammalian cells, including porcine cells. WPRE (Woodchuck hepatitis virus posttranscriptional regulatory element) enhances transcript stability and expression. AAV/DJ capsid also has broad tropism, so it can transduce pig cells efficiently in vitro and in vivo.

Procedure

Pigs were initially anesthetized with 10 mg/kg intramuscular azaperone (Stressnil®, Esteve). Thirty minutes after, pigs were weighed and transported to the operating table with spontaneous breathing. After pre-oxygenation with 100% oxygen, inhaled isoflurane (2%–5%, IsoVet®, Braun) permitted a deep sedation. Anesthesia was induced with 15 mg/kg intravenous sodium thiopental (Rotexmedica, GbmH) through cannulation of an ear vein. In prone position, a 7-mm endotracheal tube was introduced and secured and its position confirmed with capnography. Then the animal was placed in supine position with hemodynamic and respiratory monitoring (EKG, oxygen saturation and blood pressure). Ventilation was conducted with volume-controlled intermittent positive pressure ventilation to maintain an end tidal CO2 between 35 to 40 mmHg and a PaO2 between 200 to 240 mmHg. Isoflurane (1%–2%) was used for anesthesia maintenance and prior to skin puncture fentanyl 100 mg followed by 50 mg/h intravenously (Fentanest®, Kern Pharma) was administered. Cefoxitin 1 g was administered intravenously (Normon) for antibiotic prophylaxis and cisatracurium 0.2–0.3 mg/kg followed by 1.5 mg/h intravenously (Normon) for muscular paralysis. Cristalloid solution (Plasmalyte, Baxter) was administered systemically during the procedure as sodium heparin with a 100 UI/kg initial bolus when the first vessel is punctured followed by a 250 UI/kg per hour infusion. The anticoagulation was not reversed at the end of the procedure.

The perfusate composition included Aminoplasmal 10%, Insulin, Isofundin, Epoprostenol, Amoxicillin/clavulanic acid, Sodium Bicarbonate 8.4%, Dexamethasone, Heparin, 5% Glucose solution, 10% calcium gluconate and approximately 400 ml of Red Blood Cells from another pig and previously leucocyte depleted. To note, perfusate characteristics are modified by the perfused kidney metabolism and urine production during the vascular isolation duration.

The right common femoral artery was accessed under ultrasound guidance. A closure device was pre-deployed (ProGlide™, Abbott Vascular, Santa Clara, CA, USA), and an 8-Fr introducer sheath was placed. The left femoral vein was then cannulated with an 8.5-Fr deflectable sheath (TourGuide Steerable Sheath Medtronic®, 55 cm).

After securing both vascular accesses, digital subtraction aortography using fluoroscopy as OEC Elite CFD 31 (GE Healthcare) was performed with a pigtail catheter to delineate kidney arterial anatomy and venous drainage. The aim was to identify vascular variants that could

affect the closed perfusion circuit (e.g., multiple kidney arteries or veins). In one case a double venous drainage was observed and therefore the contralateral kidney was selected for the procedure.

The kidney artery was catheterized with an 8-Fr FlowGate™ Balloon Guide Catheter (Stryker Neurovascular, Fremont, CA, USA). This device, originally designed for neurovascular procedures, provides temporary vascular occlusion via a compliant balloon (maximum inflation volume 0.6 mL; diameter 10 × 10 mm). A 50:50 mixture of contrast and saline was used for balloon inflation to achieve complete kidney artery occlusion that was confirmed angiographically. The balloon was then deflated awaiting kidney vein catheterization.

The ipsilateral kidney vein was catheterized with the 8.5-Fr deflectable sheath (TourGuide Steerable Sheath Medtronic®, 55 cm), into which a Fogarty® occlusion balloon catheter (Edwards Lifesciences, Irvine, CA, USA) was advanced coaxially. The catheter was positioned approximately 1 cm from the cava confluence. The balloon was inflated with air until occlusion, and any leakage was excluded with contrast injections through the distal lumen. Once occlusion was confirmed, the balloon was deflated. The arterial inflow was connected to the external perfusion device via a three-way stopcock, while the venous catheter was left in free drainage considering that operating table was placed higher than perfusion device. After sequential inflation of the arterial and venous balloons, in-situ perfusion was initiated. After the perfusion, both balloons were deflated, and selective kidney arteriography was performed to ensure the absence of arterial dissection or thrombosis, preserved parenchymal perfusion pattern, and adequate venous drainage. Ultrasonography was also performed at the end of the procedure to assess any additional complications.

For vessels closure, the kidney artery puncture was sealed percutaneously with the pre-deployed ProGlide™ sutures, while the venous access site was managed with manual compression. Both puncture sites were additionally protected with compressive bandages. The first animal was euthanized after the in-situ perfusion was achieved. Data recorded by Perlife device was shared by Aferetica SL and it is available in **Supplemental Figures 1-4**. In the pigs permitting AAV biodistribution assessment, the virus was injected through the arterial stopcock once the venous effluent appeared clear with the characteristic “meat-wash” appearance.

Necropsies were performed at the end of the procedures and the organs examined at the animal facility. Organ samples were frozen or fixed in formaldehyde for 24 hours and then embedded

in paraffin.

Histological assessment

3-mm sections of the fixed samples were performed and stained with Hematoxylin-Eosin (H&E). Kidney sections were also stained with Masson's Trichrome. The kidneys and the liver from one pig receiving the AAV were analyzed by a senior human pathologist with an additional valuable expertise in animal models, Dr. Jordi Aluma (Patlabconsult, Spain).

Td-Tomato detection: In Vivo Imaging System (IVIS), microscopy fluorescence and immunofluorescence

Td-Tomato fluorescence was detected using an IVIS imaging system with excitation at 570 nm and emission at 620 nm.

For microscopy fluorescence detection using kidney and liver frozen tissue, 10um sections embedded in OCT were mounted with Ibidi Mounting Medium including DAPI (REF 50011 ibidi GmbH, Germany). Liver and kidney control tissues were obtained from a pig that did not receive any AAV. Sections were imaged on Nikon's CFI60 Infinity Optical System with CFI Plan Fluor 10X (MRH00105); CFI Plan Fluor 20X (MRH00205); CFI Plan Fluor 40X (MRH99425) and CFI Plan Fluor 100X Oil (MRH41902). For detecting the signal produced by Td-Tomato the sections were excited with LED-Cy5-A-000: excitation filter (nm) 626-611/18; emission filter (nm) 659.5-701/41 and dichroic mirror (nm) 652. For DAPI nuclear fluorescence detection the sections were excited with DAPI-5060C: excitation filter (nm) 352-402/50; emission filter (nm) 417-477/60 and dichroic mirror (nm) 409.

For Td-Tomato immunodetection 3 µm sections of fixed samples were incubated at 37 °C for 15 min. Deparaffinization was performed by sequential washes in xylene, 100% ethanol, 95% ethanol, 90% ethanol, 70% ethanol, and 50% ethanol, followed by rinsing in running tap water. Antigen retrieval was carried out in 1× Low-pH Antigen Retrieval Solution by heating in a pressure cooker, followed by cooling in citrate buffer to RT. Slides were then washed three times in PBS and blocked for 1 h at RT in a solution containing 3% BSA and 0.3% Triton X-100 in PBS. Sections were incubated overnight at 4 °C with the primary antibody (RFP, rabbit polyclonal, Rockland #600-401-379) diluted 1:200 in antibody diluent (1% BSA + 0.13% Triton X-100 in PBS). After three PBS washes, sections were incubated for 1 h at RT with the secondary antibody diluted 1:500 in the same diluent, together with DAPI, and washed again three times in PBS. TrueBlack® Lipofuscin Autofluorescence Quencher was applied according to the manufacturer's instructions prior to staining, using a freshly prepared solution (1:20 in

70% ethanol) for 30 sec at RT, followed by washes in buffer. Finally, sections were mounted with Ibidi Mounting Medium with DAPI (ref. 50011, Ibidi) for subsequent fluorescence imaging. Images were acquired using an Olympus BX51 Fluorescence Microscope (Leica Microsystems) and processed using Image J (U. S. National Institutes of Health, Bethesda, Maryland, USA).

Digital PCR Analysis of Tissue samples

Tissue samples were lysed and homogenized, and total RNA was extracted using the Maxwell® RSC Instrument (Promega) with the Maxwell® RSC miRNA from Tissue kit, following the supplier's protocol. cDNA was synthesized from the RNA template using a High-Capacity cDNA Reverse Transcription Kit (Applied Biosystems™ 4368813) according to the manufacturer's instructions. The resulting cDNA was used to determine expression levels. Digital PCR (dPCR) was performed on the Applied Biosystems QuantStudio Absolute Q Digital PCR System, a plate-based platform with integrated microfluidic array technology enabling compartmentalization, thermal cycling, and data acquisition in a single instrument. All reactions were run on a 20-well plate. Cycling conditions were optimized per manufacturer recommendations: 95 °C for 10 min, followed by 40 cycles of 96 °C for 5 s and 60 °C for 15 s. A TaqMan TOMATO probe (Invitrogen) was used for copy quantification in cDNA samples, and Absolute Q™ DNA Digital PCR Master Mix (5X, Invitrogen) was employed according to protocol. Data were analyzed using QuantStudio Absolute Q software. Results are expressed as copies per µL of cDNA input; pooling here is the mean of pig level means; error bars reflect pig variability.

Statistical Analysis

Statistical analyses were performed using Student T-test or ANOVA accordingly. Data was represented in graphs using GraphPad Prism version 10 for Mac (GraphPad Software, San Diego, California USA). $p < 0.05$ was considered significant. Excel was used by Aferetica SL for their provided data.

Acknowledgements:

Josep Maria Campistol Planas, nephrologist and the Hospital Clinic de Barcelona Director, for his support and leadership.

Esteban Poch, Head of Nephrology Department, Hospital Clinic de Barcelona (Spain) for his support.

Jordi Carrion, in special, and all the team from Fundació Món Clinic Barcelona (Spain)

Judith Plaza, Jaime Miret, Laura Ramio, Assela Bosch and all the team from VERSA Biomedical.

Aferetica SL team, Graziano Gravina, Afonso Correia and Andjela Kurevija in particular, for their help

Paul Ayestaran (GE Healthcare) for providing fluoroscopy system.

Jose Ramón Rico, radiology technician for his unvaluable help in the first procedure.

François Epinat for his help in data formatting.

References:

1. Stevens, P. E. *et al.* KDIGO 2024 Clinical Practice Guideline for the Evaluation and Management of Chronic Kidney Disease. *Kidney Int.* **105**, S117–S314 (2024).

2. Herrington, W. G., Judge, P. K., Grams, M. E. & Wanner, C. Chronic kidney disease. *Lancet Lond. Engl.* S0140-6736(25)01942–7 (2025) doi:10.1016/S0140-6736(25)01942-7.

3. Ocampo, A. *et al.* In Vivo Amelioration of Age-Associated Hallmarks by Partial Reprogramming. *Cell* **167**, 1719-1733.e12 (2016).

4. Browder, K. C. *et al.* In vivo partial reprogramming alters age-associated molecular changes during physiological aging in mice. *Nat. Aging* **2**, 243–253 (2022).

5. Hernandez-Benitez, R. *et al.* Intervention with metabolites emulating endogenous cell transitions accelerates muscle regeneration in young and aged mice. *Cell Rep. Med.* **5**, 101449 (2024).

6. Aguirre, M. *et al.* Application of the Yamanaka Transcription Factors Oct4, Sox2, Klf4, and c-Myc from the Laboratory to the Clinic. *Genes* **14**, 1697 (2023).

7. Naso, M. F., Tomkowicz, B., Perry, W. L. & Strohl, W. R. Adeno-Associated Virus (AAV) as a Vector for Gene Therapy. *Biodrugs* **31**, 317 (2017).

8. Rubin, J. D., Nguyen, T. V., Allen, K. L., Ayasoufi, K. & Barry, M. A. Comparison of Gene Delivery to the Kidney by Adenovirus, Adeno-Associated Virus, and Lentiviral Vectors after Intravenous and Direct Kidney Injections. *Hum Gene Ther* **30**, 1559–1571 (2019).

9. Furusho, T. *et al.* Enhancing gene transfer to renal tubules and podocytes by context-dependent selection of AAV capsids. *Nat. Commun.* **15**, 10728 (2024).

10. Jagadisan, B. & Dhawan, A. Hepatotoxicity in Adeno-Associated Viral Vector Gene Therapy. *Curr Hepatol Rep* **22**, 276–290 (2023).

11. Zulpaite, R. *et al.* Ex-vivo Kidney Machine Perfusion: Therapeutic Potential. *Front. Med.* **8**, (2021).

12. Montagud-Marrahi, E., Luque, Y., Ros, R. R. & al, et. Ex vivo normothermic preservation of a kidney graft from uncontrolled donation after circulatory death over 73 hours. *Front Bioeng Biotechnol* **11**, 1330043 (2023).

13. Chauhan, M. *et al.* AAV-DJ is superior to AAV9 for targeting brain and spinal cord, and de-targeting liver across multiple delivery routes in mice. *J. Transl. Med.* **22**, 824 (2024).

14. Huang, L. *et al.* Expression of tdTomato and luciferase in a murine lung cancer alters the growth and immune microenvironment of the tumor. *PLOS ONE* **16**, e0254125 (2021).

15. Staelens, L., Langenaeken, T., Rega, F. & Meuris, B. Difference in coagulation systems of large animal species used in cardiovascular research: a systematic review. *J. Artif. Organs* **28**, 1–14 (2025).

16. Kauffmann, E. F. *et al.* 313.12: Hypothermic Oxygenated Machine Perfusion of an En-Bloc Dual Kidney Specimen: Proof of Concept, in an Animal DCD Model, of a New Option to Preserve and Evaluate Kidney Grafts. *Transplantation* **106**, S218 (2022).

17. Елена Аверина: «Мы зарабатываем, чтобы развивать методику ЭКМО». https://vademec.ru/article/elena_averina-_-my_zarabatyvaem-_chtoby_razvivat_metodiku_ekmo%3Ferid%3D2VfnxvHx4jS/.

Figure Legends:

Figure 1. In situ perfusion set up and radiological findings

A, Schematic representation of the in-situ perfusion setup with Perlife device.

B, Upper panel: Kidney arteriography with a balloon catheter (white arrows) filled with a contrast–saline mixture. The arrowheads mark the second occlusion balloon catheter in the kidney vein, also visible in the image. Lower panel: Kidney venography with an occlusion balloon catheter (white arrows) inflated with air; note the absence of contrast leakage

C, Doppler ultrasound showing preserved kidney artery flow with color and pulsed-wave Doppler 6 days after the procedure.

D, Kidney angiography showing preserved arterial vascularization after the procedure.

Figure 2. AAV delivery assessment

A, Red Fluorescence detection with IVIS Lumina device in a pig treated with AAV and comparing perfused and non-perfused kidney.

B, anti-Td-Tomato immunodetection in perfused and non-perfused kidney showing AAV transduction in the perfused kidney, mostly in the tubular cells. White arrows point to parietal glomerular cells.

C, Td-Tomato Digital PCR Analysis of Tissue samples. Bar chart illustrates pooled mean copy numbers per µL across two pigs for each organ, confirming kidney compartments as primary sites of detection.

Supplementary Figures:

Supplemental Figure 1: Aferetica SL® Perlife kidney perfusion machine data (Perfusate Temperature)

Supplemental Figure 2: Aferetica SL® Perlife kidney perfusion machine data (Arterial Flow)

Supplemental Figure 3: Aferetica SL® Perlife kidney perfusion machine data (Vascular Resistance)

Supplemental Figure 4: Aferetica SL® Perlife kidney perfusion machine data (Arterial pressure)

Supplemental Figure 5: Necropsy Kidney Pig 1 Right Kidney

Supplemental Figure 6: Necropsy Kidney Pig 1 Left Kidney

Supplemental Figure 7: Skin aspect post procedure

Supplemental Figure 8: Perfused kidney 6 days after AAV treatment showing detail of the inflammatory infiltrates

Supplemental Figure 9 and 9 bis: Direct detection of Td tomato fluorescence in Fresh Frozen Tissue. Perfused kidney, non-perfused kidney and liver from pig receiving an AAV and liver and kidney controls.

Supplemental Movie 1: Pig behavior the day of the procedure

Conflict of Interest Statement:

YL declares the following competing financial interests: YL has received speaking fees from Aferetica SL after the procedures were performed. YL discloses personal and research support for this work from Fundació Món Clínic Barcelona, Spain.

A

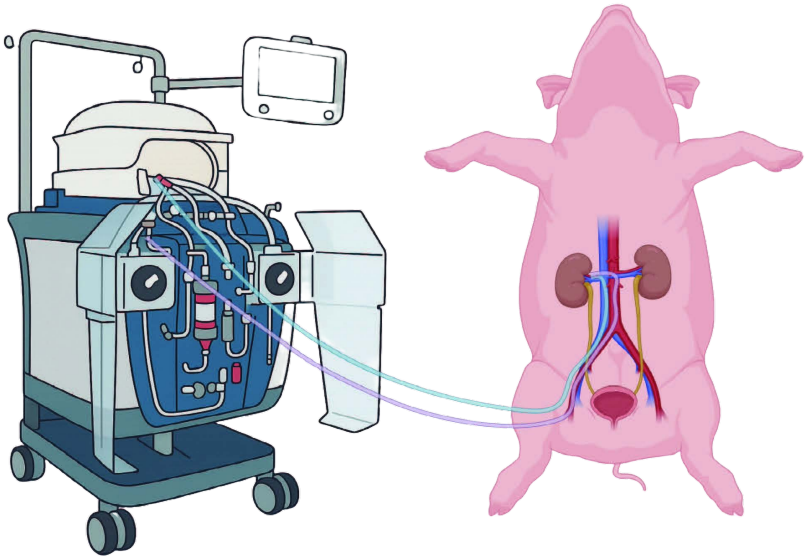

B

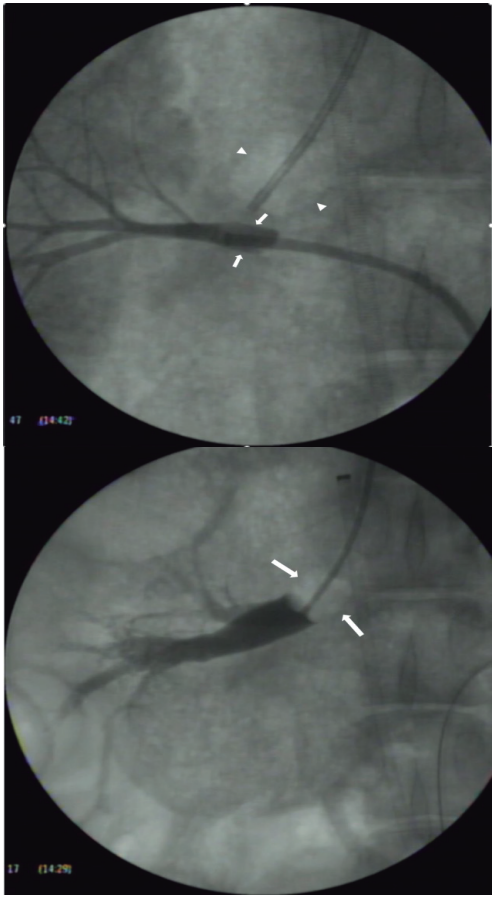

C

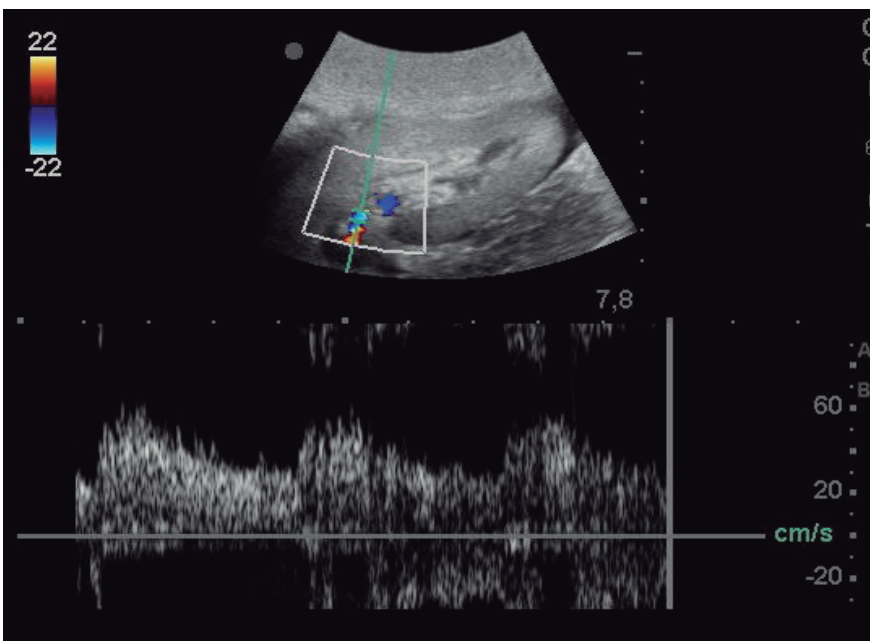

D

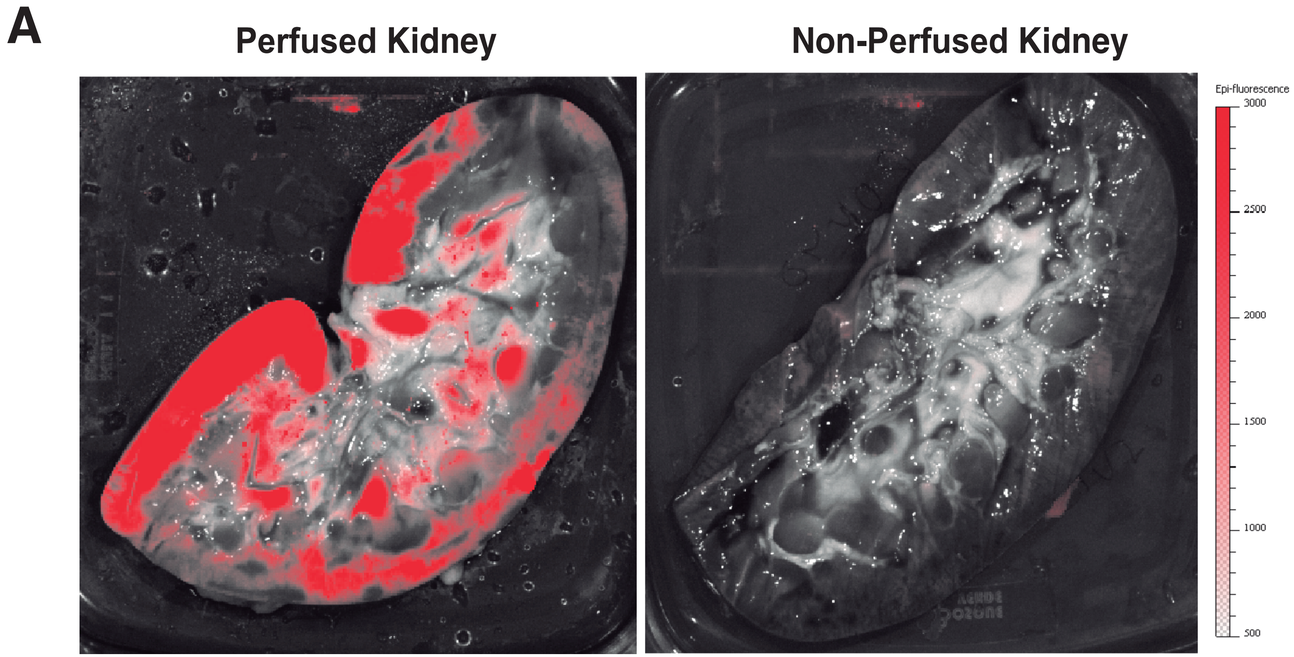
A
Perfused Kidney
Non-Perfused Kidney
Epi-fluorescence
3000
2500
2000
1500
1000
500

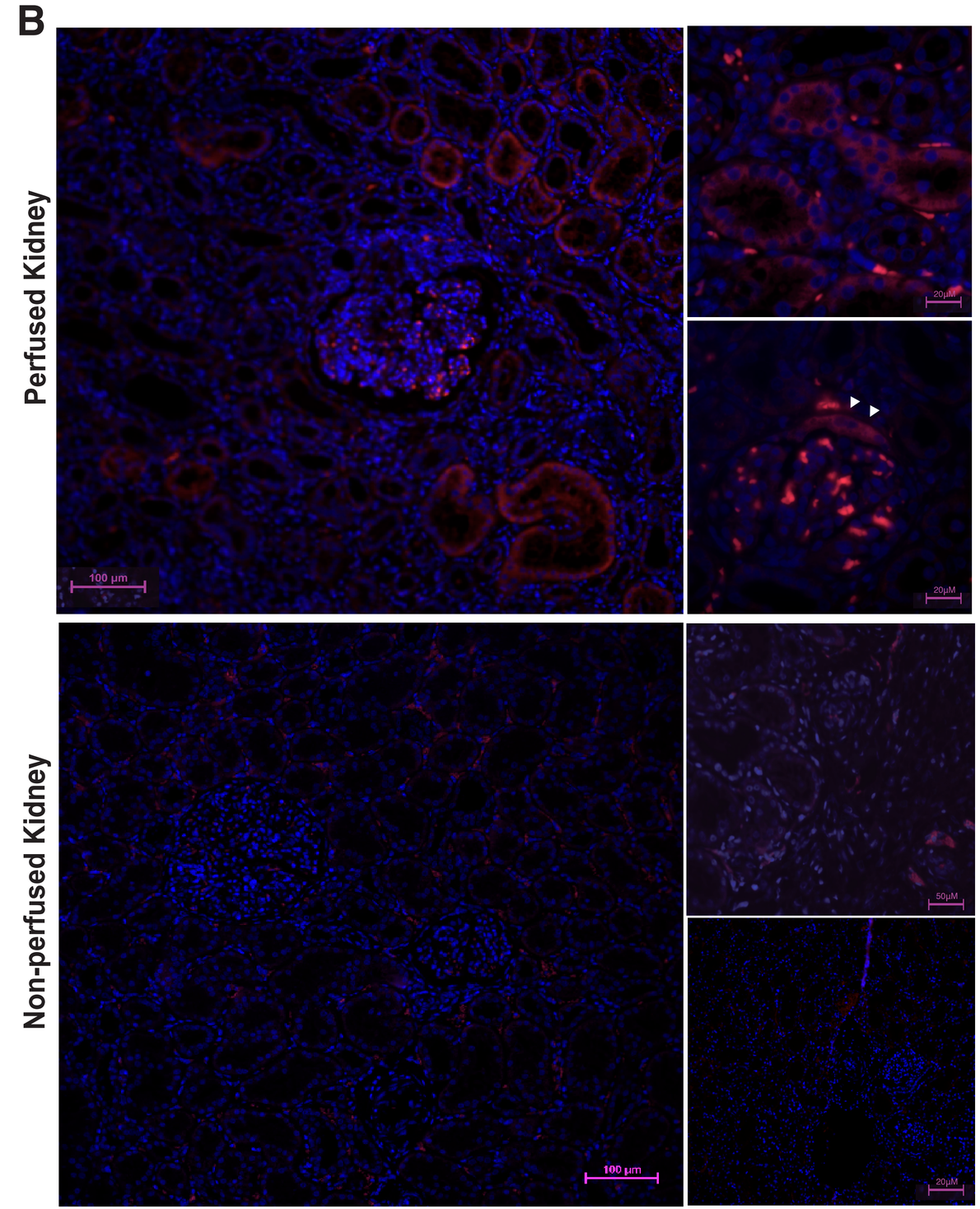
B
Perfused Kidney
Non-perfused Kidney
100 µm
20µM
50µM

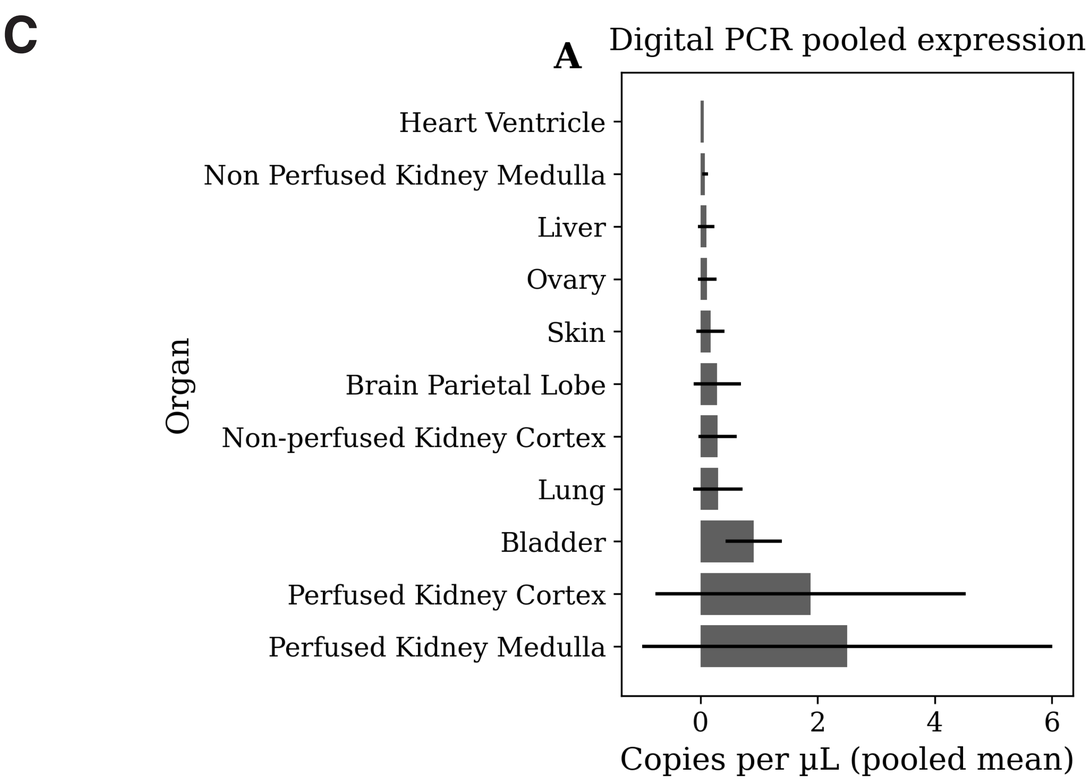
C
A
Digital PCR pooled expression
Heart Ventricle
Non Perfused Kidney Medulla
Liver
Ovary
Skin
Brain Parietal Lobe
Non-perfused Kidney Cortex
Lung
Bladder
Perfused Kidney Cortex
Perfused Kidney Medulla
Organ
0
2
4
6
Copies per µL (pooled mean)