

VERTICAL SULCI DESCRIPTION

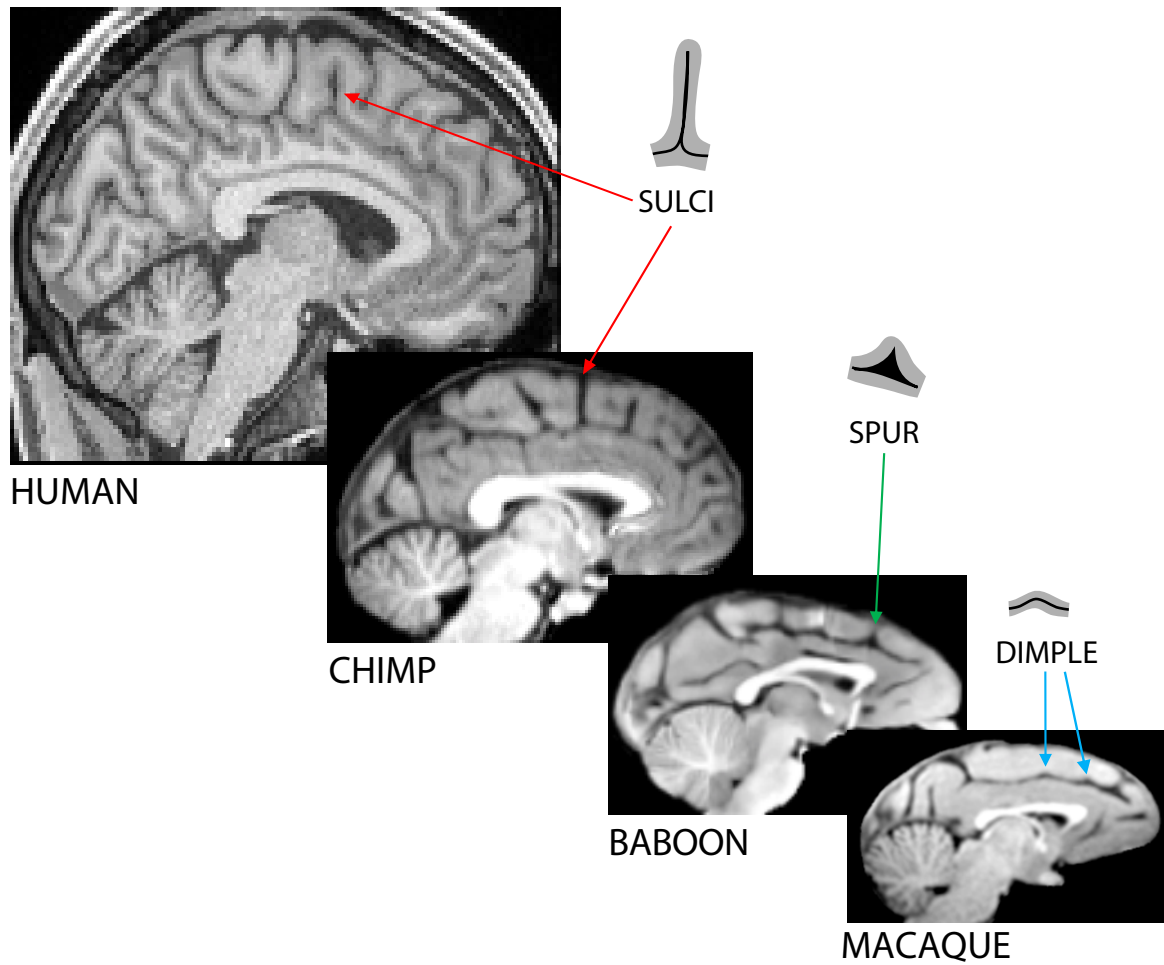


Figure S1. Description of the vertical sulci in the MCC. Vertical sulci are deep sulci in human and chimpanzee, spurs or dimples in baboons.