

Abnormal function in dentate nuclei precedes the onset of psychosis: a resting-state fMRI study in high-risk individuals

Authors

Sheeba Arnold Anteraper^{a,b*}, Xavier Guell^{c,*}, Guusje Collin^{d,e,f}, Zhenghan Qi^g, Jingwen Ren^a, Atira Nair^a, Larry J. Seidman^d, Matcheri S. Keshavan^d, Tianhong Zhang^h, Yingying Tang^h, Huijun Liⁱ, Robert W. McCarley^j, Margaret A. Niznikiewicz^j, Martha E. Shenton^{f,k,l}, William S. Stone^d, Jijun Wang^h, Susan Whitfield-Gabrieli^{a,e}

- a. Department of Psychology, Northeastern University, Boston, MA, USA
- b. Alan and Lorraine Bressler Clinical and Research Program for Autism Spectrum Disorder, Massachusetts General Hospital, Boston MA, USA
- c. Department of Neurology, Massachusetts General Hospital and Harvard Medical School, Boston, MA, USA
- d. Department of Psychiatry, Beth Israel Deaconess Medical Center, Harvard Medical School, Boston, MA, USA
- e. McGovern Institute for Brain Research, Department of Brain and Cognitive Sciences, Massachusetts Institute of Technology, Cambridge, MA, USA
- f. Psychiatry Neuroimaging Laboratory, Department of Psychiatry, Brigham and Women's Hospital, Harvard Medical School, Boston, MA, USA
- g. Department of Linguistics and Cognitive Science, University of Delaware, Newark, DE, USA
- h. Shanghai Key Laboratory of Psychotic Disorders, Shanghai Mental Health Center, Shanghai Jiao Tong University School of Medicine, Shanghai, China
- i. Department of Psychology, Florida A&M University, Tallahassee, FL, USA
- j. Department of Psychiatry, VA Boston Healthcare System, Brockton Division, Brockton, MA, USA
- k. Research and Development, VA Boston Healthcare System, Brockton Division, Brockton, MA, USA
- l. Department of Radiology, Brigham and Women's Hospital, Harvard Medical School, Boston, MA, USA

*These authors contributed equally to this work

Conflict of interest: The authors declare that they have no conflict of interest.

Corresponding Authors:

Sheeba Arnold Anteraper Ph.D., Department of Psychology,
Northeastern University
Email: s.anteraper@northeastern.edu

Jijun Wang M.D., Ph.D.,
Professor of Psychiatry, Shanghai Mental Health Center, Shanghai 200030, China
Email: jijunwang27@163.com

ABSTRACT

Objective: The cerebellum serves a wide range of functions and is suggested to be composed of discrete regions dedicated to unique functions. We recently developed a new parcellation of the dentate nuclei (DN), the major output nuclei of the cerebellum, which optimally divides the structure into three functional territories that contribute uniquely to default-mode, motor-salience, and visual processing networks as indexed by resting-state functional connectivity (RsFc). Here we test for the first time whether RsFc differences in the DN precede the onset of psychosis in individuals at risk of developing schizophrenia.

Methods: We used the MRI dataset from the Shanghai At Risk for Psychosis study that included subjects at high risk to develop schizophrenia (N=144), with longitudinal follow-up to determine which subjects developed a psychotic episode within one year of their fMRI scan (converters N=23). Analysis used the three functional parcels (default-mode, salience-motor, and visual territory) from the DN as seed regions of interest for whole-brain RsFc analysis.

Results: RsFc analysis revealed abnormalities at baseline in high-risk individuals who developed psychosis, compared to high-risk individuals who did not develop psychosis. The nature of the observed abnormalities was found to be anatomically specific such that abnormal RsFc was localized predominantly in cerebral cortical networks that matched the three functional territories of the DN that were evaluated.

Conclusions: We show for the first time that abnormal RsFc of the DN may precede the onset of psychosis. This new evidence highlights the role of the cerebellum as a potential target for psychosis prediction and prevention.

INTRODUCTION

A large and expanding body of evidence has demonstrated that cerebellar structural and functional abnormalities exist in patients diagnosed with neurological and psychiatric disorders that degrade cognition and affect, including Alzheimer's disease (1), Parkinson's disease (2), frontotemporal dementia (1), major depressive disorder (3, 4), autism spectrum disorder (ASD) (5, 6), attention-deficit/hyperactivity disorder (ADHD) (7), dyslexia (8) and schizophrenia (9, 10). Several of these conditions are neurodevelopmental in nature (e.g., ADHD, ASD, dyslexia) and show abnormalities early on. However, much less is known about whether these cerebellar abnormalities precede the manifestation of symptoms in neurodevelopmental conditions with later symptom onsets such as schizophrenia. Existing evidence of cerebellar abnormalities in patients diagnosed with neuropsychiatric disorders improves our understanding of their pathophysiology and may open new avenues for their diagnosis and treatment. The question of whether cerebellar disruption precedes the onset of symptoms in these conditions constitutes a fundamental knowledge gap in neuropsychiatry; addressing this gap will allow investigation of the cerebellum as a potential target for disease prediction and prevention.

Here we aim to test whether abnormalities in the dentate nuclei (DN), a collection of neural bodies buried beneath the cortex of each cerebellar hemisphere (**Figure 1**), precede the onset of symptoms in individuals at risk for schizophrenia. Anatomical connections between cerebellar cortex and extracerebellar territories engaged in thought and affect form the basis of the neuroscience of cerebellar behavioral neurology and psychiatry (11, 12). The DN are central structures in these anatomical pathways, as the majority of the fibers that exit the cerebellar cortex synapse in the DN before reaching extracerebellar structures such as thalamus or cerebral cortex (13). To the best of our knowledge, this is the first study assessing if DN abnormalities precede the onset of symptoms in individuals at risk for schizophrenia.

The evidence for cerebellar abnormalities in schizophrenia is limited in comparison to other brain areas (14) because the cerebellum was long overlooked in psychiatric research due to erroneous notions that it

is not involved in higher cognitive functions and cognitive-behavioral disorders (15). The past two decades, however, have seen a growing interest in the role of the cerebellum in schizophrenia, led by Nancy Andreasen's work on the role of prefrontal-thalamic-cerebellar circuitry in schizophrenia and her cognitive dysmetria hypothesis (16, 17) following Schmahmann's dysmetria of thought theory (12, 18). Neuroimaging studies since then have shown consistent evidence for cerebellar abnormalities in schizophrenia. Task-activation studies indicate both hypo- and (to a lesser extent) hyper-activation of the cerebellum in a range of tasks (19, 20), with review/meta-analytic data suggesting that hypoactivations predominate in medial portions of the anterior lobe and lobules IV and V, while hyperactivations localize more laterally in lobules VI and VII (20) and that abnormalities in task-activation may stem from an altered functional topography of the cerebellum (19). In addition, functional connectivity studies provide robust evidence for abnormalities in cortico-cerebellar and thalamo-cerebellar functional connectivity in patients with schizophrenia and high-risk individuals (10, 21-30). These studies also report both hypo- and hyperconnectivity for different cerebellar regions and distinct cerebro-cerebellar connections, supporting the diverse functional roles and heterogeneous connectivity profiles of individual cerebellar regions (27). Across studies, there appears to be relatively consistent evidence for cerebro-cerebellar hyperconnectivity in some networks including the somatomotor and default-mode network (DMN) (23, 25, 26, 29), while findings for other functional networks are more mixed. For example, some studies report hypoconnectivity between regions of the ventral attention or salience network and corresponding cerebellar clusters (26, 29) while others report hyperconnectivity for similar cerebro-cerebellar connections (27). Recent studies have also shown evidence of abnormal cerebellar functional connectivity in schizophrenia as indexed by functional gradients analyses, highlighting the possibility of large-scale disruptions in communication within and between all major functional territories of the cerebellar hemispheres and their communication with the cerebral cortex (31).

Neuropathological studies have also found evidence for cerebellar pathology in schizophrenia (32), including findings of a decreased density (33) and size (34) of Purkinje cells. The latter finding is particularly

significant as Purkinje cells provide input to deep nuclei including the DN, and thereby play a key role in modulating the output from the cerebellum to the cerebral cortex (17, 34). Moreover, studies in mice show that stimulation of the DN modulates prefrontal dopamine, a neurotransmitter system implicated in schizophrenia (35). This may be part of the mechanism underlying emerging findings that cerebellar stimulation improves symptoms of schizophrenia (36, 37). Taken together, existing evidence suggests that schizophrenia involves an altered functional modulation of higher cortical functions by the cerebellum. As the main output nucleus from cerebellum to the cerebral cortex, the DN may play a key role in this process and may thus be a promising target for intervention. These findings point to the importance of investigating dentate functional anatomy in schizophrenia, but there are no functional MRI studies to date that focus on the DN and its functional connectivity to the cerebral cortex in individuals diagnosed with or at risk for schizophrenia.

The natural history of schizophrenia makes it possible to test whether at-risk individuals reveal DN functional abnormalities that precede the formal onset of the disease. The dataset employed here included subjects at clinical high risk to develop psychosis, with longitudinal follow-up to determine which subjects developed a psychotic episode within one year of their fMRI scan, as described in (38) and determined by standardized diagnostic scales in psychiatry. The prodromal stage is considered a period of imminent risk for psychosis. The clinical high risk paradigm was developed based on observations that the majority of patients with schizophrenia experience a prodromal phase characterized by attenuated or transient psychotic symptoms including unusual thought content, suspiciousness, or mild perceptual abnormalities in the months to years preceding the first psychotic episode. Around 20% of individuals showing such subthreshold symptoms convert to psychosis within 2 years (39). To compare, the annual incidence rates of psychosis in the general population are estimated around 0.5 per 1000. Conversion rates in our current sample are similar to those reported in literature (39, 40), with approximately 16% developing a psychotic episode by one-year follow-up. Of note, our current sample is a subset of the total study sample for whom good-quality fMRI data was available. Clinical profiles and conversion rates on the total sample have been

described in detail previously (41). There is a relatively paucity of studies on outcomes in high-risk non-converters, but it is thought that approximately half maintain stable levels of subthreshold symptoms, while the other half show remission of subthreshold symptoms (42).

Contrasting prior investigations using the whole DN as one single region of analysis, our group recently showed that human DN are optimally divided into three functional territories that contribute uniquely to DMN, motor-salience, and visual processing as indexed by resting-state functional connectivity (RsFc) MRI (43) (**Figure 1**). This improved understanding of a crucial node of cerebellar functional anatomy that can be captured with RsFc, combined with longitudinal data differentiating high-risk subjects who develop psychosis versus high-risk subjects who do not develop psychosis, provides a novel avenue to study functional abnormalities in DN at the earlier stage of pathophysiological development.

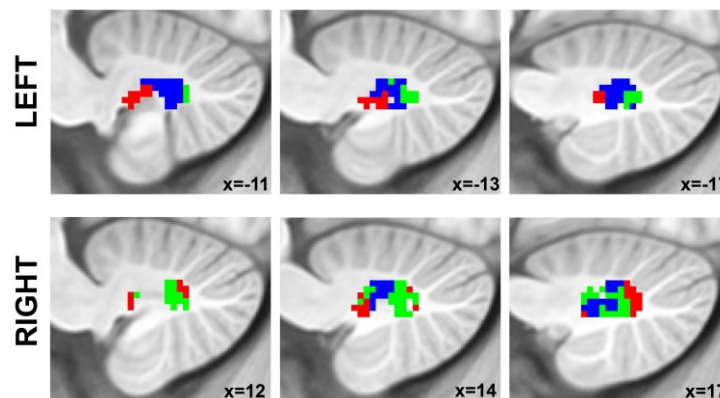


Figure 1: Structural location and functional territories of the dentate nuclei as reported in (43). Red = default-mode network functional territory. Blue = salience-motor functional territory. Green = visual functional territory.

METHODS

Study Participants

The study participants were individuals at Clinical High Risk (CHR) for psychosis (N=144; mean age = 19, age range=13–34) from the Shanghai At Risk for Psychosis (SHARP) program, an international collaborative research effort to recruit a unique sample of medication-naïve adolescents and young adults with early signs of impending psychosis. Twenty-three of the CHR subjects developed psychosis before 1-year clinical follow-up (CHR+). Ninety-three age-, gender-, education-, and handedness-matched healthy controls (HC) (mean age = 18.7, age range=12–35) were also part of this dataset. Clinical characteristics, conversion criteria, and demographics information have been previously reported (38). Briefly, a Chinese version of the Structured Interview for Prodromal Symptoms (SIPS (44)) was used to assess prodromal symptoms. There were no significant differences in baseline SIPS scores in CHR+ compared to CHR participants who did not develop psychosis (CHR-). Institutional Review Boards at Beth Israel Deaconess Medical Center and the Shanghai Mental Health Center approved the study. Informed consent was obtained from all participants or their legal guardians. DSM-IV Alcohol or Drug Dependence within 3 months of study participation was an exclusion criterion to our study. IQ < 70, and any medical condition, sensorimotor handicap, or acquired injury that may either contribute to prodromal symptoms or confound prodromal symptom assessment (e.g., deadness, blindness, acquired brain injury, epilepsy) were also grounds for exclusion. Detailed demographic and clinical characteristics are provided in **Table 1**.

Structural and Resting-state Functional MRI Acquisition Parameters

Imaging data were collected on Siemens 3T MR B17 (Verio) system, with Siemens 32-channel head coil. High-resolution whole-brain structural data (1 mm isotropic voxels) were acquired using a sagittal T1-weighted MPRAGE sequence with duration 9 min 14 s. Scan parameters for TR/TE/Flip Angle were 2.3 s/2.96 ms/9°. Whole-brain resting-state functional data (3.5 mm isotropic voxels) were acquired using a

T2*- weighted EPI sequence with duration 6 min 19 s. Scan parameters for TR/TE/Flip Angle were 2.5 s/30 ms/90°, 37 contiguous slices.

Table 1. Demographic and clinical characteristics

	CHR+ (N = 23)	CHR- (N = 121) ^a	HC (N = 93)	Statistics
Age in years, mean (sd) [range]	19.2 (5.2) [14 – 34]	18.8 (5.0) [13 – 32]	18.7 (4.6) [12 – 35]	$F = 0.10, p = 0.91$
Sex, male/female	16 / 7	57 / 64	49 / 44	$\chi = 3.99, p = 0.14$
Education in years, mean (sd) [range]	10.3 (2.2) [7 – 16]	10.6 (3.0) [4 – 19]	10.8 (2.3) [6 – 17]	$F = 0.35, p = 0.71$
IQb, mean (sd) [range]	92.1 (19.0) [52 – 112]	100.1 (11.7) [67 – 128]	104.2 (11.1) [75 – 133]	$F = 8.06, p < 0.001$
<i>Baseline SIPS scores</i>				
Positive, mean (sd) [range]	10.0 (3.3) [4 – 17]	10.1 (3.8) [0 – 21]		$F = 0.03, p = 0.87$
Negative, mean (sd) [range]	12.1 (6.4) [3 – 26]	11.5 (6.0) [1 – 27]		$F = 0.24, p = 0.63$
Total, mean (sd) [range]	37.6 (10.7) [16 – 65]	37.2 (11.0) [13 – 79]		$F = 0.02, p = 0.90$
<i>Psychotropic medication</i>				
At inclusion, N (%)	1 (4.3%)	6 (5.0%)		$\chi = 0.12, p = 0.90$
At baseline MRI, N (%)	7 (30.4%) ^c	21 (17.4%)		$\chi = 2.11, p = 0.15$
Antipsychotics, N (%)	6 (26.1%)	17 (14.0%)		$\chi = 2.09, p = 0.15$
Antidepressants, N (%)	2 (8.7%)	4 (3.3%)		$\chi = 1.41, p = 0.24$
Anxiolytics, N (%)	1 (4.3%)	0 (0%)		$\chi = 5.30, p = 0.02$

^a Of note, the CHR- group is smaller than in a previous publication on this sample (Collin et al., 2018), because the current study excluded 14 CHR- who were lost to follow-up. ^b IQ data were unavailable for 4 CHR+, 16 CHR-, and 9 HC. ^c The number of CHR converters on psychotropic medication at the time of baseline MRI (N = 7) is lower than the sum across medication types, because two individuals were on two different medications (i.e., combining an antipsychotic with an antidepressant or anxiolytic).

Data processing: Seed-to-voxel Functional Connectivity Analysis

Resting-state fMRI data were realigned and spatially normalized to the MNI template using SPM12 (Wellcome Department of Imaging Neuroscience; www.fil.ion.ucl.ac.uk/spm). Structural images were segmented into white matter (WM), gray matter, and cerebrospinal fluid (CSF) using SPM12. The CONN Toolbox (45) was used to compute whole-brain r-maps from the seed regions of interest (ROIs). ROIs, defined at the group level, included the whole DN (as defined using the SUIT DN mask; (46)), and three functional sub-territories of DN that were defined in a previous study by our group (43), including DMN, motor-salience, and visual functional regions (**Figure 1**). The CONN Toolbox uses an anatomical component-based correction method (aCompCor, (47)) for denoising BOLD time-series and integrates quality assurance methods (Artifact Detection Tools, www.nitrc.org/projects/artifact_detect). Band-pass filtering was carried out at 0.008 – 0.09 Hz. Time points with mean signal intensity outside three standard deviations from global mean signal, and 0.4 mm scan-to-scan motion (about 1/10th the acquisition voxel size) were flagged as problematic scans. There was no significant between-group difference (CHR+ versus CHR-) in the number of time-points that were flagged as motion outliers ($p=0.87$) and these time-points were regressed out along with six realignment parameters and physiological sources of noise (three principal components of WM, and three principal components of CSF segments, using aCompCor; (47)). WM and CSF segments were derived from the structural images using the segmentation routine in SPM12. Because of the small size of the DN, unsmoothed data was used for data analysis to minimize partial volume effects from structures close to DN. This strategy has been employed previously for functional connectivity analysis of dentate ROIs (48). Whole brain Pearson's correlation maps derived from denoised time-series from whole DN and the three DN functional territories were converted to z-scores using Fischer's r to z transformation to carry out second-level general linear model (GLM) analyses.

Data processing: Second Level GLM Analysis

For all three groups (HC, CHR+, and CHR-), seed-to-voxel analysis was carried out using the whole DN as a seed, as well as using the unique effect of each of the three functional territories (DMN, salience-motor, and visual). The unique effect of each functional territory was calculated using the same analysis method as in (43), i.e., the DMN unique effect was calculated as $DMN > (salience-motor \text{ and } visual)$, salience-motor unique effect was calculated as $salience-motor > (DMN \text{ and } visual)$, and visual unique effect was calculated as $visual > (DMN \text{ and } salience-motor)$. Statistical significance thresholding for three-group effects (using ANOVA) included $p < 0.005$ (two-sided) at the voxel level and $p < 0.05$ False Discovery Rate (FDR) correction at the cluster level.

RESULTS

Second Level GLM Analysis

When using the whole DN as a seed, group contrasts between CHR+ and CHR- did not show statistically significant differences. In contrast, statistically significant differences were detected for each of the three functional sub-regions in DN (DMN, salience-motor, and visual). For the DN-DMN functional territory, the CHR+ group showed increased functional connectivity with the posterior cingulate cortex (PCC), right angular gyrus (AG), and dorsolateral prefrontal cortex (DLPFC); and decreased functional connectivity with primary and supplementary motor areas (**Figure 2A**). For the DN salience-motor functional territory, the CHR+ group showed increased functional connectivity with the postcentral gyrus; and decreased functional connectivity with the angular gyrus (**Figure 2B**). For the DN-visual functional territory, the CHR+ group showed increased functional connectivity with the dorsal anterior cingulate cortex; and decreased functional connectivity with precuneus / visual association areas, as well as DLPFC (**Figure 2C**). Cluster statistics are reported in **Table 2**.

Taken together, the anatomical specificity of the observed group-differences can be summarized as follows. For DMN and salience-motor territories of the DN, we observed hyperconnectivity to cerebral cortical areas belonging to the same functional network, and hypoconnectivity to cerebral cortical areas belonging to a different functional network, with the exception of DLPFC that was hyperconnected to the non-matching DMN territory of the DN. The opposite was true for the visual territory of the DN: we observed hypoconnectivity to cerebral cortical areas belonging to the same functional network, and hyperconnectivity to cerebral cortical areas belonging to a different functional network, with the exception of DLPFC that was hypoconnected to the visual functional territory of the DN.

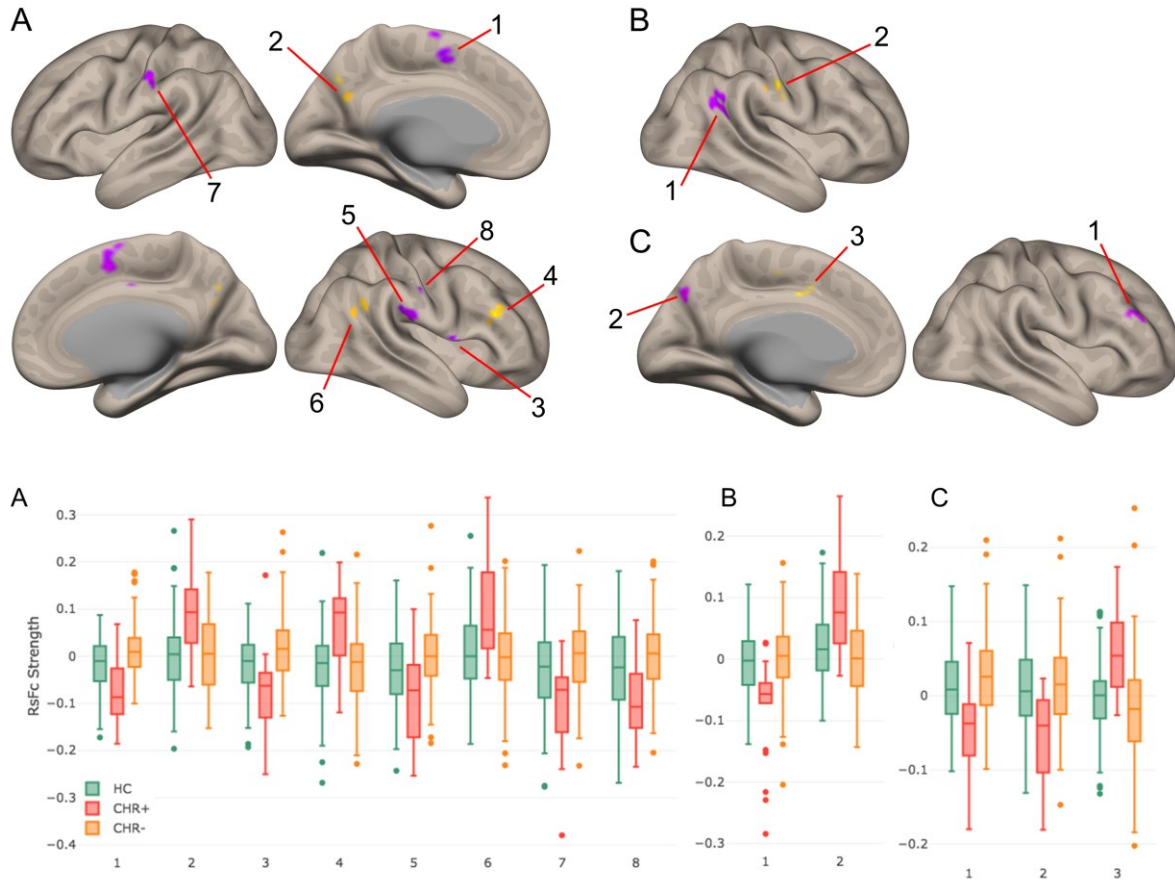


Figure 2. Top: Group contrast results (CHR+ versus CHR-) using functional connectivity calculated from the DMN functional territory of the DN (A), salience-motor functional territory of the DN (B), and visual functional territory of the DN (C), at voxel-level height threshold of $p < 0.005$ (two-sided) and cluster size FDR correction of $p < 0.05$. Bar plots at the bottom of the figure provide data for each cluster in CHR+ and CHR-, as well as data for the same clusters in the control group. Notably, for each of these group contrasts, data from CHR- participants were similar to healthy controls.

Table 2. Results from second-level seed-to-voxel analysis for CHR+ versus CHR- contrast for each functional territory within the DN (height-threshold = $p < 0.005$ (two-sided); cluster threshold = $p < 0.05$ FDR corrected).

Contrast: CHR+ vs. CHR-	Region	Cluster Size	Maximum T-value	MNI Coordinates (X, Y, Z)		
DMN	Supplementary motor cortex	192	-7.15	8	4	52
	Precuneus cortex / posterior cingulate cortex	102	4.83	0	-70	38
	Central opercular cortex	75	-6.06	52	6	0
	Dorsolateral prefrontal cortex (dlPFC)	60	5.17	44	30	24
	Primary somatosensory cortex	59	-5.44	58	-22	20
	Angular gyrus	57	4.85	54	-50	24
	Premotor cortex	54	-5.32	-54	-24	38
	Secondary somatosensory cortex	46	-5.20	58	-20	38
Saliency-Motor	Angular gyrus	116	-5.92	48	-50	22
	Postcentral Gyrus	60	5.51	58	-18	38
Visual	dlPFC	66	-5.60	44	40	28
	Precuneus cortex / visual association areas	63	-5.66	-2	-74	36
	Dorsal anterior cingulate cortex	47	5.54	-2	-2	42

DISCUSSION

Here we show for the first time that abnormalities in functional connectivity between the DN and cerebral cortical areas may precede the onset of psychosis. This conclusion is supported by DN resting-state fMRI connectivity measurements in individuals with early signs of impending psychosis. Our data revealed abnormalities in those high-risk individuals who subsequently developed psychosis, compared to high-risk individuals who did not develop psychosis. Furthermore, our results reveal anatomical specificity in the distribution of these functional abnormalities, as abnormal functional connectivity was observed to be localized predominantly in cerebral cortical networks associated with the three functional territories of the DN that were evaluated. Evaluation of functional connectivity from whole DN as a single region of interest did not reveal significant between group differences. Group-differences were only detected when analyzing functional connectivity from each of the three functional sub-territories of the DN defined in the atlas developed previously by our group (43). DN functional sub-divisions are thus useful to detect DN functional differences in disorders of thought and affect. Taken together, this new evidence highlights the role of the DN as a potential target for disease prediction and prevention in neuropsychiatric disorders.

Anatomical specificity of DN functional connectivity differences and possible pathophysiological interpretations

Our interpretation for our findings of the distinctive topography of the DN connectivity pattern between at-risk subjects who developed psychosis versus at-risk subjects who did not develop psychosis (**Figure 2**) is as follows. For DMN and salience-motor DN territories, two shared principles (a, b) and one exception (c) are observed. The first principle (a) is that hyperconnectivity was observed in cerebral cortical areas belonging to the same DN functional territory that was being examined. The DMN functional territory of the DN was hyperconnected to cerebral cortical areas associated with the DMN including posterior cingulate cortex and angular gyrus. Similarly, the salience-motor functional territory of the DN was hyperconnected to primary motor and motor association areas of the cerebral cortex. The second

principle (b) is that hypoconnectivity was observed in cerebral cortical areas that did not belong to the same network as the specific DN functional territory that was being examined. DMN functional territory of the DN was hypoconnected to primary motor, motor association, and supramarginal gyrus, which belong to motor and task-positive networks, not DMN. Again, similarly, the salience-motor functional territory of the DN was hypoconnected to the angular gyrus, which belongs to DMN. The only exception (c) is that right DLPFC, which belongs to task-positive networks rather than DMN, was hyperconnected to the DMN territory of the DN. For the visual territory of the DN, we observed a reversal of these observations (a, b, c). Hypoconnectivity was observed with visual association areas; this finding is a reversal of observation (a), and hyperconnectivity was observed with the anterior cingulate cortex that is not linked to visual networks; this finding is a reversal of observation (b). Hypoconnectivity rather than hyperconnectivity was observed with DLPFC; since DLPFC does not belong to the visual network, this finding is a reversal of observation (c).

The pathophysiological significance of these observations is difficult to establish, as the group-differences observed here may represent pathological abnormalities, compensatory reorganizations, or a combination of both. The fact that DLPFC showed a reversed direction of effect compared to the other areas of the cerebral cortex may indicate a reversed pathophysiological significance of the DLPFC compared to other cerebral cortical territories. For example, altered DLPFC-DN functional connectivity may represent a pathological abnormality in at-risk individuals who go on to develop psychosis, while the other observed alterations in functional connectivity may represent compensatory reorganizations, or vice versa. The same is true for the DN visual territory that revealed an opposite pattern of functional abnormality compared to the other two DN functional territories – abnormal functional connectivity in DN visual domains might contribute differently to the brain correlates of pre-clinical DN abnormal functional connectivity in schizophrenia when compared to DMN or salience-motor DN functional areas. In light of the recent reports on impairments in integration-segregation balance in schizophrenia (49), the results we report can be interpreted as DMN and motor parts of DN being more strongly integrated with the same systems in the cerebral cortex but more segregated with other systems (thus anticorrelated).

Prior evidence linking psychosis risk and schizophrenia to cerebellum, as well as to DMN, salience-motor, and visual processing networks

Our study is the first to report abnormalities in functional connectivity of the DN within the cerebellum in this population, and also the first to report involvement of DMN, salience-motor, and visual networks in schizophrenia and psychosis risk by assessing these networks using seeds in the DN.

Cerebellar abnormalities are commonly reported in studies of schizophrenia. Structural cerebellar abnormalities in schizophrenia were identified decades ago (50), an observation that has been recently confirmed in a multi-site mega-analysis of close to one thousand patients (51). Moreover, PET (52) and fMRI (53) investigations detected abnormalities in cerebellar function, an observation that was later expanded to include non-schizophrenic subjects who are at an increased clinical (22, 23, 54, 55) or genetic risk (30, 56, 57) of developing schizophrenia. Cellular (34) and molecular (58) studies further support a role of the cerebellum in the pathophysiology of this disorder. Our study is the first to include the DN in the large and growing body of evidence linking cerebellum to schizophrenia, and the first to show DN abnormalities that precede the onset of cognitive and affective brain disease.

A large body of evidence has linked abnormalities in brain regions that belong to the DMN to schizophrenia, including studies that analyze resting-state functional connectivity (55, 59), task-activation (59-61), and structural data (see figure 4 in (51)). Other studies have also detected abnormalities not only within nodes of the DMN but also between DMN and other networks in schizophrenia, such as the salience network (62). Primary motor and sensory cortices have also been shown to exhibit abnormalities as indexed by functional (63) and structural analyses (64) (65) of patients diagnosed with schizophrenia or individuals at risk for developing this disease. Visual network abnormalities have also been detected in fMRI investigations of schizophrenia (66). A recent study using the same dataset

reported abnormal functional connectivity in a broad range of functional territories in cerebral cortex preceding the onset of psychosis (38).

Our results provide further support for the notion that there is a wide range of functional networks implicated in the pathophysiology of schizophrenia, including in the mechanisms of disease that precede conversion to psychosis in individuals at risk, which can be captured by analyzing whole-brain functional connectivity from DN. A recently developed technique, *lesion network mapping*, assessed 89 brain lesions causing hallucinations and attributed DN for lesions causing auditory hallucinations (67). This finding may indicate that functional abnormalities of DN are especially relevant to the concurrent pathophysiology of emerging psychosis in individuals at risk. Recent developments in the field of neuromodulation and neurostimulation suggest that it may be possible in the near future to target specific sub-territories in human DN non-invasively (36, 68-71), hinting at potential future therapeutic interventions focused on DN sub-territories for the treatment or prevention of psychosis.

Acknowledgements

This study was supported by the Ministry of Science and Technology of China (2016 YFC 1306803), US National Institute of Mental Health (R21 MH 093294, R01 MH 101052, and R01 MH 111448), and the European Union's Horizon 2020 research and innovation program under the Marie Skłodowska-Curie grant agreement No. 749201 (to GC); MSK was supported by an NIMH Grant (R01 MH 64023); MES and RWM were supported by a VA Merit Award.

Author contributions

LJS passed away on 7 September 2017 and RWM passed away on 27 May 2017. LJS and RWM were two of the initiators and principal investigators of the Shanghai At Risk for Psychosis (SHARP) study.

Conflict of interest statement: The authors declare that they have no conflict of interest.

References

1. Guo CC, Tan R, Hodges JR, Hu X, Sami S, Hornberger M. Network-selective vulnerability of the human cerebellum to Alzheimer's disease and frontotemporal dementia. *Brain : a journal of neurology*. 2016;139(Pt 5):1527-38.
2. Wu T, Hallett M. The cerebellum in Parkinson's disease. *Brain : a journal of neurology*. 2013;136(Pt 3):696-709.
3. Guo W, Liu F, Xue Z, Gao K, Liu Z, Xiao C, et al. Abnormal resting-state cerebellar-cerebral functional connectivity in treatment-resistant depression and treatment sensitive depression. *Progress in neuro-psychopharmacology & biological psychiatry*. 2013;44:51-7.
4. Yucel K, Nazarov A, Taylor VH, Macdonald K, Hall GB, Macqueen GM. Cerebellar vermis volume in major depressive disorder. *Brain structure & function*. 2013;218(4):851-8.
5. Arnold Anteraper S, Guell X, D'Mello A, Joshi N, Whitfield-Gabrieli S, Joshi G. Disrupted Cerebrocerebellar Intrinsic Functional Connectivity in Young Adults with High-Functioning Autism Spectrum Disorder: A Data-Driven, Whole-Brain, High-Temporal Resolution Functional Magnetic Resonance Imaging Study. *Brain connectivity*. 2019;9(1):48-59.
6. Stoodley CJ, D'Mello AM, Ellegood J, Jakkamsetti V, Liu P, Nebel MB, et al. Altered cerebellar connectivity in autism and cerebellar-mediated rescue of autism-related behaviors in mice. *Nature neuroscience*. 2017;20(12):1744-51.
7. Castellanos FX, Lee PP, Sharp W, Jeffries NO, Greenstein DK, Clasen LS, et al. Developmental trajectories of brain volume abnormalities in children and adolescents with attention-deficit/hyperactivity disorder. *Jama*. 2002;288(14):1740-8.
8. Nicolson RI, Fawcett AJ. Dyslexia, dysgraphia, procedural learning and the cerebellum. *Cortex; a journal devoted to the study of the nervous system and behavior*. 2011;47(1):117-27.
9. Cao H, Cannon TD. Cerebellar Dysfunction and Schizophrenia: From "Cognitive Dysmetria" to a Potential Therapeutic Target. *Am J Psychiatry*. 2019;176(7):498-500.
10. Collin G, Hulshoff Pol HE, Haijma SV, Cahn W, Kahn RS, van den Heuvel MP. Impaired cerebellar functional connectivity in schizophrenia patients and their healthy siblings. *Front Psychiatry*. 2011;2:73.
11. Schmahmann JD. From movement to thought: anatomic substrates of the cerebellar contribution to cognitive processing. *Hum Brain Mapp*. 1996;4(3):174-98.
12. Schmahmann JD, Guell X, Stoodley CJ, Halko MA. The Theory and Neuroscience of Cerebellar Cognition. *Annu Rev Neurosci*. 2019;42:337-64.
13. Haines DE, Dietrichs E. The cerebellum - structure and connections. *Handbook of clinical neurology*. 2012;103:3-36.
14. Shenton ME, Dickey CC, Frumin M, McCarley RW. A review of MRI findings in schizophrenia. *Schizophr Res*. 2001;49(1-2):1-52.
15. Andreasen NC, Pierson R. The role of the cerebellum in schizophrenia. *Biol Psychiatry*. 2008;64(2):81-8.
16. Andreasen NC, O'Leary DS, Cizadlo T, Arndt S, Rezai K, Ponto LL, et al. Schizophrenia and cognitive dysmetria: a positron-emission tomography study of dysfunctional prefrontal-thalamic-cerebellar circuitry. *Proc Natl Acad Sci U S A*. 1996;93(18):9985-90.
17. Andreasen NC, Paradiso S, O'Leary DS. "Cognitive dysmetria" as an integrative theory of schizophrenia: a dysfunction in cortical-subcortical-cerebellar circuitry? *Schizophr Bull*. 1998;24(2):203-18.
18. Schmahmann JD. An emerging concept. The cerebellar contribution to higher function. *Arch Neurol*. 1991;48(11):1178-87.
19. Bernard JA, Mittal VA. Dysfunctional Activation of the Cerebellum in Schizophrenia: A Functional Neuroimaging Meta-Analysis. *Clin Psychol Sci*. 2015;3(4):545-66.

20. Lungu O, Barakat M, Laventure S, Debas K, Proulx S, Luck D, et al. The incidence and nature of cerebellar findings in schizophrenia: a quantitative review of fMRI literature. *Schizophr Bull*. 2013;39(4):797-806.
21. Anticevic A, Cole MW, Repovs G, Murray JD, Brumbaugh MS, Winkler AM, et al. Characterizing thalamo-cortical disturbances in schizophrenia and bipolar illness. *Cereb Cortex*. 2014;24(12):3116-30.
22. Anticevic A, Haut K, Murray JD, Repovs G, Yang GJ, Diehl C, et al. Association of Thalamic Dysconnectivity and Conversion to Psychosis in Youth and Young Adults at Elevated Clinical Risk. *JAMA Psychiatry*. 2015;72(9):882-91.
23. Cao H, Chen OY, Chung Y, Forsyth JK, McEwen SC, Gee DG, et al. Cerebello-thalamo-cortical hyperconnectivity as a state-independent functional neural signature for psychosis prediction and characterization. *Nat Commun*. 2018;9(1):3836.
24. Chen YL, Tu PC, Lee YC, Chen YS, Li CT, Su TP. Resting-state fMRI mapping of cerebellar functional dysconnections involving multiple large-scale networks in patients with schizophrenia. *Schizophr Res*. 2013;149(1-3):26-34.
25. Guo W, Liu F, Chen J, Wu R, Zhang Z, Yu M, et al. Resting-state cerebellar-cerebral networks are differently affected in first-episode, drug-naive schizophrenia patients and unaffected siblings. *Sci Rep*. 2015;5:17275.
26. Guo W, Zhang F, Liu F, Chen J, Wu R, Chen DQ, et al. Cerebellar abnormalities in first-episode, drug-naive schizophrenia at rest. *Psychiatry Res Neuroimaging*. 2018;276:73-9.
27. Kim DJ, Moussa-Tooks AB, Bolbecker AR, Apthorp D, Newman SD, O'Donnell BF, et al. Cerebellar-cortical dysconnectivity in resting-state associated with sensorimotor tasks in schizophrenia. *Hum Brain Mapp*. 2020;41(11):3119-32.
28. Repovs G, Csernansky JG, Barch DM. Brain network connectivity in individuals with schizophrenia and their siblings. *Biol Psychiatry*. 2011;69(10):967-73.
29. Shinn AK, Baker JT, Lewandowski KE, Ongur D, Cohen BM. Aberrant cerebellar connectivity in motor and association networks in schizophrenia. *Front Hum Neurosci*. 2015;9:134.
30. Whalley HC, Simonotto E, Marshall I, Owens DG, Goddard NH, Johnstone EC, et al. Functional disconnectivity in subjects at high genetic risk of schizophrenia. *Brain*. 2005;128(Pt 9):2097-108.
31. Dong D, Luo C, Guell X, Wang Y, He H, Duan M, et al. Compression of Cerebellar Functional Gradients in Schizophrenia. *Schizophr Bull*. 2020.
32. Katsetos CD, Hyde TM, Herman MM. Neuropathology of the cerebellum in schizophrenia--an update: 1996 and future directions. *Biol Psychiatry*. 1997;42(3):213-24.
33. Reyes MG, Gordon A. Cerebellar vermis in schizophrenia. *Lancet*. 1981;2(8248):700-1.
34. Tran KD, Smutzer GS, Doty RL, Arnold SE. Reduced Purkinje cell size in the cerebellar vermis of elderly patients with schizophrenia. *Am J Psychiatry*. 1998;155(9):1288-90.
35. Mittleman G, Goldowitz D, Heck DH, Blaha CD. Cerebellar modulation of frontal cortex dopamine efflux in mice: relevance to autism and schizophrenia. *Synapse*. 2008;62(7):544-50.
36. Brady RO, Jr., Gonsalvez I, Lee I, Ongur D, Seidman LJ, Schmahmann JD, et al. Cerebellar-Prefrontal Network Connectivity and Negative Symptoms in Schizophrenia. *Am J Psychiatry*. 2019;176(7):512-20.
37. Demirtas-Tatlidede A, Freitas C, Cromer JR, Safar L, Ongur D, Stone WS, et al. Safety and proof of principle study of cerebellar vermal theta burst stimulation in refractory schizophrenia. *Schizophr Res*. 2010;124(1-3):91-100.
38. Collin G, Seidman LJ, Keshavan MS, Stone WS, Qi Z, Zhang T, et al. Functional connectome organization predicts conversion to psychosis in clinical high-risk youth from the SHARP program. *Mol Psychiatry*. 2018.
39. Fusar-Poli P, Cappucciati M, Borgwardt S, Woods SW, Addington J, Nelson B, et al. Heterogeneity of Psychosis Risk Within Individuals at Clinical High Risk: A Meta-analytical Stratification. *JAMA Psychiatry*. 2016;73(2):113-20.
40. Jongsma HE, Gayer-Anderson C, Lasalvia A, Quattrone D, Mule A, Szoke A, et al. Treated Incidence of Psychotic Disorders in the Multinational EU-GEI Study. *JAMA Psychiatry*. 2018;75(1):36-46.

41. Li H, Zhang T, Xu L, Tang Y, Cui H, Wei Y, et al. A comparison of conversion rates, clinical profiles and predictors of outcomes in two independent samples of individuals at clinical high risk for psychosis in China. *Schizophr Res*. 2018;197:509-15.
42. Kahn RS, Sommer IE, Murray RM, Meyer-Lindenberg A, Weinberger DR, Cannon TD, et al. Schizophrenia. *Nat Rev Dis Primers*. 2015;1:15067.
43. Guell X, D'Mello AM, Hubbard NA, Romeo RR, Gabrieli JDE, Whitfield-Gabrieli S, et al. Functional Territories of Human Dentate Nucleus. *Cerebral cortex*. 2019.
44. Zheng JY, Zhang LH, Li JJ, Li JR, Cheng CF. [Chinese version of the reflux symptom index was evaluated for reliability and validity]. *Zhonghua er bi yan hou tou jing wai ke za zhi = Chinese journal of otorhinolaryngology head and neck surgery*. 2012;47(11):894-8.
45. Whitfield-Gabrieli S, Nieto-Castanon A. Conn: a functional connectivity toolbox for correlated and anticorrelated brain networks. *Brain connectivity*. 2012;2(3):125-41.
46. Diedrichsen J, Maderwald S, Kuper M, Thurling M, Rabe K, Gizewski ER, et al. Imaging the deep cerebellar nuclei: a probabilistic atlas and normalization procedure. *Neuroimage*. 2011;54(3):1786-94.
47. Behzadi Y, Restom K, Liou J, Liu TT. A component based noise correction method (CompCor) for BOLD and perfusion based fMRI. *Neuroimage*. 2007;37(1):90-101.
48. Bernard JA, Peltier SJ, Benson BL, Wiggins JL, Jaeggi SM, Buschkuhl M, et al. Dissociable functional networks of the human dentate nucleus. *Cerebral cortex*. 2014;24(8):2151-9.
49. Duan J, Xia M, Womer FY, Chang M, Yin Z, Zhou Q, et al. Dynamic changes of functional segregation and integration in vulnerability and resilience to schizophrenia. *Hum Brain Mapp*. 2019;40(7):2200-11.
50. Heath RG, Franklin DE, Shraberg D. Gross pathology of the cerebellum in patients diagnosed and treated as functional psychiatric disorders. *J Nerv Ment Dis*. 1979;167(10):585-92.
51. Moberget T, Doan NT, Alnaes D, Kaufmann T, Cordova-Palomera A, Lagerberg TV, et al. Cerebellar volume and cerebellocerebral structural covariance in schizophrenia: a multisite mega-analysis of 983 patients and 1349 healthy controls. *Mol Psychiatry*. 2018;23(6):1512-20.
52. Volkow ND, Levy A, Brodie JD, Wolf AP, Cancro R, Van Gelder P, et al. Low cerebellar metabolism in medicated patients with chronic schizophrenia. *Am J Psychiatry*. 1992;149(5):686-8.
53. Muller JL, Roder C, Schuierer G, Klein HE. Subcortical overactivation in untreated schizophrenic patients: a functional magnetic resonance image finger-tapping study. *Psychiatry and clinical neurosciences*. 2002;56(1):77-84.
54. Bernard JA, Orr JM, Mittal VA. Cerebello-thalamo-cortical networks predict positive symptom progression in individuals at ultra-high risk for psychosis. *NeuroImage Clinical*. 2017;14:622-8.
55. Wang H, Guo W, Liu F, Wang G, Lyu H, Wu R, et al. Patients with first-episode, drug-naive schizophrenia and subjects at ultra-high risk of psychosis shared increased cerebellar-default mode network connectivity at rest. *Sci Rep*. 2016;6:26124.
56. Guo W, Liu F, Zhang Z, Liu G, Liu J, Yu L, et al. Increased Cerebellar Functional Connectivity With the Default-Mode Network in Unaffected Siblings of Schizophrenia Patients at Rest. *Schizophr Bull*. 2015;41(6):1317-25.
57. Whalley HC, Simonotto E, Flett S, Marshall I, Ebmeier KP, Owens DG, et al. fMRI correlates of state and trait effects in subjects at genetically enhanced risk of schizophrenia. *Brain : a journal of neurology*. 2004;127(Pt 3):478-90.
58. Eastwood SL, Cotter D, Harrison PJ. Cerebellar synaptic protein expression in schizophrenia. *Neuroscience*. 2001;105(1):219-29.
59. Whitfield-Gabrieli S, Thermenos HW, Milanovic S, Tsuang MT, Faraone SV, McCarley RW, et al. Hyperactivity and hyperconnectivity of the default network in schizophrenia and in first-degree relatives of persons with schizophrenia. *Proceedings of the National Academy of Sciences of the United States of America*. 2009;106(4):1279-84.
60. Damme KSF, Pelletier-Baldelli A, Cowan HR, Orr JM, Mittal VA. Distinct and opposite profiles of connectivity during self-reference task and rest in youth at clinical high risk for psychosis. *Hum Brain Mapp*. 2019;40(11):3254-64.

61. de Leeuw M, Kahn RS, Zandbelt BB, Widschwendter CG, Vink M. Working memory and default mode network abnormalities in unaffected siblings of schizophrenia patients. *Schizophr Res.* 2013;150(2-3):555-62.
62. Pelletier-Baldelli A, Bernard JA, Mittal VA. Intrinsic Functional Connectivity in Salience and Default Mode Networks and Aberrant Social Processes in Youth at Ultra-High Risk for Psychosis. *PLoS One.* 2015;10(8):e0134936.
63. Xiao B, Wang S, Liu J, Meng T, He Y, Luo X. Abnormalities of localized connectivity in schizophrenia patients and their unaffected relatives: a meta-analysis of resting-state functional magnetic resonance imaging studies. *Neuropsychiatric disease and treatment.* 2017;13:467-75.
64. Lincoln SH, Hooker CI. Neural structure and social dysfunction in individuals at clinical high risk for psychosis. *Psychiatry Res.* 2014;224(3):152-8.
65. Dazzan P, Soulsby B, Mechelli A, Wood SJ, Velakoulis D, Phillips LJ, et al. Volumetric abnormalities predating the onset of schizophrenia and affective psychoses: an MRI study in subjects at ultrahigh risk of psychosis. *Schizophr Bull.* 2012;38(5):1083-91.
66. van de Ven V, Rotarska Jagiela A, Oertel-Knochel V, Linden DEJ. Reduced intrinsic visual cortical connectivity is associated with impaired perceptual closure in schizophrenia. *NeuroImage Clinical.* 2017;15:45-52.
67. Kim NY, Hsu J, Talmasov D, Joutsa J, Soussand L, Wu O, et al. Lesions causing hallucinations localize to one common brain network. *Mol Psychiatry.* 2019.
68. Folloni D, Verhagen L, Mars RB, Fouragnan E, Constans C, Aubry JF, et al. Manipulation of Subcortical and Deep Cortical Activity in the Primate Brain Using Transcranial Focused Ultrasound Stimulation. *Neuron.* 2019;101(6):1109-16 e5.
69. Grossman N, Bono D, Dedic N, Kodandaramaiah SB, Rudenko A, Suk HJ, et al. Noninvasive Deep Brain Stimulation via Temporally Interfering Electric Fields. *Cell.* 2017;169(6):1029-41 e16.
70. Lee W, Kim H, Jung Y, Song IU, Chung YA, Yoo SS. Image-guided transcranial focused ultrasound stimulates human primary somatosensory cortex. *Sci Rep.* 2015;5:8743.
71. Verhagen R, Bour LJ, Odekerken VJJ, van den Munckhof P, Schuurman PR, de Bie RMA. Electrode Location in a Microelectrode Recording-Based Model of the Subthalamic Nucleus Can Predict Motor Improvement After Deep Brain Stimulation for Parkinson's Disease. *Brain sciences.* 2019;9(3).