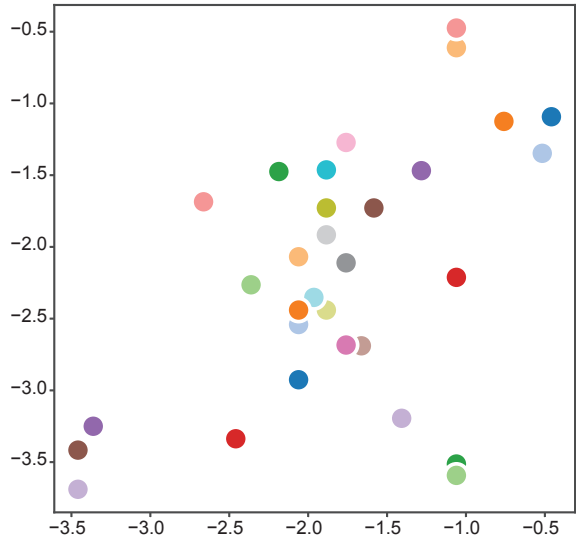


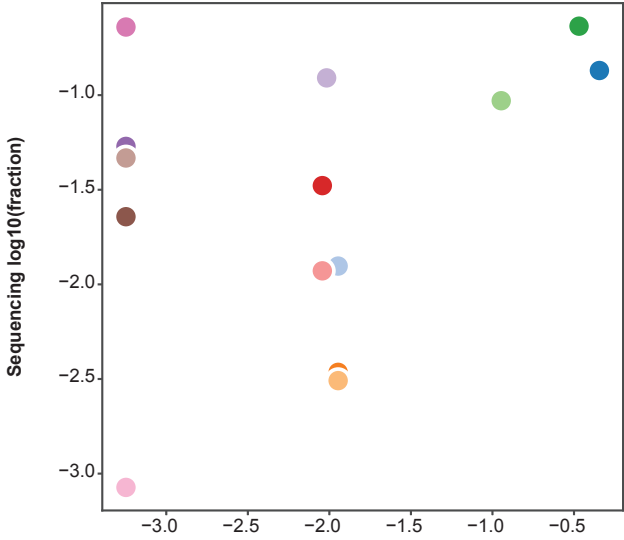
Fig. S8

A Lung



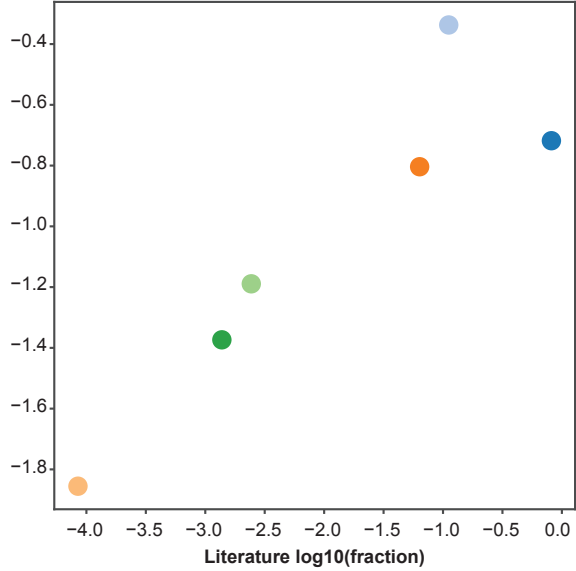
- endothelial cell
- capillary endothelial cell
- type i pneumocyte
- type ii pneumocyte
- fibroblast
- myofibroblast cell
- pericyte cell
- macrophage
- t-cell
- smooth muscle cell
- lung ciliated cell
- vascular associated smooth muscle cell
- bronchial smooth muscle cell
- classical monocyte
- intermediate monocyte
- endothelial cell of artery
- vein endothelial cell
- nk cell
- non-classical monocyte
- neutrophil
- bronchial vessel endothelial cell
- endothelial cell of lymphatic vessel
- plasma cell
- dendritic cell
- club cell
- basophil
- plasmacytoid dendritic cell
- respiratory goblet cell
- pulmonary ionocyte
- respiratory mucous cell
- serous cell of epithelium of bronchus

B Bladder



- bladder urothelial cell
- vein endothelial cell
- endothelial cell of lymphatic vessel
- capillary endothelial cell
- fibroblast
- myofibroblast cell
- pericyte cell
- b cell
- plasma cell
- t cell
- nk cell
- mast cell
- macrophage
- plasmacytoid dendritic cell

C Muscle



- endothelial cell
- mesenchymal stem cell
- skeletal muscle satellite stem cell
- skeletal muscle fiber
- t-cell
- macrophage