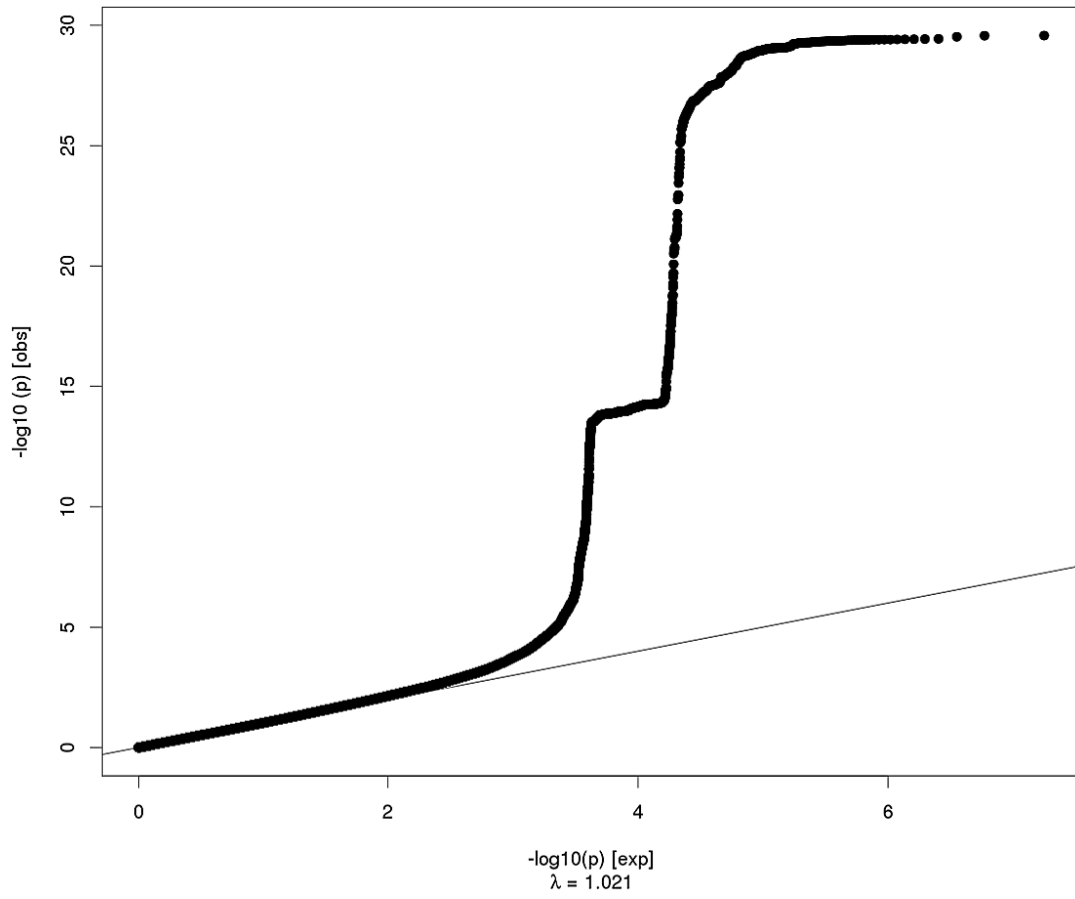


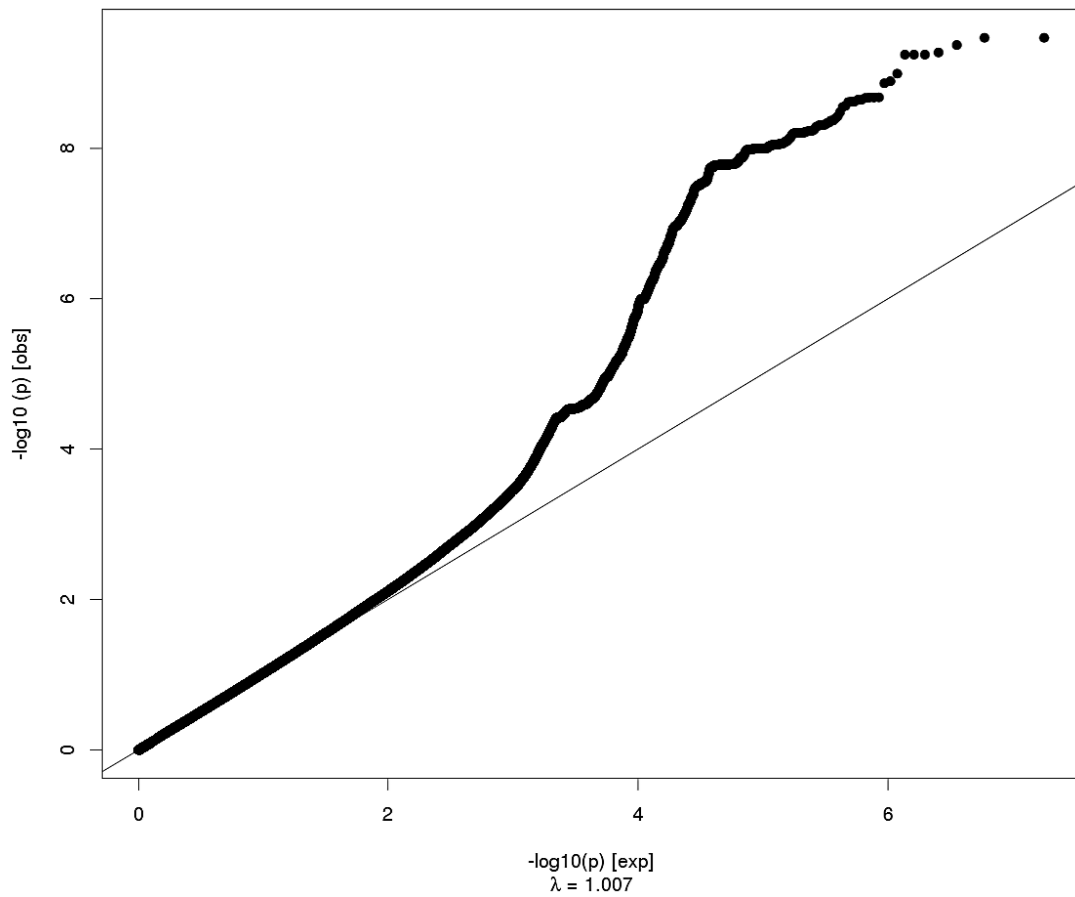
QQ plots

Region#	Phenotype	Page
0	Global	2
1	Frontal Pole	3
2	Medial Orbitofrontal	4
3	Lateral Orbitofrontal	5
4	Rostral Anterior Cingulate	6
5	Caudal Anterior Cingulate	7
6	Superior Frontal	8
7	Rostral Middle Frontal	9
8	Pars Orbitalis	10
9	Pars Triangularis	11
10	Pars Opercularis	12
11	Caudal Middle Frontal	13
12	Paracentral	14
13	Precentral	15
14	Postcentral	16
15	Precuneus	17
16	Superior Parietal	18
17	Supramarginal	19
18	Inferior Parietal	20
19	Posterior Cingulate	21
20	Isthmus Cingulate	22
21	Insula	23
22	Entorhinal	24
23	Parahippocampal	25
24	Fusiform	26
25	Temporal Pole	27
26	Inferior Temporal	28
27	Middle Temporal	29
28	Superior Temporal	30
29	Banks of the Superior Temporal Sulcus	31
30	Transverse Temporal	32
31	Lingual	33
32	Pericalcarine	34
33	Cuneus	35
34	Lateral Occipital	36

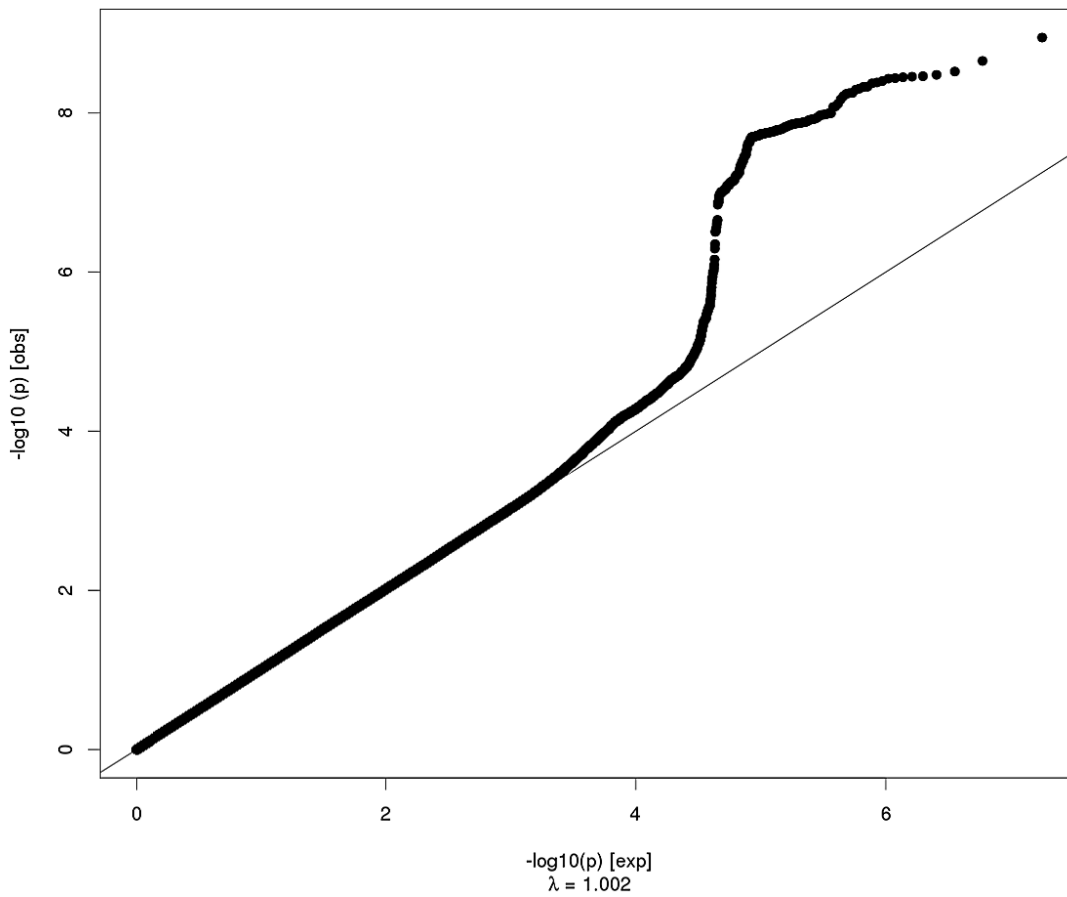
Global Surface Area



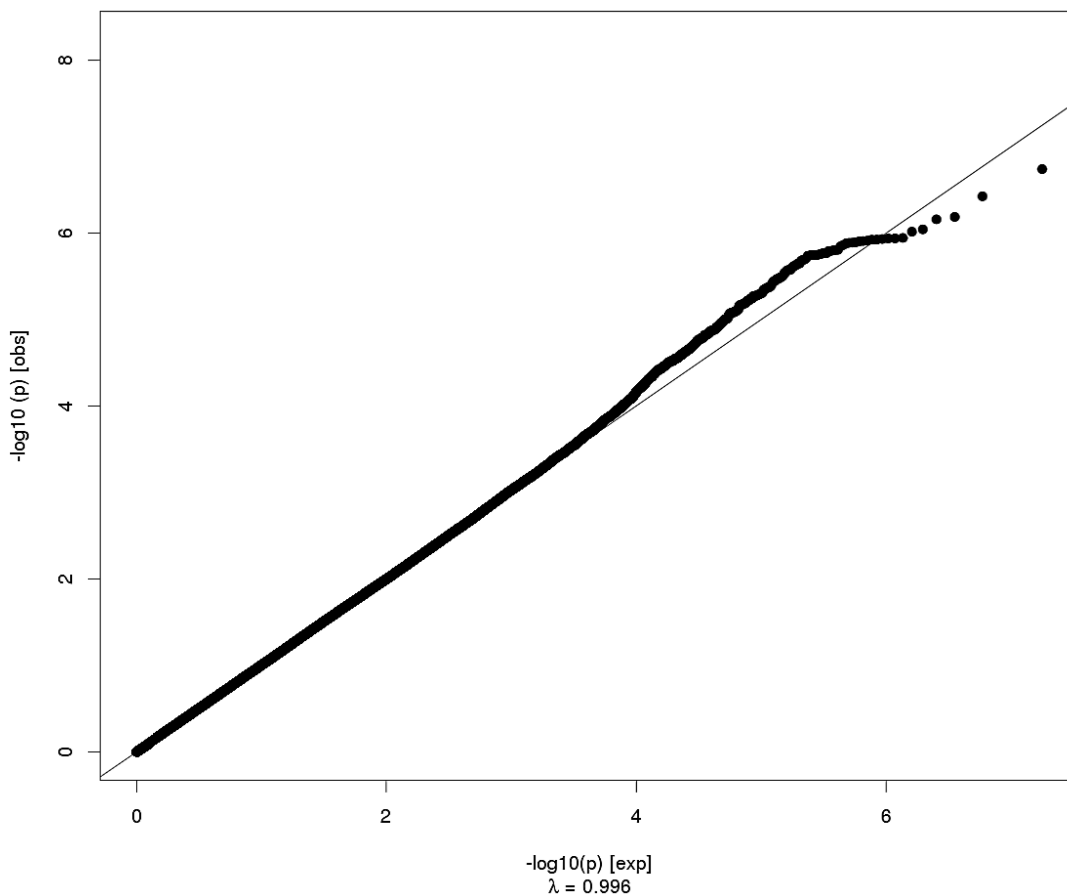
Global Thickness



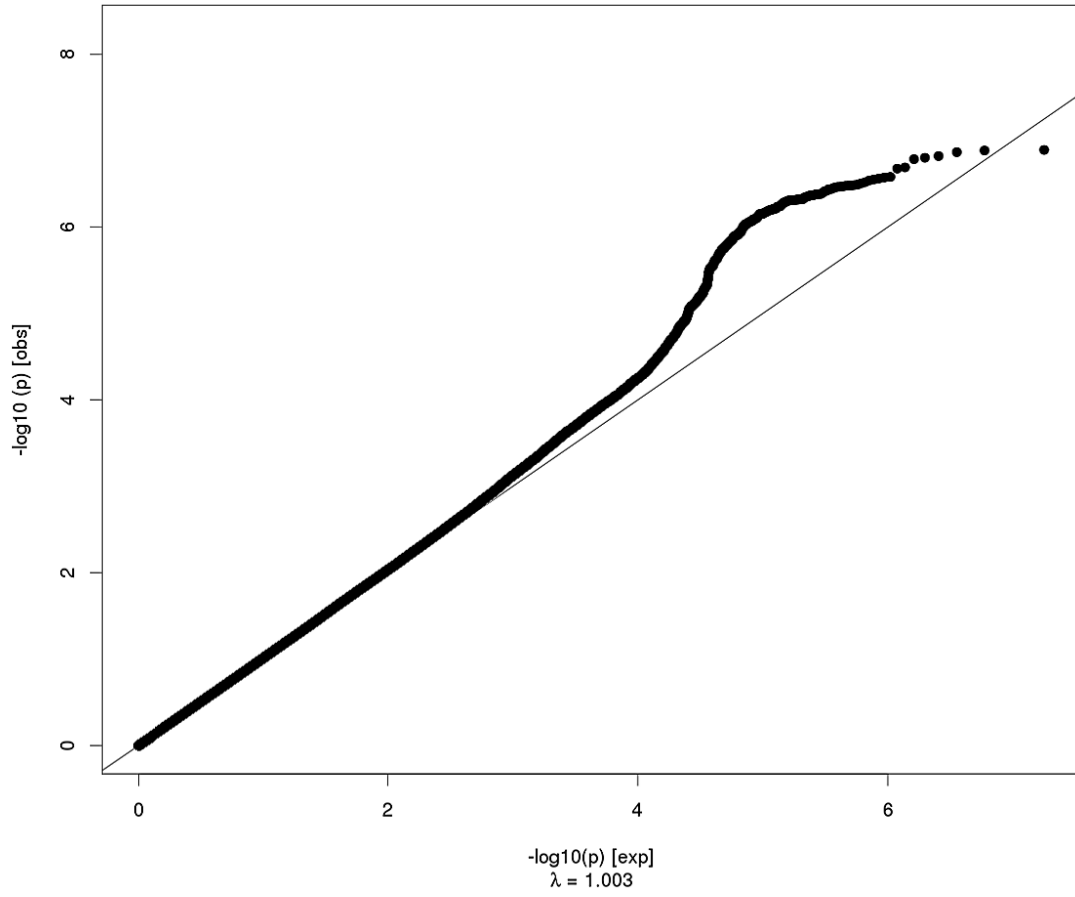
Frontal Pole Surface Area



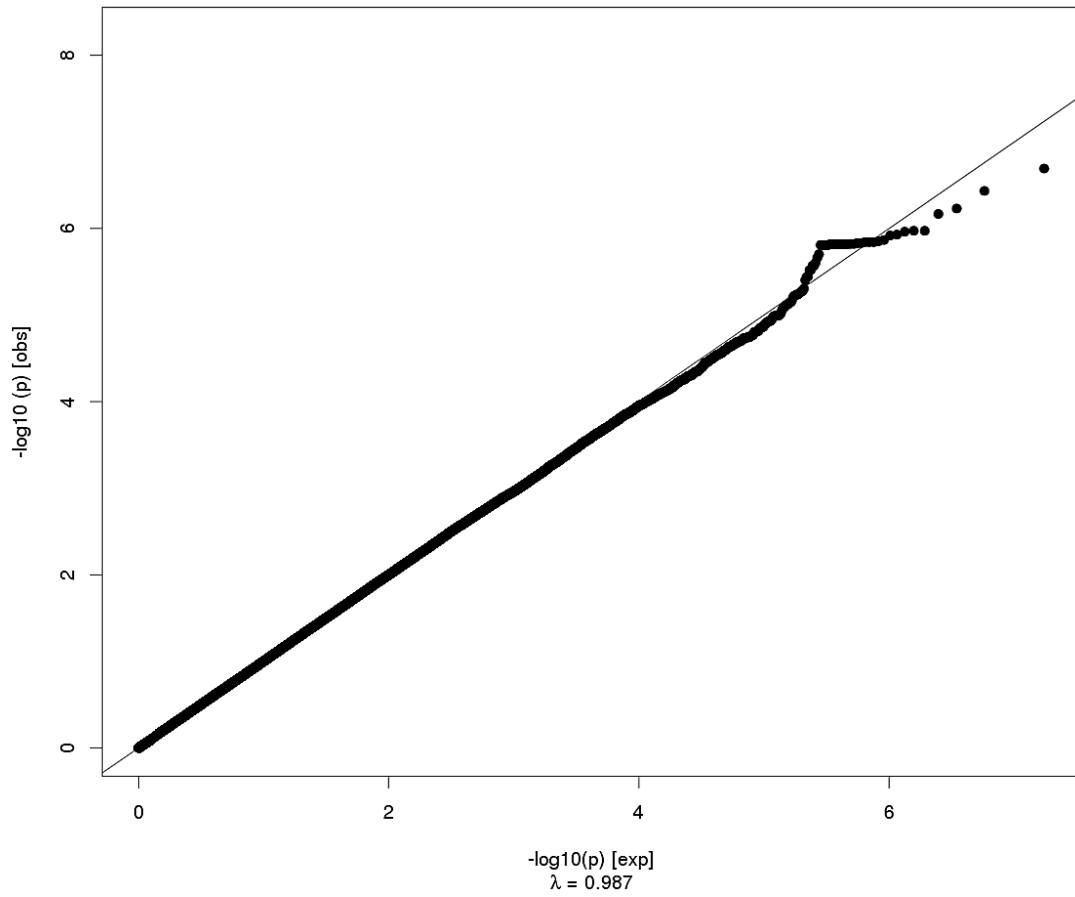
Frontal Pole Thickness



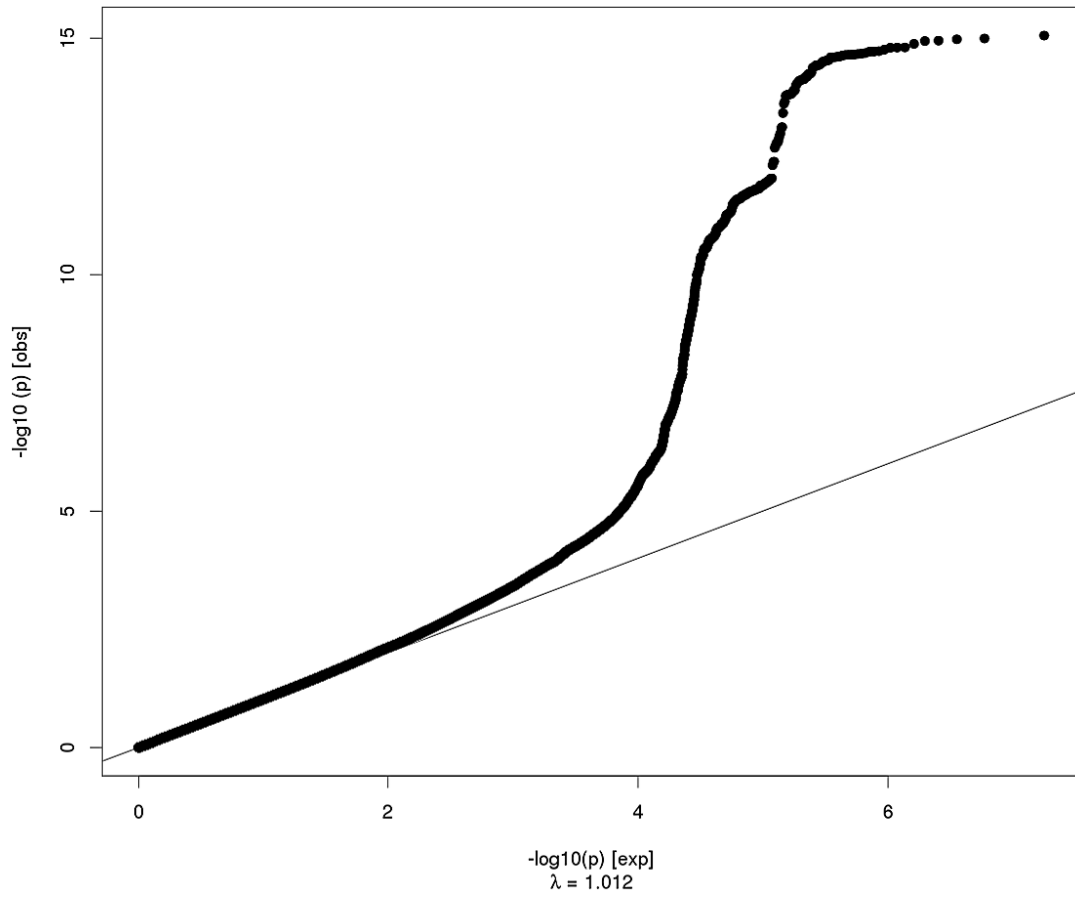
Medial Orbitofrontal Surface Area



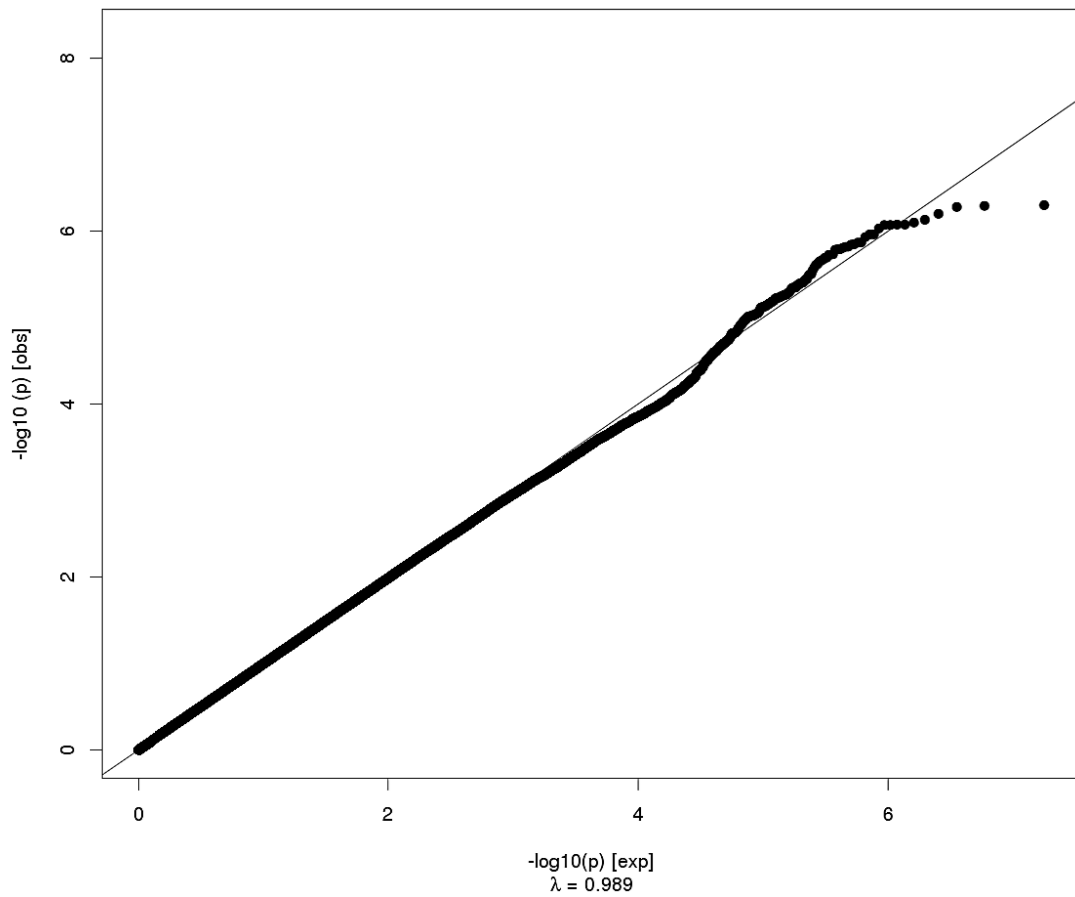
Medial Orbitofrontal Thickness



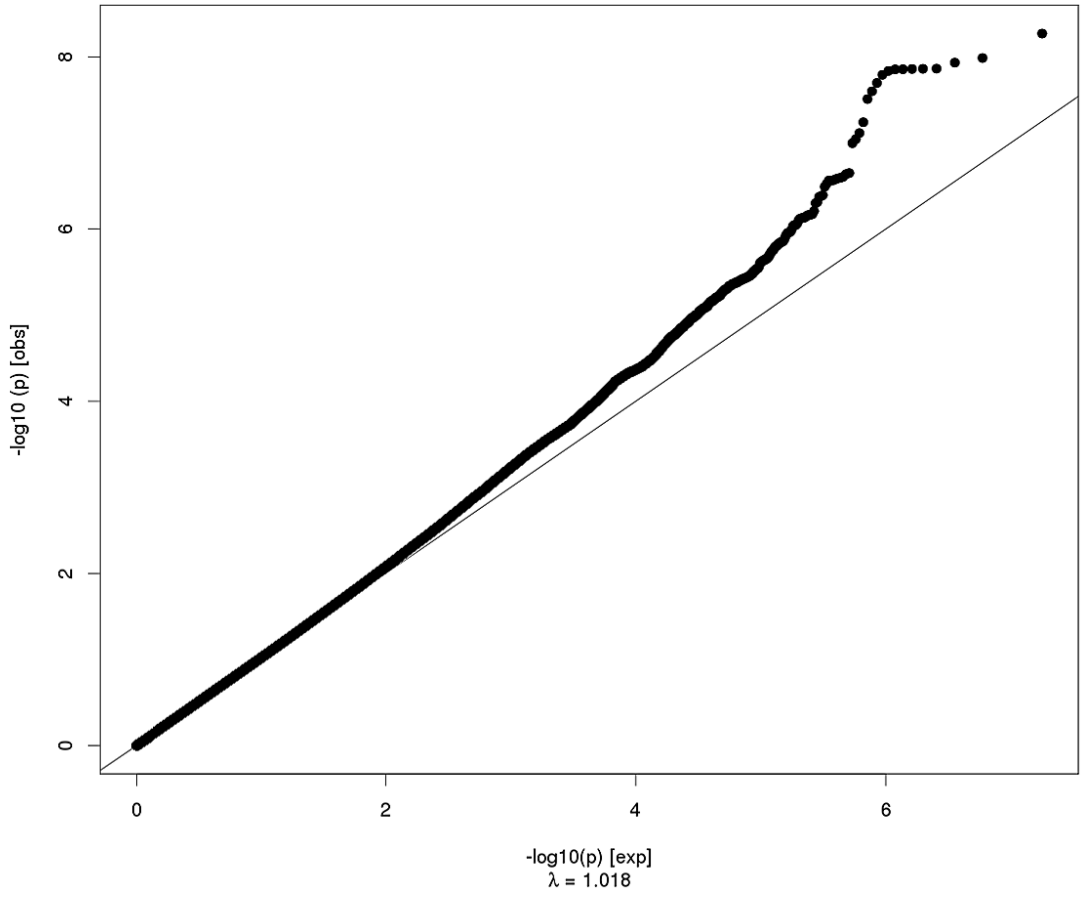
Lateral Orbitofrontal Surface Area



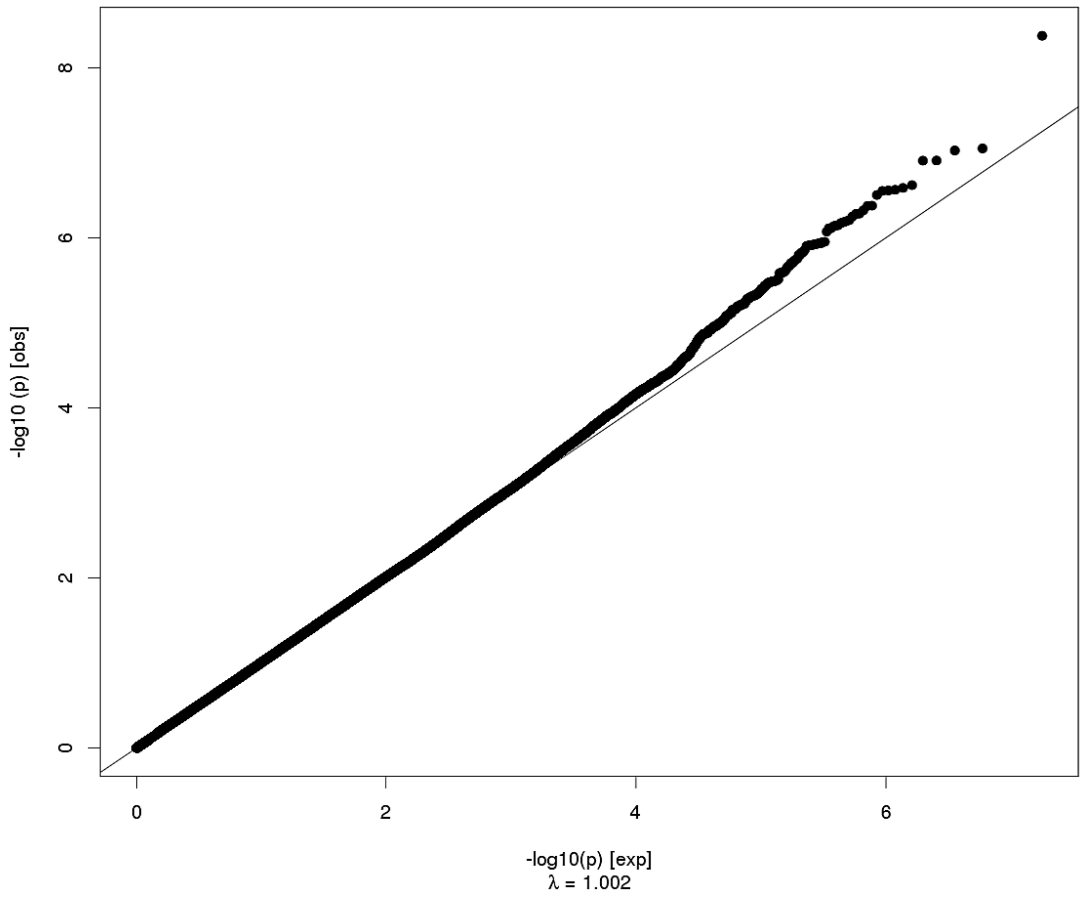
Lateral Orbitofrontal Thickness



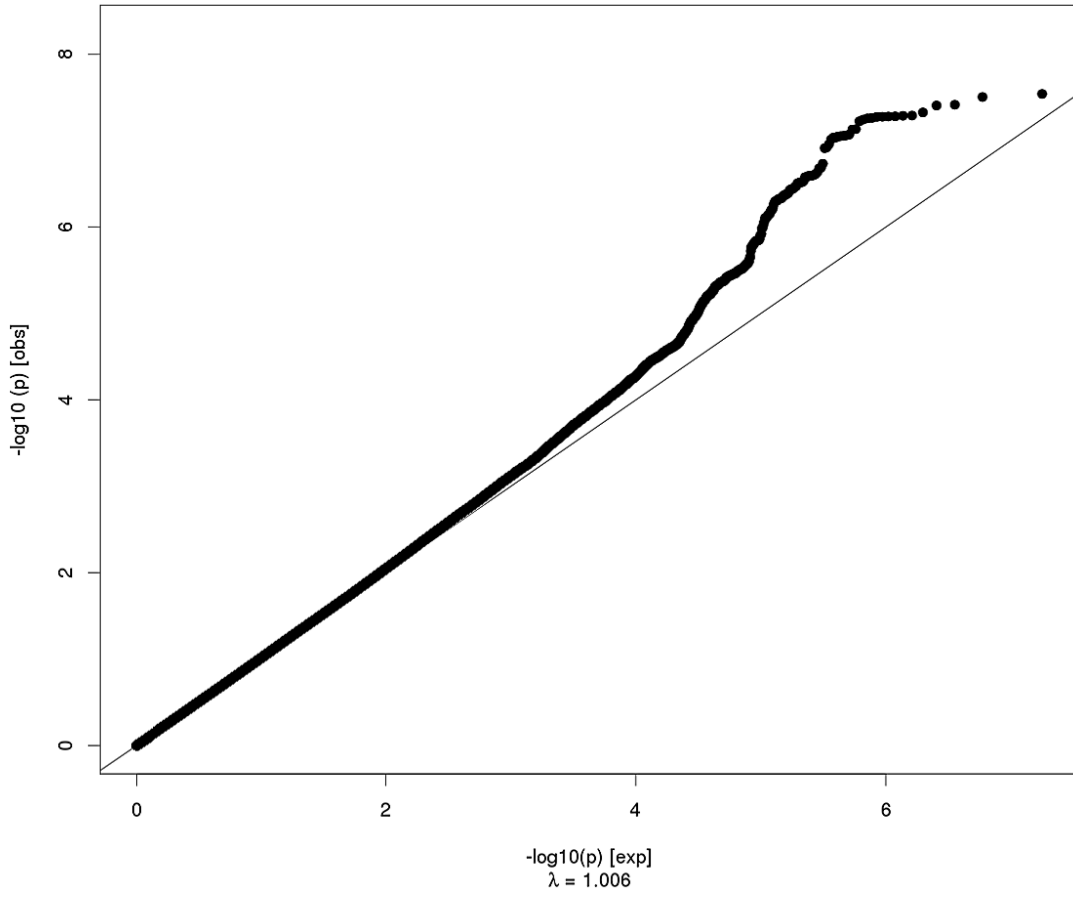
Rostral Anterior Cingulate Surface Area



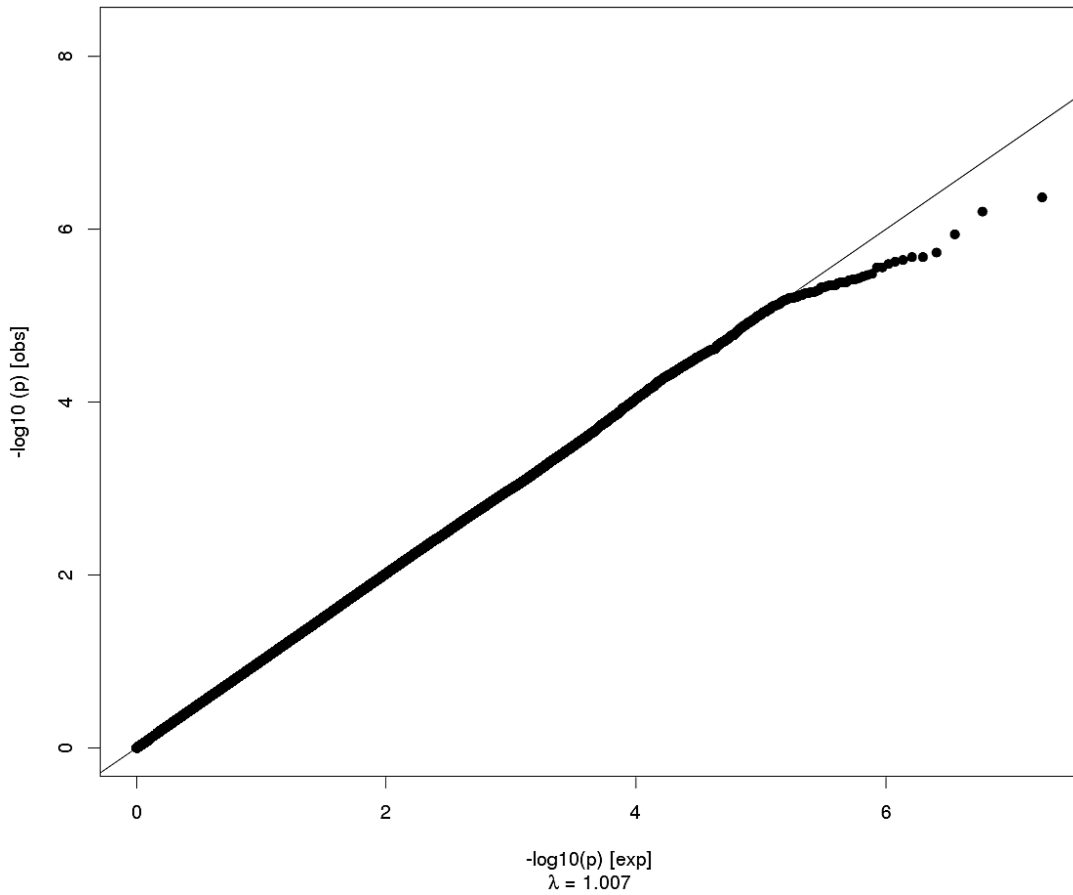
Rostral Anterior Cingulate Thickness



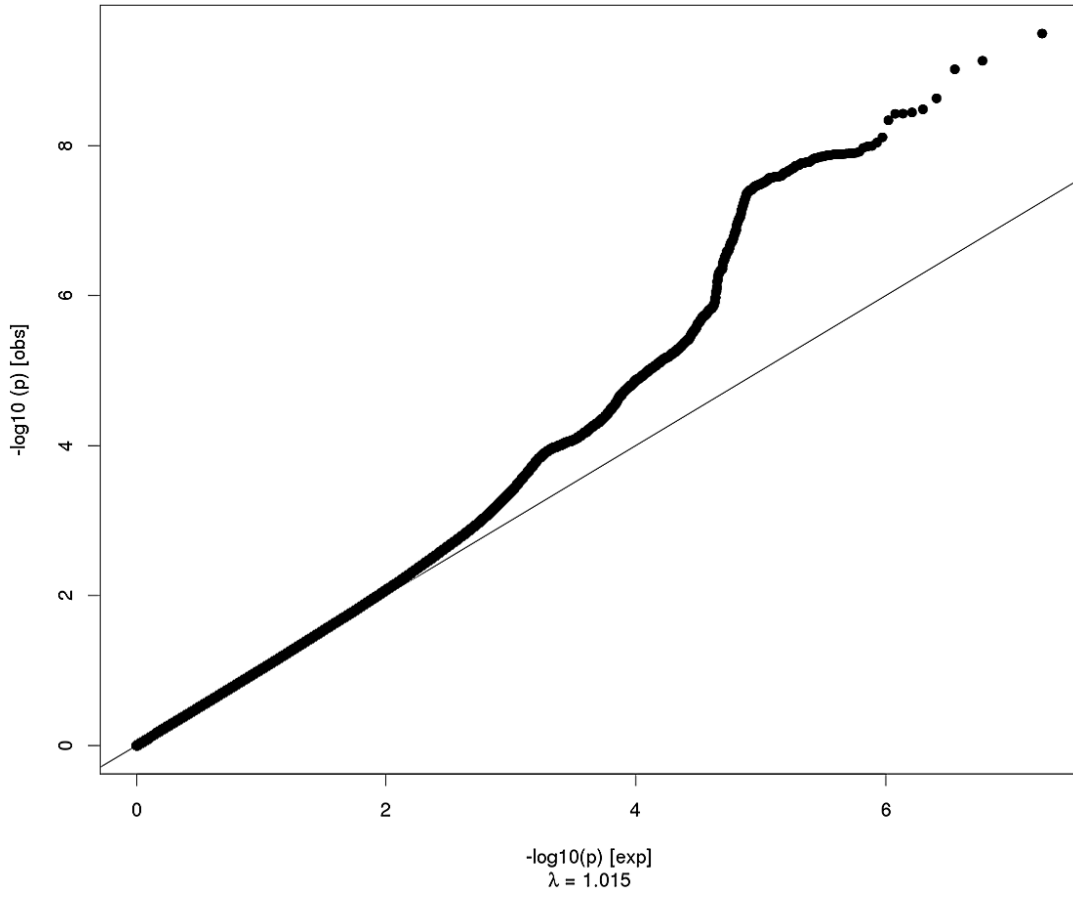
Caudal Anterior Cingulate Surface Area



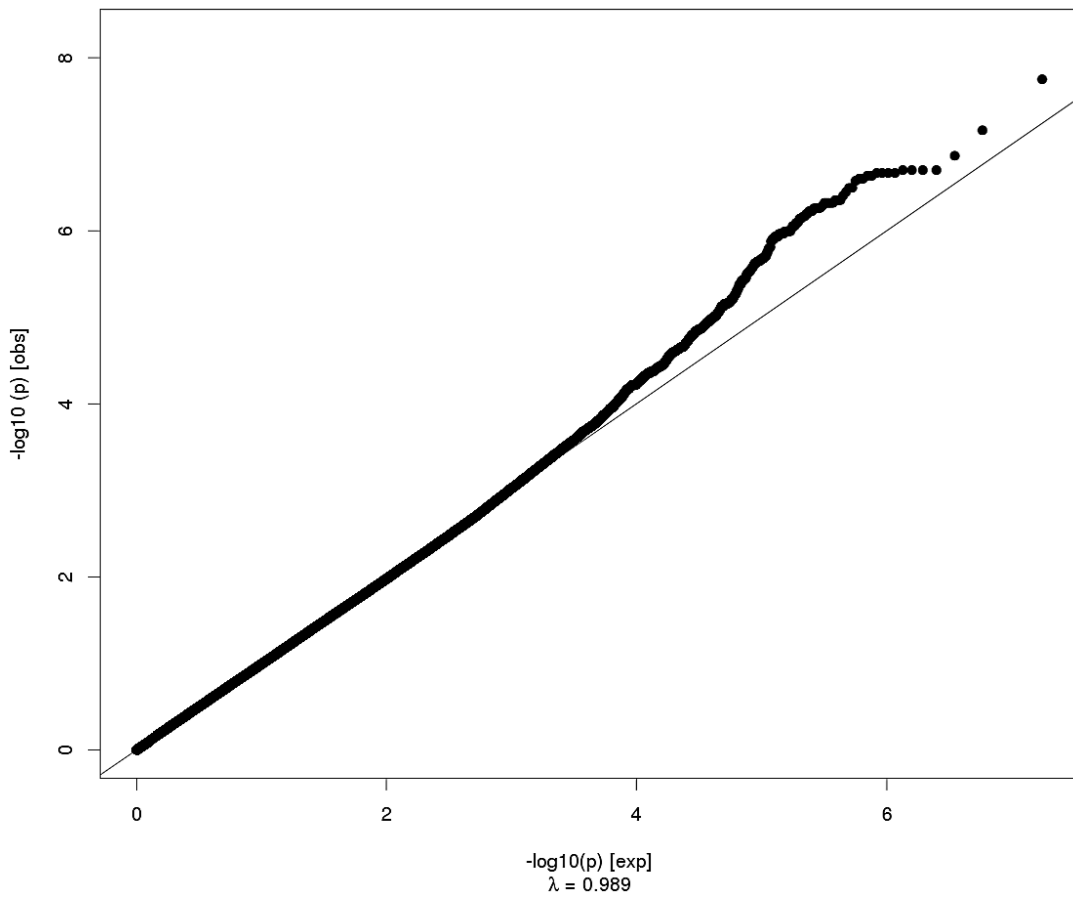
Caudal Anterior Cingulate Thickness



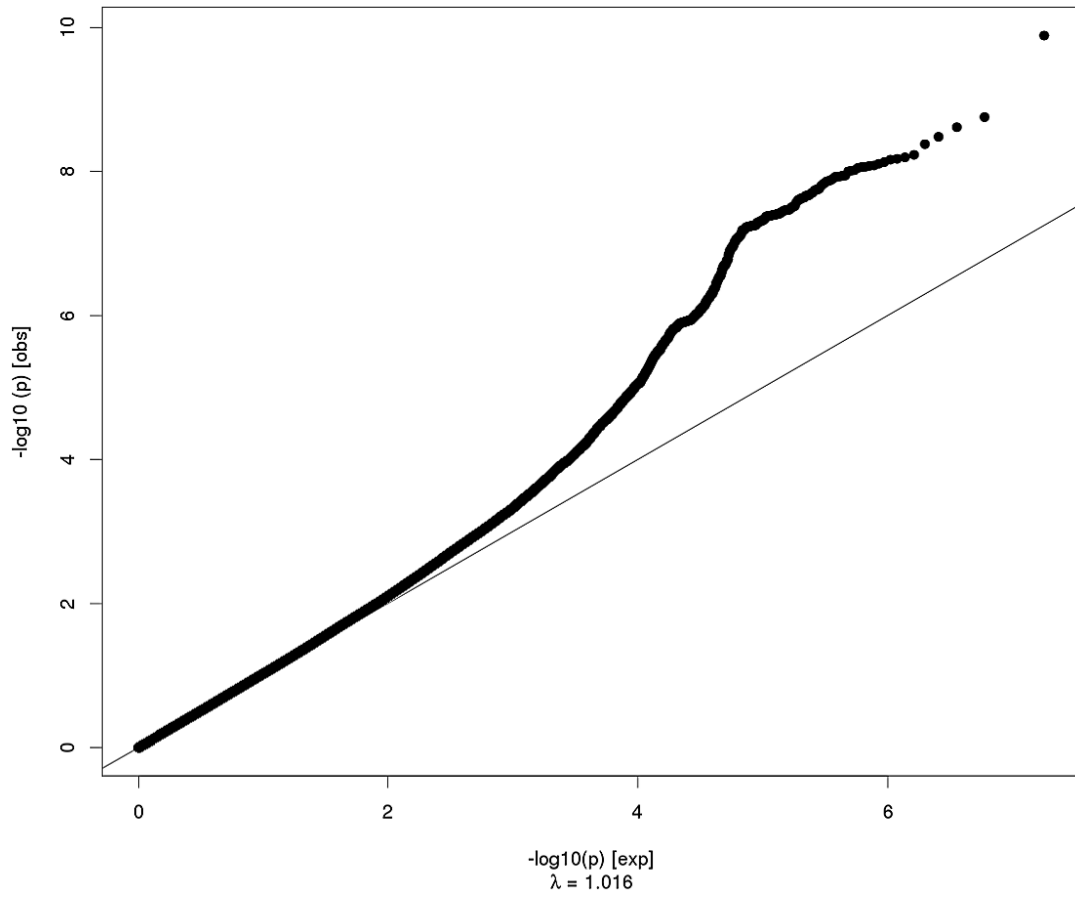
Superior Frontal Surface Area



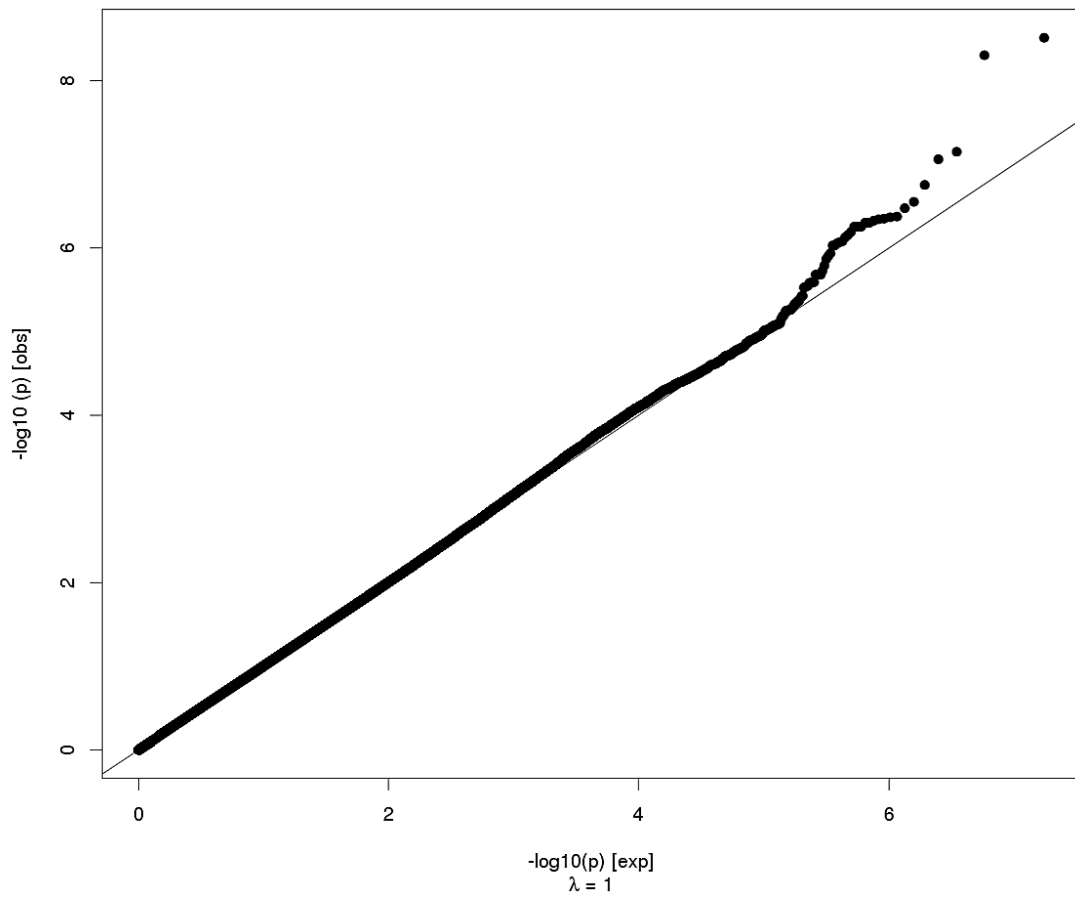
Superior Frontal Thickness



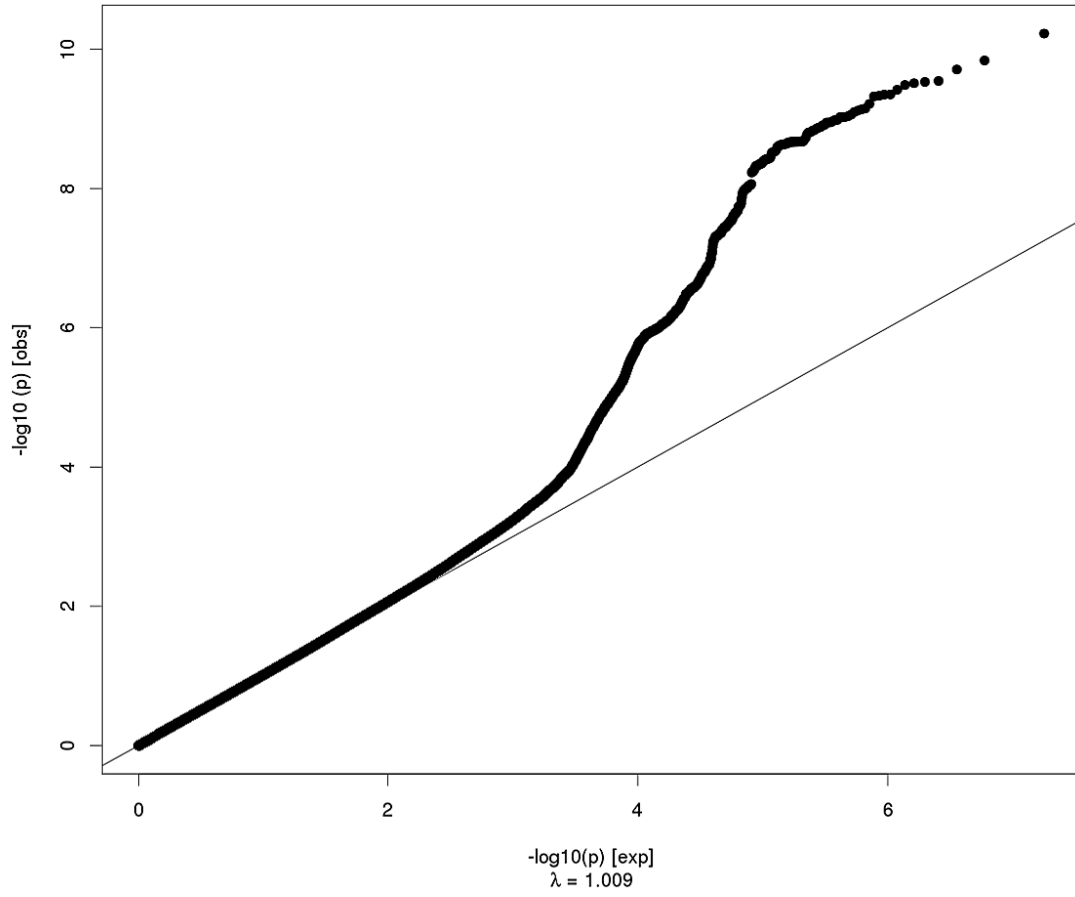
Rostral Middle Frontal Surface Area



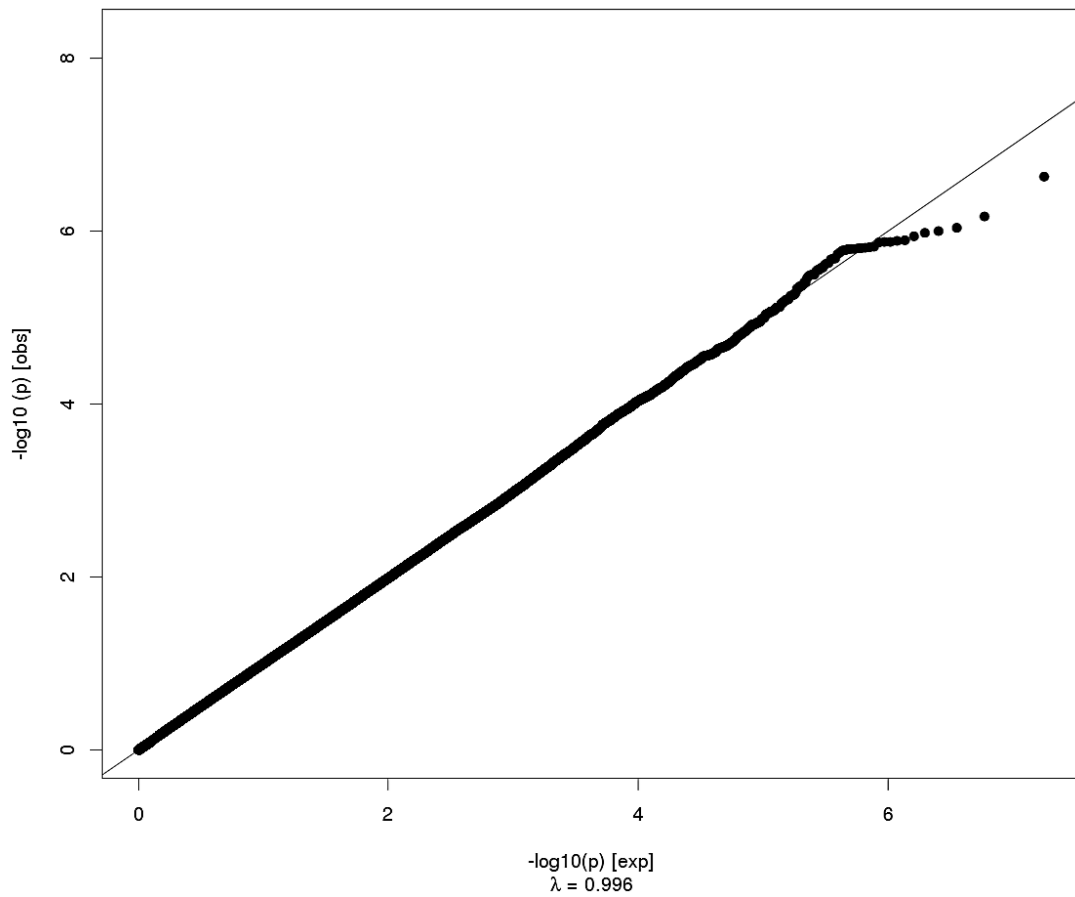
Rostral Middle Frontal Thickness



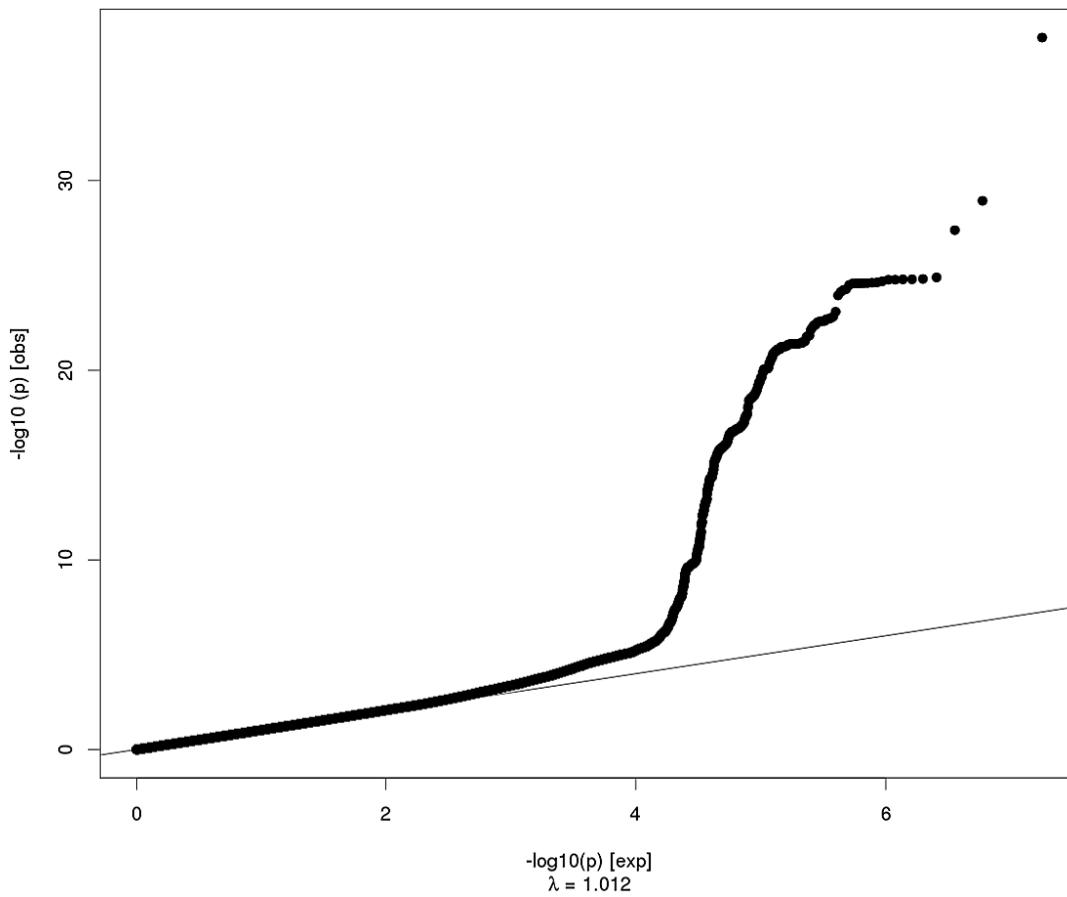
Pars Orbitalis Surface Area



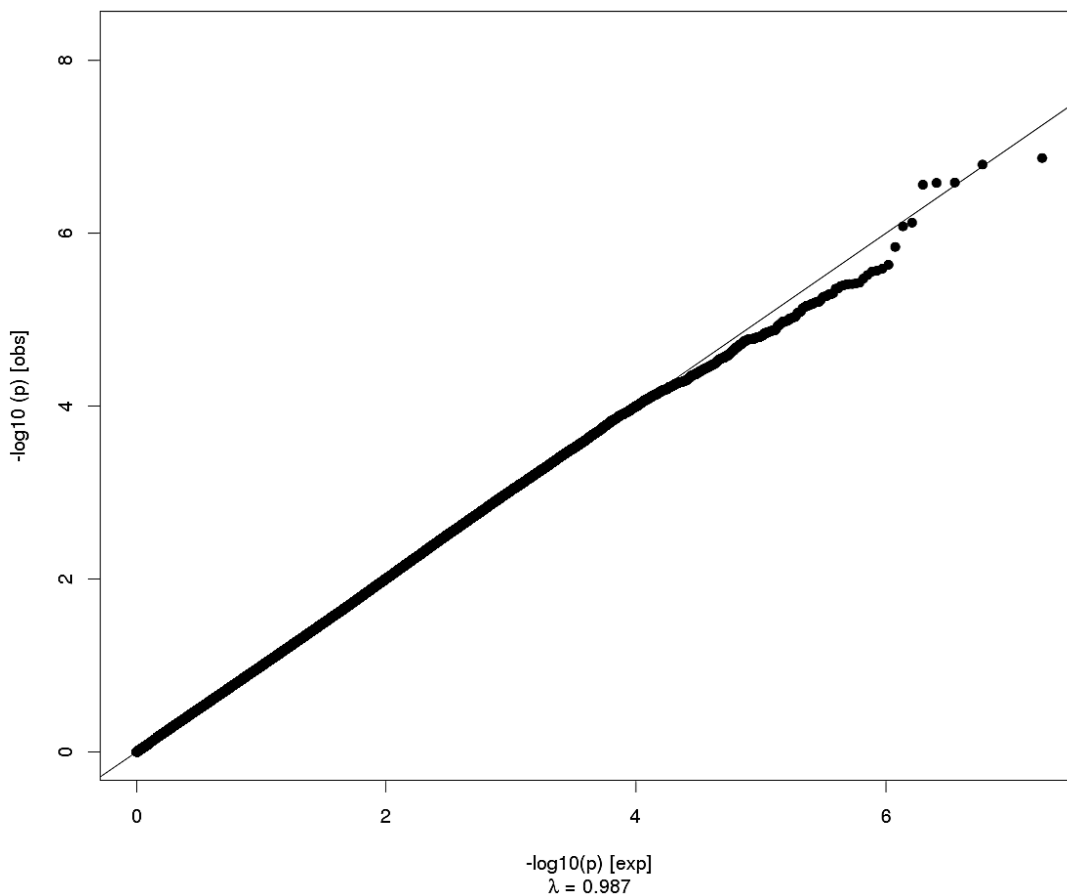
Pars Orbitalis Thickness



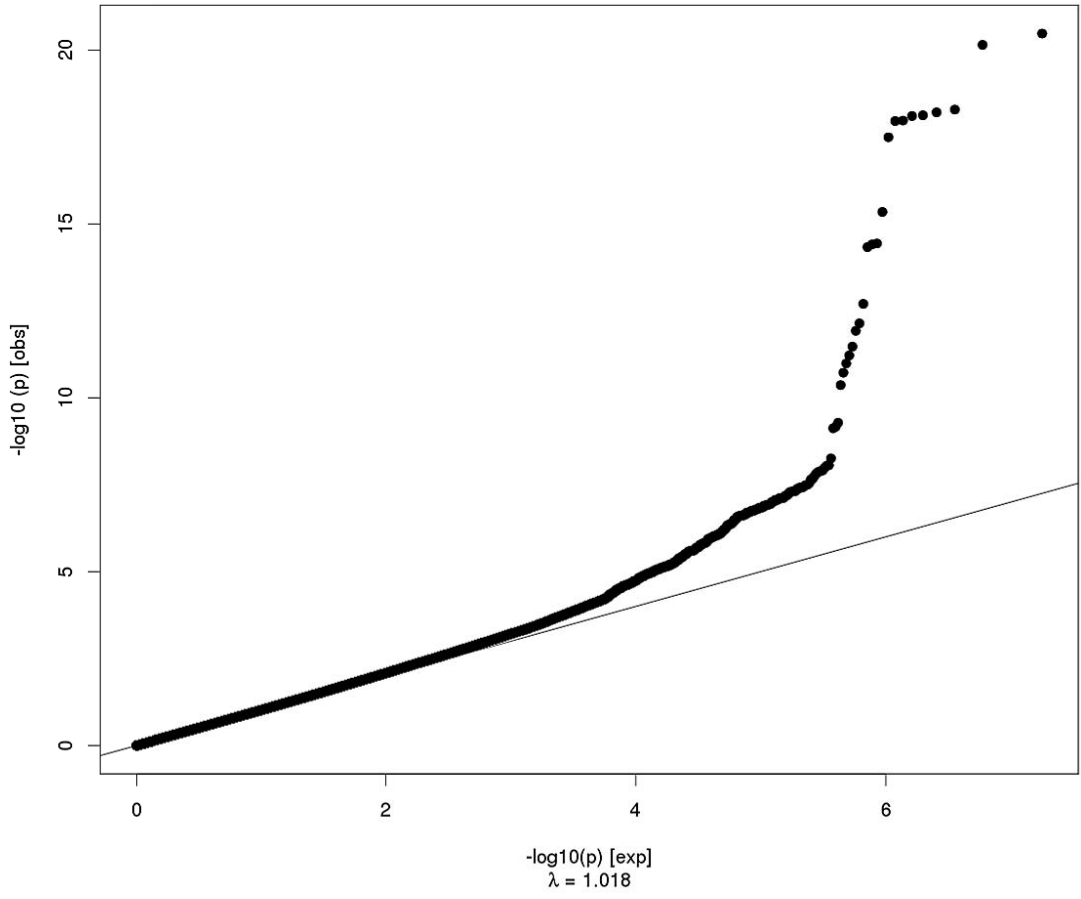
Pars Triangularis Surface Area



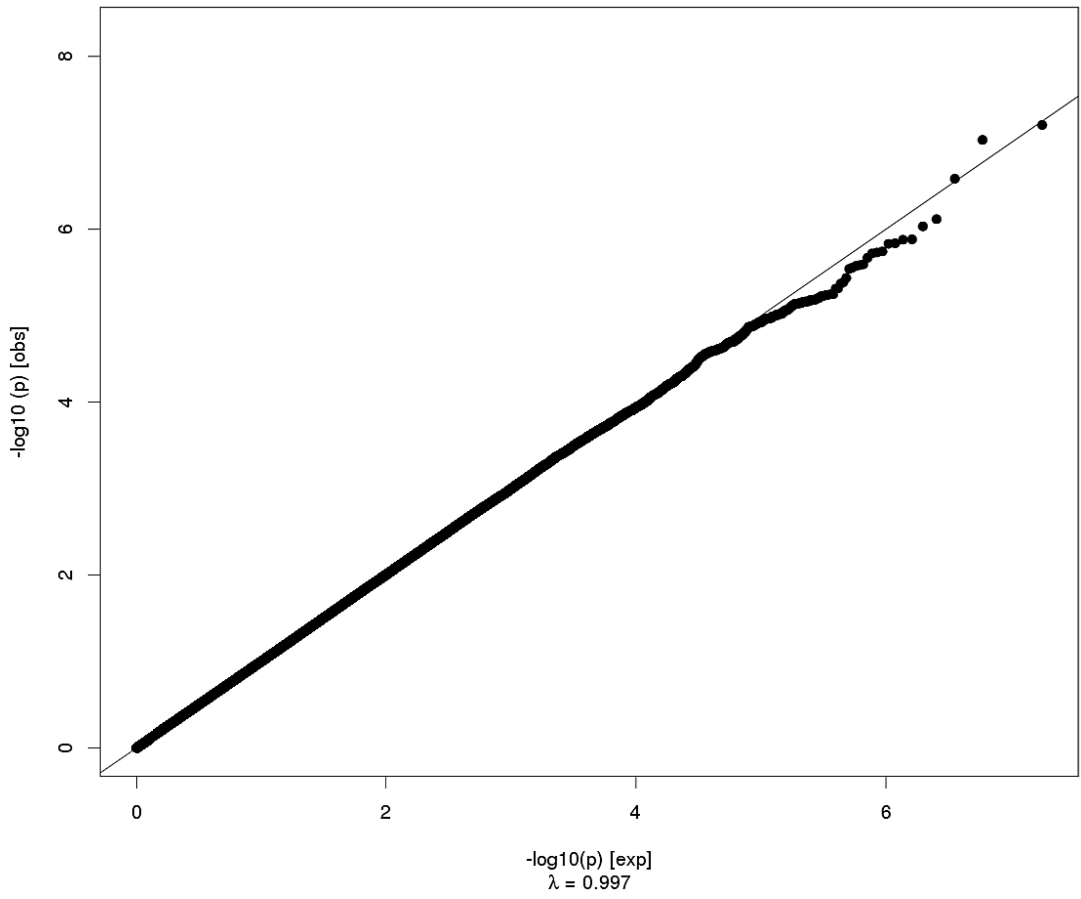
Pars Triangularis Thickness



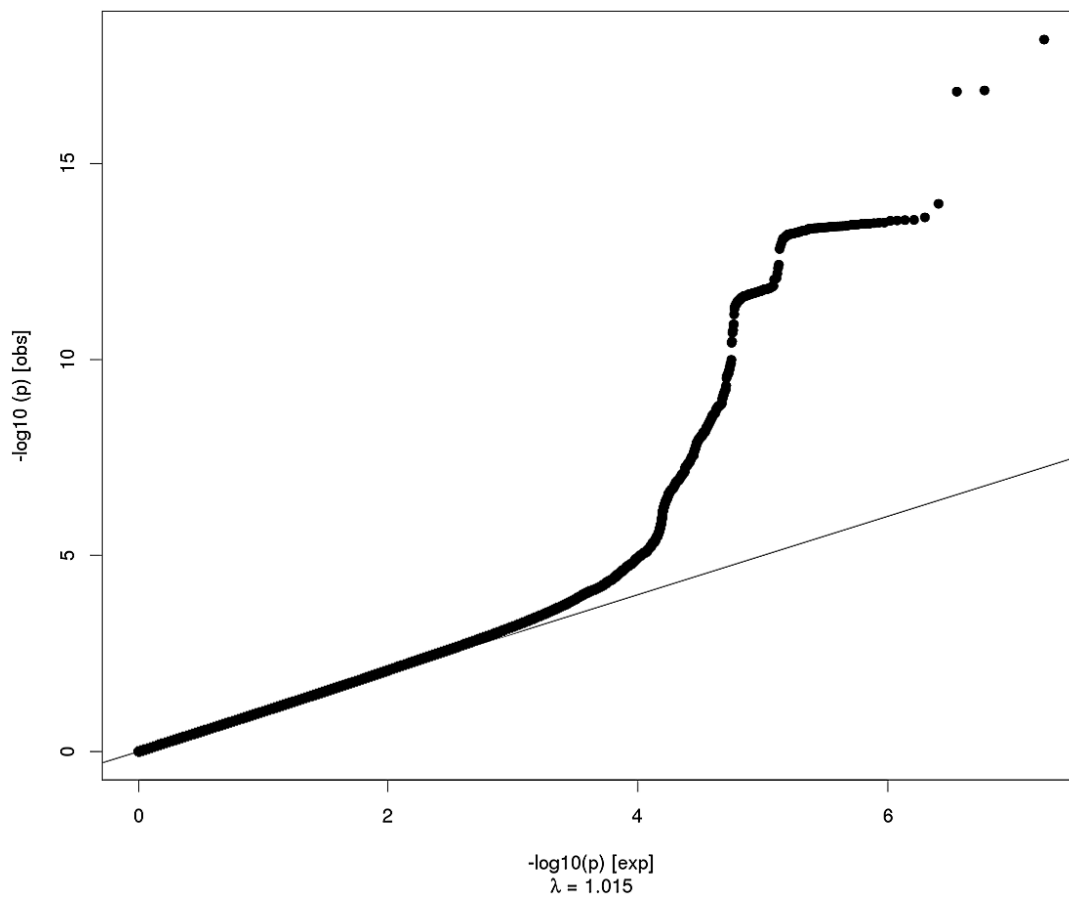
Pars Opercularis Surface Area



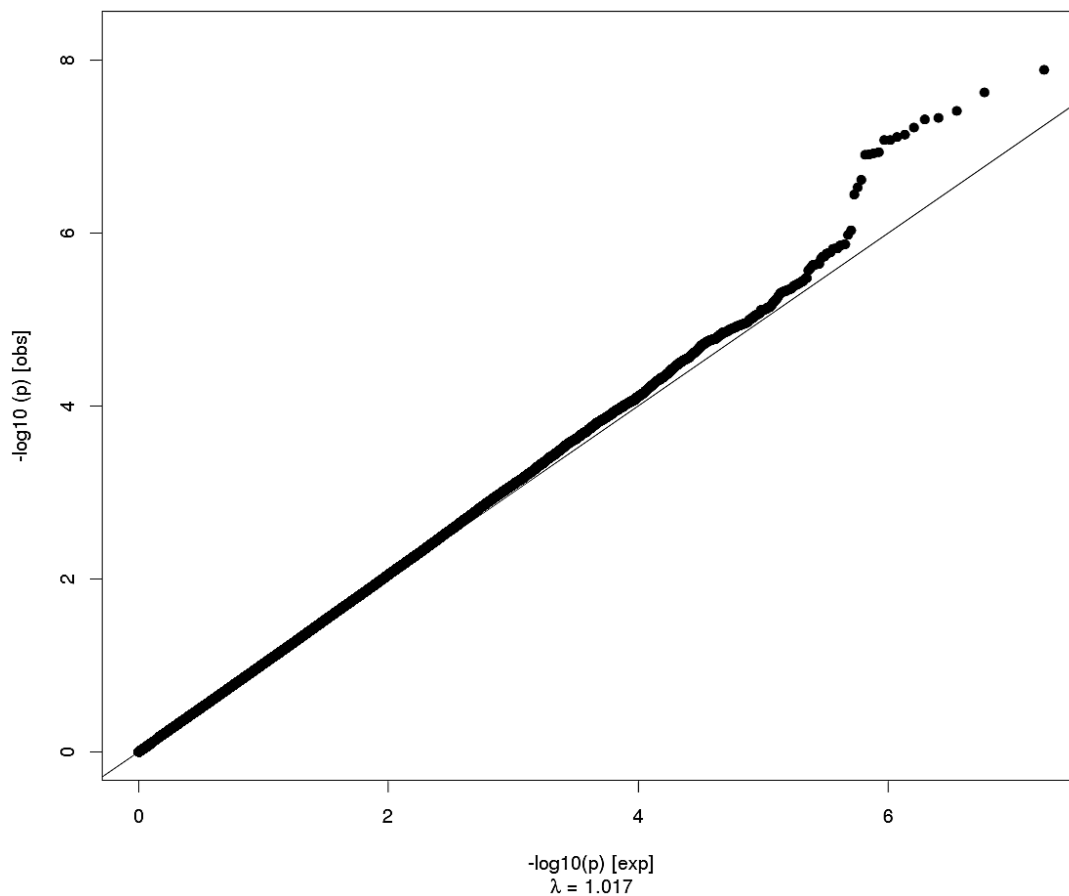
Pars Opercularis Thickness



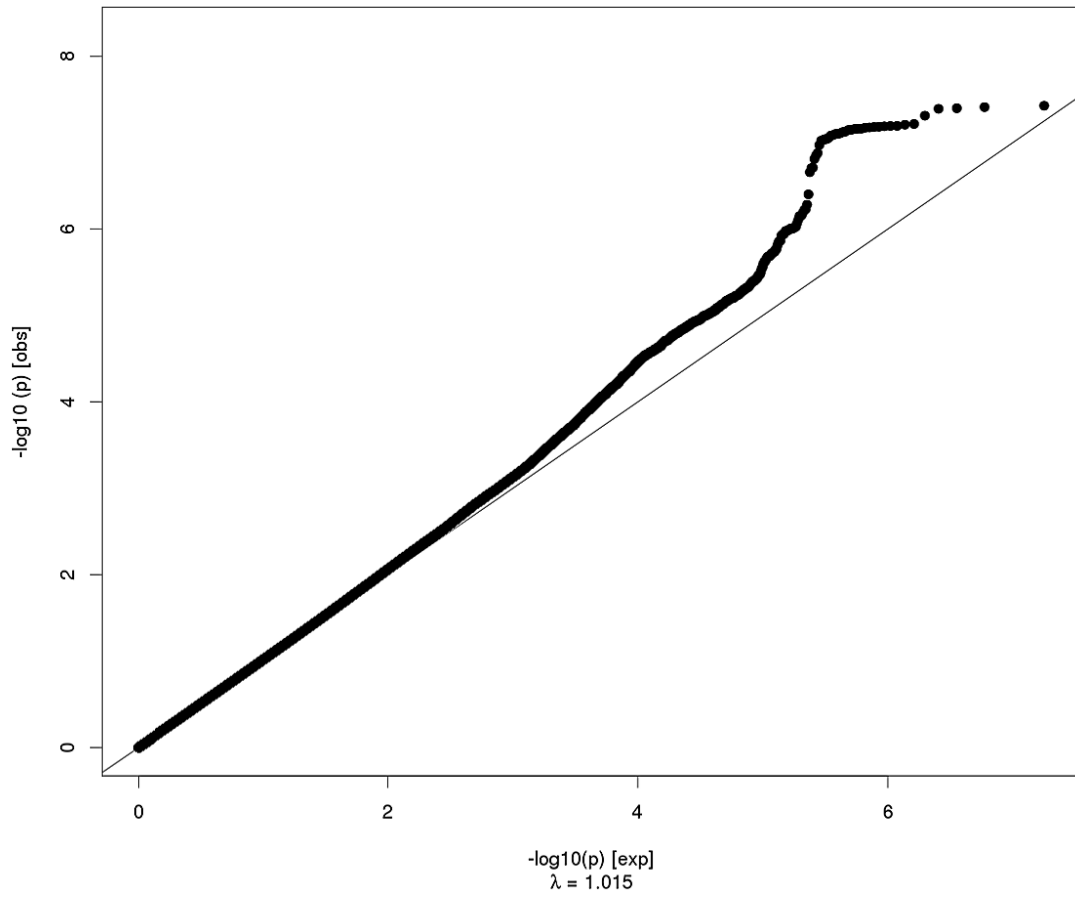
Caudal Middle Frontal Surface Area



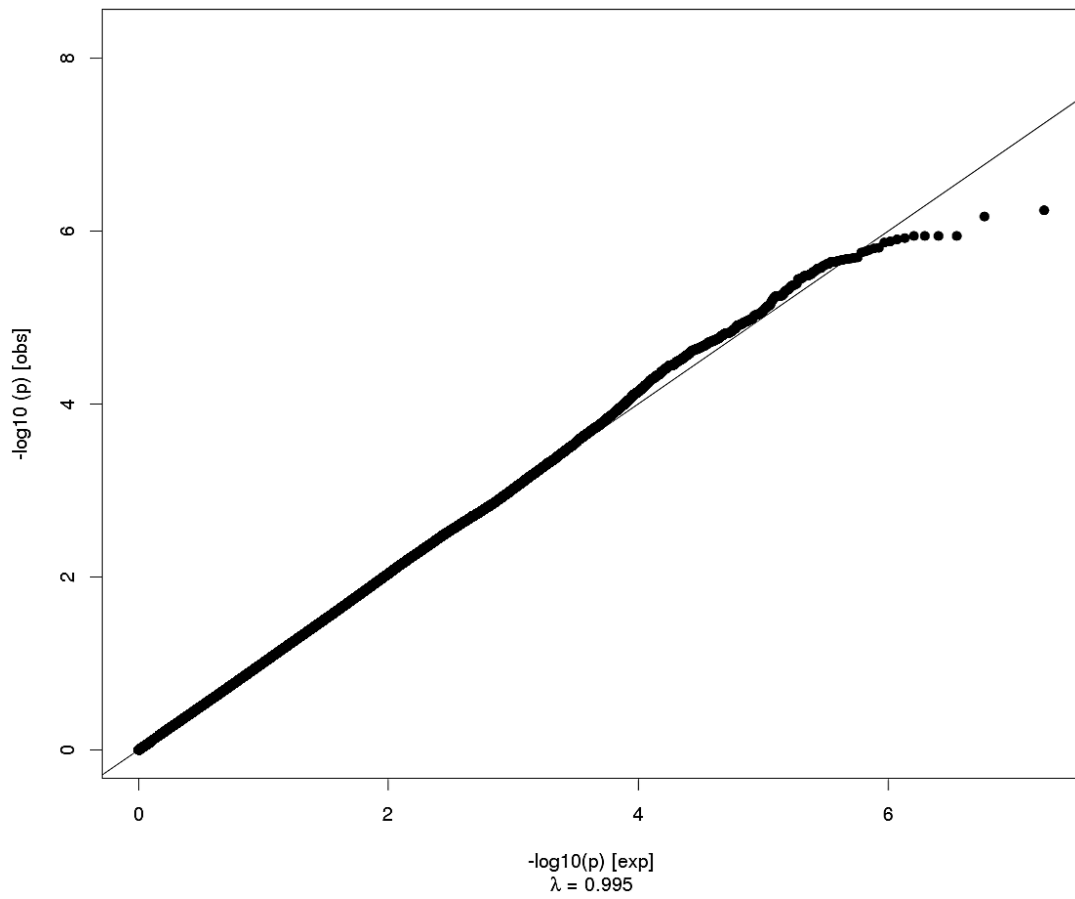
Caudal Middle Frontal Thickness



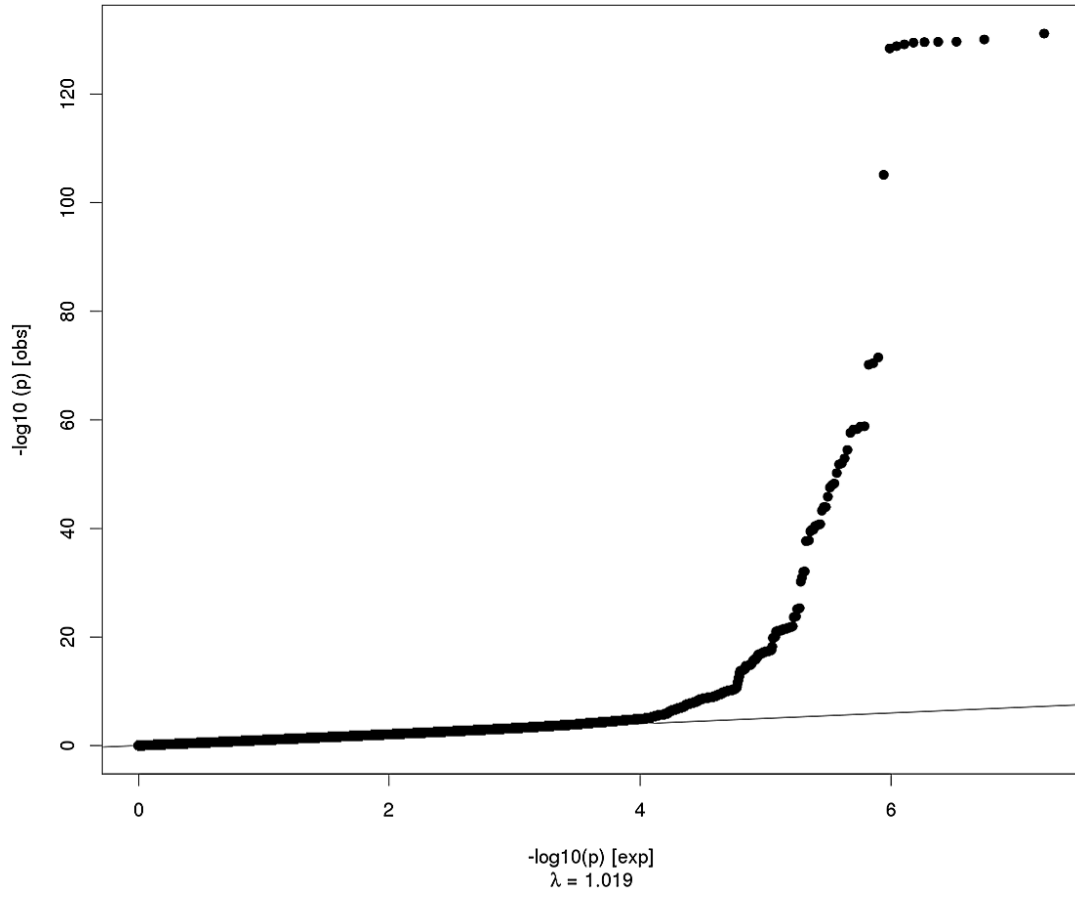
Paracentral Surface Area



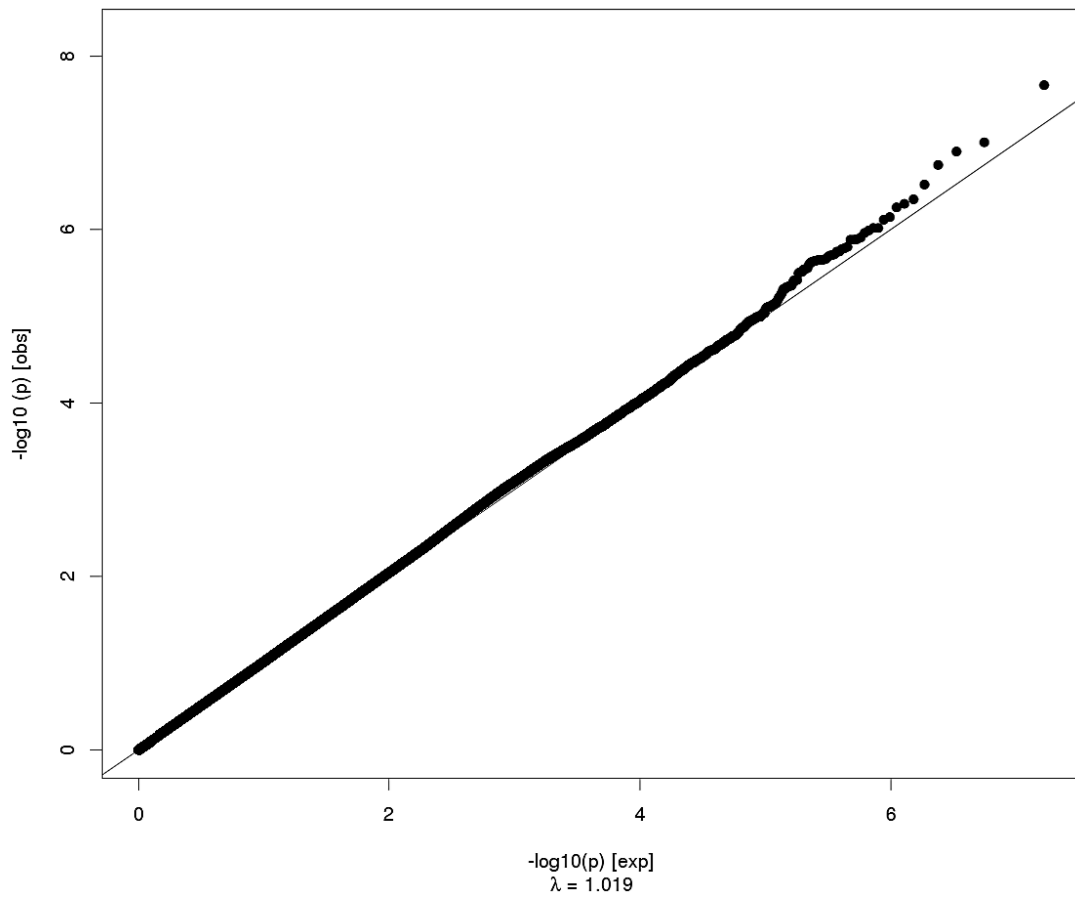
Paracentral Thickness



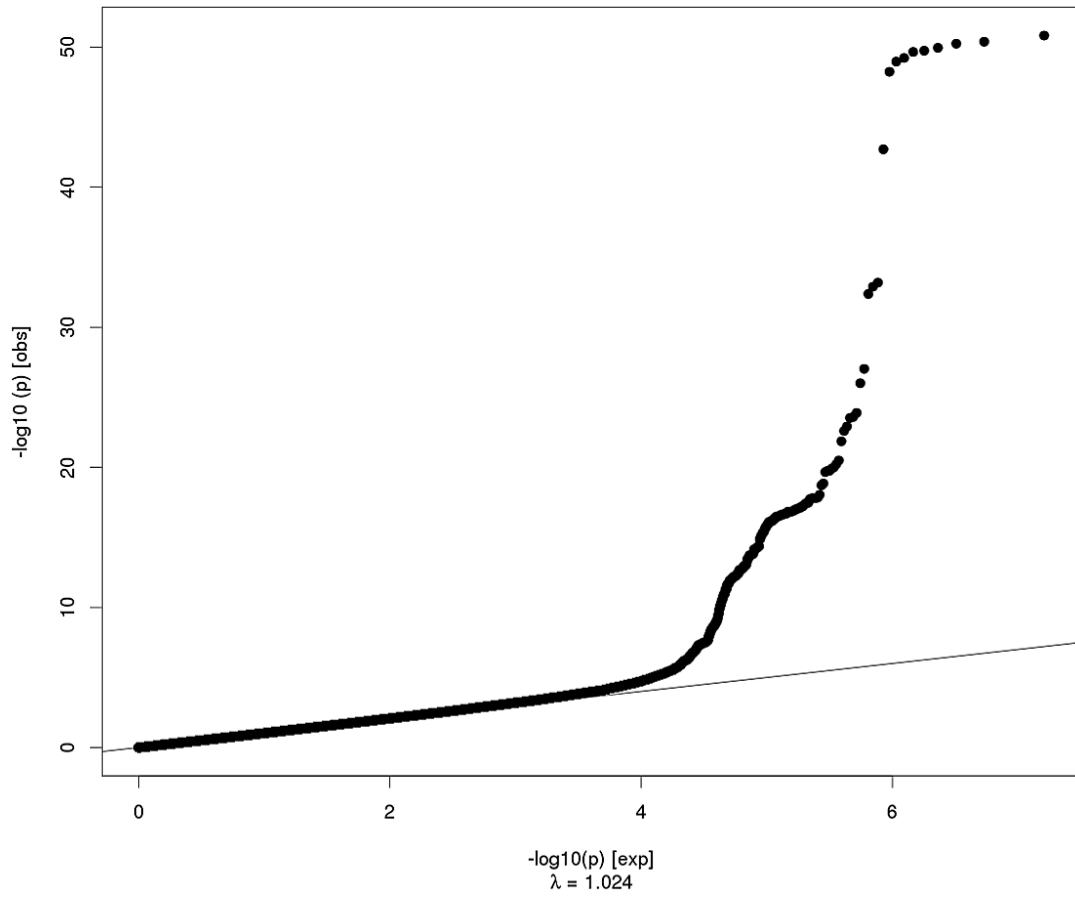
Precentral Surface Area



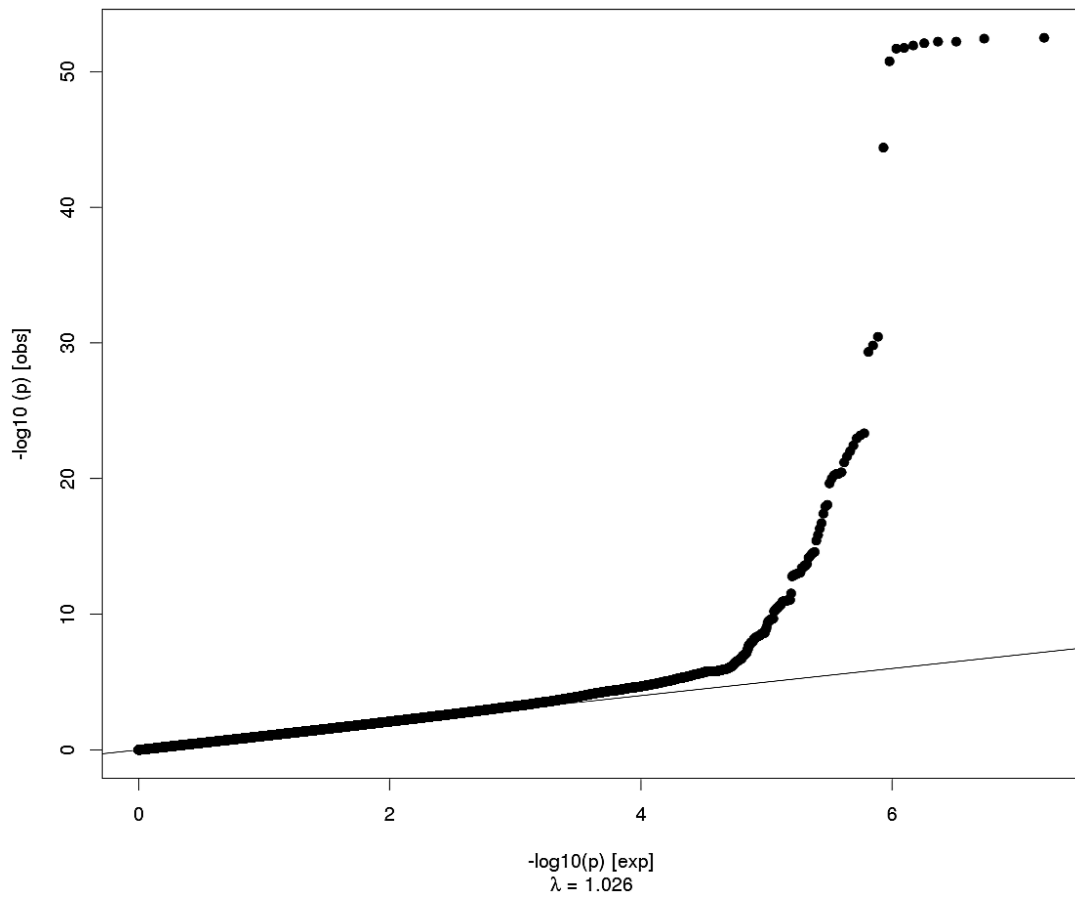
Precentral Thickness



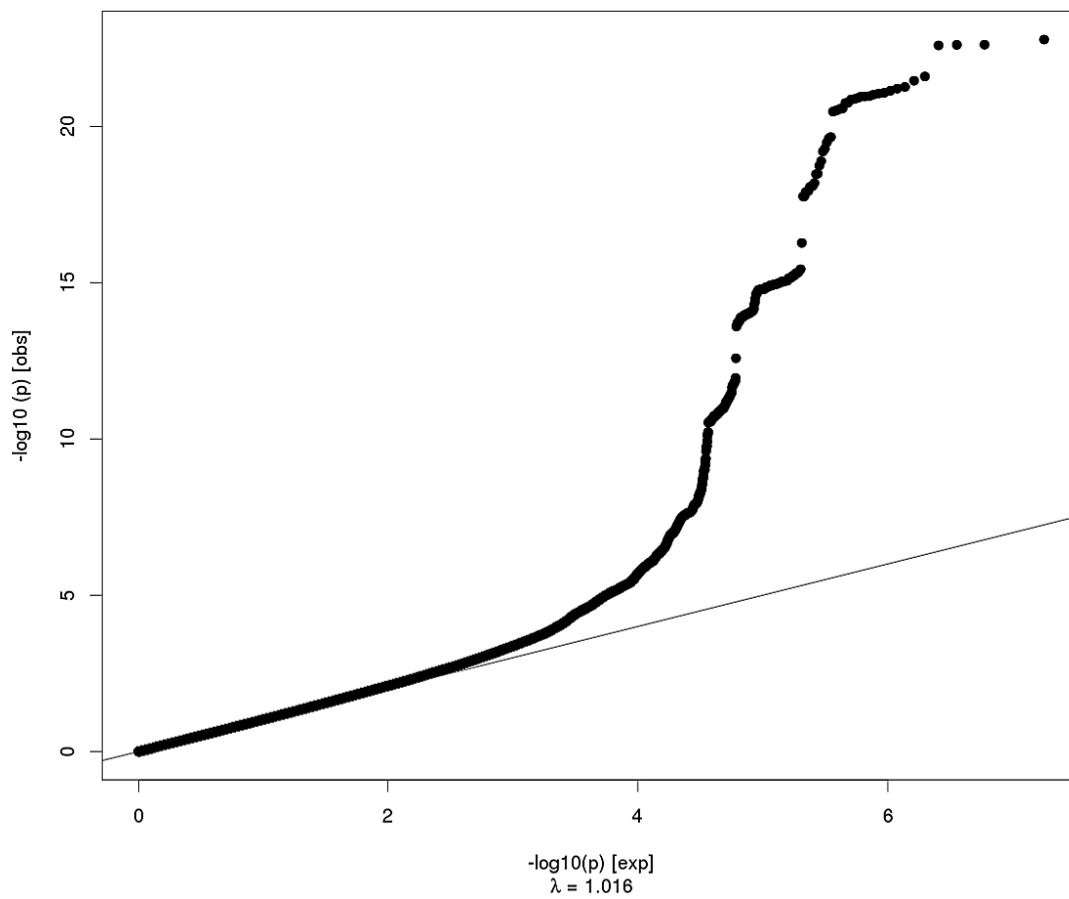
Postcentral Surface Area



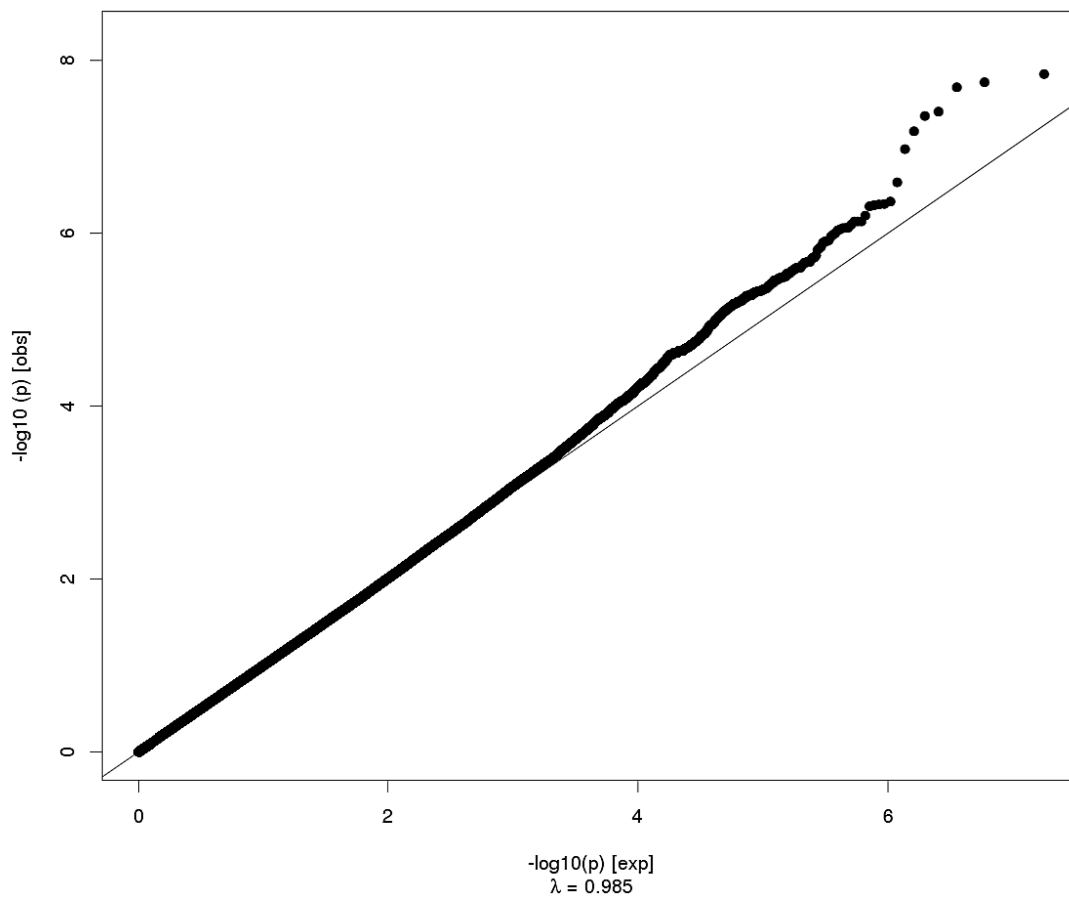
Postcentral Thickness



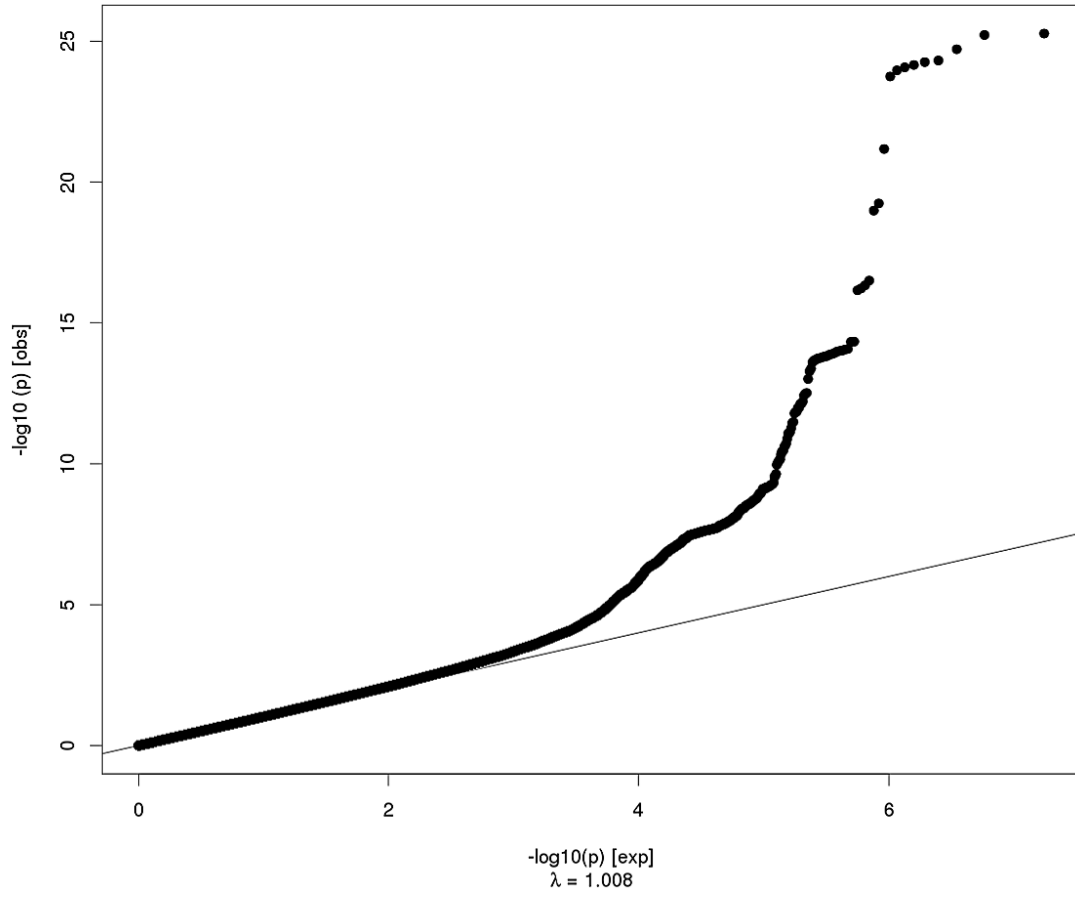
Precuneus Surface Area



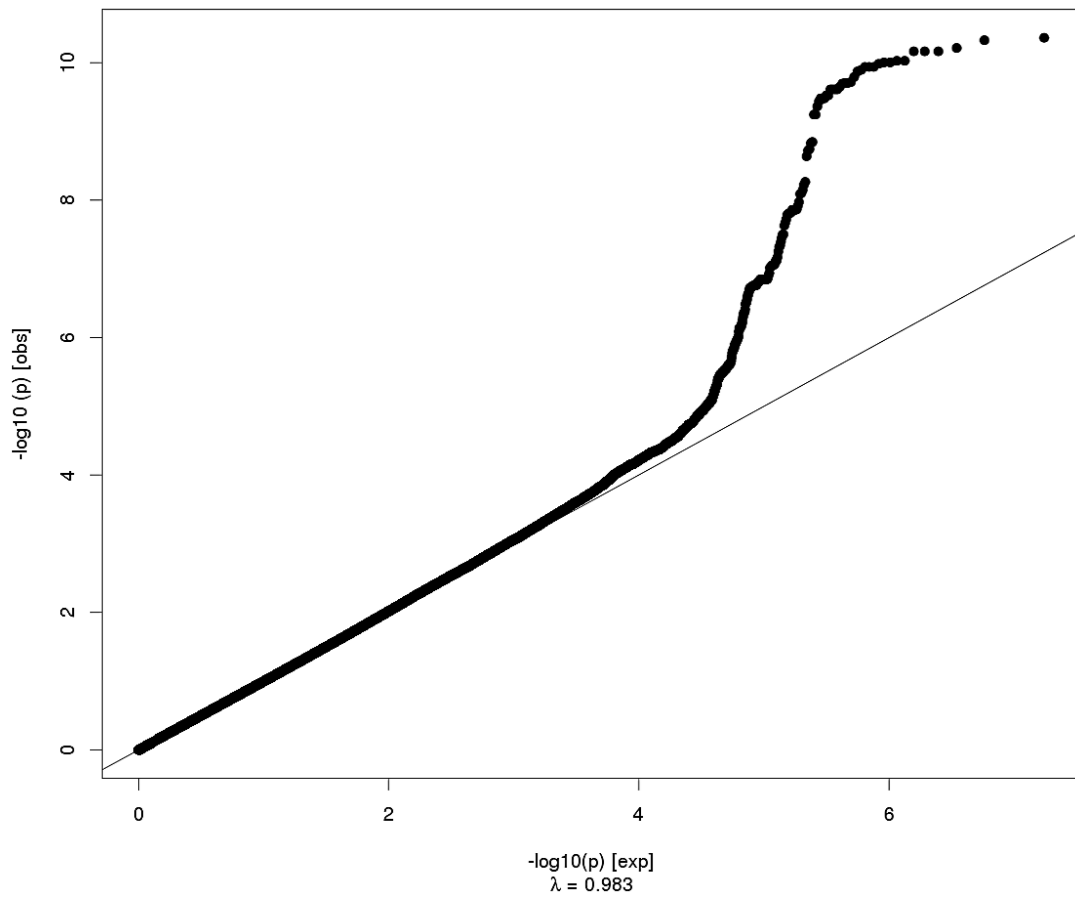
Precuneus Thickness



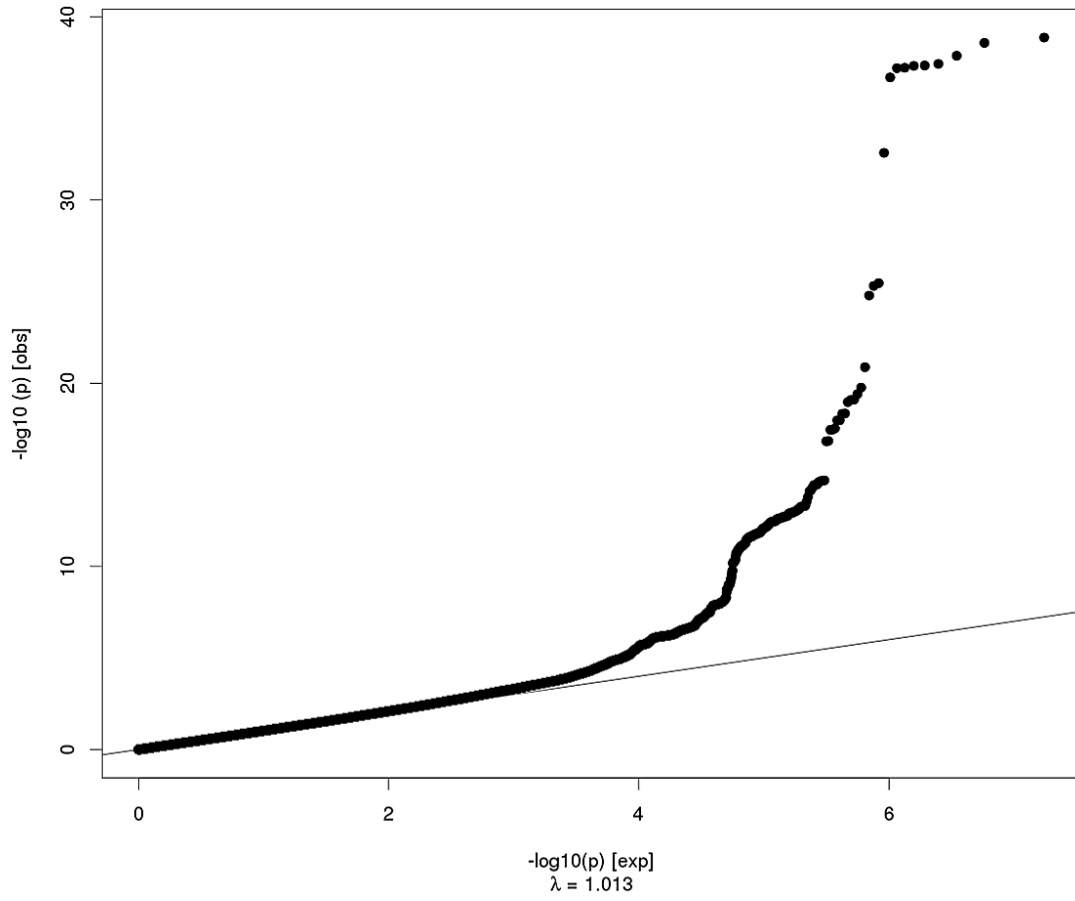
Superior Parietal Surface Area



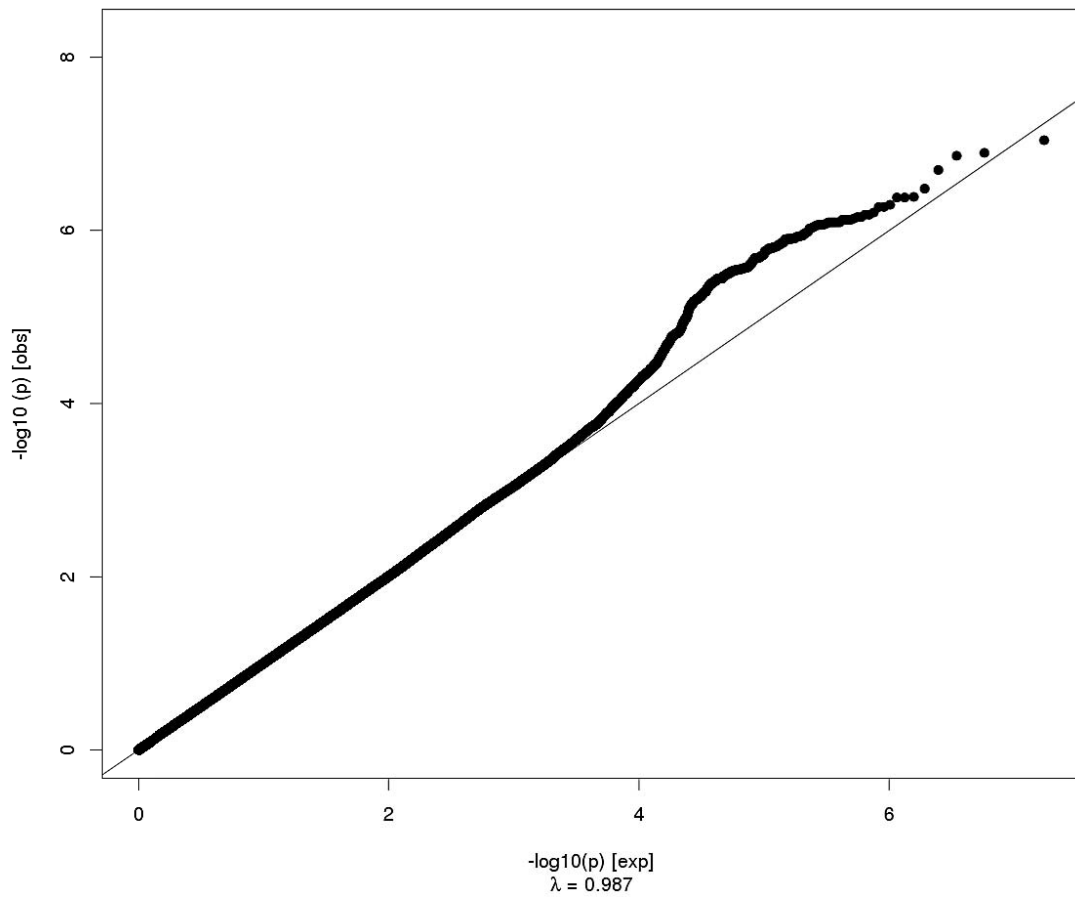
Superior Parietal Thickness



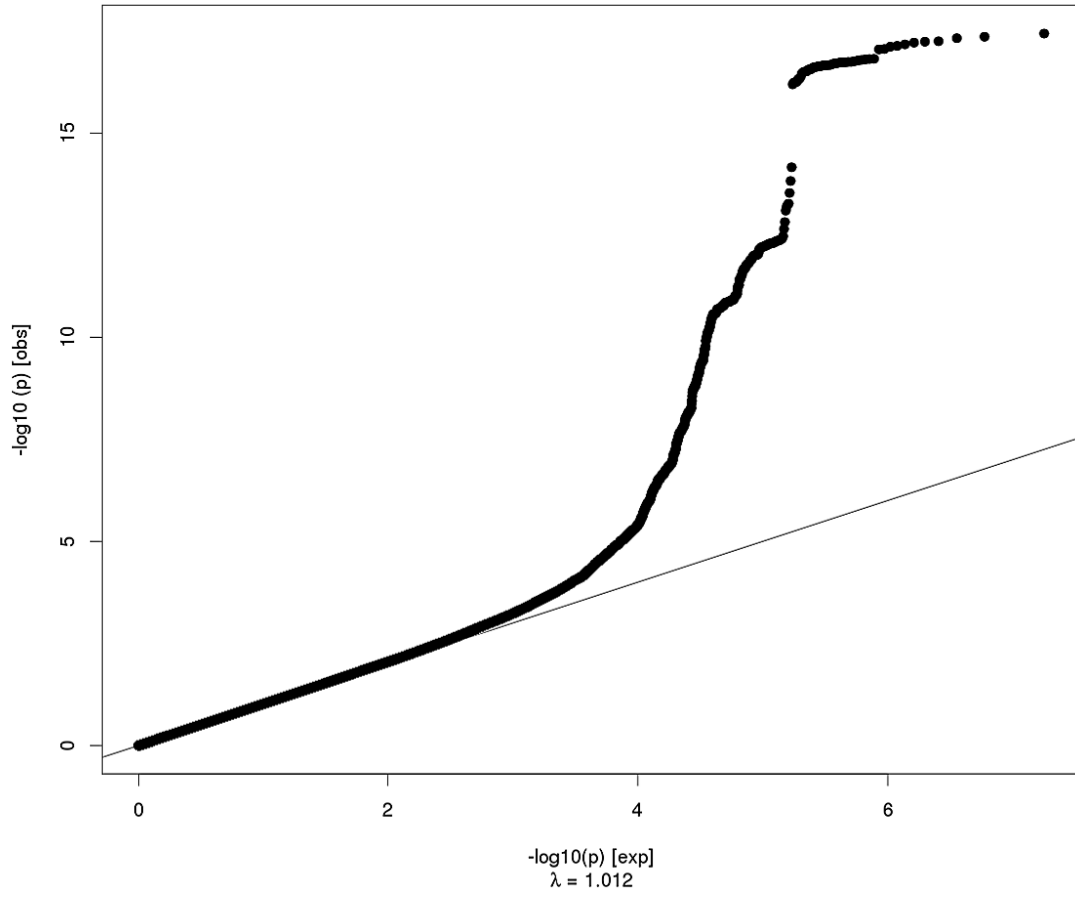
Supramarginal Surface Area



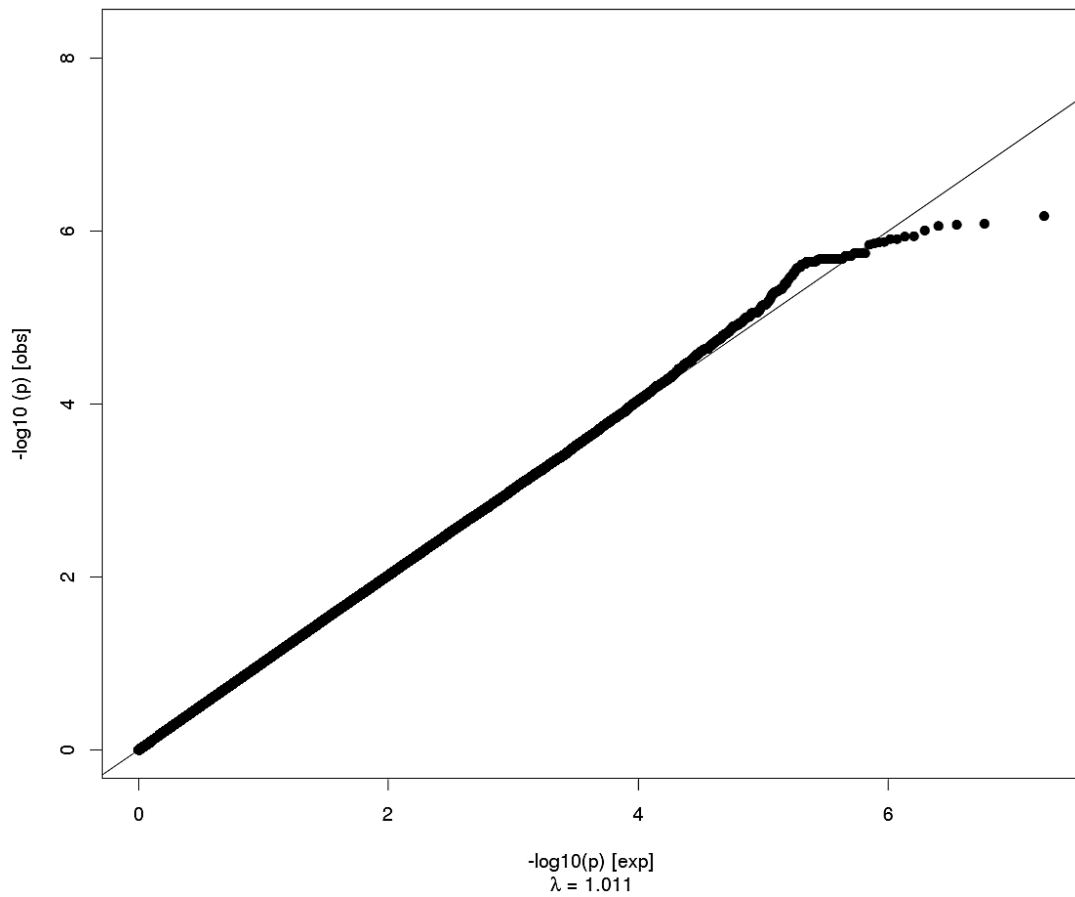
Supramarginal Thickness



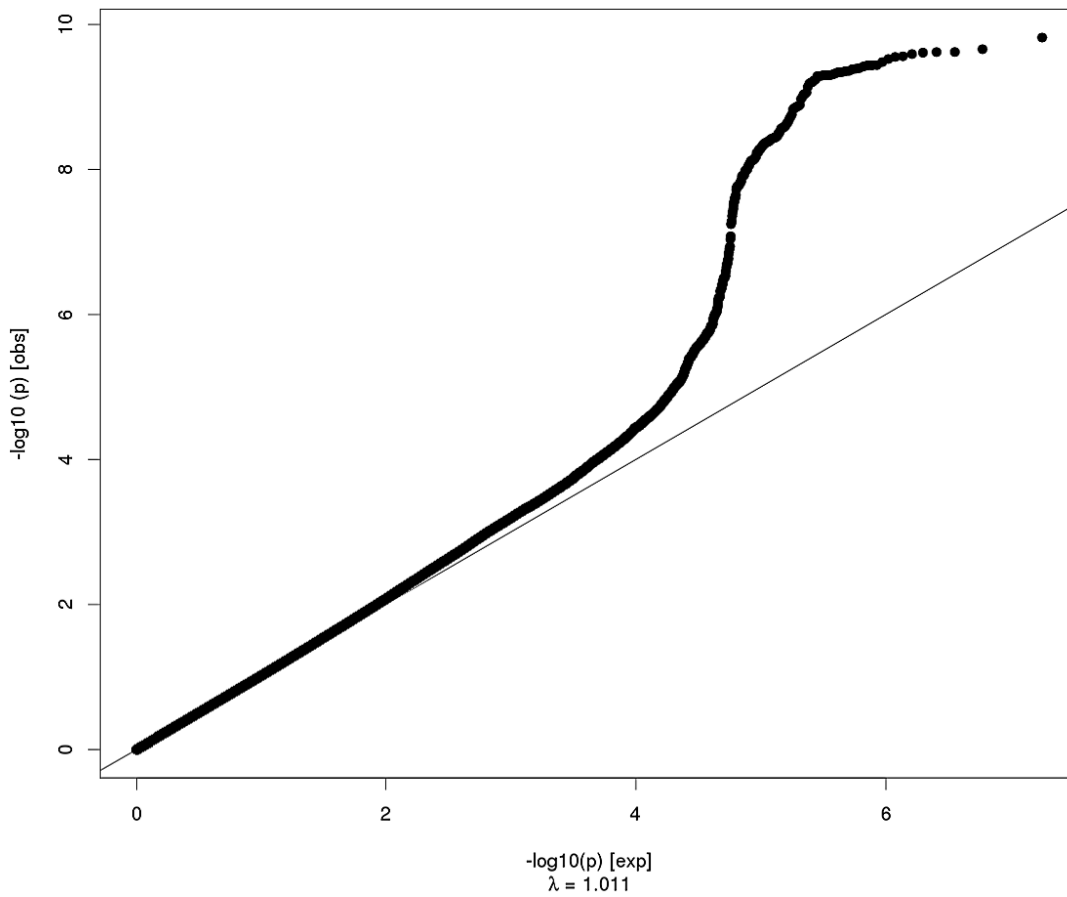
Inferior Parietal Surface Area



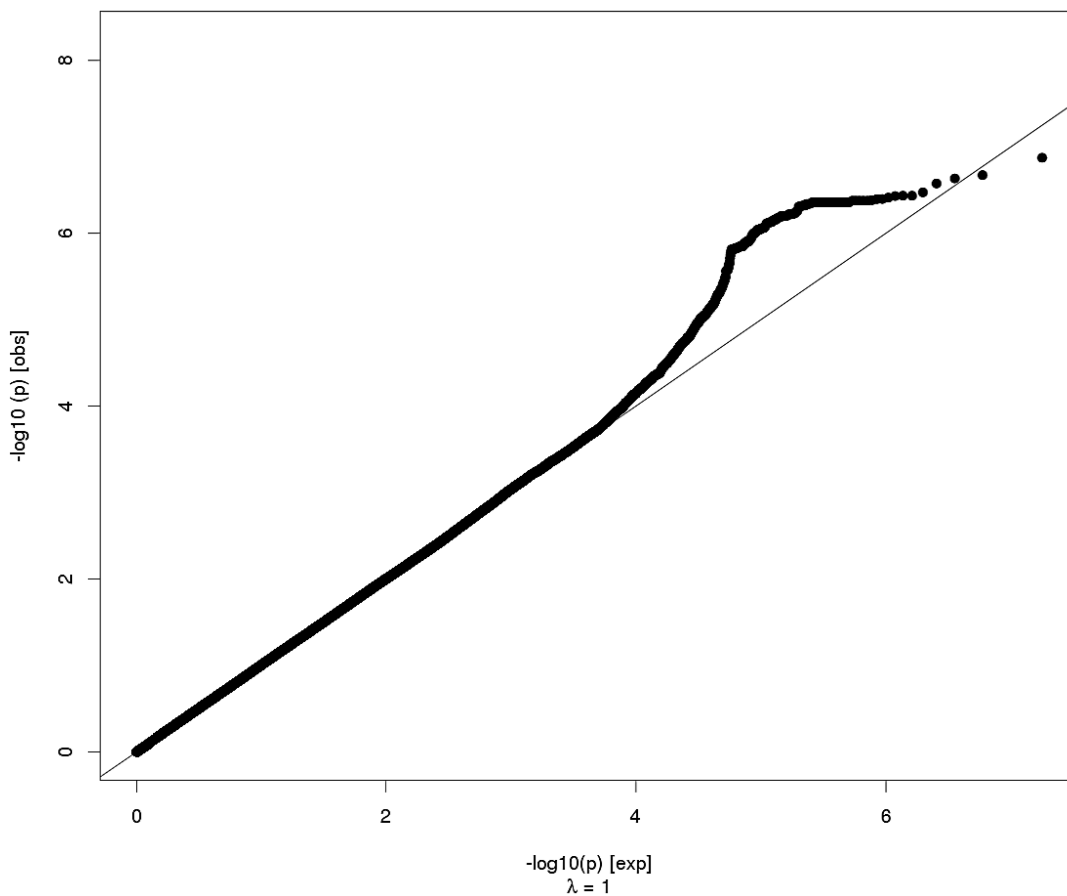
Inferior Parietal Thickness



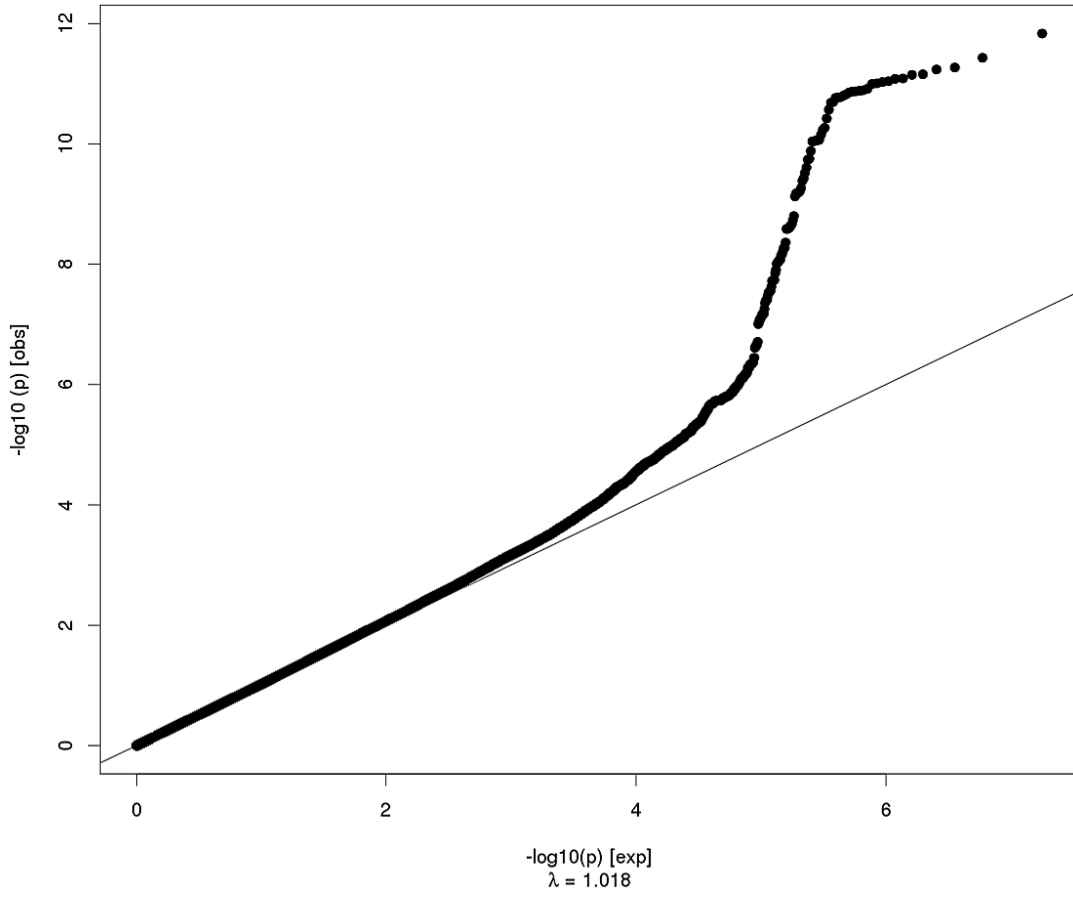
Posterior Cingulate Surface Area



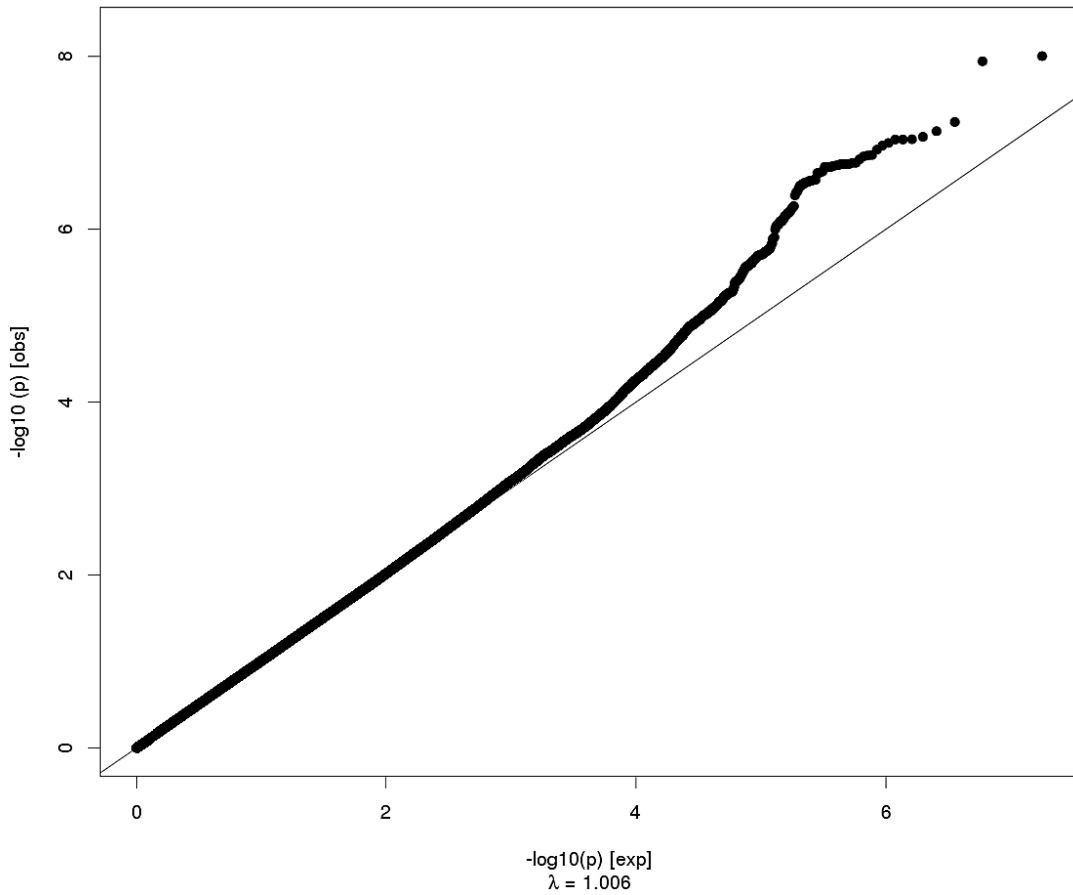
Posterior Cingulate Thickness



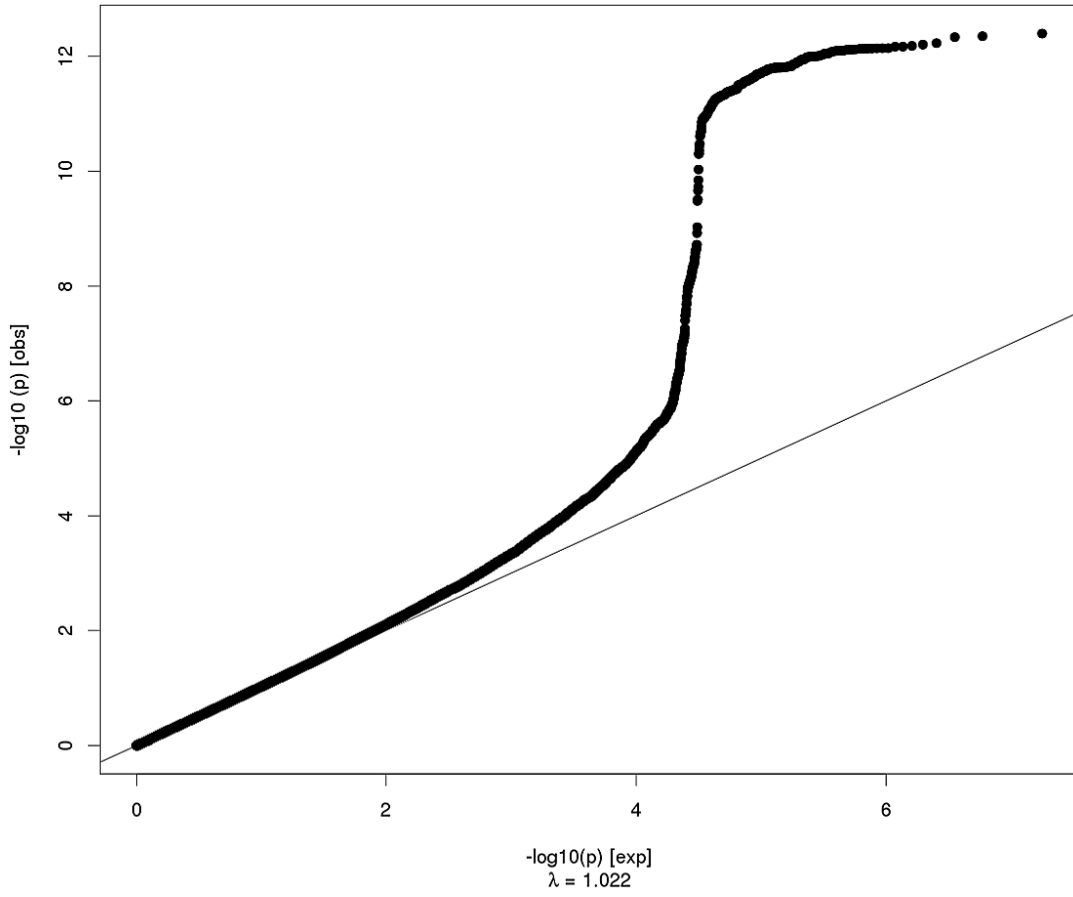
Isthmus Cingulate Surface Area



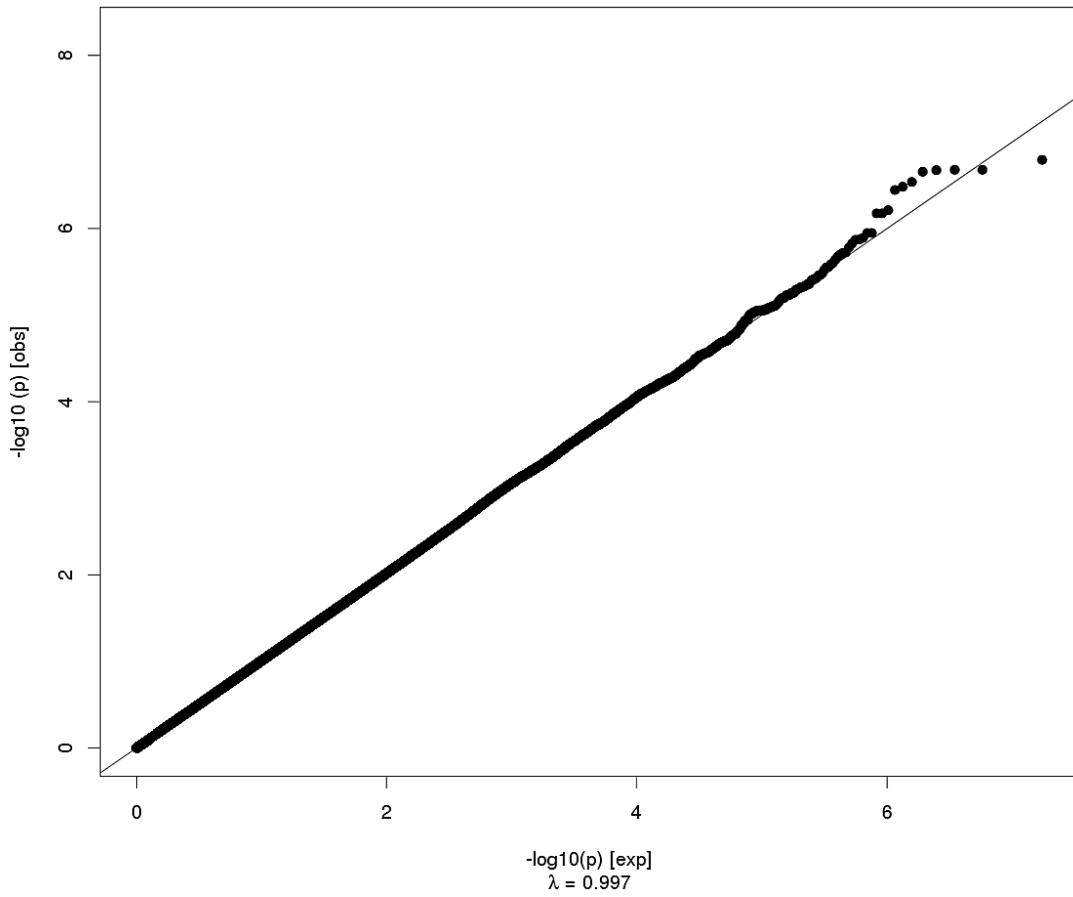
Isthmus Cingulate Thickness



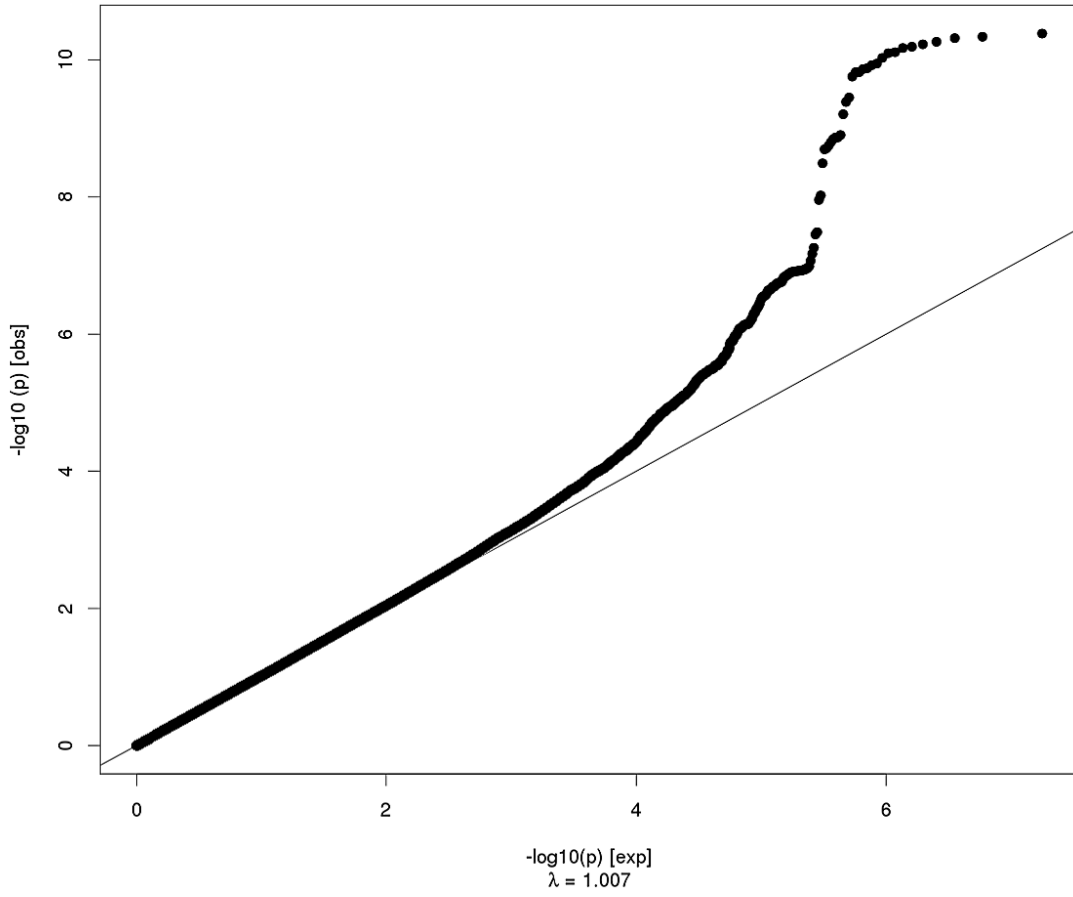
Insula Surface Area



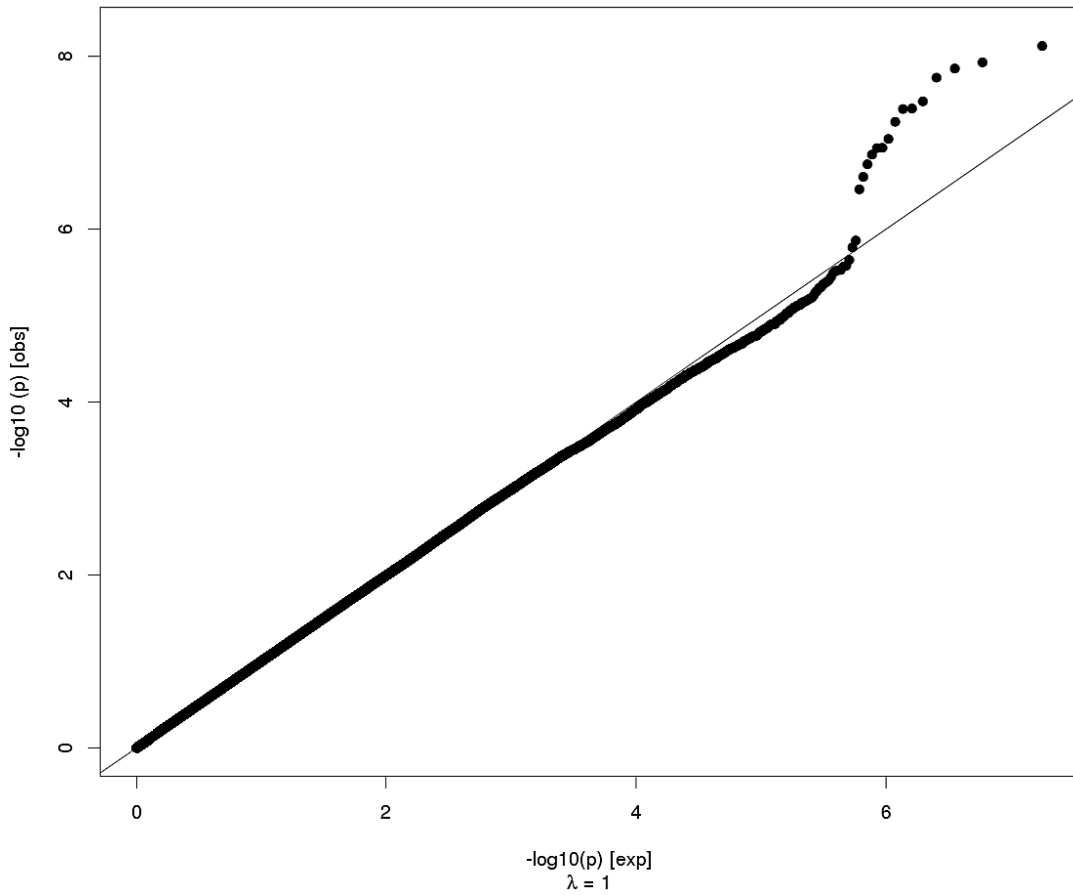
Insula Thickness



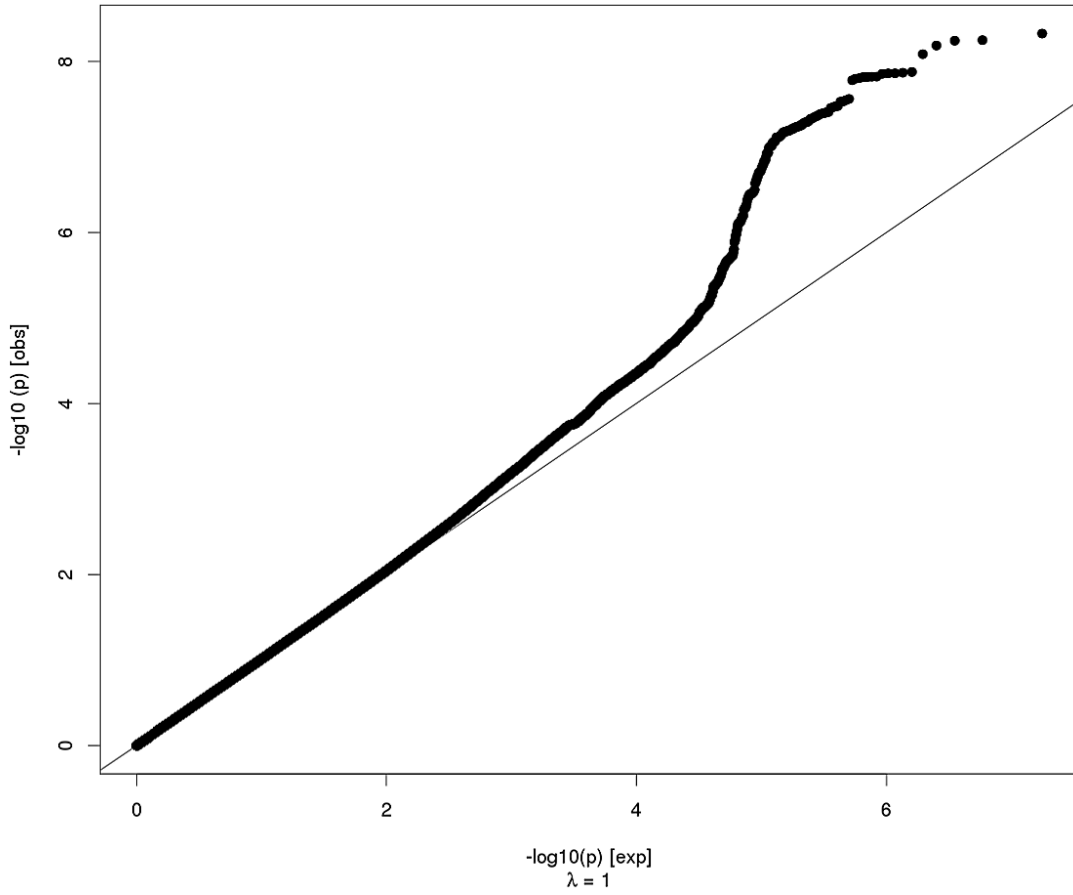
Entorhinal Surface Area



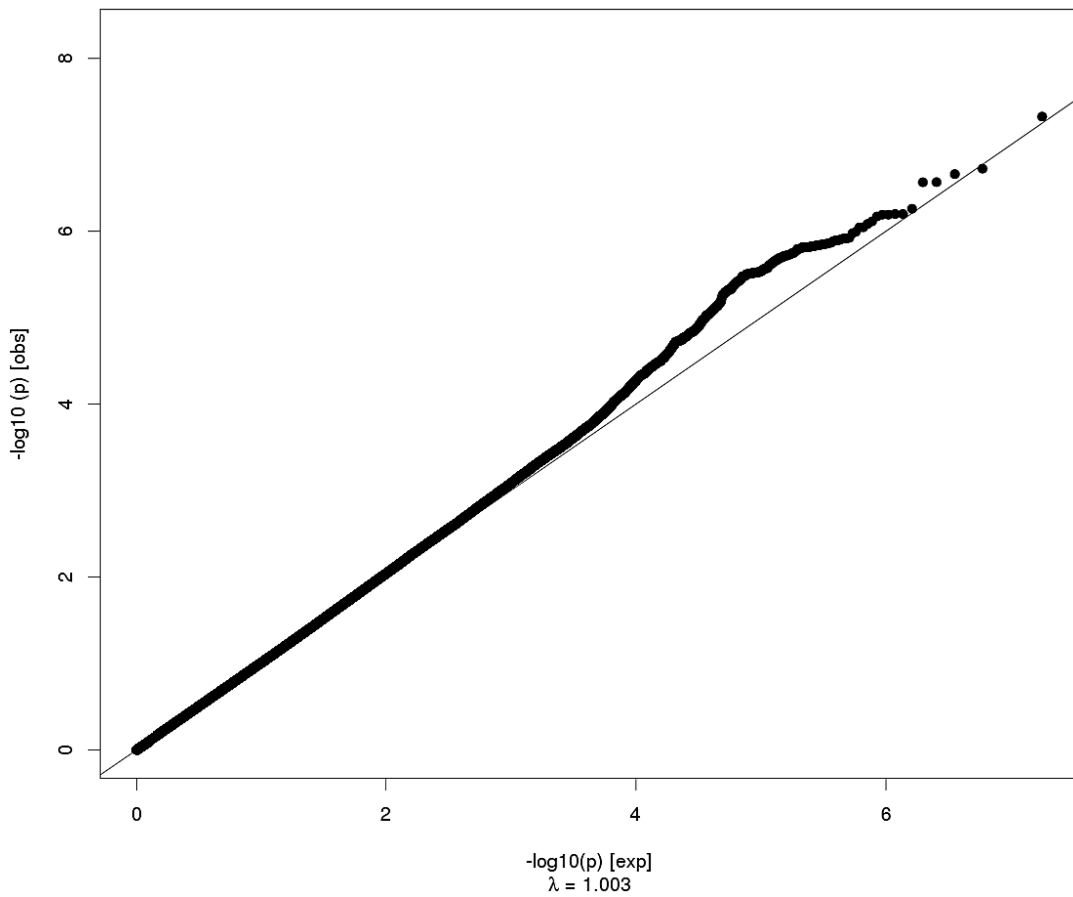
Entorhinal Thickness



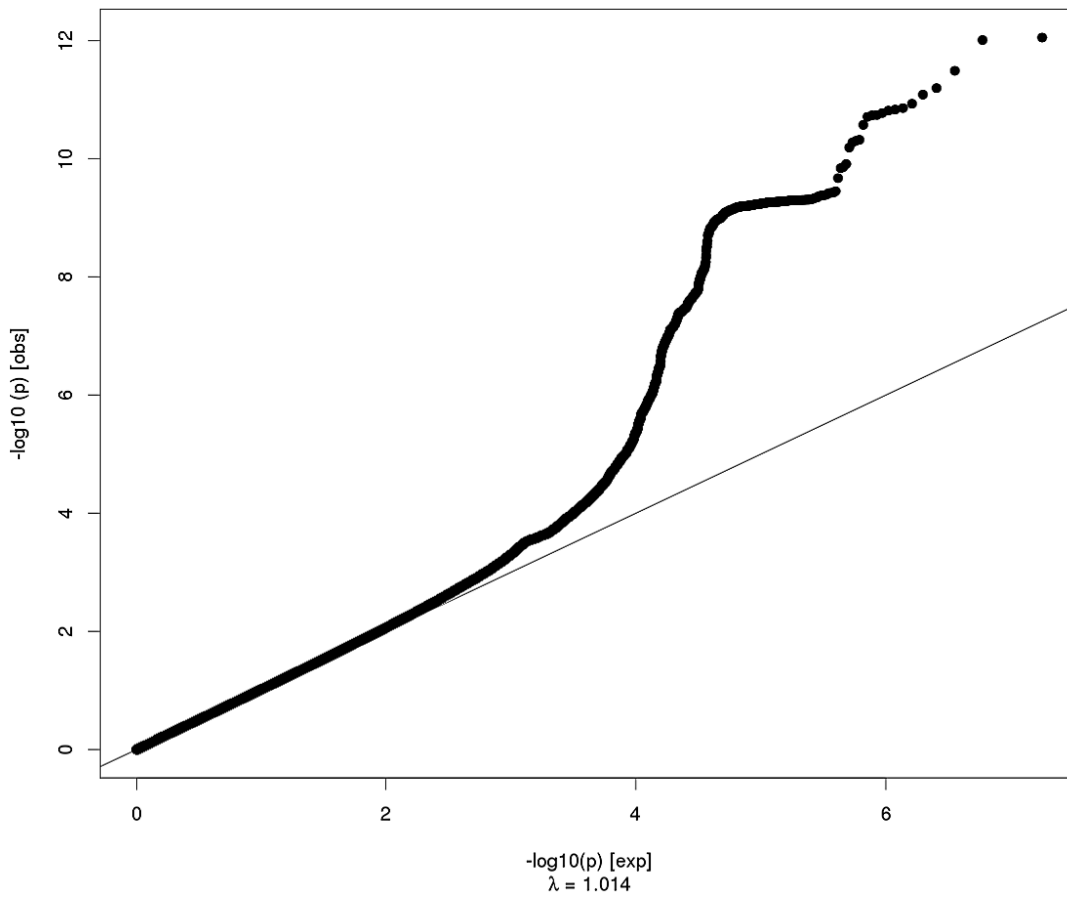
Parahippocampal Surface Area



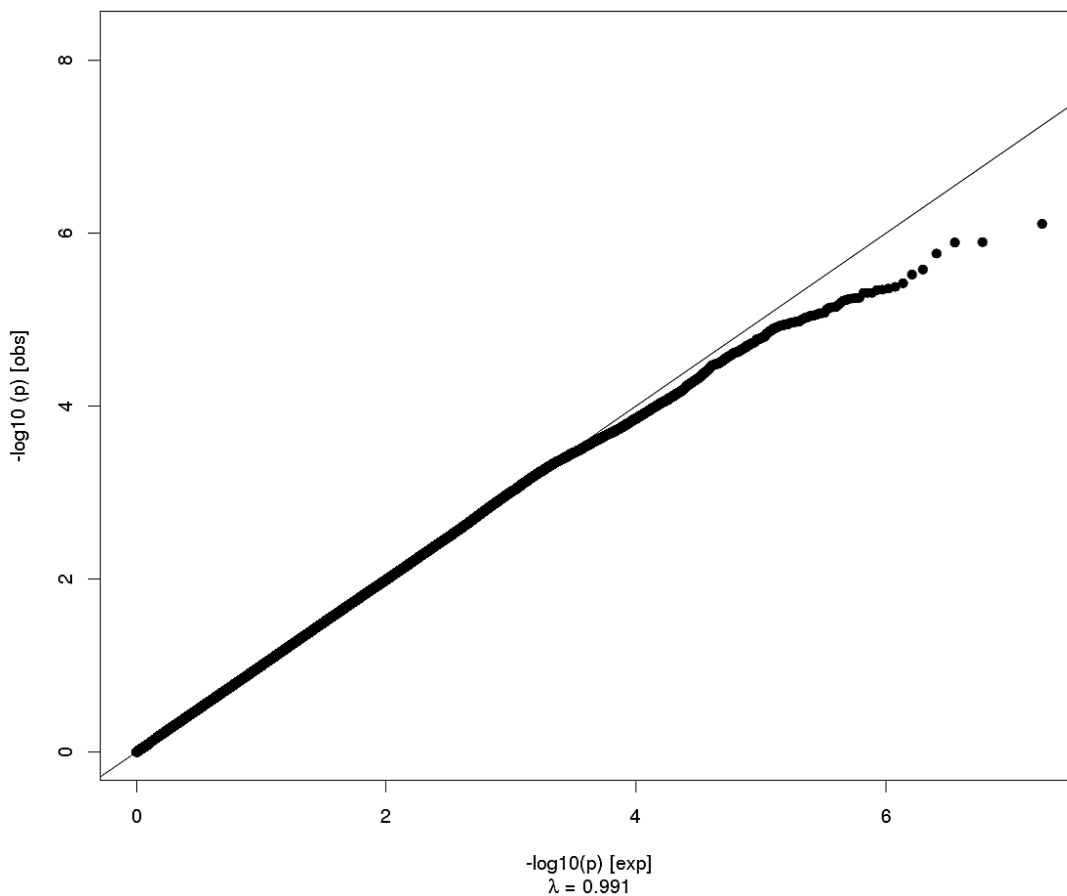
Parahippocampal Thickness



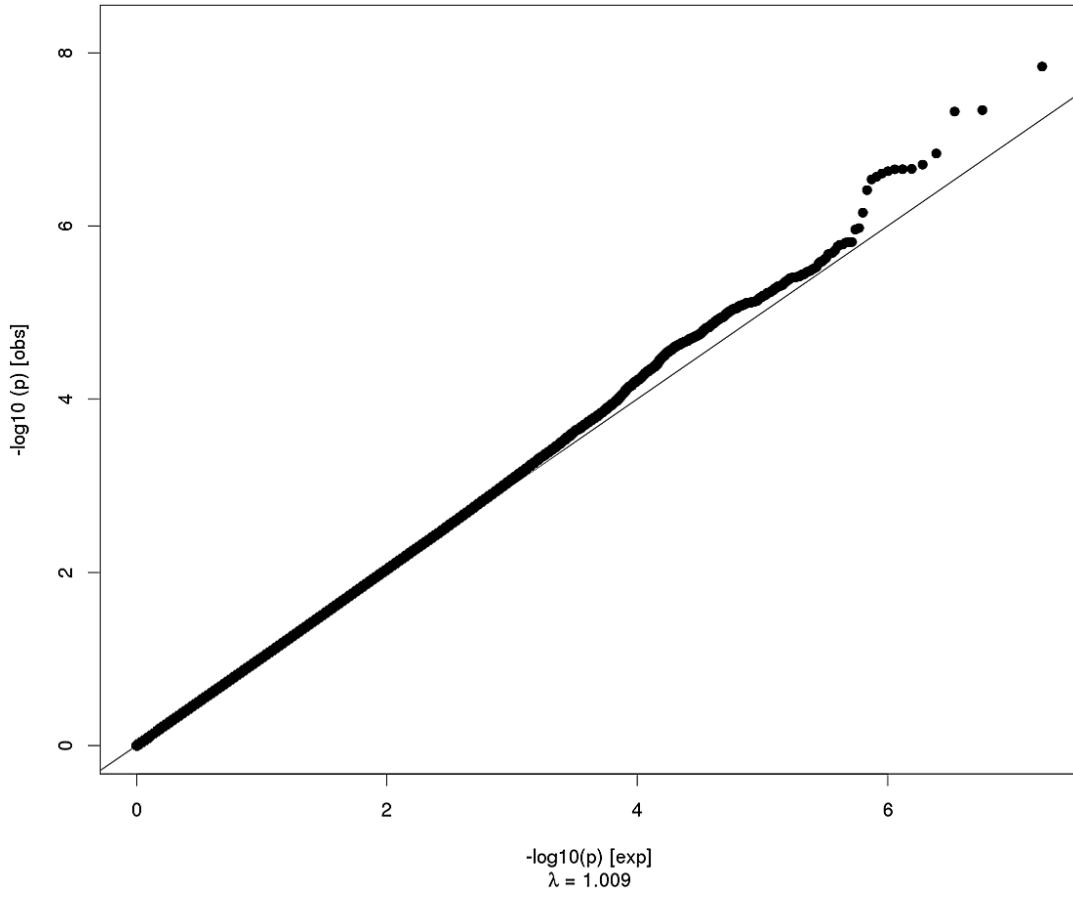
Fusiform Surface Area



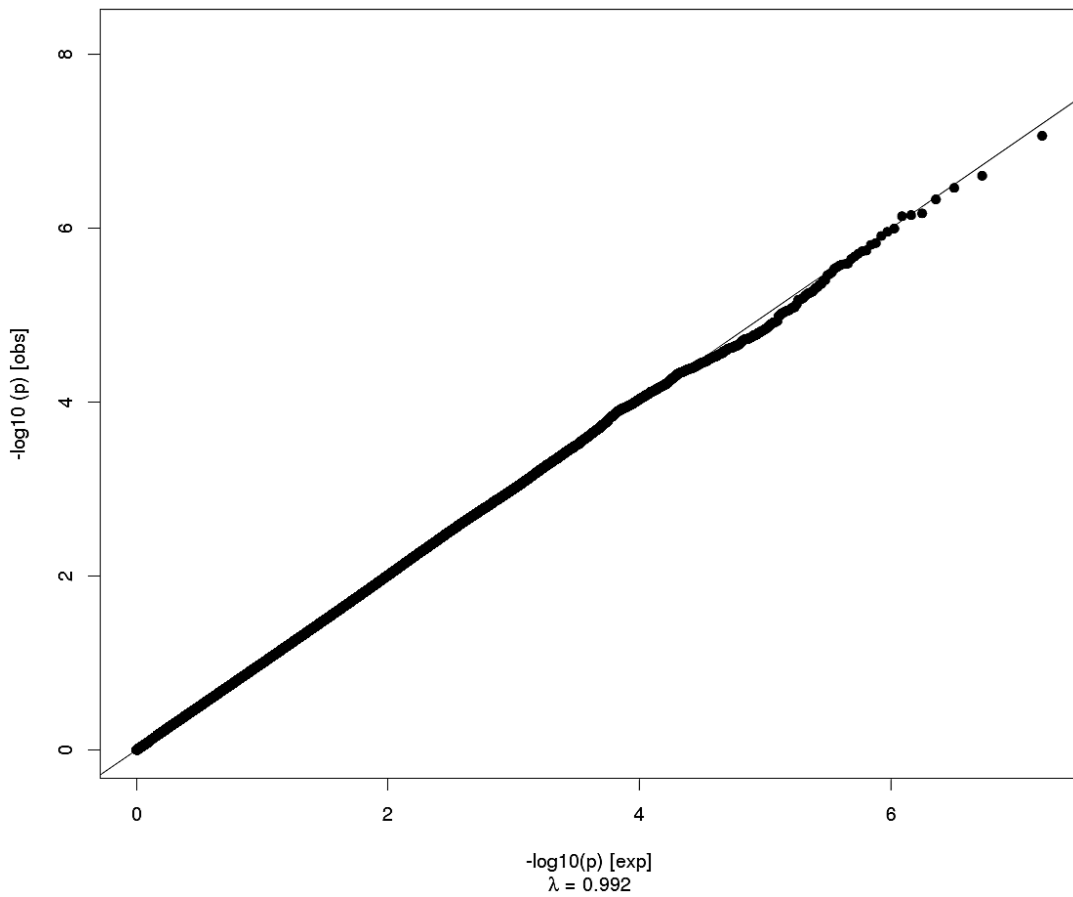
Fusiform Thickness



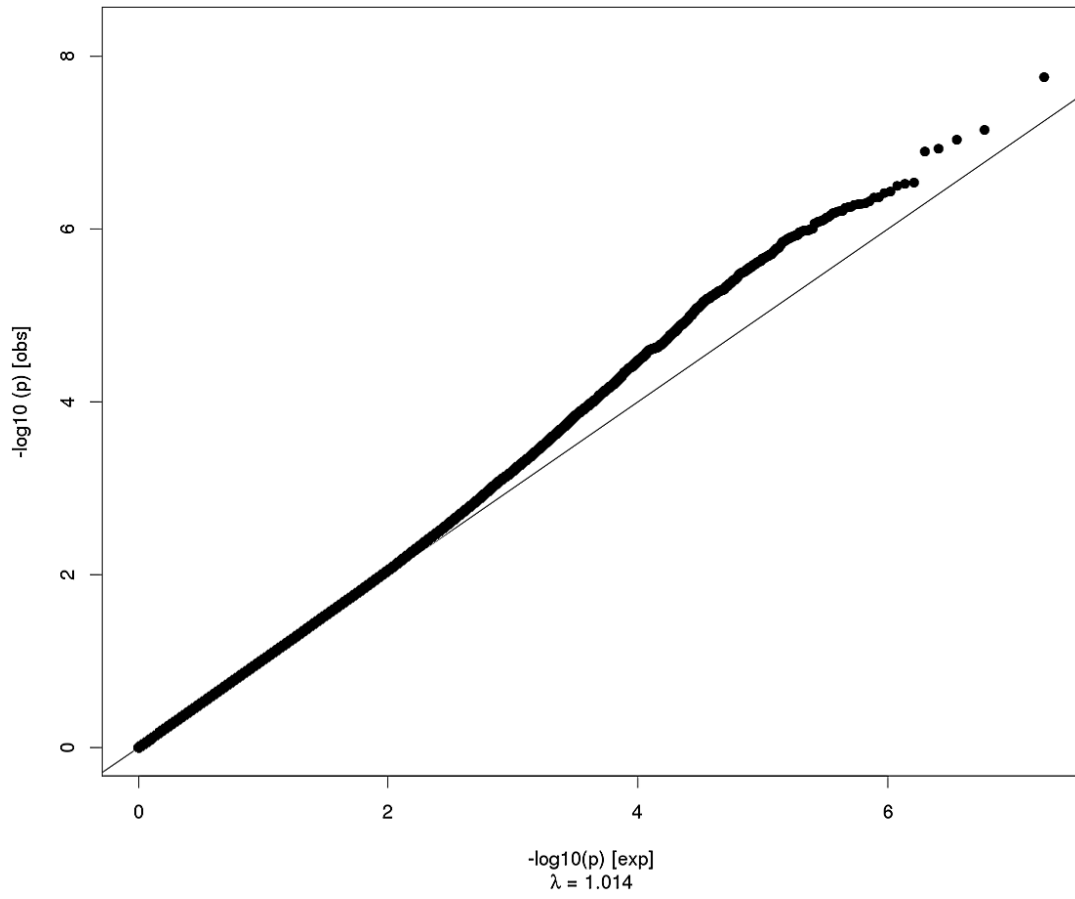
Temporal Pole Surface Area



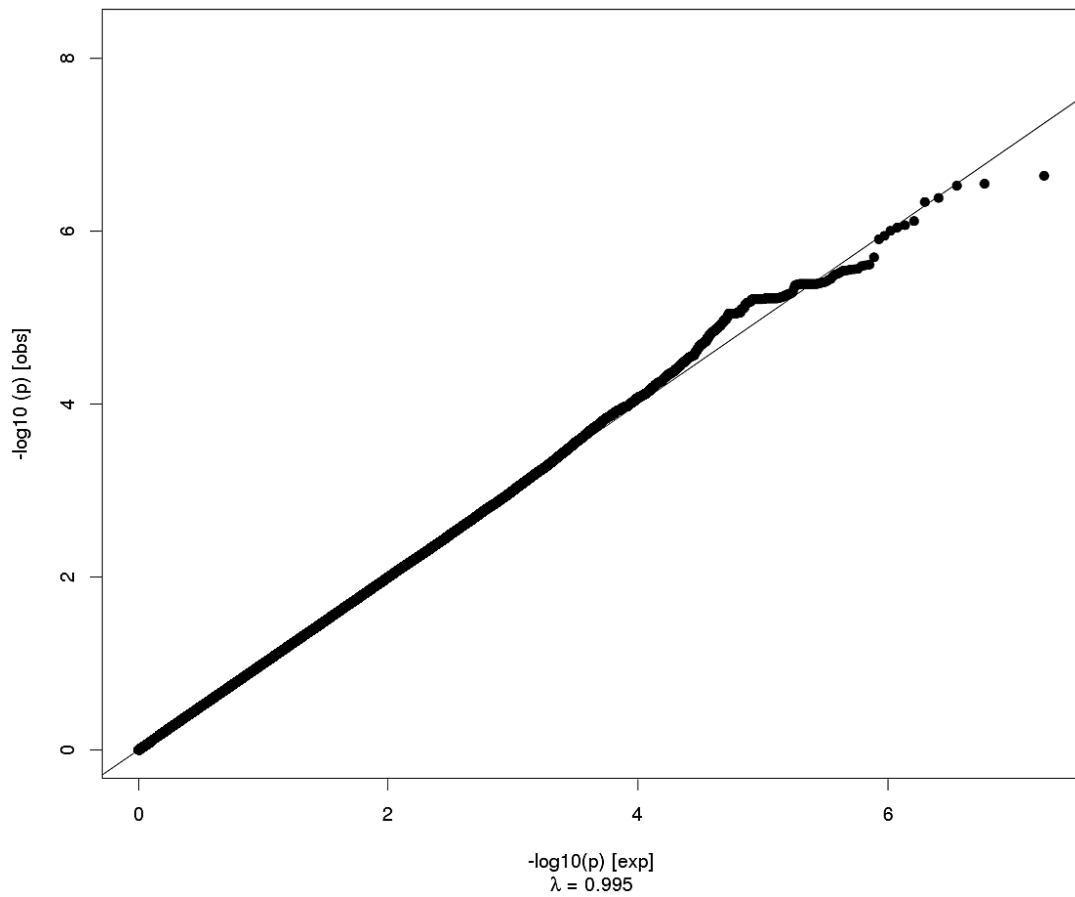
Temporal Pole Thickness



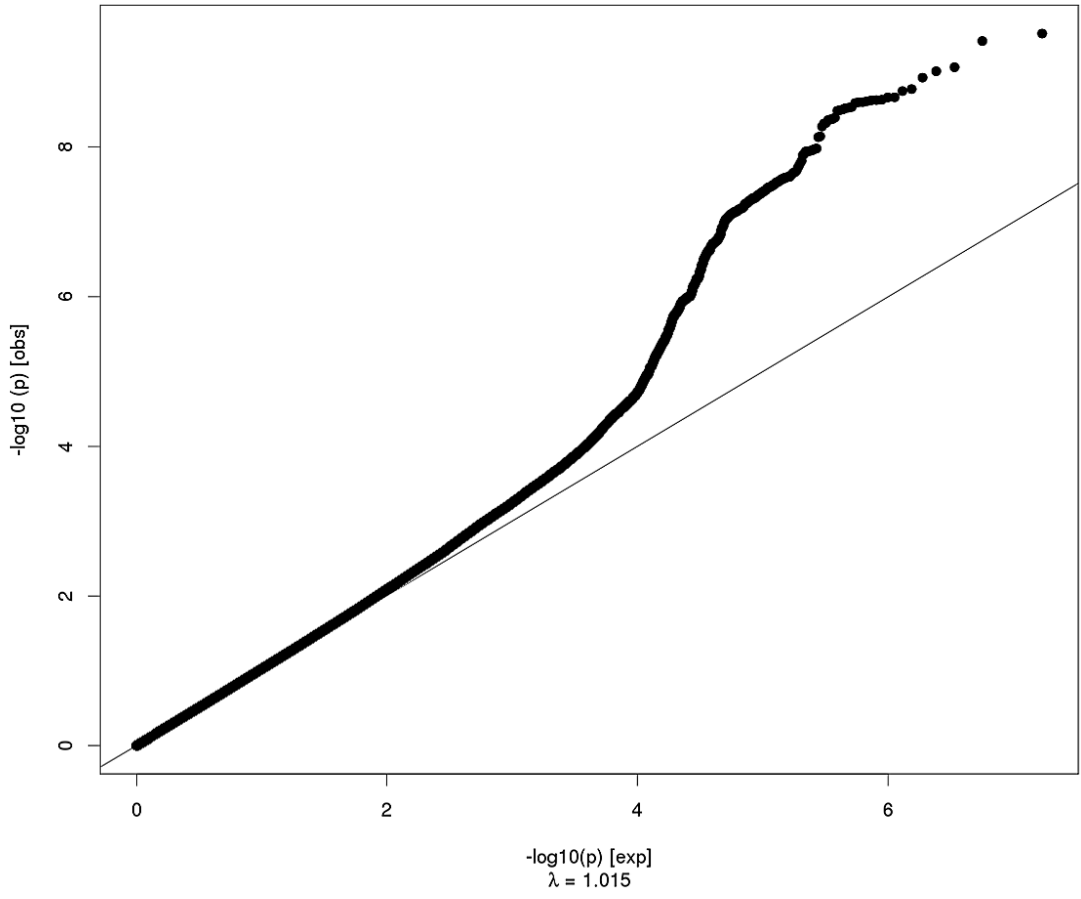
Inferior Temporal Surface Area



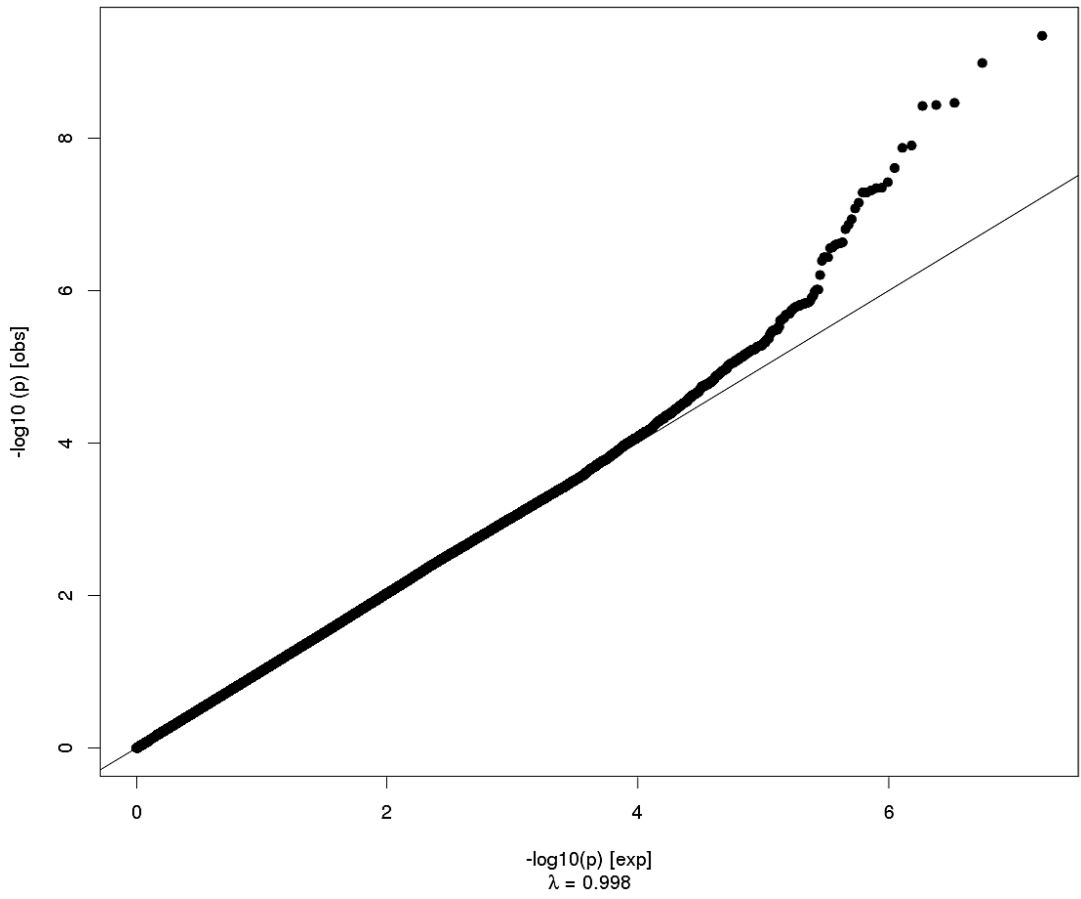
Inferior Temporal Thickness



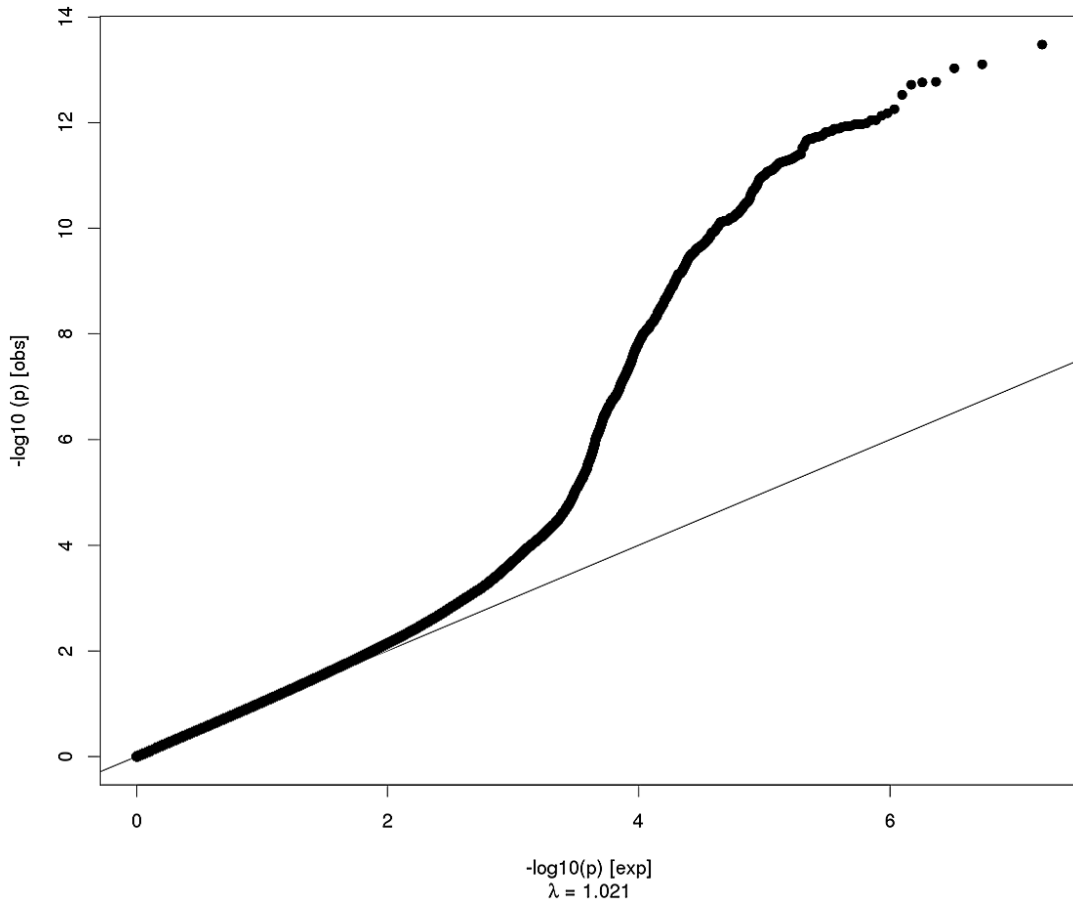
Middle Temporal Surface Area



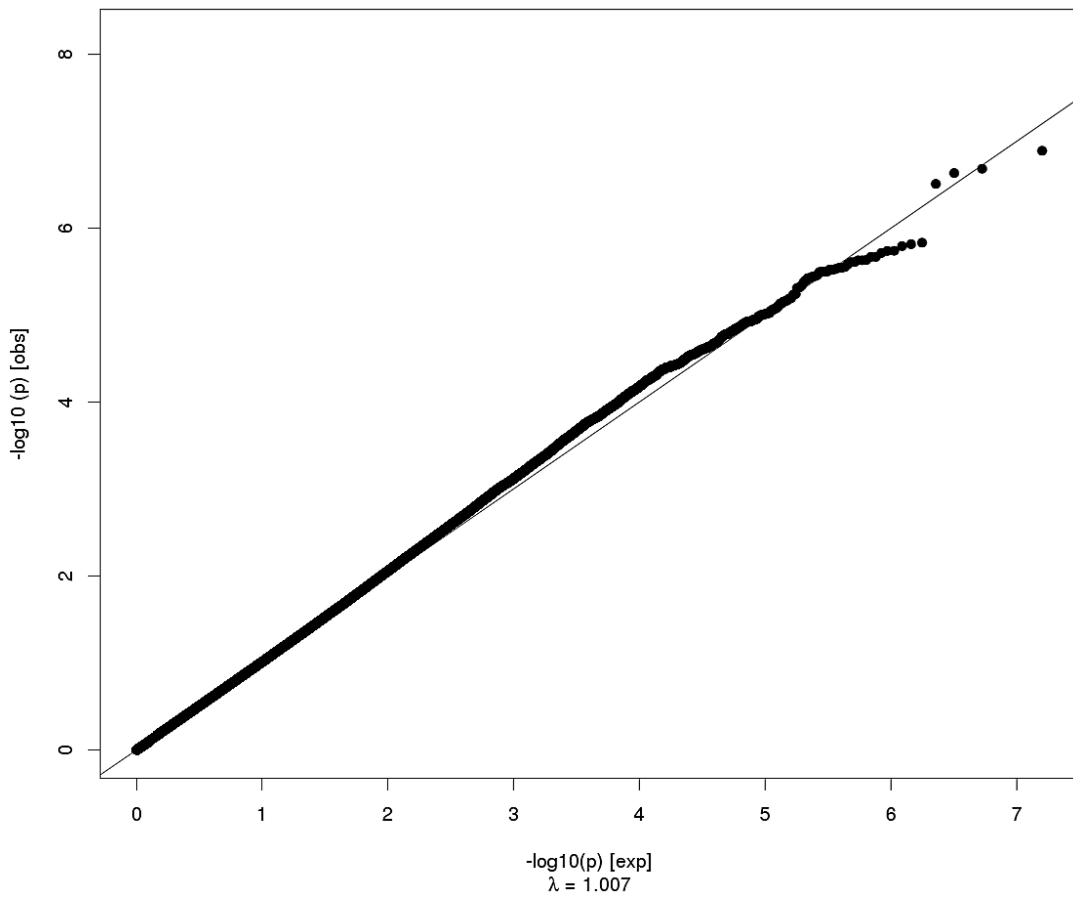
Middle Temporal Thickness



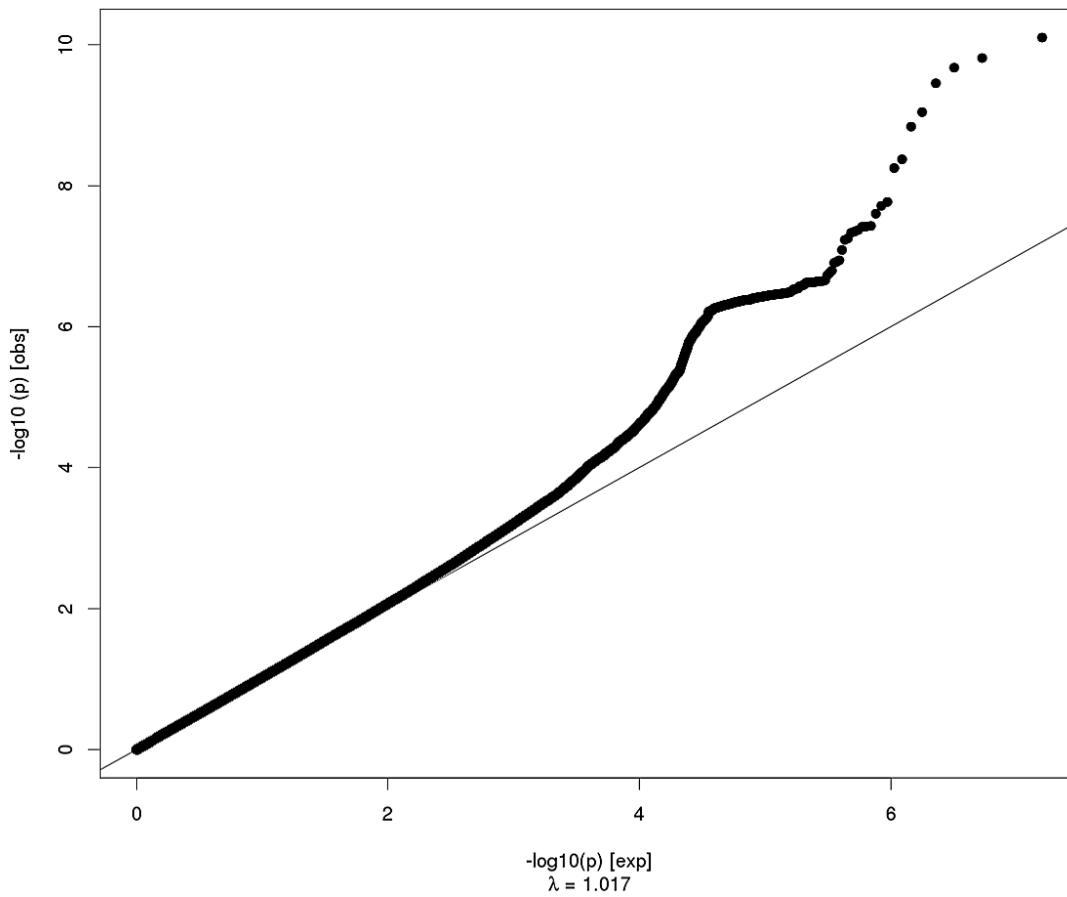
Superior Temporal Surface Area



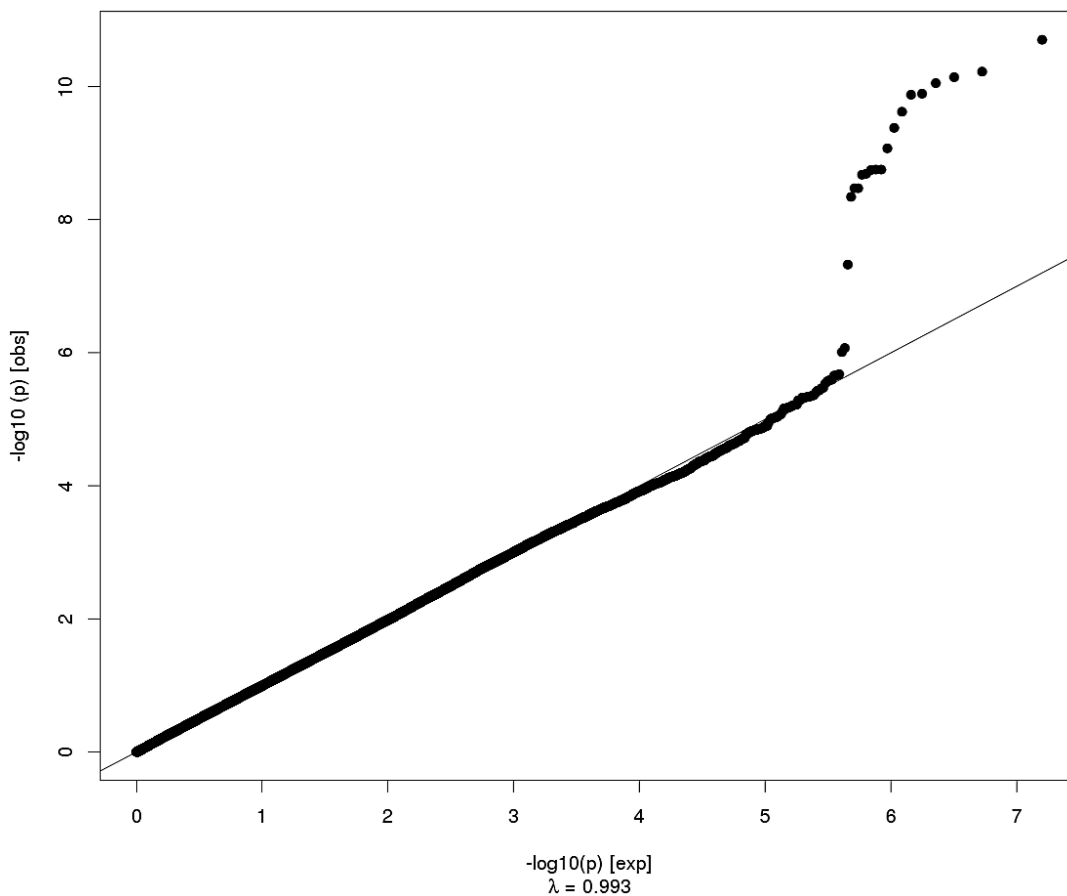
Superior Temporal Thickness



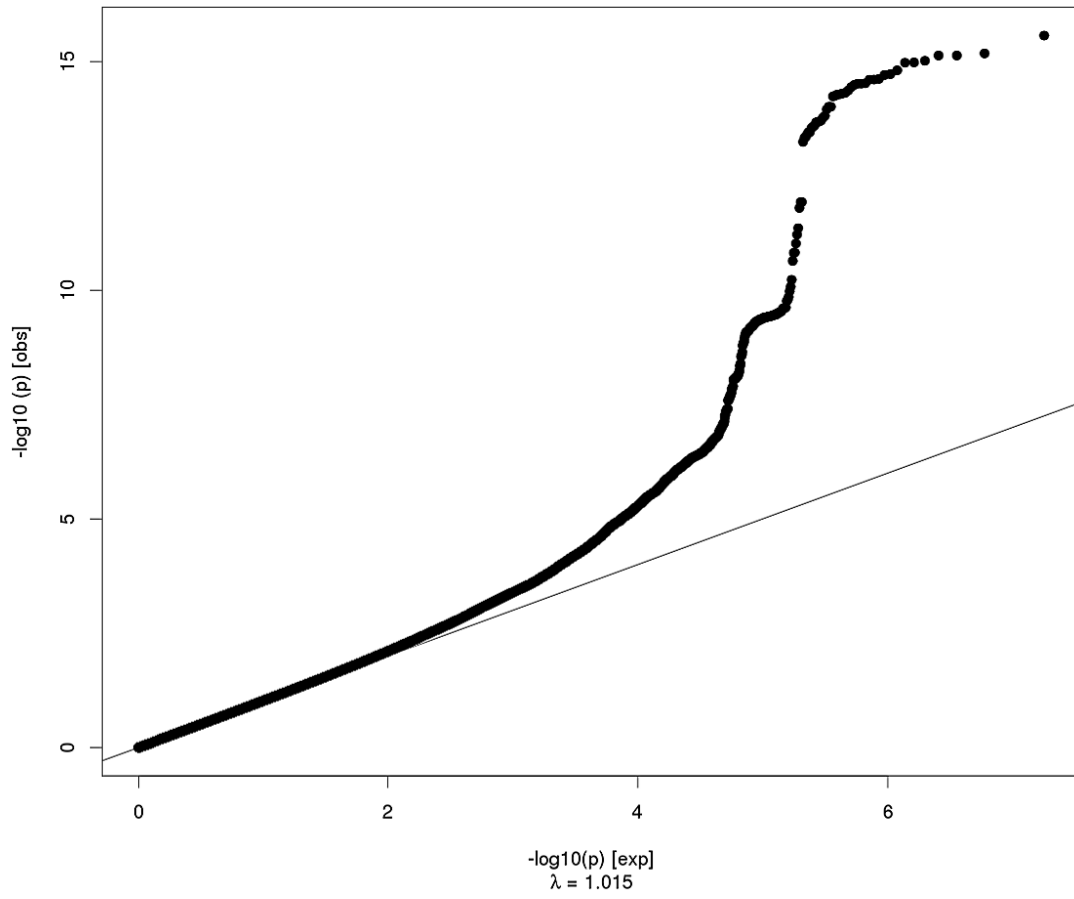
Banks of the Superior Temporal Sulcus Surface Area



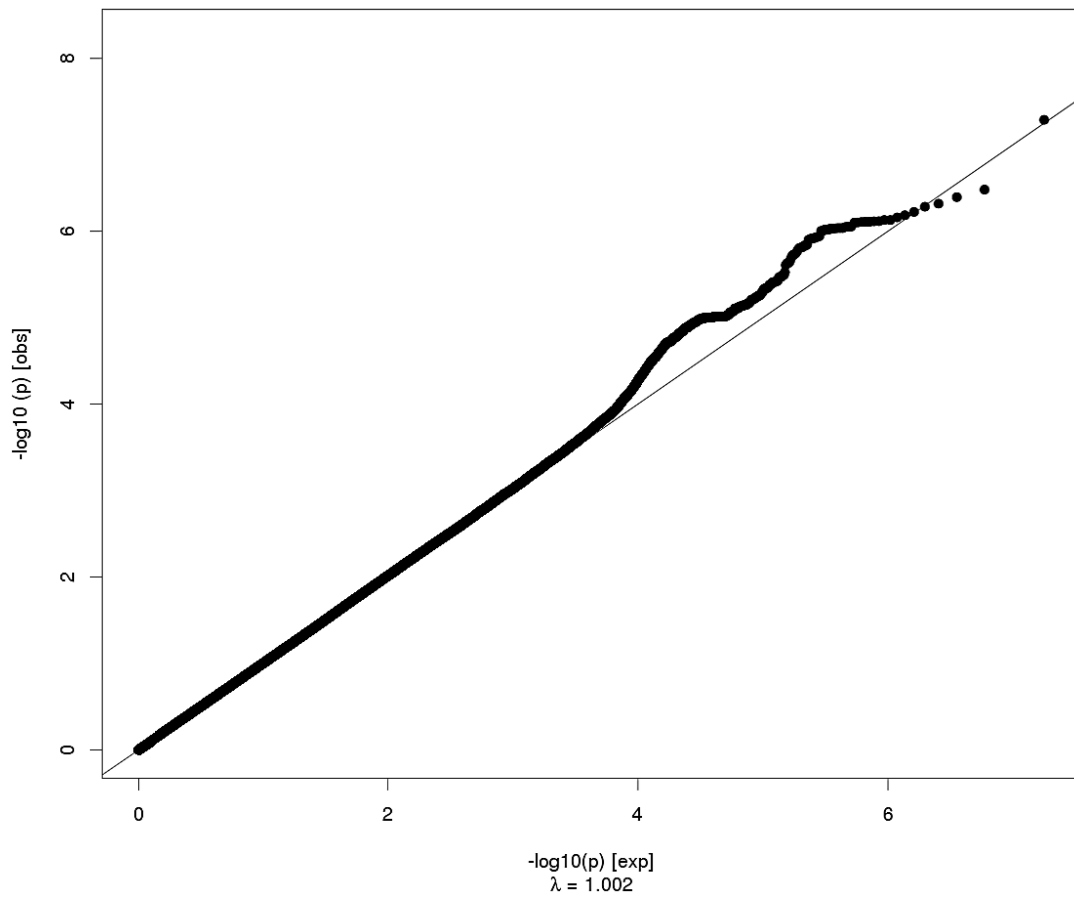
Banks of the Superior Temporal Sulcus Thickness



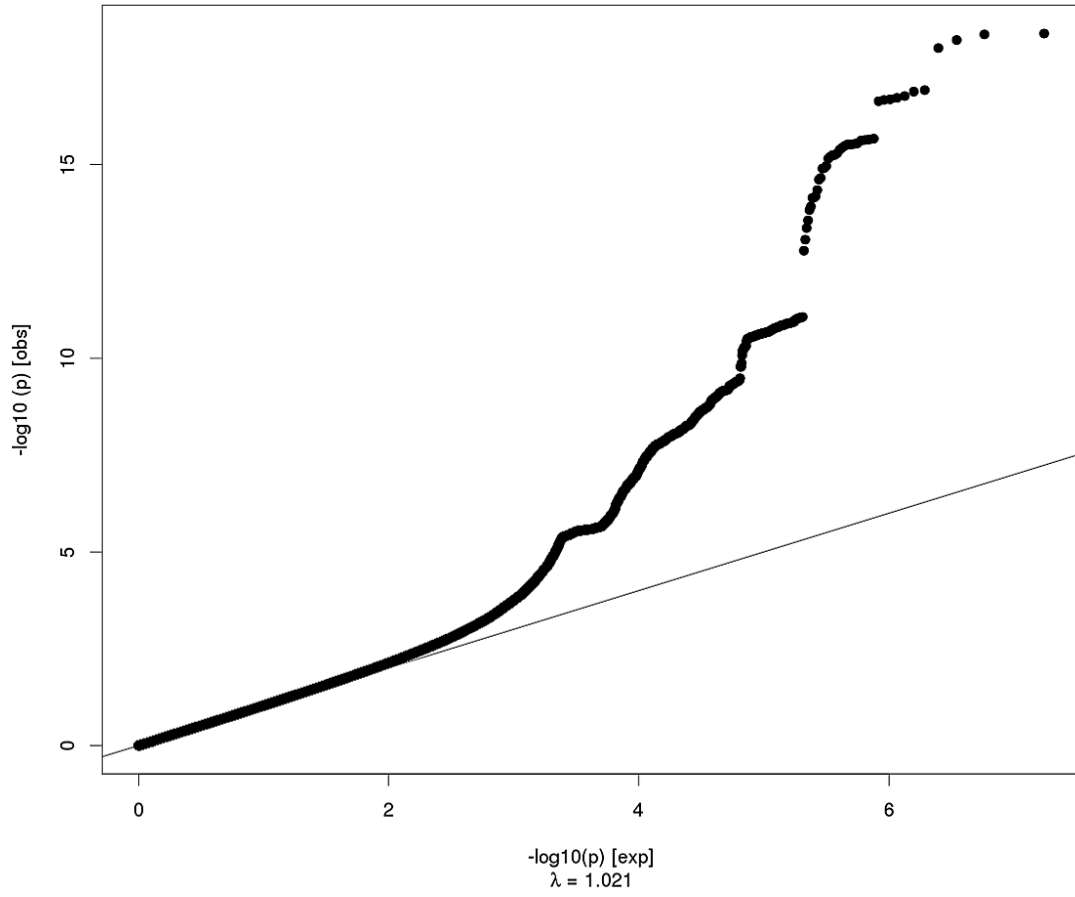
Transverse Temporal Surface Area



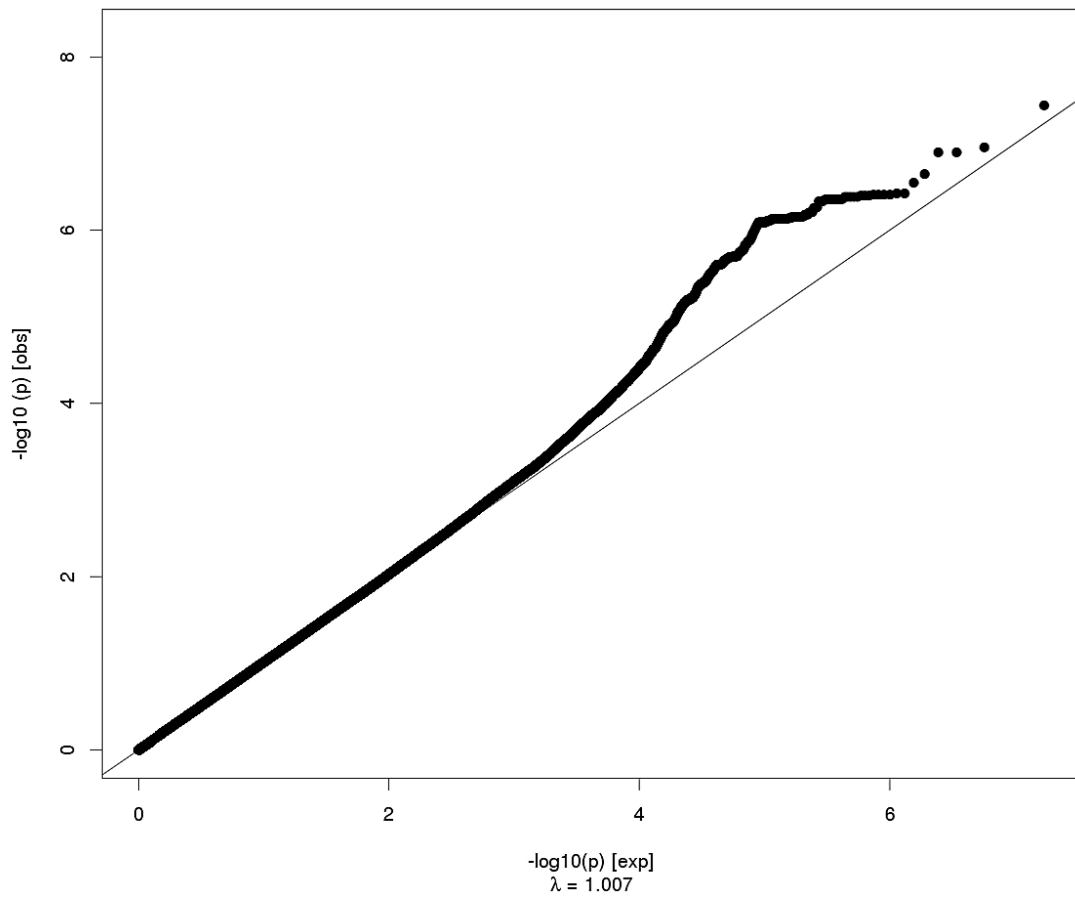
Transverse Temporal Thickness



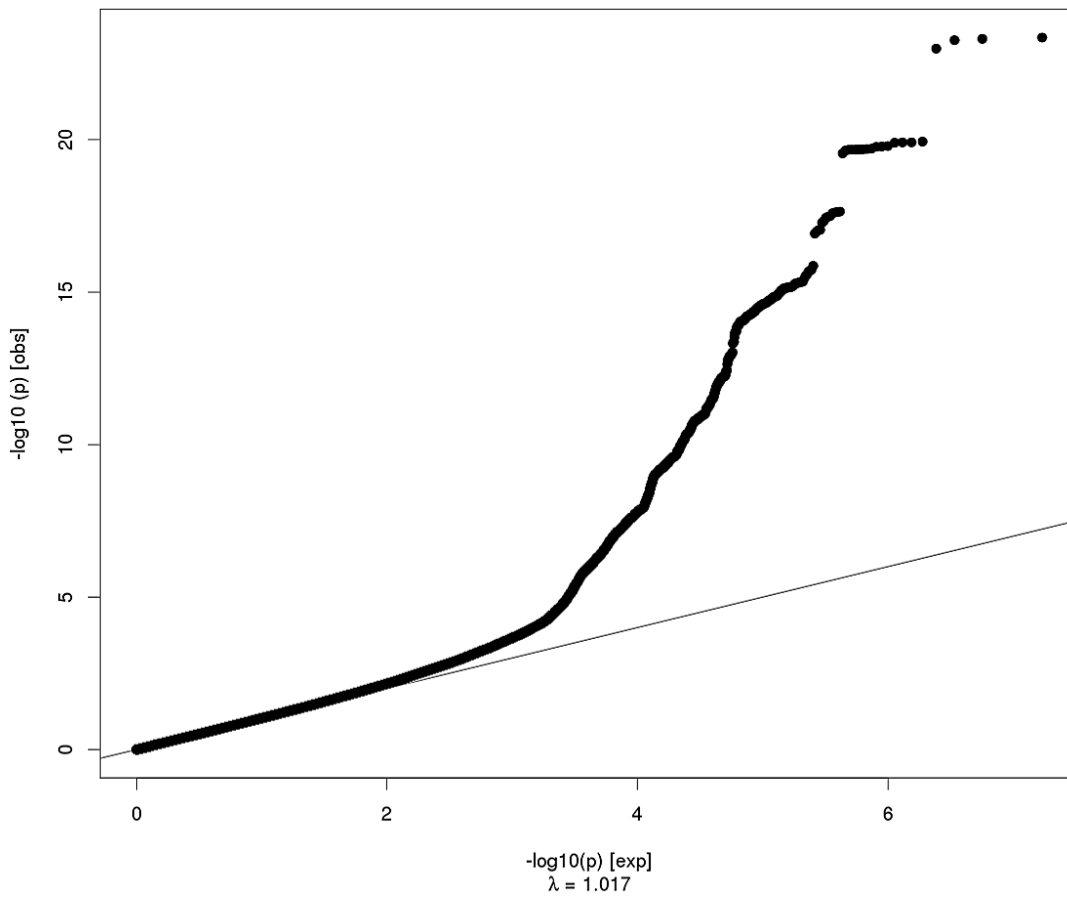
Lingual Surface Area



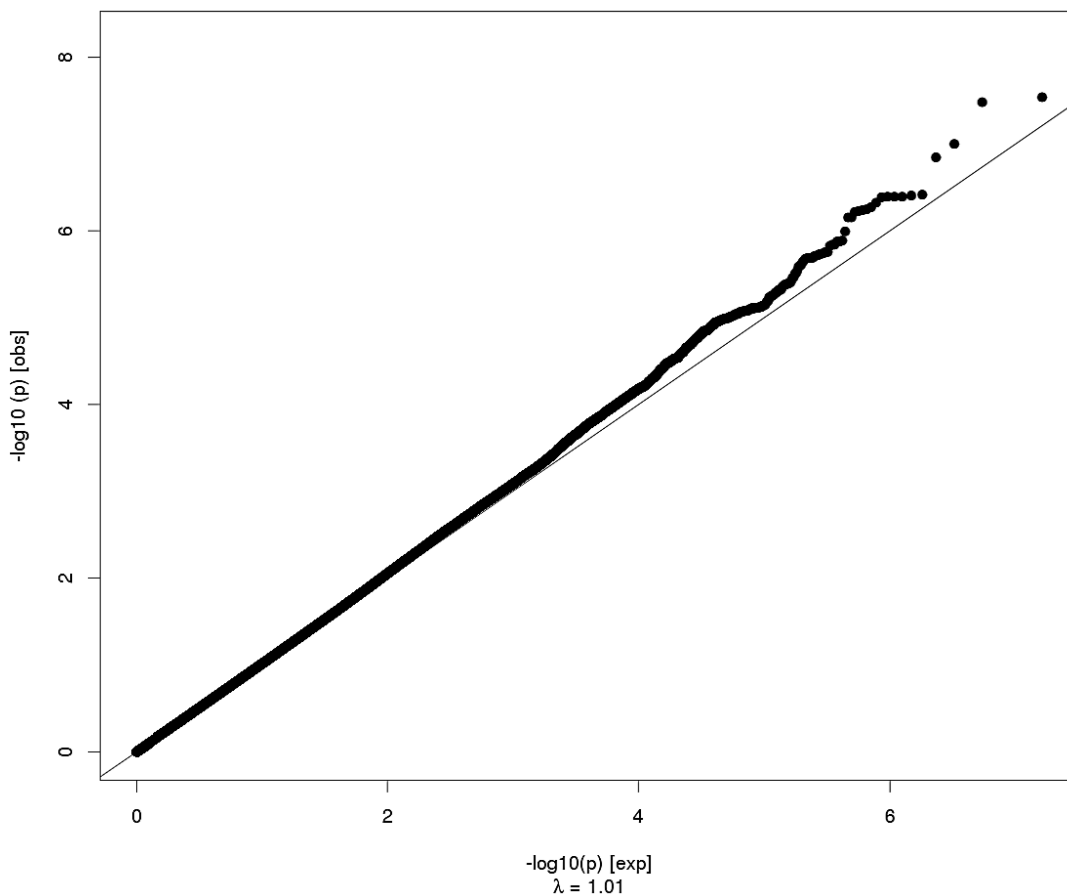
Lingual Thickness



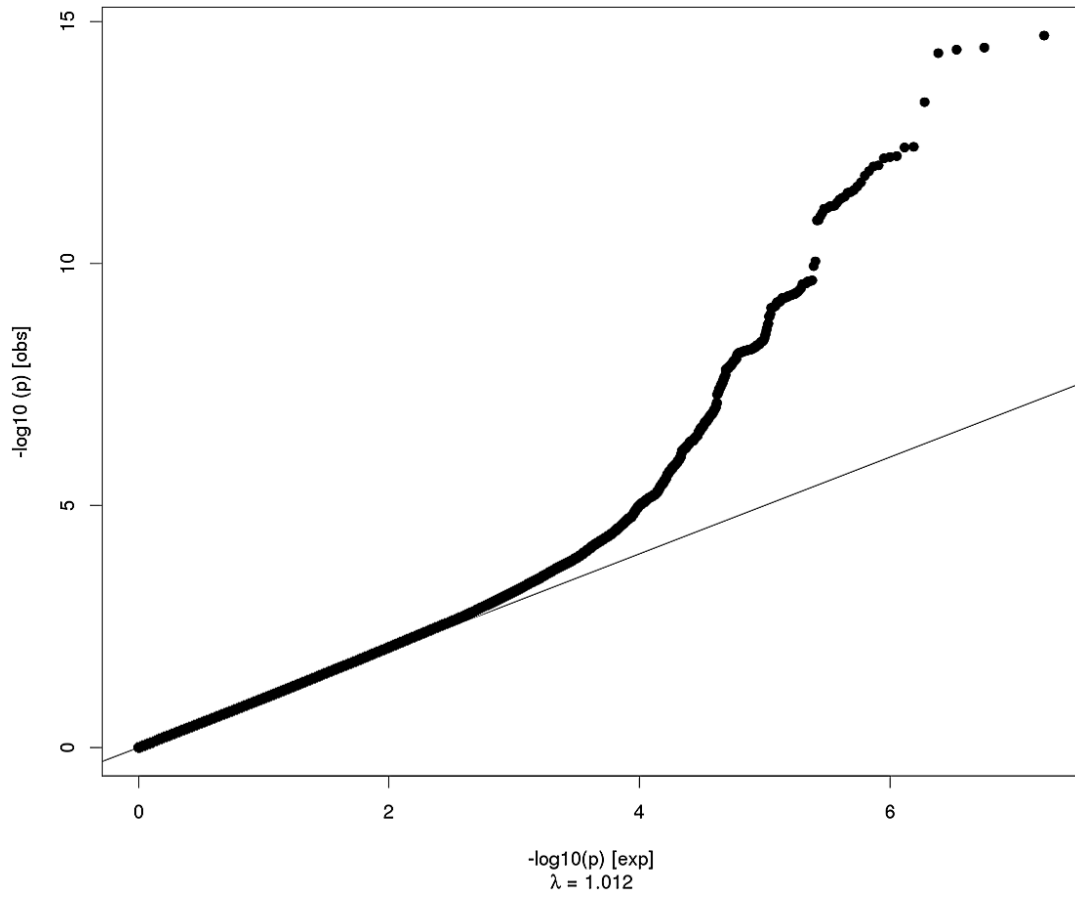
Pericalcarine Surface Area



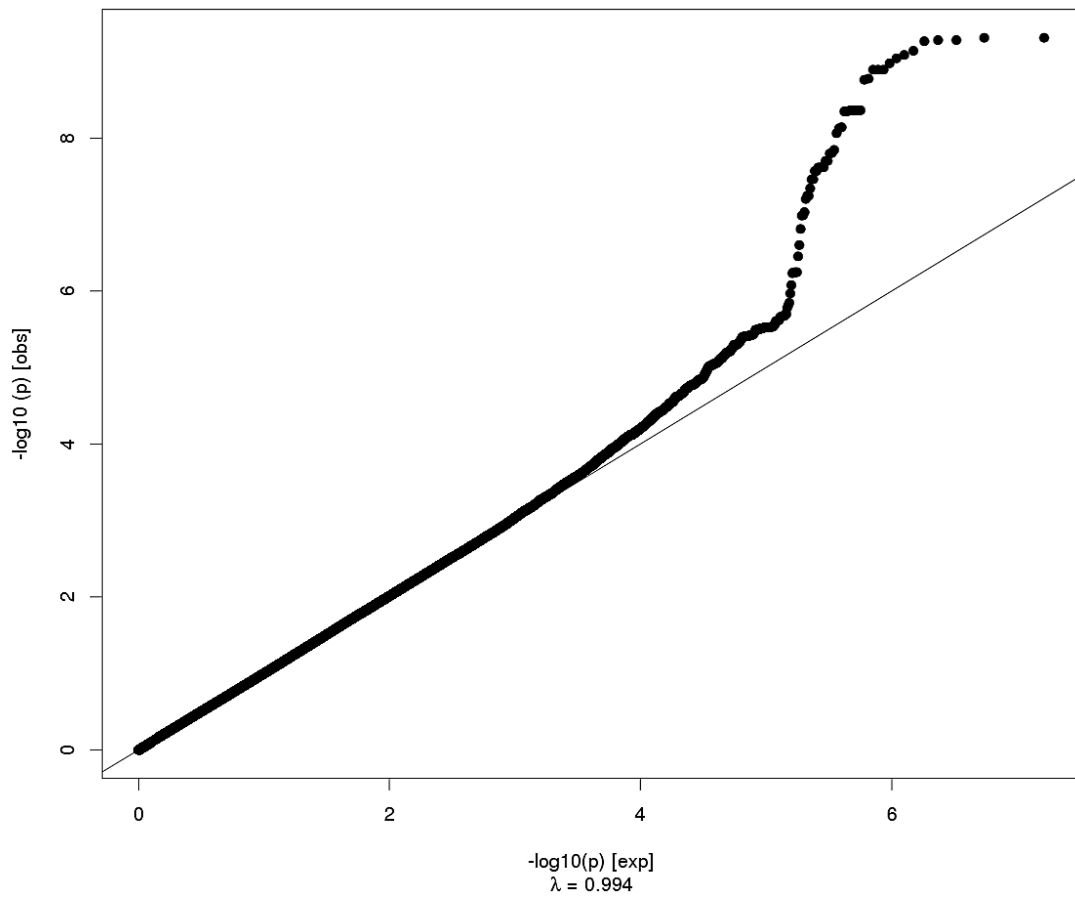
Pericalcarine Thickness



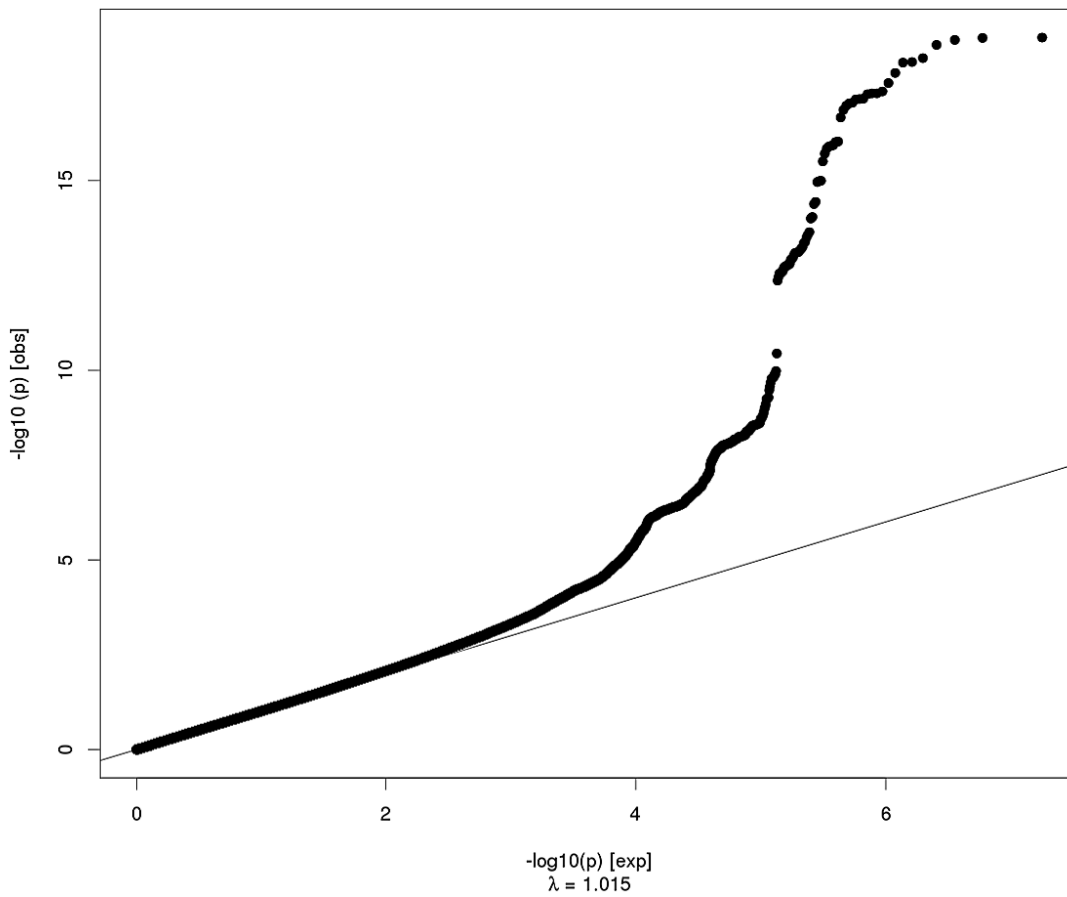
Cuneus Surface Area



Cuneus Thickness



Lateral Occipital Surface Area



Lateral Occipital Thickness

