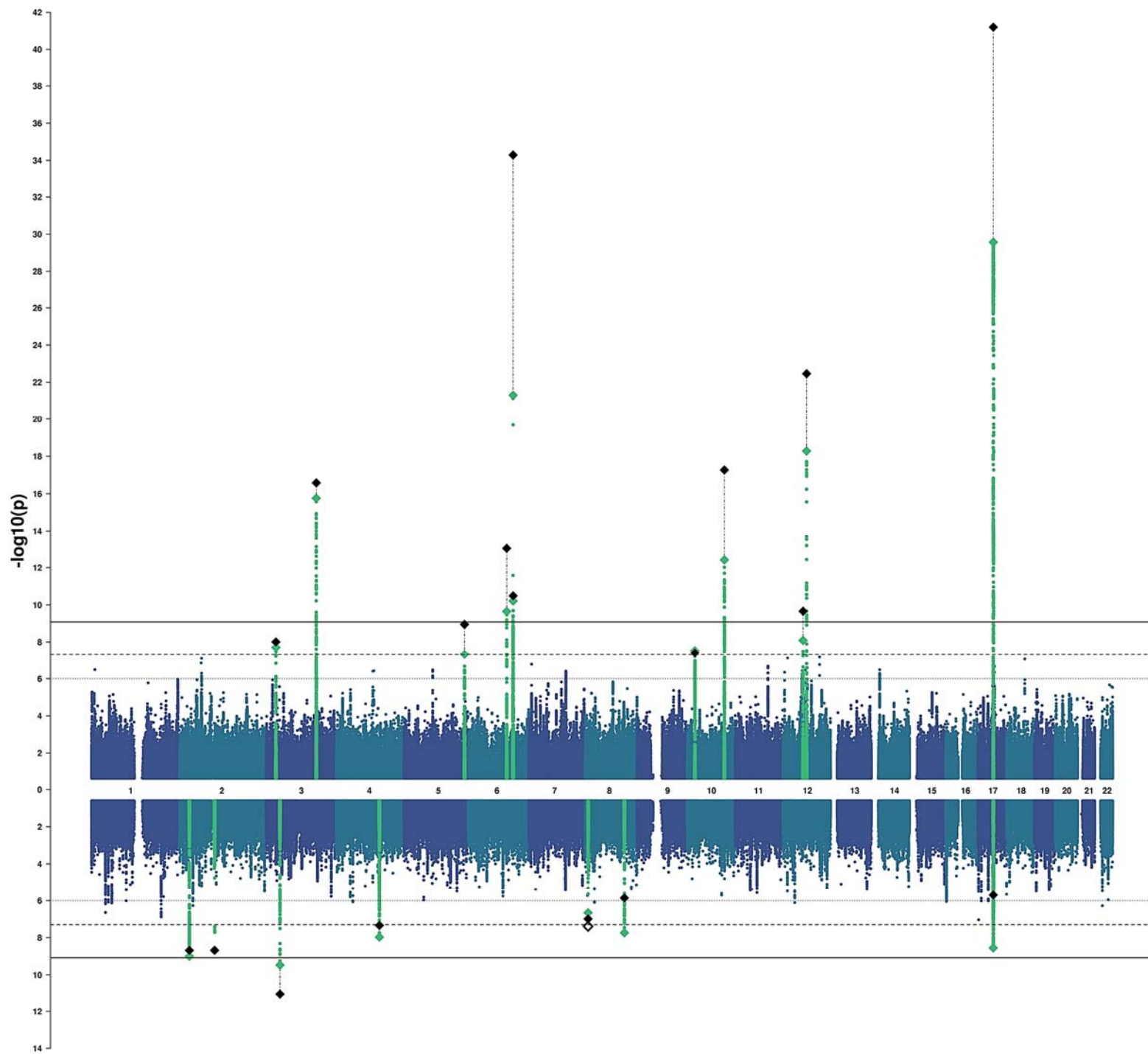


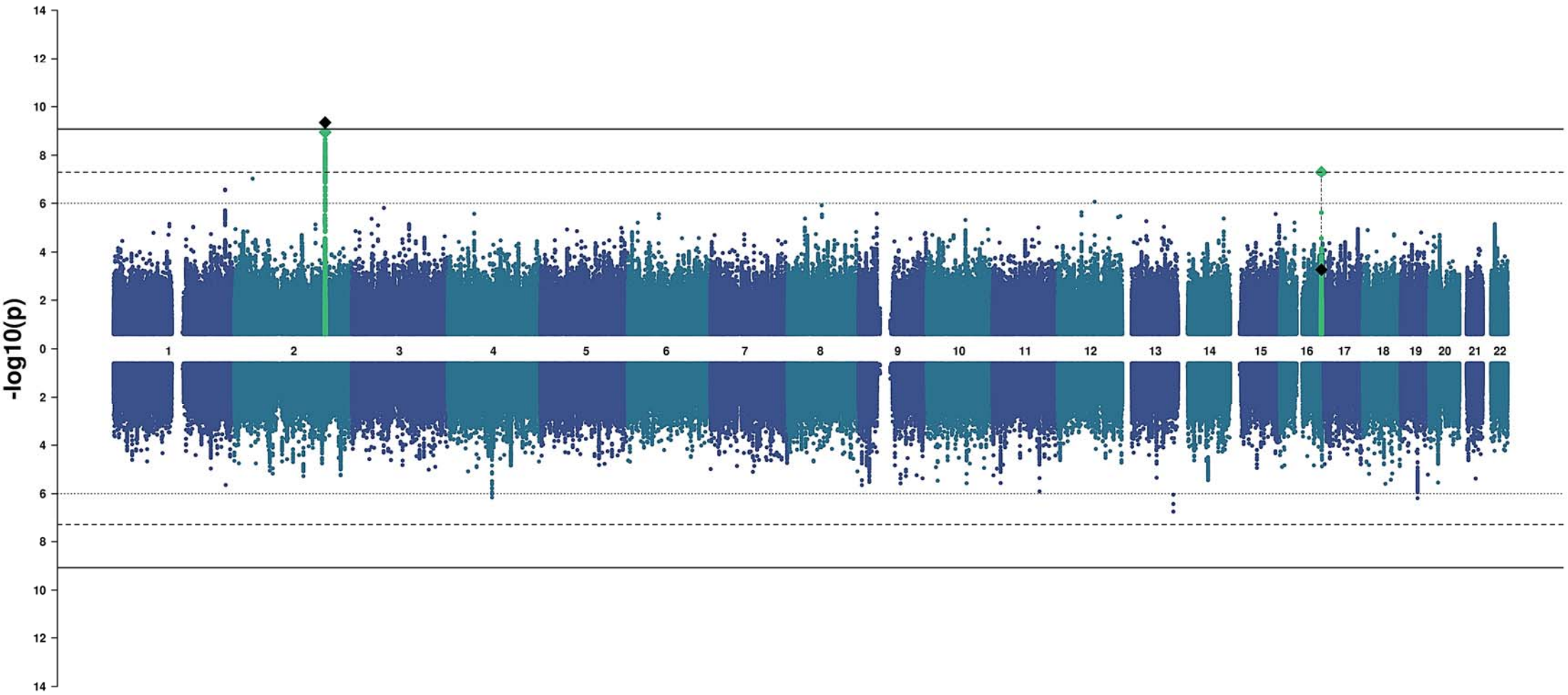
Manhattan plots - within each plot, the Manhattan plot for surface area is shown above the x axis and the Manhattan plot for thickness is shown below.

Region#	Phenotype	Page
0	Global	2
1	Frontal Pole	3
2	Medial Orbitofrontal	4
3	Lateral Orbitofrontal	5
4	Rostral Anterior Cingulate	6
5	Caudal Anterior Cingulate	7
6	Superior Frontal	8
7	Rostral Middle Frontal	9
8	Pars Orbitalis	10
9	Pars Triangularis	11
10	Pars Opercularis	12
11	Caudal Middle Frontal	13
12	Paracentral	14
13	Precentral	15
14	Postcentral	16
15	Precuneus	17
16	Superior Parietal	18
17	Supramarginal	19
18	Inferior Parietal	20
19	Posterior Cingulate	21
20	Isthmus Cingulate	22
21	Insula	23
22	Entorhinal	24
23	Parahippocampal	25
24	Fusiform	26
25	Temporal Pole	27
26	Inferior Temporal	28
27	Middle Temporal	29
28	Superior Temporal	30
29	Banks of the Superior Temporal Sulcus	31
30	Transverse Temporal	32
31	Lingual	33
32	Pericalcarine	34
33	Cuneus	35
34	Lateral Occipital	36

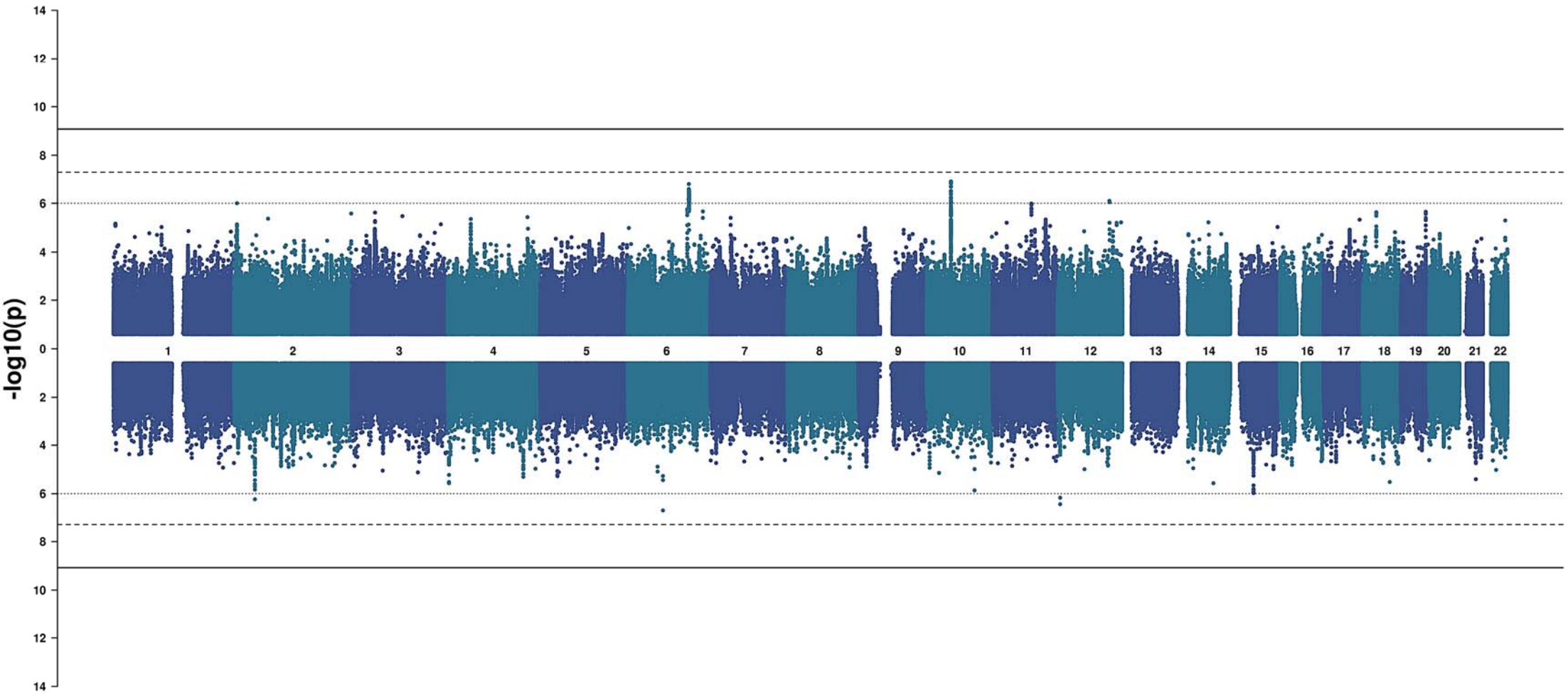
Global



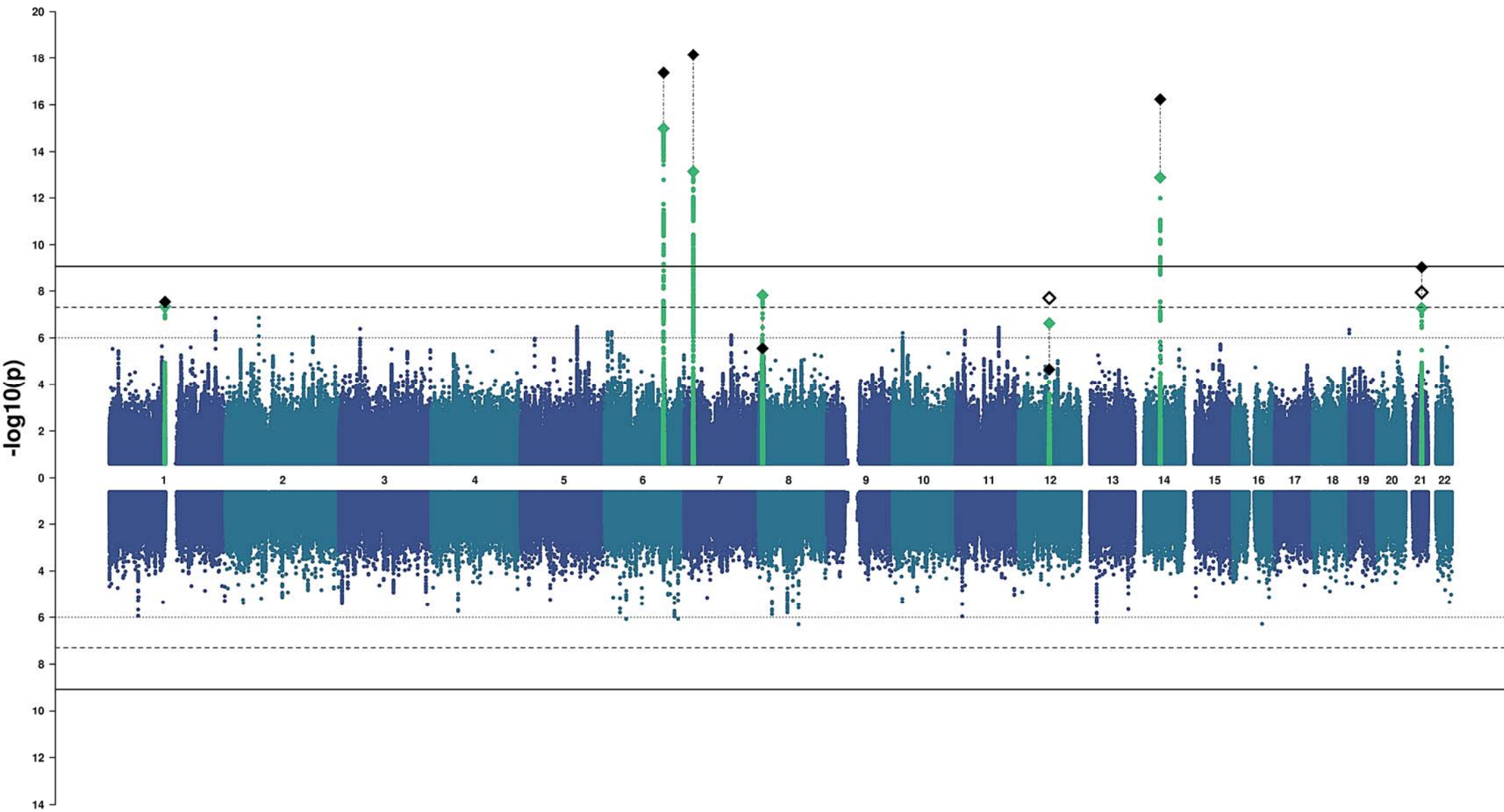
Frontal Pole



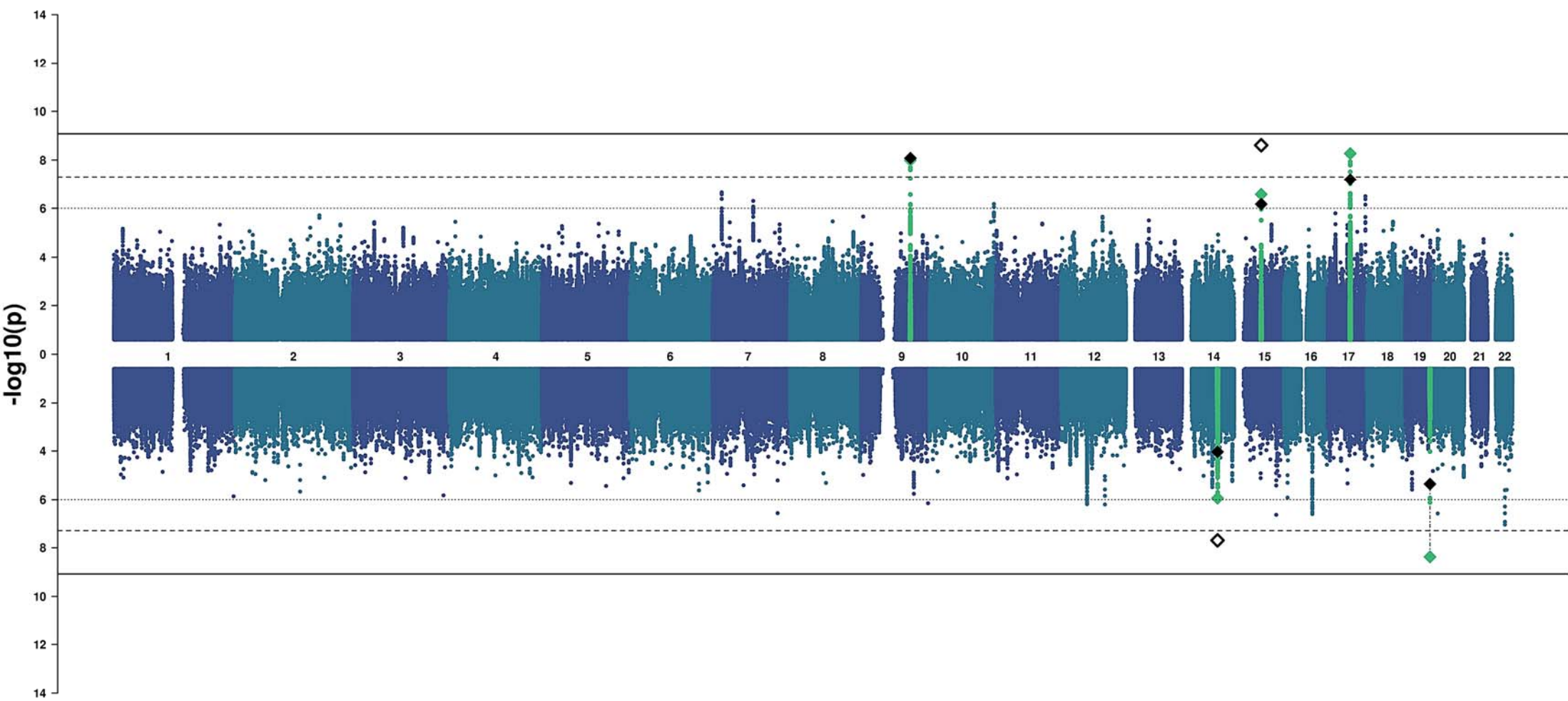
Medial Orbitofrontal



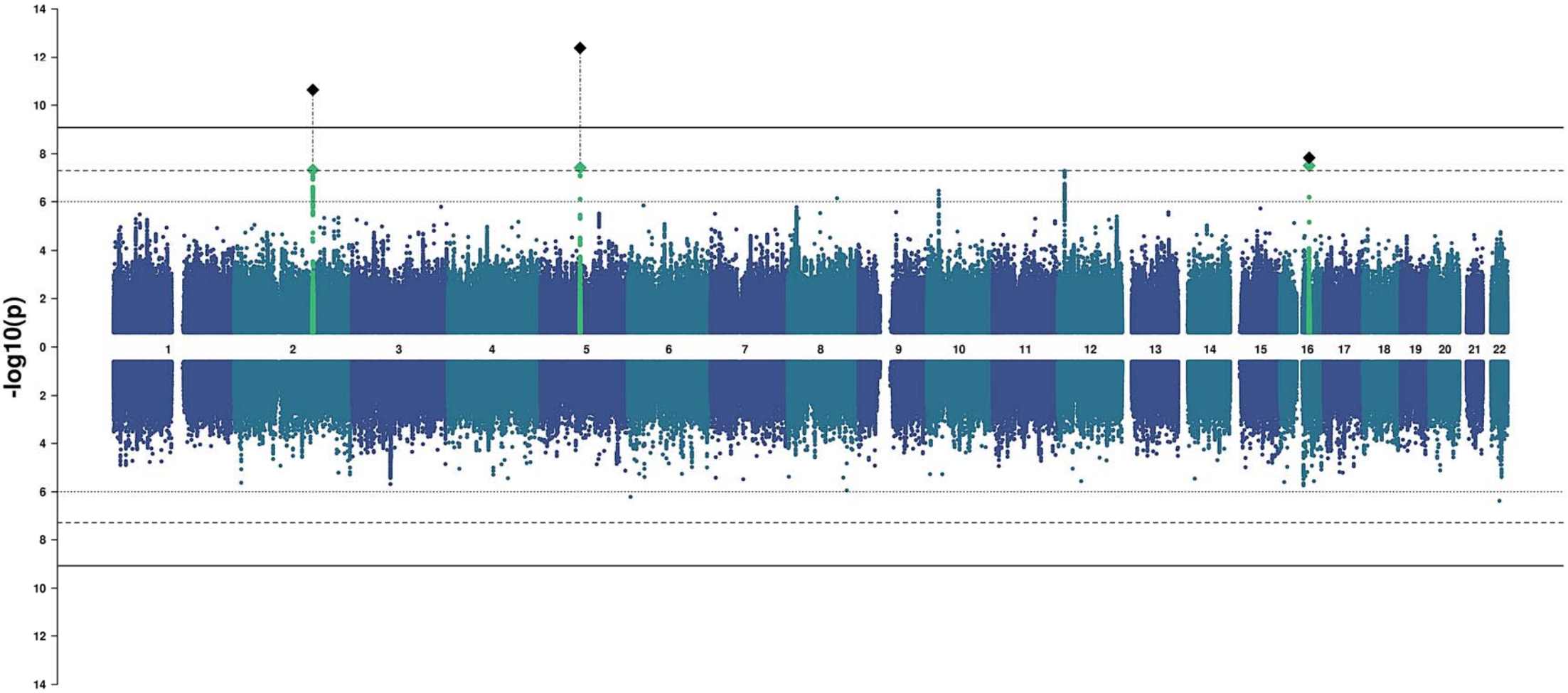
Lateral Orbitofrontal



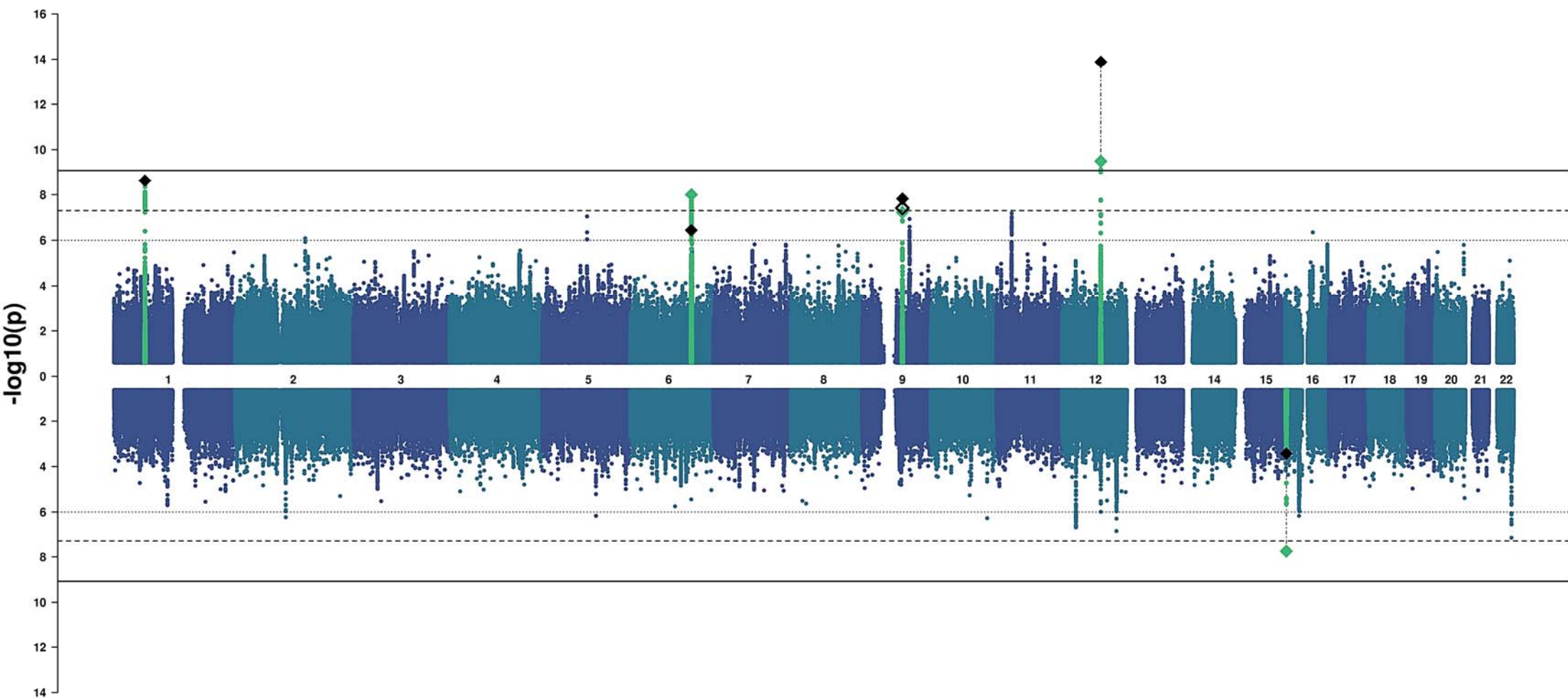
Rostral Anterior Cingulate



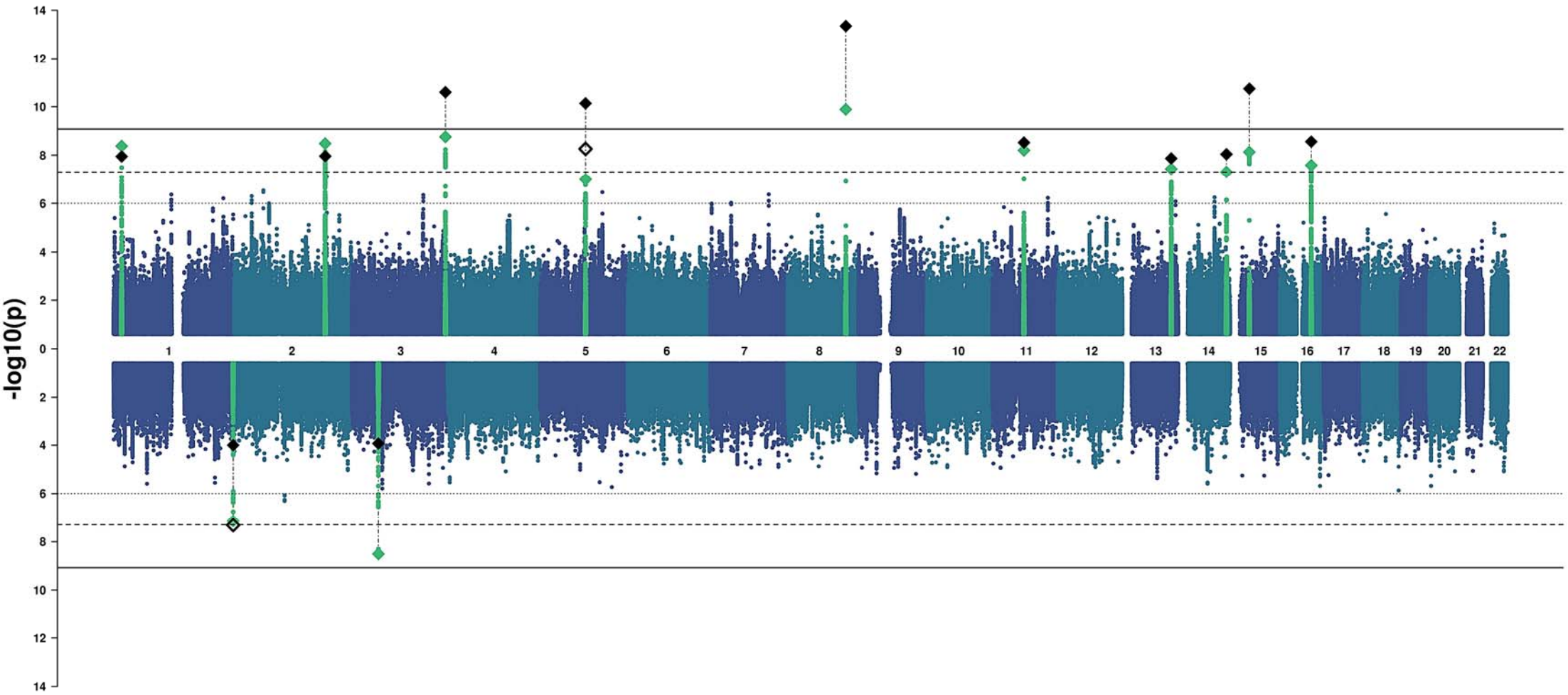
Caudal Anterior Cingulate



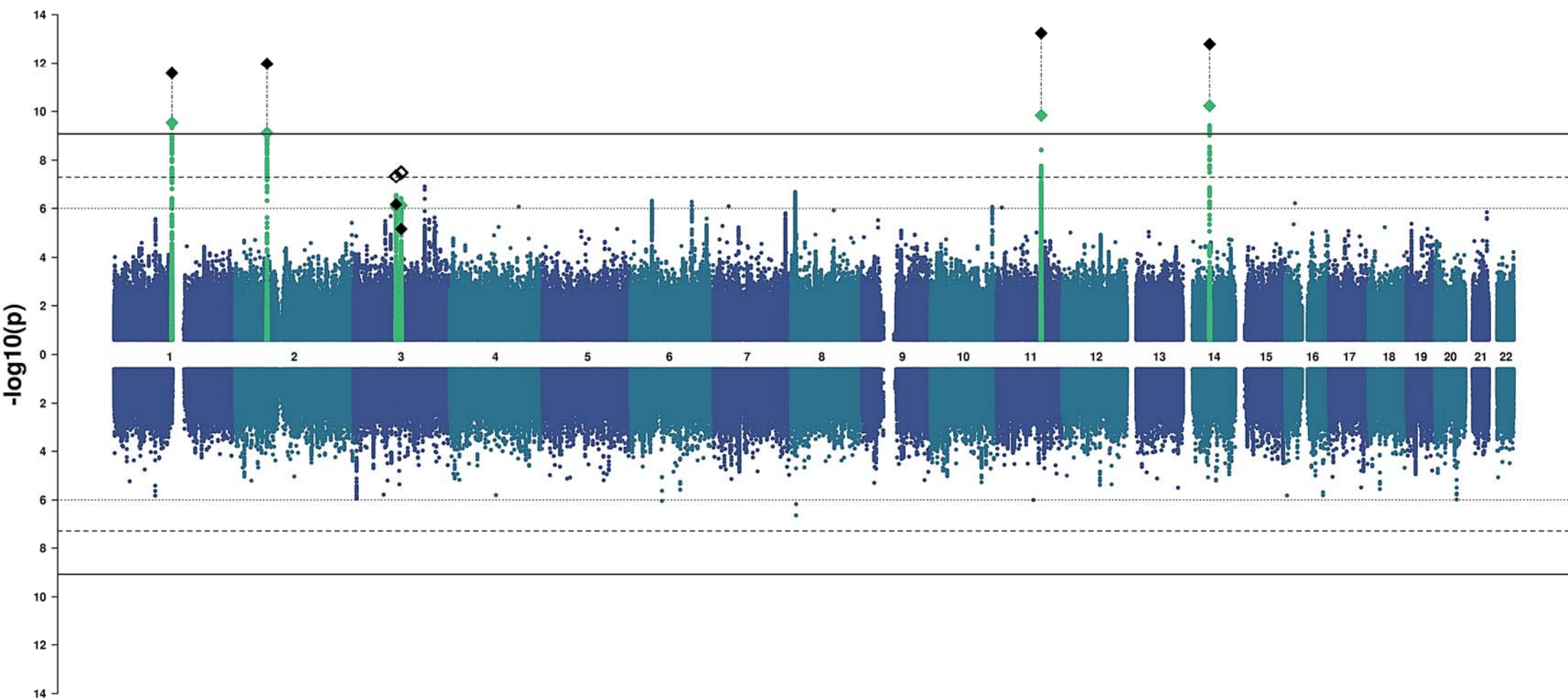
Superior Frontal



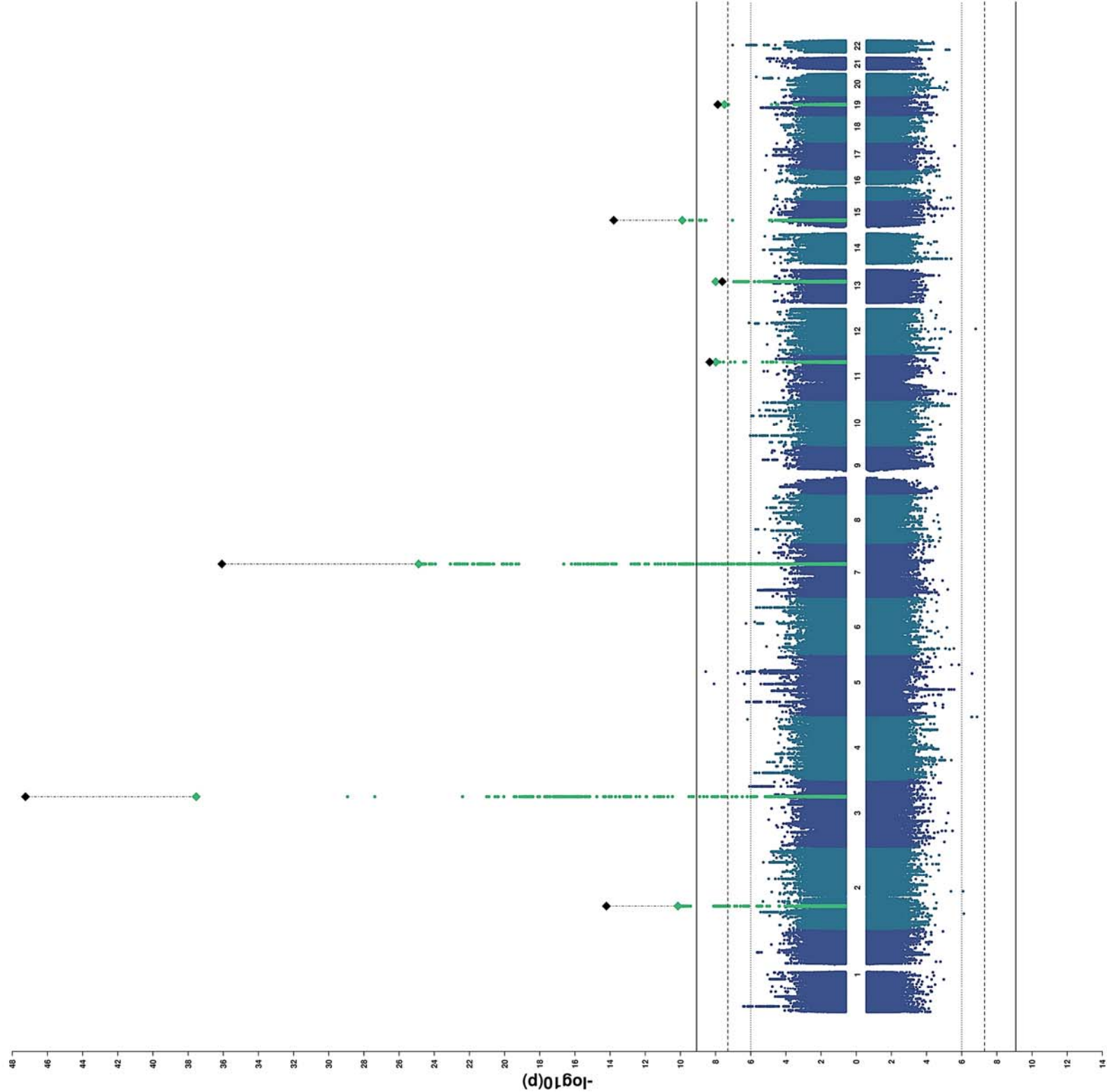
Rostral Middle Frontal



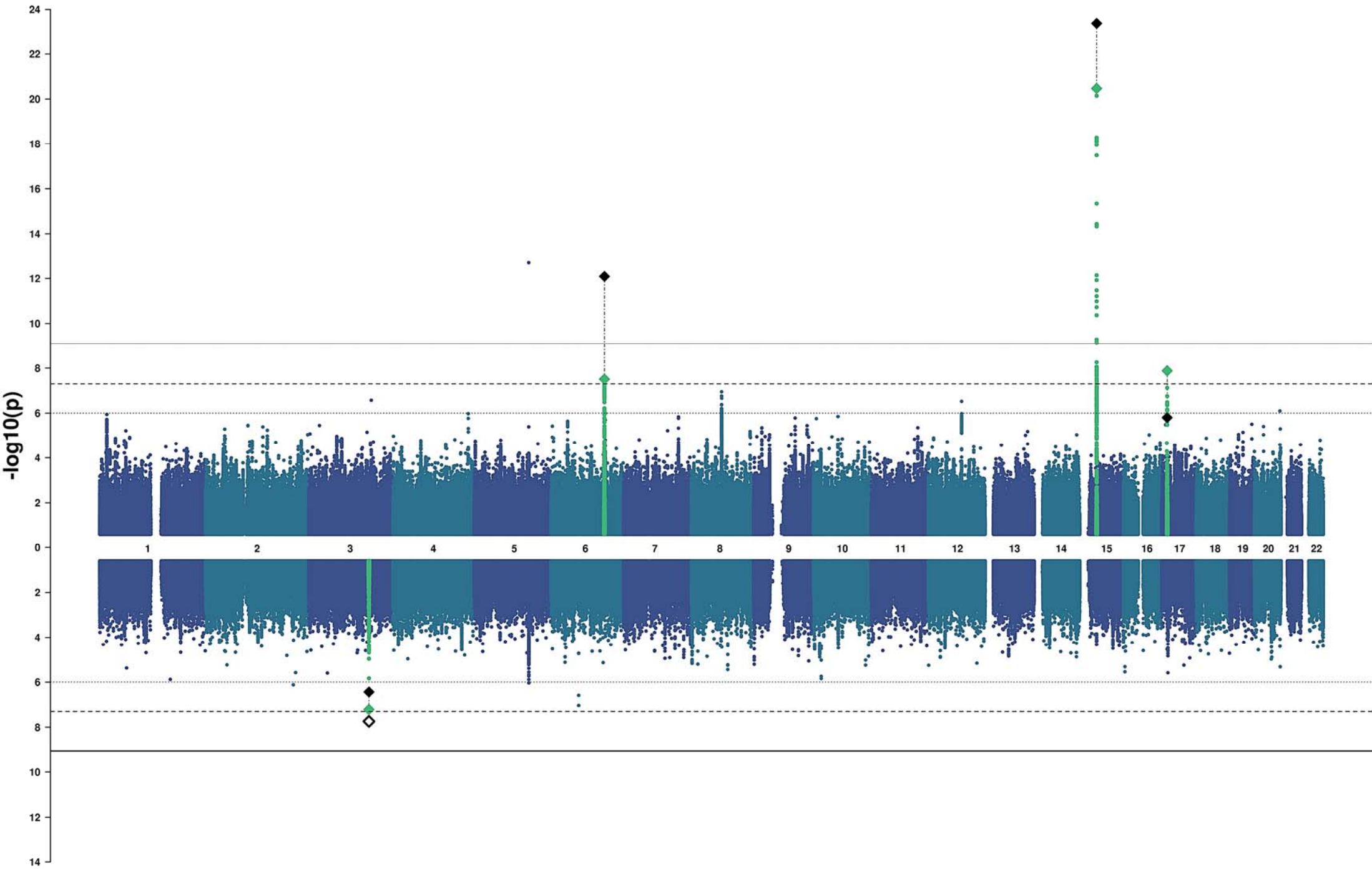
Pars Orbitalis



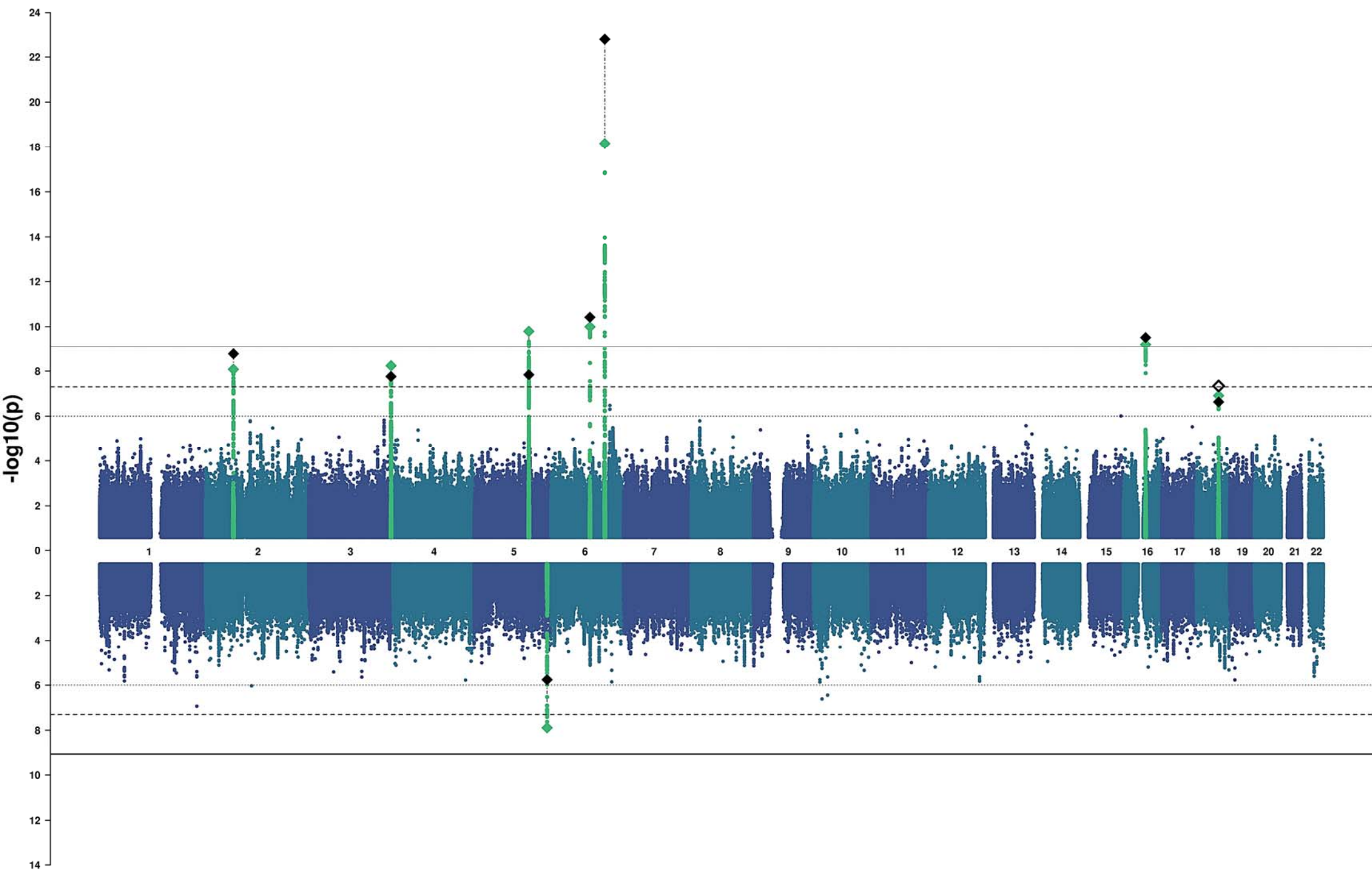
Pars Triangularis



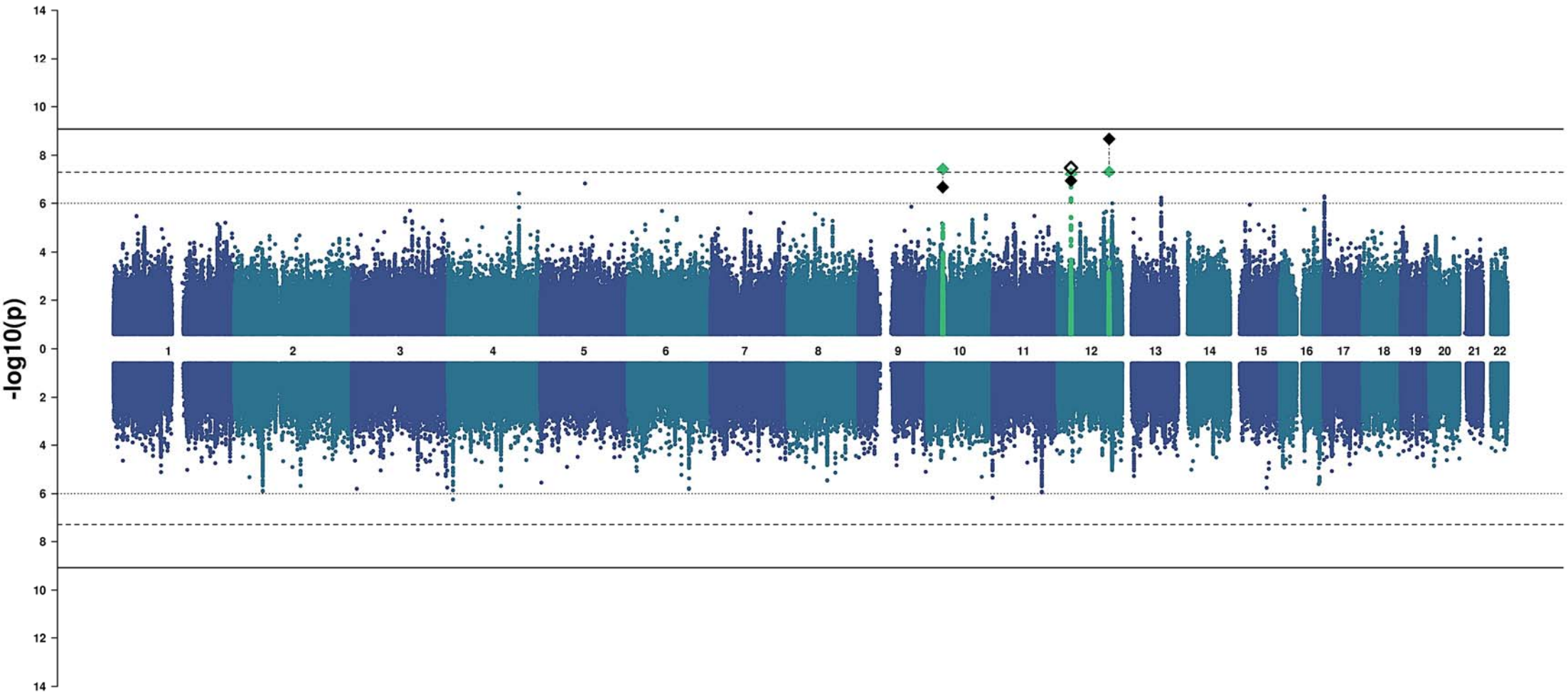
Pars Opercularis



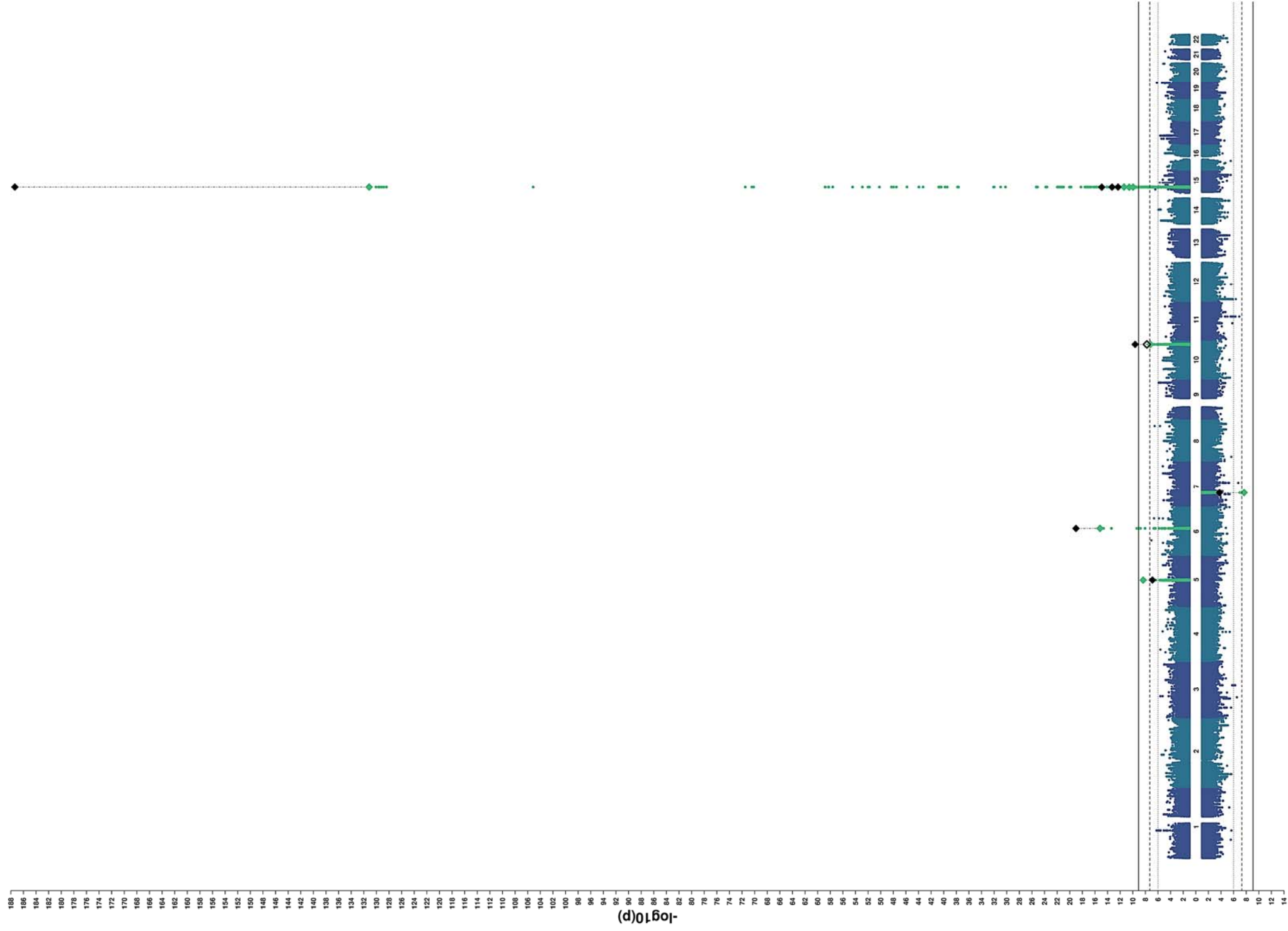
Caudal Middle Frontal



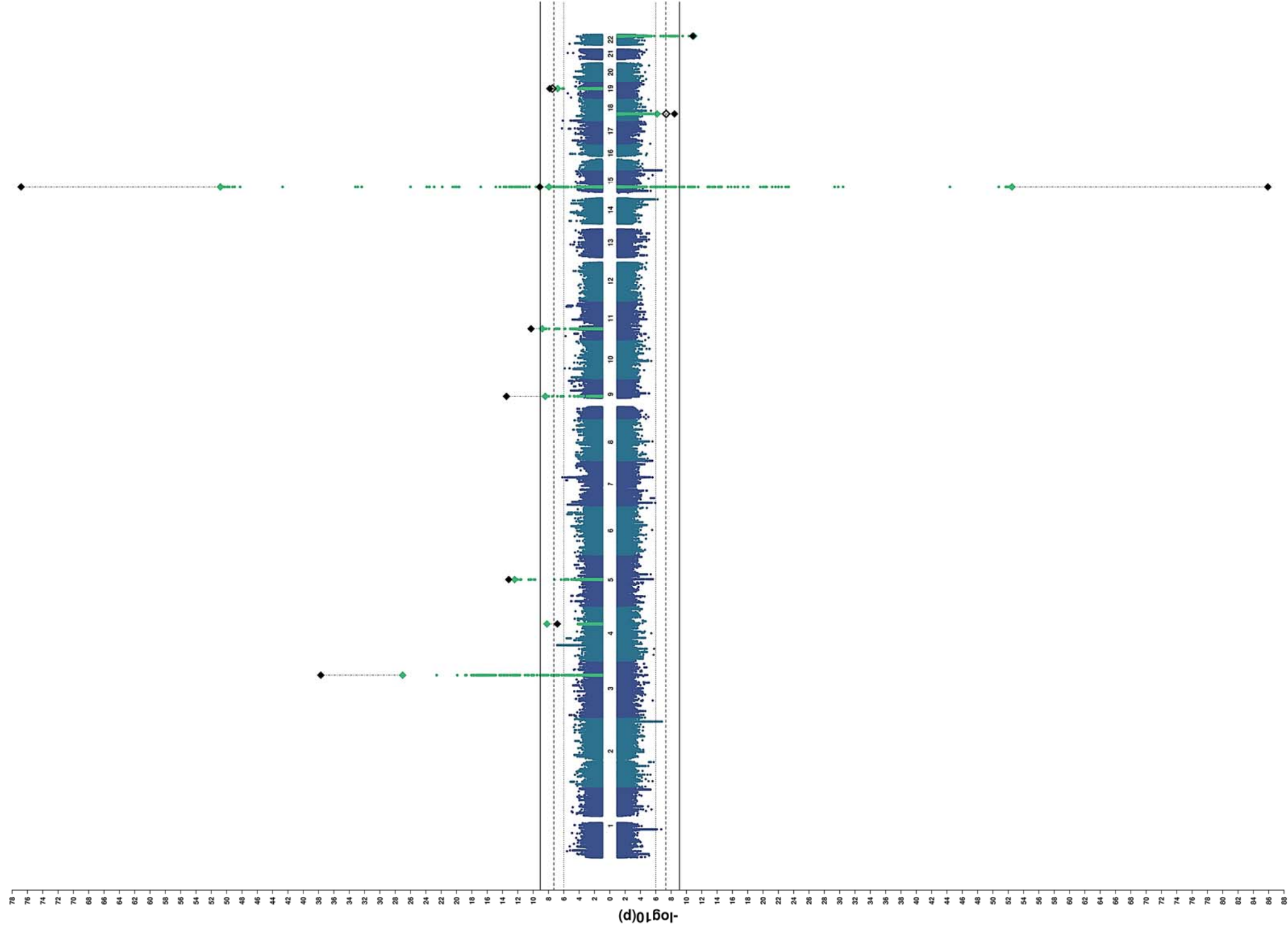
Paracentral



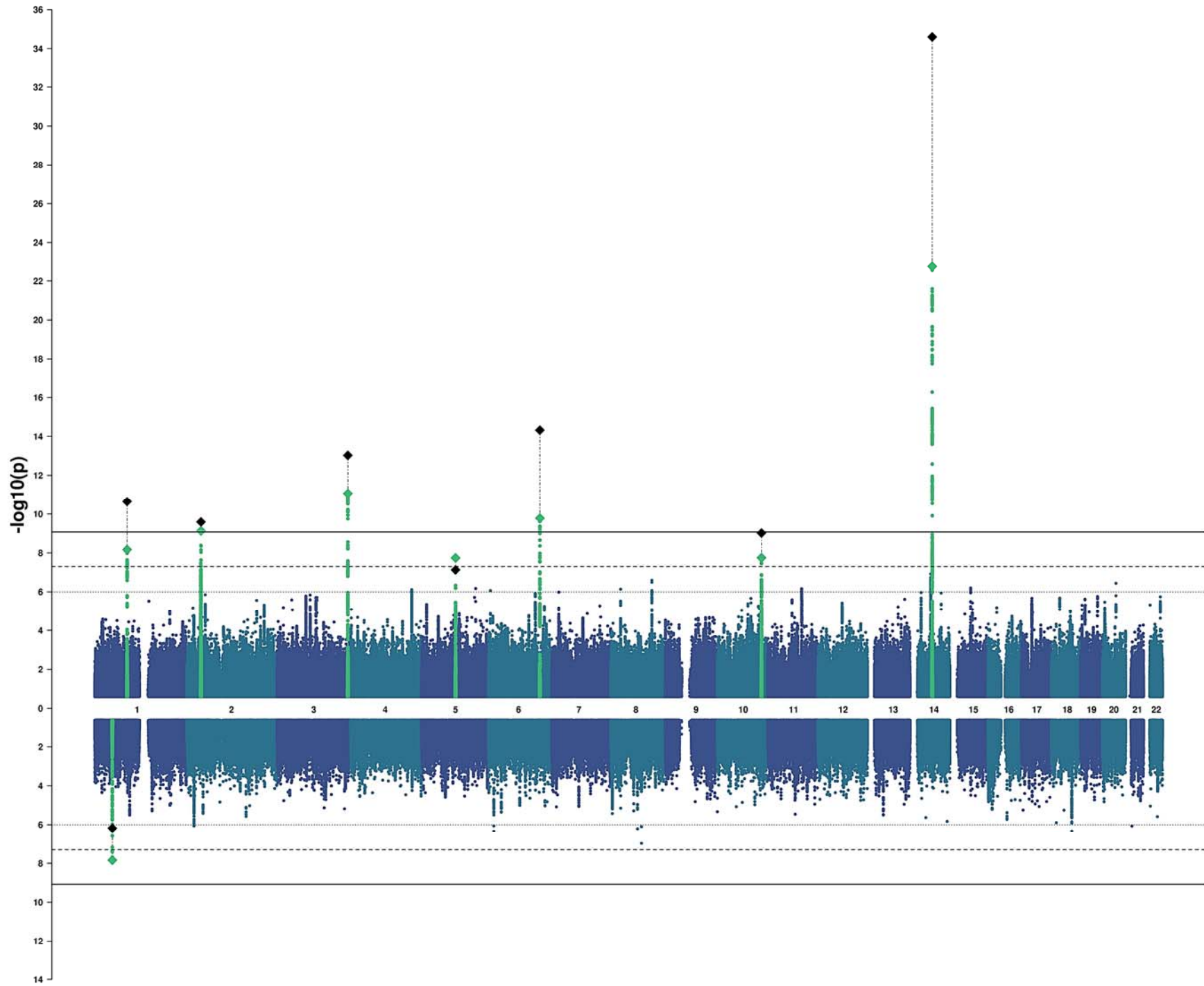
Precentral



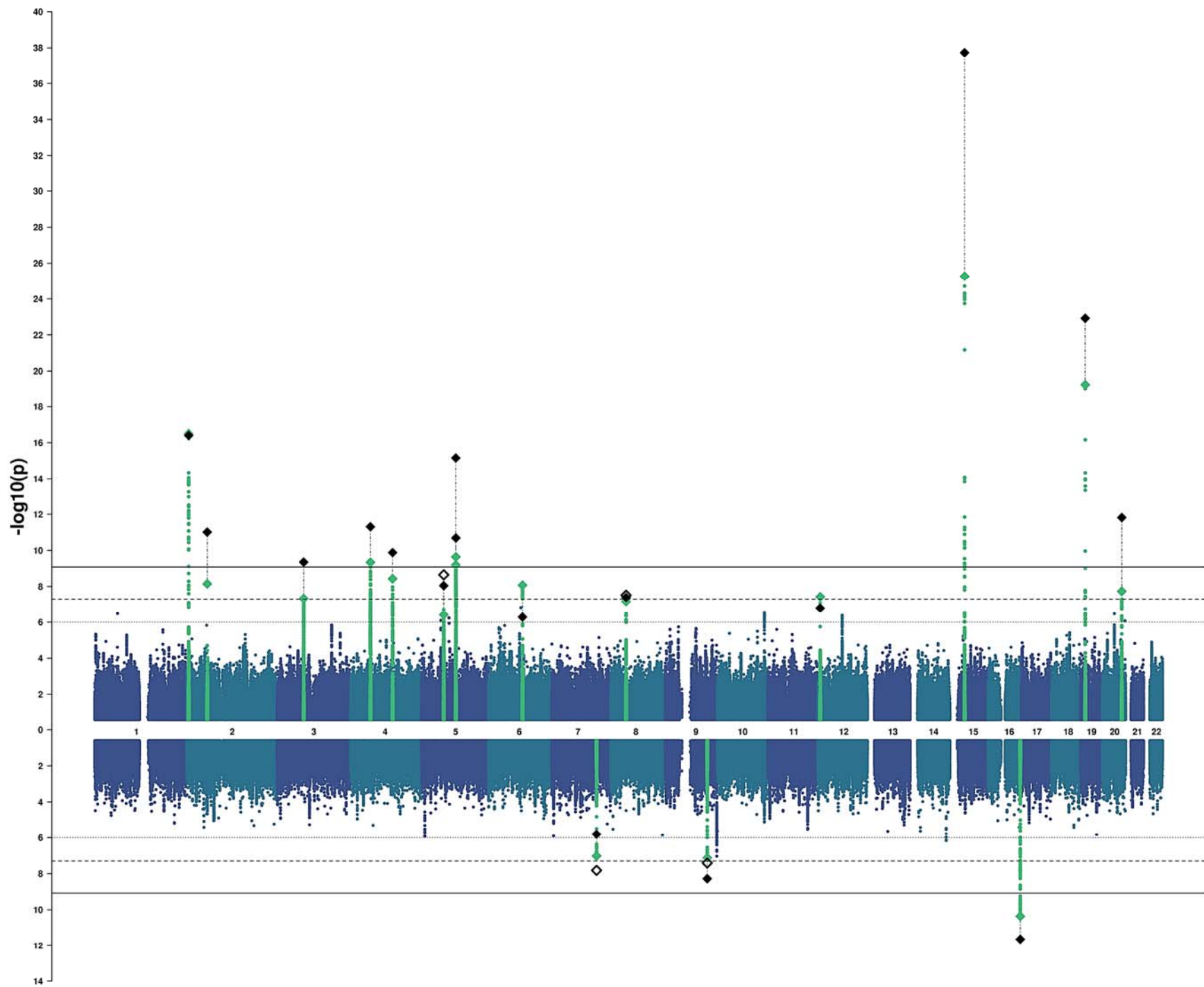
Postcentral



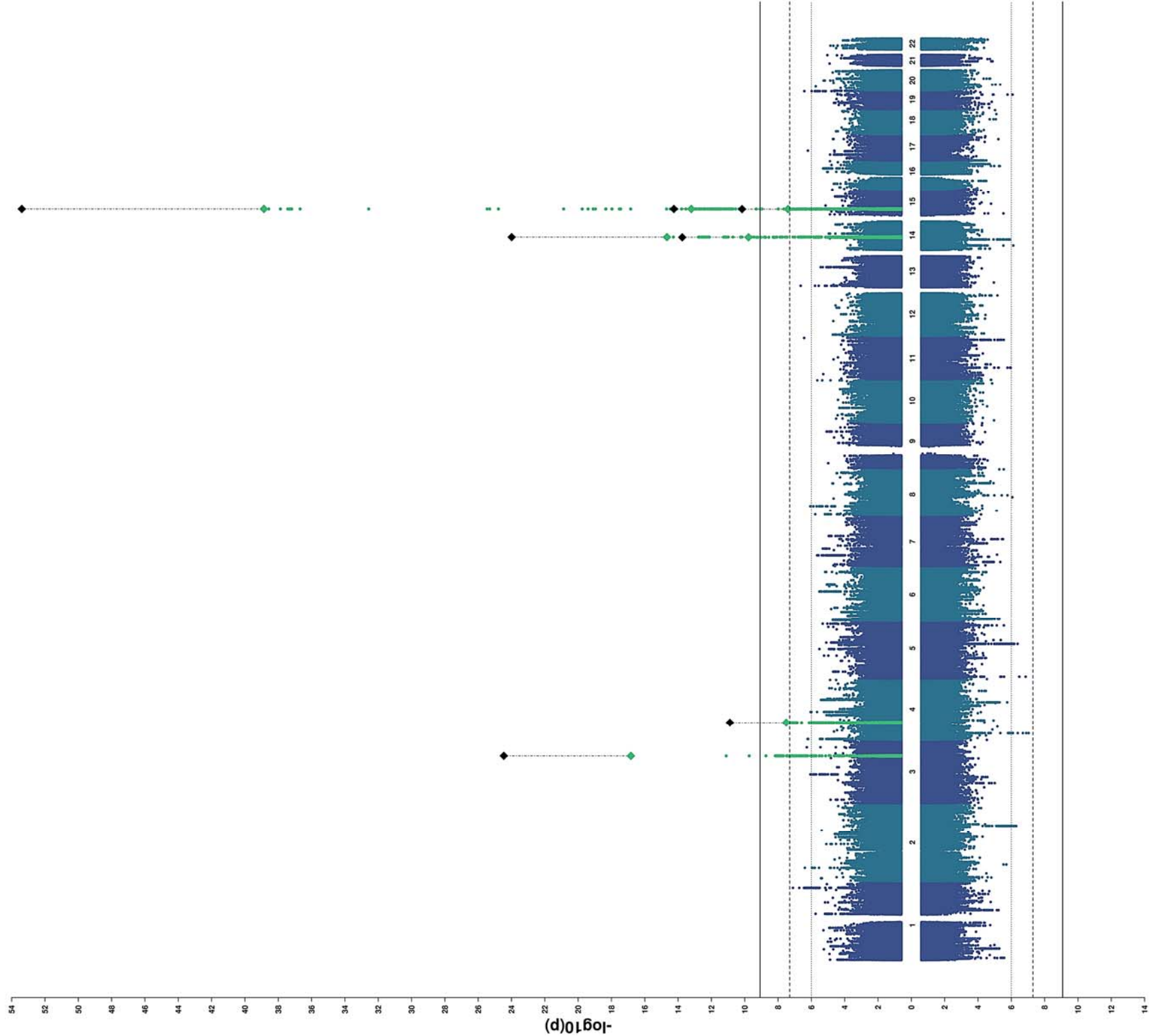
Precuneus



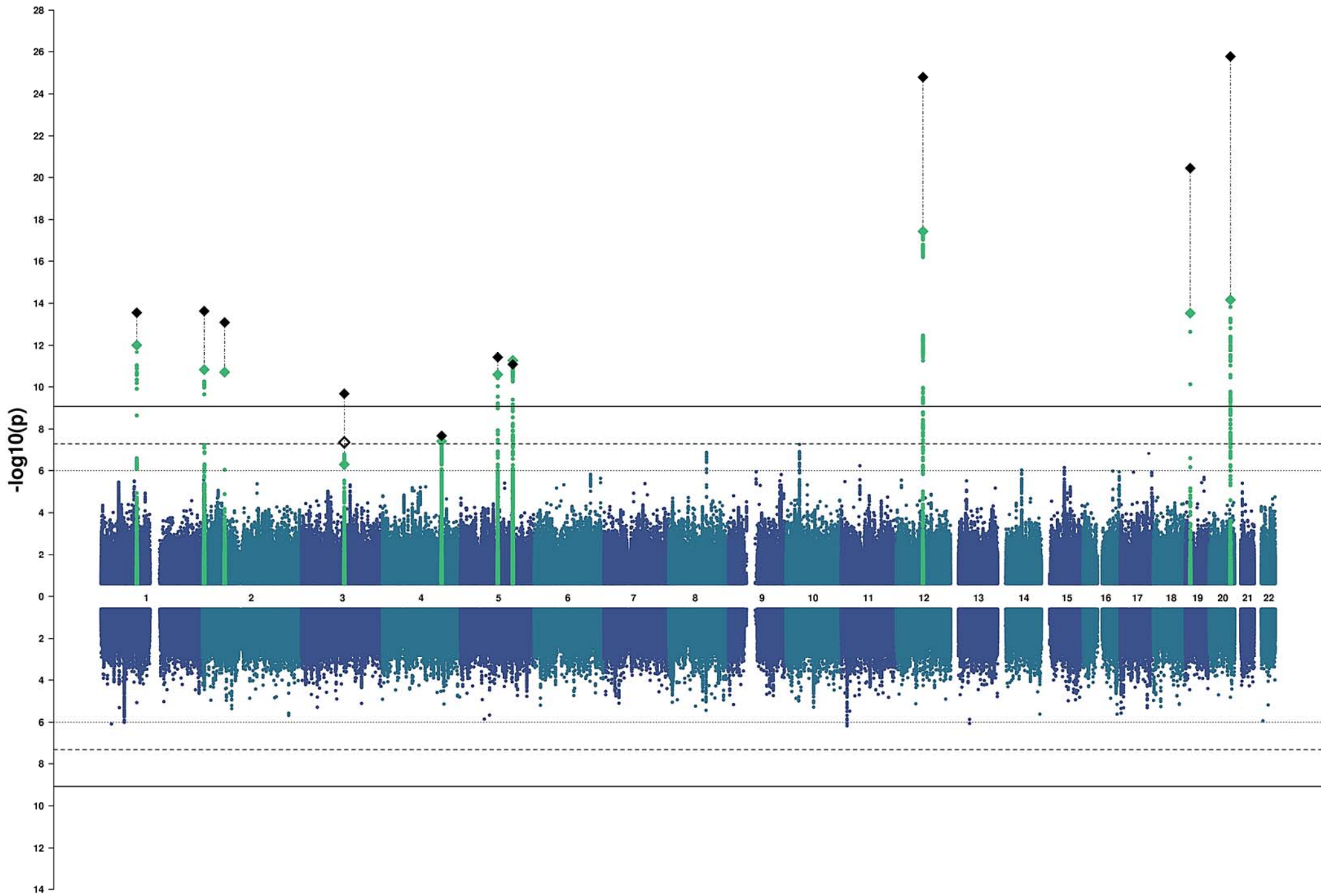
Superior Parietal



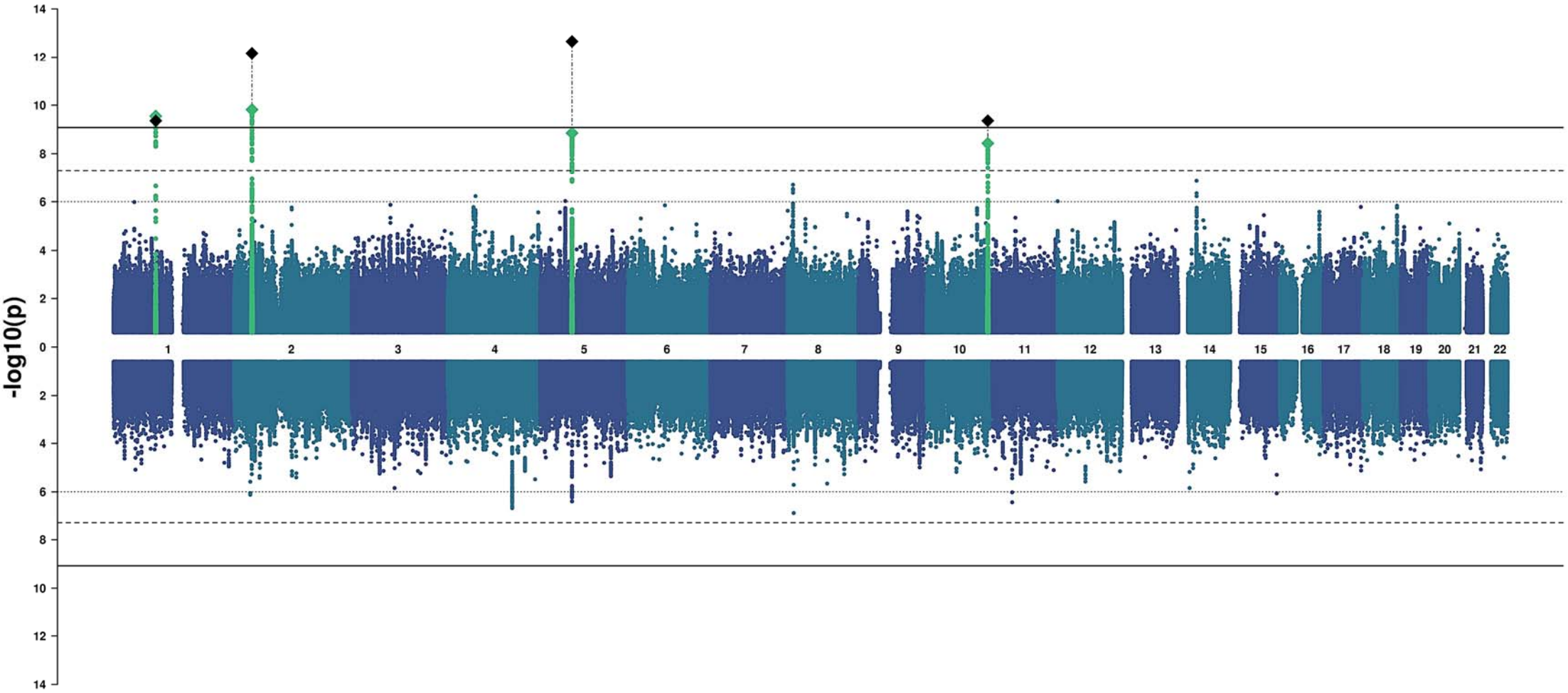
Supramarginal



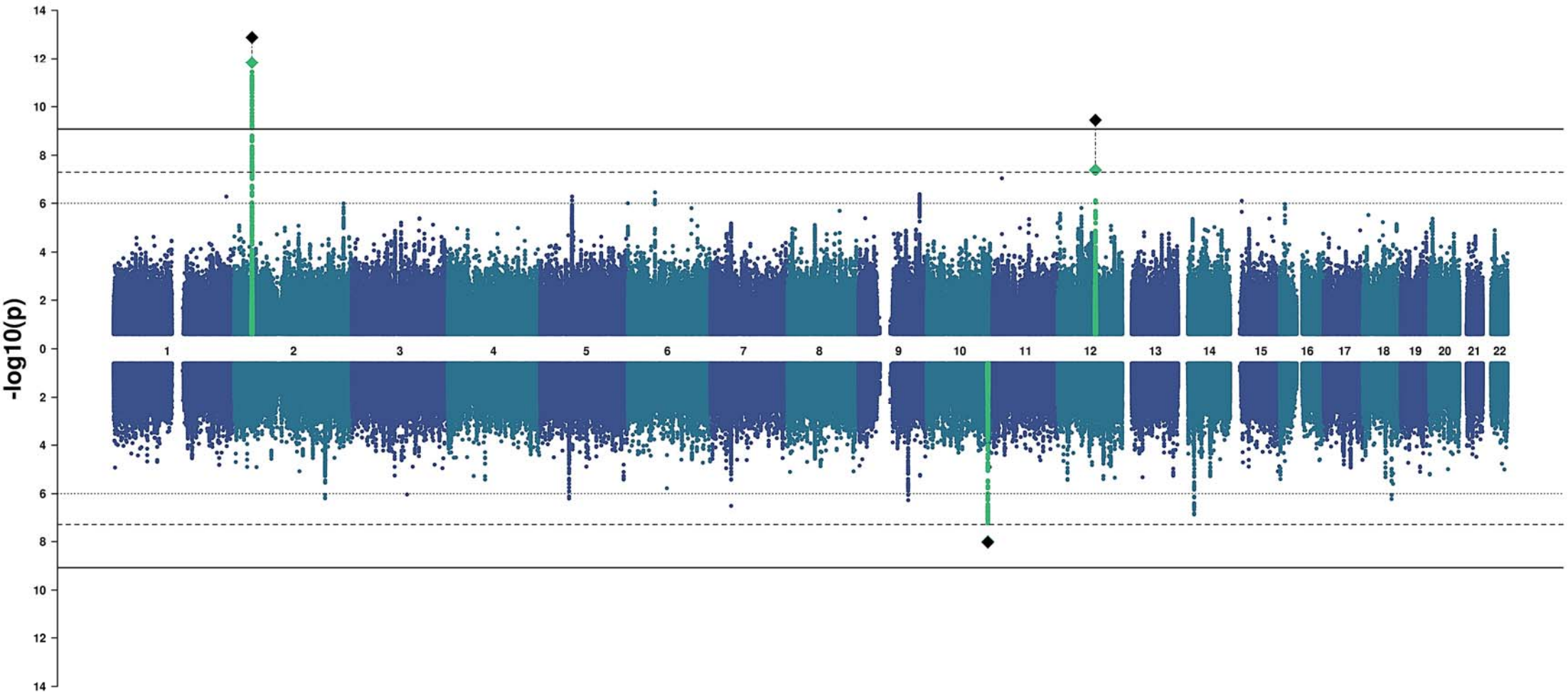
Inferior Parietal



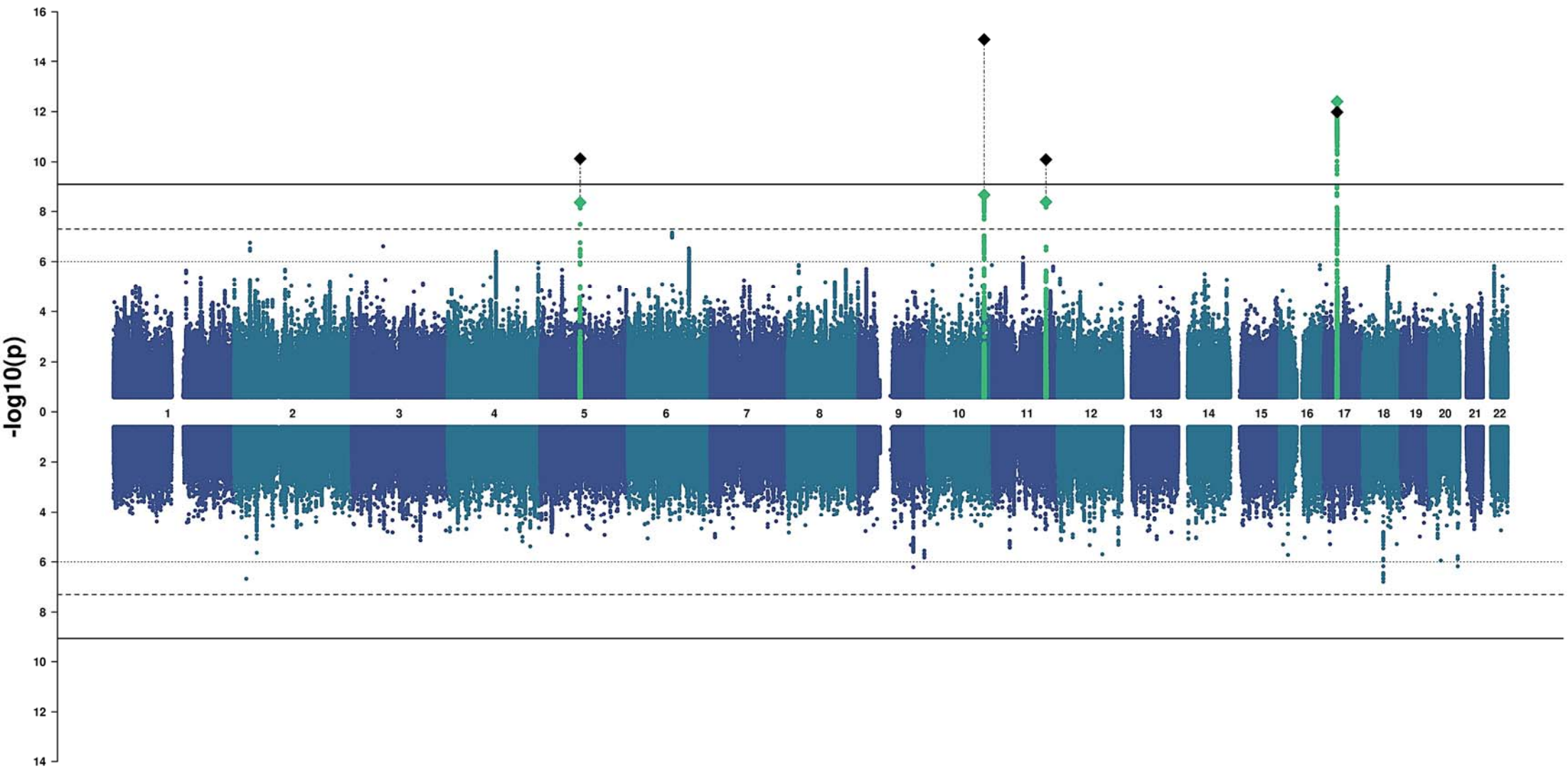
Posterior Cingulate



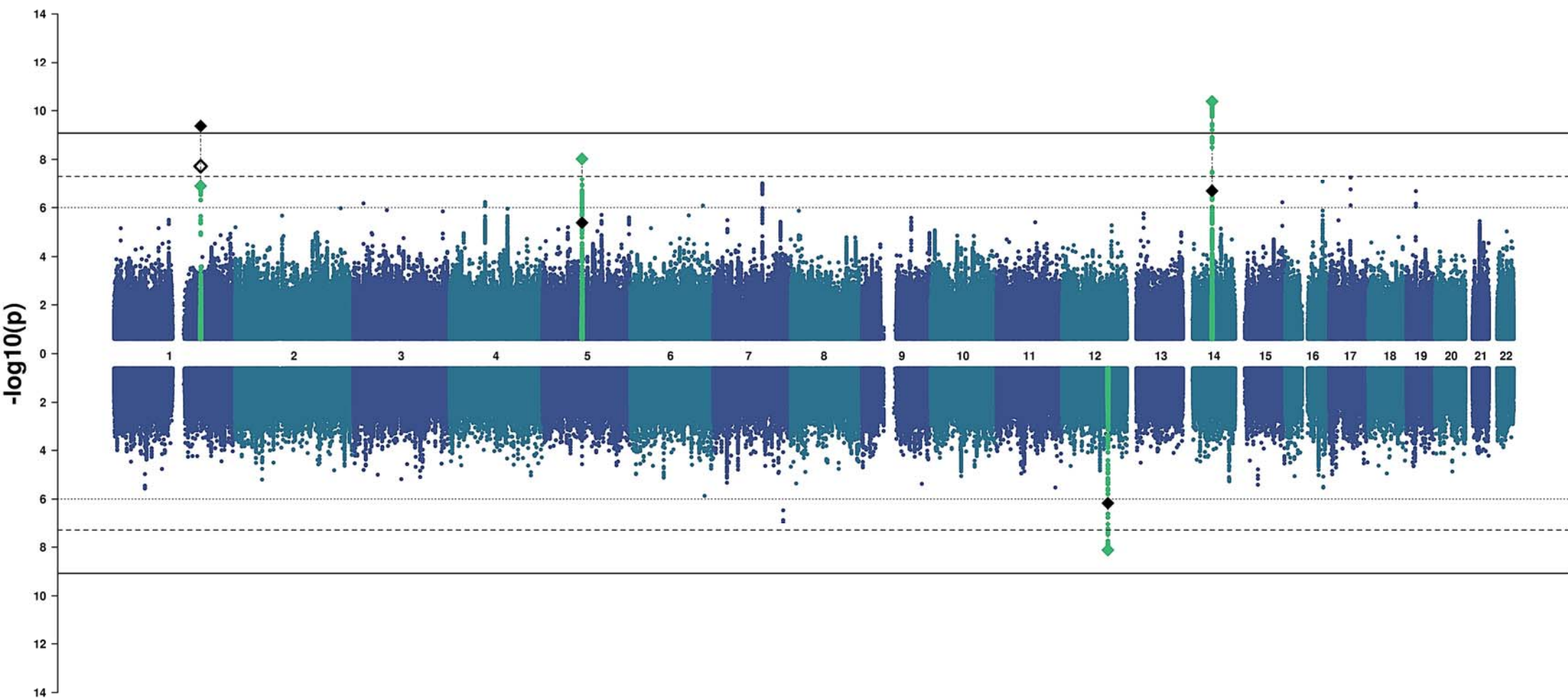
Isthmus Cingulate



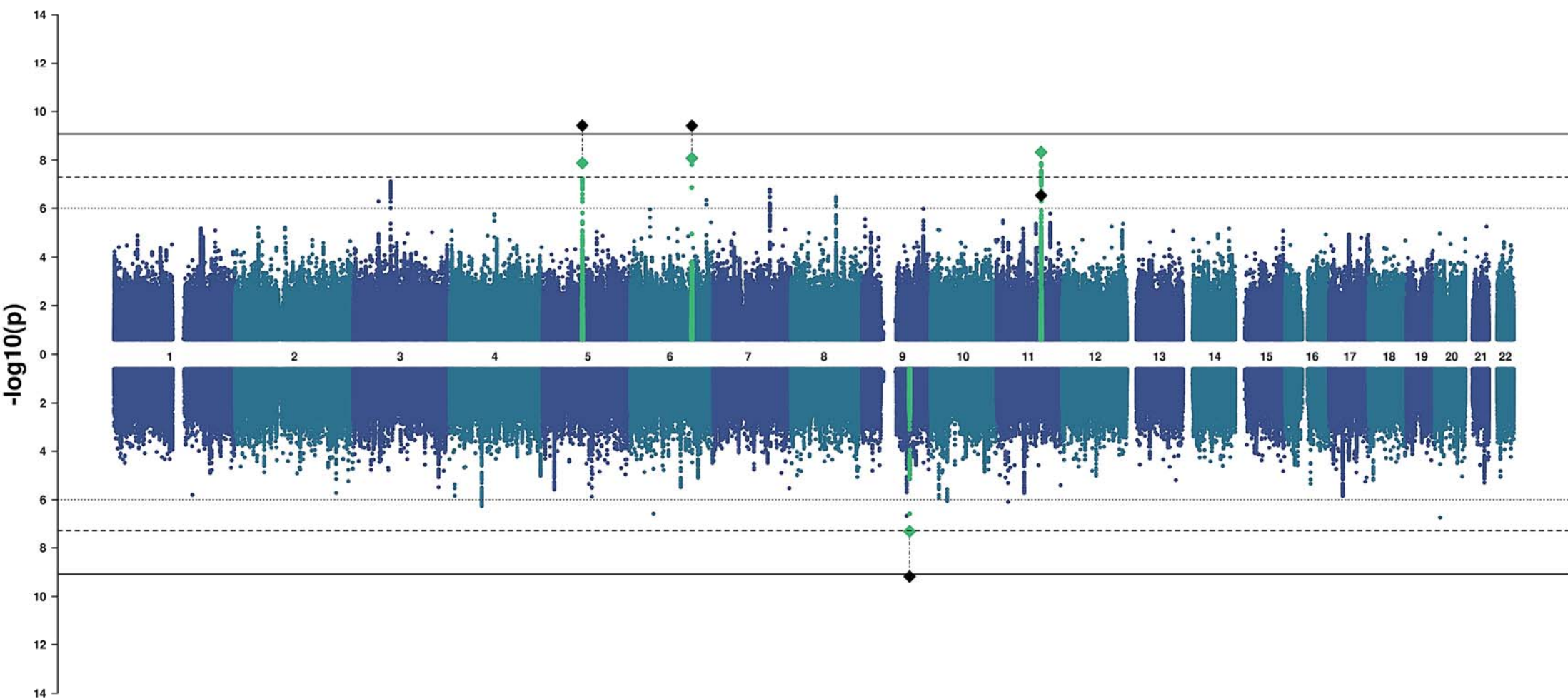
Insula



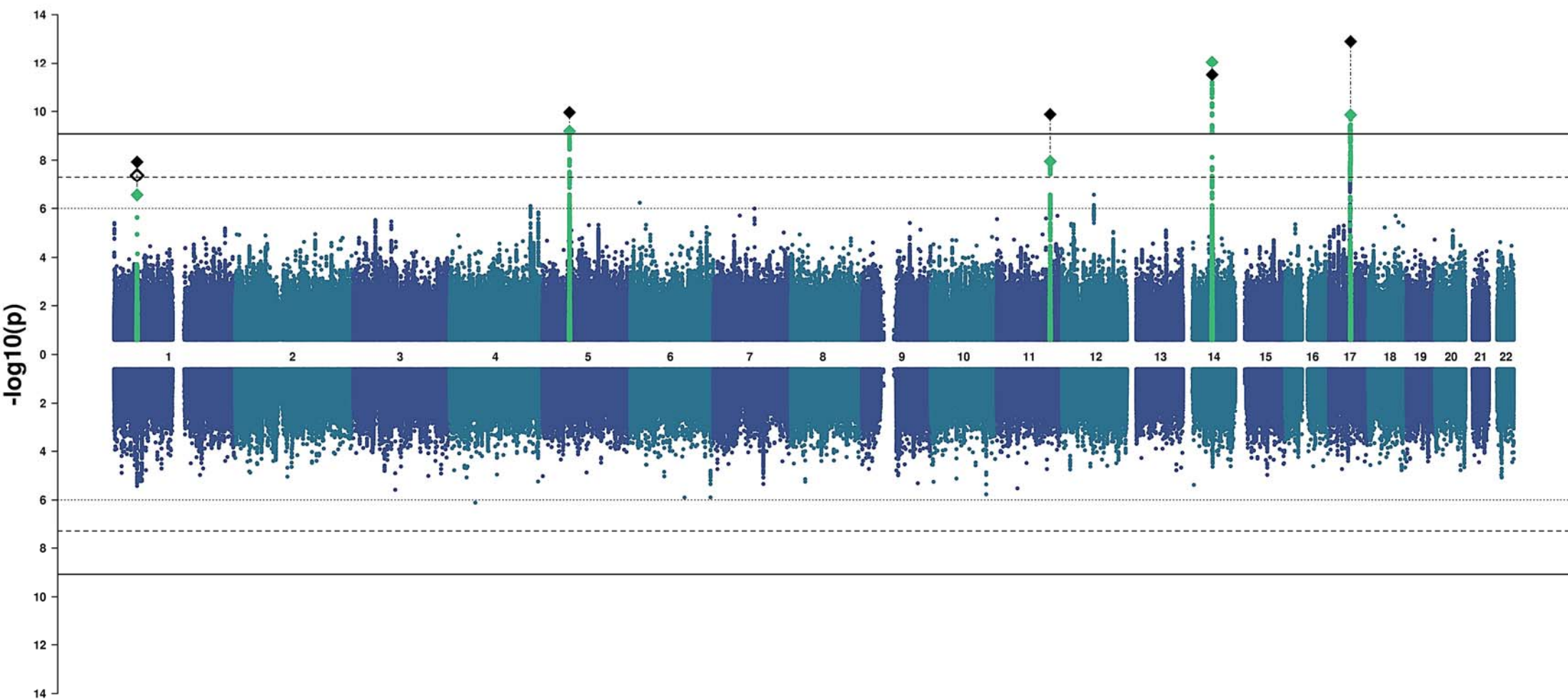
Entorhinal



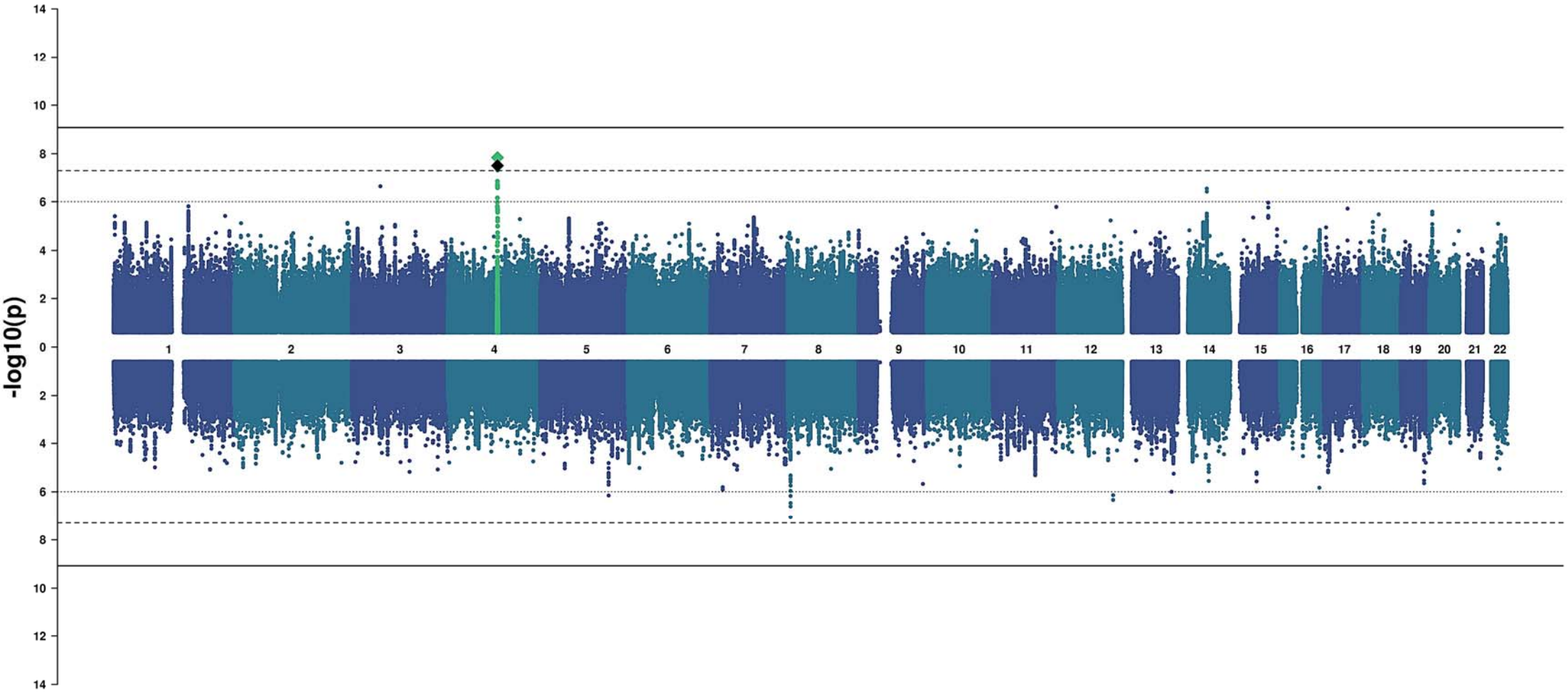
Parahippocampal



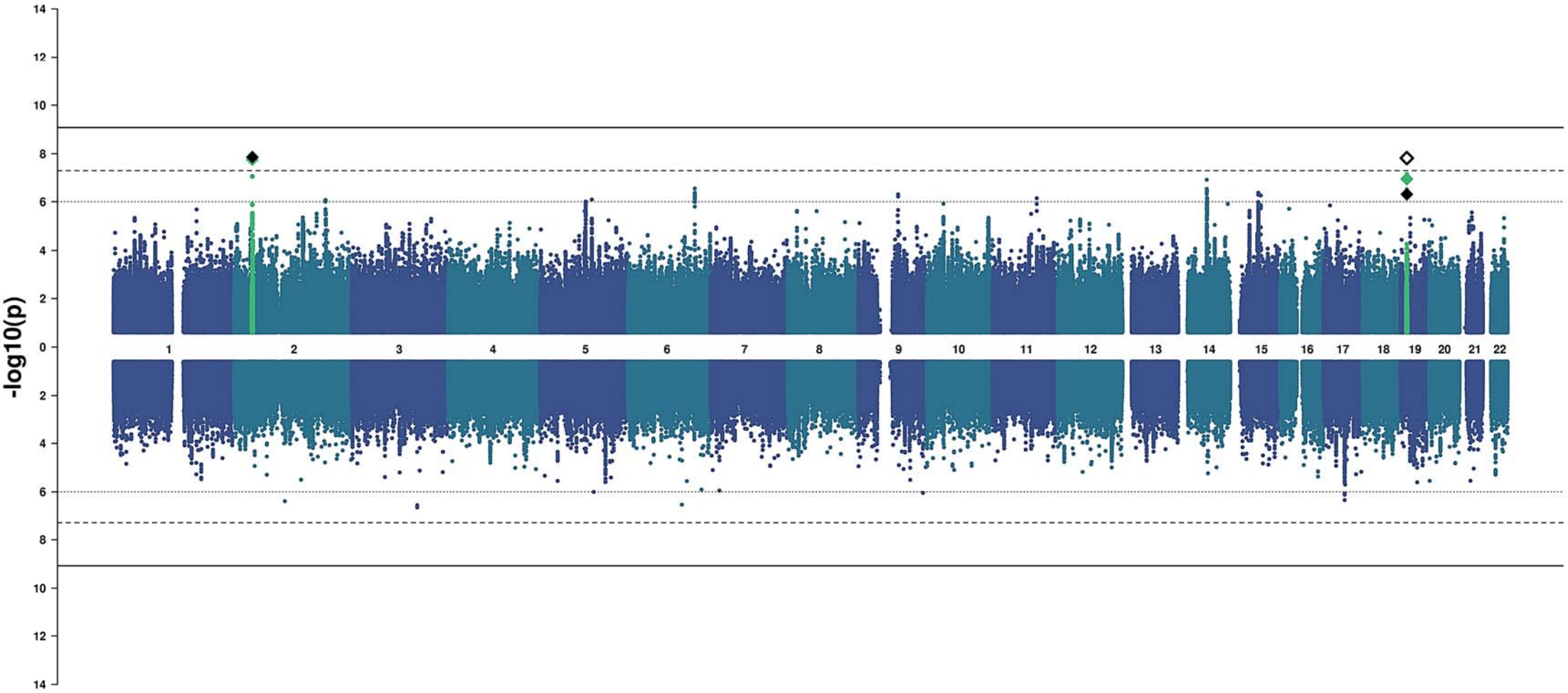
Fusiform



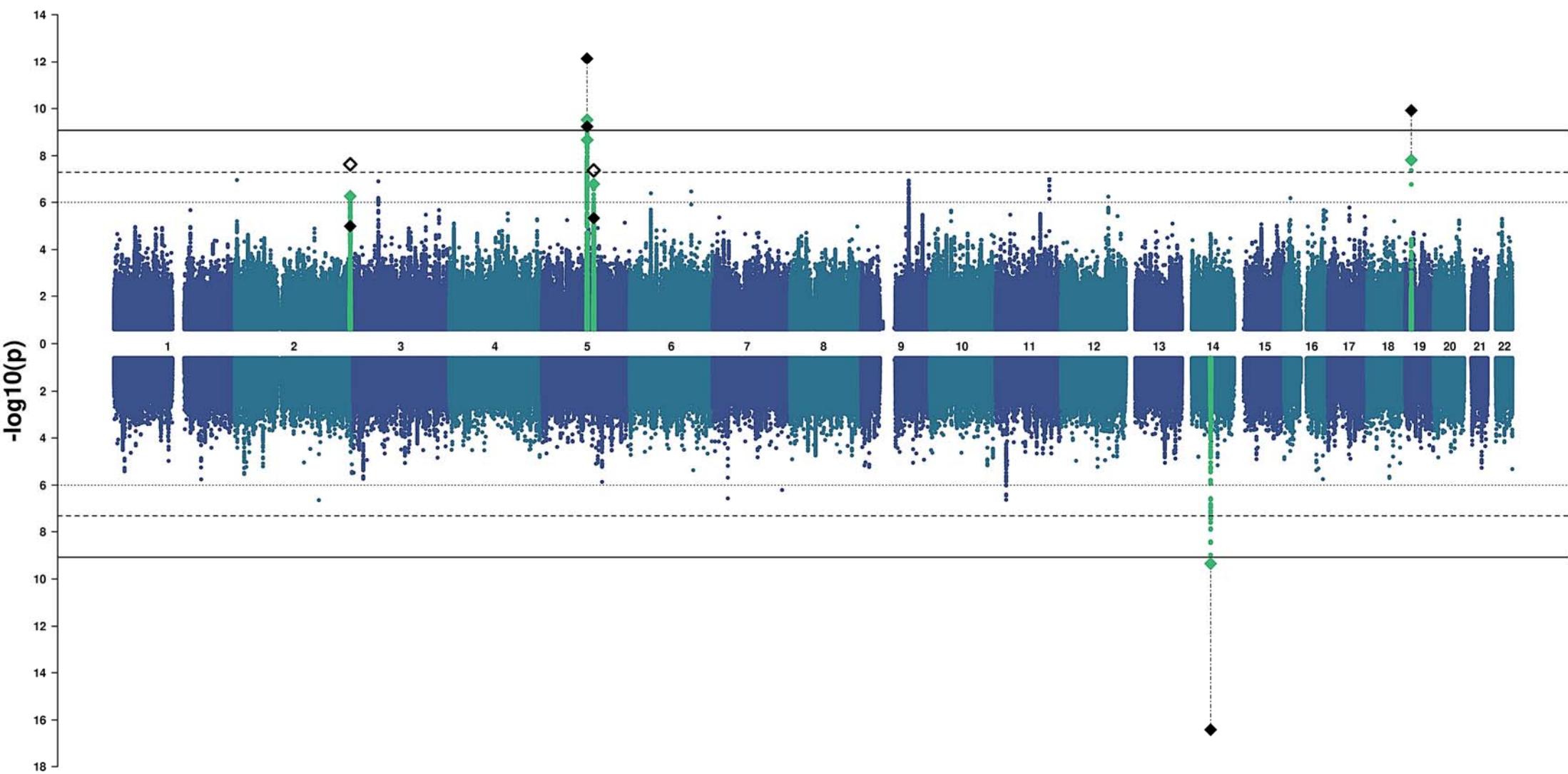
Temporal Pole



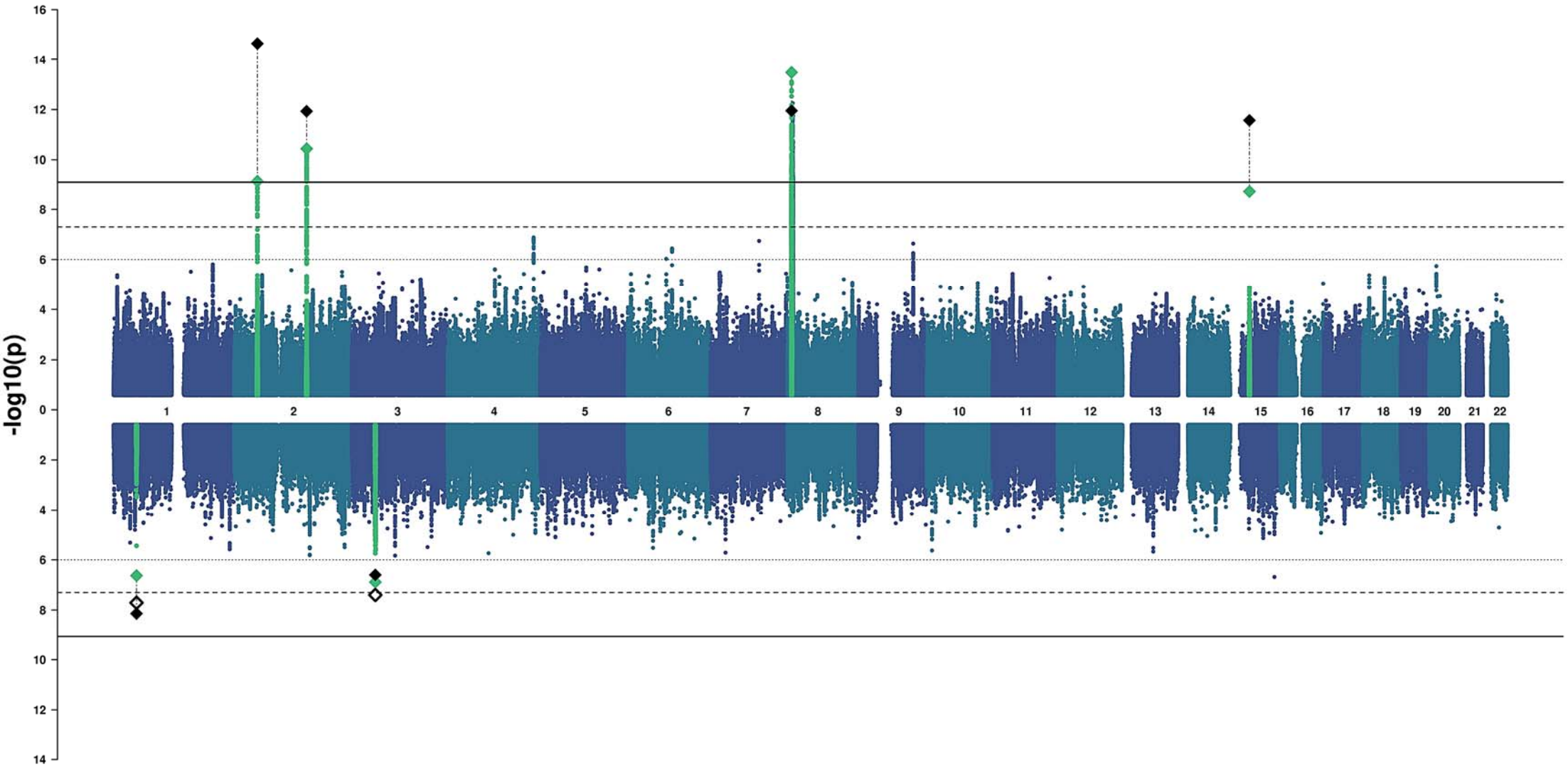
Inferior Temporal



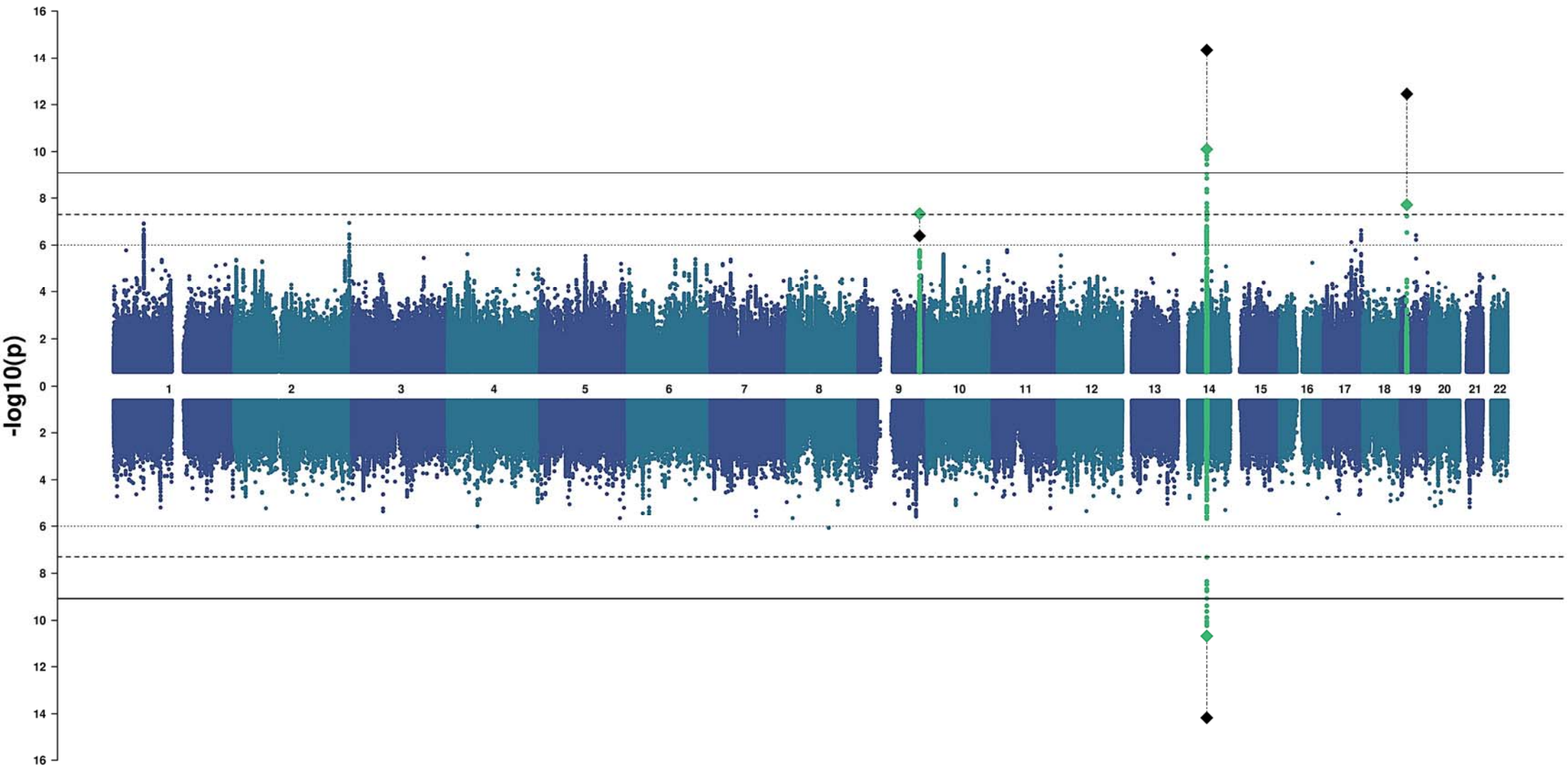
Middle Temporal



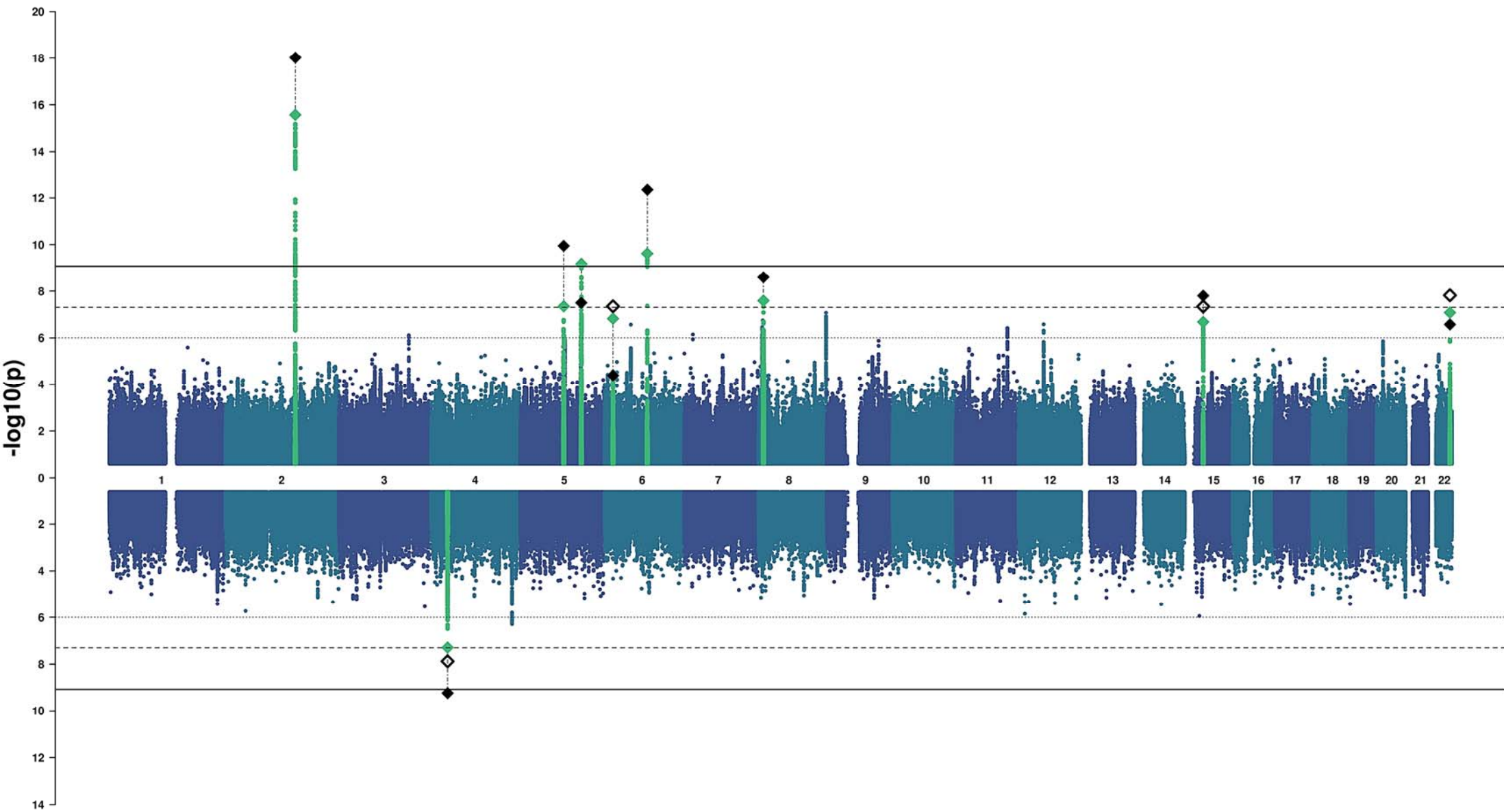
Superior Temporal



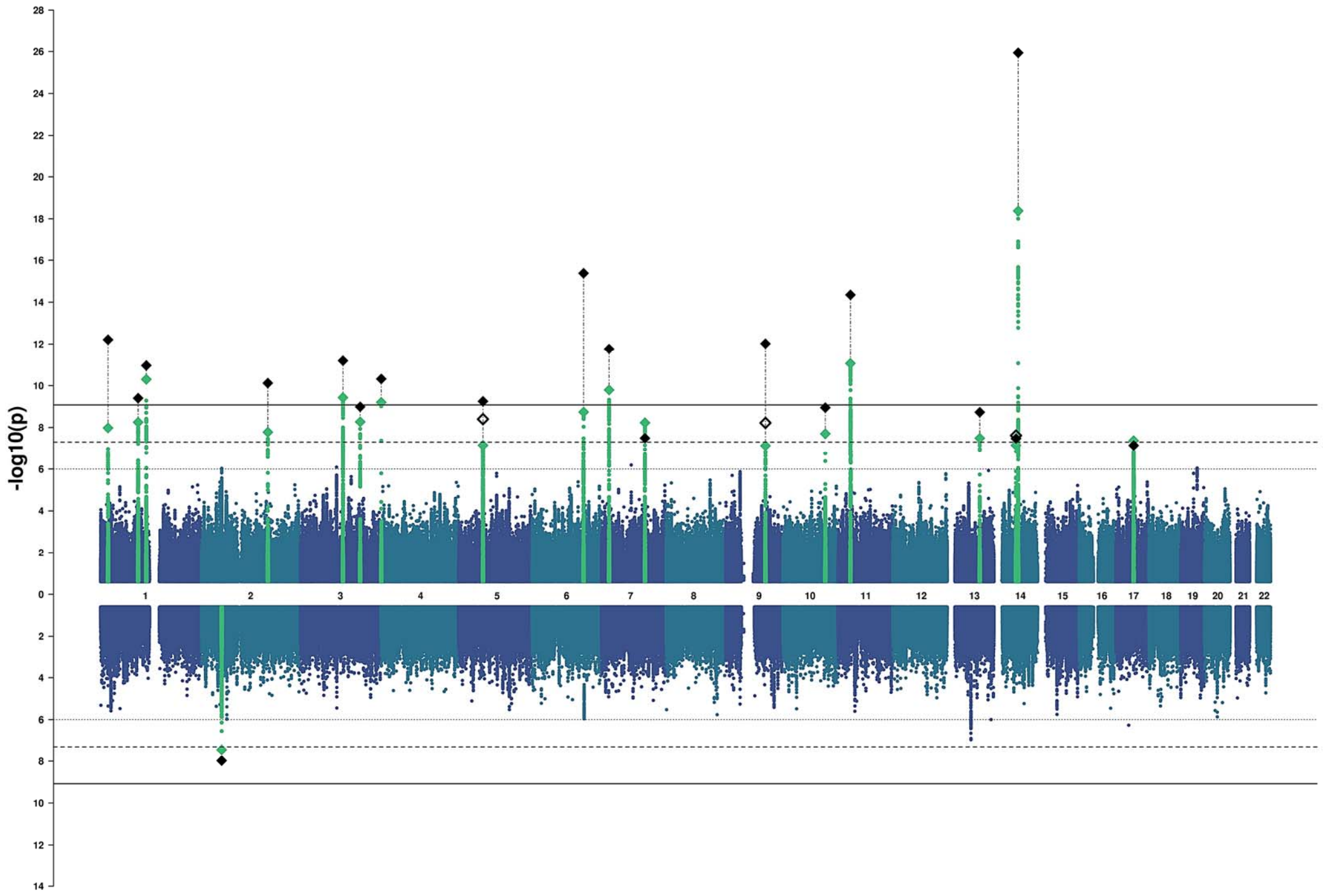
Banks of the Superior Temporal Sulcus



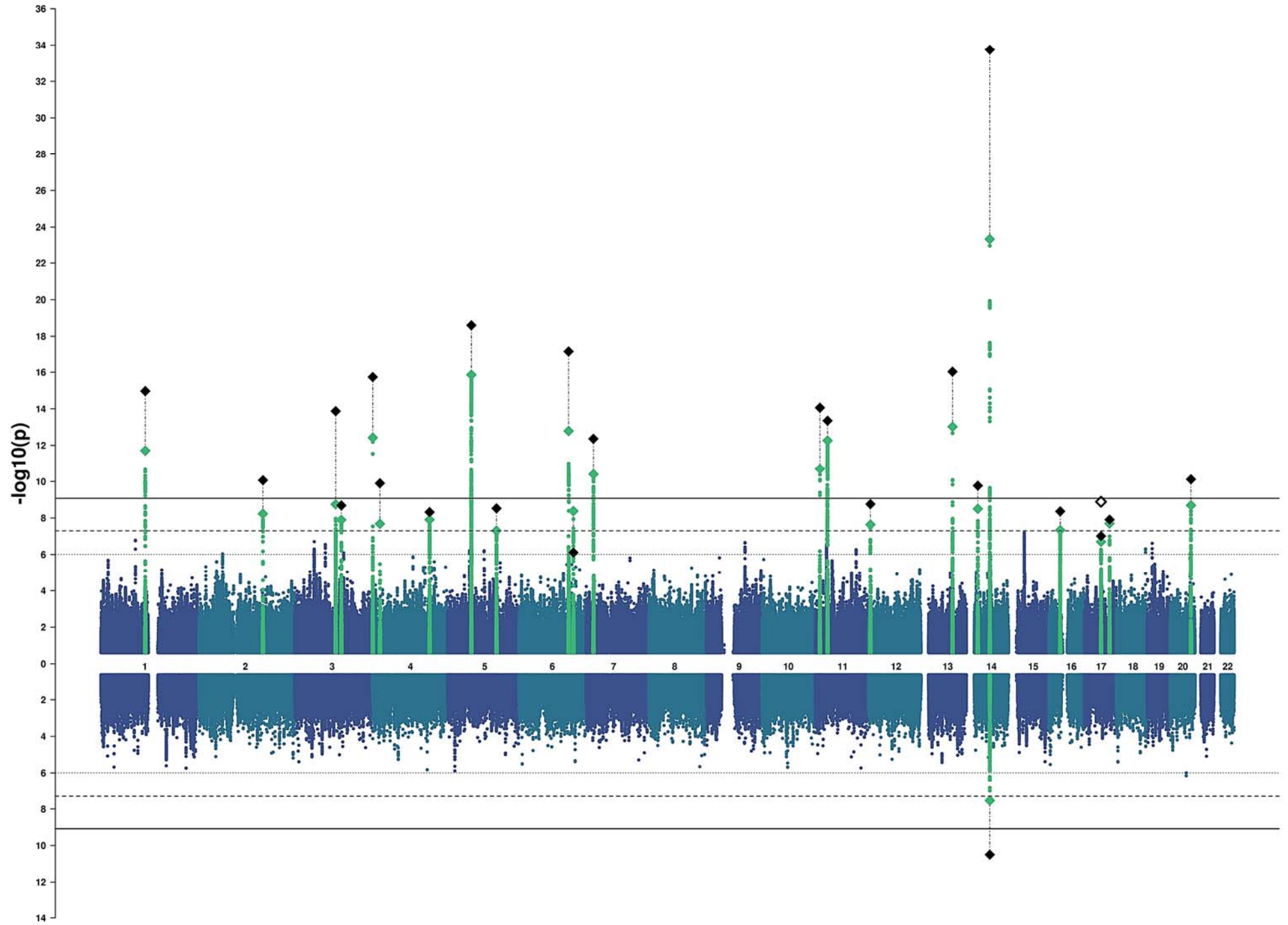
Transverse Temporal



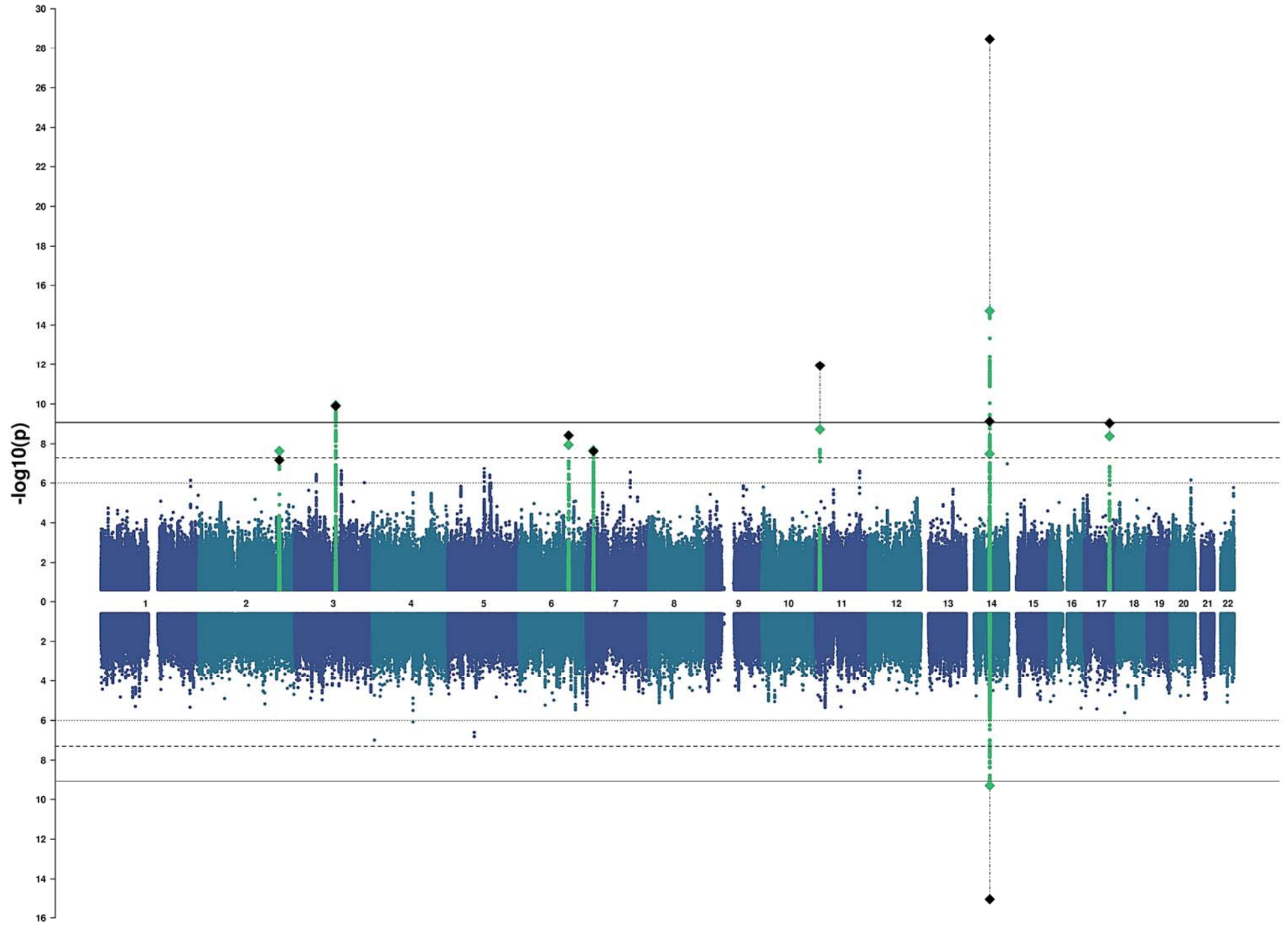
Lingual



Pericalcarine



Cuneus



Lateral Occipital

